

THE ESSENTIAL GUIDE TO PATHOLOGY

# OXFORD HANDBOOK OF CLINICAL PATHOLOGY

James Carton

A quick-reference, portable guide to the pathology of diseases

Provides vital information regarding the underlying pathological mechanisms and specific pathological features of diseases

Describes the definition, epidemiology, pathogenesis, macroscopic and microscopic pathology, and prognosis of each disease

OXFORD MEDICAL PUBLICATIONS

**Oxford Handbook of  
Clinical Pathology**

## Published and forthcoming Oxford Handbooks

Oxford Handbook for the Foundation Programme 3e  
Oxford Handbook of Acute Medicine 3e  
Oxford Handbook of Anaesthesia 3e  
Oxford Handbook of Applied Dental Sciences  
Oxford Handbook of Cardiology 2e  
Oxford Handbook of Clinical and Laboratory Investigation 3e  
Oxford Handbook of Clinical Dentistry 5e  
Oxford Handbook of Clinical Diagnosis 2e  
Oxford Handbook of Clinical Examination and Practical Skills  
Oxford Handbook of Clinical Haematology 3e  
Oxford Handbook of Clinical Immunology and Allergy 2e  
Oxford Handbook of Clinical Medicine—Mini Edition 8e  
Oxford Handbook of Clinical Medicine 8e  
Oxford Handbook of Clinical Pathology  
Oxford Handbook of Clinical Pharmacy 2e  
Oxford Handbook of Clinical Rehabilitation 2e  
Oxford Handbook of Clinical Specialties 8e  
Oxford Handbook of Clinical Surgery 3e  
Oxford Handbook of Complementary Medicine  
Oxford Handbook of Critical Care 3e  
Oxford Handbook of Dental Patient Care 2e  
Oxford Handbook of Dialysis 3e  
Oxford Handbook of Emergency Medicine 4e  
Oxford Handbook of Endocrinology and Diabetes 2e  
Oxford Handbook of ENT and Head and Neck Surgery  
Oxford Handbook of Epidemiology for Clinicians  
Oxford Handbook of Expedition and Wilderness Medicine  
Oxford Handbook of Gastroenterology & Hepatology 2e  
Oxford Handbook of General Practice 3e  
Oxford Handbook of Genitourinary Medicine, HIV, and Sexual Health 2e  
Oxford Handbook of Geriatric Medicine  
Oxford Handbook of Infectious Diseases and Microbiology  
Oxford Handbook of Key Clinical Evidence  
Oxford Handbook of Medical Dermatology  
Oxford Handbook of Medical Imaging  
Oxford Handbook of Medical Sciences  
Oxford Handbook of Neonatology  
Oxford Handbook of Nephrology and Hypertension  
Oxford Handbook of Neurology  
Oxford Handbook of Nutrition and Dietetics 2e  
Oxford Handbook of Obstetrics and Gynaecology 2e  
Oxford Handbook of Occupational Health  
Oxford Handbook of Oncology 3e  
Oxford Handbook of Ophthalmology 2e  
Oxford Handbook of Oral and Maxillofacial Surgery  
Oxford Handbook of Paediatrics  
Oxford Handbook of Pain Management  
Oxford Handbook of Palliative Care 2e  
Oxford Handbook of Practical Drug Therapy 2e  
Oxford Handbook of Pre-Hospital Care  
Oxford Handbook of Psychiatry 2e  
Oxford Handbook of Public Health Practice 2e  
Oxford Handbook of Reproductive Medicine & Family Planning  
Oxford Handbook of Respiratory Medicine 2e  
Oxford Handbook of Rheumatology 3e  
Oxford Handbook of Sport and Exercise Medicine  
Oxford Handbook of Tropical Medicine 3e  
Oxford Handbook of Urology 2e

# Oxford Handbook of Clinical Pathology

**James Carton**

Consultant Histopathologist and  
Honorary Senior Lecturer  
Imperial College Healthcare NHS Trust  
St Mary's Hospital  
London, UK

**OXFORD**  
UNIVERSITY PRESS

# OXFORD

UNIVERSITY PRESS

Great Clarendon Street, Oxford OX2 6DP

Oxford University Press is a department of the University of Oxford.  
It furthers the University's objective of excellence in research, scholarship,  
and education by publishing worldwide in

Oxford New York

Auckland Cape Town Dar es Salaam Hong Kong Karachi  
Kuala Lumpur Madrid Melbourne Mexico City Nairobi  
New Delhi Shanghai Taipei Toronto

With offices in

Argentina Austria Brazil Chile Czech Republic France Greece  
Guatemala Hungary Italy Japan Poland Portugal Singapore  
South Korea Switzerland Thailand Turkey Ukraine Vietnam

Oxford is a registered trade mark of Oxford University Press  
in the UK and in certain other countries

Published in the United States  
by Oxford University Press Inc., New York

© Oxford University Press 2012

The moral rights of the author have been asserted  
Database right Oxford University Press (maker)

First published 2012

All rights reserved. No part of this publication may be reproduced,  
stored in a retrieval system, or transmitted, in any form or by any means,  
without the prior permission in writing of Oxford University Press,  
or as expressly permitted by law, or under terms agreed with the appropriate  
reprographics rights organization. Enquiries concerning reproduction  
outside the scope of the above should be sent to the Rights Department,  
Oxford University Press, at the address above

You must not circulate this book in any other binding or cover  
and you must impose the same condition on any acquirer

British Library Cataloguing in Publication Data  
Data available

Library of Congress Cataloging-in-Publication Data  
Carton, James.

Oxford handbook of clinical pathology / James Carton.

p.; cm.—(Oxford handbooks)

Handbook of clinical pathology

Includes index.

ISBN 978-0-19-959163-3 (alk. paper)

I. Title. II. Title: Handbook of clinical pathology. III. Series: Oxford handbooks.

[DNLM: 1. Pathology, Clinical—methods—Handbooks. QY 39]

LC classification not assigned

616.07—dc23

2011033029

Typeset by Cenveo, Bangalore, India  
Printed in China on acid-free paper through  
Asia Pacific Offset

ISBN 978-0-19-959163-3

10 9 8 7 6 5 4 3 2 1

## **Dedication**

To my parents, Paul and Shirley,  
for all they have done for me,  
and to Rob for making me so happy.

# Preface

This first edition of the *Oxford Handbook of Clinical Pathology* was written with the aim of producing a pocket-sized book which concisely conveys the key pathology relevant to clinical practice.

The handbook covers both general and systems-based pathology with each topic occupying either a single- or double-page spread. A uniform sequence of headings is followed for each topic to allow easy access to the facts.

Although aimed primarily at medical students, this handbook should also be useful for postgraduate doctors working in specialties with close links to pathology.

I hope you find this handbook helpful and easy to learn from. Feedback on errors and omissions would be much appreciated. Please post your comments via the OUP website ([www.oup.co.uk/medicine/handbooks](http://www.oup.co.uk/medicine/handbooks)).

James Carton  
2011

# Acknowledgments

Although written by a single author, this book would not have been possible without the help and support of many other people. First and foremost, I thank Richard Daly, co-author on my previous publication, for his incredible professionalism and grace during difficult times. Secondly, I thank all my consultant colleagues at St Mary's Hospital for creating an environment in which projects like this are encouraged and supported. Finally, thank you to all the wonderful staff at OUP: Elizabeth Reeve, Anna Winstanley, Michael Hawkes, and Eloise Moir-Ford.



Oxford University Press makes no representation, express or implied, that the drug dosages in this book are correct. Readers must therefore always check the product information and clinical procedures with the most up-to-date published product information and data sheets provided by the manufacturers and the most recent codes of conduct and safety regulations. The authors and the publishers do not accept responsibility or legal liability for any errors in the text or for the misuse or misapplication of material in this work.

# Contents

Detailed contents *xi*

Symbols and abbreviations *xx*

1	Basic pathology	1
2	Infectious diseases	15
3	Vascular pathology	27
4	Cardiac pathology	39
5	Respiratory pathology	57
6	Gastrointestinal pathology	83
7	Hepatobiliary pathology	115
8	Pancreatic pathology	131
9	Renal pathology	141
10	Urological pathology	157
11	Gynaecological pathology	185
12	Breast pathology	215
13	Endocrine pathology	231
14	Haematopathology	255
15	Skin pathology	285
16	Osteoarticular pathology	305
17	Neuropathology	321
18	Multisystem diseases	345

Index 351

*This page intentionally left blank*

# Detailed contents

Symbols and abbreviations xx

---

## **1 Basic pathology** **1**

- Pathological terminology 2
  - Cellular adaptations 3
  - Cellular death 4
  - Inflammation & healing 5
  - Innate immunity 6
  - Adaptive immunity 8
  - Hypersensitivity reactions 10
  - Neoplasia 11
  - Carcinogenesis 12
- 

## **2 Infectious diseases** **15**

- Microbes 16
  - Antimicrobial agents 17
  - Human immunodeficiency virus 18
  - Tuberculosis 20
  - Infectious mononucleosis 21
  - Malaria 22
  - Syphilis 24
  - Lyme disease 25
  - Leishmaniasis 26
- 

## **3 Vascular pathology** **27**

- Atherosclerosis 28
  - Shock 30
  - Hypertension 31
  - Chronic lower limb ischaemia 32
  - Acute lower limb ischaemia 33
  - Aortic dissection 34
  - Abdominal aortic aneurysm 35
  - Varicose veins 36
  - Deep vein thrombosis 37
-

<b>4 Cardiac pathology</b>	<b>39</b>
Congenital heart disease	40
Angina pectoris	42
Unstable angina	43
Non-ST-elevation myocardial infarction	44
ST-elevation myocardial infarction	46
Left ventricular failure	48
Right ventricular failure	50
Valvular heart disease	51
Cardiomyopathies	52
Infective endocarditis	53
Myocarditis	54
Pericarditis	55
<hr/>	
<b>5 Respiratory pathology</b>	<b>57</b>
Respiratory tract malformations	58
Benign sinonasal diseases	59
Sinonasal malignancies	60
Nasopharyngeal diseases	61
Laryngeal diseases	62
Respiratory failure	63
Acute respiratory distress syndrome	64
Bronchiectasis	65
Cystic fibrosis	66
Pulmonary thromboembolism	67
Pulmonary hypertension	68
Asthma	69
Chronic obstructive pulmonary disease	70
Bacterial pneumonia	72
Idiopathic pulmonary fibrosis	74
Hypersensitivity pneumonitis	76
Lung carcinoma	78
Pleural effusion	80
Pneumothorax	81
Malignant mesothelioma	82

---

**6 Gastrointestinal pathology** **83**

- Gastrointestinal malformations 84
  - Oral cavity diseases 86
  - Salivary gland diseases 87
  - Oesophagitis 88
  - Oesophageal polyps and nodules 89
  - Oesophageal carcinoma 90
  - Gastritis 92
  - Gastric polyps 93
  - Gastric carcinoma 94
  - Gastrointestinal stromal tumours 96
  - Peptic duodenitis 97
  - Coeliac disease 98
  - Small bowel infarction 99
  - Intestinal infections 100
  - Intestinal obstruction 102
  - Acute appendicitis 103
  - Crohn's disease 104
  - Ulcerative colitis 105
  - Microscopic colitis 106
  - Colorectal polyps 108
  - Colorectal carcinoma 110
  - Diverticular disease 112
  - Anal pathology 113
- 

**7 Hepatobiliary pathology** **115**

- Acute viral hepatitis 116
- Chronic viral hepatitis 117
- Alcoholic liver disease 118
- Non-alcoholic fatty liver disease 119
- Autoimmune hepatitis 120
- Primary biliary cirrhosis 121
- Primary sclerosing cholangitis 122
- Wilson's disease 123
- Hereditary haemochromatosis 124
- Cirrhosis 125

- Benign liver lesions 126
  - Hepatocellular carcinoma 127
  - Intrahepatic cholangiocarcinoma 128
  - Cholecystitis 129
  - Extrahepatic bile duct carcinoma 130
- 

## **8 Pancreatic pathology** **131**

- Pancreatic malformations 132
  - Acute pancreatitis 133
  - Chronic pancreatitis 134
  - Pancreatic ductal carcinoma 135
  - Pancreatic endocrine tumours 136
  - Pancreatic cystic tumours 138
  - Acinar cell carcinoma 139
- 

## **9 Renal pathology** **141**

- Chronic kidney disease 142
  - Acute renal failure 144
  - Hypertensive nephropathy 145
  - Diabetic nephropathy 146
  - Minimal change disease 147
  - Focal segmental glomerulosclerosis 148
  - Membranous nephropathy 149
  - IgA nephropathy 150
  - Acute tubular injury 151
  - Acute drug-induced interstitial nephritis 152
  - Anti-glomerular basement membrane disease 153
  - Reflux nephropathy 154
  - Obstructive nephropathy 155
- 

## **10 Urological pathology** **157**

- Genitourinary malformations 158
- Urinary tract infection 160
- Urinary tract obstruction 162
- Urinary calculi 164
- Cystic renal diseases 165
- Benign renal tumours 166

- Renal cell carcinoma 168
  - Childhood renal tumours 170
  - Urothelial carcinomas 172
  - Benign prostatic hyperplasia 174
  - Prostate carcinoma 176
  - Testicular germ cell tumours 178
  - Testicular non-germ cell tumours 180
  - Paratesticular diseases 181
  - Urethral diseases 182
  - Penile diseases 183
  - Scrotal diseases 184
- 

## **11 Gynaecological pathology** **185**

- Vulval skin diseases 186
  - Benign vulval tumours 187
  - Vulval carcinoma 188
  - Vaginal infections 190
  - Vaginal tumours 191
  - Cervical carcinoma 192
  - Cervical screening 194
  - Endometriosis 195
  - Endometrial carcinoma 196
  - Uterine leiomyomas 198
  - Functional ovarian cysts 200
  - Polycystic ovarian syndrome 202
  - Benign ovarian tumours 204
  - Ovarian carcinomas 206
  - Pelvic inflammatory disease 208
  - Ectopic pregnancy 209
  - Hydatidiform moles 210
  - Pre-eclampsia 212
- 

## **12 Breast pathology** **215**

- Duct ectasia 216
- Acute mastitis 217
- Fat necrosis 218
- Fibrocystic change 219



- Fibroadenoma 220
  - Intraductal papilloma 222
  - Radial scar 223
  - Proliferative breast diseases 224
  - Ductal carcinoma *in situ* 225
  - Invasive breast carcinomas 226
  - Breast screening 228
  - Male breast diseases 229
- 

### **13 Endocrine pathology** **231**

- Diabetes mellitus 232
  - Hashimoto's thyroiditis 234
  - Graves' disease 235
  - Nodular goitre 236
  - Follicular adenoma 237
  - Thyroid carcinomas 238
  - Parathyroid hyperplasia 240
  - Parathyroid adenoma 241
  - Parathyroid carcinoma 242
  - Addison's disease 243
  - Adrenal cortical adenoma 244
  - Adrenal cortical carcinoma 246
  - Phaeochromocytoma 248
  - Neuroblastoma 250
  - Pituitary adenoma 252
- 

### **14 Haematopathology** **255**

- Iron deficiency anaemia 256
- Anaemia of chronic disease 257
- Megaloblastic anaemias 258
- Hereditary spherocytosis 259
- Glucose-6-phosphate dehydrogenase deficiency 260
- Thalassaemias 261
- Sickle cell disorders 262
- Idiopathic thrombocytopenic purpura 264
- Thrombotic thrombocytopenic purpura 265

- von Willebrand disease 266
  - Haemophilia 267
  - Thrombophilia 268
  - Acute B-lymphoblastic leukaemia 269
  - Acute myeloid leukaemias 270
  - Chronic lymphocytic leukaemia 271
  - Chronic myelogenous leukaemia 272
  - Polycythaemia vera 273
  - Essential thrombocythaemia 274
  - Primary myelofibrosis 275
  - Myelodysplastic syndromes 276
  - Follicular lymphoma 277
  - Diffuse large B-cell lymphoma 278
  - Extranodal marginal zone lymphoma 279
  - Mantle cell lymphoma 280
  - Classical Hodgkin lymphoma 281
  - Plasma cell myeloma 282
  - Primary amyloidosis 283
- 

## **15 Skin pathology**

**285**

- Eczemas 286
  - Psoriasis 287
  - Lichen planus 288
  - Erythema multiforme 289
  - Granuloma annulare 290
  - Pemphigus vulgaris 291
  - Bullous pemphigoid 292
  - Dermatitis herpetiformis 293
  - Erythema nodosum 294
  - Pyoderma gangrenosum 295
  - Skin infections 296
  - Benign cutaneous lumps 298
  - Basal cell carcinoma 300
  - Squamous cell carcinoma 301
  - Malignant melanoma 302
  - Mycosis fungoides 304
-

<b>16 Osteoarticular pathology</b>	<b>305</b>
Osteoarticular malformations	306
Osteoporosis	307
Paget's disease	308
Osteomalacia	309
Osteomyelitis	310
Benign bone tumours	311
Malignant bone tumours	312
Osteoarthritis	313
Rheumatoid arthritis	314
Spondyloarthropathies	315
Crystal arthropathies	316
Septic arthritis	317
Soft tissue tumours	318
<hr/>	
<b>17 Neuropathology</b>	<b>321</b>
Nervous system malformations	322
Epilepsy	323
Head injury	324
Cerebral infarction	325
Intracerebral haemorrhage	326
Subarachnoid haemorrhage	328
Meningitis	330
Cerebral infections	331
Multiple sclerosis	332
Alzheimer's disease	333
Dementia with Lewy bodies	334
Parkinson's disease	335
Huntington's disease	336
Motor neurone disease	337
Creutzfeldt–Jacob disease	338
Central nervous system neoplasms	340
Guillain–Barré syndrome	342
Myasthenia gravis	343

---

<b>18 Multisystem diseases</b>	<b>345</b>
Systemic lupus erythematosus	346
Systemic sclerosis	348
Sarcoidosis	349
Vasculitis	350
Index	351

# Symbols and abbreviations

&	and
~	approximately
%	percent
=	equal to
×	multiply
±	plus/minus
>	greater than
<	less than
≥	greater than or equal to
≤	less than or equal to
α	alpha
β	beta
γ	gamma
♀	female
♂	male
↓	decreased
↑	increased
→	leading to
⚠	warning
▶	important
▶▶	don't dawdle
📖	see (cross reference)
ACTH	adrenocorticotrophic hormone
AFP	alpha-fetoprotein
AIH	autoimmune hepatitis
AIN	anal intraepithelial neoplasia
ALL	acute lymphoblastic leukaemia
AML	acute myeloid leukaemia
ANCA	anti-neutrophil cytoplasmic antibody
APKD	adult polycystic kidney disease
APP	amyloid precursor protein
APTT	activated partial thromboplastin time
AR	aortic regurgitation
ARDS	acute respiratory distress syndrome
ARF	acute renal failure
ASD	atrial septal defect

ASH	alcoholic steatohepatitis
AVSD	atrioventricular septal defect
BAL	bronchoalveolar lavage
BPH	benign prostatic hyperplasia
BSE	bovine spongiform encephalopathy
CD	Crohn's disease
CF	cystic fibrosis
CFTR	cystic fibrosis transmembrane conductance regulator
CGIN	cervical glandular intraepithelial neoplasia
CHD	congenital heart disease
CIN	cervical intraepithelial neoplasia
CJD	Creutzfeldt–Jacob disease
CLL	chronic lymphocytic leukaemia
cm	centimetre
CMV	cytomegalovirus
CNS	central nervous system
COPD	chronic obstructive pulmonary disease
CSF	cerebrospinal fluid
CT	computerized tomography
DCIS	ductal carcinoma <i>in situ</i>
DIC	disseminated intravascular coagulation
dL	decilitre
DLBCL	diffuse large B-cell lymphoma
DNA	deoxyribonucleic acid
DPLD	diffuse parenchymal lung disease
DRE	digital rectal examination
EATL	enteropathy-associated T-cell lymphoma
EBV	Epstein–Barr virus
ECG	electrocardiogram
e.g.	<i>exempli gratia</i> (for example)
eGFR	estimated glomerular filtration rate
EGFR	epidermal growth factor receptor
ELISA	enzyme-linked immunosorbent assay
ER	oestrogen receptor
ERCP	endoscopic retrograde cholangiopancreatography
ESR	erythrocyte sedimentation rate
ETEC	enterotoxigenic <i>Escherichia coli</i>
FAP	familial adenomatous polyposis
FCC	fibrocystic change
FEV1	forced expiratory volume in one second

FIGO	International Federation of Gynaecology and Obstetrics
FiO <sub>2</sub>	fraction of inspired oxygen
FISH	fluorescence <i>in situ</i> hybridization
FMTC	familial medullary thyroid carcinoma
FNA	fine needle aspiration
FSGS	focal segmental glomerulosclerosis
FSH	follicle-stimulating hormone
g	gram
GFR	glomerular filtration rate
GH	growth hormone
GI	gastrointestinal
G6PD	glucose-6-phosphate dehydrogenase
h	hour
HAV	hepatitis A virus
Hb	haemoglobin
HBV	hepatitis B virus
HCC	hepatocellular carcinoma
HCG	human chorionic gonadotropin
HCM	hypertrophic cardiomyopathy
HCT	haematocrit
HCV	hepatitis C virus
HEV	hepatitis E virus
HH	hereditary haemochromatosis
HHV	human herpes virus
HIV	human immunodeficiency virus
HLA	human leukocyte antigen
HMA	homovanilic acid
HNPCC	hereditary non-polyposis colorectal carcinoma
hpf	high power field
HPV	human papillomavirus
HRS	Hodgkin/Reed Sternberg
HRT	hormone replacement therapy
HSV	herpes simplex virus
HUS	haemolytic uraemic syndrome
i.e.	<i>id est</i> (that is)
IFN	interferon
Ig	immunoglobulin
IgAN	IgA nephropathy
IL	interleukin
IPF	idiopathic pulmonary fibrosis

ITGCN	intratubular germ cell neoplasia
ITP	idiopathic thrombocytopenic purpura
JAK2	Janus kinase 2
kg	kilogram
kPa	kilopascal
L	litre
LDL	low density lipoprotein
LFT	liver function test
LH	luteinizing hormone
LUTS	lower urinary tract symptoms
LVF	left ventricular failure
MASP	mannose-binding lectin associated serine proteases
MCD	minimal change disease
MCV	mean corpuscular volume
MDS	myelodysplastic syndrome
MEN	multiple endocrine neoplasia
mg	milligram
MHC	major histocompatibility complex
min	minute
mL	millilitre
mm	millimetre
mmHg	millimetre mercury
mmol	millimole
nAChR	nicotinic acetylcholine receptor
NADH	nicotinamide adenine dinucleotide dehydrogenase
NAFLD	non-alcoholic fatty liver disease
NASH	non-alcoholic steatohepatitis
NHS	National Health Service
NLPHL	nodular lymphocyte predominant Hodgkin lymphoma
NSAID	non-steroidal anti-inflammatory drug
PaO <sub>2</sub>	partial pressure of oxygen in arterial blood
PaCO <sub>2</sub>	partial pressure of carbon dioxide in arterial blood
PBC	primary biliary cirrhosis
PCR	polymerase chain reaction
PCV	packed cell volume
PDA	patent ductus arteriosus
PID	pelvic inflammatory disease
PIN	prostatic intraepithelial neoplasia
PR	progesterone receptor
PrP	prion protein



PSA	prostate-specific antigen
PSC	primary sclerosing cholangitis
PT	prothrombin time
PTH	parathyroid hormone
RA	rheumatoid arthritis
RBC	red blood cell
RCC	renal cell carcinoma
RhF	rheumatoid factor
RN	reflux nephropathy
RNA	ribonucleic acid
RVF	right ventricular failure
s	second
SLE	systemic lupus erythematosus
SS	systemic sclerosis
TB	tuberculosis
TGF	transforming growth factor
TIA	transient ischaemic attack
TIBC	total iron binding capacity
TNF	tumour necrosis factor
TSH	thyroid-stimulating hormone
TTP	thrombotic thrombocytopenia purpura
UC	ulcerative colitis
UIP	usual interstitial pneumonia
UK	United Kingdom
UTI	urinary tract infection
UV	ultraviolet
TURP	transurethral resection of the prostate
VAIN	vaginal intraepithelial neoplasia
VIN	vulval intraepithelial neoplasia
VMA	vanillylmandelic acid
VSD	ventricular septal defect
VUR	vesicoureteric reflux
vWF	von Willebrand factor
VZV	varicella zoster virus
WCC	white cell count
WHO	World Health Organization
y	year

# Basic pathology

Pathological terminology	2
Cellular adaptations	3
Cellular death	4
Inflammation & healing	5
Innate immunity	6
Adaptive immunity	8
Hypersensitivity reactions	10
Neoplasia	11
Carcinogenesis	12

## Pathological terminology

### Nomenclature of disease

- **Aetiology** refers to a disease's underlying cause. Diseases whose aetiology is unknown are described as **idiopathic**, **cryptogenic**, or **essential**.
- **Pathogenesis** refers to the mechanism by which the aetiological agent produces the manifestations of a disease.
- **Incidence** refers to the number of new cases of a disease diagnosed over a certain period of time.
- **Prevalence** refers to the total number of cases of a disease present in a population at a certain moment in time.
- **Prognosis** is a prediction of the likely course of a disease.
- **Morbidity** describes the extent to which a patient's overall health will be affected by a disease.
- **Mortality** reflects the likelihood of death from a particular disease.
- **Acute** and **chronic** refer to the time course of a pathological event. Acute illnesses are of rapid onset. Chronic conditions usually have a gradual onset and are more likely to have a prolonged course.
- A **syndrome** refers to a set of symptoms and clinical signs that, when occurring together, suggest a particular underlying cause(s).

### Classification of disease

- **Genetic** diseases are inherited conditions in which a defective gene causes the disease, e.g. cystic fibrosis.
- **Infective** diseases are the result of invasion of the body by pathogenic microbes, e.g. malaria.
- **Inflammatory** diseases are due to excess inflammatory cell activity in an organ, e.g. rheumatoid arthritis.
- **Neoplastic** disease results from an uncontrolled proliferation of cells, e.g. breast carcinoma.
- **Vascular** diseases arise due to disorders of blood vessels, e.g. ischaemic heart disease.
- **Metabolic** disorders arise due to abnormalities within metabolic pathways, e.g. diabetes mellitus.
- **Degenerative** diseases occur as a consequence of damage and/or loss of specialized cells, e.g. loss of neurones from the cerebral cortex in Alzheimer's disease.
- **Iatrogenic** disease is the result of the effects of treatment, e.g. osteoporosis due to long-term glucocorticoid treatment.
- **Congenital** diseases are present at birth whereas those occurring after birth are known as **acquired**.

# Cellular adaptations

## Atrophy

- A reduction in size of a tissue or organ.
- May occur through a reduction in cell number by deletion (apoptosis) or a reduction in cell size through shrinkage.
- Atrophy may occur as a normal physiological process, e.g. thymic atrophy during adolescence and post-menopausal ovarian atrophy.
- Examples of pathological atrophy include muscle atrophy following denervation and cerebral atrophy due to cerebrovascular disease.

## Hypertrophy

- An increase in size of individual cells.
- Due to an increase in cell proteins and organelles.
- Seen in organs containing terminally differentiated cells that cannot multiply, e.g. cardiac and skeletal muscle.
- Examples of physiological hypertrophy include the myometrium of the uterus in pregnancy and muscles of a bodybuilder.
- Examples of pathological hypertrophy include left ventricular hypertrophy due to hypertension (📖 p. 31) or aortic stenosis (📖 p. 51).

## Hyperplasia

- An increase in cell number.
- Examples of physiological hyperplasia include endometrium and breast lobules in response to cyclical oestrogen exposure.
- Examples of pathological hyperplasia include benign prostatic hyperplasia (📖 p. 174) and parathyroid hyperplasia (📖 p. 241).

## Metaplasia

- A change in which one cell type is switched for another.
- Thought to be the result of progenitor cells differentiating into a new type of cell rather than a direct morphogenesis of cells from one type to another.
- Seen almost exclusively in epithelial cells, often in response to chronic injury.
- Metaplasia is named according to the new type of cell type, e.g. a change from non-squamous to squamous epithelium is called squamous metaplasia.
- Common sites of squamous metaplasia include the endocervix (creating the transformation zone where cervical neoplasia occurs) and the bronchi of smokers.
- Common sites of glandular metaplasia include the lower oesophagus in some people with reflux disease, creating a visible Barrett's oesophagus (📖 p. 88).
- Metaplasia is a marker of long-term epithelial damage which in some cases may develop into epithelial **dysplasia** and, eventually, **carcinoma**.

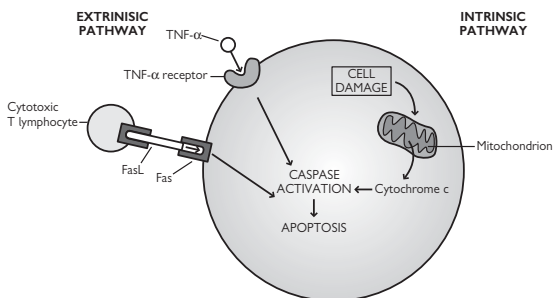
## Cellular death

### Necrosis

- A poorly controlled form of cell death in which membrane integrity is lost with leakage of cellular contents and an inflammatory response.
- **Coagulative necrosis** is the most common form, characterized by the loss of cell nuclei, but with general preservation of the underlying architecture. The dead tissue is macroscopically pale and firm.
- **Liquefactive necrosis** leads to complete loss of cellular structure and conversion into a soft, semi-solid mass. This is typically seen in the brain following cerebral infarction.
- **Caseous necrosis** is a type of necrosis in which the dead tissue macroscopically appears like cream cheese. It may be seen in many conditions, but is most commonly associated with tuberculosis.
- **Gangrene** is a term that refers to necrotic tissues modified by exposure to air, resulting in drying (dry gangrene) or infection (wet gangrene). Toes deprived of blood in critical leg ischaemia usually show dry gangrene (📖 p. 32).

### Apoptosis

- A controlled form of cell death in which no cellular contents are released from the dying cell and thus no inflammatory reaction.
- Apoptosis may occur physiologically (e.g. removal of cells during embryogenesis and cells with DNA damage) or pathologically.
- Apoptosis may be induced in two main ways (Fig. 1.1): by the engagement of surface death receptors, e.g. Fas or TNF- $\alpha$  (extrinsic pathway) or through cellular injury (intrinsic pathway).
- The end result is the activation of protease enzymes called **caspases** which dismantle the cell cytoplasm and nucleus.
- Apoptotic cells shrink down and fragment into apoptotic bodies, each of which retains an intact cell membrane.
- Apoptotic bodies are targeted for their rapid removal by adjacent cells.
- Disordered apoptosis is thought to be central to a number of important disease processes, particularly carcinogenesis.



**Fig. 1.1** Apoptosis may be triggered extrinsically by the ligation of 'death receptors' or intrinsically if cell damage causes the release of cytochrome c from mitochondria. Reproduced with permission from *Clinical Pathology*, Carton, Daly, and Ramani, Oxford University Press, p. 9, Figure 1.3.

# Inflammation & healing

## Acute inflammation

- A rapid, non-specific response to cellular injury.
- Orchestrated by **cytokines** released from injured cells, e.g. histamine, serotonin, prostaglandins, leukotrienes, and platelet-activating factor.
- Cytokines activate endothelial cells, leading to the formation of an **acute inflammatory exudate** containing fluid, fibrin, and neutrophils.
- Severe acute inflammation may lead to a localized collection of pus within a necrotic cavity (**abscess**).
- Acute inflammation may resolve, heal with scarring, or progress to chronic inflammation.

## Chronic inflammation

- Persistent form of inflammation in which there is simultaneous tissue damage and attempted repair.
- May arise from acute inflammation or occur from the outset.
- Characterized by the presence of chronic inflammatory cells, namely macrophages, lymphocytes, and plasma cells.
- More likely to heal with irreversible scarring than resolve.

## Granulomatous inflammation

- A special type of chronic inflammation characterized by the presence of activated macrophages known as epithelioid histiocytes.
- Collections of epithelioid macrophages are known as **granulomas**.
- Granulomatous inflammation is associated with foreign bodies, persistent infections (e.g. mycobacteria), and diseases whose cause is unclear (e.g. sarcoidosis).

## Healing

- Process of replacing dead and damaged tissue with healthy tissue.
- May occur through regeneration or repair.
- **Regeneration** (resolution) replaces damaged cells with the same type of cell and is the ideal outcome. This can only occur if the connective tissue framework of the tissue is not disrupted and if the tissue is capable of regeneration.
- **Repair** begins with the formation of granulation tissue which is then converted into a collagen-rich scar. Although the structural integrity is maintained, there is loss of function of the tissue that is scarred.

## Innate immunity

### Epithelial surfaces

- Epithelial surfaces are the principal portals into the body for pathogens.
- A continuous epithelial layer forms a physical barrier against infection.
- The low pH of skin and fatty acids in sebum inhibit microbial growth.
- The GI tract has gastric acid, pancreatic enzymes, mucosal IgA and normal colonic flora which act to prevent the establishment of infection.
- The respiratory tract secretes mucus to trap organisms and beating cilia transport them to the throat where they are swallowed.
- Continuous flushing of urine through the urinary tract prevents microbes from adhering to the urothelium.

### Phagocytes

- Organisms breaching epithelial surfaces encounter tissue macrophages that recognize pathogens and attract neutrophils to the site.
- Macrophages and neutrophils are phagocytes that ingest microbes by phagocytosis into a phagosome.
- The phagosome is fused to cytoplasmic lysosomes that contain enzymes and reactive oxygen intermediates that kill the microbe.
- Phagocytes recognize organisms by pattern recognition receptors, e.g. mannose receptors, Toll-like receptors, and Nod-like receptors.

### Acute phase proteins

- Cytokines produced by phagocytes stimulate the liver to rapidly synthesize and release acute phase proteins.
- **Mannose-binding lectin** recognizes microbial surface sugars and undergoes a conformational change, allowing it to bind a protein, MASP, and form a complex which activates complement.
- **C-reactive protein** binds to the phosphorylcholine portions of microbial lipopolysaccharide and targets them for phagocytosis by macrophages.

### Complement

- A collection of circulating proteins that assist the immune system in killing microbes.
- May be activated by antibodies bound to a microbe (**classical pathway**), triggered automatically on microbes lacking a regulatory protein present on host cells (**alternative pathway**), or by mannose-binding protein (**lectin pathway**).
- A sequential cascade leads to the generation of C3 convertase, an enzyme that splits many molecules of C3 into C3b.
- Microbes coated in C3b are destroyed either by phagocytosis or the **membrane attack complex**, a polymer of the terminal complement components which forms holes in the cell membrane of the microbe.
- The complement system is tightly regulated to prevent uncontrolled activation. **Decay accelerating factor** disrupts binding to C3b to cell surfaces and **membrane co-factor** protein breaks down C3b.

*This page intentionally left blank*



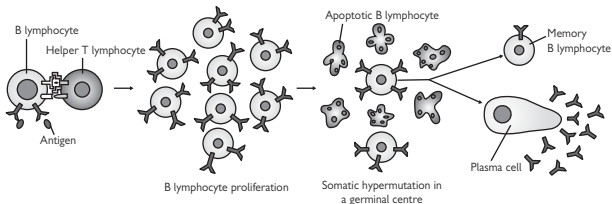
## Adaptive immunity

### Antibody-mediated immunity

- Mediated by proteins called **antibodies** or **immunoglobulins**.
- Binding of antigen to the Fab antigen-binding region unmask the binding sites on the Fc portion which mediates the functions of the antibody.
- Antibodies work in four main ways:
  - Neutralize the biological activity of a vital microbial molecule, e.g. a binding protein or toxin.
  - Target microbes for phagocytosis.
  - Activate complement.
  - Activate cytotoxic immune cells.
- Antibody production is initiated following binding of an antigen to its specific B-cell receptor on the surface of naïve B-lymphocytes in the presence of an additional signal from CD4+ helper T-lymphocytes (Fig. 1.2).

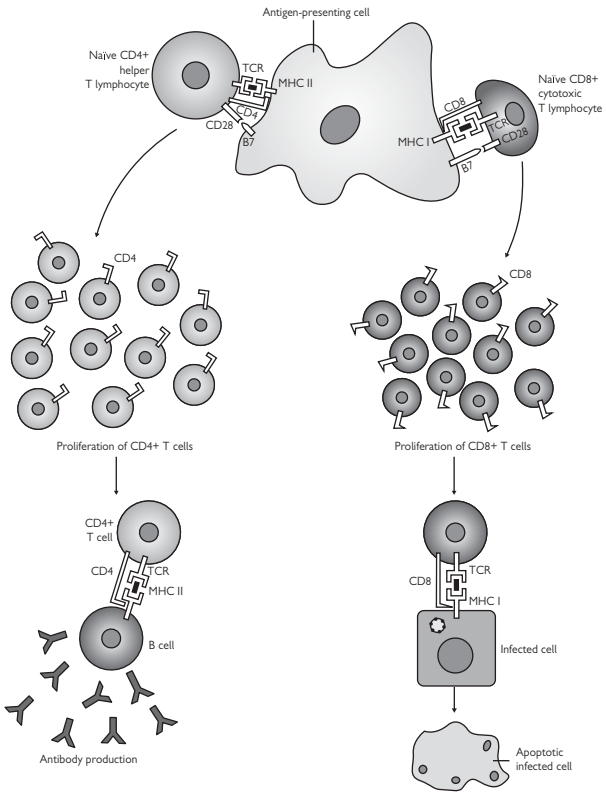
### Cell-mediated immunity

- Predominantly mediated by T-lymphocytes (Fig. 1.3).
- CD4+ helper T-cells are activated by foreign peptides presented by class II MHC molecules expressed by specialized antigen-presenting cells such as dendritic cells and macrophages.
- Activated CD4+ helper T-cells proliferate and secrete cytokines that mediate a variety of immune responses.
- Many subtypes of helper T-cells are recognized, depending on the cytokines they produce when activated, including Th1, Th2, Th3, and Th17.
- CD8+ cytotoxic T-cells are activated by foreign peptides presented by class I MHC expressed by all nucleated cells.
- Activated CD8+ cytotoxic T-cells destroy the presenting host cell either by stimulating apoptosis through the **Fas ligand** or by inserting a membrane pore called **perforin** through which the T-cell pours in proteolytic enzymes.



**Fig. 1.2** Humoral immunity. Naïve B-lymphocytes that encounter their antigen and receive appropriate T-cell help enter a germinal centre where they proliferate and undergo somatic hypermutation of the immunoglobulin gene. Only B-lymphocytes with the best fitting immunoglobulin are selected to survive and differentiate into memory cells or plasma cells. The remainder are doomed to die by apoptosis in the germinal centre.

Reproduced with permission from *Clinical Pathology*, Carton, Daly, and Ramani, Oxford University Press, p. 41, Figure 4.5.



**Fig. 1.3** Cellular immunity. T-lymphocytes activated by antigen-presenting cells proliferate and express genes appropriate to their actions. Activated CD4+ helper T-cells interact with other cells of the immune system such as B-lymphocytes, whilst activated CD8+ cytotoxic T-lymphocytes destroy infected host cells.

Reproduced with permission from *Clinical Pathology*, Carton, Daly, and Ramani, Oxford University Press, p. 43, Figure 4.6.

## Hypersensitivity reactions

### Definition

- A group of diseases caused by an abnormal immune-mediated reaction.
- May be directed at an exogenous antigen from the environment or a self-antigen (in which case the reaction is a form of autoimmunity).

### Immediate (type 1) hypersensitivity

- Characterized by the production of IgE antibodies in response to an antigen.
- Cross-linkage of surface IgE receptors on mast cells releases mediators such as histamine which stimulate acute inflammation.
- Typical of people with **atopy**, a genetic disposition to produce large quantities of IgE in response to environmental antigens such as pollen and house dust mites.
- **Anaphylaxis** represents a systemic form of immediate hypersensitivity caused by the widespread release of histamine. In its most severe form, it can lead to **anaphylactic shock** (📖 p. 30).
- Immediate hypersensitivity diseases affect >20% of people and the incidence is rising.

### Antibody-mediated (type 2) hypersensitivity

- Caused by IgG or IgM antibodies binding to a fixed antigen in a tissue.
- Binding of the antibody may activate complement and lead to cellular injury, e.g. bullous pemphigoid (📖 p. 292) or cause a change in cellular function, e.g. TSH-receptor stimulating antibody in Graves' disease (📖 p. 235).

### Immune complex-mediated (type 3) hypersensitivity

- Caused by circulating IgG or IgM antibodies forming immune complexes with antigen in the blood and depositing in tissues where they activate complement.
- Sites of predilection for the deposition of immune complexes include small blood vessels, kidneys, and joints.
- Immune complex-mediated hypersensitivity reactions tend to be multisystem diseases in which vasculitis, arthritis, and glomerulonephritis feature, e.g. systemic lupus erythematosus (📖 p. 346).

### T-cell-mediated (type 4) hypersensitivity

- Caused by activated T-lymphocytes that injure cells by direct cell killing or releasing cytokines that activate macrophages.
- Because T-cell responses take 1–2 days to occur, this type is also known as delayed-type hypersensitivity.
- Examples include contact dermatitis (📖 p. 286), Hashimoto's thyroiditis (📖 p. 234), primary biliary cirrhosis (📖 p. 121), and tuberculosis (📖 p. 20).

# Neoplasia

## Definitions

- A **neoplasm** is an abnormal mass of tissue which shows uncoordinated growth and serves no useful purpose. The word is often used synonymously with the word **tumour** which simply means a swelling.
- **Benign** neoplasms usually have a slow rate of growth and remain confined to their site of origin. Although benign neoplasms usually run an innocuous course, they can be dangerous if they compress vital nearby structures or if the neoplasm secretes hormones uncontrollably.
- **Malignant** neoplasms have capacity to spread or metastasize to distant sites and produce secondary tumours called metastases which can grow independently from the primary tumour.
- **Cancer** is a broad term for any malignant neoplasm.

## Nomenclature of neoplasms

### Epithelial neoplasms

- Benign neoplasms of squamous epithelium are called **acanthomas** if they are flat or **papillomas** if they grow in branching fronds.
- Benign neoplasms of glandular epithelium are called **adenomas**.
- Epithelial malignancies are called **carcinomas**. Carcinomas showing squamous differentiation are called **squamous cell carcinomas**. Carcinomas showing glandular differentiation are called **adenocarcinomas**.
- Carcinomas are often preceded by a phase of epithelial **dysplasia**, in which the epithelium contains neoplastic cells, but invasion beyond the confines of the epithelium has not yet occurred.

### Connective tissue neoplasms

- Lipoma is a benign adipocytic tumour.
- Leiomyoma is a benign smooth muscle tumour.
- Rhabdomyoma is a benign skeletal muscle tumour.
- Angioma is a benign vascular tumour.
- Osteoma is a benign bony tumour.
- Liposarcoma is a malignant adipocytic tumour.
- Leiomyosarcoma is a malignant smooth muscle tumour.
- Rhabdomyosarcoma is a malignant skeletal muscle tumour.
- Angiosarcoma is a malignant vascular tumour.
- Osteosarcoma is a malignant bony tumour.

### Other types of neoplasms

- Lymphomas, leukaemias, and myeloma are haematological malignancies derived from cells of the blood or bone marrow.
- Malignant melanoma is a malignant melanocytic neoplasm.
- Malignant mesothelioma is a malignant mesothelial tumour.
- Germ cell tumours are a diverse group of tumours which usually arise in the testes or ovaries.
- Embryonal tumours are a group of malignant tumours seen predominantly in children and composed of very primitive cells, e.g. neuroblastoma (📖 p. 250) and nephroblastoma (📖 p. 170).

## Carcinogenesis

### Definition

- The sequence of events leading to the development of a malignant neoplasm.

### Aetiology

- Radiation or chemicals which damage DNA, e.g. sunlight in skin carcinomas and cigarette smoke in lung carcinomas.
- Chronic inflammatory diseases which stimulate persistent proliferation of cells, e.g. ulcerative colitis predisposes to colonic carcinoma.
- High levels of hormones causing proliferation of hormonally responsive tissues, e.g. oestrogens in breast and endometrial carcinomas.
- Certain oncogenic viruses produce proteins which promote uncontrolled cell division, e.g. HPV in cervical carcinoma.

### Pathogenesis

- DNA damage to genes whose protein products are involved in the control of cell division allows deregulated growth of cells.
- Genes controlling cell division are divided into **oncogenes** and **tumour suppressor genes**.

### Oncogenes

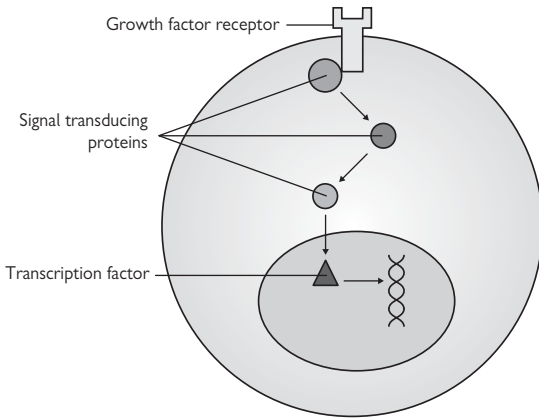
- Mutated genes that promote cell division (Fig. 1.4).
- Mutations usually result in overexpression of the gene product or constitutive activation of the protein product.
- Examples of oncogenes commonly mutated in malignancies include KIT, RAS, and MYC.

### Tumour suppressor genes

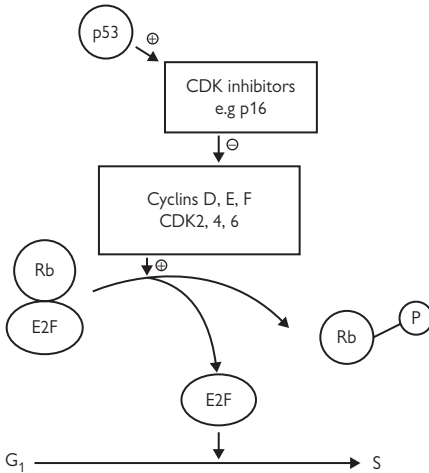
- Genes encoding proteins that normally inhibit cell growth.
- Loss of activity of both gene copies is usually required for a tumour-promoting effect.
- Examples of tumour suppressor genes commonly mutated in malignancies include P53, CDKN2A, and RB (Fig. 1.5).

### Metastasis

- The acquisition of metastatic potential is a pivotal event in the evolution of a neoplasm; spread to distant sites is one of the major reasons why malignant tumours eventually lead to death.
- Malignant neoplasms metastasize via three main routes: **haematogenous spread** to distant organs (e.g. lungs, liver, bone, brain), **lymphatic spread** to regional lymph nodes (e.g. axillary lymph nodes in breast carcinomas), and **transcoelomic spread** whereby malignant tumours growing near a body cavity such as the pleura or peritoneum can seed into these spaces and spread across them to other organs.
- Successful metastasis requires a number of hurdles to be overcome by the malignant cells: loss of adhesion from neighbouring cells, eroding the extracellular matrix, penetrating the lumen of a vessel, surviving in the circulation whilst travelling to a distant site, exiting the vessel, and successfully implanting at the new site and multiplying.



**Fig. 1.4** Oncoproteins. Oncogenes code for proteins with key roles in growth-stimulating cell signalling pathways. Reproduced with permission from *Clinical Pathology*, Carton, Daly, and Ramani, Oxford University Press, p. 56, Figure 5.5.



**Fig. 1.5** Critical role of P53 and RB at the G<sub>1</sub> to S checkpoint. Reproduced with permission from *Clinical Pathology*, Carton, Daly, and Ramani, Oxford University Press, p. 57, Figure 5.6.

*This page intentionally left blank*

# Infectious diseases

- Microbes 16
- Antimicrobial agents 17
- Human immunodeficiency virus 18
- Tuberculosis 20
- Infectious mononucleosis 21
- Malaria 22
- Syphilis 24
- Lyme disease 25
- Leishmaniasis 26



## Microbes

### Bacteria

- Single-celled organisms with their double-stranded DNA lying free in cytoplasm surrounded by a cell membrane and cell wall.
- Most grow in air (aerobes), but can grow without it (facultative anaerobes). Some only grow in the absence of oxygen (strict anaerobes).
- Gram-positive bacteria have a thick cell wall composed of peptidoglycan and a second polymer, often teichoic acid.
- Gram-negative bacteria have a thinner peptidoglycan wall overlaid by an outer lipid membrane composed of lipopolysaccharide.
- Mycobacteria are a type of bacteria with a thick waxy cell wall which can be stained with the Ziehl–Nielsen stain.

### Viruses

- Smallest and simplest microbes composed of genetic material in the form of DNA or RNA enclosed in a protein shell (capsid). Some viruses also have an outer lipid membrane acquired from the host cell they formed in.
- Obligate intracellular organisms that can only replicate by infecting a host cell and hijacking its metabolic apparatus.
- Cause disease by destroying host cells (direct cytopathic effect) or due to the immune reaction against the infection.
- Some viruses are able to establish latent infection, e.g. herpes simplex.
- Some viruses are oncogenic and implicated in the transformation of the host cell and development of malignancy, e.g. HPV in cervical carcinoma (📖 p. 192) and EBV in nasopharyngeal carcinoma (📖 p. 61).

### Fungi

- Contain DNA within a nucleus and have a cell membrane containing ergosterol and an outer cell wall composed of chitin.
- Yeasts are unicellular fungi that reproduce by budding, e.g. *Candida*.
- Moulds grow as branching filaments called hyphae that interlace to form a tangled mass known as a mycelium. Mycelia produce spores.
- Some fungi can exist in yeast and mould forms, e.g. *Histoplasma*.

### Protozoa

- Single-celled organisms which may live inside host cells or in the extracellular environment.
- Intracellular protozoa derive nutrients from the host cell (e.g. *Plasmodium*, *Leishmania*, *Toxoplasma*).
- Extracellular protozoa feed by direct nutrient uptake and/or ingestion of shed epithelial cells (e.g. *Giardia*, *Trichomonas*).

### Helminths

- Complex multicellular parasitic worms ranging in size from microscopic organisms to giant organisms several metres in length.
- Many have complex life cycles involving more than one host.
- Divided into nematodes (roundworms), cestodes (tapeworms), and trematodes (flukes).

# Antimicrobial agents

## Antibacterial agents

### *Inhibitors of cell wall synthesis*

- Interfere with peptidoglycan synthesis.
- $\beta$ -lactams, e.g. penicillins and cephalosporins.
- Glycopeptides, e.g. vancomycin and teicoplanin.

### *Inhibitors of protein synthesis*

- Bind to bacterial ribosomes and prevent the elongation of protein chains.
- Aminoglycosides, e.g. gentamycin.
- Tetracyclines, e.g. doxycycline.
- Macrolides, e.g. erythromycin, clarithromycin.

### *Inhibitors of nucleic acid synthesis*

- Interfere with the synthesis of DNA precursors or DNA replication.
- Sulphonamides, e.g. sulphamethoxazole.
- Trimethoprim.
- Quinolones, e.g. ciprofloxacin.
- Rifamycins, e.g. rifampicin.
- Nitroimidazoles, e.g. metronidazole.

## Antiviral agents

- Aciclovir is a guanosine analogue which is phosphorylated by viral thymidine kinase. Aciclovir triphosphate is incorporated into viral DNA and terminates chain replication.
- Ganciclovir is related to acyclovir, but is more active against cytomegalovirus (CMV).
- Modern HIV therapy involves combinations of reverse transcriptase inhibitors and protease inhibitors.

## Antifungal agents

- Azoles act by blocking the synthesis of ergosterol, e.g. fluconazole.
- Polyenes impair fungal cell membrane function, e.g. amphotericin and nystatin.

# Human immunodeficiency virus

## Pathogen

- Single-stranded, positive sense, enveloped RNA virus.
- Member of lentivirus genus, part of the retrovirus family.

## Epidemiology

- Very common worldwide, most notably in Sub-Saharan Africa.
- Declared pandemic by World Health Organization (WHO).

## Transmission

- Major routes of transmission are unprotected sex, contaminated needles, breast milk, and transmission from mother to baby at birth.
- Transmission via transfused blood products now virtually eliminated by stringent donor screening.

## Immunopathogenesis

- Infects CD4+ helper T-lymphocytes, macrophages, and dendritic cells.
- Widespread seeding of lymphoid tissue occurs following infection.
- HIV-specific CD8+ cytotoxic T-cells initially control the disease.
- Eventually, HIV escapes immune control through antigenic mutation.
- Viral load rapidly rises and CD4+ counts fall precipitously.

## Presentation

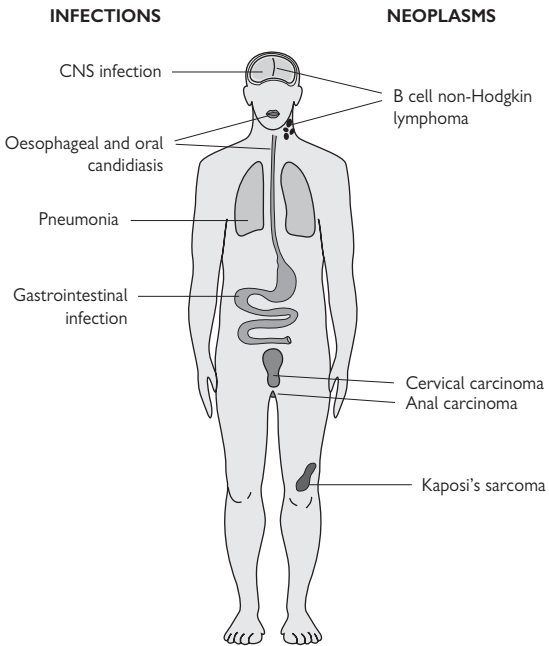
- Acute seroconversion causes a flu-like illness with fever, lymphadenopathy, sore throat, myalgia, rash, and mouth ulcers.
- Latency phase then follows which is usually asymptomatic.
- Final phase presents with opportunistic infections and/or neoplasms (Fig. 2.1).
- Common infections include bacterial pneumonia (📖 p. 72), pulmonary tuberculosis (📖 p. 20), *Pneumocystis pneumonia*, oesophageal candidiasis (📖 p. 88), cryptosporidiosis and *Mycobacterium avium* in bowel (📖 p. 100), cryptococcal meningitis, cerebral toxoplasmosis.
- Common neoplasms include cervical/anal warts and carcinoma, non-Hodgkin B-cell lymphomas, and Kaposi's sarcoma.

## Histopathology

- Lymph nodes show florid follicular hyperplasia with follicle lysis. Lymphomas are usually of diffuse large B-cell type (📖 p. 278).
- Bone marrow appears dysplastic with jumbling of haematopoietic lineages and increased numbers of plasma cells.
- Skin may show eosinophilic folliculitis (infiltration of hair follicles by eosinophils). Cutaneous Kaposi's sarcoma shows an irregular proliferation of HHV-8-positive spindle cells in the dermis which form slit-like vascular spaces.
- *Pneumocystis pneumonia* shows a lymphocytic alveolitis with silver-positive organisms in the alveolar spaces.

## Prognosis

- With modern anti-HIV therapy, many patients can expect to have a near normal lifespan such that they die with HIV rather than from it.



**Fig. 2.1** Manifestations of advanced HIV infection. Reproduced with permission from *Clinical Pathology*, Carton, Daly, and Ramani, Oxford University Press, p. 50, Figure 4.8.

# Tuberculosis

## Pathogen

- *Mycobacterium tuberculosis*, an acid-fast rod-shaped bacillus.

## Epidemiology

- Most common infectious disease worldwide.
- Kills 2 million people per year.

## Transmission

- Respiratory spread from an infectious patient with active pulmonary tuberculosis (TB).

## Immunopathogenesis

- Inhaled bacilli are engulfed by alveolar macrophages, but can survive and multiply within them.
- Mycobacteria spread in macrophages in the blood to oxygen-rich sites in the body such as the lung apices, kidneys, bones, and meninges.
- After a few weeks, mycobacteria-specific CD4<sup>+</sup> helper T-cells are activated following MHC class II antigen presentation by macrophages.
- Th1 subset helper T-cells secrete IFN- $\gamma$ , activating macrophages into epithelioid macrophages which aggregate into granulomas and wall off the mycobacteria in an anoxic and acidic environment.
- Most immunocompetent hosts contain the infection, leading to scarring.
- Active disease tends to occur in the elderly, malnourished, diabetic, immunosuppressed, or alcoholic.
- Active disease may be pulmonary (75%) or extrapulmonary (25%).

## Presentation

- Pulmonary TB presents as a chronic pneumonia with persistent cough, fever, night sweats, weight loss, and loss of appetite.
- Extrapulmonary TB may present with meningitis, lymphadenopathy, genitourinary symptoms, bone or joint pain.

## Diagnosis

- Acid-fast bacilli may be seen in sputum, pleural fluid, or bronchoalveolar lavage (BAL) fluid.
- Culture is the definitive investigation, but takes up to 12 weeks.
- Polymerase chain reaction (PCR) can be used for diagnosis and identification of drug-resistant strains.

## Histopathology

- The histological hallmark is necrotizing granulomatous inflammation.

## Prognosis

- With antituberculous treatment, most people make a full recovery.
- Untreated, about half of people will eventually die of the infection.
- Prognosis is worse with coexisting HIV or organisms with multidrug resistance.

# Infectious mononucleosis

## Pathogen

- Epstein–Barr virus (EBV), a DNA herpesvirus.

## Epidemiology

- Most patients are teenagers or young adults.
- No gender or racial predilection.

## Transmission

- Saliva or droplet spread from an EBV-infected person.
- Incubation period of 4–5 weeks.

## Pathogenesis

- EBV infects oropharyngeal epithelial cells via the C3d receptor and replicates within them.
- EBV also infects B-lymphocytes where the linear genome circularizes and persists as an episome.
- Viral persistence allows ongoing replication in oropharyngeal epithelial cells and the release of infectious particles into saliva.

## Presentation

- Sore throat, fever, malaise.
- Clinical examination may reveal lymphadenopathy, palatal petechiae, and splenomegaly.

## Diagnosis

- Lymphocytosis.
- Peripheral blood film shows large atypical lymphocytes (these are not specific for EBV).
- 90% have heterophil antibodies (Paul–Bunnell; Monospot test).
- EBV-specific IgM antibodies imply current infection.

## Histopathology

- Lymph nodes and tonsils show marked paracortical expansion by large lymphoid blasts which are a mixture of B- and T-cells.
- EBV-LMP1 antigen can be detected in some of the B-blasts immunohistochemically.

## Prognosis

- In most cases, the illness is self-limiting.
- Rare complications include meningitis, encephalitis, cranial nerve lesions, Guillain–Barré syndrome, depression, and fatigue.

# Malaria

## Pathogen

- Plasmodia protozoa: *Plasmodium* (*P.*) *falciparum*, *P. vivax*, *P. ovale*, *P. malariae*.

## Epidemiology

- Endemic in tropical Africa, Asia, and South America.
- ~10 million new infections each year.
- ~1 million deaths each year (mostly *P. falciparum*).

## Transmission

- *Plasmodium* sporozoites are injected by the female *Anopheles* mosquito during a blood meal.

## Pathogenesis

- Sporozoites infect hepatocytes and proliferate into merozoites.
- Merozoites infect and multiply in red cells, causing haemolytic anaemia.
- Sequestration of red cells heavily parasitized by *P. falciparum* causes acute renal failure and cerebral malaria (Fig. 2.2).

## Presentation

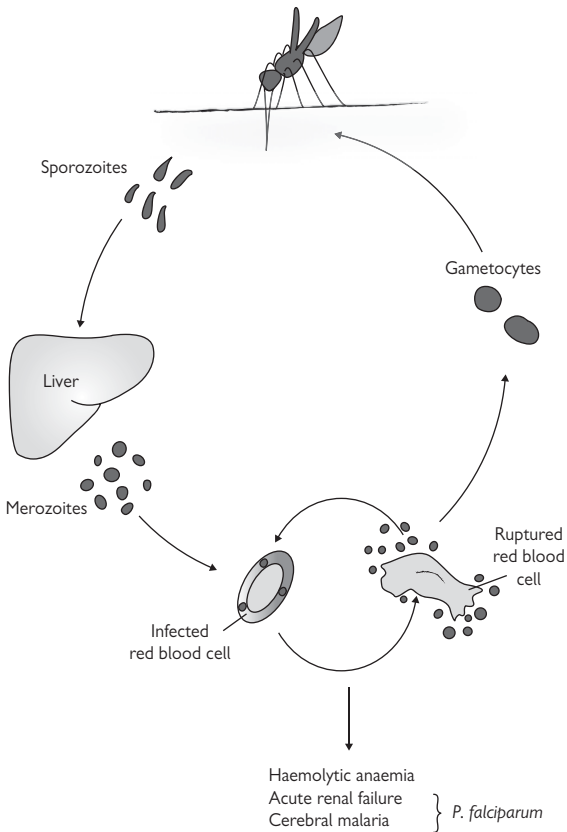
- Non-specific flu-like illness initially with headache, malaise, and myalgia.
- Fevers and chills then follow.
- Cerebral malaria presents with confusion, seizures, and coma.

## Diagnosis

- Parasitized red cells may be seen on examination of blood films.

## Prognosis

- Non-falciparum malaria has a very low mortality.
- Severe falciparum malaria can kill. Poor prognostic signs include high levels of parasitaemia, hypoglycaemia, disseminated intravascular coagulation (DIC), and renal impairment.



**Fig. 2.2** Malaria life cycle. An infected mosquito injects sporozoites into blood which home to the liver and multiply in hepatocytes, forming merozoites. Merozoites released into blood infect red blood cells and multiply again, rupturing the red cells and infecting more red cells. Some merozoites mature into gametocytes which newly infect a mosquito, completing the life cycle. Reproduced with permission from *Clinical Pathology*, Carton, Daly, and Ramani, Oxford University Press, p. 26, Figure 3.5.



# Syphilis

## Pathogen

- *Treponema pallidum*, a coiled spirochaete.

## Epidemiology

- Worldwide distribution.
- Incidence increasing since the 1990s.

## Transmission

- Almost always through sexual contact with an infected person.
- Can pass from mother to baby and cause congenital syphilis.

## Pathogenesis

- Organisms enter the body via minor abrasions in epithelial surfaces.
- The organism produces a non-antigenic mucin coat which facilitates rapid spread throughout the body via blood and lymphatics.

## Presentation

- Primary syphilis causes a firm painless skin ulcer ('chancre') which appears about 3 weeks following exposure. The chancre occurs at the point of contact and is usually genital or perianal. There may be mild regional lymph node enlargement.
- Secondary syphilis presents 1–2 months after the chancre with rash, malaise, lymphadenopathy, and fever.
- Tertiary syphilis present years after exposure with so-called gummas in skin, mucosa, bone, joints, lung, and testis. Gummas are inflammatory masses caused by a granulomatous reaction to the organism.
- Quaternary syphilis causes ascending aortic aneurysms, cranial nerve palsies, dementia, and tabes dorsalis.

## Diagnosis

- In primary syphilis, the organisms may be visualized by microscopy of chancre fluid. Serology is often negative at this stage.
- In secondary syphilis, the organisms may be seen in the lesions and serology is usually positive.
- Organisms are usually not seen in later stages of syphilis, but serology usually remains positive.

## Prognosis

- Antibiotic treatment during primary or secondary stages is usually curative and prevents risk of longer term complications related to later stage disease.

# Lyme disease

## Pathogen

- *Borrelia burgdorferi*, a spirochaete.

## Epidemiology

- Found in temperate zones of Europe, North America, and Asia.

## Transmission

- Arthropod-borne infection transmitted via ticks of the genus *Ixodes*.

## Pathogenesis

- *Borrelia* organisms are injected into the skin via the tick bite where they establish infection and proliferate.
- Days to weeks later, *Borrelia* spreads via the bloodstream to distant sites, notably the joints, heart, and nervous system.
- *Borrelia* evades the immune system through antigenic variation of its surface proteins and inactivating complement components.

## Presentation

- The earliest sign is an outwardly expanding erythematous rash at the site of the tick bite, known as **erythema migrans**. Many patients do not present with or recall the rash.
- Later signs include arthralgia, myalgia, neuropathies, changes in cognition, and palpitations.

► The presence of non-specific features across multiple body systems can make the diagnosis extremely challenging.

## Diagnosis

- Western blot, ELISA, or PCR analysis on blood or CSF.

## Prognosis

- Most people diagnosed and treated recover fully with no complications.

## Leishmaniasis

### Pathogen

- *Leishmania* protozoa.

### Epidemiology

- 1–2 million new cases each year worldwide.
- Seen in Africa, India, South America, Middle East, and Mediterranean.

### Transmission

- Inoculation from the bite of an infected sandfly.

### Pathogenesis

- The parasite is inoculated into the dermis and phagocytosed by dermal macrophages.
- The ability of each species to survive within macrophages and evade host immunity dictates the clinical outcome.

### Presentation

- **Cutaneous leishmaniasis**, caused by *Leishmania (L.) tropica* and *L. Mexicana*, usually present with a single nodule which ulcerates and heals with scarring.
- **Mucocutaneous leishmaniasis**, caused by *L. braziliensis*, presents with skin lesions resembling the cutaneous form which may spread to the mucosa of the nose, mouth, and pharynx.
- **Visceral leishmaniasis** (kala-azar), caused by *L. donovani*, presents with fever, anaemia, lymphadenopathy, and hepatosplenomegaly due to widespread dissemination of the organism via macrophages through the reticuloendothelial system.

### Diagnosis

- Microscopy, culture, FISH, or PCR.

### Histopathology

- Skin biopsies show a heavy dermal inflammatory infiltrate composed of lymphocytes, plasma cells, and many parasitized macrophages.
- The organisms are round to oval, 2–4 micrometre in size, with an eccentric kinetoplast.

### Prognosis

- Cutaneous disease usually resolves spontaneously over a period of months.
- Mucocutaneous disease should be treated early as outcome is less satisfactory once mucosal sites are involved.
- Visceral disease is fatal without treatment due to liver failure and bone marrow failure.

# Vascular pathology

- Atherosclerosis 28
- Shock 30
- Hypertension 31
- Chronic lower limb ischaemia 32
- Acute lower limb ischaemia 33
- Aortic dissection 34
- Abdominal aortic aneurysm 35
- Varicose veins 36
- Deep vein thrombosis 37

## Atherosclerosis

### Definition

- An inflammatory disease of large- and medium-sized systemic arteries characterized by the formation of lipid-rich plaques in the vessel wall.

### Epidemiology

- Almost universally present to some degree in all individuals with ageing.

### Aetiology

- Risk factors include age, male gender, diabetes mellitus, hypertension, smoking, and hyperlipidaemia.
- ▶ Men who smoke have a 70% increase in death rate from ischaemic heart disease compared to non-smokers.

### Pathogenesis

- Endothelial injury leads to an inflammatory and fibroproliferative reaction in the artery, culminating in atherosclerosis ('response to injury' hypothesis).
- Endothelium may be damaged by multiple factors, including smoking, hyperglycaemia, and oxidized LDL.
- Oxidised LDL is particularly potent at driving atherosclerosis through its proinflammatory and procoagulant effects.
- Stable plaques with few inflammatory cells and a thick fibrous cap narrow the lumen of the artery, but are less likely to cause acute complications.
- Unstable plaques with more inflammatory cells have a thin fibrous cap vulnerable to erosion, cracking, or rupture. Exposure of the highly thrombogenic lipid core to the blood causes an acute ischaemic event in the organ that artery is supplying (Fig. 3.1).

### Presentation

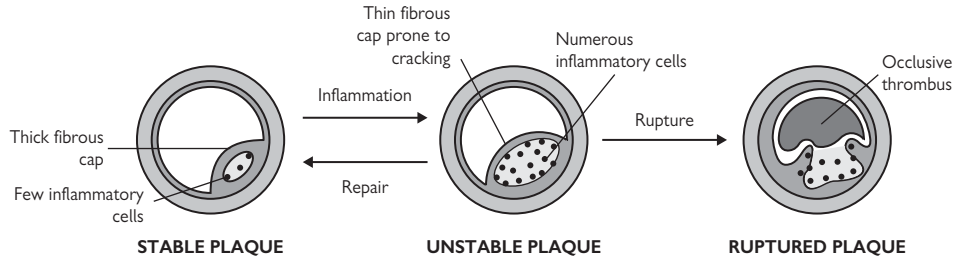
- Stable plaques cause symptoms of reversible ischaemia in the supplied organ, e.g. angina pectoris, chronic lower limb ischaemia.
- Unstable plaques cause acute ischaemic events, e.g. acute coronary syndromes, stroke, acute lower limb ischaemia.

### Macroscopy

- Atherosclerotic plaques are yellow lipid-rich lesions within the walls of large- and medium-sized arteries.
- Superimposed thrombus has a dark brown appearance.
- Sites of predilection are the coronary arteries, abdominal aorta, iliac arteries, and carotid artery bifurcations.

### Histopathology

- The intima is expanded by a plaque composed of a lipid-rich core with overlying fibrous tissue.
- If there has been superimposed thrombosis, then a fibrin-rich clot may also be present, occluding the artery.



**Fig. 3.1** Plaque stability. Stable plaques have few inflammatory cells with a thick fibrous cap. Increased inflammatory activity within an atherosclerotic plaque results in thinning of the fibrous cap, making it unstable and more liable to complications such as rupture. Reproduced with permission from *Clinical Pathology*, Carton, Daly, and Ramani, Oxford University Press, p. 79, Figure 6.10.

# Shock

## Definition

- A generalized failure of tissue perfusion.

## Aetiology

- Pump failure, e.g. acute myocardial infarction.
- Peripheral circulation failure, e.g. hypovolaemia, sepsis, anaphylaxis (📖 p. 10), tension pneumothorax (📖 p. 81), large pulmonary embolus (📖 p. 67).

## Pathogenesis

- Pump or peripheral circulation failure leads to cardiovascular collapse.
- Prolonged inadequate tissue perfusion risks the development of multiple organ failure.

## Presentation

- Tachycardia due to increased sympathetic drive.
  - Urine output declines (only apparent if the patient is catheterized).
  - Hypotension.
- ▶ Note up to 15% of circulating volume may be lost before any clinical signs become apparent.

## Prognosis

⚠ Shock is a serious condition which leads to the development of multiple organ failure if not rapidly addressed.

# Hypertension

## Definition

- Persistently elevated blood pressure at a level where the benefit of treatment is clear-cut for that individual.
- All patients with blood pressure  $\geq 160/100$ mmHg should be treated.
- Decision to treat levels  $\geq 140/90$ mmHg depends on other risk factors.

## Epidemiology

- Very common.
- Marked geographical and racial variability.
- Incidence thought to be as high as 25–30% in western countries.

## Aetiology

- 95% are of unknown cause ('essential').
- 5% of cases are due to chronic kidney disease (📖 p. 142), pheochromocytoma (📖 p. 248), adrenal cortical adenoma (📖 p. 245), coarctation of the aorta (📖 p. 41), pregnancy, and oral contraceptive pill.

## Pathogenesis

- Highly complex with multiple factors, including salt intake and genetic susceptibility, appearing to interact to produce hypertension.
- Sustained hypertension promotes atherosclerosis in medium and large systemic arteries and causes thickening of small arteries (arteriosclerosis) and arterioles (arteriolosclerosis).
- Hypertension increases the work of the left ventricle, causing left ventricular hypertrophy and eventually left ventricular failure.

## Presentation

- Most patients are asymptomatic and diagnosed when blood pressure is measured.
- Others present with symptoms related to end organ damage caused by the hypertension, e.g. intracerebral haemorrhage, left ventricular failure, chronic kidney disease.

## Prognosis

- Untreated or undertreated disease increases the risk of left ventricular failure, intracerebral haemorrhage, chronic kidney disease, and aortic dissection.



## Chronic lower limb ischaemia

### Definition

- Persistent compromise of the arterial supply to the lower limbs.

### Epidemiology

- Common.
- Affects 7% of men aged >50y.
- ♂:♀ ratio is 2:1.

### Aetiology

- Almost all cases are caused by atherosclerosis affecting the aorto-iliac, femoral, or popliteal and calf vessels, either singly or in combination.

### Pathogenesis

- Single-level disease usually results in intermittent claudication.
- Two-level disease usually results in critical limb ischaemia.

### Presentation

- Intermittent claudication is characterized by calf or thigh pain brought on by exercise and relieved by rest.
- Critical limb ischaemia is characterized by rest pain or tissue necrosis (gangrene or ulceration) or Doppler ankle pressure <50mmHg.

### Prognosis

- One third improves, one third remains stable, one third deteriorates.
- 4% require an intervention and 1% result in amputation.

## Acute lower limb ischaemia

### Definition

- Abrupt sudden cessation of the arterial supply to the lower limb.

### Epidemiology

- Incidence reported at 14 per 100,000 people per year.

### Aetiology

- 60% due to acute thrombosis in a vessel with pre-existing atherosclerosis.
- 30% due to thromboembolus from a distant site, usually the heart. Common cardiac associations are atrial fibrillation, acute myocardial infarction, or ventricular aneurysm. Common sites of impaction are the popliteal artery, common femoral artery, and aortic bifurcation.
- Rarer causes include aortic dissection, trauma, and iatrogenic injury.
- Iatrogenic injury is becoming more common with the growing use of endovascular procedures.

### Pathogenesis

- Sudden occlusion of the arterial supply to the leg causes ischaemia.
- Without intervention, irreversible tissue damage occurs within 6 hours.
- Massive muscle necrosis leads to hyperkalaemia, acidosis, acute renal failure, and cardiac arrest.

### Presentation

- Sudden onset of pain and loss of sensation in the limb.
- On examination, the limb is pale and cold with reduced or absent pulses.

### Prognosis

- Limb loss in 40% of cases.
- Death in 20% of cases.

## Aortic dissection

### Definition

- A tear in the aortic wall through which blood tracks.

### Epidemiology

- Most cases occur in adults aged 50–70y.
- ♂:♀ ratio is 2:1.

### Aetiology

- Most cases are related to hypertension.
- Other associations include Marfan's syndrome and congenital bicuspid aortic valve (📖 p. 41).

### Pathogenesis

- Precisely how hypertension leads to aortic dissection is controversial.
- Proposed that the initiating event is haemorrhage from a vasa vasorum into the media of the aorta. The intima is placed under stress and tears, allowing blood to track into the media and dissect along it.
- Dissections may propagate in the direction of the normal flow of aortic blood (anterograde) or against the normal flow of blood towards the aortic root (retrograde).
- Dissections may re-enter the aortic lumen at a distant site (creating a so-called 'double-barrelled' aorta) or rupture externally into the pericardial cavity, pleural cavity, or peritoneal cavity.
- ~75% involve the ascending aorta or aortic arch (type A).
- ~25% involve the descending aorta, without involvement of the ascending aorta or aortic arch (type B).

### Presentation

- Acute severe 'tearing' chest pain which may closely mimic acute myocardial infarction.
- External rupture causes massive internal haemorrhage and shock.

### Macroscopy

- A tear is usually visible in the intima of the aorta where the dissection starts and ends.
- If the dissection ruptures externally, large quantities of blood clot will be found around the site of rupture.

### Histopathology

- Microscopy has limited value in explaining why dissection occurs.
- However, the presence of substantial degenerative changes in the aortic wall of patients aged <60y raises the possibility of an inherited aortopathy such as Marfan's.

### Prognosis

- Untreated cases have a high mortality rate (50% within the first week).
- Treated cases have good initial survival, but remain at risk of death from rupture of the dissection or development of a new dissection.

# Abdominal aortic aneurysm

## Definition

- A permanent dilation of the abdominal aorta >3cm in diameter.

## Epidemiology

- Incidence is reported to be 5–10%.

## Aetiology

- Almost all are caused by aortic atherosclerosis.

## Pathogenesis

- Proteolytic enzymes weaken the media of the aorta, leading to aneurysmal change.
- Increased levels of matrix metalloproteinases have been found in aneurysmal aortas. These enzymes are known to degrade elastin.

## Presentation

- Unruptured aneurysms are often asymptomatic, but may cause abdominal or back pain. Most are discovered incidentally on abdominal examination or imaging.
- Ruptured abdominal aortic aneurysms present as a surgical emergency with abdominal pain and shock.

## Macroscopy

- The aorta is dilated, usually below the level of the renal arteries.
- Extensive atherosclerosis is invariably present, often with secondary thrombosis and calcification.

## Prognosis

- The natural history is that of gradual enlargement.
- Risk of rupture is exponentially related to diameter.
- Mortality after rupture exceeds 80%.
- Elective surgical repair should be considered for aneurysms with a maximum diameter of 5.5cm or more.

## Varicose veins

### Definition

- Tortuous and dilated superficial leg veins associated with valvular incompetence.

### Epidemiology

- Affect up to 20% of the population.
- Marked female predilection (♀:♂ ratio 9:1).

### Aetiology

- Most cases are primary and idiopathic.
- Secondary causes include pregnancy, large fibroids, and ovarian masses.

### Pathogenesis

- Thought that valve cusps degenerate and develop holes within them.
- Incompetence of the valves increases strain on the valve downstream.
- Eventually, a column of valves become incompetent, leading to dilation of the vein.

### Presentation

- Most patients present due to the unsightly nature of the veins.
- There may be associated discomfort, aching, itching, and swelling.
- Symptoms may be worse at the end of the day.

### Complications

- Stasis (varicose) dermatitis.
- Varicose ulceration.
- Lipodermatosclerosis.
- Bleeding.
- Thrombosis (superficial thrombophlebitis).

# Deep vein thrombosis

## Definition

- Thrombosis within the deep leg veins.

## Epidemiology

- ~1 in 1000 people each year.

## Aetiology

- Related to stasis of blood and/or an increase in blood coagulability.
  - Risk factors include immobility, pregnancy, recent surgery (particularly to lower limb or pelvis), malignancy, long haul flights, smoking, oral contraceptive pill, HRT, and thrombophilia.
- ▶ Multiple contributory factors will often operate within an individual.

## Pathogenesis

- Sluggish blood flow and/or increased blood coagulability overcomes natural anticoagulant activity and causes thrombus to form in the deep leg veins.
- The thrombus may enlarge in size as it propagates along the lumen of the vein.

## Presentation

- Warm red painful swollen lower limb.
- Some cases may not produce symptoms or signs.

## Complications

- ▶▶ Pulmonary thromboembolism ( p. 67).

*This page intentionally left blank*

# Cardiac pathology

- Congenital heart disease 40
- Angina pectoris 42
- Unstable angina 43
- Non-ST-elevation myocardial infarction 44
- ST-elevation myocardial infarction 46
- Left ventricular failure 48
- Right ventricular failure 50
- Valvular heart disease 51
- Cardiomyopathies 52
- Infective endocarditis 53
- Myocarditis 54
- Pericarditis 55



## **Congenital heart disease**

### **Ventricular septal defect**

- Most common type of congenital heart disease (CHD).
- An abnormal hole in the interventricular septum.
- May occur anywhere in the septum, but most occur in the upper part.
- A small ventricular septal defect (VSD) may have little functional significance and may close spontaneously as the child ages. There remains, however, a risk of infective endocarditis.
- A larger VSD causes a left-to-right shunt and increased volume load on the right ventricle with symptoms of cardiac failure.

### **Patent ductus arteriosus**

- Persistence of the ductus arteriosus after 10 days of life.
- Systemic blood flows from the aorta to the pulmonary artery, causing a left-to-right shunt.
- Blood flow to the lungs is increased 2-fold as is the volume return to the left side of the heart, causing left ventricular hypertrophy.
- Infective endocarditis is a frequent complication.

### **Atrial septal defect**

- An abnormal hole in the atrial septum.
- Commonest site is in the middle of the septum away from the atrioventricular valves.
- Blood flows from the left to right atrium, causing an increase in circulation through the lungs.
- May be asymptomatic or cause easy fatiguability in childhood.
- Many present in adulthood due to atrial arrhythmias.

### **Atrioventricular septal defect**

- A defect at the junction of the atrial and ventricular septa.
- In a complete atrioventricular septal defect (AVSD), there is a combination of a low atrial septal defect (ASD) and high VSD (essentially a hole right in the centre of the heart).
- Most function like a VSD with a volume overload to the right ventricle.
- Most common form of CHD seen in children with Down's syndrome.

### **Tetralogy of Fallot**

- Comprises pulmonary stenosis, VSD, overriding aorta, and right ventricular hypertrophy.
- Pulmonary stenosis causes a right-to-left shunt and reduced blood flow to the lungs, resulting in cyanosis.

### **Transposition of the great arteries**

- Incorrect placement of the aorta to the right ventricle and pulmonary artery to the left ventricle.
- Always an associated defect to allow mixing of blood from both circulations (e.g. VSD or patent ductus arteriosus [PDA]) or the abnormality is incompatible with life.

### Coarctation of the aorta

- A localized narrowing of the lumen of the aortic arch distal to the origin of the left subclavian artery.
- In the infantile form, a PDA distal to the coarctation allows cardiac output to the lower body, but most of this is deoxygenated blood from the right side of the heart so there is cyanosis of the lower half of the body.
- In the adult form, there is no PDA. Increased blood flow to the upper half of the body is increased and most patients develop upper extremity hypertension. This form is often not recognized until adult life.

### Bicuspid aortic valves

- Tend to function well at birth and go undetected.
- Most bicuspid valves eventually develop calcific aortic stenosis (at an earlier age than typical 'senile' aortic stenosis) or aortic regurgitation.
- Increased risk of aortic dissection in adult life (📖 p. 34).

## Angina pectoris

### Definition

- Recurrent transient episodes of chest pain due to myocardial ischaemia.

### Epidemiology

- Very common.

### Aetiology

- Virtually always caused by coronary artery atherosclerosis.
- Major risk factors are smoking, hypertension, diabetes, and hyperlipidaemia.
- Hypertension and aortic stenosis may also contribute by causing left ventricular hypertrophy and increased myocardial oxygen demand.

### Pathogenesis

- Myocardial ischaemia occurs whenever myocardial oxygen demand outstrips supply.
- A significant fixed stenosis of a coronary artery impairs coronary blood flow when myocardial oxygen demand increases, e.g. during exercise.

### Presentation

- Central chest discomfort which is often described as a pressure, heaviness, tightness, or squeezing sensation.
- The pain often radiates up the neck into the jaw and across the shoulders and upper arms.
- May be associated with nausea and sweating.
- Episodes of angina are typically precipitated by exercise or emotional stress, last for a few minutes, and terminate upon resting or taking medication.

### Macroscopy

- Significant stenosis of a coronary artery by atherosclerosis.
- No gross changes visible in the myocardium.

### Histopathology

- No specific light microscopic features in the myocardium.

### Prognosis

- Atherosclerosis is often generalized so patients are at risk not only from other forms of ischaemic heart disease (acute myocardial infarction, left ventricular failure [LVF]), but also abdominal aortic aneurysm, peripheral vascular disease, and stroke.

# Unstable angina

## Definition

- Severe acute myocardial ischaemia without myocardial necrosis.

## Epidemiology

- Very common.

## Aetiology

- Almost always due to coronary artery atherosclerosis.

## Pathogenesis

- Erosion of the surface of an unstable atherosclerotic plaque stimulates platelets to aggregate over the plaque.
- Platelet fragments may also break off and embolize down the artery.
- The reduction in coronary blood flow causes acute ischaemia of the affected myocardium, but not myocardial necrosis.

## Presentation

- Acute coronary syndrome with sudden onset of prolonged ischaemic cardiac chest pain at rest or on minimal exertion.
- The electrocardiogram (ECG) shows ischaemic changes, but not ST-elevation.

## Biochemistry

- Blood troponin levels do not rise.

## Macroscopy

- Significant stenosis of the involved coronary artery by a complicated atherosclerotic plaque.
- No gross changes visible in the myocardium.

## Histopathology

- No specific light microscopic features in the myocardium.

## Prognosis

- Patients are at high risk of future acute coronary events and subsequent development of LVF.

## **Non-ST-elevation myocardial infarction**

### **Definition**

- Partial thickness necrosis of an area of the myocardium.

### **Epidemiology**

- Very common.

### **Aetiology**

- Almost always due to coronary artery atherosclerosis.

### **Pathogenesis**

- Cracking or fissuring of an unstable atherosclerotic plaque stimulates the formation of a platelet-rich thrombus.
- The thrombus causes significant prolonged narrowing of the artery such that part of the territory of the supplied myocardium undergoes ischaemic necrosis.

### **Presentation**

- Acute coronary syndrome with prolonged ischaemic cardiac chest pain at rest or minimal exertion.
- ECG shows ischaemic changes, but not ST-elevation.

### **Biochemistry**

- Blood troponin levels are elevated.

### **Macroscopy**

- Significant stenosis of the involved coronary artery by a complicated atherosclerotic plaque.

### **Histopathology**

- The earliest change of myocardial infarction is increased cytoplasmic eosinophilia and loss of nuclei within the affected myocytes after about 8–12h.
- By 24h, neutrophils infiltrate the necrotic area and after a few days, granulation tissue is laid down.
- Over a period of several weeks, the granulation tissue is replaced by scar tissue.

### **Prognosis**

- Patients are at high risk of future acute coronary events and subsequent development of LVF.

*This page intentionally left blank*

## ST-elevation myocardial infarction

### Definition

- Full thickness necrosis of an area of the myocardium.

### Epidemiology

- Very common.

### Aetiology

- Almost always a complication of coronary artery atherosclerosis.

### Pathogenesis

- Rupture of an unstable coronary artery atherosclerotic plaque stimulates the formation of an occlusive fibrin-rich thrombus over the plaque.
- Complete occlusion of the coronary artery leads to full thickness necrosis of the area of myocardium supplied by that artery (Fig. 4.1).

### Presentation

- Severe ischaemic cardiac chest pain which does not resolve.
- Patients often describe a feeling as though they are going to die.
- ECG shows ST-elevation or new onset left bundle branch block.

### Biochemistry

- Blood troponin levels are elevated.

### Macroscopy

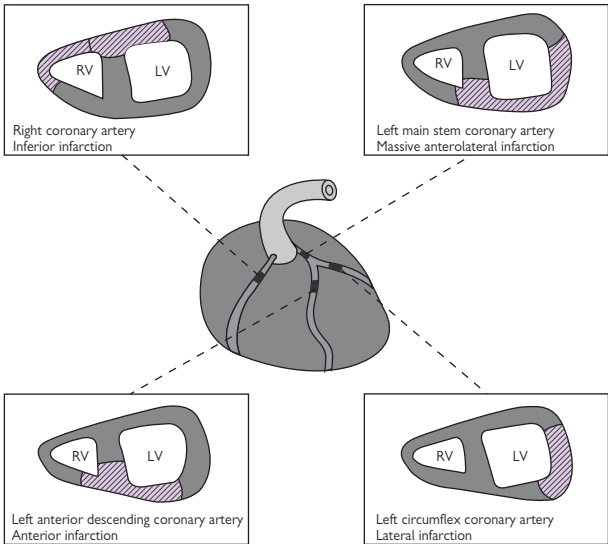
- The affected coronary artery shows complete occlusion by a thrombus overlying an atherosclerotic plaque.
- The infarcted myocardium is not discernible until about 15h after the event where it appears soft and swollen with a darker red colour.
- By 24–48h, the infarct turns yellow.
- Over a period of weeks to months, the infarct is replaced by white scar tissue and the ventricular wall becomes thinned.

### Histopathology

- The earliest change of myocardial infarction is cytoplasmic eosinophilia and loss of nuclei within the affected myocytes after ~8–12h.
- By 24h, neutrophils infiltrate the necrotic area and after a few days, granulation tissue is laid down.
- Over a period of weeks to months, the granulation tissue is replaced by fibrous scar tissue.

### Prognosis

- Immediate complications include ventricular arrhythmias (which may be fatal) and acute cardiac failure in severe cases. Rupture of the free wall of the infarcted ventricle causes haemopericardium with rapid cardiac tamponade and death. Thrombus forming over the akinetic myocardium can detach and give rise to systemic emboli.
- Later complications include ventricular aneurysm formation and the development of LVF.



**Fig. 4.1** Territories of myocardial infarction according to the coronary artery involved.

Reproduced with permission from *Clinical Pathology*, Carton, Daly, and Ramani, Oxford University Press, p. 90, Figure 6.17.



## Left ventricular failure

### Definition

- A syndrome resulting from insufficient left ventricular output.

### Epidemiology

- Very common.
- Occurs in ~1% of people after age 75 and 2% after 80y.

### Aetiology

- Ischaemic heart disease.
- Hypertensive heart disease.
- Aortic or mitral valve disease.

► Note that all of these are common and so LVF is often due to a combination of two or more of these conditions.

### Pathogenesis

- Falling cardiac output triggers a drop in blood pressure. Low blood pressure stimulates baroreceptors and reduces renal blood flow.
- This leads to sympathetic overdrive and the activation of the renin-angiotensin-aldosterone system.
- Blood pressure is restored at the expense of an increased heart rate, increased peripheral vascular resistance (afterload), and increased blood volume (preload).
- Unfortunately, this short-term solution is deleterious in the long term as the work of the heart is increased even further (Fig. 4.2).
- In response, the left ventricle undergoes hypertrophy, but this reduces the volume of ventricular cavity and lowers the stroke volume.
- Eventually, the heart becomes overloaded with blood and dilates.

### Presentation

- Breathlessness, fatigue, palpitations.
- Peripheral oedema and ascites tend to occur in advanced disease.

### Macroscopy

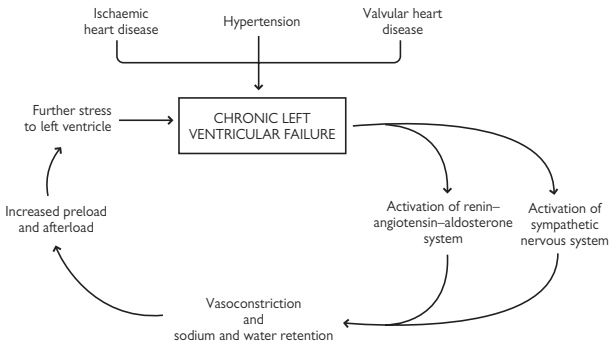
- The heart is heavy and the left ventricle is hypertrophic and dilated.
- The underlying cause(s) may also be evident, e.g. coronary artery atherosclerosis or valvular disease.

### Histopathology

- Histology is non-specific, usually showing patchy myocyte hypertrophy and interstitial fibrosis as a result of chronic injury to the chamber.

### Prognosis

- Poor prognosis with many patients dying within 3y of diagnosis.
- Associated with a poor quality of life and frequent hospital admissions.
- Fatal ventricular arrhythmias are a common cause of sudden death.



**Fig. 4.2** The neurohormonal response in chronic left ventricular failure. Reproduced with permission from *Clinical Pathology*, Carton, Daly, and Ramani, Oxford University Press, p. 84, Figure 6.13.

## Right ventricular failure

### Definition

- A syndrome resulting from insufficient right ventricular output.

### Epidemiology

- Uncommon.
- Seen much less frequently than LVF.

### Aetiology

- Most cases are caused by chronic lung diseases such as chronic obstructive pulmonary disease (COPD), pulmonary fibrosis, bronchiectasis, and recurrent pulmonary emboli.
- Rarer causes include ischaemic heart disease affecting the right ventricle and right-sided valvular heart disease.

### Pathogenesis

- In most cases, right ventricular failure (RVF) is the result of pulmonary hypertension caused by chronic lung diseases.
- Pulmonary hypertension increases the work of the right ventricle by requiring a higher chamber pressure to maintain adequate output.
- Initially, there is right ventricular hypertrophy, but eventually the chamber dilates and fails.

### Presentation

- Worsening of pre-existing breathlessness and development of peripheral oedema.

### Macroscopy

- The right ventricle is hypertrophic and dilated.

### Histopathology

- Histology is non-specific, usually showing patchy myocyte hypertrophy or atrophy with interstitial fibrosis.

### Prognosis

- High chance of death from a combination of cardiac and respiratory failure.
- Many patients die suddenly from a fatal ventricular arrhythmia arising in the diseased right ventricle.

## Valvular heart disease

### Aortic stenosis

- Most common valve disease.
- Most are caused by calcification of an anatomically normal tricuspid valve in the elderly (senile calcific aortic stenosis). Bicuspid aortic valves calcify at a younger age.
- Chronic rheumatic disease may also cause aortic stenosis.
- Years of turbulent blood flow across the valve is thought to cause damage followed by calcification.
- Presents with chest pain, syncope, and breathlessness.

### Aortic regurgitation

- Caused by diseases which dilate the aortic root, e.g. Marfan's syndrome, ankylosing spondylitis.
- Congenital abnormalities of the valve leaflets may also cause aortic regurgitation (AR).
- Dilation of the aortic root causes pulls the annulus of the aortic valve and prevents tight closure of the leaflets.
- Presents with breathlessness and palpitations.

### Mitral stenosis

- Usually the result of chronic rheumatic valvular heart disease.
- Narrowing of the valve prevents free flow of blood from the left atrium into the left ventricle during ventricular diastole.
- The rise in left atrial pressure is transmitted to the pulmonary venous system, causing pulmonary oedema and breathlessness.
- The left atrium increases in size and become prone to developing atrial fibrillation.
- Stenotic mitral valves shows marked thickening of the valve leaflets and attached chordae tendinae. Fusion of the leaflets gives rise to the so-called 'fish mouth' appearance.

### Mitral regurgitation

- Usually due to mitral valve prolapse or ischaemic heart disease.
- In mitral valve prolapse, the abnormal valve leaflets balloon into the left atrium during ventricular systole.
- In ischaemic heart disease, the regurgitation is caused by a combination of ischaemic papillary dysfunction and widening of the mitral valve annulus due to left ventricular dilation.
- Patients may remain asymptomatic for some time as the left ventricle and left atrium enlarge to cope with the increased volume, but eventually, there is decompensation and development of LVF.

## Cardiomyopathies

### Hypertrophic cardiomyopathy

- Uncommon with an incidence of 0.5%.
- ~70% of cases have been linked to mutations in genes encoding sarcomeric proteins such as  $\beta$ -myosin heavy chain, troponin T, myosin binding protein, and  $\alpha$ -tropomyosin.
- Wide spectrum of presentation including breathlessness, angina, syncope, palpitations, and sudden death.
- Macroscopically, most cases show asymmetric left ventricular hypertrophy involving predominantly the septum. Associated systolic anterior motion of the mitral valve often leads to a patch of endocardial fibrosis over the septum known as the sub-aortic mitral impact lesion.
- Some cases cause symmetric left ventricular hypertrophy indistinguishable from that caused by hypertension or aortic stenosis.
- The histological hallmark of HCM is the presence of myocyte hypertrophy, myocyte disarray, and interstitial fibrosis. Myocyte disarray refers to the loss of the normal parallel arrangement of myocytes which, instead, adopt haphazard oblique organizations.

### Idiopathic dilated cardiomyopathy

- Uncommon with an incidence of 0.2%.
- Mode of inheritance includes autosomal dominant, X-linked, and autosomal recessive forms as well as mitochondrial inheritance.
- Mutations in a number of genes have been described, including cardiac actin, desmin, sarcoglycan, troponin, and tropomyosin.
- Presents with breathlessness, fatigue, and palpitations. Thrombus formation over the akinetic myocardium can cause systemic emboli.
- Macroscopically, the heart has increased mass with dilation and thinning of the cardiac chambers in the absence of any cause to account for it (e.g. coronary artery disease, valvular disease, hypertension, alcohol abuse).
- Microscopic findings are not specific, but may show myocyte attenuation and loss of myofibrils with the enlargement of myocyte nuclei together with interstitial fibrosis.

### Arrhythmogenic right ventricular cardiomyopathy

- Exact incidence and prevalence in the general population is unknown.
- Mutations in genes encoding cell adhesion molecules described.
- Mutations lead to detachment and apoptosis of myocytes under mechanical stress, with subsequent fat replacement and scarring.
- Presents with palpitations or sudden death.
- Macroscopically, there is thinning of the right ventricle, often the right ventricular outflow tract, with a yellow appearance due to fat replacement.
- Microscopically, there is replacement of the normal right ventricular myocardium by fat and fibrosis. The disease process usually starts in the epicardial region and works its way towards the endocardial surface.

# Infective endocarditis

## Definition

- An infection of the interior surface of the heart, usually a heart valve.

## Classification

- Acute endocarditis is caused by pathogenic organisms infecting a structurally normal heart.
- Subacute endocarditis is a more insidious illness caused by weakly pathogenic organisms infecting a structurally abnormal heart.

## Epidemiology

- Uncommon, but important to recognize.

## Microbiology

- Acute endocarditis is usually due to *Staphylococcus (S.) aureus*.
- Subacute endocarditis is most commonly is due to *Streptococcus (S.) viridans* or *Enterococci*.

## Pathogenesis

- *S. aureus* usually gains access to the blood from the skin via indwelling vascular lines or via intravenous drug abuse.
- *S. viridans* gain access to the blood from the oropharynx following tooth brushing or dentistry.
- *Enterococci* gain access to the bloodstream following instrumentation of the bowel (endoscopy) or bladder (cystoscopy or catheterization).

## Presentation

- Left-sided acute endocarditis presents acutely with fever and signs of valve damage. Major systemic embolic events are also common; septic emboli can travel to multiple organs and cause abscesses.
- Right-sided acute endocarditis presents with fevers, chills, and prominent pulmonary symptoms due to numerous septic emboli in the lungs.
- Subacute endocarditis causes low-grade fever and constitutional symptoms. The diagnosis may be difficult and easily overlooked.

## Macroscopy

- The involved endocardial surface is covered with friable vegetations.
- Acute cases may show extensive underlying tissue destruction and abscess formation.

## Histopathology

- Vegetations are composed of a mixture of fibrin, inflammatory cells, and bacterial colonies which, in almost all cases, are Gram-positive cocci.

## Prognosis

- Acute endocarditis has a high mortality due to rapid valve destruction and the development of acute cardiac failure.
- Subacute endocarditis has a more protracted course, but remains a serious disease if undiagnosed and untreated.

## Myocarditis

### Definition

- Inflammation of the myocardium unrelated to ischaemia.

### Epidemiology

- Rare.

### Aetiology

- Most cases are infective in origin.
- Drugs and toxins have also been implicated.
- Some cases are idiopathic.

### Microbiology

- Coxsackie virus is the most commonly implicated organism.
- Other organisms include HIV, *Clostridia*, meningococcus, *Mycoplasma*, *Borrelia*, leptospirosis, and Chagas disease.

### Pathogenesis

- Myocyte injury causes a variable degree of necrosis and inflammation.

### Presentation

- Depends on the extent of myocardial necrosis.
- Mild cases may cause a flu-like illness without obvious localizing symptoms to the heart and go undiagnosed.
- More severe cases cause breathlessness, chest pain, and palpitations.
- Very severe cases present as a medical emergency with acute cardiac failure and cardiogenic shock, mimicking a massive acute myocardial infarction.

### Macroscopy

- Macroscopic changes vary widely, depending on severity.
- Importantly, many cases of myocarditis produce no gross pathology and the heart appears macroscopically normal.
- Very severe cases of myocarditis producing extensive necrosis may give a macroscopic abnormality similar to myocardial infarction.

### Histopathology

- All forms of myocarditis show an inflammatory cell infiltrate together with myocardial necrosis or degeneration.
- The infiltrate is usually a mixture of lymphocytes and histiocytes.
- Some cases show an eosinophil-rich infiltrate (hypersensitivity myocarditis) or contain giant cells (giant cell myocarditis).

### Prognosis

- In most cases, recovery is complete without complications.
- Giant cell myocarditis runs a fulminant course with an almost inevitable development of cardiac failure and high mortality.

# Pericarditis

## Definition

- Inflammation of the pericardium.

## Epidemiology

- Uncommon.

## Aetiology

- Infections are a common cause and these may be viral (coxsackie, EBV, HIV), bacterial (extension from a pneumonia, acute rheumatic fever, tuberculosis), or fungal.
- Full thickness acute myocardial infarction causes pericarditis overlying the infarct.
- Other miscellaneous causes include severe renal failure ('uraemic' pericarditis), hypothyroidism, multisystem autoimmune diseases (e.g. rheumatoid arthritis, systemic lupus erythematosus), cardiac surgery, radiotherapy, malignant infiltration, and some drugs.

## Pathogenesis

- Injury to the pericardium causes an inflammatory response.

## Presentation

- Central chest pain which is worse on inspiration or lying flat and relieved by sitting forward.
- A superimposed large pericardial effusion may cause breathlessness.

## Macroscopy

- The pericardial surface of the heart is roughened due to the presence of an inflammatory exudate.
- Strands of fibrinous material may be present between the two pericardial surfaces.
- The exudate may be purulent if associated with bacterial infection.
- An associated pericardial effusion may be present.

## Histopathology

- The pericardium is infiltrated by inflammatory cells, often with fibrin deposition.
- Malignant cells may be seen in cases due to malignant infiltration.

## Prognosis

- Infective pericarditis often resolves with appropriate treatment.
- Pericarditis associated with an acute myocardial infarction is governed by the outcome of the infarction.
- Uraemic pericarditis implies severe renal failure with attendant risk of mortality.
- Malignant pericarditis usually implies significant metastatic disease and poor prognosis.
- Any cause of pericarditis may lead to a reactive pericardial effusion which, if large, requires urgent drainage to prevent cardiac tamponade.



*This page intentionally left blank*

# Respiratory pathology

- Respiratory tract malformations 58
- Benign sinonasal diseases 59
- Sinonasal malignancies 60
- Nasopharyngeal diseases 61
- Laryngeal diseases 62
- Respiratory failure 63
- Acute respiratory distress syndrome 64
- Bronchiectasis 65
- Cystic fibrosis 66
- Pulmonary thromboembolism 67
- Pulmonary hypertension 68
- Asthma 69
- Chronic obstructive pulmonary disease 70
- Bacterial pneumonia 72
- Idiopathic pulmonary fibrosis 74
- Hypersensitivity pneumonitis 76
- Lung carcinoma 78
- Pleural effusion 80
- Pneumothorax 81
- Malignant mesothelioma 82

## Respiratory tract malformations

### **Congenital diaphragmatic hernia**

- A defect in the diaphragm caused by failure of the pleuroperitoneal canals to close during 8–10 weeks of gestation.
- Bowel loops and the liver can pass into the thorax and compress the developing lung, causing lung hypoplasia.
- Infants usually present with respiratory failure and 50% die within 24h of birth.

### **Congenital (cystic) adenomatoid malformation**

- A lung mass composed of terminal bronchioles. There are no normal alveoli.
- Usually, a single lobe is involved.
- Many cases diagnosed by antenatal ultrasound at 20 weeks gestation.
- Most cause a degree of respiratory distress and so are surgically removed.

### **Pulmonary sequestration**

- A discrete mass of lung tissue that has no normal connection with the respiratory tract.
- Sequestrations have a systemic blood supply.
- Most are intrapulmonary and found in the left lower lobe.
- Up to half of extrapulmonary sequestrations may be associated with other anomalies.
- Pulmonary sequestrations may become infected or cause massive haemoptysis.

### **Laryngomalacia**

- Relatively common condition in which the epiglottis and arytenoid cartilages collapse during inspiration.
- Affected neonates present with inspiratory stridor in the first few weeks of life.
- The stridor may worsen until about 6 months of age and then gradually improves.
- Most children are symptom-free by 24 months.

## Benign sinonasal diseases

### Sinonasal polyps

- Benign polypoid lesions of the sinonasal tract.
- Usually related to repeated episodes of inflammation from infection or allergic rhinitis.
- Occur predominantly in adults. Presence in children should raise the possibility of cystic fibrosis.
- Present with nasal obstruction.
- Histologically, the polyps comprise an oedematous inflamed stromal core covered by sinonasal-type epithelium.

### Schneiderian papillomas

- A group of benign papillary lesions arising from the sinonasal epithelium.
- Exophytic type arises from the nasal septum and is composed of papillary fronds covered by bland squamous epithelium.
- Endophytic (inverted) type arises from the lateral nasal wall and is composed of inverted lobules of transitional/squamous epithelium with many intraepithelial microcysts.
- Oncocytic (cylindrical) type arises from the lateral nasal wall and is composed of an exophytic and endophytic proliferation of columnar oncocytic epithelium with many intraepithelial microcysts.
- All types have a risk of local recurrence if incompletely removed. The recurrence risk is highest with the inverted type.

### Allergic fungal sinusitis

- Allergic reaction to ubiquitous fungal antigens.
- Presents with nasal itching and discharge.
- Severe cases can give rise to a large destructive inflammatory mass.
- Histology shows a layered arrangement of mucoid material with abundant eosinophils and eosinophilic cellular debris. Fungal hyphae can be highlighted within the material with special stains.

## Sinonasal malignancies

### Sinonasal squamous cell carcinoma

- Most common malignant neoplasm of the sinonasal tract.
- Arise in elderly adults with symptoms of a mass lesion.
- Most common sites are the maxillary sinus, lateral nasal wall, and nasal septum.
- Nasal tumours tend to be keratinizing and well differentiated.
- Sinus tumours tend to be non-keratinizing and less well differentiated.
- Prognosis for nasal cavity-confined tumours is good (80% 5-year survival). Prognosis for sinus tumours is less favourable.

### Sinonasal adenocarcinomas

- Second most common malignant neoplasm of sinonasal tract.
- Salivary-type adenocarcinomas have equal gender incidence and mostly arise in the maxillary sinuses. The most common histological type is adenoid cystic carcinoma.
- Intestinal type adenocarcinoma shows a marked male predilection and usually arises in the ethmoid sinus and nasal cavity. There is a well-recognized association with occupational exposure, particularly in wood workers.
- Non-intestinal type adenocarcinomas tend to involve the ethmoid sinus and maxillary sinus.

### Sinonasal undifferentiated carcinoma

- A rare, but highly aggressive, malignancy arising in the sinonasal tract.
- Presents with a large mass with bone destruction.
- Histology shows sheets of undifferentiated cells with high mitotic activity and necrosis.
- Prognosis is poor with 5-year survival rate of 20%.

### Olfactory neuroblastoma

- Rare sinonasal malignancy arising from the olfactory epithelium.
- Bimodal age of onset at 10–20y and 50–60y.
- Presents with nasal obstruction, anosmia, and headaches.
- Histology shows lobules of closely packed small round blue cells which may form pseudorosettes or true rosettes.

### Malignant melanoma

- Very rare sinonasal malignancy which presents with symptoms of nasal obstruction, discharge, and pain.
- Histology shows malignant melanocytes which can grow in a multitude of different patterns.
- Prognosis is generally poor.

## Nasopharyngeal diseases

### Nasopharyngeal angiofibroma

- Rare benign soft tissue tumour which arises exclusively in the nasopharynx of young males (peak age of onset 15y).
- Histology shows a highly vascular neoplasm in which variably sized vessels are surrounded by a cellular fibroblastic stroma. The lesion is covered by an intact sinonasal epithelium.
- Local recurrence occurs in ~20% of cases following surgery.

### Nasopharyngeal carcinoma

- A malignant epithelial neoplasm arising in the nasopharynx.
- Presents in adults with nasal obstruction, hearing loss, and tinnitus.
- Marked geographical variation in incidence, being particularly common in southern China, Thailand, and the Philippines.
- Strong association with EBV and diet.
- Histology recognizes three subtypes: non-keratinizing, keratinizing, and basaloid.
- Most cases are treated with radical radiotherapy.
- 5-year survival rate ~60%.

## Laryngeal diseases

### Vocal cord nodules

- Benign growths of the laryngeal mucosa.
- Nodules are seen mostly in young women associated with vocal abuse.
- Present with vocal changes.
- Small lesions arising in the middle third of both vocal cords.
- Histology shows a nodule with an oedematous stroma which then becomes fibrotic.

### Vocal cord polyp

- Benign growth of the laryngeal mucosa.
- Occurs at any age and with equal gender incidence.
- Presents with vocal changes.
- Involves the ventricular space or Reinke's space of one vocal cord.
- Histology shows a polyp with a stroma that may be variably oedematous, myxoid, hyaline, or fibrous.

### Laryngeal amyloidosis

- A localized form of amyloidosis.
- Usually arises in false vocal cord.
- Presents with vocal changes.
- Histology shows a deposition of amorphous eosinophilic material beneath the epithelium. Amyloid stains with Congo Red and demonstrates chromatic changes under polarized light.
- The amyloid is usually derived from light chain immunoglobulins.

### Squamous papillomas

- Most common benign laryngeal neoplasms.
- Associated with human papillomavirus (HPV) types 6 and 11.
- Bimodal age of incidence <5y and 20–40y.
- Present with vocal changes.
- Histology shows branching exophytic papillary fronds covered by bland squamous epithelium.
- Children tend to develop a more aggressive disease with early recurrences and higher chance of spread beyond the larynx.
- Adults tend to show a more favourable course with less frequent recurrences.

### Squamous cell carcinoma

- Most common malignant neoplasm of the larynx.
- Occurs in older adults with a predilection for men.
- Association with tobacco and alcohol abuse.
- Presents with vocal changes.
- Histology shows infiltrating nests of malignant epithelial cells showing squamous differentiation.
- Prognosis is dependent of the stage of the tumour at presentation.

# Respiratory failure

## Definition

- Arterial  $pO_2 < 8kPa$ .

## Subtypes

- Type 1 is associated with a normal or low  $pCO_2$ .
- Type 2 is associated with a raised  $pCO_2$ .

## Aetiology

- Type 1: severe pneumonia, pulmonary embolism, acute asthma, pulmonary fibrosis, acute left ventricular failure.
- Type 2: chronic obstructive pulmonary disease (COPD), neuromuscular disorders impairing ventilation.

## Pathogenesis

- Type 1 respiratory failure is a result of ventilation/perfusion mismatching in areas of the lungs. Increased ventilation removes any excess carbon dioxide, but cannot compensate for the low  $pO_2$ .
- Type 2 respiratory failure is a result of a generalized alveolar hypoventilation. Transfer of both oxygen and carbon dioxide is impaired so  $pCO_2$  is raised in addition to the low  $pO_2$ .

## Presentation

- Acute respiratory failure typically develops suddenly in a patient with otherwise healthy lungs. There is obvious respiratory distress with hyperventilation.
- Chronic respiratory failure is a more persistent problem in patients with chronic lung diseases. By contrast, the clinical picture may be surprisingly undramatic despite the low  $pO_2$  levels due to compensatory mechanisms.

## Complications

- Prolonged chronic hypoxia causes pulmonary hypertension and ultimately right ventricular failure.



## Acute respiratory distress syndrome

### Definition

- A very severe form of acute lung injury defined as a ratio of  $\text{PaO}_2:\text{FiO}_2 < 200\text{mmHg}$  in the presence of bilateral alveolar infiltrates on chest X-ray and in the absence of left ventricular failure.

### Epidemiology

- Uncommon.

### Aetiology

- Any severe injury to the lung may lead to acute respiratory distress syndrome (ARDS).
- Common causes include severe pneumonia, shock, trauma, multiple transfusions, and near drowning.

### Pathogenesis

- Severe damage to the lung causes widespread alveolar necrosis with severe impairment of normal gas exchange.

### Presentation

- Severe breathlessness in addition to signs of the underlying cause.

### Macroscopy

- Both lungs are typically markedly heavy and fluid-filled, often weighing  $>1000\text{g}$  each (a normal lung weighs  $\sim 300\text{--}400\text{g}$ ).

### Histopathology

- The histopathological hallmark is **diffuse alveolar damage** characterized by the presence of hyaline membranes lining alveolar spaces.
- Hyaline membranes are composed of a mixture of fibrin and necrotic alveolar epithelial cells.

### Prognosis

- Severe condition with high mortality rates averaging between 30–50%, depending on the cause.
- Survivors usually demonstrate residual pulmonary functional abnormalities.

# Bronchiectasis

## Definition

- An abnormal permanent dilation of bronchi accompanied by inflammation in their walls and in adjacent lung parenchyma.

## Epidemiology

- Uncommon in developed countries.
- Remains a cause of significant morbidity in less developed countries.

## Aetiology

- A structural condition resulting from a number of different causes.
- In developed countries, bronchiectasis is usually related to obstruction to an area of lung (e.g. tumour or foreign body) or in association with cystic fibrosis. Many cases prove to be idiopathic.
- In less developed countries, severe pulmonary infections are a major cause.

## Pathogenesis

- Thought to be the result of weakening in bronchial walls caused by recurrent inflammation.
- Scarring in the adjacent lung parenchyma places traction on the weakened bronchi, causing them to permanently dilate.

## Presentation

- Persistent productive cough and haemoptysis (which may be massive).

## Macroscopy

- Affected areas of the lung contain visibly dilated airways filled with mucopurulent material which extend right up to the pleural surface.
- In obstructive cases, the cause may be seen proximally, e.g. a tumour.

## Histopathology

- Bronchial dilation with marked chronic inflammation in the wall, often with lymphoid aggregates and germinal centres.
- Adjacent alveoli may show an acute and organizing pneumonia.

## Complications

- Pulmonary hypertension and right ventricular failure.
- Deposition of serum amyloid A protein in  $\beta$ -pleated sheets in multiple organs (AA amyloidosis).

## Cystic fibrosis

### Definition

- An inherited disorder caused by a mutation in the **cystic fibrosis transmembrane conductance regulator** (CFTR) gene.

### Epidemiology

- The most common lethal genetic disease in European populations.
- ~1 in 2,500 babies born in the United Kingdom (UK) have cystic fibrosis (CF).

### Genetics

- Inherited in an autosomal recessive manner.
- CFTR gene is on chromosome 7q and codes for a chloride ion channel.
- Over 1,400 mutations have been described, though the most common is a deletion at position 508 that leads to loss of a phenylalanine amino acid (the  $\Delta F508$  mutation).

### Pathogenesis

- The  $\Delta F508$  mutation causes abnormal folding of the CFTR protein and its subsequent degradation in the cell.
- Other mutations may result in a correctly located protein, but abnormal function.
- Lack of normal CFTR causes a defective electrolyte transfer across epithelial cell membranes, resulting in thick mucus secretions.

### Presentation

- Most patients present with pulmonary disease due to recurrent infections. Initially, common bacteria colonize the lungs, but eventually *Pseudomonas aeruginosa* often becomes the dominant organism.
- Pancreatic insufficiency is also common.
- Bowel obstruction may occur in the neonatal period due to thick meconium (meconium ileus) or develop later in childhood.
- Liver disease develops late.
- Some cases may be diagnosed when a raised serum immunoreactive trypsin is picked up on neonatal screening.

### Macroscopy

- Lungs from older children usually show widespread bronchiectasis.
- The liver may appear fatty and, in severe cases, may be cirrhotic.

### Histopathology

- The lungs show bronchiectatic airways containing thick mucus. Acute inflammation may be seen if there is active infection.
- The liver shows inspissated bile in intrahepatic bile ducts. There may be periportal fibrosis which, in more severe cases, progresses to cirrhosis.

### Prognosis

- Average lifespan is currently ~35y.
- Most patients die as a result of pulmonary disease.

# Pulmonary thromboembolism

## Definition

- Occlusion of a pulmonary artery by embolic thrombus.

## Epidemiology

- Very common and often underdiagnosed.

## Aetiology

- As pulmonary emboli originate from deep vein thromboses, the risk factors are the same as for that condition i.e. immobility, acute medical illness, recent surgery, malignancy, pregnancy, congenital and acquired thrombotic disorders.

## Pathogenesis

- A fragment of detached thrombus from a deep vein thrombosis embolizes via the right side of the heart into the pulmonary arterial circulation and lodges in a pulmonary artery.

## Presentation

- Clinical presentation depends on the size of the pulmonary artery blocked by the embolus.
- Blockage of a major pulmonary artery usually leads to instant death due to a sudden huge rise in pulmonary arterial pressure, acute right ventricular failure, and cardiac arrest.
- Blockage of medium-sized arteries causes an area of ventilation-perfusion mismatch in the lungs with breathlessness.
- Smaller pulmonary emboli may lead to subtle symptoms of breathlessness, chest pain, and dizziness; these can easily go undiagnosed.

## Macroscopy

- Emboli are visible as fragments of thrombi within pulmonary arteries.
- Thrombi are firm and brown and the cut surface may show visible bands (lines of Zahn).

## Histopathology

- Fresh thromboemboli are composed of a mixture of fibrin and enmeshed blood cells, often arranged in alternating linear bands that correspond to the macroscopic lines of Zahn.
- Thromboemboli organize after 2–3 days with ingrowth of granulation tissue composed of fibroblasts and capillaries from the vessel wall.
- Old thromboemboli may be evident as fibrous nodules projecting from the vessel wall or fibrous bands crossing the lumen of a pulmonary artery.

## Prognosis

- ~30% of all patients die from pulmonary embolism.
- The risk of death is much higher if the diagnosis is not initially made.

## Pulmonary hypertension

### Definition

- A mean pulmonary artery pressure  $>25\text{mmHg}$  at rest or  $>30\text{mmHg}$  during exercise.

### Subtypes

- Secondary pulmonary hypertension is a complication of chronic lung or cardiac disease.
- Primary pulmonary hypertension occurs in the absence of chronic lung or heart disease.

### Epidemiology

- Secondary pulmonary hypertension is quite common.
- Primary pulmonary hypertension is rare.

### Aetiology

- Common causes of secondary hypertension include COPD, interstitial lung disease, left ventricular failure, and chronic pulmonary thromboemboli.
- Primary pulmonary hypertension may be idiopathic or associated with certain drugs, HIV infection, collagen vascular disease, and congenital systemic-to-pulmonary shunts.

### Pathogenesis

- Chronic hypoxia and obliterative pulmonary fibrosis both lead to the development of raised pressure in the pulmonary arterial circulation.

### Presentation

- Secondary pulmonary hypertension causes worsening of the symptoms of the pre-existing condition with increasing breathlessness.
- Primary pulmonary hypertension presents with exertional dyspnoea and fatigue. Dizziness and syncope are also common.

### Macroscopy

- The presence of atherosclerosis in large pulmonary arteries is a clue to underlying pulmonary hypertension.
- Right ventricular hypertrophy may also be present.

### Histopathology

- All cases show muscular hypertrophy and intimal proliferation of small pulmonary arteries and muscularization of pulmonary arterioles.
- Severe cases show plexiform lesions, characterized by a proliferation of slit-like vascular spaces from the arterial wall.
- Very severe cases may display fibrinoid necrosis of the arterial wall.

### Prognosis

- Secondary pulmonary hypertension generally implies significant underlying cardiac or lung disease with poor prognosis.
- Prognosis of primary pulmonary hypertension is also very poor with 5-year survival rates of only 25–50%.

# Asthma

## Definition

- A chronic inflammatory disorder of large airways characterized by recurrent episodes of reversible airway narrowing.

## Epidemiology

- Very common, affecting >10% of children and 5% of adults.

## Aetiology

- Most cases are associated with **atopy**, a genetic tendency of the immune system to produce IgE in response to common environmental allergens.
- The aetiology of non-atopic asthma is uncertain, but some have suggested a link with gastro-oesophageal reflux disease.

## Pathogenesis

- Atopic individuals respond to common environment allergens by producing large amounts of allergen-specific IgE which bind to the surface of mast cells.
- Re-exposure to the allergen causes cross-linking of allergen-specific IgE antibodies and degranulation of mast cells.
- Degranulated mast cells stimulate airway inflammation and bronchospasm.
- Ongoing inflammation results in hypersensitive airways which react to a number of stimuli, including exercise, cold air, and cigarette smoke.

## Presentation

- Intermittent episodes of breathlessness, wheeze, and chest tightness.
- Cough, particularly at night, is also common.

## Macroscopy

- Lungs of most asthmatics may be macroscopically normal.
- Thick mucus plugs in airways may be seen in severe disease.

## Histopathology

- Airways show evidence of inflammatory activity with eosinophils which are not usually seen in normal airways.
- There may also be basement membrane thickening, goblet cell hyperplasia, and prominent smooth muscle.

## Prognosis

- Generally good with appropriate treatment.
- There is a small mortality rate associated with severe acute asthma.

## Chronic obstructive pulmonary disease

### Definition

- A chronic lung condition characterized by breathlessness due to poorly reversible and progressive airflow obstruction.

### Epidemiology

- Very common.
- Mostly a disease of middle-aged to elderly adult smokers.

### Aetiology

- Almost all cases are caused by smoking.
- Cases in younger individuals may be due to  $\alpha$ -1-antitrypsin deficiency.

### Pathogenesis

- Inflammation and scarring of small bronchioles is thought to be the main source of airflow obstruction.
- Imbalance of proteases and antiproteases causes destruction of lung parenchyma with dilation of terminal airspaces (emphysema) and air trapping.
- Mucous gland hyperplasia and irritant effects of smoke causes productive cough (chronic bronchitis).

### Presentation

- Sudden onset of exertional breathlessness on a background of prolonged cough and sputum production.
- Spirometry typically shows a low FEV1 and low FEV1/FVC ratio (Fig. 5.1).

### Macroscopy

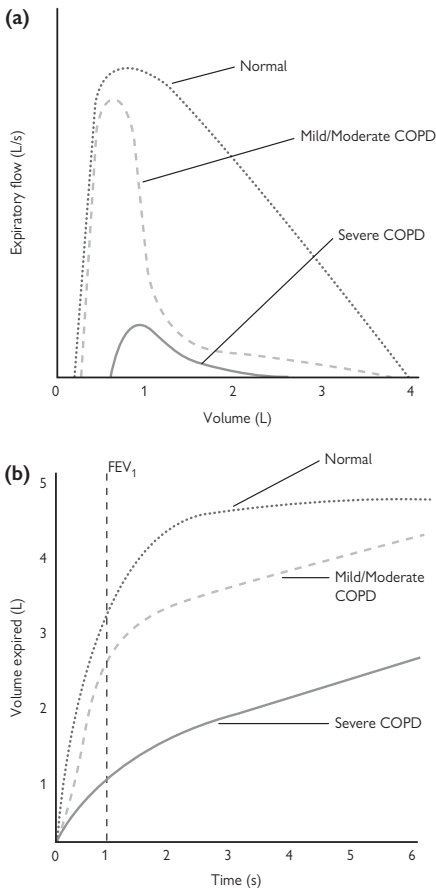
- The lungs are hyperinflated with thick mucus in the airways and dilated terminal airspaces.
- Bullae may be present.

### Histopathology

- Chronic inflammation and fibrosis of small bronchioles (chronic obstructive bronchiolitis).
- Finely pigmented macrophages in respiratory bronchioles (respiratory bronchiolitis).
- Dilated terminal airspaces (emphysema).
- Larger airways may show mucus gland hyperplasia.

### Prognosis

- Gradual decline in lung function with episodes of acute exacerbation due to infection, pneumothorax, or pulmonary embolism.
- Pulmonary hypertension and right ventricular failure then occur.
- Left ventricular failure often coexists due to ischaemic heart disease.
- Death often related to a combination of respiratory and cardiac failure.



**Fig. 5.1** (a) Flow–volume loops in a normal individual compared with patients with COPD. In mild-to-moderate COPD, the immediate flow is relatively normal (this is why peak flow can be normal in patients with early COPD), but then the airflow rapidly decreases. In severe COPD, the airflow is very poor with prominent air trapping (note how at the start of expiration, there is already nearly 1L of air in the lungs). (b) Spirometry in a normal individual compared with patients with COPD. Note how in COPD, the forced expiratory volume in 1s (FEV<sub>1</sub>) is reduced, but the final volume expired is relatively normal (they just take longer to get there!), hence the FEV<sub>1</sub> to FVC ratio is lowered.

Reproduced with permission from *Clinical Pathology*, Carton, Daly, and Ramani, Oxford University Press, p. 115, Figure 7.7.



## Bacterial pneumonia

### Definition

- An infection of the lung parenchyma caused by bacterial organisms.

### Classification

- Community-acquired.
- Hospital-acquired.
- Aspiration.
- Immunosuppression.

### Epidemiology

- Very common.

### Microbiology

- Community-acquired: *Streptococcus pneumoniae*, *Mycoplasma pneumoniae*, *Haemophilus influenzae*, *Legionella pneumophila*.
  - Hospital-acquired: Gram-negative bacteria, e.g. *Klebsiella*, *Escherichia coli*, *Pseudomonas*.
  - Aspiration: mixed aerobic and anaerobic bacteria.
  - Immunosuppression: all the previously mentioned possible (as well as viral, mycobacterial, and *Pneumocystis*).
- ▶ Multiple coexisting infections are common in the immunosuppressed.

### Pathogenesis

- Bacterial organisms overcome the defenses of the lung and establish infection within alveoli.

### Presentation

- Productive cough, breathlessness, chest pain, and fever.

### Macroscopy

- The infected lung parenchyma feels firm and appears yellowish.
- Purulent material may be expressed from small airways.
- The overlying pleura may show evidence of pleuritis.

### Histopathology

- The alveolar spaces are filled with an inflammatory infiltrate rich in neutrophils. Bacterial colonies are often visible within the exudate.
- In cases of aspiration pneumonia, food material may be present within the lung parenchyma.
- Severe cases complicated by abscess formation show destruction of the lung tissue and replacement by confluent sheets of neutrophils.

### Prognosis

- Recovery is usually expected with appropriate antimicrobial therapy in an otherwise healthy individual.
- Complications include respiratory failure, septicaemia, pleural effusion, empyema, and lung abscess. These are more likely with virulent organisms or in patients with coexisting heart and lung disease.

*This page intentionally left blank*

## Idiopathic pulmonary fibrosis

### Definition

- An idiopathic interstitial pneumonia limited to the lung and associated with a histological appearance of usual interstitial pneumonia.

### Epidemiology

- The majority of patients are between 50–70y.
- Men are affected about twice as often as women.

### Aetiology

- Unknown.

### Pathogenesis

- Thought to be due to repeated episodes of focal damage to alveolar epithelium.
- Injured alveolar epithelial cells express profibrotic cytokines such as transforming growth factor- $\beta$  (TGF- $\beta$ ) and interleukin-10 (IL-10) which stimulate irreversible lung scarring (Fig. 5.2).

### Presentation

- Progressive breathlessness and non-productive cough.

### Macroscopy

- Marked lung fibrosis with honeycomb change.
- Disease most marked at the peripheries of the lower lobes.

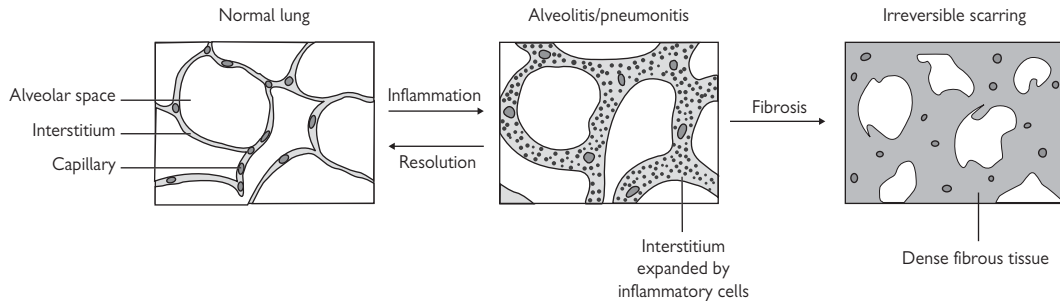
### Histopathology

- Heterogeneous non-uniform fibrotic process characterized by markedly scarred areas of lung juxtaposed to islands of relatively normal lung ('spatial variability').
- Evidence of ongoing active ongoing fibrosis in the form of numerous fibroblastic foci ('temporal variability').

► This histopathological picture, known as **usual interstitial pneumonia** (UIP), is always seen in idiopathic pulmonary fibrosis (IPF), but is not specific for it.

### Prognosis

- Very poor with average survival only 2–3y from diagnosis.
- A common terminal event is an acute exacerbation of IPF, characterized histologically by diffuse alveolar damage on a background of the UIP pattern.



**Fig. 5.2** Evolution of diffuse parenchymal lung disease (DPLD). The normal interstitium is thin and contains pulmonary artery capillaries. In DPLD, the interstitium becomes expanded by an inflammatory cell infiltrate ('pneumonitis' or 'alveolitis'), impairing gas exchange. Complete resolution can occur, but the danger is the development of fibrosis which permanently destroys the lung parenchyma.

Reproduced with permission from *Clinical Pathology*, Carton, Daly, and Ramani, Oxford University Press, p. 126, Figure 7.10.

## Hypersensitivity pneumonitis

### Definition

- An interstitial lung disease caused by an immunologic reaction to inhaled antigens.

### Synonyms

- Extrinsic allergic alveolitis.
- Individual forms of the disease are also known by many other names (farmer's lung, humidifier lung, maple bark stripper's lung, mushroom worker's lung, pigeon breeder's lung, bird fancier's lung, etc.)

### Epidemiology

- Uncommon.

### Aetiology

- Thermophilic bacteria (moldy hay, compost, air conditioner ducts),
- Fungi (mouldy maple bark, barley, or wood dust).
- Avian proteins (bird droppings and feathers).

### Pathogenesis

- Inhaled antigens lead to an abnormal immune reaction in the lungs.
- Involves a combination of antibody (type 2), immune complex (type 3), and cell-mediated (type 4) hypersensitivity reactions (📖 p. 10).

### Presentation

- Acute disease follows exposure to large amounts of antigen and causes severe breathlessness, cough, and fever 4–6h after exposure. Resolution occurs within 12–18h after exposure ceases.
- Chronic disease results from prolonged exposure to small amounts of antigen with gradual onset of breathlessness, dry cough, and fatigue.

### Radiology

- High-resolution computed tomography (CT) shows middle to upper lobe predominant linear interstitial opacities and small nodules.
- Often associated with traction bronchiectasis and honeycomb areas.

### Histopathology

- Cellular chronic interstitial pneumonia with peribronchiolar accentuation.
- Foci of organizing pneumonia and poorly formed granulomas may also be present.

### Prognosis

- Generally good if the causative antigen is identified and exposure is avoided.
- Persistent exposure can lead to irreversible lung fibrosis and respiratory failure.

*This page intentionally left blank*

## Lung carcinoma

### Definition

- A malignant epithelial tumour arising in the lung.

### Epidemiology

- The most common and deadly cancer with >1 million deaths annually.

### Aetiology

- Up to 90% of cases are directly attributable to smoking.

### Carcinogenesis

- TP53 mutations are common in all types of lung carcinoma.
- HER2 and KRAS overexpression in adenocarcinomas.
- EGFR overexpression and 3p loss in squamous cell carcinomas.
- Inactivation of RB is almost universal in small cell carcinomas.

### Presentation

- Symptoms related to local growth of the tumour include progressive breathlessness, cough, chest pain, hoarseness or loss of voice, haemoptysis, weight loss, and recurrent pneumonia.
- Abdominal pain, bony pain, and neurological symptoms may occur from metastases.
- A small proportion of small cell carcinomas present with paraneoplastic syndromes or the superior vena cava syndrome.

### Macroscopy

- A firm white/grey tumour mass within the lung.
- Yellow consolidation may be seen in the lung parenchyma distal to large proximal tumours due to an obstructive pneumonia.
- Pleural puckering may be seen overlying peripheral tumours that have infiltrated the pleura.
- Metastatic tumour deposits may be seen in hilar lymph nodes.

### Histopathology

- **Adenocarcinoma** is a malignant epithelial tumour showing glandular differentiation and/or mucin production.
- **Squamous cell carcinoma** is a malignant epithelial tumour showing keratinization and/or intercellular bridges.
- **Small cell carcinoma** is a malignant epithelial tumour consisting of small cells with scanty cytoplasm, ill-defined cell borders, finely granular chromatin, and absent nucleoli. The mitotic count is high and necrosis is often extensive.
- **Large cell carcinoma** is an undifferentiated (non-small) cell carcinoma that lacks any evidence of either squamous or glandular differentiation.

### Prognosis

- Poor with 5-year survival rates of ~10% in most countries.

**TNM 7 pathological staging of lung carcinomas****Primary tumour (T)**

T1a: tumour  $\leq 2$ cm in size, confined to the lung.

T1b: tumour  $>2$ – $3$ cm in size, confined to the lung.

T2: tumour  $3$ – $7$ cm in size; tumour of any size that involves the main bronchus  $2$ cm or more distal to the carina, invades visceral pleura, causes partial atelectasis.

T3: tumour  $>7$ cm in size; tumour of any size that invades the chest wall, diaphragm, pericardium, mediastinal pleura, main bronchus  $<2$ cm distal to the carina, causes total atelectasis; multiple tumour nodules in same lobe.

T4: tumour of any size that invades the mediastinum, heart, great vessels, carina, trachea, oesophagus, vertebra; multiple tumour nodules in same lung, but different lobes.

**Regional lymph nodes (N)**

N0: no regional lymph node metastasis.

N1: metastasis in ipsilateral peribronchial or hilar lymph nodes.

N2: metastasis in ipsilateral mediastinal or subcarinal lymph nodes.

N3: metastasis in contralateral mediastinal or hilar lymph nodes or any scalene or supraclavicular lymph nodes.



## Pleural effusion

### Definition

- An accumulation of excess fluid within the pleural space.

### Epidemiology

- Common.

### Aetiology

- Left ventricular failure.
- Pneumonia.
- Pulmonary embolism.
- Malignancy.
- Multisystem autoimmune diseases (e.g. lupus, rheumatoid arthritis).

### Pathogenesis

- Increased pulmonary venous congestion (left ventricular failure), inflammation of the pleura (pneumonia, pulmonary embolism, autoimmune disease), infiltration of the pleura (malignancy).

### Presentation

- Small effusions may be asymptomatic (but may be visible on imaging).
- Large effusions cause breathlessness.

### Macroscopy

- Fluid is seen within the pleural space.
- Fluid may be straw-coloured, haemorrhagic, or purulent.

### Cytopathology

- Cytological examination of pleural fluid in benign conditions shows mesothelial cells and variable numbers of inflammatory cells, depending on the cause.
- Pleural fluid due to malignancy may contain malignant cells with enlarged pleomorphic nuclei.

### Prognosis

- Parapneumonic effusions and those due to pulmonary emboli resolve upon treatment.
- Pleural effusion due to left ventricular failure usually implies advanced disease and poor prognosis.
- Pleural effusion due to malignancy is invariably due to metastatic disease and so has a very poor prognosis.

# Pneumothorax

## Definition

- The presence of air in the pleural space.

## Epidemiology

- Common.
- Men are affected more than women.

## Aetiology

- Spontaneous pneumothorax typically occurs in thin tall young men. It is thought to be due to the rupture of small delicate apical blebs of lung tissue which result from stretching of the lungs.
- Underlying lung disease, e.g. COPD, asthma, pneumonia, tuberculosis, cystic fibrosis, sarcoidosis, lung carcinoma, IPF. Rare conditions often associated with pneumothorax include pulmonary Langerhans cell histiocytosis, pulmonary lymphangioleiomyomatosis, and thoracic endometriosis.
- Trauma, e.g. penetrating chest wound, rib fractures.
- Iatrogenic, e.g. subclavian vein cannulation, lung biopsy.

## Pathogenesis

- Air leaks out of the damaged lung into the pleural space until the pressures equalize.
- The lung collapses to a variable degree, depending on the size of the pneumothorax.
- Rarely, the tissues near the lung defect act as a one-way valve, preventing the equalization of pressure. The continuous build-up of pressure and volume in the pleural space displaces mediastinal structures, causing cardiorespiratory arrest (**tension pneumothorax**).

## Presentation

- Sudden onset of unilateral pleuritic chest pain.
- There may be breathlessness, depending on the size of the pneumothorax. Patients with an underlying lung disease will usually notice a worsening in their symptoms.

## Radiology

- Air is present within the pleural space together with varying amounts of lung collapse.

## Histopathology

- Apical lung tissue excised from patients with spontaneous pneumothoraces shows one or more bullae associated with subpleural alveolar collapse and fibrosis.
- The overlying visceral pleura shows reactive mesothelial hyperplasia and inflammation which is often rich in eosinophils.

## Prognosis

- About one third of patients with spontaneous pneumothorax suffer recurrent episodes, usually on the same side.

## Malignant mesothelioma

### Definition

- A malignant tumour arising in the pleura from mesothelial cells and showing a diffuse pattern of growth over the pleural surfaces.

### Epidemiology

- Most cases are seen in males >60y.
- Incidence still rising due to the long latency period between asbestos exposure and development of the tumour.
- Incidence is expected to peak between 2015–2020.

### Aetiology

- >90% of cases are directly attributable to asbestos exposure.
- Amphibole asbestos is the most potent type, followed by chrysotile, and then amosite.
- Other possible causes include non-asbestos mineral fibres and therapeutic radiation.

### Pathogenesis

- Inhaled asbestos fibres become permanently entrapped in the lung.
- Most do not cause a tissue reaction and these are probably the ones responsible for the carcinogenic effects.
- A minority become coated with iron, forming asbestos bodies.

### Presentation

- Breathlessness, often due to a large unilateral pleural effusion, and chest pain.
- Weight loss and malaise is often profound.

### Macroscopy

- Initially, multiple small nodules are seen studding the parietal pleura.
- As the tumour grows, the nodules become confluent and form a tumour mass that encases the entire lung and fuses to the chest wall.

### Cytopathology

- Epithelioid mesotheliomas are the most likely to shed into pleural fluid where malignant cells are seen forming sheets, clusters, and papillae.

### Histopathology

- **Epithelioid mesothelioma** is composed of round cells, forming tubules and papillae.
- **Sarcomatoid mesothelioma** is composed of elongated spindled malignant cells.
- **Biphasic mesothelioma** contains a mixture of epithelioid and sarcomatoid types.
- **Desmoplastic mesothelioma** is a variant composed of small numbers of malignant cells set in very dense collagenous tissue.

### Prognosis

- Very poor.

# Gastrointestinal pathology

- Gastrointestinal malformations 84
- Oral cavity diseases 86
- Salivary gland diseases 87
- Oesophagitis 88
- Oesophageal polyps and nodules 89
- Oesophageal carcinoma 90
- Gastritis 92
- Gastric polyps 93
- Gastric carcinoma 94
- Gastrointestinal stromal tumours 96
- Peptic duodenitis 97
- Coeliac disease 98
- Small bowel infarction 99
- Intestinal infections 100
- Intestinal obstruction 102
- Acute appendicitis 103
- Crohn's disease 104
- Ulcerative colitis 105
- Microscopic colitis 106
- Colorectal polyps 108
- Colorectal carcinoma 110
- Diverticular disease 112
- Anal pathology 113

## **Gastrointestinal malformations**

### **Oesophageal atresia**

- Occurs in 1 in 3,500 live births.
- Results from faulty division of the foregut into the tracheal and oesophageal channels during the first month of embryonic life.
- In the majority of cases, there is a communication between the distal oesophagus and the trachea known as a tracheo-oesophageal fistula.
- Neonates present with coughing and choking during feeding.
- At least half of affected babies have other congenital abnormalities and cardiac defects account for the majority of deaths in infants with oesophageal atresia.

### **Duodenal atresia**

- Less common than oesophageal atresia.
- Associated with Down's syndrome in 30% of cases.
- Caused by failure of epithelial apoptosis and incomplete canalization of the duodenal lumen by 8 weeks of gestation.
- The obstruction is usually distal to the ampulla of Vater.
- Prenatal ultrasound shows dilation of the proximal duodenum and stomach with polyhydramnios.

### **Exomphalos**

- An anterior abdominal wall defect at the umbilicus that causes abdominal contents to protrude through the umbilicus.
- The protrusion is covered by a delicate transparent sac composed of amniotic membrane and peritoneum.
- Arises due to failure of the midgut to return to the abdomen from the umbilical coelom during embryogenesis.

### **Gastroschisis**

- An anterior abdominal wall defect which lies to the side of the umbilicus through which loops of bowel protrude.
- Unlike exomphalos, there is no protective covering sac.

### **Malrotation**

- Malpositioning of the intestine and mesentery due to failure of rotation of the developing gut as it returns from the umbilical coelom to the abdomen during development.
- A malrotated bowel is likely to have a narrow mesenteric base, predisposing to volvulus around the superior mesenteric artery.
- Compromised arterial blood supply leads to ischaemic necrosis of the entire midgut, extending from the duodenum to the transverse colon.
- Necrosis causes bleeding into the bowel and a high risk of perforation.
- Without prompt surgical intervention, the condition can be fatal.

### **Meckel's diverticulum**

- A remnant of the vitellointestinal duct, the structure that connects the primitive gut to the yolk sac.
- Estimated to occur in 2% of the normal population.

- The mucosa of the diverticulum may contain areas of gastric or pancreatic tissue (heterotopia).
- Most children with a Meckel's diverticulum are asymptomatic.
- The most common symptom is painless rectal bleeding due to ulceration in a diverticulum containing acid-secreting gastric mucosa.
- Small bowel obstruction may also occur, related to intussusception or incarceration.

### **Imperforate anus**

- Umbrella term for any atretic condition of the rectum or anus.
- Lesions range in severity from a stenosed anal canal to anorectal agenesis.
- Surgically, they are considered as either high or low anomalies, depending on the level of termination of the bowel with respect to the pelvic floor.
- Low defects are easier to correct and post-operative function is good.
- Higher defects are more difficult to correct as they are more likely to be associated with fistulae between the rectum and the genitourinary tract as well as a deficient pelvic floor.

### **Hirschsprung's disease**

- Not strictly a malformation, but a congenital gastrointestinal condition in which there is absence of ganglion cells from a variable length of intestinal wall.
- Results from failure of neuroblasts to migrate from the oesophagus to the anal canal during weeks 5–12 of gestation.
- Absence of ganglion cells causes spasm in the aganglionic segment.
- Presents with intestinal obstruction and failure to pass meconium 24h after birth.
- Rectal suction biopsy is the gold standard for the diagnosis of Hirschsprung's disease. The key feature is the absence of ganglion cells in the submucosa and abnormally thick nerve fibres in the mucosal layer.

## Oral cavity diseases

### Candidiasis

- Fungal infection which is more common in the immunosuppressed.
- Clinically, there is erythema with pseudomembrane formation.

### Actinomycosis

- Gram-positive anaerobic bacteria which are part of normal oral flora and colonize tonsillar crypts, dental plaque, and the gums.
- Pathological infection can occur if the organisms enter deeper tissue through trauma (e.g. tooth extraction).

### Lichen planus

- Often involves the oral cavity (📖 p. 288).

### Pemphigus vulgaris

- Usually involves the oral cavity (📖 p. 291).

### Mucous membrane pemphigoid

- Also known as cicatricial pemphigoid.
- Autoimmune blistering disease predominantly affecting mucosal sites.
- Presents between ages 50–70y with oral blistering.
- The conjunctiva, upper airways, and skin are also often involved.
- Histology shows separation of the squamous epithelium from the underlying connective tissue with a variable inflammatory infiltrate.
- Direct immunofluorescence shows linear deposition of IgG and C3 along the basement membrane zone.

### Squamous papilloma

- Benign exophytic proliferation of squamous epithelium.
- Most occur in adults aged 30–50y.
- Predisposition for hard and soft palates and the uvula.
- Histology shows papillary fronds lined by mature squamous epithelium.

### Fibroma

- Benign proliferation of fibrous tissue in response to irritation.
- Most present as a painless oral lump in an adult aged 30–50y.
- Histology shows a subepithelial mass of dense collagenous tissue.

### Pyogenic granuloma

- Benign vascular lesion better termed 'lobular capillary haemangioma'.
- Presents with a dark red polypoid mass which often ulcerates.
- Histology shows a lobulated proliferation of small blood vessels.

### Squamous cell carcinoma

- Most common malignancy of the oral cavity.
- Strong association with alcohol and smoking.
- 30% have regional lymph node metastases at presentation.
- Overall 5-year survival ~50%.

## Salivary gland diseases

### Mucocele

- Pooling of salivary mucus due to blockage to a salivary duct.
- Most commonly occurs on the lower lip.
- Histology shows a cystic lesion filled with mucin and lined by epithelium (retention mucocele) or granulation tissue (extravasation mucocele).

### Pleomorphic adenoma

- Most common salivary gland neoplasm.
- Majority occurs in the parotid gland as a painless slowly growing lump.
- Fine needle aspiration (FNA) cytology is cellular with abundant epithelial and myoepithelial cells and fibrillary stromal fragments.
- Histology shows a circumscribed tumour composed of a mixture of ductal epithelium, myoepithelial cells, and a myxochondroid stroma.
- Benign tumour, but may recur following incomplete excision.

### Warthin's tumour

- Second most common salivary gland neoplasm.
- Almost all occur in the parotid gland as a painless slowly growing lump.
- FNA cytology shows sheets of oncocytic epithelial cells with abundant lymphoid cells in the background.
- Histology shows a circumscribed tumour composed of a double layer of oncocytic epithelium with an underlying dense lymphoid stroma.
- Benign tumour, but may recur following incomplete excision.

### Mucoepidermoid carcinoma

- Most common malignant salivary gland neoplasm.
- Presents with a tender mass related to a major salivary gland.
- FNA cytology shows mucus, intermediate cells, and mucus cells.
- Histology shows an infiltrative tumour composed of a mixture of intermediate, squamoid, and mucus cells. Cystic change may be seen.
- Most tumours are low-grade and behave well with survival >95%.
- High-grade tumours are aggressive with survival ~45%.

### Acinic cell carcinoma

- Malignant salivary gland tumour mostly arising in the parotid.
- Presents with a mass which may be painful.
- Histology shows a tumour composed of serous acinar cells with granular cytoplasm which may grow in a variety of architectural patterns.
- 5-year survival ~80%.

### Adenoid cystic carcinoma

- Malignant salivary gland tumour mostly arising in minor salivary glands.
- Presents with a slowly growing mass which may be painful.
- Histology shows an infiltrative tumour composed of basaloid epithelial and myoepithelial cells, classically forming cribriform sheets. Perineural invasion is very frequently seen.
- 5-year survival ~60%.



## Oesophagitis

### Definition

- Inflammation of the oesophagus.

### Presentation

- Burning retrosternal pain (heartburn).
- Dysphagia and hiccups may also occur.

### Reflux oesophagitis

- Caused by gastric acid refluxing into the lower oesophagus.
- Very common. Most prevalent in adult white males, but can occur in men and women of all races and in children.
- Predisposing conditions include alcohol, medications, hypothyroidism, pregnancy, hiatus hernia, diabetes, and obesity.
- Mucosal biopsy shows regenerative changes of the squamous epithelium demonstrated by basal cell hyperplasia and extension of vascular papillae into the upper part of the epithelium. Inflammation is typically mild with scattered eosinophils.
- ~10% of patients develop glandular metaplasia of the lower oesophagus which is visible endoscopically (**Barrett's oesophagus**).

► Barrett's oesophagus is associated with a 50 times increased risk of oesophageal adenocarcinoma (📖 p. 90). Patients with Barrett's oesophagus should be considered for entry into a surveillance programme of regular endoscopy and biopsy to check for glandular epithelial dysplasia.

### Drug-induced ('pill') oesophagitis

- Caused by direct toxicity of drugs to the oesophageal mucosa.
- Occurs mostly in the elderly.
- Common culprit drugs are bisphosphonates and iron tablets.
- Mucosal biopsy shows acute inflammation with erosion or ulceration of the surface epithelium. Encrusted golden brown iron pigment may be seen in cases caused by iron tablets.
- Usually resolves after discontinuation of the offending drug.

### Eosinophilic oesophagitis

- Uncommon condition which occurs mostly in atopic individuals with a history of allergy, asthma, and drug sensitivities.
- Mucosal biopsy shows heavy infiltration of the mucosa by eosinophils which often form clusters.
- Good outlook if diagnosed and treated early. If untreated, it can lead to severe oesophageal strictures.

### Infectious oesophagitis

- Seen almost exclusively in immunocompromised patients as the oesophagus is normally highly resistant to infection.
- Mucosal biopsy shows inflammation together with pseudohyphae in *Candida*, multinucleation, and margination of chromatin in herpes simplex and inclusions in cytomegalovirus.

## Oesophageal polyps and nodules

### Squamous papilloma

- Uncommon lesion usually seen as a tiny white polyp in the distal oesophagus at endoscopy.
- Although human papillomavirus (HPV) infection has been speculated, most studies have not identified HPV material within them.
- Histology shows bland squamous epithelium forming papillary projections.

### Leiomyoma

- Uncommon benign smooth muscle tumour arising from the muscular layers of the oesophagus.
- Usually produce a polypoid mass covered by mucosa that may show surface ulceration.
- Histology shows interlacing fascicles of bland smooth muscle cells.

### Granular cell tumour

- Uncommon neural tumour which can occur anywhere in the gastrointestinal tract, but most frequently in the tongue and oesophagus.
- Form a small firm raised mucosal nodule in the lower oesophagus.
- Histologically characterized by aggregates of large polygonal cells with conspicuous granular cytoplasm.
- Almost all are benign, though rare malignant cases have been reported.

### Fibrovascular polyp

- Rare oesophageal lesion which typically presents with dysphagia.
- Can reach an alarmingly large size (up to 25cm long!) such that it can regurgitate into the pharynx or mouth.
- Endoscopically visible as a pedunculated lesion on a long stalk.
- Histology shows a polypoid lesion covered by squamous epithelium with an underlying stromal core composed of loose fibrous tissue, fat, and a prominent vasculature.

## Oesophageal carcinoma

### Definition

- A malignant epithelial tumour arising in the oesophagus.
- Two major subtypes are distinguished: **squamous cell carcinoma** and **adenocarcinoma**.

### Epidemiology

- Both types occur at a median age of 65y.
- Oesophageal adenocarcinoma has attracted much attention in developed countries due to its dramatic and ongoing rise in incidence over recent decades.

### Aetiology

- Heavy tobacco and alcohol use for squamous cell carcinoma.
- Chronic gastro-oesophageal reflux disease leading to Barrett's oesophagus is the most common precursor to adenocarcinoma.

### Carcinogenesis

- Both types frequently harbour TP53 mutations.

### Presentation

- Dysphagia, retrosternal or epigastric pain, and weight loss.
- By the time most patients present, the tumour is already advanced.

### Macroscopy

- Tumour mass in the oesophagus which may grow into the lumen in an exophytic manner or infiltrate into the wall in a plaque-like fashion.
- Squamous cell carcinomas tend to occur in the middle oesophagus whereas adenocarcinomas tend to occur in the lower oesophagus.

### Histopathology

- Squamous cell carcinomas show infiltrating malignant epithelial cells with evidence of squamous differentiation, i.e. intercellular bridges and/or keratinization.
- Adenocarcinomas show infiltrating malignant epithelial cells with evidence of glandular differentiation, i.e. tubule formation and/or mucin production. The adjacent oesophageal mucosa may show high-grade dysplasia within an area of Barrett's oesophagus.

### Prognosis

- Generally poor due to late presentation.
- 5-year survival rates ~10–20%.

**TNM 7 pathological staging of oesophageal carcinoma****Primary tumour (T)**

pT1a: tumour invades no deeper than the submucosa.

pT2: tumour invades the muscularis propria.

pT3: tumour invades the adventitia.

pT4: tumour invades adjacent structures.

**Regional lymph nodes (N)**

pN0: no regional lymph node metastasis.

pN1: 1 or 2 regional lymph node metastases.

pN2: 3–6 regional lymph node metastases.

pN3: 7 or more regional lymph node metastases.

## Gastritis

### Acute haemorrhagic gastritis

- Caused by an abrupt insult to the gastric mucosa.
- Often the result of a severe alcohol binge, but any acute medical illness which reduces gastric blood flow may also cause acute gastritis.
- Endoscopy shows numerous punctate erosions which ooze blood.
- Severe forms can cause significant upper gastrointestinal haemorrhage.
- Histology shows neutrophilic infiltration of the gastric mucosa with haemorrhage and mucosal necrosis.
- Acute gastritis usually resolves rapidly and uneventfully.

### Chemical/reactive gastritis

- Caused by any low-grade injury to the gastric mucosa.
- Seen mostly in the antrum in relation to bile reflux or non-steroidal anti-inflammatory drugs (NSAIDs).
- Endoscopically, there is erythema of the gastric mucosa.
- Histology shows vascular congestion, foveolar hyperplasia, and smooth muscle proliferation. Inflammation is minimal or absent.
- Reactive gastritis usually resolves without complication if the offending cause is removed.

### Iron pill gastritis

- Caused by the corrosive effects of ingested iron tablets.
- Histology shows causes acute inflammation with erosion or ulceration of the gastric mucosa. Yellow-brown iron pigment may be seen.

### Helicobacter gastritis

- A very common cause of gastritis which is usually antral-predominant.
- Most are caused by *Helicobacter (H.) pylori*, a curved flagellate Gram-negative rod.
- *H. heilmannii*, which is more tightly coiled, accounts for <1% of cases.
- Histology shows a heavy lymphoid inflammatory infiltrate in the lamina propria with neutrophilic infiltration of the superficial mucosa.
- The organisms can be identified on routine stains, but are better visualized on special stains that highlight the bacteria.
- In most cases, the gastritis is healed by eradicating the organism.
- In a small proportion of untreated cases, the gastritis can be complicated by peptic ulceration, gastric carcinoma (📖 p. 94), or gastric marginal zone B-cell lymphoma (📖 p. 279).

### Autoimmune gastritis

- Caused by autoimmune attack directed at parietal cells in fundic glands.
- Histology shows infiltration of the body mucosa by lymphocytes and plasma cells. The infiltrate is directed at fundic glands with the loss of chief and parietal cells. Pyloric and intestinal type metaplasia is common.
- Increased risk of gastric neuroendocrine tumours and carcinoma.
- Some patients also develop antibodies to intrinsic factor, leading to depletion of vitamin B12 and megaloblastic anaemia (📖 p. 258).

## Gastric polyps

### Hyperplastic polyp

- Common polyp which occurs mostly in the antrum or body.
- Non-neoplastic reactive lesion thought to represent an exaggerated regenerative response to mucosal injury.
- Usually associated with underlying gastric pathology such as *Helicobacter* or autoimmune gastritis.
- Histology shows a polyp containing dilated elongated tortuous foveolar epithelium in an oedematous inflamed lamina propria.

### Fundic gland polyp

- Common polyp which occurs only in the body or fundus.
- Can occur sporadically or in association with familial adenomatous polyposis (FAP).
- FAP-associated polyps are more likely to be multiple and occur at a younger age.
- Sporadic polyps are not normally associated with any underlying mucosal pathology.
- Some publications have described an association with proton pump inhibitors, but this observation has been subsequently disputed.
- Histology shows a polyp containing cystically dilated fundic glands lined by flattened parietal and chief cells.

### Gastric adenoma

- Uncommon neoplastic polyp that can occur throughout the stomach.
- Microscopically composed of dysplastic glands with stratified hyperchromatic nuclei.
- Two types are described, an intestinal and a foveolar type.
- Intestinal types are far more likely to show high-grade dysplasia or harbour gastric carcinoma than the foveolar type.

### Gastric xanthoma

- Uncommon polyp that occurs anywhere in the stomach.
- Appears as a pale yellow nodule due to its lipid content.
- Histology shows numerous lipid-laden macrophages in the lamina propria.

### Inflammatory fibroid polyp

- Rare lesion which occurs mostly in the antrum.
- Histology shows a submucosal lesion composed of bland spindle cells arranged around prominent vessels, all set in a loose myxoid stroma containing conspicuous eosinophils.

## Gastric carcinoma

### Definition

- A malignant epithelial tumour arising in the stomach.

### Epidemiology

- Marked geographical variability in incidence due to differences in diet.
- Changes in nutrition in countries with a traditionally high incidence is leading to a steadily declining global incidence.

### Aetiology

- Diet is the most consistent factor. High salt intake is a strong risk factor whilst fresh fruit and vegetables are protective due to their antioxidant effects.
- *H. pylori* and autoimmune gastritis are the other major risk factors as they both promote a sequence of chronic gastritis → gastric atrophy → intestinal metaplasia → epithelial dysplasia → carcinoma.

### Carcinogenesis

- Free radicals, oxidants, and reactive oxygen species produced by *H. pylori* infection and dietary carcinogens cause DNA damage.
- Common gene targets include TP53 and KRAS.
- Diffuse type carcinomas often show E-cadherin loss.

### Presentation

- Early gastric cancer may be asymptomatic or cause non-specific symptoms such as dyspepsia.
- Advanced cases cause persistent abdominal pain with weight loss.
- Tumours may also bleed causing haematemesis or obstruct the gastric outlet leading to vomiting.

### Macroscopy

- A tumour mass in the stomach wall which may be exophytic or diffusely infiltrative.

### Histopathology

- Almost all are adenocarcinomas.
- Intestinal-type adenocarcinoma shows infiltrating malignant epithelial cells forming recognizable glandular structures.
- Diffuse-type adenocarcinoma shows infiltrating malignant epithelial cells growing as poorly cohesive cells with little or no gland formation. Individual malignant cells may contain intracytoplasmic vacuoles filled with mucin. Cells distended with mucin such that the nucleus is displaced to one side are also known as 'signet ring' cells. Tumours with abundant signet ring cells tend to be widely infiltrative.

### Prognosis

- Dependent on stage, but generally presents late with a poor prognosis.

**TNM 7 pathological staging of gastric carcinomas****Primary tumour (T)**

pT1a: tumour invades the lamina propria.

pT1b: tumour invades the submucosa.

pT2: tumour invades the muscularis propria.

pT3: tumour invades the subserosa.

pT4a: tumour perforates the serosa.

pT4b: tumour invades adjacent structures.

**Regional lymph nodes (N)**

pN0: no regional lymph node metastasis.

pN1: metastasis in 1 or 2 regional lymph nodes.

pN2: metastasis in 3–6 regional lymph nodes.

pN3: metastasis in 7 or more regional lymph nodes.



## **Gastrointestinal stromal tumours**

### **Definition**

- Mesenchymal tumours of variable malignant potential which arise within the wall of the gastrointestinal tract and recapitulate the phenotype of the interstitial cell of Cajal, the pacemaker cell of the Auerbach plexus.

### **Epidemiology**

- Incidence of about ~15 per million population per year.
- Most arise in adults at a median age of 50–60y.

### **Aetiology**

- Aetiology of sporadic cases unknown.
- A small proportion arise in association with neurofibromatosis type 1, Carney's triad, and families with germline KIT mutations.

### **Genetics**

- The vast majority show activating mutations of the oncogene, KIT.
- The remainder show activating mutations in the related gene, PDGFRA.

### **Presentation**

- Palpable upper abdominal mass, pain, or bleeding.
- Malignant tumours may present with symptoms related to metastases.

### **Sites of involvement**

- Can occur anywhere in the gastrointestinal tract from the oesophagus to the rectum.
- Most arise in the stomach (60–70%) or small intestine (20–30%).
- A small number appear to arise primarily within the omentum.

### **Macroscopy**

- Well-defined tumour mass centred on the submucosal, muscular, or serosal layer of the bowel.
- Ranges in size from 1 to >20cm.

### **Histopathology**

- Composed of spindle cells, often with paranuclear vacuoles.
- Plumper epithelioid cells may also be present and some tumours may be entirely epithelioid in nature.
- Small intestinal tumours may also have so-called 'skeinoid' fibres.
- Almost all express the markers CD117 (c-kit) and DOG-1.

### **Prognosis**

- All should be considered potentially malignant.
- Based on location, size, and mitotic activity, they are stratified into very low-risk, low-risk, intermediate-risk, and high-risk categories for malignancy.

# Peptic duodenitis

## Definition

- Inflammation  $\pm$  ulceration of the duodenal mucosa due to excess gastric acid.

## Epidemiology

- Common, affecting up to 10% of the population.
- Mostly seen in male patients aged >40y.

## Aetiology

- Chronic *H. pylori* infection is thought to be the key aetiological factor.
- Smoking and NSAIDs are also major risk factors.
- Recurrent multiple duodenal ulcers, particularly if present beyond the first part of the duodenum, should raise suspicion of possible Zollinger–Ellison syndrome (📖 p. 136).

## Pathogenesis

- Increased gastric acid production causes injury to the duodenal mucosa, varying from mild erosions only through to severe ulceration.

## Presentation

- Burning epigastric pain relieved by eating.
- Severe cases cause persistent epigastric pain, nausea, and vomiting.

## Macroscopy

- Peptic duodenitis shows mucosal erythema  $\pm$  superficial erosions.
- Peptic ulcers appear as well-circumscribed punched-out mucosal defects with granulation tissue at the base.

## Histopathology

- Peptic duodenitis shows acute inflammation, oedema, and haemorrhage in the lamina propria. The surface epithelium typically shows areas of gastric metaplasia. *H. pylori* organisms may be identified overlying the metaplastic gastric epithelium.
- Peptic ulcers show complete loss of the whole mucosal layer with replacement by granulation tissue and underlying scar tissue.

## Prognosis

- Eradication of *H. pylori* and acid suppressive therapy improves symptoms and leads to healing.
- Scarring of ulcers can lead to stricture formation and obstruction.
- Breach of a large vessel by a peptic ulcer is a common cause of acute upper gastrointestinal haemorrhage.
- Free perforation causes acute generalized peritonitis, necessitating urgent surgical intervention.

## Coeliac disease

### Definition

- An autoimmune disorder caused by an abnormal immune response to dietary gluten.

### Epidemiology

- Common, affecting ~1% of the population.

### Aetiology

- Dietary gluten and related proteins.

### Pathogenesis

- The culprit proteins are poorly digested by intestinal proteases.
- Intact peptides enter the lamina propria and are deamidated by tissue transglutaminase, rendering them negatively charged.
- Negatively charged peptides bind more efficiently to HLA receptors on antigen-presenting cells which are recognized by intestinal T-cells.
- Activated T-cells stimulate an immune reaction in the intestinal wall.

### Presentation

- Symptoms relating to the gastrointestinal tract may be present such as weight loss, abdominal pain, and diarrhoea.
- However, many patients are asymptomatic and only diagnosed during investigation of an iron deficiency anaemia.

### Serology

- Presence of serum IgA endomysial or transglutaminase antibodies is highly specific and sensitive for coeliac disease.

### Macroscopy

- Blunting and flattening of villi may be visible under dissecting microscope.

### Histopathology

- Fully developed cases show increased intraepithelial lymphocytes, many lymphocytes and plasma cells in the lamina propria, villous atrophy, and crypt hyperplasia.
- Milder cases may only show increased intraepithelial lymphocytes without villous atrophy.

► Note that none of these changes are specific to coeliac disease; identical changes can be seen in a number of other conditions. Biopsy findings must be interpreted in light of the clinical and serological picture.

### Prognosis

- Strict adherence to a gluten-free diet leads to resolution of symptoms and normalization of histology.
- Increased risk of type 1 diabetes, autoimmune thyroid disease, dermatitis herpetiformis, oropharyngeal and oesophageal carcinoma, small bowel adenocarcinoma, and a rare, but highly aggressive, form of T-cell lymphoma known as enteropathy-associated T-cell lymphoma.

## Small bowel infarction

### Definition

- Ischaemic necrosis of a segment of small intestine.

### Epidemiology

- Usually seen in patients aged >50y.

### Aetiology

- Thrombosis overlying an unstable atherosclerotic plaque in the superior mesenteric artery.
- Thromboemboli from the left ventricle or left atrium.
- Hypovolaemia.

### Pathogenesis

- Sudden reduction in blood flow through the superior mesenteric artery leads to ischaemic necrosis of a segment of small bowel.
- Massive haemorrhage into the infarcted bowel causes hypovolaemia.
- Bacteria rapidly permeate the devitalized intestinal wall, leading to sepsis.

### Presentation

- Acute onset of severe abdominal pain with bloody diarrhoea and hypovolaemia.

### Macroscopy

- The infarcted small bowel appears dusky purple.
- On opening the segment of bowel, large amounts of blood are present in the lumen and the mucosal surface is friable and necrotic.

### Histopathology

- Full thickness necrosis of the bowel wall.

### Prognosis

- Early laparotomy is essential to resect the infarcted segment of bowel.
- Survival is generally poor due to the rapid development of hypovolaemia and sepsis, causing multiorgan failure.

## Intestinal infections

### ***Campylobacter, Salmonella, Shigella, E. coli***

- Common bacterial causes of gastrointestinal infection.
- Mucosal biopsies usually show an acute colitis with neutrophils present in the lamina propria and within crypts.
- Enterotoxigenic *E. coli* (ETEC) is a common cause of diarrhoea in travellers. ETEC possesses fimbriae which allow the bacteria to adhere to small bowel epithelial cells and produce toxins, causing massive fluid loss.
- Enterohaemorrhagic *E. coli* produces a cytotoxin, leading to haemorrhagic necrosis of the colonic mucosa and bloody diarrhoea. Susceptible individuals, particularly children, are at risk of developing thrombotic microangiopathy, leading to haemolysis and acute renal failure (haemolytic uraemic syndrome).

### ***Clostridium difficile***

- An important cause of colitis often associated with broad spectrum antibiotic use in hospitalized patients.
- The clinical picture is highly varied, ranging from mild diarrhoea to fulminant colitis with a risk of perforation and death.
- Macroscopically, the colitis leads to the formation of cream-coloured pseudomembranes on the mucosal surface of the colon.
- Microscopically, crypts distended with neutrophils and mucin are covered by pseudomembranes composed of fibrin and neutrophils.

### ***Mycobacterium avium***

- Significant opportunistic pathogen in the immunosuppressed.
- Disseminated infection throughout the small and large bowel causes chronic diarrhoea.
- Mucosal biopsy shows extensive infiltration of the lamina propria by macrophages filled with acid-fast bacilli.

### **Rotavirus**

- Most common cause of severe diarrhoea in infants and young children.
- Faecal-oral transmission.
- Immunity develops during childhood such that adult infection is rare.

### **Norovirus**

- Common cause of epidemic outbreaks of gastroenteritis.
- Highly infectious with transmission through contaminated food or water, person-to-person contact, and contamination of surfaces.
- Often seen in close communities such as institutions, hospitals, and cruise ships.

### **Cytomegalovirus**

- Usually associated with immunocompromise.
- Cytomegalovirus (CMV) infection is an important cause of a sudden clinical deterioration in immunosuppressed patients with inflammatory bowel disease.
- Microscopically, the changes vary from mild inflammation to deep ulceration. CMV inclusions are found in endothelial and stromal cells.

### **Giardia lamblia**

- Protozoan transmitted by drinking water contaminated with cysts of the organism.
- The mature pathogen attaches to the brush border of the epithelial cells of the upper small bowel.
- The inflammatory reaction causes a mild diarrhoeal illness which lasts ~1 week and then resolves.
- Immunocompromised individuals may develop chronic infection.

### **Entamoeba histolytica**

- Common protozoal infection affecting ~10% of people worldwide.
- Symptoms range from mild diarrhoea and abdominal pain to a severe fulminant colitis.
- The infection can disseminate to other sites such as the liver and, rarely, large inflammatory masses can form (amoebomas).
- Mild cases show neutrophilic infiltration only, but more severe cases are associated with deep ulceration of the bowel.
- The organisms are round structures with a bean-shaped nucleus and foamy cytoplasm containing ingested red blood cells.

### **Enterobius vermicularis**

- Nematode pinworm transmitted by hand-to-mouth transfer of eggs.
- Larvae mature into adult organisms, residing mainly in the caecum.
- At night, female organisms migrate to the anus to deposit eggs which cause marked perianal itching.

### **Necator americanus & Ancylostoma duodenale**

- Nematode hookworms which attach themselves to jejunal mucosa.
- A pump mechanism is used to ingest blood and interstitial fluid from the host. High wormloads can lead to significant cumulative blood loss.
- Hookworm infestation is the commonest cause of iron deficiency anaemia worldwide.

## **Intestinal obstruction**

### **Definition**

- Mechanical blockage to a segment of bowel.

### **Epidemiology**

- Common.

### **Aetiology**

- Small bowel obstruction: adhesions, hernias, intussusception, volvulus.
- Large bowel obstruction: tumours, sigmoid volvulus, diverticular strictures.

### **Pathogenesis**

- Mechanical blockage to the bowel prevents normal peristaltic movements.

### **Presentation**

- Small bowel obstruction: acute colicky abdominal pain, abdominal distension, early onset of vomiting, later onset of absolute constipation (neither flatus nor faeces passed).
- Large bowel obstruction: acute colicky abdominal pain, abdominal distension, early onset of absolute constipation, later onset of vomiting.

### **Macroscopy**

- The bowel proximal to the obstruction is usually dilated.
- The underlying cause of the obstruction is usually apparent, e.g. adhesions, tumour, intussusception.

### **Histopathology**

- Ischaemic changes may be present in prolonged cases.
- Features of the underlying cause may also be seen.

### **Prognosis**

- Depends on the underlying cause.
- Benign causes of obstruction generally have a good prognosis following either spontaneous resolution or surgical intervention.
- Large bowel obstruction due to colorectal carcinoma generally implies advanced disease and poorer prognosis.

# Acute appendicitis

## Definition

- An acute inflammatory process of the appendix related to obstruction.

## Epidemiology

- Peak incidence between ages 5–15, but can occur at any age.

## Aetiology

- Believed to be the result of obstruction of the appendiceal lumen by a faecolith, undigested food, or enlarged lymphoid tissue.

## Pathogenesis

- Obstruction to the appendiceal lumen leads to superimposed infection in the mucosa which then spreads through the whole wall of the appendix.

## Presentation

- Right iliac fossa pain accompanied by fever and malaise.
- Many cases do not show typical features, possibly related to the precise positioning of the appendix within the individual.

## Macroscopy

- The appendix may appear normal in early cases where the inflammation is confined to the mucosal layer.
- In more advanced cases, the appendix is dilated and a fibrinopurulent exudate may be seen on the serosal surface.

## Histopathology

- Early cases show neutrophils within crypts (crypt abscesses) and erosions of the surface epithelium.
- Neutrophils then extend into the lamina propria of the mucosa and collect within the lumen of the appendix.
- Later cases show extension of the acute inflammatory process into the submucosa, muscularis propria, and serosa.
- Extensive necrosis of the muscularis propria can lead to perforation.

## Prognosis

- Prognosis is excellent, provided appendectomy is performed promptly.
- Delayed treatment risks perforation of the inflamed appendix with potential complications such as intra-abdominal abscess formation or generalized peritonitis.



## Crohn's disease

### Definition

- An idiopathic inflammatory bowel disease characterized by multifocal areas of inflammation which may involve any part of the gastrointestinal tract.

### Epidemiology

- Uncommon.
- Major incidence between 20–30y.

### Aetiology & pathogenesis

- Thought to be caused by an abnormal mucosal immune response to luminal bacteria in genetically susceptible individuals.
- Mutations in the gene CARD15 (which codes for an intracellular receptor for bacterial peptidoglycan moieties) has been associated with small intestinal Crohn's disease in white populations.
- Smoking increases the risk.
- A true infectious aetiology remains unproven.

### Presentation

- Crampy right iliac fossa pain and diarrhoea which is usually not bloody.
- Fever, malaise, and weight loss are common.

### Macroscopy

- Disease usually involves the terminal ileum and colon.
- Affected bowel is thickened with encroachment of mesenteric fat around the anti-mesenteric border of the bowel ('fat wrapping').
- Adhesions and fistulas may be seen between adjacent loops of bowel.
- The mucosal surface shows linear ulceration and cobblestoning.

### Histopathology

- Mucosal biopsies: variability of inflammation within a single biopsy and between several biopsies is the key feature. This is typically manifested by discrete areas of inflammation adjacent to histologically normal crypts. Surface erosions and ulceration may be present. Poorly formed granulomas may be seen, but these are generally uncommon.
- Resection specimens: deep fissuring ulcers separated by relatively normal mucosa. Lymphoid aggregates are present in the submucosa and muscular layers. Poorly formed granulomas may be seen.

### Prognosis

- Relapsing and remitting course.
- Most patients require surgery at some point to relieve symptoms from obstruction or fistula formation.
- Increased risk of small and large bowel adenocarcinoma.
- Extragastrintestinal manifestations include enteropathic arthropathy (📖 p. 315), anterior uveitis, gallstones, erythema nodosum (📖 p. 294), and pyoderma gangrenosum (📖 p. 295).

# Ulcerative colitis

## Definition

- An idiopathic inflammatory bowel disease characterized by inflammation restricted to the large bowel mucosa, which always involves the rectum and extends proximally in a continuous fashion for a variable distance.

## Epidemiology

- Uncommon.
- Major incidence between 15–25y.

## Aetiology & pathogenesis

- Thought to be due to an abnormal mucosal immune response to luminal bacteria.
- The genetic link is weaker than for Crohn's disease.
- Smoking appears to decrease the risk of ulcerative colitis (UC).
- One unusual, but consistently confirmed, observation is the protective effect of appendectomy on the subsequent development of UC.

## Presentation

- Recurrent episodes of bloody diarrhoea, often with urgency and tenesmus.

## Macroscopy

- Erythematous mucosa with a friable eroded surface and haemorrhage.
- Inflamed mucosa may form polypoid projections (inflammatory polyps).
- Disease always involves the rectum and extends continuously to involve a variable amount of colon.

## Histopathology

- Biopsies show diffuse mucosal inflammation with cryptitis and crypt abscess formation. Inflammation is usually more severe distally.
- Resection specimens show diffuse inflammation limited to the mucosal layer. Inflammatory polyps may be present.
- Extension of inflammation into the submucosa or muscle layers may occur in very severe acute UC, but the inflammation still remains heaviest in the mucosal layer.

## Prognosis

- Generally good with treatment.
- Increased risk of colorectal carcinoma, so surveillance colonoscopy is usually recommended several years after diagnosis.
- Extragastrointestinal manifestations include enteropathic arthropathy (📖 p. 315), primary sclerosing cholangitis (📖 p. 122), erythema nodosum (📖 p. 294), pyoderma gangrenosum (📖 p. 295), uveitis, and AA amyloidosis.

## Microscopic colitis

### Definition

- A chronic form of colitis characterized by chronic watery diarrhoea, normal or near normal colonoscopy, and microscopic evidence of colonic inflammation.

### Subtypes

- Two types are recognized: **lymphocytic** and **collagenous colitis**.

### Lymphocytic colitis

- Incidence of 3 per 100,000 population.
- Equal sex incidence.
- Mean age of onset is 50y.
- Strong association with coeliac disease.
- Mucosal biopsy specimens show increased numbers of plasma cells in the lamina propria and increased intraepithelial lymphocytes.
- Most patients respond to medical therapy.

### Collagenous colitis

- Incidence of 1–2 per 100,000 population.
- Significant predilection for women (♀:♂ = 8:1).
- Mean age of onset is 60y.
- Association with NSAIDs and coeliac disease.
- Mucosal biopsy specimens show subepithelial deposition of collagen, increased numbers of plasma cells in the lamina propria, and increased intraepithelial lymphocytes.
- Most patients respond to medical therapy.

*This page intentionally left blank*

## Colorectal polyps

### Hyperplastic polyps

- Very common polyps, occurring most frequently in the distal colon.
- Usually small lesions, <1cm in size, found on the crest of a mucosal fold.
- Microscopically, they are composed of crypts which are dilated and serrated in the superficial portion and narrow at the base.
- Benign lesions with no risk of progression into carcinoma.

### Adenomatous polyps

- Very common polyps which may occur anywhere in the large bowel.
- Most occur sporadically, but they are also associated with **familial adenomatous polyposis (FAP)**.
- FAP is an inherited condition in which the colon becomes carpeted with thousands of adenomas at a young age with the inevitable development of colorectal carcinoma without prophylactic colectomy.
- Neoplastic polyps which harbour frequent mutations of APC, KRAS, and TP53.
- Microscopically, the polyps contain dysplastic glands lined by epithelial cells with stratified hyperchromatic nuclei growing in complex tubules or finger-like villous projections.
- The dysplasia is graded into low or high grade, according to the degree of cytological and architectural abnormality.
- ~10% of adenomas develop carcinoma.
- The likelihood of malignant transformation is higher with larger polyps, high grade dysplasia, and a villous architecture.

### Sessile serrated adenomas

- Relatively recently characterized polyps which tend to be >1cm and more likely to be found in the right colon.
- Genetically, they tend to harbour mutations in mismatch repair genes.
- Microscopically, they show markedly dilated serrated crypts which are widened at their base.
- Associated with an increased risk of subsequent colorectal carcinoma.

### Inflammatory polyps

- Thin filiform lesions which occur following any mucosal injury, but are often seen in patients with inflammatory bowel disease.
- Microscopically, they are covered by mucosa on all sides with only a tiny amount of submucosal tissue.

### Mucosal prolapse

- Prolapsed pieces of mucosa which appear as a polypoid projections.
- Can occur at any point in the large bowel, but characteristically seen on the anterior rectal wall or in association with diverticular disease.
- Can ulcerate and mimic colorectal carcinoma.
- Microscopically, they show distorted angulated crypts set in a lamina propria containing bundles of smooth muscle.

### Benign fibroblastic polyps

- Almost always incidental polyps picked up in adults undergoing screening colonoscopy.
- Microscopically, they show a bland spindle cell proliferation in the lamina propria. The spindle cells show no specific line of differentiation immunohistochemically.

### Leiomyomas

- Benign smooth muscle tumours arising from the muscularis mucosae.
- Usually small polyps located mostly in the distal large bowel.
- Microscopically, they show bundles of bland smooth muscle cells.

### Juvenile polyps

- Most common colonic polyp found in children.
- Thought to be hamartomatous in nature.
- Microscopically, they show irregular dilated disorganized colonic glands in an oedematous stroma.
- Presence of multiple juvenile polyps may be a marker for **juvenile polyposis**, an autosomal dominant condition caused by germline mutations in either SMAD4 or BMPR1A.

## Colorectal carcinoma

### Definition

- A malignant epithelial tumour arising in the colon or rectum.
- ▶ Note that only tumours that have penetrated through the muscularis mucosae into the submucosa are considered malignant at this site. This contrasts with carcinomas at other sites where a breach of the basement membrane directly underlying the epithelium is sufficient for the categorization of an epithelial tumour as malignant.

### Epidemiology

- Third most common cancer in the UK, with a lifetime risk of 1 in 16 men and 1 in 20 women.
- Second most common cause of cancer-related death.

### Aetiology

- A diet high in animal fat and low in fibre, together with a sedentary lifestyle, increases the risk.
- Other associations include idiopathic inflammatory bowel disease, FAP, and hereditary non-polyposis colorectal cancer (HNPCC).

### Carcinogenesis

- Most develop through a sequence of aberrant crypt focus (dysplasia in a single crypt) → adenomatous polyp → invasive carcinoma.
- Common genetic aberrations include the loss of APC, TP53, and SMAD4.
- Some tumours are characterized by the inactivation of mismatch repair genes, recognized by the epiphenomenon of microsatellite instability.

### Presentation

- Change in bowel habit, tenesmus, abdominal pain, iron deficiency anaemia.
- Asymptomatic tumours may be discovered via screening or surveillance programmes.

### Macroscopy

- Most tumours grow as polypoid masses projecting into the bowel lumen, often with areas of surface ulceration. Some tumours, particularly in the distal colon, form circumferential stenosing lesions.
- The cut surface shows a firm white tumour mass with poorly defined margins infiltrating into the bowel wall.
- Large pools of gelatinous material are seen in mucinous carcinomas.

### Histopathology

- The vast majority are adenocarcinomas, i.e. infiltrating malignant epithelial tumours showing evidence of glandular differentiation.
- Well-differentiated tumours show plentiful tubular formation whereas poorly differentiated tumours show minimal gland formation.

- Most tumours are moderately differentiated and often contain abundant necroinflammatory debris within the glandular spaces (so-called 'dirty' necrosis).
- ~10% of colonic and 30% of rectal tumours show extensive mucin production such that the malignant cells are seen floating in large pools of extracellular mucin; these are termed **mucinous adenocarcinomas**.

### Prognosis

- 5-year survival rate ~50%.
- Important prognostic factors include the stage, presence of vascular invasion, differentiation of tumour, and completeness of surgical excision.

### National Health Service (NHS) bowel cancer screening programme

- Offers screening every 2y to men and women aged 60–69.
- People >70y are not routinely invited, but can request screening.
- Eligible patients are sent a faecal occult blood test kit to their home with instructions on how to complete the test and send their sample to their nearest laboratory.
- ~2% of people receive a positive result and are usually offered a colonoscopy.
- Of those, 50% have a normal colonoscopy, 40% will be found to have a polyp, and 10% will be found to have carcinoma.

### TNM 7 pathological staging of colorectal carcinomas

#### Primary tumour (T)

pT1: tumour invades the submucosa.

pT2: tumour invades the muscularis propria.

pT3: tumour invades through the muscularis propria into the subserosa or into non-peritonealized pericolic or perirectal tissues.

pT4a: tumour perforates the visceral peritoneum.

pT4b: tumour directly invades other organ or structures.

#### Regional lymph nodes (N)

pN0: no regional lymph node metastasis.

pN1a: metastasis in 1 regional lymph node.

pN1b: metastasis in 2 or 3 regional lymph nodes.

pN2a: metastasis in 4–6 regional lymph nodes.

pN2b: metastasis in 7 or more regional lymph nodes.



## Diverticular disease

### Definition

- The presence of outpouchings of colonic mucosa that have herniated through the circular muscular layer of the large bowel. The vast majority of cases are seen in the sigmoid colon.

### Epidemiology

- Very common. Mostly a disease of patients aged >60y.

### Aetiology

- A diet low in fibre and high in meat is the strongest risk factor.

### Pathogenesis

- Firm stools require higher intraluminal pressures to propel.
- High intraluminal pressure forces pouches of colonic mucosa through an anatomical weak point in the muscular layer where blood vessels pass through to supply the mucosal layers.

### Presentation

- Intermittent abdominal pain, altered bowel habit, iron deficiency anaemia. ► These symptoms may closely mimic colorectal carcinoma.
- Acute inflammation in a diverticulum (acute diverticulitis) presents with severe left iliac fossa pain.
- Occasionally, erosion of a large submucosal vessel can cause severe rectal bleeding.

### Macroscopy

- Diverticula are seen herniating out between the taenia coli of the sigmoid colon.
- The circular muscle layer is often markedly thickened and numerous redundant mucosal folds are present, projecting into the lumen.
- In acute diverticulitis, an inflammatory mass may be visible surrounding a diverticulum.
- Diverticular strictures cause fibrous narrowing of the bowel lumen which can closely mimic a stenosing carcinoma.

### Histopathology

- Diverticula are seen herniating through a thickened circular muscle layer. Only a thin coating of longitudinal muscle separates the diverticulum from the pericolic fat.
- In cases of acute diverticulitis, there is superimposed acute inflammation associated with a diverticulum; severe cases may show pericolic abscess formation.

### Prognosis

- Acute diverticulitis can be complicated by pericolic abscess formation, fistula formation, and free perforation.
- Free perforation causes generalized peritonitis which can be fatal in frail elderly patients.

## Anal pathology

### Haemorrhoids

- Abnormally dilated and prolapsed anal cushions.
- Extremely common.
- Thought to be due to disruption of the normal suspensory mechanisms caused by chronic straining at stool.
- Cause bright red rectal bleeding and discomfort.
- Excised haemorrhoids examined microscopically contain large dilated blood vessels with overlying hyperplastic squamous epithelium.

### Anal tags

- Polypoid projections of anal mucosa and submucosa.
- Unrelated to haemorrhoids, but frequently confused with them.
- Microscopically composed of a fibrovascular core covered by squamous epithelium. The fibrovascular core lacks the typical ectatic vessels of haemorrhoids.

### Anal fissure

- A tear in the mucosa of the lower anal canal which is almost always located posteriorly in the midline.
- Cause is unclear, but chronic infection may lead to the loss of the normal elasticity of mucosa such that passage of hard faeces may precipitate the tear.
- Usually presents with severe pain.

### Anorectal abscess

- A collection of pus within deep perianal tissue.
- A complication of infection within a deep anal gland.
- Presents with perianal erythema, swelling, and pain.

### Anorectal fistula

- An abnormal epithelial-lined tract connecting the anal canal to the perianal skin.
- Usually, the result of infection in an anal gland tracking to the skin surface.
- Multiple perianal fistulas can also be a manifestation of Crohn's disease.

### Anal cancer

- Uncommon and invariably associated with HPV infection.
- Vast majority are squamous cell carcinomas which arise from areas of squamous dysplasia known as anal intraepithelial neoplasia (AIN).

*This page intentionally left blank*

# Hepatobiliary pathology

- Acute viral hepatitis 116
- Chronic viral hepatitis 117
- Alcoholic liver disease 118
- Non-alcoholic fatty liver disease 119
- Autoimmune hepatitis 120
- Primary biliary cirrhosis 121
- Primary sclerosing cholangitis 122
- Wilson's disease 123
- Hereditary haemochromatosis 124
- Cirrhosis 125
- Benign liver lesions 126
- Hepatocellular carcinoma 127
- Intrahepatic cholangiocarcinoma 128
- Cholecystitis 129
- Extrahepatic bile duct carcinoma 130

## Acute viral hepatitis

### Definition

- Infection of the liver by hepatitis A, B, C, or E, lasting 6 months or less.

### Epidemiology

- Hepatitis A virus (HAV) and hepatitis C virus (HCV) are common worldwide.
- Hepatitis B virus (HBV) is common in parts of Asia and China.
- Hepatitis E virus (HEV) is common in South East Asia, India, and Central America.
- All ages may be affected.

### Virology

- HAV is a positive sense, single-stranded RNA picornavirus transmitted orally by faecal contamination of food or water.
- HBV is a partially double-stranded DNA hepadnavirus transmitted through contaminated needles, sexual contact, or vertically from an infected mother to her baby.
- HCV is a positive sense, single-stranded RNA hepacivirus transmitted from contaminated needles, mostly through intravenous drug abuse.
- HEV is positive sense, single-stranded RNA hepevirus transmitted orally by faecal contamination of food or water.

### Immunopathogenesis

- The viruses localize to the liver. After a variable incubation period, a specific T-lymphocyte response to the virus is mounted.
- The necroinflammatory activity in the liver causes an episode of acute hepatitis.

### Presentation

- Many cases are clinically silent or cause a non-specific, flu-like illness.
- Clinically apparent cases cause nausea, vomiting, malaise, and jaundice.

### Serology

- Presence of serum anti-hepatitis IgM antibodies confirms recent infection.

### Macroscopy

- The liver may be swollen and discoloured with bile.

### Histopathology

- Liver lobules are infiltrated by mononuclear inflammatory cells.
- Hepatocyte injury is manifested morphologically by swelling ("ballooning") or shrinkage and pyknosis (acidophil bodies).
- Severe cases show confluent areas of hepatocyte necrosis and parenchymal collapse.

► Note these histological changes are not specific to viral hepatitis and may be seen in acute liver injury from other causes.

### Prognosis

- Acute HAV never progresses to chronic infection.
- Acute HBV progresses to chronic infection in ~10% of cases.
- Acute HCV progresses to chronic infection in ~90% of cases.

# Chronic viral hepatitis

## Definition

- Infection of the liver by hepatitis B or C, lasting >6 months.

## Epidemiology

- Chronic HCV is common worldwide with ~3% of the world's population infected.
- Chronic HBV shows more geographical variation, being rarer in western countries, but very common in areas of Asia and China where infection rates are as high as 15%.

## Immunopathogenesis

- Chronic viral hepatitis is the result of an immune response that fails to clear the virus following infection.
- 10% of people fail to clear HBV infection.
- 90% of people fail to clear HCV infection.

## Presentation

- Often asymptomatic and diagnosed incidentally on abnormal liver function tests.
- Many patients do not present till advanced cirrhosis with ascites.

## Serology

- Chronic HBV: presence of serum HBsAg and anti-HBcAg antibodies.
- Chronic HCV: presence of serum anti-HCV antibodies and HCV RNA by polymerase chain reaction (PCR).

## Macroscopy

- The liver may feel slightly firm due to fibrosis.

## Histopathology

- Portal inflammation is dominant and composed mostly of lymphocytes.
- Interface hepatitis ('piecemeal necrosis') refers to the extension of the portal inflammatory infiltrate into the hepatocytes at the limiting plate associated with hepatocyte degeneration.
- Lobular inflammation is usually focal and mild in chronic viral hepatitis (compare with acute viral hepatitis where it is the dominant site).
- Fibrosis is a marker of how advanced the disease is. Extensive bridging fibrosis through the liver terminates in cirrhosis.

► Note that all of these changes may be seen in chronic liver injury from a number of causes. Clues to a viral aetiology may be present, however, e.g. 'ground glass' hepatocytes in hepatitis B and portal lymphoid aggregates in hepatitis C.

## Prognosis

- Prognosis largely depends on the extent of fibrosis present on liver biopsy.
- Viral genotype is also important in hepatitis C.
- High risk of hepatocellular carcinoma, particularly with chronic HBV.

## Alcoholic liver disease

### Definition

- Liver disease due to excessive alcohol consumption. Three patterns of disease are recognized: **steatosis**, **alcoholic steatohepatitis (ASH)**, and **cirrhosis**.

### Epidemiology

- Extremely common.

### Pathogenesis

- Alcohol metabolism in the liver generates high levels of NADH which stimulates fatty acid synthesis and production of triglycerides, leading to steatosis.
- In some individuals, oxidative stress from metabolism of alcohol leads to hepatocyte injury and necroinflammatory activity (ASH).
- Ongoing necroinflammatory activity causes liver fibrosis which may progress to cirrhosis.

### Presentation

- Steatosis and mild ASH are usually asymptomatic, but are a common cause of mildly abnormal liver function tests.
- Severe alcoholic hepatitis following binge drinking causes malaise and fever with marked elevation of liver function tests. Jaundice may occur if there is marked loss of liver function.
- Alcoholic cirrhosis presents with complications of cirrhosis, e.g. ascites or ruptured oesophageal varices.

### Macroscopy

- Steatosis causes an enlarged soft greasy liver.
- ASH may cause a firm texture due to fibrosis in the liver.
- Cirrhosis causes diffuse nodularity of the liver.

### Histopathology

- Steatosis shows large droplets of fat in hepatocytes, which displace the nucleus to one side (macrovesicular steatosis).
- ASH shows ballooned hepatocytes which may contain Mallory's hyaline (clumps of dense pink material) and an inflammatory infiltrate rich in neutrophils. The fibrosis in ASH is typically pericellular, but eventually forms fibrous bridges.
- Cirrhosis shows diffuse replacement of the liver by nodules of regenerating hepatocytes surrounded by fibrous bands. Background steatosis and hepatitis may not be present.

### Prognosis

- Simple steatosis is fully reversible if alcohol consumption ceases.
- Alcoholic hepatitis may resolve with cessation of alcohol consumption or may progress to fibrosis and cirrhosis.
- Alcoholic cirrhosis has a poor prognosis, with 5-year survival rates of only 50%.

## Non-alcoholic fatty liver disease

### Definition

- The hepatic manifestation of the metabolic syndrome (central obesity, abnormal glucose tolerance, hyperlipidaemia). Non-alcoholic fatty liver disease (NAFLD) covers a range of conditions, including simple **steatosis** (fatty liver), **non-alcoholic steatohepatitis** (NASH), and **cirrhosis**.

### Epidemiology

- Very common and increasing in incidence due to rising obesity rates.
- Now the most common cause of abnormal liver function tests.
- Many cases of cirrhosis once thought to be cryptogenic are now thought to represent end-stage NAFLD.

### Aetiology

- Obesity and diabetes are the most common associations.
- Also associated with some drugs and parenteral nutrition.

### Pathogenesis

- Insulin resistance seems to be the key factor and is linked to obesity.
- Insulin resistance causes the accumulation of fat and hepatocyte injury.
- Inflammation in response to hepatocyte injury leads to fibrosis and eventually, cirrhosis in some individuals.

### Presentation

- Most cases are asymptomatic and discovered because of abnormal liver function tests.
- Occasional cases present with complications related to cirrhosis.

### Macroscopy

- The liver is enlarged, soft, and greasy.
- Cirrhotic livers are diffusely nodular.

### Histopathology

- Steatosis shows accumulation of fat within hepatocytes without significant inflammatory activity.
- NASH shows steatosis together with the presence of ballooned hepatocytes and neutrophils. Variable fibrosis may be present, depending on the stage of the disease.

► Note that these histological findings are essentially identical to those seen in alcoholic liver disease. Ruling out alcoholic liver disease can sometimes be difficult as many patients significantly under-report their alcohol intake.

### Prognosis

- Steatosis has a very low risk of progression to chronic liver disease.
- NASH progresses to cirrhosis in ~10–15% of cases over 8y.
- Patients with cirrhosis due to NAFLD generally have a better survival rate than patients with cirrhosis due to alcoholic liver disease.



## Autoimmune hepatitis

### Definition

- A liver disease due to an autoimmune response targeted against the liver.

### Epidemiology

- Uncommon.
- Typically affects middle-aged females.

### Aetiology

- Unknown for certain, but thought to be triggered by infection or drugs.

### Pathogenesis

- Current thinking suggests that liver damage from an infection or a drug causes genetically susceptible people to become sensitized to their liver and mount an immune response against it.

### Presentation

- Most cases are asymptomatic in the early stages, but may be diagnosed incidentally due to abnormalities of liver function tests.
- Some patients present late with symptoms and signs of chronic liver disease or terminal cirrhosis.
- ~25% of cases present suddenly with an episode of acute hepatitis with jaundice.
- Rarely, massive acute liver damage occurs and the patient presents with acute hepatic failure.

### Serology

- Serum IgG is usually raised.
- A variety of autoantibodies may be present, e.g. anti-nuclear antibodies, liver-kidney microsomal antibodies, and smooth muscle antibodies.

### Macroscopy

- Few macroscopic changes except in patients with cirrhosis or in cases of severe acute hepatitis with massive hepatocyte necrosis.

### Histopathology

- Chronic hepatitis pattern of injury with portal inflammation, interface hepatitis, lobular inflammation, and variable fibrosis.
- In contrast to chronic viral hepatitis, the interface hepatitis and lobular inflammation tend to be more prominent. Plasma cells are often a conspicuous component of the inflammatory cell infiltrate.

### Prognosis

- Most cases respond well to immunosuppressive therapy.
- Long-term prognosis is dependent on the extent of fibrosis in the liver at the time of diagnosis.

# Primary biliary cirrhosis

## Definition

- A chronic liver disease characterized by the autoimmune destruction of small intrahepatic bile ducts and the presence of anti-mitochondrial antibodies.

## Epidemiology

- Uncommon.
- Occurs most frequently in middle-aged women and is associated with other autoimmune conditions.

## Aetiology

- Unknown, but may be triggered by infections with organisms that show molecular mimicry to antigens present on the biliary epithelium.

## Pathogenesis

- Thought to be an autoimmune disease in which the immune system mounts an abnormal response to the biliary epithelium.

## Presentation

- Asymptomatic in its early stages, although may be picked up by elevated alkaline phosphatase levels.
- Patients presenting with symptoms usually do so with fatigue or pruritus due to the accumulation of bile salts.

## Serology

- >95% of cases are associated with the presence of anti-mitochondrial antibodies directed at a component of the pyruvate dehydrogenase enzyme complex located in the inner mitochondrial matrix.

## Macroscopy

- Early disease shows few macroscopic changes in the liver.
- In advanced disease, the liver is cirrhotic and bile-stained.

## Histopathology

- Earliest feature is the infiltration and destruction of interlobular bile ducts by lymphocytes and macrophages ('florid duct lesion'). The macrophages may coalesce into clusters and form granulomas.
- As the disease progresses, there is inflammation and destruction of hepatocytes at the edges of the portal tracts (interface hepatitis) which begins a sequence of periportal fibrosis → portal-portal bridging → cirrhosis.

## Prognosis

- Gradual progression towards cirrhosis over 15–20y.
- Ursodeoxycholic acid therapy decreases the rate of progression.

## Primary sclerosing cholangitis

### Definition

- A chronic liver disease characterized by inflammation and scarring in the biliary tree. Usually, the entire biliary tree is affected, but occasionally, only small interlobular bile ducts are affected (small duct primary sclerosing cholangitis [PSC]).

### Epidemiology

- Uncommon.
- Seen predominantly in young men with UC (~70% of patients with PSC also have UC).

### Aetiology

- Unknown, although there is a genetic link with certain HLA types.

### Pathogenesis

- Chronic biliary inflammation is followed by fibrotic scarring which narrows the affected bile ducts. Obstruction within the biliary system leads to progressive fibrosis within the liver which terminates in cirrhosis. Biliary stasis also promotes infection and stone formation.

### Presentation

- Asymptomatic in its early stages, but often picked up when elevated alkaline phosphatase levels are found in a patient known to have UC.

### Radiology

- Demonstration of strictures and dilations within the biliary tree on imaging is highly suggestive of PSC.

### Macroscopy

- Early PSC usually causes no macroscopic changes. Advanced disease causes a cirrhotic liver with bile staining. Fibrotic biliary strictures may be apparent in the major bile ducts.

### Histopathology

- Explanted liver specimens show fibrosis and inflammation in large bile ducts with inspissated bile and stones. There is a biliary pattern of cirrhosis with large irregular jigsaw-like nodules of hepatocytes.
- Liver biopsy specimens show variable features, depending on the biopsy site. If the biopsy is taken from an area unaffected by the primary disease, but distal to a large duct stricture, the liver shows features of duct obstruction (i.e. portal oedema with proliferation of bile ductules). If the biopsy comes from an area affected by PSC, then medium-sized bile ducts show periductal oedema and concentric fibrosis whilst small bile ducts are often completely absent.

### Prognosis

- Progressive liver disease eventually terminating in cirrhosis.
- ▶ Patients are at high risk of bile duct carcinoma which develops in ~20% of patients (📖 p. 130) and has a very poor prognosis.

# Wilson's disease

## Definition

- An inherited disorder of copper metabolism, leading to the accumulation of toxic levels of copper in the liver and brain.

## Epidemiology

- Uncommon.
- Most cases present in childhood or young adulthood; however, the diagnosis should be considered as a possible cause of liver disease presenting at any age.
- Males and females are equally affected.

## Genetics

- Autosomal recessive disorder due to mutations in the gene ATP7B which codes for a copper-transporting ATPase.
- ~100 different mutations have been described and the majority of patients are compound heterozygotes (i.e. they have two differently mutated alleles).

## Pathogenesis

- Possession of two mutated ATP7B alleles causes disruption of normal copper transport and accumulation of toxic levels of copper in hepatocytes and basal ganglia.

## Presentation

- Most patients present in childhood or early adulthood with chronic liver disease or cirrhosis.
- A small proportion of patients present in hepatic failure.
- About half of patients also develop neuropsychiatric symptoms due to copper accumulation in the brain, though this usually occurs after the liver disease presents.

## Macroscopy

- By the time of presentation, most patients have advanced disease and the liver is firm due to extensive fibrosis or cirrhotic.

## Histopathology

- Liver biopsies show a chronic hepatitis pattern with portal inflammation, scattered lobular inflammation, and variable amounts of fibrosis, depending on the stage of the disease.
- The diagnosis is strongly suggested by the presence of high levels of stainable copper or copper-associated protein in hepatocytes.

## Prognosis

- Progressive disease which terminates in cirrhosis if untreated.
- Lifelong treatment with metal chelating agents prevents this progression if the diagnosis is made early enough.
- Risk of hepatocellular carcinoma is low.

## Hereditary haemochromatosis

### Definition

- An inherited disorder characterized by increased intestinal absorption of iron, leading to iron overload in multiple organs, particularly the liver, and sometimes leading to organ damage.

### Epidemiology

- Genetic prevalence of the mutated gene is 0.4% in white races, though the clinical penetrance is much lower.
- Males and females are affected equally, though women usually present later in life due to menstrual iron loss.

### Genetics

- Autosomal recessive disorder caused by mutations of the HFE gene on chromosome 6p.
- HFE encodes an iron regulatory hormone called **hepcidin**.
- Most common mutation is a missense mutation at codon 282, causing a cysteine residue to be switched for a tyrosine (C282Y).

### Pathogenesis

- Hepcidin controls plasma iron concentrations by inhibiting iron export by ferroportin from duodenal enterocytes and macrophages.
- Deficiency of hepcidin results in raised plasma iron concentrations and accumulation in multiple organs, including the liver, pancreas, heart, joints, and pituitary.

### Presentation

- Early symptoms are non-specific and include fatigue and arthropathy.
- Later, there may be skin pigmentation, cirrhosis, hypogonadism, cardiac failure, and diabetes mellitus.
- If transferrin saturation and serum ferritin are raised, then testing for the C282Y mutation should be performed.

### Macroscopy

- Advanced cases cause diffuse nodularity due to cirrhosis.

### Histopathology

- The earliest histological change is the accumulation of iron within periportal hepatocytes, highlighted by Perl's stain.
- As the disease progresses, iron accumulates within hepatocytes throughout the liver lobules, associated with expansion of portal tracts by fibrosis.
- Eventually, bridging fibrosis occurs which terminates in cirrhosis.

### Prognosis

- Overall mortality is not higher in patients with timely diagnosis and adequate iron depletion therapy.
- ~5% of men and 1% of women develop cirrhosis. This has a worse prognosis, even with treatment, and carries a significant risk of hepatocellular carcinoma (📖 p. 127).

# Cirrhosis

## Definition

- Irreversible replacement of the normal liver architecture by bands of fibrous tissue separating nodules of regenerating hepatocytes.

## Epidemiology

- Common and increasing in incidence due to alcohol and obesity.

## Aetiology

- Alcohol, chronic viral hepatitis, and NAFLD are the most common causes.
- Less commonly PBC, PSC, autoimmune hepatitis (AIH), Wilson's disease, and haemochromatosis.
- In some cases, the cause remains unclear (cryptogenic cirrhosis).

## Pathogenesis

- Persistent liver injury causes Kupffer cells lining the vascular sinusoids to release cytokines which activate hepatic stellate (Ito) cells.
- Activated stellate cells proliferate and secrete large quantities of dense collagen, leading to irreversible liver fibrosis and hepatocyte loss.
- Cirrhosis causes a number of functional defects: reduced synthesis of coagulation factors; low glycogen reserves; reduced clearance of organisms by Kupffer cells; portal hypertension with hypersplenism and oesophageal varices; splanchnic vasodilation → decreased renal blood flow → secondary hyperaldosteronism → ascites.

## Presentation

- Non-specific symptoms of tiredness and malaise.
- Signs of chronic liver disease are usually present on clinical examination and liver function tests are usually abnormal.
- Patients often present with a complication related to the presence of cirrhosis, e.g. upper gastrointestinal haemorrhage.

## Macroscopy

- The liver may be normal in size, enlarged, or shrunken.
- The cut surface has a firm texture and shows diffuse nodularity.

## Histopathology

- The entire liver is replaced by nodules of regenerating hepatocytes surrounded by fibrous bands.
- The fibrous bands contain a variable inflammatory infiltrate and reactive bile ductular proliferation.
- In some cases, the features may point to a particular aetiology.

## Prognosis

- Generally poor, with a high risk of significant complications such as infections (including bacterial peritonitis), upper gastrointestinal bleeding, renal failure, and hepatocellular carcinoma.
- ▶ Development of complications may tip the patient into terminal hepatic failure characterized by deep jaundice, severe coagulopathy, hepatic encephalopathy, and high risk of mortality.

## **Benign liver lesions**

### **Haemangioma**

- Most common tumour of the liver.
- Macroscopically, well-circumscribed red tumours with a spongy texture due to the numerous vessels within them.
- Microscopically, composed of numerous dilated blood vessels lined by bland endothelial cells.
- Benign lesions which are usually asymptomatic and require no treatment.

### **Hepatic adenoma**

- Rare tumour seen almost exclusively in young women of reproductive age.
- Thought to be associated with oral contraceptive use.
- Macroscopically, solitary lesions, often >10cm in size, with a softer consistency and a lighter colour than the adjacent liver.
- Microscopically, hepatocytes arranged in plates 1–3 cells thick. Large vessels are often present within the lesion, but portal tracts are absent.
- Surgical resection is often performed to prevent the potentially fatal complication of rupture and haemoperitoneum.

### **Focal nodular hyperplasia**

- Benign non-neoplastic lesion usually seen in young women of reproductive age.
- Thought to represent a localized area of liver hyperplasia in response to changes in blood flow associated with a pre-existing arterial malformation.
- Macroscopically, a well-defined nodular area with a lighter colour than the adjacent liver. Most lesions have a characteristic central scar.
- Microscopically, nodules of hepatocytes separated by fibrous stroma containing bile ductules. Large thick-walled vessels are very often present and a helpful diagnostic clue.
- Benign and not associated with a risk of haemorrhage.

### **Biliary hamartoma**

- Thought to be a ductal plate malformation.
- Macroscopically, it is a small (<5mm) irregular grey lesion of the liver which may be multifocal.
- Microscopically, it is composed of small irregular ductules embedded in a dense fibrous stroma. Inspissated bile may be present within the ductules.

### **Bile duct adenoma**

- May not be a true neoplasm, but rather a reactive proliferation of ductular structures.
- Macroscopically, small (but usually larger than biliary hamartomas) firm white lesions which are often subcapsular.
- Microscopically, small uniform ductules which are more closely packed than a biliary hamartoma. Bile is not present in the ductules.

# Hepatocellular carcinoma

## Definition

- A malignant epithelial neoplasm of the liver derived from hepatocytes.

## Epidemiology

- Common worldwide, but with a wide geographical variation.
- Incidence figures largely parallel rates of infection with HBV, making hepatocellular carcinoma (HCC) particularly common in part of Africa and Asia.

## Aetiology

- HCC usually arises on a background of liver cirrhosis.
- Chronic hepatitis B and haemochromatosis are particularly carcinogenic substrates.
- Dietary ingestion of aflatoxins produced by *Aspergillus* fungi are also known to be potent liver carcinogens.

## Carcinogenesis

- Loss of function of tumour suppressor genes such as TP53 is common.
- Activating mutations of oncogenes appear to be rare.
- Hepatitis B X gene product disrupts p53 function and inhibits nucleotide excision repair.

## Presentation

- Presents late with non-specific weight loss and abdominal pain.
- Known cirrhotics may be diagnosed following investigation of a rising serum alpha-fetoprotein or on ultrasound surveillance.

## Macroscopy

- Expansile tumour mass in the liver, often with satellite deposits.
- Tumour may have a green tinge due to the production of bile.
- Distinguishing tumour deposits from cirrhotic nodules can be difficult.

## Histopathology

- Classical HCC is composed of epithelial cells resembling hepatocytes which typically grow in trabeculae that resemble thickened liver cell plates. Bile production may be seen by the tumour.
- Fibrolamellar HCC is a rare, but distinctive, variant which typically arises in young patients without background cirrhosis. Histologically, the tumour is composed of nests of very large neoplastic cells with abundant granular pink cytoplasm separated by dense fibrous bands.

## Prognosis

- Generally very poor, with 5-year survival rates <5%.
- Fibrolamellar HCC has a slightly better prognosis with 5-year survival rates ~60%.



## **Intrahepatic cholangiocarcinoma**

### **Definition**

- A malignant epithelial neoplasm arising in the liver composed of cells resembling bile ducts.

### **Epidemiology**

- Rare in most populations.

### **Aetiology**

- Liver flukes (*Clonorchis sinensis* and *Opisthorchis viverrini*).
- Hepatolithiasis.
- PSC (📖 p. 122).
- Exposure to Thorotrast (a contrast medium used from 1930 to 1955).
- Biliary malformations.

### **Carcinogenesis**

- Mutations of RAS and TP53 are the most common genetic abnormalities.

### **Presentation**

- Most present late as they can grow to a large size within the liver before causing symptoms of malaise, weight loss, and abdominal pain.
- Tumours infiltrating the hilar region of the liver may present with obstructive jaundice.

### **Macroscopy**

- The liver contains large confluent nodules of grey white tumour, often with satellite deposits.
- The background liver is usually non-cirrhotic.

### **Histopathology**

- Adenocarcinomas in which the infiltrating malignant epithelial cells form glandular and papillary structures.
- A typical feature is the presence of abundant fibroblastic stroma.

### **Prognosis**

- Generally poor with 5-year survival rates of 40–50%, depending on the stage.

# Cholecystitis

## Definition

- Inflammation of the gallbladder.

## Epidemiology

- Very common.

## Aetiology

- Most cases are caused by gallstones (calculous cholecystitis).
- Acalculous cholecystitis also occurs, particularly in the elderly.

## Pathogenesis

- Thought to be due to chemical injury to the mucosa caused by bile.
- Biliary stasis may be caused by obstruction of the gallbladder outlet by a gallstone or poor gallbladder motility.

## Presentation

- Biliary colic, characterized by severe upper abdominal pain which resolves spontaneously after several hours.
- Acute cholecystitis is a more severe illness with prolonged upper abdominal pain, fever, and tachycardia.

## Macroscopy

- The gallbladder wall is thickened and the mucosa may be friable.
- Gallstones are usually present.

## Histopathology

- Acute cholecystitis shows oedema, acute inflammatory cells, and granulation tissue.
- Chronic cholecystitis shows muscular hypertrophy and fibrosis, mild chronic inflammation, and the presence of mucosal diverticula herniating through the muscular layer (Rokitansky–Aschoff sinuses).
- Xanthogranulomatous cholecystitis is a variant of chronic cholecystitis in which sheets of macrophages and fibroblasts are present, probably in reaction to a ruptured Rokitansky–Aschoff sinus.

## Prognosis

- Most patients with calculous cholecystitis are cured by cholecystectomy.

## Extrahepatic bile duct carcinoma

### Definition

- A malignant epithelial tumour arising in an extrahepatic bile duct.

### Epidemiology

- Rare with no geographical variations in incidence.

### Aetiology

- PSC.
  - Liver fluke infestation.
  - Choledochal cysts.
- ▶ Choledocholithiasis does not seem to be relevant.

### Carcinogenesis

- Mutations in KRAS and TP53 are described.

### Presentation

- Obstructive jaundice.
- Superimposed cholangitis may cause fevers and rigors.

### Macroscopy

- The involved bile duct contains a tumour which may be polypoid, stenosing, or diffusely infiltrative.

### Histopathology

- Most are well or moderately differentiated adenocarcinomas in which the infiltrating malignant epithelial cells form glandular structures resembling biliary ducts.

### Prognosis

- 5-year survival in patients with resectable tumours and clear surgical margins is in the order of 20–40%.
- Tumours arising on a background of PSC have a particularly poor outlook with 5-year survival rates of <10%.

# Pancreatic pathology

- Pancreatic malformations 132
- Acute pancreatitis 133
- Chronic pancreatitis 134
- Pancreatic ductal carcinoma 135
- Pancreatic endocrine tumours 136
- Pancreatic cystic tumours 138
- Acinar cell carcinoma 139

## **Pancreatic malformations**

### **Ectopic pancreas**

- Common developmental anomaly in which pancreatic tissue is located outside the usual position of the pancreas.
- The duodenum is the most common site, but it can be seen in the jejunum and ileum and within a Meckel's diverticulum (📖 p 84).
- Most cases are incidental findings, but some patients present with symptoms relating to bleeding or obstruction.

### **Pancreas divisum**

- Common developmental anomaly in which the dorsal and ventral pancreatic buds fail to fuse.
- The duct of Santorini becomes the dominant ductal system of the pancreas. As this duct drains into the duodenum via the smaller minor papilla, there is a tendency to stasis of pancreatic secretions and susceptibility to pancreatitis.
- Usually asymptomatic and discovered incidentally on imaging, though some patients may present with pancreatitis in adulthood.

### **Annular pancreas**

- Rare developmental anomaly in which the dorsal and ventral pancreatic buds fuse around the duodenum.
- The ring of pancreas can cause obstruction to the duodenum.
- Most patients present around 1y of age with vomiting and abdominal distension after meals.

# Acute pancreatitis

## Definition

- Acute inflammation of the pancreas and peripancreatic tissues.

## Epidemiology

- Uncommon.

## Aetiology

- Gallstones and alcohol account for the majority of cases.
- Other causes include abdominal trauma, endoscopic retrograde cholangiopancreatography (ERCP), drugs, hypercalcaemia, pancreas divisum, and viral infection.
- Many cases are idiopathic.

## Pathogenesis

- Injury to the pancreas leads to the release and activation of digestive enzymes which cause necrosis of pancreatic and peripancreatic tissue.
- Exudation of plasma into the retroperitoneal space leads to hypovolaemia and cardiovascular instability.
- Paralytic ileus may also occur as a reaction to extensive inflammation occurring in the vicinity of the bowel.

## Presentation

- Sudden onset of severe upper abdominal pain radiating to the back, associated with nausea, vomiting, and fever.
- Hypotension is often present which, in severe cases, causes shock.

## Biochemistry

- A significantly raised serum amylase is virtually diagnostic of acute pancreatitis in the correct clinical setting.

## Macroscopy

- The pancreas is swollen and soft.
- White flecks of fat necrosis are present in peripancreatic tissues.
- In severe cases, there is haemorrhage into the necrotic pancreas.

## Histopathology

- Acute inflammation, oedema, and focal necrosis within the pancreas.
- Surrounding peripancreatic tissue shows fat necrosis.
- Severe cases show widespread necrosis and haemorrhage into the gland.

## Prognosis

- Many cases are mild and resolve with supportive treatment.
- Severe cases can be life-threatening and require organ support on an intensive care unit.
- Superadded infection of the necrotic pancreatic tissue is an ominous complication, often leading to disseminated intravascular coagulation and multiple organ failure.
- Pancreatic pseudocyst (a collection of fluid within the region of the pancreas) is a common late complication.

## Chronic pancreatitis

### Definition

- A chronic inflammatory process of the pancreas, leading to irreversible loss of pancreatic function.
- ▶ Chronic pancreatitis can closely mimic pancreatic carcinoma clinically, radiologically, and pathologically.

### Epidemiology

- Uncommon.

### Aetiology

- Almost all cases are associated with alcohol abuse.
- A small proportion is thought to be autoimmune in origin.

### Pathogenesis

- Chronic inflammation in the pancreas leads to the replacement of functional pancreatic tissue by fibrous scar tissue.

### Presentation

- Persistent upper abdominal pain and weight loss.
- Steatorrhea and diabetes mellitus occur late once most of the gland is destroyed.

### Macroscopy

- The pancreas is replaced by firm fibrous tissue within which are dilated ducts and areas of calcification.
- ▶ The scarred mass is so firm, it can closely mimic carcinoma macroscopically.

### Histopathology

- The pancreas shows a chronic inflammatory cell infiltrate with scarring and loss of exocrine tissue. The endocrine tissue is typically spared until late in the disease. Large ducts are dilated and contain inspissated secretions. Calcification is also common. ▶ Small residual atrophic ducts set in a fibrous background can closely mimic infiltrating pancreatic carcinoma.
- A recently recognized variant of chronic pancreatitis has been described in which there is a prominent periductal and perivenular chronic inflammatory cell infiltrate rich in IgG4+ plasma cells. Patients often have raised serum IgG4 levels. This variant is thought to be autoimmune in nature.

### Prognosis

- Alcoholic chronic pancreatitis tends to be associated with a fairly poor outcome. Treatment is supportive only and most patients will have other alcohol-related pathology.
- The outlook is better for patients with autoimmune pancreatitis as this responds to steroid therapy.

# Pancreatic ductal carcinoma

## Definition

- A malignant epithelial tumour arising in the pancreas composed of infiltrating duct-like structures.

## Epidemiology

- Most common type of pancreatic neoplasm.
- Usually seen in people >60y and slightly more commonly in men.
- Incidence in developed countries ranges from 1–10 per 100,000.

## Aetiology

- Smoking is the main recognized risk factor.

## Carcinogenesis

- Activating mutations of KRAS.
- Loss of function of TP53, P16, and DPC4.

## Presentation

- Persistent upper abdominal pain and profound weight loss.
- Tumours in the head may cause obstructive jaundice.
- Sudden onset of diabetes mellitus is also a suspicious finding.

## Macroscopy

- A poorly defined, firm tumour mass is present within the pancreas.
- Most arise within the head, but they can occur anywhere in the pancreas.

## Histopathology

- Most pancreatic carcinomas are well to moderately differentiated adenocarcinomas in which the infiltrating malignant cells form well-developed glandular structures.
- A typical feature is the presence of abundant fibroblastic stroma around the infiltrating glands.
- Perineural invasion is also common and probably accounts for the high rates of peripancreatic tumour extension.

## Prognosis

- Extremely poor with 5-year survival rates of <5%.



## Pancreatic endocrine tumours

### Definition

- A group of epithelial tumours of the pancreas showing endocrine differentiation. Tumours may be functioning or non-functioning, depending on whether a syndrome of inappropriate hormone secretion is present.

### Epidemiology

- Rare tumours accounting for ~2% of all pancreatic tumours.
- Peak incidence between 30–60y.

### Aetiology

- Unknown in sporadic cases.
- ~15% associated with multiple endocrine neoplasia (MEN)-1.

### Genetics

- Losses at chromosome 1 and 11q and gains of 9q appear to be early events.
- Accumulation of further alterations is associated with malignant behaviour.

### Presentation

- Functioning tumours present with features related to excess hormone production, e.g. hypoglycaemia (insulin-producing tumours), recurrent duodenal ulceration (gastrin-producing tumours), necrolytic migratory erythema (glucagon-producing tumours).
- Non-functioning tumours are either picked up incidentally on imaging or present when they grow large enough to produce symptoms of local disease or metastasis.

### Macroscopy

- Most are well-demarcated tumours within the pancreas.

### Cytopathology

- Fine needle aspiration (FNA) smears are cellular and composed of a monotonous population of cells present singly, in loose clusters, or pseudorosettes.
- The nuclei usually have a distinct granular chromatin pattern ('salt-and-pepper').

### Histopathology

- Most tumours are composed of cells with granular cytoplasm, forming solid nests, trabeculae, glands, or rosettes.
- Immunostaining confirms the endocrine nature of the cells with reactivity for markers CD56, chromogranin, and synaptophysin.

### Prognosis

- Often difficult to predict with certainty.

- All tumours should be considered potentially malignant and long-term follow-up is essential as metastases may develop many years after removal of the primary lesion.

### **Clinicopathological classification of pancreatic endocrine tumours**

#### **Well-differentiated endocrine tumour**

Benign behaviour: confined to the pancreas, non-angioinvasive, <2cm in size,  $\leq 2$  mitoses/10hpf,  $\leq 2\%$  Ki-67 positive cells/10hpf.

Uncertain behaviour: confined to the pancreas and one or more of the following features —  $\geq 2$ cm in size, 2–10 mitoses/10hpf,  $>2\%$  Ki-67 positive cells/10hpf, angioinvasion, perineural invasion.

#### **Well-differentiated endocrine carcinoma**

Histologically low-grade, but with evidence of gross local invasion and/or metastases.

#### **Poorly differentiated endocrine carcinoma**

Histologically high-grade with  $>10$  mitoses/10hpf.

## **Pancreatic cystic tumours**

### **Intraductal papillary mucinous neoplasm**

- A grossly visible, mucin-producing tumour that grows within the pancreatic ductal system.
- Most arise within the head of pancreas in men.
- Macroscopically, there are mucin-filled cysts within the pancreas that communicate with the duct system.
- Histologically, the cysts are lined by mucin-secreting columnar epithelial cells which form papillary projections into the cyst. The epithelial cells may show a range of atypia from low to high grade. Invasive carcinoma can arise within this lesion.

### **Mucinous cystic neoplasms**

- A range of lesions, most of which are benign.
- Almost all occur in women and present with symptoms of an abdominal mass.
- Macroscopically, they are well-circumscribed cystic tumours with large locules containing mucoid material. The cysts do not communicate with the pancreatic ductal system.
- Histologically, the cysts are lined by mucus-secreting columnar epithelial cells beneath which there is a densely cellular, ovarian-like stroma. The epithelial component may show a range of atypia from low to high grade. Invasive carcinomas can arise within these lesions.

### **Serous cystic neoplasms**

- A range of lesions, the majority of which are benign.
- Almost all occur in women and present with symptoms of an abdominal mass.
- The most common type is the **serous microcystic adenoma** which gives rise to a well-circumscribed pancreatic mass containing numerous small cysts with a central scar. Histologically, the small cysts are lined by cuboidal cells with a round nucleus and clear cytoplasm due to the accumulation of glycogen.

### **Solid pseudopapillary neoplasm**

- A neoplasm of the pancreas which often shows cystic change.
- Occurs mostly in young women with symptoms of an abdominal mass.
- The tumours may occur anywhere in the pancreas as a solid mass with cystic areas and haemorrhage.
- Histologically, the tumour is composed of uniform round cells which form sheets and cords. The cells tend to be poorly cohesive and fall apart, creating pseudopapillary and cystic areas.
- The tumours generally have very low-grade biological behaviour with most patients remaining tumour-free many years after resection.

## Acinar cell carcinoma

### Definition

- A malignant epithelial neoplasm of the pancreas demonstrating evidence of enzyme production by the neoplastic cells.

### Epidemiology

- Rare tumour, accounting for ~1% of all pancreatic tumours.
- Most occur in older adults.

### Aetiology

- Unknown.

### Carcinogenesis

- Abnormalities have been described in the APC/ $\beta$ -catenin pathway.
- Genetic mutations typically found in ductal adenocarcinoma are absent.

### Presentation

- Non-specific symptoms of abdominal pain, weight loss, nausea, and diarrhoea.
- ~10% of patients have a syndrome of multifocal fat necrosis and polyarthralgia due to lipase secretion.

### Macroscopy

- Large well-demarcated soft tan tumour arising within the pancreas.
- Extension outside the pancreas may be present.

### Histopathology

- Cellular tumours composed of neoplastic epithelial cells growing in sheets, trabeculae, and acini.
- Some cells have abundant eosinophilic finely granular cytoplasm.
- The cells show positive immunoreactivity for lipase, trypsin, and chymotrypsin.

### Prognosis

- Aggressive malignant tumours.
- Median survival 18 months from diagnosis with 5-year survival rates of <10%.

*This page intentionally left blank*

# Renal pathology

- Chronic kidney disease 142
- Acute renal failure 144
- Hypertensive nephropathy 145
- Diabetic nephropathy 146
- Minimal change disease 147
- Focal segmental glomerulosclerosis 148
- Membranous nephropathy 149
- IgA nephropathy 150
- Acute tubular injury 151
- Acute drug-induced interstitial nephritis 152
- Anti-glomerular basement membrane disease 153
- Reflux nephropathy 154
- Obstructive nephropathy 155

## Chronic kidney disease

### Definition

- A progressive and irreversible decline in renal function which is classified into five stages according to the estimated glomerular filtration rate (eGFR) (Table 9.1).

### Epidemiology

- Common, largely due to the high incidence of diabetes and vascular disease of the kidney.

### Aetiology

- Diabetic nephropathy and hypertensive nephropathy are the most common causes.
- Other causes include reflux nephropathy, obstructive nephropathy, IgA nephropathy (IgAN), focal segmental glomerulosclerosis (FSGS), membranous nephropathy, systemic lupus erythematosus (SLE), myeloma, amyloidosis, drugs, gout, and adult polycystic kidney disease (APKD).

### Pathogenesis

- A reduction in nephron mass below a certain level is known to cause progressive renal damage that is independent of the activity of the underlying disease.
- The sequence of events causing progressive renal damage is thought to be glomerular hyperfiltration → glomerular hypertension → glomerular injury → glomerulosclerosis → tubulointerstitial fibrosis.
- Transforming growth factor (TGF)- $\beta$  appears to be a key mediator in stimulating renal scarring.

### Presentation

- Early disease is asymptomatic and will only be picked up if eGFR is measured in patients known to be at risk, e.g. diabetics, hypertensives.
- With progression, patients feel tired and develop bony pain.
- Some patients present in end-stage renal failure with marked fluid overload and metabolic derangement requiring immediate renal replacement therapy.

### Biochemistry

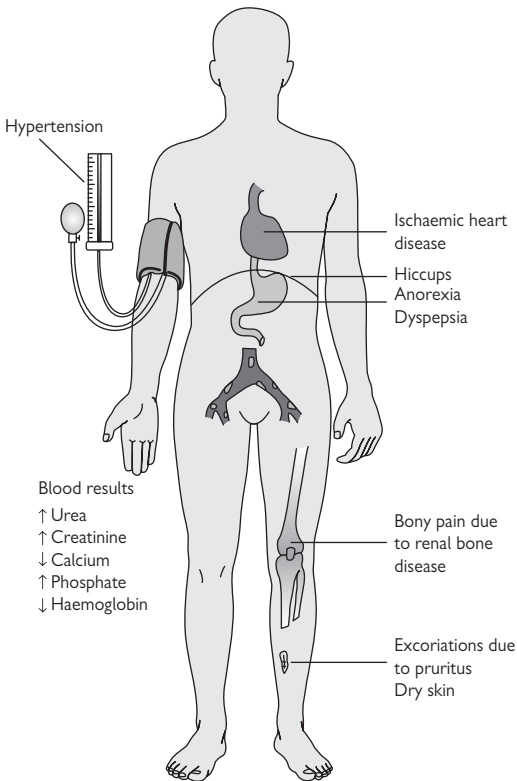
- $\uparrow$  Urea and creatinine due to impaired excretion of waste products.
  - $\downarrow$  Calcium due to lack of active calcitriol.
  - $\uparrow$  Phosphate due to impaired excretion of phosphate.
  - Secondary hyperparathyroidism due to hypocalcaemia.
  - $\downarrow$  Haemoglobin due to reduced erythropoietin secretion.
- Note that loss of acid-base and sodium/potassium balance occurs late in chronic kidney disease.

### Complications

- High incidence of cardiovascular disease due to a combination of hypertension, vascular calcification, and hyperlipidaemia.
- Derangement of calcium and phosphate metabolism leads to renal bone disease which is a complex mixture of hyperparathyroid bone disease, osteomalacia, and osteoporosis (Fig. 9.1).

**Table 9.1** Stages and prevalence of chronic kidney disease

Stage	Description	eGFR (mL/min/1.73 <sup>2</sup> )	Prevalence (%)
1	Normal or ↑ GFR	>90	2
2	Mild ↓ GFR	60–89	3
3	Moderate ↓ GFR	30–59	8
4	Severe ↓ GFR	15–29	0.35
5	End-stage renal failure	<15	0.25



**Fig. 9.1** Symptoms and signs of advanced chronic renal failure. Reproduced with permission from *Clinical Pathology*, Carton, Daly, and Ramani, Oxford University Press, p. 208, Figure 10.4.



## Acute renal failure

### Definition

- A significant deterioration in renal function occurring over hours or days.

### Epidemiology

- Common.
- Often occurs as a complication of a pre-existing illness causing circulatory disturbance.

### Aetiology

- **Pre-renal:** hypoperfusion, e.g. hypovolaemia, sepsis.
- **Renal** ('intrinsic'): acute tubular injury, acute drug-induced interstitial nephritis, anti-glomerular basement membrane disease, small vessel vasculitis (📖 p. 350), haemolytic uraemic syndrome (HUS) (📖 p. 100), thrombotic thrombocytopenic purpura (TTP) (📖 p. 265), severe hypertension.
- **Post-renal:** bilateral obstruction (or obstruction to a single kidney).

▶ By far the most common causes are hypoperfusion and acute tubular injury.

### Pathogenesis

- Sudden damage to the kidneys causes an abrupt deterioration in renal function.

### Presentation

- Most cases are heralded by the onset of oliguria (passing small volumes of urine), though some cases may produce few symptoms or signs.
- Very severe cases cause marked pulmonary oedema, encephalopathy, and pericarditis.

### Biochemistry

- ↑ Serum urea and creatinine are the hallmarks.
  - Hyperkalaemia and metabolic acidosis are also commonly present.
- ▶▶ Severe hyperkalaemia is pro-arrhythmic and can lead to a cardiac arrest, so must be treated promptly.

### Prognosis

- Pre-renal and post-renal acute renal failure (ARF) may be reversible if treated promptly by restoring circulating volume or relieving obstruction.
- Intrinsic forms of ARF usually require dialysis while the underlying cause is treated and renal function recovers.

# Hypertensive nephropathy

## Definition

- Chronic kidney disease thought to be due to hypertension.

## Epidemiology

- A common causes of chronic kidney disease.

## Aetiology

- Hypertension.

## Pathogenesis

- Two pathophysiological theories have been suggested, which may not be mutually exclusive.
- The first suggests that narrowing of arterioles causes glomerular ischaemia and scarring.
- The second suggests that glomerular hypertension leads to glomerular hyperfiltration and progressive glomerulosclerosis.

## Presentation

- Renal dysfunction and proteinuria in a longstanding hypertensive in the absence of other causes of renal disease.
- Other signs of hypertension may be present, e.g. left ventricular hypertrophy.

## Macroscopy

- Both kidneys are shrunken with finely granular cortical surfaces.

## Histopathology

- Hyaline deposits are seen in the walls of afferent arterioles.
- Interlobular and larger arteries show medial hypertrophy and intimal thickening.
- Glomeruli may show wrinkling and shrinkage followed by scarring of the whole tuft or enlargement of the tuft followed by segmental scarring.
- This constellation of pathological features is often referred to as **nephrosclerosis**, a term simply meaning hardening of the kidney.

► Note that the presence of nephrosclerosis is not specific for hypertensive nephropathy as identical changes can be seen with ageing and in diabetes. Nevertheless, these features on a renal biopsy support a diagnosis of hypertensive nephropathy provided the clinical picture is compatible.

## Prognosis

- As with all forms of chronic kidney disease, there is a tendency to progressive disease.
- The decline in renal function can be slowed by aggressive control of blood pressure.

## Diabetic nephropathy

### Definition

- Chronic kidney disease caused by diabetes mellitus.

### Epidemiology

- A common cause of chronic kidney disease.

### Aetiology

- Diabetes mellitus.
- Only 30–40% of diabetics develop nephropathy so other factors are involved.

### Pathogenesis

- High glucose levels cause endothelial damage in capillaries of the glomeruli, leading to glomerulosclerosis and nephron loss.

### Presentation

- Onset of proteinuria in a patient with diabetes mellitus.
- Typically, this starts as microalbuminuria, but progresses to overt proteinuria which may be heavy enough to cause the nephrotic syndrome.
- Hypertension is invariably present.

### Histopathology

- Diffuse increase in mesangial matrix (glomerulosclerosis) which may form nodules (Kimmelsteil–Wilson nodules).
- Thickened glomerular basement membranes.
- Hyalinization of afferent and efferent arterioles.
- Tubulointerstitial fibrosis proportional to the degree of glomerular damage.

► Note that renal biopsy is not necessary to confirm a diagnosis of diabetic nephropathy provided the clinical picture is typical. Biopsy is usually reserved for atypical cases where an alternative diagnosis may be possible.

### Immunofluorescence

- Linear deposition of IgG in glomerular and tubular basement membranes may be seen.

### Electron microscopy

- Diffuse glomerular basement membrane thickening and expansion of the mesangial matrix is seen.
- No immune complexes are present.

### Prognosis

- Gradual deterioration in renal function.
- Patients with severe hypertension and marked proteinuria fare worse.
- Control of blood pressure is the cornerstone of slowing the disease process.

## Minimal change disease

### Definition

- A glomerulopathy characterized clinically by the nephrotic syndrome and histologically by glomeruli that appear normal by light microscopy.

### Epidemiology

- Uncommon.
- Usually arises in children, with a peak incidence from 2–6y, but can be seen in adults too.

### Aetiology

- Unknown for certain, but current evidence suggests it is caused by an immune dysfunction.
- Minimal change disease (MCD) following drug administration, bee stings, and venom exposure is well documented.

### Pathogenesis

- The podocyte is thought to be the key cell involved in MCD.
- Normal podocyte function is lost such that the glomerular filtration barrier becomes abnormally permeable to proteins.

### Presentation

- Nephrotic syndrome.

### Light microscopy

- By definition, the glomeruli appear normal by light microscopy.

### Immunofluorescence

- No specific immune deposition is present.

### Electron microscopy

- Podocyte foot processes show widespread simplification and effacement.
- No immune complexes are present.

### Prognosis

- Complete recovery usually occurs in MCD, particularly in children.
- ▶ Adults with steroid-resistant disease should be carefully monitored as they may turn out to have FSGS (📖 p. 148) which was not apparent on biopsy due to the focal nature of that condition.

## Focal segmental glomerulosclerosis

### Definition

- A primary glomerulopathy characterized histologically by sclerosis involving some, but not all, glomeruli (focal) and affecting only a portion of the glomerular tuft (segmental).

► Note that segmental glomerulosclerosis is merely a marker of glomerular injury; *it can be seen in many contexts and is not pathognomic of FSGS*. Careful exclusion of other known causes of segmental glomerulosclerosis is, therefore, essential before making a diagnosis of FSGS as this labels the patient with a disease expected to rapidly progress to end-stage renal failure.

### Epidemiology

- Uncommon.

### Aetiology

- Unknown, though recurrence of the disease in transplanted kidneys suggests a circulating factor.
- A rare inherited form of the disease also exists.

### Pathogenesis

- New studies suggest the podocyte is the primary source of damage.
- Podocyte injury causes heavy proteinuria and is followed by scarring of the glomerulus and rapidly progressive renal disease.

### Presentation

- Nephrotic syndrome.

### Light microscopy

- Involved glomeruli show collapse of a segment of the tuft and replacement by sclerosis.
- The sclerotic segment often shows adhesion to the overlying epithelial cells of Bowman's space.
- The glomerulosclerosis is usually accompanied by tubulointerstitial fibrosis around the involved glomerulus.

### Immunofluorescence

- Non-specific entrapment of IgM and C3 may be seen in the areas of sclerosis.

### Electron microscopy

- Podocyte foot process effacement is present.
- There are no immune deposits.

### Prognosis

- Virtually all cases of FSGS are progressive, with most patients reaching end-stage renal failure within a few years of diagnosis.

# Membranous nephropathy

## Definition

- A glomerulopathy caused by diffuse global subepithelial immune deposits within glomeruli.

## Epidemiology

- Uncommon.

## Aetiology

- Most cases are idiopathic in which the immune complexes are thought to develop *in situ*. The antigen in these cases is unidentified.
- Some cases are secondary to other conditions, including malignancies, drugs, infections, and SLE. In these cases, the immune complexes probably form elsewhere and circulate to the kidneys where they are deposited within the glomeruli.

## Pathogenesis

- Immune complexes within the glomerulus disrupt the normal filtration barrier, causing heavy proteinuria.

## Presentation

- Nephrotic syndrome.

## Light microscopy

- All of the glomeruli have thickened rigid capillary loops.
- Silver staining shows 'holes' in the glomerular basement membrane, which represent the immune deposits and 'spikes' which represent the glomerular basement membrane reaction to the deposits.
- More advanced cases may also show tubulointerstitial fibrosis.

## Immunofluorescence

- By definition, granular deposits of IgG and C3 are present diffusely along the capillary loops.
- If deposits of IgA, IgM, and C1q are also present, then membranous nephropathy secondary to SLE should be considered.

## Electron microscopy

- Subepithelial electron dense immune deposits are present with a varying surrounding basement membrane reaction.
- Podocytes show diffuse foot process effacement.

## Prognosis

- About one third of patients develop progressive disease.

## IgA nephropathy

### Definition

- A glomerulopathy caused by dominant or co-dominant deposition of IgA in glomeruli.

### Epidemiology

- The most common glomerulopathy worldwide.

### Aetiology

- Unknown, though IgAN can recur in a transplanted kidney, suggesting a systemic basis.
- One hypothesis is that an abnormal mucosal immune system produces a form of IgA which is resistant to breakdown, enters the circulation, and is deposited in glomeruli.

### Pathogenesis

- Deposition of IgA in the mesangium disrupts normal glomerular function, leading to leakage of blood and protein into the urine.

### Presentation

- Haematuria (microscopic or macroscopic) and proteinuria.

### Light microscopy

- IgAN can cause a number of changes in the glomeruli, ranging from mild mesangial expansion only to focal and diffuse proliferative lesions.
- Crescents may be seen in the most severe cases.

### Immunofluorescence

- By definition, there is dominant or co-dominant staining with IgA in the mesangial region of the glomeruli.

### Electron microscopy

- Electron dense immune deposits are present in the mesangial areas of glomeruli.

### Prognosis

- About one third of patients develop progressive renal disease.
- A number of clinical features can help predict the risk of progression (proteinuria, hypertension, renal function).
- The Oxford classification of IgAN has shown that four histopathological features also provide independent prognostic value in predicting the outcome of IgAN (mesangial hypercellularity, segmental glomerulosclerosis, endocapillary hypercellularity, and tubular atrophy/interstitial fibrosis).

# Acute tubular injury

## Definition

- Acute renal impairment caused by injury to renal tubules.

## Epidemiology

- One of the most common causes of ARF.

## Aetiology

- Ischaemia due to prolonged hypoperfusion.
- Nephrotoxins such as drugs, radiological contrast, uric acid, haemoglobin, myoglobin, and ethylene glycol.

## Pathogenesis

- Tubular epithelial cells are metabolically active and very sensitive to damage from ischaemia or toxins.

## Presentation

- ARF.

## Macroscopy

- The kidneys are swollen with increased mass (>200g).
- The renal cortex appears pale on the cut surface.

## Histopathology

- The injured tubules are dilated with flattening of tubular epithelial cells and loss of the brush border.
- Casts of sloughed necrotic epithelial cells may be seen in the lumen of distal tubules.
- The interstitial compartment is expanded by oedema, but there is no significant inflammatory cell infiltrate.
- Clues to the underlying cause may be present, e.g. birefringent oxalate crystals in ethylene glycol poisoning or pigmented casts in rhabdomyolysis.

## Prognosis

- Usually associated with a severe circulatory disturbance and significant mortality rate.



## Acute drug-induced interstitial nephritis

### Definition

- Renal impairment caused by a hypersensitivity reaction to a drug.

### Epidemiology

- Uncommon.

### Aetiology

- NSAIDs.
- Antibiotics.
- Diuretics.
- Allopurinol.
- Proton pump inhibitors.

### Pathogenesis

- A hypersensitivity reaction to the offending drug causes tubulointerstitial inflammation and tubular damage.

### Presentation

- The typical presentation is ARF with fever and rash.
- Many patients have eosinophilia, eosinophiluria, and raised serum IgE levels.
- Patients with NSAID-induced disease may also show heavy proteinuria.
- In most cases, presentation occurs within days of starting the drug, though occasionally, it may not occur until several months of exposure.

### Macroscopy

- The kidneys are swollen, pale, and heavy.

### Histopathology

- The interstitium is expanded by oedema and a mixed inflammatory cell infiltrate which includes conspicuous numbers of eosinophils and may form eosinophil microabscesses.
- Lymphocytes are also seen infiltrating into the tubules ('tubulitis').

### Prognosis

- Cessation of the offending drug usually results in complete recovery.

## Anti-glomerular basement membrane disease

### Definition

- A severe renal disease caused by the development of autoantibodies to the glomerular basement membrane.

### Epidemiology

- Rare. The peak incidence is in adults from 20–40y.

### Aetiology

- Autoantibodies to the C-terminal domain of type IV collagen.

### Pathogenesis

- Autoantibodies bind to the glomerular basement membrane and initiate an autoimmune attack on the glomeruli.

### Presentation

- ARF due to severe acute glomerular injury.
- Some patients also present with pulmonary haemorrhage if the autoantibody also cross-reacts with alveolar basement membrane.

### Light microscopy

- Glomeruli show a segmental, necrotizing glomerulonephritis with breaches in the glomerular basement membrane and the formation of crescents in the Bowman's space.
- Unaffected segments of the glomeruli appear normal.
- A lymphoplasmacytic inflammatory cell infiltrate is present in the interstitium surrounding affected glomeruli.

### Immunofluorescence

- Strong linear staining of IgG and C3 is seen in the glomerular basement membrane.
- Sometimes, linear staining in tubular basement membranes is also seen.

### Electron microscopy

- No immune deposits are present.

### Prognosis

- Although prompt immunosuppressive therapies can halt ongoing disease activity, damage already suffered in the kidneys may be irreversible.

## Reflux nephropathy

### Definition

- Renal scarring associated with vesicoureteric reflux (VUR), a congenital disorder in which urine regurgitates from the bladder into the upper urinary tract.

### Epidemiology

- An important cause of chronic kidney disease, estimated to be responsible for up to 30% of cases in children and 10% of cases in adults.

### Aetiology

- VUR.
- Note not all VUR cases are complicated by reflux nephropathy (RN).

### Pathogenesis

- Thought to be the result of reflux of infected urine into the kidney.
- Intra-renal reflux tends to occur at the poles of the kidneys where compound papillae are found.
- Compound papillae are more susceptible to reflux as the papillary ducts open at less oblique angles onto a flat or concave surface.
- The acute inflammatory response to the infection causes renal scarring.
- Once sufficient nephron mass has been lost, progressive renal disease occurs.

### Presentation

- Patients typically present with hypertension and/or proteinuria.
- Once renal scarring is extensive, biochemical evidence of renal dysfunction becomes evident.

### Macroscopy

- The poles of the kidneys show areas of coarse renal cortical scarring.

### Histopathology

- The scarred areas show features of chronic pyelonephritis with tubular atrophy and interstitial fibrosis associated with a mononuclear inflammatory cell infiltrate.
- Some tubules are collapsed whereas others may be dilated and filled with proteinaceous material ('thyroidization').
- Residual glomeruli show hypertrophy and secondary glomerulosclerosis.

► This constellation of features is not specific to reflux nephropathy and may be seen in other contexts, most notably obstructive nephropathy. Distinction between the two is usually possible, based on the clinical picture and the pattern of scarring.

### Complications

- Recurrent urinary tract infection.
- Renal stones.
- Chronic kidney disease.

# Obstructive nephropathy

## Definition

- Renal damage caused by obstruction in the urinary tract.

## Epidemiology

- Predominantly seen in children (due to congenital anomalies of the urinary tract) and elderly men (due to prostatic hyperplasia).

## Aetiology

- Obstruction may occur anywhere in the urinary tract (📖 p. 162).
- Common causes include urinary calculi, pelviureteric junction obstruction, prostatic hyperplasia, urothelial tumours, and compression of the ureters by abdominal/pelvic masses.

## Pathogenesis

- Renal damage is thought to be predominantly a pressure-related phenomenon, though superimposed infection may also be contributory.

## Presentation

- The clinical features are diverse. depending on the extent of disease and laterality.
- Patients may be asymptomatic or present with hypertension, polyuria, or renal failure.

## Macroscopy

- The kidney is small and shrunken with hydronephrosis, diffuse calyceal dilation, blunting of papillae, and cortical thinning.

## Histopathology

- The renal parenchyma shows features of chronic pyelonephritis with extensive tubulointerstitial fibrosis and tubular atrophy.
- Atrophic tubules are often dilated and filled with proteinaceous material ('thyroidization').
- The collecting system shows marked chronic inflammation with lymphoid aggregates and follicles.
- Residual glomeruli may show hypertrophy and secondary glomerulosclerosis.

► Note that the term 'chronic pyelonephritis' refers to a constellation of pathological features which are not specific to obstructive nephropathy and may be seen in other contexts such as reflux nephropathy. Distinction is usually possible, based on the clinical picture and pattern of scarring.

## Prognosis

- Patients with significant bilateral disease are at risk of developing progressive renal impairment.

*This page intentionally left blank*

# Urological pathology

- Genitourinary malformations 158
- Urinary tract infection 160
- Urinary tract obstruction 162
- Urinary calculi 164
- Cystic renal diseases 165
- Benign renal tumours 166
- Renal cell carcinoma 168
- Childhood renal tumours 170
- Urothelial carcinomas 172
- Benign prostatic hyperplasia 174
- Prostate carcinoma 176
- Testicular germ cell tumours 178
- Testicular non-germ cell tumours 180
- Paratesticular diseases 181
- Urethral diseases 182
- Penile diseases 183
- Scrotal diseases 184

## Genitourinary malformations

### Renal agenesis

- Absence of one or both kidneys.
- Bilateral renal agenesis is uniformly fatal *in utero* or shortly after birth.
- Unilateral renal agenesis is usually asymptomatic, though it is often associated with other anomalies of the genital tract.

### Renal fusion

- May involve some or all portions of each kidney.
- The commonest form of renal fusion is the **horseshoe kidney** in which the lower poles of each kidney are fused into a single renal mass in the midline.
- Patients are prone to developing obstruction.

### Rotational anomalies

- Occur due to failure of the renal pelvis to rotate from an anterior position to a medial position.
- May occur in an otherwise normal kidney or accompany renal fusion or ectopia.

### Renal dysplasia

- Refers to a kidney with abnormal nephric development.
- Unilateral disease causes renal enlargement and a flank mass in infancy.
- Bilateral disease is usually fatal.
- Grossly, the kidney may be enlarged and cystic or small and solid.
- Histologically, the kidney contains abnormally formed nephron structures, often with cystic change. The presence of fetal cartilage is a characteristic feature.

### Pelviureteric junction obstruction

- A common cause of congenital obstructive uropathy.
- Due to an intrinsic malformation of the smooth muscle of the wall of the outflow tract at that site.
- More common in boys.
- Usually unilateral, more common on the left.
- May present in childhood with abdominal pain.

### Ureteral duplication

- A common anomaly in which the kidney has two separate renal pelves, accompanied by partial to complete reduplication of the ureter.
- When there is complete reduplication, the upper ureter typically enters the bladder posteriorly at the normal site of the ureteric orifice on the trigone of the bladder. The lower ureter usually enters the bladder laterally with a short intramural course, predisposing it to vesicoureteric reflux.

### Vesicoureteric reflux

- Failure of the vesicoureteric valve causes abnormal reflux of urine into the ureter when the bladder contracts.

- Predisposes to urinary tract infection (UTI) in children. In severe cases, may be complicated by intra-renal reflux and renal scarring, a condition known as **reflux nephropathy** (📖 p. 154).

### Posterior urethral valves

- Abnormal mucosal folds in the posterior prostatic urethra that cause obstructive uropathy.
- Their presence is usually indicated when bilateral hydronephrosis is detected on antenatal ultrasound.

### Cryptorchidism

- Occurs when the testis fails to descend into its normal position in the scrotum.
- Mobilization of the testis and fixation in the scrotum (orchidopexy) should be performed by the age of 2y to preserve fertility.
- Cryptorchidism is important due to its association with a higher risk of testicular germ cell tumours (📖 p. 178).

### Hypospadias

- The most common anomaly of the penis.
- Refers to the abnormal opening of the urethral meatus on the undersurface of the penis.
- Usually an isolated defect, though the incidence of cryptorchidism appears to be higher in boys with hypospadias.



## Urinary tract infection

### Pathogens

- *Escherichia (E.) coli* is the main organism.
- *Staphylococcus saprophyticus* and *Proteus mirabilis* are other causes.

### Epidemiology

- Extremely common.
- ~60% of women will have a UTI at some point in their life.

### Transmission

- Ascending spread of endogenous gut bacteria into the urethra.
- The shorter urethra of women and its closer proximity to the anus is thought to be the main reason why females are more susceptible.

### Risk factors

- Female gender, sexual intercourse, pregnancy, diabetes, catheterization, urinary tract obstruction or malformation.

### Pathogenesis

- Pathogenic strains of *E. coli* have pili which allow them to bind to galactose-containing receptors on the surface of urothelial cells.
- Other important virulence factors include haemolysin which allows invasion of tissues and the K antigen which protects the organism from neutrophil phagocytosis.

### Presentation

- Bladder infection (**cystitis**) causes frequency, urgency, dysuria, haematuria, and suprapubic pain.
  - Ascending spread into the kidneys (**acute pyelonephritis**) causes a more severe illness with fever, rigors, vomiting, and loin pain.
- ▶ May present with acute confusion in the elderly.

### Diagnosis

- Urinalysis showing leukocytes or nitrites is a useful quick screening test.
- The gold standard is microbiological culture of a correctly collected midstream urine specimen. A pure growth of  $>10^5$  organisms/mL of urine is considered diagnostic.

*This page intentionally left blank*

## Urinary tract obstruction

### Definition

- Urinary tract obstruction (**obstructive uropathy**) is a blockage to the flow of urine at some point in the urinary tract (Fig. 10.1).

### Epidemiology

- Seen mostly in older men (due to benign prostatic hypertrophy) and children (due to congenital anomalies of the urinary tract).

### Aetiology

- Urinary stones.
- Urothelial tumours.
- Extrinsic compression by abdominal/pelvic masses.
- Prostatic hyperplasia.
- Urinary tract malformations.
- Strictures.

### Presentation

- Symptoms directly suggestive of obstruction (e.g. ureteric colic).
- Impaired renal function.
- Recurrent UTIs.

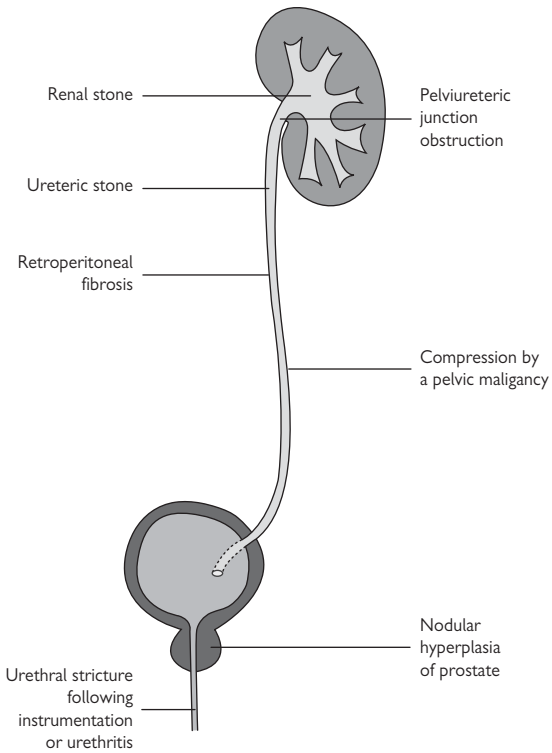
The precise clinical picture will depend on whether the obstruction is acute or chronic, involves the upper or lower urinary tract, and whether it is unilateral or bilateral.

### Macroscopy

- There is dilation of the urinary tract above the level of the obstruction, causing hydronephrosis and hydroureter.
- Renal damage is associated with loss of renal tissue and scarring.

### Complications

- Obstruction increases the risk of infection, stone formation, and renal damage (**obstructive nephropathy**) (📖 p. 155).



**Fig. 10.1** Common causes of obstruction in the urinary tract. Reproduced with permission from *Clinical Pathology*, Carton, Daly, and Ramani, Oxford University Press, p. 226, Figure 11.2.

## Urinary calculi

### Definition

- Crystal aggregates which form in the renal collecting ducts, but may become deposited anywhere in the urinary tract.

### Epidemiology

- Common, with a lifetime incidence of up to 15%.
- Males are at higher risk than females (3:1).

### Stone types

- Calcium oxalate (75%).
- Magnesium ammonium phosphate (15%).
- Uric acid stones (5%).

### Pathogenesis

- Calcium stones are associated with hypercalciuria. Most patients have absorptive hypercalciuria in which too much calcium is absorbed from the gut. Others have renal hypercalciuria in which calcium absorption from the proximal tubule is impaired. Only a minority have hypercalciuria due to hypercalcaemia which is usually due to primary hyperparathyroidism.
- Triple stones are formed largely as a result of infections with organisms such as *Proteus* that produce the enzyme urease which splits urea to ammonia. The ammonia alkalizes the urine and promotes precipitation of magnesium ammonium phosphate salts. Triple stones can become very large and may form branching masses filling the entire renal pelvis and calyces (**staghorn calculus**).
- Uric acid stones may form in patients with hyperuricaemia, e.g. patients with gout and conditions of rapid cell turnover, e.g. leukaemias. However, most patients do not have hyperuricaemia nor increased urinary excretion of uric acid. It is thought that these patients have a tendency to make slightly acidic urine which is prone to forming uric acid stones.

### Presentation

- Large stones tend to remain confined to the kidney. They may be asymptomatic or picked up following investigation of haematuria or recurrent UTIs.
- Smaller stones may pass into the ureter and become impacted, causing ureteric colic. Common points of impaction are the pelviureteric junction, the pelvic brim, and the vesicoureteric junction.

### Complications

- ▶ Complete obstruction of the urinary tract requires urgent intervention to remove the stone.
- ▶▶ Superadded infection in an obstructed urinary tract or any obstruction within the tract of a solitary kidney is a urological emergency requiring immediate intervention.

## Cystic renal diseases

### Adult (dominant) polycystic kidney disease

- The most common cystic renal disease with a frequency of up to 1 in 500 and a leading cause of end-stage renal failure.
  - 90% of cases are caused by an inherited mutation in the PKD1 gene on chromosome 16.
  - Defects in the function of the PKD1 protein lead to cystic change in renal tubules and loss of normal renal tissue.
  - Most patients present in adulthood, usually aged 30–40, with hypertension, flank pain, and haematuria.
  - Grossly, the kidneys are massively enlarged (weighing >2kg) and completely replaced with cysts.
  - Histologically, both kidneys contains numerous cysts lined by flattened cuboidal epithelium with little intervening normal renal parenchyma.
  - Extra-renal manifestations include liver cysts and berry aneurysms.
- ▶ Subarachnoid haemorrhage from a ruptured berry aneurysm is a serious complication of adult polycystic kidney disease (APKD) and a common cause of sudden death.

### Infantile (recessive) polycystic kidney disease

- A rare, inherited condition causing bilateral polycystic kidneys and congenital hepatic fibrosis.
- Caused by mutations in the gene PKHD1 on chromosome 6p which encodes a protein, fibrocystin, a component of the cilia on collecting duct epithelial cells.
- Grossly, the kidneys are enlarged and contain numerous cysts.
- Histologically, the cysts are lined by flattened cuboidal epithelium.
- Severe cases cause neonatal death from pulmonary hypoplasia.
- Patients with less severe renal disease who survive into childhood suffer from congenital hepatic fibrosis and complications of portal hypertension.

### Medullary cystic disease

- Congenital presence of numerous cysts at the corticomedullary junction which vary in size from <1mm to 2cm.
- The childhood disease (juvenile nephronophthisis) is autosomal recessive and associated with mutations in the genes NPH1, 2, or 3.
- The adult disease (uraemic medullary cystic disease) is autosomal dominant and associated with mutations in the genes MCDK1 or 2.

### Medullary sponge kidney

- Associated with an irregular enlargement of the collecting ducts, leading to microcystic change of the renal medullae and papillae with calcification.
- The condition usually presents in adult life with recurrent infections.

### Acquired renal cystic disease

- Development of multiple bilateral cortical and medullary cysts in patients with end-stage kidneys on dialysis.
- An important additional feature is the increased occurrence of renal tumours which are often papillary in type and may be multiple.

## **Benign renal tumours**

### **Papillary adenoma**

- Benign renal epithelial tumour with a papillary or tubulopapillary architecture and a size of 5mm or less.
- Frequently found incidentally in nephrectomy specimens or at autopsy.
- Macroscopically, they are well-circumscribed cortical nodules which measure 5mm or less.
- Histologically, they are composed of bland epithelial cells growing in papillary or tubulopapillary patterns.

### **Oncocytoma**

- Benign oncocytic renal epithelial tumour which is usually discovered incidentally in adults.
- Most cases are sporadic, but some are associated with genetic syndromes (e.g. Birt–Hogg–Dubé syndrome).
- Macroscopically, they are well-circumscribed tumours with a mahogany brown colour, often with central scarring.
- Histologically, they are characterized by cells with abundant granular eosinophilic cytoplasm, growing in nests within an oedematous stroma.
- Oncocytomas are benign tumours with no capacity for metastatic spread. Large tumours are nevertheless often excised.
- Infiltration of tumour cells into perinephric fat may be seen and this has no adverse consequence.

### **Angiomyolipoma**

- Benign mesenchymal tumour of the kidney composed of variable amounts of fat, smooth muscle, and thick-walled blood vessels.
- Most occur sporadically in adults, but a small proportion is associated with tuberous sclerosis. These are more likely to be multiple and bilateral.
- Although most are picked up incidentally, occasionally, they present with flank pain due to haemorrhage into the tumour.
- Macroscopically, they are lobulated renal masses which may appear rather yellow if their fat content is high.
- Histologically, they are composed of a mixture of adipose tissue, smooth muscle bundles, and thick-walled blood vessels in variable amounts.

### **Cystic nephroma**

- Benign cystic renal tumour which shows a marked predilection for women.
- Macroscopically, they are encapsulated multicystic lesions without a solid component.
- Microscopically, the cysts are lined by a single layer of attenuated cuboidal epithelial cells.
- The septa may show cellular areas resembling ovarian stroma and interestingly, the nuclei of the cells within the septa often react with antibodies to oestrogen and progesterone receptors.

### **Leiomyoma**

- Benign smooth muscle tumours which usually arise from the renal capsule.
- Most occur in adults as incidental small well-circumscribed capsular tumours.
- Histologically, they show bundles of bland smooth muscle cells.

### **Renomedullary interstitial cell tumour**

- Common benign renal tumours which are often encountered incidentally in kidneys at autopsy.
- Macroscopically they are small (1–5mm) white nodules centred on a medullary pyramid.
- Histologically, they are composed of small stellate or polygonal cells set in a loose stroma. Entrapped tubules may be found at the edge of the lesion.



## Renal cell carcinoma

### Definition

- A malignant epithelial tumour arising in the kidney.

### Epidemiology

- Accounts for ~2% of all cancers worldwide.
- Commoner in developed countries with an average incidence of ~10 per 100,000 in men and 3 per 100,000 in women.

### Aetiology

- Recognized risk factors include smoking, hypertension, obesity, environmental chemicals, and long-term dialysis.
- Some genetic syndromes are associated with renal cell carcinoma (RCC), e.g. von Hippel Lindau and tuberous sclerosis.

### Genetics

- Clear cell RCCs demonstrate losses at chromosome 3p.
- Papillary RCCs show trisomy of chromosomes 7 and 17 and loss of chromosome Y in men.
- Chromophobe RCCs show extensive chromosomal losses.

### Presentation

- About half of all cases present with painless haematuria,
- Most of the remainder is picked up incidentally on imaging.
- A small proportion presents with metastatic disease.

### Macroscopy

- The tumours are usually centred on the renal cortex.
- Clear cell types are heterogeneous with golden yellow areas.
- Papillary tumours may be friable.
- Chromophobe tumours are usually solid and brown.

### Histopathology

- **Clear cell RCC** (70%) is composed of cells with clear or eosinophilic cytoplasm set within a delicate vascular network.
- **Papillary RCC** (15%) has a papillary or tubulopapillary growth pattern and measures >5mm in size.
- **Chromophobe RCC** (5%) is composed of sheets of large cells with distinct cell borders. The vasculature within the tumour is thick-walled.
- The rest are made up of a mixture of rare subtypes such as collecting duct carcinoma and mucinous tubular and spindle cell carcinoma.

### Prognosis

- Overall 5-year survival rate is ~60%.
- Stage and grade are the most important prognostic factors.
- The most commonly employed grading system is the four-tiered Fuhrman system based on nuclear size, shape, chromatin pattern, and nucleolar prominence. Grade 1 has the best prognosis and grade 4 the worst.

**TNM 7 pathological staging of renal cell carcinomas****Primary tumour (T)**

pT1a: tumour  $\leq 4$ cm, limited to the kidney.

pT1b: tumour  $> 4$ cm, but  $\leq 7$ cm, limited to the kidney.

pT2a: tumour  $> 7$ cm, but  $\leq 10$ cm, limited to the kidney.

pT2b: tumour  $> 10$ cm, limited to the kidney.

pT3a: tumour extends into perinephric fat or renal veins.

pT3b: tumour extends into the vena cava below the diaphragm.

pT3c: tumour extends into the vena cava above the diaphragm.

pT4: tumour directly invades the adrenal gland or beyond the Gerota fascia.

**Regional lymph nodes (N)**

pN0: no regional lymph node metastasis.

pN1: metastasis in regional lymph nodes.

## Childhood renal tumours

### Nephroblastoma (Wilms' tumour)

- A malignant childhood renal neoplasm.
- Second most common childhood malignancy with an incidence of ~1 in 8,000.
- Most children present aged 2–5y old with an abdominal mass.
- Macroscopically, they are well-demarcated tumours with a grey or tan colour.
- Histologically, most nephroblastomas contain a mixture of undifferentiated small round blue cells (blastema) with areas of more differentiated epithelial and stromal components (so-called 'triphasic' tumours).
- Most nephroblastomas are of low stage with favourable histology and have an excellent prognosis with treatment.
- ~5% of cases show unfavourable histology characterized by nuclear anaplasia or the presence of multipolar mitotic figures; these cases are associated with an adverse outcome.

### Clear cell sarcoma

- A rare childhood renal sarcoma with a marked propensity to metastasize to bone.
- Most children present between 1–2y of age.
- Macroscopically, they are typically large tumours centred on the renal medulla.
- Histologically, the classical pattern is of nests or cords of cells separated by fibrovascular septa.

### Rhabdoid tumour

- A rare highly malignant renal tumour of young children.
- Most present around 1y of age with either haematuria or symptoms of disseminated disease.
- Macroscopically, the tumours are large and infiltrative with areas of necrosis.
- Histologically, the malignant cells have vesicular chromatin, prominent cherry red nucleoli, and hyaline pink intracytoplasmic inclusions. Extensive vascular invasion is usually evident.
- Prognosis is extremely poor with mortality rates in excess of 80% within 2y of diagnosis.

### Congenital mesoblastic nephroma

- A low-grade fibroblastic renal sarcoma arising in young children.
- May be diagnosed on antenatal ultrasound or present within the first year of life with an abdominal mass.
- Macroscopically, the tumour is centred on the renal sinus and has either a firm whorled appearance or a softer cystic cut surface.
- Histologically, two types are recognized, a 'classic' type composed of fascicles of bland spindle cells and a 'cellular' type composed of sheets of densely packed rounder cells.
- Prognosis is generally excellent when the tumour is completely excised by nephrectomy.

*This page intentionally left blank*

## Urothelial carcinomas

### Definition

- A group of neoplasms arising in the urothelial tract.

### Synonym

- Transitional cell carcinomas.

### Epidemiology

- Common with over 250,000 new cases worldwide.
- Can occur anywhere in the urothelial tract, but the vast majority arises in the bladder, then renal pelvis, then ureters (50:3:1, respectively).
- Bladder tumours are probably commoner because carcinogens passing through the urinary tract dwell in the bladder for longer.

### Aetiology

- Cigarette smoking.
- Occupational exposure to aromatic amines.

### Genetics

- Non-invasive low-grade papillary urothelial carcinomas show few genetic alterations, the most common being losses of chromosome 9.
- Non-invasive high-grade papillary urothelial carcinomas, urothelial carcinoma *in situ*, and infiltrating urothelial carcinomas are genetically unstable with many chromosomal aberrations, including TP53 and RB mutations.

### Presentation

- Most present with haematuria.

### Macroscopy

- Non-invasive papillary tumours usually grow as frond-like masses from the urothelial mucosa.
- Infiltrating urothelial carcinomas are usually solid masses which infiltrate into underlying tissues.
- Urothelial carcinoma *in situ* is a flat lesion which may be invisible macroscopically or manifest as an erythematous area of mucosa.

### Urine cytopathology

- Poorly sensitive at picking up low-grade urothelial carcinomas.
- Good at detecting high-grade lesions where the severely atypical urothelial cells display large pleomorphic nuclei with dark coarsely granular chromatin.

### Histopathology

- **Non-invasive low-grade papillary urothelial carcinoma** is composed of slender papillae lined by urothelium showing mild disorder and low-grade nuclear atypia.
- **Non-invasive high-grade papillary urothelial carcinoma** is composed of branching, fused papillae lined by urothelium showing marked disorder and high-grade nuclear atypia.

- **Urothelial carcinoma *in situ*** is a flat lesion in which the urothelium displays unequivocally high-grade nuclear atypia.
- **Infiltrating urothelial carcinoma** is a urothelial tumour that has invaded beyond the basement membrane. This group is not formally subdivided into low and high grade, though most show high-grade nuclear atypia.

### Prognosis

- All show a tendency to multifocality and recurrence.
- Non-invasive low-grade papillary urothelial carcinomas carry a very low risk of progression to invasion and death (<5%).
- Non-invasive high-grade papillary urothelial carcinomas and urothelial carcinoma *in situ* carry a much higher risk of progression.
- The prognosis of infiltrating urothelial carcinoma is mostly dependent on disease stage. The presence of lymphovascular invasion is an adverse prognostic factor.

### TNM 7 pathological staging of bladder carcinomas

#### Primary tumour (T)

pTa: non-invasive tumour.

pT1: tumour invades the lamina propria.

pT2: tumour invades the muscularis propria.

pT3: tumour invades perivesical tissue.

pT4: tumour invades adjacent organs (prostate, uterus, vagina, pelvic wall).

#### Regional lymph nodes (N)

pN1: single positive node in the primary drainage region.

pN2: multiple positive nodes in the primary drainage region.

pN3: common iliac node involvement.

### TNM 7 pathological staging of renal pelvis and ureter carcinomas

#### Primary tumour (T)

pTa: non-invasive tumour.

pT1: tumour invades the lamina propria.

pT2: tumour invades the muscularis propria.

pT3: tumour invades beyond the muscularis into peripelvic fat or renal parenchyma (renal pelvis) or into periureteric fat (ureter).

pT4: tumour invades adjacent organs or through the kidney into perinephric fat

#### Regional lymph nodes (N)

pN0: no regional lymph node metastases.

pN1: metastasis in a single lymph node, 2cm or less in dimension.

pN2: metastasis in a single lymph node, >2cm, but not >5cm, or multiple lymph nodes, none >5cm.

pN3: metastasis in a lymph node, >5cm in dimension.

## Benign prostatic hyperplasia

### Definition

- Enlargement of the prostate gland due to an increase in cell number.

### Epidemiology

- Very common.
- Symptomatic disease affects ~3% of men aged 45–49, rising to nearly 25% of men by age 80.
- Histological evidence is present in 90% of men by age 80.

### Aetiology

- Unclear.

### Pathogenesis

- Androgens are critical in the development of benign prostatic hyperplasia (BPH), more specifically increased levels of dihydrotestosterone locally in the prostate.
- Current evidence suggests that increased oestrogen levels in the blood (which rise with age) induce androgen receptors in prostate tissue and stimulate hyperplasia.

### Presentation

- Frequency, urgency, nocturia, hesitancy, poor flow, and terminal dribbling (collectively known as lower urinary tract symptoms or 'LUTS').
- Some patients present with UTI, acute urinary retention, or renal failure.


### Macroscopy

- The prostate shows nodular enlargement which usually involves the transition zone.
- There is a poor correlation between the size of the prostate and the severity of symptoms.

### Histopathology

- There is a proliferation of both epithelial and stromal elements of the prostate, which form nodules.
- The proportion of epithelial and stromal elements varies considerably between cases, with some being predominantly epithelial and some being predominantly stromal.

### Complications

- Urinary retention.
- Recurrent UTIs.
- Bladder stones.
- Obstructive nephropathy ( p. 155).

*This page intentionally left blank*



## Prostate carcinoma

### Definition

- A malignant epithelial tumour arising in the prostate.

### Epidemiology

- The most common malignant tumour in men.
- Rising incidence due to higher life expectancy and increased detection.
- A less prominent cause of cancer-related death as many cases behave in a relatively indolent fashion.

### Aetiology

- Racial background and genetic factors are important, with a 5–10-fold increased risk in men with two or more affected first-degree relatives.
- Dietary association with animal products, particularly red meat.

### Carcinogenesis

- Arises from a precursor lesion known as **prostatic intraepithelial neoplasia (PIN)**, characterized by neoplastic transformation of the lining epithelium of the prostatic ducts and acini.
- Harbour mutations in a number of genes, including GST-pi, PTEN, AMACR, p27, and E-cadherin (note these are not classical tumour suppressor genes or oncogenes).

### Presentation

- The vast majority of prostate cancers are asymptomatic and diagnosed when needle biopsy is performed for a raised prostate-specific antigen (PSA) or a suspicious prostate on digital rectal examination (DRE).
- LUTS may be present.
- Rarely, patients present with symptoms of metastatic disease.

### Macroscopy

- Early cases of latent prostate cancer are unlikely to be visible macroscopically.
- More extensive tumours may be visible as firmer areas which differ in colour from the surrounding prostate.

### Histopathology

- Virtually all prostate carcinomas are gland-forming epithelial tumours, i.e. adenocarcinomas.
- One of the key diagnostic features of prostate cancer is the abnormal architecture of the malignant glands which show crowding and a haphazard growth pattern when compared to adjacent normal acini.
- Malignant epithelial cells have enlarged nuclei with prominent nucleoli and denser amphophilic cytoplasm.
- Malignant glands often have intraluminal crystalloids (dense crystal-like structures), pink secretions, or blue-tinged mucin.
- A morphological diagnosis or suspicion of prostate carcinoma can be confirmed immunohistochemically by demonstrating a lack of basal cells surrounding the malignant glands. Common basal cell markers used for this purpose include p63 and high molecular weight keratins.

### Prognosis

- The most powerful indicator is the histological grade, known as the **Gleason score** after the pathologist who first devised the system.
- The Gleason score ranges from 2 to 10 and is calculated by adding together two numbers from 1 to 5, based on the architectural growth patterns of the tumour. In practice, patterns 1 and 2 are virtually never diagnosed and so almost all prostate cancers have a Gleason score between 6 and 10. A higher score is associated with poorer tumour differentiation and worse outcome.
- Other important factors are the PSA level and the stage of the disease.

### Prostate cancer screening

- Screening using serum PSA is a controversial subject.
- At present, most countries do not operate an organized prostate screening programme.
- Current evidence suggests that screening would result in overdiagnosis and overtreatment of many men with prostate cancers that are unlikely to behave in an aggressive manner.

### TNM 7 pathological staging of prostatic carcinomas

#### Primary tumour (T)

pT1a: tumour incidental histologic finding in 5% or less of TURP tissue.

pT1b: tumour incidental histological finding in more than 5% of TURP tissue.

pT1c: tumour identified by needle biopsy (e.g. because of elevated PSA).

pT2a: tumour involves one half of one lobe or less.

pT2b: tumour involves more than half of one lobe, but not both lobes.

pT2c: tumour involves both lobes.

pT3a: extracapsular extension or microscopic bladder neck invasion.

pT3b: tumour invades seminal vesicle(s).

pT4: tumour invades adjacent structures other than seminal vesicles.

#### Regional lymph nodes (N)

pN0: no regional lymph node metastasis.

pN1: regional lymph node metastasis.

## Testicular germ cell tumours

### Definition

- A group of malignant tumours of the testis arising from germ cells.

### Epidemiology

- >90% of all testicular tumours are germ cell tumours.
- Most arise in young men aged from 20–45.

### Aetiology

- The most consistent risk factor is the presence of cryptorchidism (p. 159) which increases the risk by 3–5-fold.
- Other prenatal risk factors include low birthweight and small for gestational age.
- No consistent adulthood risk factors have been identified.

### Carcinogenesis

- Most germ cell tumours arise from a precursor lesion known as **intratubular germ cell neoplasia (ITGCN)**, characterized by the presence of neoplastic germ cells confined to the seminiferous tubules.
- It is likely that the disease process begins in fetal life and that ITGCN is present during childhood and young adulthood during which time further genetic aberrations lead to malignant transformation.
- One consistently observed structural chromosomal aberration is gain of 12p sequences.

### Presentation

- Most patients present with a painless testicular lump.
- ~10% present with symptoms related to metastatic disease, most commonly back pain from retroperitoneal lymph node metastases or cough/dyspnoea from pulmonary metastases.

### Serum tumour markers

- Alpha-fetoprotein (AFP) is typically associated with the presence of yolk sac elements.
- Beta human chorionic gonadotrophin ( $\beta$ HCG) is associated with the presence of syncytiotrophoblastic cells; these may be present individually within a pure seminoma or as an integral component of choriocarcinoma.

### Macroscopy

- Pure seminomas tend to produce lobulated tan lesions.
- Teratomas often show cystic and solid areas.
- Mixed tumours tend to have a variegated appearance.

### Histopathology

- **Seminoma** is composed of sheets or nests of polygonal cells with clear or eosinophilic cytoplasm and round nuclei containing one or two nucleoli. A lymphocytic infiltrate is commonly present within the tumour.

- **Teratoma** is composed of tissues resembling immature fetal-type tissues and/or mature adult-type tissues.
  - **Embryonal carcinoma** is composed of anaplastic cells with large vesicular nuclei containing large nucleoli. The tumours may grow in solid sheets or form glandular structures.
  - **Yolk sac tumour** is composed of small mildly pleomorphic cells which form a wide variety of architectural patterns, the most common of which are reticular and microcystic.
  - **Choriocarcinoma** is composed of a mixture of syncytiotrophoblastic and cytotrophoblastic cells. There is often extensive haemorrhage and necrosis.
- ▶ Germ cell tumours may be composed entirely of one subtype or a mixture of different subtypes.

### Prognosis

- Excellent with 5-year survival rates of ~98% in most countries.
- This is a reflection of the high sensitivity of germ cell tumours to modern platinum-based chemotherapeutic regimes.

### TNM 7 pathological staging of testicular germ cell tumours

#### Primary tumour (T)

pT1: tumour limited to the testis without lymphovascular invasion.

pT2: tumour limited to the testis with lymphovascular invasion or tumour extending through the tunica albuginea with involvement of the tunica vaginalis.

pT3: tumour invades the spermatic cord with or without lymphovascular invasion.

pT4: tumour invades the scrotum with or without lymphovascular invasion.

## Testicular non-germ cell tumours

### Testicular lymphomas

- ~5% of all testicular tumours.
- Mostly seen in elderly men.
- The testis is usually replaced by a large grey/tan mass which may extend into the cord.
- Histologically, the most common type is **diffuse large B-cell lymphoma** (📖 p. 278).
- Survival is generally poor.

### Leydig cell tumour

- A sex-cord stromal tumour which accounts for ~3% of all testicular tumours.
- May occur at any age.
- Prepubertally, they tend to present with signs of precocious puberty due to androgen production.
- Post-pubertally, they present with a testicular mass.
- Macroscopically, they are well-circumscribed tumours, often with a brown cut surface.
- Histologically, they are composed of sheets or nests of polygonal cells with eosinophilic cytoplasm and round nuclei with a single nucleolus. Reinke's crystals (rhomboid-shaped, intracytoplasmic crystals) may be seen.
- The majority of Leydig cell tumours behave in a benign fashion; however, ~10% show malignant behaviour.
- Histology is not always entirely reliable at predicting which tumours will behave aggressively; however, worrying findings include tumour size >5cm, necrosis, vascular invasion, cellular pleomorphism, and raised mitotic activity.

### Sertoli cell tumour

- A sex-cord stromal tumour which accounts for ~1% of all testicular tumours.
- Most present as a testicular mass in young and middle-aged men.
- Macroscopically, they are usually solid yellow or white tumours.
- Histologically, they are composed of oval cells forming hollow or solid tubular structures.
- ~10% of tumours are malignant; similar histological criteria are used to predict malignant behaviour as for Leydig cell tumours.

## Paratesticular diseases

### Epididymal cyst

- Benign cystic lesion of the epididymis.
- Usually present as a small paratesticular swelling which may be tender.
- Grossly, appears as a thin-walled translucent cystic lesion.
- Histologically, the cyst is lined by a thin attenuated layer of bland epithelial cells.

### Epididymitis

- Usually results from ascending infection from the lower urinary tract.
- In young men <35y, it is usually due to a sexually transmitted infection such as *Chlamydia (C.) trachomatis* or *Neisseria (N.) gonorrhoeae*.
- In men >35y, it is usually due to *E. coli*.

### Varicocele

- A persistent abnormal dilation of the pampiniform venous plexus in the spermatic cord.
- More common on the left side where the testicular vein drains into the renal vein.
- Usually present with nodularity on the lateral side of the scrotum.
- Some cause a dull ache, especially after prolonged standing or towards the end of the day.
- May contribute to male subfertility as the increased blood flow raises scrotal temperature and impairs spermatogenesis.

### Hydrocele

- An abnormal accumulation of fluid in the space between the two layers of the tunica vaginalis.
- A common cause of scrotal swelling.
- Usually caused by trauma or a reaction to an underlying pathology such as epididymitis, orchitis, or a tumour.

### Adenomatoid tumour

- The most common benign paratesticular neoplasm.
- Can occur in the epididymis, spermatic cord, and tunica albuginea.
- Most present in young adults.
- Grossly, they are small solid firm grey/white tumours which are usually <3cm.
- Histologically, they are composed of dilated tubular structures lined by attenuated mesothelial cells.

### Paratesticular sarcomas

- Rare, but well recognized, paratesticular tumours.
- The two most common types are **well-differentiated liposarcoma** in adults and **embryonal rhabdomyosarcoma** in children/adolescents.

## Urethral diseases

### Urethritis

- Usually caused by sexually transmitted infections.
- Divided into gonococcal and non-gonococcal urethritis.
- Non-gonococcal urethritis is commoner and most are caused by *C. trachomatis*. Patients typically describe a sensation of urethral 'itching'.
- Gonococcal urethritis is due to infection with *N. gonorrhoeae*. Patients tend to present with a more purulent discharge and dysuria.
- Gram staining of urethral discharge can detect *N. gonorrhoeae* as intracellular Gram-negative diplococci. If these organisms are not detected, but numerous neutrophils confirm a urethritis, then non-gonococcal urethritis is presumed.
- Detection of *C. trachomatis* is usually by molecular methods as culture is slow and unreliable.

### Prostatic urethral polyp

- Lesion of the prostatic urethra containing prostatic epithelium.
- Typically presents with haematuria.
- Grossly, they are papillary lesions projecting into the prostatic urethra.
- Histologically, they are composed of crowded collections of prostatic-type glands covered by urothelium.

### Urethral caruncle

- Relatively common polypoid lesion of the distal urethra in women.
- Presents with dysuria and spotty bleeding.
- The caruncle is visible as a polypoid mass at the urethral meatus.
- Histologically, it contains a dense inflammatory cell infiltrate rich in blood vessels and is covered by hyperplastic epithelium.

### Urethral carcinomas

- These are rare, but commoner in women.
- Often present at a high stage with poor prognosis.
- Most are squamous cell carcinomas (70%) and arise in the distal urethra near the meatus.
- The others are either urothelial carcinomas (20%) or adenocarcinomas (10%) and tend to arise in the proximal urethra.

### Malignant melanoma

- Rare, but well described in the urethra.
- Grossly, they appear as polypoid or ulcerated urethral masses.
- Histologically, they are composed of atypical epithelioid or spindled cells. Frequently amelanotic which can lead to diagnostic difficulty.
- Immunohistochemical reactivity of the malignant cells for melanocytic markers (S100, HMB-45, Melan-A) helps to clinch the diagnosis.

## Penile diseases

### Lichen sclerosus

- Penile lichen sclerosus (balanitis xerotica obliterans) is an inflammatory disease that usually affects the foreskin or glans penis.
- Most cases present in adulthood with phimosis.
- Macroscopically, the affected areas appear white and atrophic.
- Histologically, there is epidermal atrophy and hyperkeratosis with underlying bands of hyalinized collagen and a chronic inflammatory cell infiltrate.

### Lichen planus

- Penile involvement is commonly seen in patients with generalized lichen planus (📖 p. 288).
- The lesions often involve the glans penis.
- Histology shows a band-like inflammatory infiltrate hugging the epithelium. The infiltrate often contains plasma cells, in contrast with cutaneous lesions where lymphocytes and macrophages predominate.

### Zoon's balanitis

- Usually presents as a solitary red area in uncircumcised elderly men.
- Clinically mimics penile Bowen's disease.
- Histology shows thinning of the epidermis, spongiosis, lozenge-shaped keratinocytes, and a dense band-like inflammatory infiltrate rich in plasma cells.

### Condylomas

- Caused by human papillomavirus (HPV) infection, usually types 6 and 11. Seen mostly in sexually active young men.
- Macroscopically, condylomas appear as either flat or frond-like papillary growths.
- Histologically, they show a papillomatous squamous proliferation with koilocytes (keratinocytes showing HPV cytopathic changes).

### Peyronie's disease

- Also known as penile fibromatosis, but probably unrelated to the other forms of fibromatosis (📖 p. 318).
- Presents between ages 40–60 with thickening of the corpus cavernosa, leading to penile pain and curvature on erection.
- Histological examination of excised tissue shows hypocellular collagenous scar tissue with aggregates of chronic inflammatory cells.

### Penile carcinoma

- Rare malignancy which usually arises on the glans penis of elderly men.
- Risk factors include HPV infection, smoking, phimosis, and longstanding lichen sclerosus. Circumcision is associated with a reduction in risk.
- Macroscopically, they are exophytic masses which may ulcerate.
- Histologically, the majority are squamous cell carcinomas which arise from areas of squamous dysplasia (sometimes termed penile intraepithelial neoplasia).



## Scrotal diseases

### Epidermoid cysts

- Common cause of a scrotal skin lump.
- Macroscopically, they contain yellow keratinous debris.
- Histologically, they are lined by squamous epithelium showing epidermoid-type keratinization.

### Scrotal calcinosis

- An uncommon disorder in which multiple calcified nodules develop in the scrotal skin.
- The calcification is thought to be dystrophic in type and probably represents calcification of old epidermoid cysts.

### Angiokeratomas

- Benign vascular lesions which usually present as multiple small blue/red lesions of the scrotal skin.
- Histologically, they are composed of dilated vascular channels in the papillary dermis associated with hyperplasia and hyperkeratosis of the overlying epidermis.

### Fournier's gangrene

- A clinical variant of necrotizing fasciitis (📖 p. 296) which involves the penis, scrotum, perineum, and abdominal wall of men.
- Main risk factors are diabetes and immunosuppression.
- Usually, a polymicrobial infection caused by a mixture of aerobic and anaerobic bacteria.
- Histology shows a severe necrotizing inflammatory process involving the skin and deep subcutaneous tissue.
- Mortality is in the order of 15–20%.

### Scrotal squamous cell carcinoma

- A very rare malignancy.
- Mostly of historical interest due to its association with occupational exposure to carcinogens in chimney workers.

# Gynaecological pathology

- Vulval skin diseases 186
- Benign vulval tumours 187
- Vulval carcinoma 188
- Vaginal infections 190
- Vaginal tumours 191
- Cervical carcinoma 192
- Cervical screening 194
- Endometriosis 195
- Endometrial carcinoma 196
- Uterine leiomyomas 198
- Functional ovarian cysts 200
- Polycystic ovarian syndrome 202
- Benign ovarian tumours 204
- Ovarian carcinomas 206
- Pelvic inflammatory disease 208
- Ectopic pregnancy 209
- Hydatidiform moles 210
- Pre-eclampsia 212

## Vulval skin diseases

### Eczemas

- Commonly arise on vulval skin.
- Seborrhoeic dermatitis and irritant contact dermatitis are the two most frequent types.
- These have appearances similar to those elsewhere on the skin (📖 p. 286).

### Lichen simplex chronicus

- Thickened patches of skin which probably represent a non-specific reaction to chronic itching.
- The labium majus is the predominant site on the vulva.
- Histologically, there is marked epidermal thickening with overlying hyperkeratosis and hypergranulosis.

### Psoriasis

- Vulval psoriasis is typically of flexural type with marked erythema and absence of scaling.
- Typical histology shows regular psoriasiform epidermal hyperplasia with plaques of parakeratosis and loss of the granular layer. Neutrophils are present within the parakeratosis.
- Vulval psoriasis may, however, show atypical histology, making the diagnosis more difficult to make.

### Lichen planus

- May be found in patients with generalized disease (📖 p. 288) or be restricted to the genital region.
- The lesions are purple, flat-topped, shiny papules. Erosive disease may occur, which can lead to scarring.
- Histologically, there is a band-like inflammatory cell infiltrate containing lymphocytes, histiocytes, and plasma cells. The overlying epidermis shows basal cell damage and may be thickened or atrophic.
- Lichen planus carries a small increased risk of the development of vulval intraepithelial neoplasia (VIN) and squamous cell carcinoma.

### Lichen sclerosis

- An inflammatory dermatosis of unknown cause with a predilection for the anogenital skin of women.
- Clinically, there are white papules and plaques with a wrinkled surface. There may be areas of atrophy and haemorrhage. Itching, burning, and dyspareunia are common symptoms.
- Histologically, the epidermis is thinned and there is interface change. There is a band of hyalinization beneath the epidermis and an underlying chronic inflammatory cell infiltrate.
- Lichen sclerosis carries a small increased risk of development of VIN and squamous cell carcinoma.

## Benign vulval tumours

### Bartholin duct cysts

- Arise due to obstruction of a Bartholin's gland duct.
- Present as painless lumps of the vulva in young women.
- Histologically, they are lined by transitional-type epithelium with areas of squamous metaplasia.

### Papillary hidradenoma

- Benign sweat gland tumour which usually presents in middle-aged women as a small painless vulval lump.
- Histologically, they are well-circumscribed papillary tumours of the dermis. The epithelium covering the papillae is double-layered, with inner tall columnar cells and outer small myoepithelial cells.

### Condylomas

- Solitary or multiple lesions related to certain types of human papilloma virus (HPV) infection.
- Histologically, they show papillary squamous proliferations with koilocytes (keratinocytes showing HPV cytopathic effect).
- Widespread vulval condylomas may be seen in the immunosuppressed.

### Granular cell tumour

- Uncommon neural tumour that may occur in the vulva.
- Histologically composed of nests of large polygonal cells with abundant granular cytoplasm.
- The vast majority behave in a benign fashion.

### Angiomyofibrolastoma

- Benign mesenchymal neoplasm that occurs almost exclusively in the vulvovaginal region of young women.
- Presents as a small subcutaneous lump, often mistaken for a cyst.
- Histologically, they are well-circumscribed lesions composed of dilated capillary-sized vessels set in an oedematous stroma containing many plump epithelioid stromal cells.

### Cellular angiofibroma

- Benign mesenchymal neoplasm presenting as a small painless subcutaneous mass in the vulvovaginal region of reproductive age women.
- Histologically, they are well-circumscribed cellular lesions composed of bland spindle cells and many small thick-walled blood vessels.

### Deep angiofibroma

- Locally infiltrative, but non-metastasizing, mesenchymal neoplasm that presents as a large deep-seated mass in the pelvis and perineum of reproductive age women.
- Histologically, they are infiltrative, paucicellular tumours composed of small numbers of bland spindle cells set in a myxoid stroma containing thick-walled blood vessels.

## Vulval carcinoma

### Definition

- A malignant epithelial tumour arising in the vulva.

### Epidemiology

- Rare with an annual incidence of 0.8 per 100,000.
- Most arise in elderly women, but it can also occur in younger women.

### Aetiology

- Unknown in many cases.
- Some are linked to chronic vulval dermatoses such as lichen sclerosus or lichen planus.
- Most cases arising in younger women are linked to high-risk HPV infection of the vulva.

### Carcinogenesis

- Most cases arise from a precursor lesion known as **vulval intraepithelial neoplasia (VIN)**.
- VIN is a dysplastic lesion of the squamous epithelium of the vulva and is divided into two types: **classical** and **differentiated**.
- Classical type is seen in young women and is related to HPV infection.
- Differentiated type is seen in older women and is related to chronic vulval inflammation.
- Both VIN and vulval carcinomas display genetic aberrations which include mutations of TP53 and PTEN.

### Presentation

- Most present with a vulval mass which may ulcerate and bleed.

### Macroscopy

- A vulval tumour mass which may be nodular, verrucous, or ulcerated.

### Histopathology

- Almost all cases are **squamous cell carcinomas**, composed of infiltrating malignant epithelial cells showing squamous differentiation.
- The squamous epithelium adjacent to the tumour may show VIN.

### Prognosis

- The most important prognostic indicators are tumour size, depth of invasion, and extent of lymph node metastasis.
- Tumours with depth of invasion  $\leq 1$ mm have a very low risk of lymph node metastasis and a good chance of cure following local excision.
- 5-year survival rates in patients with unilateral lymph node disease is 65% whereas with bilateral disease, it falls to 25%.

**FIGO staging of vulval carcinomas**

Stage IA: tumour confined to the vulva or perineum,  $\leq 2$ cm in size with stromal invasion  $\leq 1$ mm, negative nodes.

Stage IB: tumour confined to the vulva or perineum,  $> 2$ cm in size or with stromal invasion  $> 1$ mm, negative nodes.

Stage II: tumour of any size with extension to adjacent perineal structures (lower one third of urethra, lower one third of vagina, anus), negative nodes.

Stage III: tumour of any size with or without extension to adjacent perineal structures with positive inguino-femoral lymph nodes.

Stage IV: tumour invades other regional structures or distant structures.

## Vaginal infections

### Bacterial vaginosis

- Commonest cause of an abnormal vaginal discharge.
- Caused by overgrowth of anaerobic bacteria such as *Gardenerella vaginalis* and *Bacteroides* species.
- The metabolic products of these bacteria include volatile amines which give the discharge a distinctive fishy odour.
- There is no actual inflammation in the vaginal wall, hence the term vaginosis is applied rather than vaginitis.

### Vulvovaginal candidosis

- Also known as 'thrush'.
- Very common infection in young women caused by *Candida albicans*.
- The typical presentation is vulvovaginal itching and burning, dyspareunia, and dysuria. A thick white discharge is common.
- Wet mount microscopy of the discharge shows fungal pseudohyphae.
- The organism can also be cultured in the microbiology laboratory.
- Recurrent *Candida* infections may be a sign of underlying diabetes mellitus or immunosuppression.

### Trichomoniasis

- Sexually transmitted infection caused by the flagellate protozoan, *Trichomonas vaginalis*.
- The male partner is usually asymptomatic and half of all affected women are also asymptomatic.
- Women with symptoms usually complain of vaginal itching and a thin frothy offensive discharge. Dyspareunia and dysuria may also occur.
- Wet mount microscopy of the discharge shows motile trichomonads.

## Vaginal tumours

### Vaginal carcinoma

- Uncommon in comparison to cervical and vulval carcinomas.
- Most are squamous cell carcinomas which arise from a precursor dysplastic lesion known as **vaginal intraepithelial neoplasia (VAIN)**.
- Risk factors include HPV infection, smoking, and immunosuppression.
- Prognosis is generally poor with 5-year survival rate of ~60%.

### Fibroepithelial stromal polyp

- Benign lesion of the distal female genital tract which most commonly involves the vagina, but may also arise in the vulva.
- Hormonally-responsive lesions which occur in reproductive age women as a small polypoid mass.
- Histologically, they are composed of a central fibrovascular core covered by hyperplastic squamous epithelium. Stellate and multinucleate stromal cells are typically seen within the core near the epithelial surface.

### Genital rhabdomyoma

- Benign tumour showing skeletal muscle differentiation that most commonly occurs in the vagina.
- Presents in middle-aged women with symptoms related to a mass lesion.
- Histologically, it is composed of a haphazard proliferation of spindle cells with abundant brightly eosinophilic cytoplasm containing cross-striations.

### Embryonal rhabdomyosarcoma

- A malignant tumour showing skeletal muscle differentiation which can arise in the vagina of children.
- Most cases present in children aged <5y with vaginal bleeding. Tumour may be seen projecting through the vaginal opening.
- Macroscopically, the tumour is composed of oedematous polypoid nodules projecting from the vaginal wall.
- Histologically, the tumour is composed of small round and spindled tumour cells condensed beneath the squamous epithelium of the vaginal wall. Some tumour cells have brightly eosinophilic cytoplasm; cytoplasmic cross-striations may be visible.
- Prognosis following treatment is generally excellent with 10-year survival rates of >90%.



## Cervical carcinoma

### Definition

- A malignant epithelial tumour arising in the cervix.

### Epidemiology

- Worldwide, cervical carcinoma is the most common malignancy of the female genital tract and the second most common non-cutaneous malignancy in women following breast cancer.
- In developed countries, cervical carcinoma is the third most common malignancy of the female genital tract after endometrial and ovarian carcinoma. The lower incidence is largely attributable to the success of cervical screening programmes.

### Aetiology

- Virtually all are caused by high-risk HPV infection (types 16 and 18).
- Other risk factors include smoking and oral contraceptive use, which probably act by enhancing HPV persistence in the cervix.

### Carcinogenesis

- 80% are squamous cell carcinomas which arise from a precursor lesion known as **cervical intraepithelial neoplasia (CIN)**.
- 20% are adenocarcinomas which arise from a precursor lesion known as **cervical glandular intraepithelial neoplasia (CGIN)**.
- HPV-mediated cervical carcinogenesis is linked to the presence of two viral genes, E6 and E7.
- The E6 and E7 proteins interact with the tumour suppressor proteins, P53 and RB, targeting them for degradation. Loss of function of these proteins results in uncontrolled proliferation of the infected cells.

### Presentation

- Non-menstrual vaginal bleeding and discharge.

### Macroscopy

- Visible tumours show a solid tumour mass on the cervix which may be exophytic or endophytic.

### Histopathology

- **Squamous cell carcinomas** are characterized by infiltrating irregular nests of malignant epithelial cells showing squamous differentiation. Residual CIN may be seen adjacent to small tumours.
- **Adenocarcinomas** are characterized by infiltrating malignant epithelial cells forming glandular structures. Residual CGIN may be seen adjacent to small tumours.

### Prognosis

- Depends on a number of factors, including age, stage, and the presence or absence of lymphovascular invasion.

**FIGO staging of cervical carcinomas**

IA1: microscopic tumour with stromal invasion  $\leq 3$ mm in depth,  $\leq 7$ mm in horizontal spread.

IA2: microscopic tumour with stromal invasion  $> 3$ mm in depth and not more than 5mm with a horizontal spread  $\leq 7$ mm.

IB: any clinically visible lesion confined to the cervix or microscopic lesion greater than IA1/2.

II: tumour invades beyond the uterus, but not to the pelvic side wall or to the lower third of the vagina.

IIIA: tumour involves the lower third of vagina, no extension to the pelvic side wall.

IIIB: tumour extends to the pelvic side wall and/or causes hydronephrosis or non-functioning kidney.

IVA: tumour invades the mucosa of bladder or rectum and/or extends beyond the true pelvis.

IVB: distant metastasis.

## Cervical screening

► The main aim of cervical screening is the detection of CIN.

### NHS cervical screening programme

- All women aged between 25 and 64 are eligible for cervical screening.
- Routine screening is performed every 3y from age 25 to 49y and every 5y from age 50 to 64y.
- The screening test is a cervical sample ('smear') for **liquid-based cytology**.
- A special device is used to brush cells from the cervix. The head of the brush is then broken off into a small glass vial containing fixative or rinsed directly in the fixative.
- The sample is then sent to the local laboratory where a processing machine creates a thin monolayer of cells on a glass slide for cytological examination.

### Cytopathology

- The principal aim of cytological examination of cervical samples is the detection of **dyskaryotic squamous epithelial cells**.
- Dyskaryosis is graded into mild, moderate, or severe, depending on how abnormal the cell appears.
- Women with one test showing moderate or severe dyskaryosis must be referred for colposcopy.
- Ideally, women with one test showing mild dyskaryosis should also be referred to colposcopy, but it remains acceptable to repeat the screening test first. Women with two tests reported as mild dyskaryosis must then be referred for colposcopy.

### Colposcopy

- Colposcopy is a detailed examination of the cervix using a binocular microscope called a colposcope and an intense light source.
- Application of acetic acid and iodine to the cervix helps identify areas of possible CIN for directed biopsy.

### Histopathology

- Directed cervical biopsies are sent for histopathological examination to confirm the presence of CIN and provide a grade from 1 to 3.
- CIN 1 shows squamous dysplasia in which the abnormalities are concentrated in the basal third of the epidermis.
- CIN 2 shows squamous dysplasia in which the abnormalities are concentrated in the basal two thirds of the epithelium.
- CIN 3 shows squamous dysplasia in which the abnormalities extend into the upper one third of the epithelium.

### Management

- CIN 2 and 3 are high-grade lesions which should be removed by excision of the transformation zone.
- CIN 1 is a low-grade lesion and may be managed conservatively or excised, depending on the clinical situation.

# Endometriosis

## Definition

- The presence of endometrial tissue outside the uterine body. Almost all cases occur within the pelvis, most commonly the ovaries, uterosacral ligaments, pelvic peritoneum, pouch of Douglas, and sigmoid colon. Endometriosis is also recognized at sites outside of the pelvis such as surgical scars and the lungs, but this is rarer.

## Epidemiology

- Common, affecting up to 10% of women.

## Pathogenesis

- **Implantation theory** proposes that endometrial glands are regurgitated into the peritoneal cavity during menstruation and implant on the peritoneal surface. Credence to this theory is lent by experimental induction of endometriosis in animals by placing endometrial tissue in the peritoneal cavity.
- **Metaplastic theory** proposes that endometriosis arises due to metaplasia of the peritoneal surface epithelium into endometrial-type epithelium. Given that the peritoneum and female genital tract arise from the same embryological cells (coelomic epithelium), this seems plausible and would account for endometriotic deposits in areas in which implantation is unlikely.
- **Metastatic theory** proposes that endometriosis arises due to haematogenous spread of endometrial tissue that enters the circulation during menstruation. This would account for cases arising in locations where implantation and metaplasia are improbable such as the lung.

## Presentation

- Dysmenorrhoea caused by swelling of endometriotic deposits during menstruation.
- Subfertility through unclear mechanisms, though implantation failure and/or endocrine dysfunction have been proposed. There is little evidence to support tubal distortion as a cause in most women.


## Macroscopy

- Ovarian involvement typically gives rise to cysts filled with dark brown altered blood ('chocolate cysts'). Peritoneal involvement causes small nodules which often appear brown/black.

## Histopathology

- Microscopy is diagnostic, demonstrating the presence of endometrial glands and endometrial stromal cells in tissues other than the uterine body. There is often abundant surrounding haemorrhage.

## Prognosis

- Endometriosis is chronic and progressive in 50% of cases.
- Ovarian endometriosis is thought to be a precursor to ovarian endometrioid carcinomas ( p. 196).

## Endometrial carcinoma

### Definition

- A malignant epithelial tumour arising in the endometrium.

### Epidemiology

- The most frequent malignant tumour of the female genital tract in developed countries.
- 85% are oestrogen-dependent ('type 1') tumours, occurring in women in their 50s and 60s.
- 15% are oestrogen-independent ('type 2') tumours, occurring in older women in their 70s and 80s.

### Aetiology

- Oestrogen-dependent tumours are associated with diabetes, obesity, nulliparity, early menarche, late menopause, and polycystic ovarian syndrome.
- The aetiology of oestrogen-independent tumours is less clear.

### Carcinogenesis

- Oestrogen-dependent tumours develop from a precursor lesion called **endometrial intraepithelial neoplasia** (atypical hyperplasia) on a background of (simple) endometrial hyperplasia. Loss of function of PTEN is typical.
- Oestrogen-independent tumours develop from a precursor lesion called **endometrial intraepithelial carcinoma** on a background of endometrial atrophy. Loss of function of TP53 gene is typical.

### Presentation

- Post-menopausal bleeding is the key symptom.

### Macroscopy

- An exophytic friable mass fills the endometrial cavity and infiltrates to a varying extent into the underlying myometrium.
- In advanced cases, tumour may breach the serosal surface or invade the cervix.

### Histopathology

- Oestrogen-dependent tumours are usually well-differentiated **endometrioid adenocarcinomas** in which the malignant epithelial cells form complex villoglandular structures.
- Oestrogen-independent tumours are usually either **serous carcinomas** or **clear cell carcinomas**, which look identical to their ovarian counterparts. Both are high-grade malignancies with extensive spread at presentation.

### Prognosis

- Oestrogen-dependent tumours generally have a favourable outcome.
- Oestrogen-independent tumours are highly aggressive and usually fatal.

**FIGO staging of endometrial carcinomas**

IA: tumour confined to the endometrium or invades less than half of the myometrium.

IB: tumour invades one half or more of the myometrium.

II: tumour invades the cervical stroma, but does not extend beyond the uterus.

IIIA: tumour invades the uterine serosa and/or adnexa.

IIIB: tumour invades the vagina and/or parametrium.

IIIC: metastases to pelvic and/or para-aortic lymph nodes.

IVA: tumour invades the bladder and/or bowel mucosa.

IVB: distant metastases.

## Uterine leiomyomas

### Definition

- Benign smooth muscle tumours arising in the myometrium.

### Synonym

- Fibroids.

### Epidemiology

- Extremely common tumours found in up to 75% of all women.
- Symptomatic fibroids affect ~20% of women.

### Aetiology

- The precise cause is unclear, but risk factors include race and parity, with black and nulliparous women more likely to be affected.

### Pathogenesis

- Hormonally-driven tumours which occur almost exclusively in reproductive age women, rapidly grow in pregnancy, and regress after the menopause.
- Genetic studies show that they are clonal neoplasms with chromosomal aberrations.

### Presentation

- Menorrhagia.
- Subfertility: this is likely due to distortion of the endometrium, preventing implantation.
- Pelvic pain: this may be related to tumour infarction or twisting of a pedunculated fibroid.
- Palpable mass: fibroids may be large enough to be felt abdominally.

### Macroscopy

- Well-circumscribed, white, whorled tumours which characteristically bulge from the surrounding myometrium when cut.
- Often multiple and may be intramural or project from the serosal surface (subserosal) or into the endometrial cavity (submucosal).
- Calcification is very common.
- Infarcted tumours appear red rather than white ('red degeneration').

### Histopathology

- Classical fibroids are composed of intersecting fascicles of bland smooth muscle cells with blunt-ended nuclei and eosinophilic cytoplasm. Areas of hyalinization and calcification are common.
- A number of histological variants are well recognized, all of which behave in a benign fashion. These include cellular leiomyoma, highly cellular leiomyoma, mitotically active leiomyoma, and atypical leiomyoma.

### Prognosis

- Benign tumours with no capacity for malignant behaviour.

### **Uterine leiomyosarcoma**

Uterine leiomyosarcoma is a malignant smooth muscle tumour arising in the myometrium. Although uncommon, it represents the most common uterine sarcoma. Whilst rapid enlargement of a uterine mass may prompt suspicion for leiomyosarcoma, many are unsuspected preoperatively and assumed to be large fibroids.

Macroscopically, leiomyosarcomas are poorly circumscribed and tend not to bulge from the surrounding myometrium due to their infiltrative nature. They are softer than fibroids and may show evidence of necrosis.

Histologically, leiomyosarcomas are smooth muscle tumours which demonstrate a number of atypical features such as diffuse cytological atypia, tumour cell necrosis, and high mitotic activity.

Leiomyosarcomas are aggressive malignancies with a tendency to local recurrence and metastasis, particularly to the liver and lungs.



## Functional ovarian cysts

### Definition

- Ovarian follicles showing pathological cystic change.
- A proposed cut-off between normal cystic follicles and functional cysts is 2.5cm.

### Terminology

- Cysts derived from pre-ovulatory follicles are known as **follicular cysts** and those derived from the corpus luteum are known as **corpus luteum cysts**.

### Epidemiology

- Very common.

### Aetiology

- Follicular cysts are thought to reflect disordered function of the pituitary-ovarian axis.
- Corpus luteum cysts result from excessive haemorrhage in a corpus luteum.

### Presentation

- Almost all are discovered incidentally either on imaging or by a surgeon exploring the pelvis.
- Occasionally, large cysts may present as a pelvic mass.

### Macroscopy

- Follicular cysts are usually single and measure from 2.5 to 10cm in size. They are smooth-lined and contain clear fluid.
- Corpus luteum cysts usually measure from 2.5 to 5cm in size. The cyst contains bloody fluid and the wall often is yellow.

### Cytopathology

- Aspirated fluid from a follicular cyst contains many granulosa cells with round nuclei, coarse chromatin, and a small rim of cytoplasm. Nuclear grooves may be seen. Some cysts may also contain luteinized cells.
- Aspirated fluid from a corpus luteum cyst contains blood, haemosiderin-laden macrophages, and many fully luteinized granulosa cells. These are large polyhedral cells with abundant finely granular cytoplasm. The nuclei are round to oval with finely granular chromatin and prominent nucleoli. Nuclear grooves are not present.

### Histopathology

- Follicular cysts are lined by granulosa cells and theca cells which may show some luteinization.
- Corpus luteum cysts contain abundant central haemorrhage. The lining is composed of fully luteinized granulosa and theca cells.

### Prognosis

- Functional ovarian cysts are entirely benign. They are predominantly of clinical importance as large cysts may raise concern for a cystic neoplasm.

*This page intentionally left blank*

## Polycystic ovarian syndrome

### Definition

- A metabolic syndrome characterized by androgen excess, ovulatory failure, and in some women, polycystic ovaries.

### Epidemiology

- Common, affecting ~5% of women.

### Aetiology

- Insulin resistance appears to be the key underlying cause (Fig. 11.1).

### Pathogenesis

- Insulin resistance → obesity and ↑ androgen production by the ovaries.
- ↑ Androgens → hirsutism, acne, and abnormal follicle maturation.
- Abnormal follicle maturation → polycystic ovaries in some women.
- Chronic anovulation → subfertility and ↑ oestrogen production.
- Prolonged oestrogen exposure → endometrial hyperplasia and risk of development of endometrial intraepithelial neoplasia and endometrial carcinoma (📖 p. 196).

### Presentation

- Subfertility is a common presentation.
- Some women present with hirsutism and acne.

### Radiology

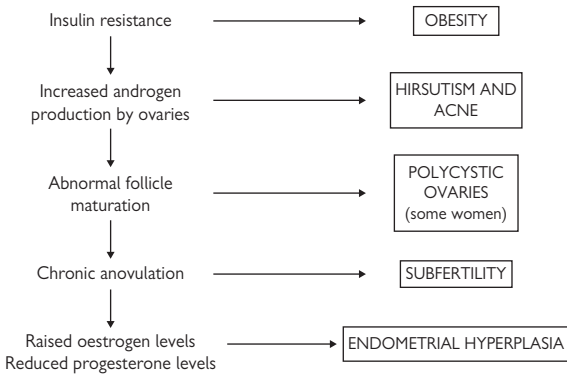
- Polycystic ovaries may be seen in some, but not all, women.

### Biochemistry

- Elevated blood androgens.
- Impaired glucose tolerance or frank diabetes.

### Prognosis

- The main issues are the complications associated with obesity and the risk of endometrial carcinoma.
- Weight reduction, insulin-lowering agents, and progesterone administration all act to reduce these complications.



**Fig. 11.1** Pathophysiology and clinical features of polycystic ovarian syndrome. Reproduced with permission from *Clinical Pathology*, Carton, Daly, and Ramani, Oxford University Press, p. 272, Figure 12.11.

## Benign ovarian tumours

### Mature cystic teratoma

- Benign germ cell ovarian tumour, also known as 'dermoid cyst'.
  - Occurs in young women with peak incidence between 20–29y old.
  - Many are asymptomatic and discovered incidentally, but larger tumours may cause pelvic pain. The most serious complication is torsion or rupture, leading to an acute abdomen.
  - Macroscopically, the tumour is cystic and contains greasy soft yellow material. Hair, cartilage, bone, and teeth may be visible.
  - Histologically, the tumour is comprised of mature adult-type tissues of virtually any type, including skin, brain, fat, smooth muscle, cartilage, respiratory, and gastrointestinal tissue.
- Note that most other germ cell ovarian tumours (e.g. dysgerminoma, immature teratoma) are much rarer, but behave in a malignant fashion.

### Serous cystadenoma

- Benign epithelial ovarian tumour which usually occurs in pre-menopausal women.
- May be picked up incidentally with symptoms of a pelvic mass or with an acute abdomen due to torsion.
- Macroscopically, it may be unilocular or multilocular. The cysts contain clear fluid and have a thin wall with a smooth lining.
- Histologically, the cysts are lined by a single layer of bland columnar cells which may be ciliated or non-ciliated.

### Mucinous cystadenoma

- Benign epithelial ovarian tumour which usually occurs in pre-menopausal women.
- May be picked up incidentally with symptoms of a pelvic mass or with an acute abdomen due to torsion.
- Macroscopically, the tumour is usually unilateral with a mean size of 10cm, but massive tumours have been reported. The tumour is composed of single or multiple cysts filled with gelatinous mucoid material.
- Histologically, the cysts are lined by a single layer of bland columnar cells which may be of endocervical type or intestinal type.

### Ovarian fibroma

- Benign sex-cord stromal ovarian tumour composed of fibroblasts and collagen.
- Occurs over a wide age range, though most are found in women >50y old. They are often small and discovered incidentally. Large tumour may cause abdominal pain and ascites.
- Macroscopically, the tumour is firm with a solid white cut surface.
- Histologically, the tumour is composed of bland spindled cells growing in a collagenous stroma.

### **Borderline epithelial ovarian tumours**

Borderline epithelial ovarian tumours are a group of epithelial tumours that exhibit more pronounced proliferation than benign epithelial tumours, but which tend to behave in an indolent fashion.

The vast majority of borderline epithelial tumours are serous in type (borderline serous tumours). Macroscopically, they are large, usually multilocular, cystic tumours that are frequently bilateral. The cysts often show many papillary excrescences growing from the surface. Histologically, the tumours are composed of complex branching papillae covered by proliferating columnar epithelial cells demonstrating low-grade nuclear atypia.

One curious feature of borderline serous tumours is the presence of small tumour 'implants' in the peritoneum or omentum in ~15–30% of cases. Histologically, these implants are divided into non-invasive and invasive types. Most are of the non-invasive type and these patients tend to have a favourable prognosis. Invasive implants are generally associated with an adverse prognosis, but are much rarer.

## Ovarian carcinomas

### Definition

- A group of malignant epithelial tumours arising in the ovary.

### Epidemiology

- Uncommon, but a leading cause of cancer-related death due to its late presentation.

### Aetiology

- High parity and oral contraceptive use are both consistently associated with a reduced risk of ovarian carcinoma.
- Post-menopausal women treated with oestrogen replacement therapy have an increased risk.
- Emerging evidence suggests obesity is associated with an increased risk.

### Carcinogenesis

- Recent morphological and genetic evidence suggest that ovarian carcinomas can be grouped into distinct categories according to their likely origin and behaviour.
- One group (low-grade serous, mucinous, Brenner) behave indolently and rarely show TP53 mutations. Some workers speculate that these tumours arise from paraovarian Mullerian epithelium through a sequence of benign cystadenoma → borderline neoplasm → invasive carcinoma.
- The second group (high-grade serous, high-grade endometrioid, undifferentiated carcinomas) are highly aggressive malignancies which frequently display TP53 mutations. Some workers speculate that these tumours may, in fact, arise in other pelvic organs (e.g. the Fallopian tubes) and secondarily involve the ovaries.
- Endometrioid and clear cell ovarian carcinomas are thought to arise from ovarian endometriosis.

### Presentation

- Abdominal pain, fatigue, abdominal distension, and diarrhoea.
  - The vague and non-specific nature of the symptoms often cause women to dismiss the symptoms as stress or menopause-related.
  - Women who do seek medical attention are easily misdiagnosed with benign gastrointestinal or urinary conditions.
- ▶ Most women have advanced disease by the time of diagnosis.

### Macroscopy

- The ovary is enlarged and replaced by a tumour mass which is often part solid and part cystic.
- Mucinous tumours may contain gelatinous material.

### Histopathology

- **Serous carcinomas** comprise malignant epithelial cells growing in irregular branching papillae and forming slit-like glandular spaces. Psammoma bodies may be present.

- **Endometrioid carcinomas** comprise malignant epithelial cells that form round or oval glands resembling endometrial carcinomas. Areas of squamous differentiation are common.
- **Mucinous carcinomas** comprise malignant epithelial cells with mucinous cytoplasm forming glandular structures. Distinguishing primary ovarian mucinous carcinoma from metastatic mucinous carcinoma from the gastrointestinal tract can be extremely difficult.
- **Clear cell carcinomas** comprise malignant epithelial cells with clear cytoplasm and hobnailing which grow in small tubules and papillae.
- **Transitional cell carcinomas** morphologically resemble urothelial carcinomas (📖 p. 172), but immunophenotypically are much more like serous carcinomas.

### Prognosis

- Generally poor as most women present with advanced disease (FIGO III and IV) which is associated with a 5-year survival of 25–30% (compared with 80–90% with FIGO I or II).

### FIGO staging of ovarian carcinomas

IA: tumour limited to one ovary; capsule intact, no tumour on the ovarian surface; no malignant cells in ascites or peritoneal washings.

IB: tumour limited to both ovaries; capsule intact, no tumour on the ovarian surface; no malignant cells in ascites or peritoneal washings.

IC: tumour limited to one or both ovaries with any of the following: capsule ruptured, tumour on the ovarian surface, malignant cells in ascites or peritoneal washings.

IIA: extension and/or implants on the uterus and/or tube(s); no malignant cells in ascites or peritoneal washings.

IIB: extension to other pelvic tissues; no malignant cells in ascites or peritoneal washings.

IIC: pelvic extension with malignant cells in ascites or peritoneal washings.

IIIA: microscopic peritoneal metastasis beyond the pelvis.

IIIB: macroscopic peritoneal metastasis beyond the pelvis, 2cm or less in size.

IIIC: peritoneal metastasis beyond the pelvis, >2cm in size and/or regional lymph node metastasis.

IV: distant metastasis.



## **Pelvic inflammatory disease**

### **Definition**

- An infection of the upper female genital tract.

### **Epidemiology**

- Most cases are seen in young sexually active women aged 15–25.
- True incidence is difficult to estimate as many cases go undiagnosed.

### **Aetiology**

- Most cases are caused by ascending infection by either *Chlamydia (C.) trachomatis* or *Neisseria (N.) gonorrhoeae*. Both organisms are sexually transmitted bacteria.
- Cases unrelated to sexually transmitted infection are often associated with intrauterine devices or retained products of conception post-partum or post-miscarriage.

### **Presentation**

- Usually, there are persistent symptoms of pelvic pain, dyspareunia, and post-coital or intermenstrual bleeding.
  - Severe cases may cause an acute illness with fever, abdominal pain, and peritonism.
- ▶ Note that many women are asymptomatic and go undiagnosed.

### **Complications**

- Infertility: the risk of infertility increases with each episode of infection. Women with three or more episodes of pelvic inflammatory disease (PID) have a 40% chance of being infertile.
- Ectopic pregnancy: there is a 6-fold increased risk, presumably due to tubal distortion and scarring.
- Chronic pelvic pain and dyspareunia.

# Ectopic pregnancy

## Definition

- Abnormal implantation of a fertilized ovum outside the uterine cavity. Nearly all occur in the Fallopian tubes, usually in the ampullary region. Other sites include the ovaries and abdominal cavity, but these are rare.

## Epidemiology

- Annual incidence is 12 per 1000 pregnancies and rising.

## Aetiology

- Tubal scarring from previous episodes of PID is the most common predisposing factor.
- Other risk factors include previous tubal surgery and endometriosis.
- About half occur for no apparent underlying reason.

## Pathogenesis

- Trophoblast implanting within the Fallopian tube causes intense haemorrhage into the tube.
- The embryo may be dislodged and shed or absorbed into the tubal wall.
- Rupture of the tubal wall may be sudden or gradual.

## Presentation

- The typical presentation is gradually increasing abdominal pain and vaginal bleeding.
  - Sudden rupture causes an acute abdomen with peritonism and shock.
- Consider the diagnosis in any woman of reproductive age with abdominal pain.

## Macroscopy

- The involved Fallopian tube is markedly dilated and congested.
- The tubal lumen is filled with blood and friable material.

## Histopathology

- Chorionic villi and infiltrating extravillous trophoblast are seen within the Fallopian tube.

## Prognosis

- Prognosis is good provided the diagnosis is made and appropriate management follows.
- Having one ectopic pregnancy is associated with a higher risk of future ectopics.

## Hydatidiform moles

### Definition

- A type of gestational trophoblastic disease characterized by abnormal trophoblastic proliferation. Two types are recognized: **complete moles** and **partial moles**.

### Epidemiology

- ~1 in 1000 pregnancies in the western world is molar.
- For unknown reasons, they are much commoner in areas of the Far East where incidence rates are as high as 1 in 80.

### Genetics

- Complete moles are usually diploid (46 XX or 46 XY) with all chromosomes being paternally derived. They arise from fertilization of an anucleate ovum by a haploid sperm which then duplicates its genetic material.
- Partial moles are triploid (69 XXY, 69 XXX, or 69 XYY) with one set of maternal chromosomes and two sets of paternal chromosomes. They arise from fertilization of an ovum by two sperms.

### Presentation

- Most present with early miscarriage. Usually, there is no clinical suspicion of molar pregnancy, the diagnosis being made following histopathological examination of the evacuated products of conception.

### Macroscopy

- Most molar products of conception are grossly unremarkable.
- Cases presenting late may contain visibly hydropic villi.

### Histopathology

- Complete moles show villi with a characteristic lobulated 'budding' architecture. The villi have a myxoid stroma containing collapsed empty blood vessels and karyorrhectic debris. There is abnormal non-polar trophoblastic hyperplasia and sheets of pleomorphic extravillous trophoblast may be present. A prominent implantation site reaction is often seen, but with the absence of the normal trophoblast plugging of decidual blood vessels.
- Partial moles show villi with irregular, 'dentate', or 'geographic' outlines. The villi are often fibrotic and contain prominent villous pseudo-inclusions and villous blood vessels with nucleated fetal red cells. Abnormal non-polar trophoblastic hyperplasia is present, though this is usually focal and less marked than in complete moles. The implantation site is usually unremarkable with normal trophoblast plugging of decidual blood vessels.

### Prognosis

- In most cases, evacuation of molar tissue is curative and  $\beta$ HCG levels rapidly fall to normal. Persistence of  $\beta$ HCG levels is indicative of persistent gestational trophoblastic disease; this complicates ~15% of complete moles and ~1% of partial moles and requires chemotherapy to cure.

**Gestational choriocarcinoma**

One other type of gestational trophoblastic disease is choriocarcinoma, a rare, but highly malignant, trophoblastic tumour. About half develop from a preceding hydatidiform mole with the remainder following a normal pregnancy or non-molar miscarriage.

Histologically, choriocarcinomas are composed of a mixture of cytotrophoblast and syncytiotrophoblast, typically forming bilaminar structures. By definition, chorionic villi are absent.

Choriocarcinomas have a great propensity for vascular invasion, leading to early dissemination to multiple distant sites. Fortunately, gestational choriocarcinomas respond extremely well to chemotherapy and the prognosis for most women is very good.

## Pre-eclampsia

### Definition

- Pregnancy-induced hypertension with proteinuria.

### Epidemiology

- Complicates ~5% of pregnancies.
- More frequent in women carrying their first child.

### Aetiology

- Abnormal placentation is the key underlying problem (Fig. 11.2).

### Pathogenesis

- Abnormally shallow invasion of trophoblast with failure of physiological conversion of intradecidual spiral arteries and basal arteries into large low resistance vessels.
- Maternal blood pressure rises in an attempt to compensate, but the net result is placental ischaemia.
- Toxic substances released from the ischaemic placenta enter the maternal circulation and cause endothelial damage.
- Progression to eclampsia is heralded by widespread formation of fibrin thrombi within the microcirculation and risk of renal failure, hepatic failure, cardiac failure, and cerebral haemorrhage.

### Presentation

- Most women are diagnosed when routine antenatal surveillance picks up hypertension after 20 weeks gestation together with proteinuria.

### Macroscopy

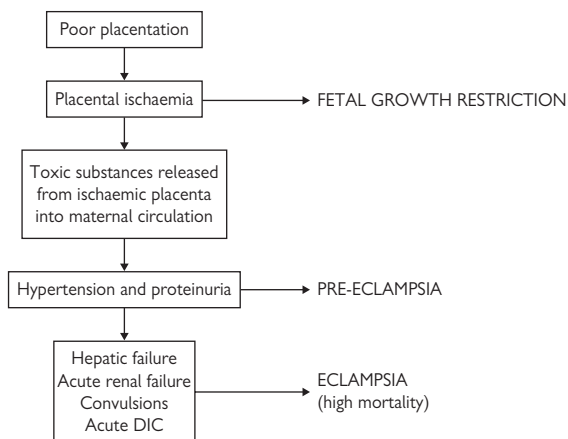
- Placentas tend, on average, to be smaller than those from normal pregnancies.
- The incidence of placental infarcts is much higher.

### Histopathology

- Placental villi show increased number and prominence of villous cytotrophoblast with irregular thickening of the basement membrane. Villous blood vessels are often small and inconspicuous. Maternal decidual arteries show failure of physiological conversion by trophoblast. A minority also show fibrinoid necrosis of the arterial wall together with intramural accumulation of lipid-laden macrophages ('atherosis').
- The kidneys show enlarged 'bloodless' glomeruli containing swollen endothelial cells. Fibrin microthrombi may be seen within glomerular capillary loops in more severe cases.
- The liver may show fibrin thrombi in hepatic sinusoids with hepatic necrosis and haemorrhage in severe cases.

### Prognosis

- ▶ Delivery is the only cure for pre-eclampsia. The danger to the fetus from premature delivery must be weighed against the risks to the mother. The disease behaves very unpredictably and can progress very rapidly so patients must be closely monitored for signs of deterioration.



**Fig. 11.2** Postulated pathogenesis of pre-eclampsia. Reproduced with permission from *Clinical Pathology*, Carton, Daly, and Ramani, Oxford University Press, p. 282, Figure 12.18.

*This page intentionally left blank*

# Breast pathology

- Duct ectasia 216
- Acute mastitis 217
- Fat necrosis 218
- Fibrocystic change 219
- Fibroadenoma 220
- Intraductal papilloma 222
- Radial scar 223
- Proliferative breast diseases 224
  - Ductal carcinoma *in situ* 225
  - Invasive breast carcinomas 226
- Breast screening 228
- Male breast diseases 229



## Duct ectasia

### Definition

- Inflammation and dilation of large breast ducts.

### Epidemiology

- Common in adult women of all ages.

### Aetiology

- Unclear.
- Whilst infection may complicate duct ectasia, it does not seem to be the underlying cause.

### Presentation

- Nipple discharge is the most common presenting symptom. The discharge may be clear, creamy, or bloodstained.
- More florid cases may cause pain, a breast mass, and nipple retraction.

### Macroscopy

- Subareolar ducts are visibly dilated and contain thick secretions.

### Cytopathology

- Smears prepared from a sample of nipple discharge contain proteinaceous debris and macrophages.
- Ductal epithelial cells are usually not seen.

### Histopathology

- Subareolar ducts are dilated and filled with proteinaceous material and macrophages.
- Periductal chronic inflammation and fibrosis are also seen.

### Prognosis

- Duct ectasia is a benign condition with no increased risk of malignancy.

## Acute mastitis

### Definition

- Acute inflammation in the breast.

### Epidemiology

- Common.
- Most are associated with either lactation or duct ectasia.

### Microbiology

- Staphylococci and streptococci in lactating women.
- Staphylococci or anaerobic organisms in women with duct ectasia.

### Pathogenesis

- It is thought that cracks in the skin allow bacterial access to the breast and stasis of milk promotes the establishment of infection.

### Presentation

- A painful red breast is the most common presentation.
- Abscess formation may produce a breast mass.

### Macroscopy

- A florid area of acute mastitis may produce a palpable mass.
- Purulent material may be present with abscess formation.

### Cytopathology

- Fine needle aspiration (FNA) of an inflammatory breast mass usually yields purulent material which microscopically contains abundant neutrophils.

### Histopathology

- Acute inflammation is present within the breast parenchyma. Confluence of the acute inflammatory process may form an abscess cavity.
- The adjacent breast tissue may show lactational change or duct ectasia.

### Prognosis

- Drainage and appropriate antibiotic treatment usually results in resolution.

## Fat necrosis

### Definition

- An inflammatory reaction to damaged adipose tissue.

### Epidemiology

- Common.

### Aetiology

- Trauma to the breast.
- Post-surgery or radiotherapy.

### Pathogenesis

- Damaged adipocytes spill their lipid contents, resulting in an inflammatory reaction which gives rise to a palpable mass.

### Presentation

- Most present with a breast mass which feels firm and thickened.
- ▶ Can closely mimic breast carcinoma clinically.

### Macroscopy

- The breast tissue shows yellow-white flecks of discoloration.

### Cytopathology

- FNA cytology show foamy macrophages, multinucleated giant cells, and background debris.

### Histopathology

- Degenerating adipocytes are present surrounded by foamy macrophages, multinucleated giant cells, lymphocytes, and plasma cells.
- Later changes include fibrosis and calcification.

### Prognosis

- Benign with no increased risk of breast cancer.

# Fibrocystic change

## Definition

- A number of alterations within the breast, which reflect normal, albeit exaggerated, responses to hormonal influences.

## Epidemiology

- Very common.
- Found in more than one third of pre-menopausal adult women.

## Aetiology

- A hormonally-driven condition in response to oestrogens.

## Pathogenesis

- Somewhat unclear, though some workers speculate that the initial event is apocrine metaplasia of breast ducts.
- Secretions produced by these cells lead to duct dilation and formation of cysts.

## Presentation

- Breast nodularity and lumpiness is the main feature.
- There may also be cyclical tenderness.

## Macroscopy

- The breast tissue has a firm rubbery texture.
- Visible cysts are usually evident with a brown or bluish hue.

## Cytopathology

- Aspirates of cysts show debris, foamy macrophages, and apocrine cells.
- Aspirates of non-cystic areas contain cohesive fragments of bland ductal epithelial cells and many background bare bipolar nuclei.

## Histopathology

- Associated with a number of histological changes, including cystic change, apocrine metaplasia, adenosis, mild epithelial hyperplasia, and stromal hyperplasia.

## Prognosis

- Benign with no increased risk for subsequent invasive breast carcinoma.

## Fibroadenoma

### Definition

- A benign fibroepithelial tumour of the breast.

### Epidemiology

- Common.
- Occurs mostly in young women aged 20–30y old.

### Aetiology

- Most authorities believe them to be neoplastic growths of fibroblasts within the specialized connective tissue of the intralobular stroma.

### Pathogenesis

- As the neoplastic fibroblasts multiply within the intralobular stroma, they entrap and compress terminal duct lobular units and interlobular stroma to form a well-circumscribed nodular mass.

### Macroscopy

- Well-circumscribed mobile breast masses which usually measure 3cm or less.
- The cut surface is usually solid, whorled, and grey-white in colour.

### Cytopathology

- Aspirates are cellular, containing many branching sheets of cohesive bland ductal epithelial cells and abundant bare bipolar nuclei in the background.
- Fragments of stromal material may also be seen.

### Histopathology

- Histology shows a multinodular mass which is well demarcated from the surrounding breast tissue.
- Each nodule contains an expanded myxoid intralobular stromal compartment containing bland spindled fibroblastic cells. The terminal duct lobular unit is compressed into slit-like channels.
- Narrow strands of interlobular stroma are present between each nodule of the fibroadenoma.
- Older lesions often show fibrosis and calcification.

### Prognosis

- Benign lesions with no capacity for malignant behaviour.
- Surgical excision with simple 'shelling out' is virtually always curative with little chance of recurrence.

### Phyllodes tumours

Phyllodes tumours are a group of potentially aggressive fibroepithelial tumours. They are uncommon tumours which usually present as a growing breast mass in women aged >50y. Some are thought to arise with pre-existing fibroadenomas.

Macroscopically, the tumours are usually large fleshy lobulated masses with areas of cystic change.

Histologically, they are fibroepithelial tumours in which the neoplastic stromal cells overgrow the epithelial component, leading to a disorganized, heterogeneous appearance. The stroma shows variation in cellularity and composition of the extracellular matrix. Large stromal nodules projecting into cystic spaces produce characteristic 'leaf-like' fronds.

All phyllodes tumours have the potential for local recurrence and are usually treated by wide local excision. In practice, most do not recur, even following simple enucleation. Phyllodes tumours can develop the capacity to metastasize, but this is very rare.

## Intraductal papilloma

### Definition

- A benign papillary tumour arising within the duct system of the breast. Papillomas can develop anywhere in the ductal system, but show a predilection for either small terminal ductules (peripheral papillomas) or the large lactiferous ducts (central papillomas).

### Epidemiology

- Common.
- Seen mostly in women in their 40s and 50s.

### Aetiology

- Believed to be neoplastic growths of glandular and stromal breast tissue.

### Presentation

- Most women with central papillomas present with nipple discharge.
- Small peripheral papillomas usually present with a breast mass.

### Macroscopy

- Large papillomas are visible as friable masses within a dilated duct.

### Cytopathology

- Smears prepared from nipple discharge may contain branching papillaroid groups of epithelial cells which suggest the diagnosis.

### Histopathology

- A papillary mass is present with a duct space.
- The papillae are broad and rounded such that the fronds fit neatly around each other.
- Each frond contains abundant stroma composed of blood vessels and fibrous tissue.
- The epithelium covering the fronds is double-layered, composed of inner columnar epithelial cells and outer myoepithelial cells.

### Prognosis

- Benign lesions, though some studies have suggested that women with papillomas have a 2-fold increased risk of subsequent invasive breast carcinoma.

# Radial scar

## Definition

- A benign sclerosing breast lesion characterized by a central zone of scarring surrounded by a radiating rim of proliferating glandular tissue.
- Radial scars range in size from tiny microscopic lesions to larger clinically apparent masses. Large lesions >1cm in size are sometimes called 'complex sclerosing lesions'.

## Epidemiology

- Radial scars are reasonably common lesions.
- Incidence rates vary widely, depending on how they are defined.

## Aetiology

- Little is known about the aetiology or pathogenesis of radial scars.
- One hypothesis is that they represent a reparative phenomenon in response to areas of tissue damage in the breast.

## Presentation

- Large radial scars are usually detected on mammography as stellate or spiculated masses.
- ▶ They can closely mimic the appearance of a carcinoma.

## Macroscopy

- Grossly, radial scars are stellate firm masses which appear to infiltrate the surrounding parenchyma.
- They may be easily confused for invasive carcinomas macroscopically.

## Histopathology

- Radial scars are symmetrical stellate breast lesions with a characteristic zonal architecture.
- The centre of the lesion (the nidus) comprises dense collagen bundles and elastic tissue in which there are entrapped, haphazardly arranged tubules.
- Surrounding the nidus are radially arranged clusters of ducts and lobules, each of which points towards the centre of the lesion. The ducts and lobules within this zone typically exhibit florid benign changes, including fibrocystic change, sclerosing adenosis, and marked usual epithelial hyperplasia.

## Prognosis

- Radial scars are considered to be benign lesions, but their presence has been associated with a 2-fold increased risk of subsequent development of breast cancer.



## Proliferative breast diseases

### Definition

- A diverse group of intraductal proliferative lesions of the breast associated with an increased risk, of greatly different magnitudes, for subsequent development of invasive breast carcinoma.

### Epidemiology

- Very common.
- Incidence higher since the introduction of breast screening programmes.

### Aetiology

- Similar to invasive breast carcinoma (📖 p. 226).

### Genetics

- Most cases of flat epithelial atypia and *in situ* lobular neoplasia show genetic abnormalities, most notably the loss of heterozygosity of chromosome 16p.
- Only a minority of cases of usual epithelial hyperplasia show genetic abnormalities.

### Macroscopy

- The vast majority are picked up either on screening mammography or incidentally in breast tissue removed for other reasons.

### Histopathology

- **Usual epithelial hyperplasia** is a haphazard proliferation of immature ductal epithelial cells which form slit-like spaces.
- **Flat epithelial atypia** is a uniform proliferation of mildly atypical ductal epithelial cells no more than five cells thick. This is thought to be the earliest morphological precursor to low-grade ductal carcinoma *in situ*.
- ***In situ* lobular neoplasia** is a proliferation of small poorly cohesive epithelial cells characterized by the loss of E-cadherin expression immunohistochemically.

### Prognosis

- Usual epithelial hyperplasia is not considered a direct precursor lesion to invasive breast carcinoma, but is a marker for a slightly increased risk (relative risk of 1.5–2.0) for subsequent invasive carcinoma.
- No quantitative data are currently available on the relative risk for future development of invasive breast carcinoma in patients with flat epithelial atypia. Emerging genetic data suggest flat epithelial atypia may represent the earliest morphological precursor to low-grade ductal carcinoma *in situ*.
- Current evidence suggests that *in situ* lobular neoplasia is a risk factor for subsequent invasive breast carcinoma in either breast in a minority of women. The relative risk is quoted as between 7–12 times that expected in women without lobular neoplasia.

## Ductal carcinoma *in situ*

### Definition

- Neoplastic intraductal epithelial proliferation in the breast with inherent, but not inevitable, risk of progression to invasive breast carcinoma.

### Epidemiology

- Common.
- Incidence has markedly increased since the introduction of breast screening programmes.

### Aetiology

- Risks similar to invasive breast carcinoma (📖 p. 226).

### Genetics

- Low-grade ductal carcinoma *in situ* (DCIS) often shows loss of homozygosity at 16p.
- High-grade DCIS is genetically distinct with a more complex karyotype.

### Presentation

- 85% are detected on mammography as areas of microcalcification.
- 10% produce clinical findings such as a lump, nipple discharge, or eczematous change of the nipple (**Paget's disease of the nipple**).
- 5% are diagnosed incidentally in breast specimens removed for other reasons.

### Macroscopy

- DCIS is often macroscopically invisible, even to an experienced pathologist.
- Extensive high-grade DCIS may be visible as gritty yellow flecks due to calcified necrotic debris in the involved ducts.

### Histopathology

- DCIS is subclassified into low, intermediate, and high nuclear grade.
- **Low-grade DCIS** has small monotonous cells growing in cribriform, solid, or micropapillary patterns with good cellular polarization (cells have basally positioned nuclei and apical cytoplasm directed towards the duct lumen). Necrosis in the centre of the duct is unusual.
- **Intermediate-grade DCIS** has cells with moderately sized nuclei and coarse chromatin growing in solid, cribriform, or micropapillary patterns with a moderate degree of cellular polarization. Central necrosis may be present.
- **High-grade DCIS** has cells with large, markedly pleomorphic nuclei with clumped chromatin, prominent nucleoli, and poor cellular polarization. Central necrosis is common.

### Prognosis

- Complete surgical excision with clear margins is curative. Prognosis depends on the persistence of any neoplastic cells after treatment. Recurrence is more likely with extensive disease, high nuclear grade, and the presence of comedo necrosis.

## Invasive breast carcinomas

### Definition

- A group of malignant epithelial tumours which infiltrate within the breast and have the capacity to spread to distant sites.

### Epidemiology

- The most common cancer in women with a lifetime risk of 1 in 8.
- Incidence rates rise rapidly with increasing age such that most cases occur in older women.

### Aetiology

- Early menarche, late menopause, increased weight, high alcohol consumption, oral contraceptive use, and a positive family history are all associated with increased risk.
- ~5% show clear evidence of inheritance. BRCA mutations cause a lifetime risk of invasive breast carcinoma of up to 85%.

### Carcinogenesis

- Recent genetic studies have led to the hypothesis that breast cancer evolution is broadly classified into two groups.
- The low-grade group (e.g. low-grade invasive ductal carcinoma, classical lobular carcinoma, mucinous carcinoma, tubular carcinoma) express hormone receptors, do not overexpress HER2, and do not express basal markers. Genetically, they have simple diploid or near diploid karyotypes and as a hallmark, show deletion of 16q and gains of 1q.
- The high-grade group (e.g. high-grade invasive ductal carcinoma, basal-like carcinoma) frequently lack hormone receptors, overexpress HER2, and express basal markers. Genetically, they have complex karyotypes with many unbalanced chromosomal aberrations. Frequent changes include loss of 1p, 8p, and 17p and gains of 1q and 8q.

### Presentation

- Most cases present symptomatically with a breast lump.
- An increasing proportion of asymptomatic cases are detected on screening mammography.

### Macroscopy

- Most breast carcinomas produce a firm stellate mass in the breast.

### Cytopathology

- FNA from breast carcinomas are typically highly cellular, containing a poorly cohesive population of malignant epithelial cells. Background bare bipolar nuclei are absent.

### Histopathology

- **Invasive ductal carcinomas** (80%) are infiltrating carcinomas which do not exhibit sufficient characteristics to achieve classification as a specific histological type such as lobular or tubular carcinoma (hence, they are also sometimes referred to as 'no special type'). They, therefore, represent a heterogenous group of tumours rather than

a distinct type. It is likely in the future that this group will become divided up into more meaningful entities on the basis of their genetic profiles.

- **Invasive lobular carcinomas** (15%) are composed of small, poorly cohesive cells with scant cytoplasm, which characteristically grow in linear cords and encircle pre-existing normal ducts.
- **Tubular carcinomas** (5%) are composed of well-formed tubular structures lined by a single layer of epithelial cells with low-grade atypia.
- **Mucinous carcinomas** (5%) are characterized by the production of abundant quantities of mucin within which the tumour cells float.
- **Basal-like carcinomas** are a recently described group of tumours discovered by the genetic profiling of large numbers of breast carcinomas. They often occur in young women and are linked to BRCA mutations. Morphologically, they typically show sheets of highly atypical epithelial cells with a prominent lymphocytic inflammatory infiltrate and central necrosis. Immunohistochemically, they are characterized by the expression of basal-type keratins, e.g. cytokeratins 5 and 14. Basal-like tumours are frequently ER- and PR-negative and Her2 non-amplified (so-called 'triple negative' tumours). These tumours appear to have a propensity to visceral metastasis, notably to the lungs and brain.

### Grading

- All invasive breast cancers are graded histologically by assessing nuclear pleomorphism, tubule formation, and mitotic activity.
- Each parameter is scored from 1 to 3 and the three values are added together to produce total scores from 3 to 9.
- 3–5 points = grade 1 (well differentiated).
- 6–7 points = grade 2 (moderately differentiated).
- 8–9 points = grade 3 (poorly differentiated).

### Prognosis

- The single most important prognostic factor is the status of the axillary lymph nodes.
- Other important factors include tumour size, histological type, and histological grade.

### Simplified TNM 7 pathological staging of breast carcinomas

#### Primary tumour (T)

pT1: tumour 2cm or less in size.

pT2: tumour >2cm, but not >5cm in size.

pT3: tumour >5cm in size.

pT4: tumour of any size with extension to the chest wall and/or skin.

#### Regional lymph nodes (N)

pN0: no regional lymph node metastasis.

pN1: metastasis in 1–3 ipsilateral axillary lymph nodes.

pN2: metastasis in 4–9 ipsilateral axillary lymph nodes.

pN3: metastasis in 10 or more ipsilateral axillary lymph nodes.

## Breast screening

► The aim of screening is to pick up DCIS or early invasive carcinoma.

### NHS breast screening programme

- Women aged 50–70 are invited for screening every 3y.
- By 2012, this will be extended to women aged 47–73.
- The screening test is a mammogram which looks for abnormal areas of calcification or a mass within the breast.

### Assessment clinic

- ~5% of women have an abnormal mammogram and are recalled to an assessment clinic for further investigation.
- This may include more mammograms or an ultrasound followed by sampling of the abnormal area, usually by core biopsy.

### Histopathology

- Core biopsies taken from breast screening patients are given a B code from 1 to 5.
- B1 is normal breast tissue. This usually implies the biopsy missed the area of interest.
- B2 is a core containing a benign abnormality. This is appropriate for a range of lesions, including fibroadenomas, fibrocystic change, sclerosing adenosis, and fat necrosis.
- B3 is a lesion of uncertain malignant potential. This category mainly consists of lesions which may be benign in the core, but are known to show heterogeneity or to have an increased risk (albeit low) of an adjacent malignancy. This is appropriate for cores showing flat epithelial atypia, *in situ* lobular neoplasia, atypical ductal hyperplasia, partly sampled papillomas, phyllodes tumours, and radial scars.
- B4 is a core showing features suspicious of malignancy, but in which unequivocal diagnosis is not possible due to reasons such as insufficient abnormal tissue or crushing of the biopsy.
- B5 is a core biopsy showing unequivocal features of malignancy. This is subdivided into B5a for DCIS or B5b for invasive carcinoma.

### Management

- B1: rebiopsy.
- B2: reassure and return to normal recall.
- B3: excision of the abnormal area.
- B4: rebiopsy or excision of the abnormal area.
- B5: surgical excision with wide local excision or mastectomy.

### Effectiveness

- Published figures state that the NHS breast screening programme saves about 1,250 lives each year.

## Male breast diseases

### Gynaecomastia

- Refers to the enlargement of the male breast.
- Usually seen in boys around puberty and older men aged >50.
- Most cases are either idiopathic or associated with drugs (both therapeutic and recreational).
- Histologically, the breast ducts show epithelial hyperplasia with typical finger-like projections extending into the duct lumen. The periductal stroma is often cellular and oedematous.
- The condition is benign with no increased risk of malignancy.

### Male breast cancer

- Carcinoma of the male breast is rare (0.2% of all cancers).
- The median age at diagnosis is 65y old.
- Most patients present with a palpable lump.
- Grossly, the tumours are firm irregular masses.
- Histologically, the tumours show similar features to female breast cancers.

*This page intentionally left blank*

# Endocrine pathology

- Diabetes mellitus 232
- Hashimoto's thyroiditis 234
- Graves' disease 235
- Nodular goitre 236
- Follicular adenoma 237
- Thyroid carcinomas 238
- Parathyroid hyperplasia 240
- Parathyroid adenoma 241
- Parathyroid carcinoma 242
- Addison's disease 243
- Adrenal cortical adenoma 244
- Adrenal cortical carcinoma 246
- Phaeochromocytoma 248
- Neuroblastoma 250
- Pituitary adenoma 252



# Diabetes mellitus

## Definition

- A metabolic disorder characterized by chronic hyperglycaemia due to lack of insulin.

## Epidemiology

- Very common, affecting ~2% of the population.
- Rising in incidence.

## Aetiology

- Type 1 diabetes is due to the autoimmune destruction of insulin-producing beta cells by CD4+ and CD8+ T-lymphocytes. Autoantibodies against beta cells and insulin may also be relevant.
- Type 2 diabetes is strongly related to obesity and insulin resistance. Initially, the pancreas compensates for insulin resistance by increasing insulin secretion, but eventually beta cells suffer 'secretory exhaustion' and insulin levels then become inappropriately low.

## Pathogenesis

- Lack of insulin drives the mobilization of energy stores from muscle, fat, and the liver (Fig. 13.1).
- Glucose accumulates in the blood, causing hyperglycaemia.
- In the kidneys, the glucose reabsorption mechanism becomes saturated and glucose appears in the urine.
- Glucose within renal tubules draws water in by osmosis, leading to osmotic diuresis.
- The raised plasma osmolality stimulates the thirst centre.
- Over time, diabetes damages capillaries and markedly accelerates atherosclerosis.

## Presentation

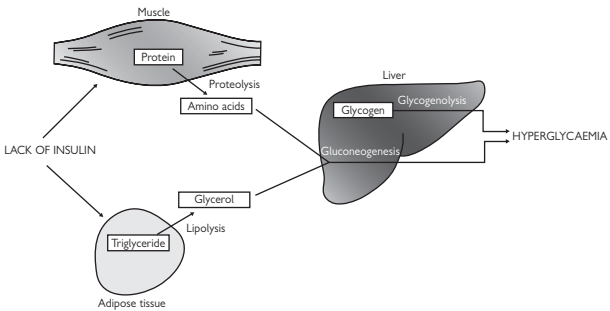
- Polyuria and polydipsia are the classic symptoms of diabetes mellitus.
- Hyperglycaemia also predisposes to recurrent skin and urinary tract infections.
- Type 1 diabetics may present acutely in diabetic ketoacidosis.

## Biochemistry

- Fasting plasma glucose >7.0mmol/L or a random plasma glucose >11.1mmol/L.
- Patients with borderline values should have an oral glucose tolerance test.

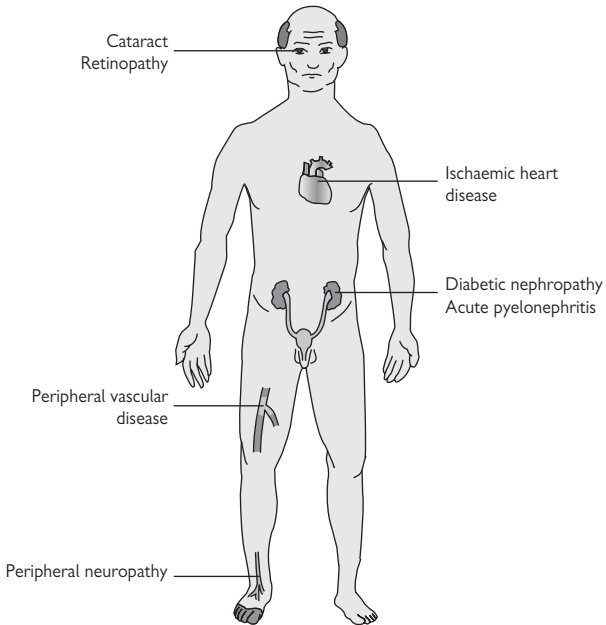
## Complications

- A number of organ systems are at risk in diabetes (Fig. 13.2).
- Ischaemic heart disease due to severe coronary artery atherosclerosis.
- Chronic kidney disease due to diabetic nephropathy (p. 146).
- Blindness due to cataract formation and diabetic retinopathy.
- Peripheral vascular disease due to atherosclerosis.
- Foot ulceration due to peripheral neuropathy and ischaemia.



**Fig. 13.1** Mechanism of hyperglycaemia in diabetes mellitus. Lack of insulin causes the breakdown of protein in muscle and of triglyceride in fat, providing substrates for gluconeogenesis in the liver. This, together with glucose formed from glycogen in the liver, causes hyperglycaemia.

Reproduced with permission from *Clinical Pathology*, Carton, Daly, and Ramani, Oxford University Press, p. 324, Figure 14.13.



**Fig. 13.2** Long-term complications of diabetes mellitus.

Reproduced with permission from *Clinical Pathology*, Carton, Daly, and Ramani, Oxford University Press, p. 326, Figure 14.14.

## Hashimoto's thyroiditis

### Definition

- An autoimmune thyroid disease characterized by diffuse enlargement of the thyroid and high titres of thyroid autoantibodies.

### Epidemiology

- Common, affecting ~1% of the population.
- Predominantly occurs in middle-aged women.

### Aetiology

- Unknown.

### Pathogenesis

- Activated CD4+ helper T-cells recruit CD8+ cytotoxic T-cells which destroy thyroid follicular epithelial cells.
- Anti-thyroid autoantibodies produced by activated B-cells may also contribute.

### Presentation

- Diffuse firm goitre and features of hypothyroidism.

### Biochemistry

- ↑ Thyroid-stimulating hormone (TSH) and ↓ T4.
- Autoantibodies against thyroglobulin, thyroid peroxidase, and TSH receptor are usually present. Note the latter antibody is different from that seen in Graves' disease as it blocks the TSH receptor rather than activates it.

### Macroscopy

- The thyroid is diffusely enlarged and nodular.
- The cut surface is often soft and white, resembling lymphoid tissue.


### Cytopathology

- Aspirates are cellular, containing abundant lymphoid cells and scanty follicular epithelial cells showing Hurthle cell change.
- Hurthle cells have abundant granular cytoplasm and enlarged nuclei with vesicular chromatin.

### Histopathology

- The thyroid shows diffuse heavy lymphoid infiltration with the formation of germinal centres.
- Thyroid follicles are atrophic and show widespread Hurthle cell change characterized by abundant eosinophilic granular cytoplasm and nuclear enlargement.

### Prognosis

- Good with thyroxine replacement therapy.
- ▶ There is an increased incidence of thyroid lymphoma, usually extranodal marginal zone B-cell lymphoma ( p. 279).

# Graves' disease

## Definition

- An autoimmune thyroid disease characterized by thyrotoxicosis and diffuse hyperplasia of the thyroid.

## Epidemiology

- Common, affecting up to 1% of the population.
- Peak incidence is in young adults in their 30s and 40s.
- Women are affected much more frequently than men.

## Aetiology

- Production of TSH receptor-stimulating antibodies.

## Pathogenesis

- TSH receptor-stimulating antibodies bind to the TSH receptor and activate it, stimulating hyperplasia of the thyroid follicular epithelium and unregulated secretion of thyroid hormones.

## Presentation

- Patients present with thyrotoxicosis and a diffuse goitre.
- Some patients also develop a form of orbital disease known as Graves' ophthalmopathy

## Macroscopy

- The thyroid is diffusely enlarged with a firm red cut surface.
- If treatment has been administered, the thyroid may show a nodular appearance.

## Cytopathology

- Aspirates are highly cellular with little colloid and many follicular epithelial cells showing hyperplastic changes.
- In practice, aspiration is rarely performed in cases of active Graves' disease as the diagnosis is usually straightforward clinically. This is fortunate as the highly cellular aspirates can easily be mistaken for a neoplastic process by the unwary.

## Histopathology

- The thyroid shows diffuse hyperplasia with loss of colloid and marked hyperplastic changes of the follicular epithelium.
- A variable lymphoid infiltrate, with or without germinal centres, is usually present.

## Prognosis

- Excellent with appropriate thyroid ablative therapy.

## Nodular goitre

### Definition

- Nodular enlargement of the thyroid gland.

### Epidemiology

- Very common.
- Clinically apparent nodular goitre affects up to 5% of the population.

### Aetiology

- Many cases are thought to be due to mild genetic defects in components of the thyroid hormone synthetic apparatus.

### Pathogenesis

- Reduced levels of thyroid hormones stimulate the release of TSH from the anterior pituitary.
- Repetitive cycles of stimulation and involution causes the development of multiple nodules within the thyroid.

### Presentation

- A palpably enlarged, nodular goitre.
- Most patients are euthyroid.

### Macroscopy

- The thyroid gland is enlarged and multinodular.
- Slicing reveals numerous unencapsulated nodules of varying size, usually containing abundant colloid.
- Areas of cystic change, haemorrhage, and calcification are common.

### Cytopathology

- Aspirates contain abundant colloid with scanty thyroid follicular epithelium.
- Haemosiderin-laden macrophages may be present due to previous haemorrhage.
- Foamy macrophages often indicate cystic change within a nodule.

### Histopathology

- The thyroid contains numerous nodules of varying sizes with areas of cystic change and haemorrhage.
- The follicles within the nodules are heterogeneous in appearance. Some are markedly distended with colloid, some appear hyperplastic, whilst others are small and tightly packed, forming cellular 'adenomatoid' nodules.

### Prognosis

- Nodular goitre is a benign condition with no reported increased risk of development of thyroid carcinoma.
- The main potential complication is compression of nearby structures such as the trachea by a markedly enlarged nodular goitre.

# Follicular adenoma

## Definition

- A benign encapsulated thyroid tumour showing follicular differentiation.

## Epidemiology

- The most common thyroid neoplasm.
- The true incidence is difficult to analyze due to a lack of consistent criteria in distinguishing follicular adenomas from cellular adenomatoid nodules in nodular goitres.

## Aetiology

- Associated with radiation exposure and iodine deficiency.

## Genetics

- Chromosomal trisomies (particularly trisomy 7) are the most frequent type of genetic aberration.

## Presentation

- Most present with a solitary thyroid nodule, either palpated by the patient or picked up incidentally on imaging.
- Spontaneous haemorrhage into an adenoma may cause acute pain and enlargement of the nodule.

## Macroscopy

- The thyroid contains a well-demarcated thinly encapsulated solid nodule with a grey, tan, or brown cut surface.

## Cytopathology

- Aspirates are cellular, containing numerous follicular cells and little colloid.
- The follicular cells are both dissociated and present in small microfollicular arrangements.

► Note that it is not possible to distinguish between follicular adenoma and follicular carcinoma on cytology. This can only be done histologically.

## Histopathology

- Follicular adenomas are encapsulated epithelial tumours showing follicular differentiation.
- By definition, there is no capsular or vascular invasion.

## Prognosis

- Follicular adenomas are benign lesions which are cured by excision.

## Thyroid carcinomas

### Definition

- A group of malignant epithelial tumours arising in the thyroid. Four major types are recognized: **papillary, follicular, medullary, and anaplastic**.

### Epidemiology

- Uncommon, accounting for ~1% of all malignancies in developed countries.
- Mean age at diagnosis is mid-40s to early 50s for the papillary type, 50s for the follicular and medullary types, and 60s for the anaplastic type.

### Aetiology

- Radiation exposure is a well-documented risk factor for thyroid carcinoma, most notably papillary carcinoma. Iodine deficiency is also a factor, particularly with follicular carcinomas. ~25% of medullary carcinomas are linked to the inherited syndromes, multiple endocrine neoplasia (MEN) 2A, MEN 2B, and familial medullary thyroid cancer (FMTC).

### Carcinogenesis

- RET and TRK mutations are typical of papillary carcinomas.
- Follicular carcinomas usually demonstrate RAS mutations.
- TP53 mutations are common in anaplastic carcinomas.

### Presentation

- Most well-differentiated thyroid carcinomas present with a solitary thyroid nodule. Thyroid function is usually normal. Anaplastic carcinoma usually presents with a rapidly enlarging neck mass; involvement of nearby structures causes hoarseness, dysphagia, and dyspnoea.

### Macroscopy

- Papillary carcinomas are usually grey-white firm masses with irregular borders. They are often multifocal.
- Follicular carcinomas are usually encapsulated round solid tumours with a tan to brown colour.
- Medullary carcinomas are firm grey-white to tan tumours, often described as having a gritty consistency.
- Anaplastic carcinomas are large soft necrotic masses which usually replace the thyroid and extensively invade adjacent tissues.

### Cytopathology

- Papillary carcinoma aspirates contain papillary fragments of follicular epithelial cells with the characteristic nuclear features of papillary carcinoma, i.e. powdery chromatin, thick nuclear membranes, nuclear grooves, and nuclear pseudoinclusions. Multinucleated giant cells, psammoma bodies, and thick colloid may be present.
- Follicular carcinoma aspirates are cellular, containing follicular epithelial cells present singly and in microfollicular arrangements. ► Note these appearances are identical to follicular adenomas; cytology cannot distinguish between these entities (📖 p. 237).

- Medullary carcinoma aspirates are cellular, containing loosely cohesive epithelial cells which may be round or spindled. Some cells may have eccentric nuclei, imparting a plasmacytoid appearance. The nuclei contain coarsely granular chromatin. Fragments of amyloid may be seen.
- Anaplastic carcinoma aspirates are highly cellular, containing markedly atypical malignant cells.

### Histopathology

- Papillary carcinoma is defined by characteristic nuclear features: oval shape, overlapping, clearing of the nuclear chromatin, nuclear grooves, and pseudoinclusions. Although most tumours have a papillary architecture, this is not a prerequisite for the diagnosis.
- Follicular carcinoma is an invasive follicular neoplasm that lacks the nuclear features of papillary thyroid carcinoma. Follicular carcinomas are subdivided into two major types: **minimally invasive** and **widely invasive**. Minimally invasive tumours show limited capsular invasion and/or vascular invasion. Widely invasive tumours show widespread infiltration of the thyroid and/or blood vessels.
- Medullary carcinoma shows sheets, nests, or trabeculae of round or spindled neoplastic cells with granular cytoplasm and nuclei with coarse chromatin. Amyloid deposits may be seen. The diagnosis can be confirmed by immunoreactivity for calcitonin.
- Anaplastic carcinomas are composed of highly pleomorphic epithelioid and spindled cells. Extensive necrosis is seen and occlusion of vessels by tumour is common.

### Prognosis

- Papillary carcinomas and minimally invasive follicular carcinomas are low-grade malignancies with excellent prognosis. Widely invasive follicular carcinomas and medullary carcinomas are intermediate-grade malignancies with a higher risk of metastasis and mortality. Anaplastic carcinomas are highly malignant and almost always fatal within months of diagnosis.

### TNM 7 pathological staging of thyroid carcinomas

#### Primary tumour (T)

pT1a: tumour  $\leq 10$ mm in size, limited to the thyroid.

pT1b: tumour  $\leq 20$ mm, but  $> 10$ mm in size, limited to the thyroid.

pT2: tumour  $> 20$ mm, but  $\leq 40$ mm in size, limited to the thyroid.

pT3: tumour  $> 40$ mm in size, limited to thyroid, or any tumour with minimal extrathyroid extension.

pT4a: tumour of any size extending beyond the thyroid capsule to invade subcutaneous soft tissues, the larynx, trachea, oesophagus, or recurrent laryngeal nerve.

pT4b: tumour invades the prevertebral fascia, mediastinal vessels, or encases the carotid artery.

► Note that all anaplastic tumours are considered T4.

#### Regional lymph nodes (N)

pN0: no regional lymph node metastasis.

pN1a: metastases in level VI cervical lymph nodes.

pN1b: metastases in levels I–V cervical, retropharyngeal, or superior mediastinal lymph nodes.



## Parathyroid hyperplasia

### Definition

- An increase in parathyroid cell mass without an apparent stimulus.

### Epidemiology

- Uncommon, accounting for ~20% of primary hyperparathyroidism.
- Women are affected more than men (3:1).

### Aetiology

- Most patients have sporadic hyperplasia with no clear underlying cause.
- ~20% of cases have familial disease, most commonly MEN 1.

### Pathogenesis

- Parathyroid hyperplasia leads to overproduction of parathyroid hormone (PTH).
- Raised PTH levels cause hypercalcaemia by stimulating an increased absorption of calcium from the gut and kidneys and increasing osteoclastic activity in bone.

### Presentation

- Patients present with primary hyperparathyroidism, a biochemical syndrome defined by the presence of hypercalcaemia and an inappropriately normal or raised PTH level.
- Many patients are asymptomatic when this is discovered incidentally.
- Some may present with vague symptoms of fatigue, nausea, constipation, polyuria, and arthralgias.

### Macroscopy

- All of the parathyroid glands are increased in weight (>60mg) and size (>6mm), though this may be to varying degrees between the glands.

### Histopathology

- The key feature is an increase in cell mass within the gland, associated with a decrease in fat content.
- Generally, both chief and oncocytic cell types are increased.
- Secondary fibrosis and haemorrhage are common findings.

### Prognosis

- Excellent following subtotal parathyroidectomy.

# Parathyroid adenoma

## Definition

- A benign epithelial neoplasm of the parathyroid.

## Epidemiology

- Common, accounting for ~80% of primary hyperparathyroidism.
- Peak incidence 50–60y old.
- Women are affected more than men (3:1).

## Aetiology

- Poorly understood although prior irradiation of the neck appears to increase the risk.

## Pathogenesis

- Autonomous production of PTH from the adenoma causes hypercalcaemia due to an unregulated mobilization of calcium from the bone and enhanced absorption of calcium from the kidneys and gut.

## Presentation

- Patients present with primary hyperparathyroidism, i.e. hypercalcaemia together with an inappropriately normal or raised PTH level.
- Many patients are asymptomatic when this is discovered incidentally.
- Some may present with vague symptoms of fatigue, nausea, constipation, polyuria, and arthralgias.

## Macroscopy

- A single parathyroid gland is enlarged in size (>6mm) and weight (>60mg).
- The adenoma is usually smooth, solid, soft, and light brown in colour.

## Histopathology

- The parathyroid gland contains a well-circumscribed, usually encapsulated, mass composed of parathyroid epithelial cells without fat. A compressed rim of normal parathyroid tissue is often present at one edge.
- Chief cells tend to predominate, though an intermingling of oncocytic cells is also commonly present. The cells may be arranged in solid sheets, trabeculae, or follicles.
- Stromal oedema, fibrosis, and haemorrhage are often present.

## Prognosis

- Parathyroid adenomas are benign lesions which are cured by excision.

## Parathyroid carcinoma

### Definition

- A malignant epithelial neoplasm of the parathyroid.

### Epidemiology

- Rare, accounting for ~1% of cases of primary hyperparathyroidism.
- Most occur in patients in their 40s and 50s with no gender predilection.

### Aetiology

- Unknown though anecdotal reports have linked it with secondary hyperparathyroidism and prior neck irradiation.
- Parathyroid carcinoma has not been linked with MEN 1.

### Carcinogenesis

- Loss of genetic material at chromosome 13q is the most frequently reported aberration.

### Presentation

- Unlike patients with parathyroid hyperplasia or adenoma, patients usually present with symptomatic primary hyperparathyroidism and a palpable neck mass.
- Calcium levels are usually very high (3.5–4mmol/L) with symptoms of polyuria, polydipsia, weakness, renal colic, and bone pain.

### Macroscopy

- Parathyroid carcinomas are generally much larger than adenomas, weighing on average 12g.
- They may be well circumscribed or have clearly infiltrative borders.

### Histopathology

- Parathyroid carcinomas are composed of sheets of epithelial cells which are often deceptively bland. Follicle formation is unusual.
- They often have a thick capsule and are traversed by thick bands of fibrous tissue which divide the tumour into multiple expansile nodules.
- Capsular invasion, vascular invasion, tumour necrosis, and a high mitotic index are all very suggestive of malignancy.

### Prognosis

- 10-year survival rates are ~50%.
- Most patients succumb to the uncontrollable metabolic effects of severe hyperparathyroidism secreted by recurrent tumour.

## Addison's disease

### Definition

- Primary adrenocortical insufficiency.

### Epidemiology

- Rare with an estimated annual incidence of 1 in 100,000 people.
- Most cases present in young to middle-aged adults.
- Women are affected more than men.

### Aetiology

- Autoimmune destruction in developed countries.
- Disseminated tuberculosis in developing countries.
- Other causes such as adrenal metastases are rare.

### Pathogenesis

- Addison's disease leads to a marked lack of glucocorticoid and mineralocorticoid production from the adrenal cortex. Clinical features do not become manifest until ~90% of the gland has been destroyed.

### Presentation

- Tiredness, lethargy, and weakness.
- Anorexia, nausea, vomiting, and diarrhoea.
- Loss of weight may be prominent.

▶ The clinical presentation is often insidious and non-specific, making the diagnosis challenging.

### Biochemistry

- ↓ Sodium and ↑ potassium.
- ↑ Urea due to dehydration.
- Up to half of patients have hypoglycaemia.
- Circulating anti-adrenal autoantibodies are often present.

### Diagnosis

- Patients suspected of having Addison's disease should have dynamic testing of the adrenal cortex with a **Synacthen test**. This involves an intramuscular injection of synthetic adrenocorticotrophic hormone (ACTH). The normal response is a rise in plasma cortisol. In Addison's disease, there is either no cortisol rise or only a minimal rise.

### Prognosis

- Good provided the diagnosis is made and lifelong replacement therapy is started with a synthetic glucocorticoid (hydrocortisone) and mineralocorticoid (fludrocortisone).
- ▶ It is vital that patients understand they must increase their dose of hydrocortisone during any intercurrent illness.
- ▶▶ Untreated or undertreated Addison's disease can cause acute adrenal failure ('Addisonian crisis') with a deadly combination of hypovolaemic shock, marked hypoglycaemia, and hyponatraemia.

## Adrenal cortical adenoma

### Definition

- A benign epithelial neoplasm of the adrenal cortex.

### Epidemiology

- Most cases occur in adults with no gender predilection.
- True incidence figures are unknown, largely due to the inability to distinguish nodular adrenal hyperplasia from true neoplastic adenomas.

### Aetiology

- Unknown in most cases.

### Genetics

- No consistent genetic aberrations have been described.

### Presentation

- Most non-functional tumours are diagnosed incidentally when the abdomen is imaged for unrelated reasons.
- Aldosterone-producing adenomas present with primary hyperaldosteronism (Conn's syndrome) characterized by hypertension and, in some patients, hypokalaemia.
- Cortisol-producing adenomas present with Cushing's syndrome.

### Macroscopy

- The adrenal gland contains a well-circumscribed tumour which may be encapsulated.
- The median tumour weight is 40g.
- Aldosterone-producing adenomas may be bright yellow while those associated with Cushing's syndrome may be yellow to tan.
- A small number of adenomas have a black colour ('black adenoma').

### Histopathology

- The tumours are composed of large polygonal cells arranged in nests and trabeculae separated by a fine vascular network.
- The cells have cytoplasm which is either clear and microvesicular or compact and eosinophilic. Nuclei are round to oval and usually bland.
- Occasionally, striking nuclear pleomorphism may be seen, though this does not equate with malignant behaviour.
- A compressed rim of normal adrenal cortex may be seen at the edge.

### Prognosis

- Adrenal cortical adenomas are benign tumours with no capacity for malignant behaviour.
- Prognosis is largely determined by the severity of the endocrine effects of functional tumours.

*This page intentionally left blank*

## **Adrenal cortical carcinoma**

### **Definition**

- A malignant epithelial neoplasm arising in the adrenal cortex.

### **Epidemiology**

- Rare tumours with an annual incidence of 1 per million population.
- Most occur in adults aged >60y old.

### **Aetiology**

- Unknown in most cases.

### **Carcinogenesis**

- The most frequent genetic aberrations are overexpression of IGF2 and EGFR and loss of function of p21 and p16.

### **Presentation**

- Most are functioning tumours which present with endocrine manifestations related to hormone overproduction.
- Flank pain may be present if the adrenal mass is large.
- 45% overproduce glucocorticoids alone causing Cushing's syndrome.
- 45% overproduce glucocorticoids and androgens which induce virilization in women.
- 10% overproduce androgens alone.
- Overproduction of mineralocorticoids is extremely rare.

### **Macroscopy**

- A large bulky tumour mass replaces the adrenal gland.
- Most tumours weigh >100g. The mean size is 12cm.
- The cut surface of the tumour appears lobulated and heterogeneous with areas of necrosis and haemorrhage.
- Obvious invasion into adjacent structures may be seen in some cases.

### **Histopathology**

- Most tumours show obvious invasive growth with extension beyond the capsule and vascular invasion.
- Broad fibrous bands are often present which divide the tumour into expansile nodules.
- The tumour cells are highly pleomorphic and arranged in sheets, nests, and trabeculae.
- Areas of necrosis may be seen.

### **Prognosis**

- 5-year survival is 50–70%.
- The most important prognostic factors are age and stage.

**Pathological staging of adrenal cortical carcinoma****Primary tumour (T)**

pT1: tumour 5cm or less in size, localized.

pT2: tumour >5cm, localized.

pT3: tumour of any size, locally invasive, but not involving adjacent organs.

pT4: tumour of any size, involving adjacent organs.

**Regional lymph nodes (N)**

N0: no regional lymph node metastasis.

N1: regional lymph node metastasis.



## Phaeochromocytoma

### Definition

- A neoplasm of the chromaffin cells of the adrenal medulla.

### Epidemiology

- Rare with an annual incidence of 8 per million.

### Aetiology

- Most are sporadic.
- ~10% are associated with inherited syndromes such as MEN 2, neurofibromatosis 1, and von Hippel–Lindau disease.
- Inherited tumours are more likely to occur at a younger age and be bilateral.

### Genetics

- Sporadic tumours show a high frequency of 1p loss of heterozygosity.

### Presentation

- Patients suffer from abrupt episodes of throbbing headaches, sweating, palpitations, chest pain, and abdominal pain due to excess circulating catecholamines produced by the tumour.
- Hypertension is often present (📖 p. 31).

### Biochemistry

- Raised urinary catecholamines and their metabolites is an important diagnostic aid.

### Macroscopy

- A well-circumscribed tumour with a firm grey cut surface.
- Mean size of 6cm and weight of 200g.

### Histopathology

- The tumour cells form characteristic balls of cells ('zellballen') separated by a delicate vascular network.
- The cells are polygonal with granular basophilic cytoplasm.
- Nuclei have a typical stippled chromatin pattern.
- Scattered pleomorphic nuclei may be seen.

### Prognosis

- 90% behave in a benign manner.
- Unfortunately, histology is not reliable at predicting the 10% which will be malignant, although worrying factors include invasive growth, necrosis, and high mitotic activity.

*This page intentionally left blank*

# Neuroblastoma

## Definition

- A malignant childhood tumour arising from neural crest-derived cells of the sympathetic nervous system. Most arise in the adrenal medulla or paraspinal sympathetic ganglia.

## Epidemiology

- Third most common malignant childhood tumour.
- Incidence of 1 in 10,000 live births per year.
- Most arise in the first 4y of life.

## Aetiology

- Unknown.

## Genetics

- Tumour genetics have important prognostic implications.
- Amplification of MYCN, diploidy, and deletions at chromosome 1p are all associated with poorer prognosis.

## Presentation

- Most children present unwell with weight loss, fever, watery diarrhoea, and a palpable abdominal mass.

## Biochemistry

- High urinary concentrations of catecholamines and their metabolites, vanillylmandelic acid (VMA) and homovanilic acid (HMA), are an important diagnostic aid.

## Macroscopy

- A lobulated soft grey tumour mass averaging 6–8cm in size, which is intimately related to the adrenal gland or sympathetic chain.

## Histopathology

- Neuroblastoma is divided into four subtypes, depending on the extent to differentiation of the primitive neuroblasts towards ganglion cells.
- **Undifferentiated neuroblastoma** is composed of undifferentiated neuroblasts with no evidence of ganglionic differentiation. They appear identical to a number of other 'small round blue cell tumours' of childhood and so require ancillary techniques to confirm the diagnosis (e.g. immunoreactivity for neural markers such as CD56 and synaptophysin).
- **Poorly differentiated neuroblastoma** shows limited evidence of ganglionic differentiation (<5% cells) and contains neurofibrillary stroma.
- **Differentiating neuroblastoma** contains many ganglionic cells (>5%, but <50% cells) and plentiful neurofibrillary stroma.
- **Ganglioneuroblastoma** is composed almost entirely of ganglionic cells (>50% cells) and neurofibrillary stroma.

**Prognosis**

- Based on several factors, including stage, age, histology, and genetics.
- Cure rates are >90% for low-risk disease, 70–90% for intermediate-risk disease, but only 10–40% for high-risk disease.

**Staging system for neuroblastomas**

Stage 1: localized tumour, completely excised, with or without microscopic residual disease and negative lymph nodes.

Stage 2A: localized tumour, incompletely excised, negative lymph nodes.

Stage 2B: as for 2A, with positive ipsilateral nodes, negative contralateral nodes.

Stage 3: unresectable tumour, crossing the midline, with or without lymph node involvement; midline tumour with bilateral lymph node involvement.

Stage 4: dissemination to distant lymph nodes, bone, bone marrow, liver, skin, and/or other organs, except as defined by stage 4S.

Stage 4S: localized primary tumour, dissemination limited to skin, liver, and/or bone marrow, <1y of age.

## Pituitary adenoma

### Definition

- A benign epithelial neoplasm of the anterior pituitary.
- Most are functioning tumours which overproduce prolactin, growth hormone (GH), or ACTH, in descending order of frequency.
- Functional adenomas producing TSH, follicle-stimulating hormone (FSH), or luteinizing hormone (LH) are very rare.

### Epidemiology

- Uncommon with an incidence of 1 in 100,000 per year.
- Most arise in middle-aged adults.
- Women are affected more than men.

### Aetiology

- Unknown in the majority of cases.
- A small proportion is seen in association with inherited tumour syndromes, e.g. MEN 1.

### Genetics

- The two best characterized gene aberrations are MEN 1 and *gsp*, a mutation in the G-protein alpha subunit.

### Presentation

- Features of endocrine hyperfunction, depending on the hormone produced, e.g. galactorrhoea and sexual dysfunction (prolactin-secreting), acromegaly (Fig. 13.3) if GH-secreting, or Cushing's syndrome (Fig. 13.4) if ACTH-secreting.
- Large adenomas may also produce symptoms of mass effect such as headache, nausea, and visual field disturbance due to compression of the overlying optic chiasm.
- Many patients will also have symptoms and signs of hypopituitarism, though rarely present with these.

### Macroscopy

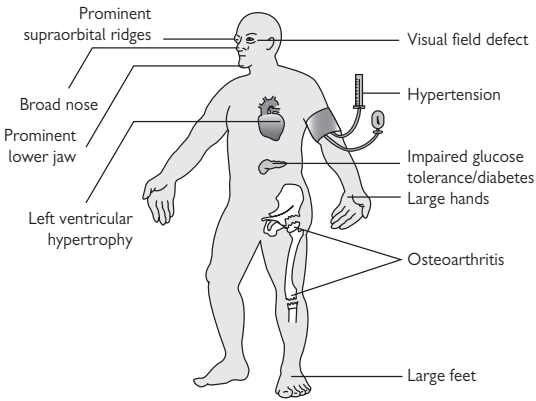
- Pituitary adenomas are soft tumours which may be very small microadenomas (<10mm in size) or larger macroadenomas (>10mm in size).

### Histopathology

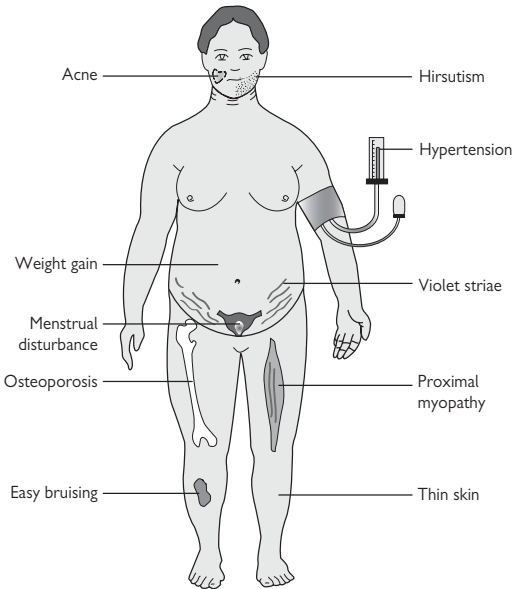
- The tumours are composed of solid nests or trabeculae of neoplastic cells with uniform round nuclei, stippled chromatin, and inconspicuous nucleoli.
- Immunohistochemistry using antibodies against prolactin, GH, and ACTH can be used to identify the hormone produced by the tumour.

### Prognosis

- Generally good following appropriate medical or surgical treatment, though some patients may suffer recurrences.
- ▶ The endocrine effects of these tumours may, however, have significant consequences, e.g. cardiovascular disease in acromegaly.



**Fig. 13.3** Clinical features of acromegaly. Reproduced with permission from *Clinical Pathology*, Carton, Daly, and Ramani, Oxford University Press, p. 300, Figure 14.3.



**Fig. 13.4** Clinical features of Cushing's syndrome. Reproduced with permission from *Clinical Pathology*, Carton, Daly, and Ramani, Oxford University Press, p. 303, Figure 14.5.

*This page intentionally left blank*

# Haematopathology

- Iron deficiency anaemia 256
- Anaemia of chronic disease 257
- Megaloblastic anaemias 258
- Hereditary spherocytosis 259
- Glucose-6-phosphate dehydrogenase deficiency 260
- Thalassaemias 261
- Sickle cell disorders 262
- Idiopathic thrombocytopenic purpura 264
- Thrombotic thrombocytopenic purpura 265
- von Willebrand disease 266
- Haemophilia 267
- Thrombophilia 268
- Acute B-lymphoblastic leukaemia 269
- Acute myeloid leukaemias 270
- Chronic lymphocytic leukaemia 271
- Chronic myelogenous leukaemia 272
- Polycythaemia vera 273
- Essential thrombocythaemia 274
- Primary myelofibrosis 275
- Myelodysplastic syndromes 276
- Follicular lymphoma 277
- Diffuse large B-cell lymphoma 278
- Extranodal marginal zone lymphoma 279
- Mantle cell lymphoma 280
- Classical Hodgkin lymphoma 281
- Plasma cell myeloma 282
- Primary amyloidosis 283



## Iron deficiency anaemia

### Definition

- A reduction in haemoglobin (Hb) concentration due to inadequate iron supply.

### Epidemiology

- The most common cause of anaemia.

### Aetiology

- Chronic blood loss from the gastrointestinal tract is the most common cause.
- Worldwide, this is usually related to hookworm infection.
- Common causes in developed countries include peptic ulcers, gastric carcinoma, sigmoid diverticular disease, and colorectal carcinoma.
- Heavy menstrual loss in women can also lead to iron deficiency.
- Gastrointestinal diseases causing malabsorption of iron can also cause iron deficiency, e.g. coeliac disease.

⚠ Ruling out a gastrointestinal tract malignancy is mandatory in any adult patient with unexplained iron deficiency anaemia.

### Pathogenesis

- Iron is an essential constituent of the haem group of Hb.
- When there is chronic iron deficiency, the final step in haem synthesis is interrupted.

### Presentation

- May be asymptomatic and diagnosed on routine full blood count.
- Symptoms include tiredness and breathlessness on exertion.
- Some cases may cause additional features such as koilonychia, angular cheilitis, and glossitis.

### Full blood count

- ↓ Hb.
- ↓ Mean corpuscular volume (MCV).
- ↓ Serum ferritin, ↓ serum iron, ↓ transferrin saturation, ↑ total iron binding capacity (TIBC).

### Peripheral blood film

- Small red cells (microcytic).
- Pale red cells (hypochromic).
- Variability in red cell size (anisocytosis) and shape (poikilocytosis).
- Long elliptical red cells are often seen ('pencil cells').

### Bone marrow

- Mild to moderate erythroid hyperplasia.
- Absence of stainable iron.

## Anaemia of chronic disease

### Definition

- A reduction in Hb concentration related to chronic inflammatory disorders, chronic infections, and malignancy.

### Epidemiology

- Second most common cause of anaemia.

### Aetiology

- Any chronic inflammatory disease, chronic infection, or malignancy.

### Pathogenesis

- The underlying mechanisms are complex and multifactorial.
- Current evidence suggests that inflammatory cytokines (e.g. IL-6) lead to reduced sensitivity of the marrow to erythropoietin and failure to incorporate iron into developing red cells.
- The end result is a reduction in erythropoiesis which is often ineffective.

### Presentation

- Tiredness and breathlessness.

### Full blood count

- ↓ Hb which is usually mild to moderate.
- MCV is usually normal, but may be low.

### Peripheral blood film

- Red cells usually normal in size, but can be small.
- There is no noticeable variation in size or shape.

### Bone marrow

- The marrow is usually of normal cellularity.
- Stainable iron is present.

## Megaloblastic anaemias

### Definition

- A reduction in Hb concentration due to impaired erythroid DNA synthesis. Most cases are related to either vitamin B12 or folate deficiency.

### Aetiology

- Autoimmune gastritis (📖 p. 92) is the most common cause of vitamin B12 deficiency. Megaloblastic anaemia due to autoimmune gastritis is also known as **pernicious anaemia**. This affects about 1 in 1000 people with a female predilection.
- Poor diet is the most common cause of folate deficiency. The main dietary sources of folate are leafy green vegetables. Deficiency is typically seen in the elderly and alcoholics.

### Pathogenesis

- Vitamin B12 and folate are both required to convert deoxyuridine monophosphate into deoxythymidine monophosphate, a molecule required for DNA synthesis.
- Developing red cells are unable to divide because they cannot make enough DNA to form two nuclei.
- They, therefore, become arrested in their development as large immature cells (megaloblasts), many of which die in the bone marrow.
- Some megaloblasts survive and develop into abnormally large red cells (macrocytes) which are released into the circulation.

### Presentation

- Symptoms related to profound anaemia.
- Mild jaundice may be present due to haemolysis.
- Vitamin B12 deficiency may also cause neurological symptoms, including cognitive impairment, peripheral neuropathy, and subacute combined degeneration of the spinal cord.

### Full blood count

- Hb concentration is typically very low (approaching only 2g/dL).
- MCV is typically very high.

### Peripheral blood film

- Prominent anisocytosis and poikilocytosis with large oval macrocytes.
- Nucleated red blood cells may be seen.
- Hypersegmented neutrophils.

### Bone marrow

- The marrow is hypercellular, containing many immature large erythroid blasts (megaloblasts) and large metamyelocytes.

# Hereditary spherocytosis

## Definition

- An inherited haemolytic condition caused by mutations in genes encoding proteins involved in maintaining the integrity of the red cell membrane.

## Epidemiology

- Common with an incidence of up to 1 in 2,000.

## Aetiology

- Mutations in genes encoding red cell membrane proteins.

## Pathogenesis

- Mutations cause destabilization of the red cell membrane with loss of lipid from the membrane.
- Reduction in the surface area of the membrane forces red cells to assume a spherical shape (spherocyte).
- Spherocytes are less deformable than normal red cells and are susceptible to becoming trapped in the spleen and destroyed by splenic macrophages.

## Presentation

- The degree of haemolysis is highly variable.
- Most patients have a mild to moderate anaemia (Hb 8–12g/dL).
- Splenomegaly is common.

## Full blood count

- Mild to moderate anaemia (Hb 8–12g/dL).
- Raised reticulocyte count.

## Peripheral blood film

- Spherocytes are readily identifiable.
- Reticulocytes are also present.

## Ancillary tests

- The **direct antiglobulin test** is negative, distinguishing spherocytosis from immune haemolytic anaemia which has similar blood film findings.

## Prognosis

- Most patients have well-compensated disease and only require folate supplements to avoid megaloblastic anaemia.
- Recognized complications include gallstone disease (from pigment gallstones) and aplastic crisis due to parvovirus B19 infection. The latter is potentially fatal.

## **Glucose-6-phosphate dehydrogenase deficiency**

### **Definition**

- An inherited haemolytic condition caused by a mutation in the glucose-6-phosphate dehydrogenase (G6PD) gene.

### **Epidemiology**

- Common, affecting up to 10% of the population worldwide.
- There is much geographical variability with highest rates in Africans, Asians, Italians, and Greeks.

### **Genetics**

- The G6PD gene is located on the X chromosome.
- A single mutated copy, therefore, causes G6PD deficiency in men.
- Homozygous women are also affected, but such individuals are not often seen.
- Heterozygous women do not have clinical manifestations as the other normal copy produces enough enzyme activity.

### **Pathogenesis**

- G6PD is one of the enzymes of the hexose monophosphate pathway, a metabolic process necessary for generating reduced glutathione.
- Reduced glutathione protects the red cell membrane from oxidative damage.
- Individuals with G6PD deficiency suffer from episodes of haemolysis following oxidant stress.

### **Presentation**

- Most individuals are asymptomatic with normal Hb levels.
- If exposed to oxidants, however, they suffer an acute haemolytic episode with fever, jaundice, and dark urine due to haemoglobinuria.
- Common precipitants include drugs (especially anti-malarials) and fava beans, a common food in Mediterranean countries.

### **Full blood count**

- ↓ Hb during an acute haemolytic episode.

### **Peripheral blood film**

- Variation in red cell shape (poikilocytosis).
- Red cells with punched out defects in their contours ('bite cells') are characteristic.
- Spherocytes may also be seen.

### **Ancillary tests**

- Screening tests for G6PD deficiency are available which indirectly assess G6PD activity by testing the ability of red cells to reduce dyes.
- Definitive diagnosis requires direct assay of the enzyme.

# Thalassaemias

## Definition

- A group of inherited red cell disorders caused by the underproduction of  $\alpha$ - or  $\beta$ -globin chains.

## Pathogenesis

- Underproduction of either  $\alpha$ - or  $\beta$ -globin chains causes accumulation of excess unpaired chains.
- This leads to the destruction of developing red cells and premature removal of circulating red cells in the spleen.
- The anaemia in thalassaemia is, therefore, a combination of ineffective erythropoiesis and haemolysis in the spleen.

## Beta-thalassaemia major

- Caused by mutations in both  $\beta$ -globin genes.
- Problems begin in the first few months of life as HbF levels decline and excess  $\alpha$ -chains begin to accumulate in red cells.
- Worsening anaemia leads to intense erythropoietic drive, with expansion of the bone marrow compartment and resumption of extramedullary haematopoiesis.
- Presents in infancy with pallor, poor feeding, and failure to thrive.
- Full blood count shows a hypochromic, microcytic anaemia.
- Diagnosis is confirmed by the near absence of HbA on haemoglobin electrophoresis.

## Beta-thalassaemia minor

- Caused by mutations in only one  $\beta$ -globin gene.
- Silent carriers who have an asymptomatic mild microcytic anaemia.
- A raised HbA<sub>2</sub> level on haemoglobin electrophoresis is a key diagnostic feature.

## Alpha-thalassaemia

- $\alpha$ -chains are required for both adult and fetal haemoglobin.
- In the fetus, excess  $\gamma$ -chains form tetramers known as Hb Bart's.
- In adults, excess  $\beta$ -chains form tetramers known as HbH.
- Deletion of all four  $\alpha$ -globin genes causes severe fetal anaemia, generalized oedema, massive hepatosplenomegaly, and fetal demise between 28–40 weeks gestation.
- Deletion of three  $\alpha$ -globin genes causes HbH disease with variable levels of chronic haemolysis. Most patients have a moderate chronic haemolytic anaemia throughout life (Hb 7–10g/dL) and splenomegaly.
- Deletion of one or two  $\alpha$ -globin genes leads to alpha-thalassaemia minor which is usually asymptomatic. There may be a very mild microcytic anaemia.

## Sickle cell disorders

### Definition

- A group of inherited red cell disorders caused by HbS.

### Epidemiology

- Seen most frequently in people of African descent and other areas of current or previous malaria endemicity.
- The mutant gene has survived because heterozygote carriers are protected against the effects of severe *Plasmodium falciparum* malaria.

### Genetics

- HbS is caused by a point mutation in the  $\beta$ -globin gene on chromosome 11 which causes a glutamine  $\rightarrow$  valine replacement.
- Heterozygotes are said to have **sickle cell trait**.
- Homozygotes suffer from **sickle cell disease** or **sickle cell anaemia**.

### Pathogenesis

- HbS is 50 times less soluble than HbA.
- Under conditions of low oxygen tension, HbS polymerizes into rod-like aggregates which cause the red cell to adopt a sickled shape.

### Presentation

- Individuals with sickle cell trait do not suffer from sickling because the normal HbA protein reduces the formation of HbS aggregates. Patients are usually asymptomatic and have normal Hb levels. They are nevertheless genetically important as carriers of the sickle cell gene.
- Individuals with sickle cell disease present at around 2y of age once they have lost most of their HbF and virtually all their Hb is HbS. Their red cells sickle in venous blood, causing persistent haemolysis and episodes of vascular crises.

### Full blood count

- $\downarrow$  Hb, typically between 7–9g/dL.

### Peripheral blood film

- Sickled red cells and their variants are present.
- In adults, there is also evidence of hyposplenism (target cells, Howell–Jolly bodies, Pappenheimer bodies).

### Diagnosis

- The **sickle cell solubility test** is a useful screening test in which a reducing agent is added to Hb extracted from red cells. HbS readily precipitates and the solution goes cloudy.
- Definitive diagnosis requires **Hb electrophoresis** which shows a single major HbS band and no normal HbA.

### Prognosis

- Patients with sickle cell disease have a significantly decreased lifespan.
- The median age of death is  $\sim$ 42y in men and 48y in women.

## Complications of sickle cell disease

### *Childhood*

- Hand and foot syndrome.
- Splenic sequestration crisis.
- Stroke.

### *Later life*

- Bacterial infections.
- Chronic kidney disease.
- Priapism.
- Lower limb ulceration.
- Pigment gallstones.
- Avascular necrosis of the femoral head.
- Pulmonary syndrome.



## Idiopathic thrombocytopenic purpura

### Definition

- A reduction in platelet number due to autoimmune destruction.

### Epidemiology

- Uncommon with an incidence of 1 in 100,000.
- Occurs in adults and children.
- Adult idiopathic thrombocytopenic purpura (ITP) is more common in women (3:1).
- Childhood ITP has a peak incidence between ages 2–4 with no gender predilection.

### Aetiology

- Platelet autoantibodies are formed for unknown reasons.

### Pathogenesis

- Platelets become coated with autoantibodies and are destroyed in the spleen.

### Presentation

- Sudden onset of cutaneous petechiae, nose bleeds, and gum bleeding.
- A preceding viral infection is often noted in childhood cases.

### Full blood count

- Severe thrombocytopenia.
- Normal Hb and white cell count.

### Peripheral blood film

- A mixture of normal and large platelets are present.

### Bone marrow findings

- Normal or increased numbers of megakaryocytes.
- Normal megakaryocyte morphology.
- Normal haematopoiesis.

► Note that ITP is a diagnosis of exclusion once other causes of thrombocytopenia have been ruled out.

### Prognosis

- Childhood cases usually resolve within 1–2 months.
- Adult cases are more likely to persist with a chronic mild-to-moderate bleeding tendency.

# Thrombotic thrombocytopenic purpura

## Definition

- A thrombotic microangiopathy due to lack of ADAMTS13.

## Epidemiology

- Rare.

## Aetiology

- Inherited cases are due to genetic mutations of ADAMTS13.
- Sporadic cases are due to autoantibodies against ADAMTS13.

## Pathogenesis

- ADAMTS13 is a metalloproteinase which cleaves von Willebrand factor (vWF) into small fragments.
- Deficiency of ADAMTS13 leads to the accumulation of ultra-high molecular weight forms of vWF which attach to endothelial cells and stimulate microthrombus formation in small vessels.
- Microthrombi cause organ impairment, most notably affecting the brain and kidneys.
- Platelets are rapidly consumed in the microthrombi, causing thrombocytopenia.
- Red blood cells passing through the microthrombi are sheared apart, causing anaemia.

## Presentation

- Fever, petechiae, and bleeding.
- Neurological symptoms are typically prominent.
- Acute renal failure may also occur.

## Haematology

- ↓ Hb with normal MCV.
- ↑ Reticulocyte count.
- ↓ Platelets.
- Normal clotting.

## Blood film

- Red cell anisocytosis.
- Prominent schistocytes (fragmented red cells).

## Prognosis

- Survival rates are 80–90% with early diagnosis and plasma exchange.
- Around one third of patients suffer relapses within 2y.

## von Willebrand disease

### Definition

- An inherited bleeding tendency caused by a quantitative or qualitative deficiency of vWF.

### Epidemiology

- The most common inherited bleeding disorder.
- Type 1 (75%) is a quantitative defect.
- Type 2 (20%) is a qualitative defect.
- Type 3, although rarer, is the most severe form of the disease.

### Genetics

- The vWF gene is located on chromosome 12.
- Types 1 and 2 are inherited in an autosomal dominant fashion.
- Type 3 is an autosomal recessive trait.

### Pathogenesis

- vWF acts as an adhesion molecule which allows platelets to bind to subendothelial tissues and it also acts as a carrier for factor VIII.
- Lack of vWF activity leads to a bleeding tendency due to a combination of failure of platelet adhesion and factor VIII deficiency.

### Presentation

- Mucosal bleeding, particularly nose bleeds, and bleeding after injury or surgery are the main manifestations.
- Joint and muscle bleeds are rare and only occur in type 3 disease.

### Clotting studies

- Prolonged activated partial thromboplastin time (APTT).
- Prolonged bleeding time.
- Normal prothrombin time (PT).
- Formal diagnosis requires the measurement of plasma vWF and testing of vWF functionality (e.g. ristocetin-induced platelet agglutination assay).

### Prognosis

- Most patients require no regular treatment.
- Prophylactic treatment is given before surgery.

# Haemophilia

## Definition

- An inherited bleeding tendency due to a deficiency of either factor VIII (haemophilia A) or factor IX (haemophilia B).

## Epidemiology

- Haemophilia A occurs in about 1 in 5–10,000 male births.
- Haemophilia B is less common with an incidence of about 1 in 20–30,000 male births.

## Genetics

- The factor VIII and factor IX genes are both located on the X chromosome, so haemophilia demonstrates sex-linked inheritance with males being predominantly affected.
- Numerous mutations have been described, leading to a wide variation in the severity of haemophilia.

## Pathogenesis

- Factors VIII and IX together form the factor VIII-factor IX complex which activates factor X in the clotting cascade.
- Lack of these factors impairs clotting.

## Presentation

- Easy bruising and massive bleeding after trauma or surgery.
- Spontaneous haemorrhages into large weight-bearing joints such as the knee, elbow, and ankles (haemarthroses) are common.

## Clotting studies

- Both forms of haemophilia cause a prolonged APTT and a normal PT.
- The two can only be distinguished by measuring levels of each factor.

## Prognosis

- Replacement of the missing factor is the key therapeutic intervention.
- Factor concentrates are pooled from multiple donors and carry a much higher risk of transmission of infection.
- Although stringent donor screening and viral inactivation of concentrates reduces this risk, there is a move toward the use of synthetic factors.

## Thrombophilia

### Definition

- An inherited predisposition to venous thrombosis.

### Presentation

- Deep vein thrombosis or pulmonary embolus, which may be recurrent.
- Venous thrombosis at unusual sites, e.g. axillary or cerebral veins may also occur.

### Activated protein C resistance

- The most common form of thrombophilia, affecting 5–10% of people.
- Due to a point mutation in the factor V gene (known as factor V Leiden mutation).
- Factor V Leiden protein has normal procoagulant activity, but is not inhibited in the normal way by activated protein C, resulting in a tendency to thrombosis.

### Prothrombin G20210A mutation

- Affects ~1–5% of people.
- Caused by a single nucleotide change of guanine for adenine at position 20210 of the PT gene.
- Associated with elevated PT levels and an increased risk of venous thrombosis, possibly due to increased rates of thrombin generation, excess growth of fibrin clots, and possibly increased activation of platelets.

### Protein C and S deficiency

- Affects ~0.2% of people.
- Protein C and S are natural anticoagulants which inactivate clotting factors and regulated normal coagulation.
- Defects in these proteins, therefore, predispose to thrombosis.

## Acute B-lymphoblastic leukaemia

### Definition

- A haematological neoplasm composed of malignant B-lymphoid blasts.

### Epidemiology

- Uncommon.
- Primarily a disease of children (75% of cases occur aged <6y)

### Aetiology

- Largely unknown, though there is a suggestion of an inherited component in some cases.

### Pathogenesis

- Mutations in a haematopoietic stem cell lead to the clonal expansion of immature B-lymphoid blasts.
- Rapidly proliferating lymphoid blasts overwhelm the normal bone marrow, spill into the peripheral blood, and infiltrate other organs.

### Presentation

- Sudden onset of bone marrow failure with profound anaemia and thrombocytopenia. The leukocyte count may be decreased, normal, or increased.
- Infiltration of other organs is common, causing lymphadenopathy, hepatosplenomegaly, bone pain, headache, vomiting, and cranial nerve palsies.

### Microscopy

- By definition, >20% of cells in the peripheral blood or bone marrow are lymphoid blasts.
- Lymphoid blasts are medium to large cells with a high nuclear to cytoplasmic ratio.

### Immunophenotype

- B-lymphoid blasts usually express CD19, CD79a, CD10, Pax5, and TdT.

### Prognosis

- Modern treatment regimens have excellent success rates with complete remission achieved in >95% of children.

## Acute myeloid leukaemias

### Definition

- A group of haematological neoplasms composed of malignant myeloid blasts.

### Epidemiology

- Worldwide incidence is 3 per 100,000 population per year.
- Predominantly, a disease of adults (mean age at diagnosis is 65y).

### Aetiology

- Acute myeloid leukaemias (AML) may be sporadic or occur as a complication of previous chemotherapy or as a terminal event in a pre-existing myeloproliferative or myelodysplastic disease.

### Pathogenesis

- Mutations in a haemopoietic stem cell lead to the clonal expansion of immature myeloid blasts.
- Rapidly proliferative myeloid blasts overwhelm the bone marrow and spill into the peripheral blood.
- Infiltration of organs by myeloid blasts can occur in AML, but this is less common than in acute B-lymphoblastic leukaemia.

### Presentation

- Most cases present with bone marrow failure, leading to anaemia, thrombocytopenia, and neutropenia. There may be leukocytosis.

### Microscopy

- By definition, >20% of the cells in the peripheral blood or bone marrow are myeloid blasts.
- The blasts are medium to large sized cells with a high nuclear to cytoplasmic ratio. Some myeloid blasts contain cytoplasmic granules or Auer rods.

### Immunophenotype

- Myeloid blasts usually express CD13, CD117, CD33, and CD34.
- They do not express B-lymphoid markers such as CD79a.

### Prognosis

- Outcome is dependent on the precise type of AML; however, most are aggressive diseases requiring intensive ablative regimes to achieve remission.
- AML associated with previous chemotherapy or a pre-existing myeloid disorder generally has a poor outcome.

# Chronic lymphocytic leukaemia

## Definition

- A malignant neoplasm composed of small mature B-cells that usually coexpress CD5 and CD23.

## Epidemiology

- The most common leukaemia with an incidence of 5 per 100,000.
- A disease of older adults with a peak incidence between 60–80y.
- Men are affected twice as often as women.

## Aetiology

- Unknown.

## Pathogenesis

- The neoplastic B-cells gradually fill the bone marrow and then spill into the peripheral blood.
- With progression, lymph nodes become involved and then, the liver and spleen.
- In the final stages of the disease, the neoplastic cells overwhelm the bone marrow and cause bone marrow failure.

## Presentation

- Many patients are diagnosed incidentally when a full blood count reveals a leukocytosis.
- The remainder presents with lymphadenopathy or autoimmune phenomena such as autoimmune haemolytic anaemia or autoimmune thrombocytopenia.

## Peripheral blood film

- Excess of mature lymphocytes.
- So-called 'smear cells' are characteristic of chronic lymphocytic leukaemia (CLL); these represent neoplastic cells which are smudged during preparation of the film.

## Histopathology

- Lymph nodes are replaced by small, slightly irregular B-cells with variable numbers of so-called proliferation centres containing larger lymphoid cells.
- Involved bone marrow contains collections of neoplastic lymphoid cells.

## Immunophenotype

- Positive for PAX5, CD20, CD79a, CD5, and CD23.
- Negative for cyclin D1.

## Prognosis

- Generally behaves indolently with many patients surviving for several years after diagnosis, often without treatment.
- A small proportion of cases are complicated by the development of diffuse large B-cell lymphoma (Richter's syndrome) which has a poor prognosis.



## Chronic myelogenous leukaemia

### Definition

- A myeloproliferative neoplasm that predominantly involves the granulocytic lineage and is consistently associated with the BCR-ABL1 fusion gene located on the Philadelphia chromosome.

### Epidemiology

- Incidence of 1–2 per 100,000 population per year.
- The peak age of onset is between 50–70y old.

### Aetiology

- Unknown.

### Genetics

- By definition, typical cases of chronic myelogenous leukaemia (CML) have the characteristic t(9;22) translocation that results in the Philadelphia chromosome.
- The translocation results in fusion of the BCR gene on chromosome 22 to the ABL1 gene on chromosome 9.
- The BCR-ABL1 protein has enhanced tyrosine kinase activity, leading to the constitutive activation of signal transduction pathways and deregulated proliferation of myeloid cells.

### Presentation

- Most patients are diagnosed during the chronic phase of the disease when a white cell count is abnormally raised.
- Hepatosplenomegaly is often present at diagnosis.

### Peripheral blood

- Leukocytosis due to the presence of increased numbers of neutrophils in various stages of maturation.
- Basophilia and eosinophilia are common.
- No dysplasia is present.

### Bone marrow

- Bone marrow trephines are hypercellular due to increased numbers of neutrophils and their precursors.
- Megakaryocytes are typically small and hypolobated.
- Blasts account for <5% of marrow cells in the chronic phase.

### Prognosis

- Outcome is much improved since the development of the tyrosine kinase inhibitor, imatinib, with 5-year survival rates of 80–90%.
- Disease progression is usually heralded by an increase in circulating blasts to >10% (accelerated phase) and terminates in acute leukaemia when blasts account for >20% of circulating cells.

# Polycythaemia vera

## Definition

- A myeloproliferative neoplasm that predominantly involves the erythroid lineage and is almost always associated with a somatic gain-of-function mutation of the JAK2 gene.

## Epidemiology

- Incidence 1–2.5 cases per 100,000 population per year.
- Median age at diagnosis is 60.
- There is a slight male predominance.

## Aetiology

- Unknown.

## Genetics

- >95% of cases have the JAK2 V617F mutation, leading to a deregulated proliferation of all myeloid cells, though most notably the erythroid lineage.
- Progression of the disease is associated with the acquisition of cytogenetic abnormalities.

## Presentation

- May present incidentally on full blood count or with symptoms related to hyperviscosity (headache, dizziness, visual disturbance, venous or arterial thrombosis).
- Most patients are plethoric and have hepatosplenomegaly.

## Full blood count

- ↑ Hb, ↑ red cell count, ↑ haematocrit (HCT), ↑ packed cell volume (PCV).
- Often ↑ white cell count and ↑ platelets.

## Bone marrow

- The marrow is hypercellular due to an increase in all myeloid lineages ('panmyelosis').
- Erythroid precursors and megakaryocytes are most prominent.
- Megakaryocytes form loose clusters and often show significant variation in size and shape.

## Prognosis

- Median survival is >10y with treatment. Most patients die from thrombosis or haemorrhage.
- ~20% die due to the development of myelodysplasia or AML.

## Essential thrombocythaemia

### Definition

- A myeloproliferative neoplasm that predominantly involves the megakaryocytic lineage.

### Epidemiology

- Estimated at 0.5–2.5 per 100,000 people per year.
- Most cases present in adults aged 50–60.
- There is no gender predilection.

### Aetiology

- Unknown.

### Genetics

- No recurring molecular genetic or cytogenetic abnormality is known.

### Presentation

- About half of patients present incidentally when a markedly raised platelet count is found on full blood count.
- The remainder presents with symptoms related to vascular occlusion or haemorrhage (transient ischaemic attacks, digital ischaemia and gangrene, major arterial and venous thrombosis).
- Splenomegaly is present in only a minority of patients.

### Full blood count

- Sustained elevated platelet count ( $>450 \times 10^9/L$ ).
- The white cell count and red cell count are usually normal.

### Bone marrow

- The marrow is of normal cellularity, but contains increased numbers of large and giant megakaryocytes with abundant cytoplasm and deeply lobated 'stag-horn' nuclei.
- There is no significant erythroid or granulocytic proliferation.

### Prognosis

- Relatively indolent disease with median survival of 10–15y.
- Only a very small proportion of patients progress to bone marrow fibrosis or AML.

# Primary myelofibrosis

## Definition

- A myeloproliferative neoplasm characterized by predominant proliferation of megakaryocytes and granulocytes in the bone marrow associated with reactive deposition of fibrous connective tissue and with extramedullary haematopoiesis.

## Epidemiology

- Estimated annual incidence of 0.5–1.5 per 100,000 population.
- Occurs mostly in adults aged 60–70 with no gender predilection.

## Aetiology

- Unknown in most cases.

## Genetics

- No specific genetic defect has been identified.

## Presentation

- Abdominal discomfort due to massive splenomegaly.
- Night sweats, fever, weight loss.

## Peripheral blood

- ↑ platelets and/or white cell count.
- ↓ Hb.
- Blood film shows leukoerythroblastosis with teardrop-shaped red blood cells.

## Bone marrow

- Megakaryocytes are markedly abnormal with extensive clustering and marked cytological atypia.
- With progression, there is increasing marrow fibrosis.

## Prognosis

- Survival depends on the extent of marrow fibrosis at diagnosis.
- Patients with marked fibrosis have median survival times of 3–7y.
- The major causes of death are bone marrow failure, thromboemboli, and the development of AML.

## Myelodysplastic syndromes

### Definition

- A group of haematopoietic neoplasms characterized by dysplasia in one or more of the myeloid cell lineages and associated with ineffective myelopoiesis, cytopenias, and an increased risk of development of AML.

### Epidemiology

- Estimated annual incidence of 3–5 per 100,000 population.
- Occur mostly in older adults at a median age of 70.

### Aetiology

- Unknown in most cases.

### Genetics

- A number of recurring chromosomal aberrations have been described in myelodysplastic syndromes (MDS).
- Cytogenetic and molecular studies are important in proving clonality and determining the prognosis.

### Presentation

- Refractory anaemia is the most common presentation.
  - Neutropenia and thrombocytopenia are less frequent.
- Note that hepatosplenomegaly is uncommon in MDS.

### Peripheral blood

- Cytopenias in one or more myeloid lineages.
- Blood films may show macrocytes and abnormal neutrophils with poorly developed nuclear segmentation and hypogranular cytoplasm.

### Bone marrow

- Morphological evidence of myelodysplasia may be seen in one or more myeloid lineages in the bone marrow.
- Dyserythropoiesis is characterized by nuclear budding, internuclear bridging, karyorrhexis, multinuclearity, nuclear hypolobulation, megaloblastic changes, ring sideroblasts, and cytoplasmic vacuolization.
- Dysgranulopoiesis is characterized by small size, nuclear hypolobation, irregular hypersegmentation, and cytoplasmic hypogranularity.
- Dysmegakaryocytopenia is characterized by small size, nuclear hypolobation, or multinucleation.

### Prognosis

- Survival depends on a number of factors, including morphological subtype, karyotype, severity of cytopenia, and age.
- Low-risk forms of MDS tend to have a more prolonged natural history with a very low incidence of progression into AML.
- High-risk forms are more aggressive with many patients succumbing rapidly to bone marrow failure or AML.

# Follicular lymphoma

## Definition

- A mature B-cell neoplasm composed of germinal centre cells (centrocytes and centroblasts).

## Epidemiology

- Accounts for ~20% of all non-Hodgkin lymphomas.
- Predominantly affects adults aged 50–60.

## Aetiology

- Unknown.

## Genetics

- 90% of cases have a characteristic t(14;18) translocation which results in fusion of the BCL2 gene to the IGH locus.
- Deregulated production of the anti-apoptotic Bcl-2 protein results in clonal proliferation.

## Presentation

- Widespread lymphadenopathy and splenomegaly.
- Patients are otherwise relatively asymptomatic.

## Histopathology

- Nodal architecture is replaced by back-to-back neoplastic follicles.
- Neoplastic follicles lack mantle zones and are composed of randomly distributed neoplastic centroblasts and centrocytes.
- Tingible body macrophages are usually absent.
- Interfollicular spread of neoplastic cells is usually present.
- Bone marrow involvement is characterized by paratrabecular aggregates of neoplastic centrocytes and centroblasts.

## Immunophenotype

- B-cell markers PAX5, CD20, and CD79a are positive.
- Bcl-2, Bcl-6, and CD10 are also positive.
- CD5, CD23, and cyclin D1 are negative.

## Prognosis

- Related to the extent of disease and tumour grade.
- ~25% progress into a high-grade lymphoma, usually diffuse large B-cell lymphoma, associated with a rapid clinical decline and death.

## Diffuse large B-cell lymphoma

### Definition

- A mature B-cell neoplasm composed of large B-lymphoid cells with a diffuse growth pattern.

### Epidemiology

- Accounts for 25–30% of all non-Hodgkin lymphomas.
- Predominantly affects elderly adults aged >60.

### Aetiology

- Unknown in many cases.
- Strong association with immunodeficiency states such as HIV or post-transplant where the lymphoma is driven by EBV, HHV-8, or both.

### Genetics

- A number of genetic alterations have been described in diffuse large B-cell lymphoma (DLBCL).
- The commonest translocation involves a region of 3q encoding the BCL6 gene.

### Presentation

- Rapidly growing mass which may be nodal (60%) or extranodal (40%).
- The commonest extranodal site is the gastrointestinal tract, but virtually any site may be affected.

### Histopathology

- Involved tissues are replaced by diffuse sheets of large atypical lymphoid cells which are usually more than twice the size of a normal lymphocyte.
- Apoptotic debris are usually seen and there may be confluent areas of tumour necrosis.

### Immunophenotype

- Positive for B-cell markers PAX5, CD20, and CD79a.
- Cyclin D1 is negative.
- High proliferation index (usually 40–90% of cells).

### Prognosis

- Survival is much improved since the introduction of the anti-CD20 inhibitor, rituximab, with long-term survival rates of around 60–75%.
- Bone marrow involvement is generally associated with poor prognosis.

# Extranodal marginal zone lymphoma

## Definition

- An extranodal mature B-cell neoplasm composed predominantly of small neoplastic marginal zone cells.

## Epidemiology

- Accounts for 7–8% of all non-Hodgkin B-cell lymphomas.
- Predominantly arises in adults at a mean age of 60.

## Sites of involvement

- The gastrointestinal tract accounts for 50% of all cases, with the stomach being the most common location.
- Other sites include lung, salivary gland, skin, thyroid, and breast.

## Aetiology

- Gastric cases are typically associated with *Helicobacter pylori*.
- Other implicated organisms include *Campylobacter jejuni* (jejunum), and *Borrelia burgdorferi* (skin).
- Autoimmune diseases are also associated, e.g. Hashimoto's thyroiditis (thyroid) and Sjögren's syndrome (salivary gland).

## Pathogenesis

- Most cases are preceded by a chronic inflammatory disorder that causes the accumulation of extranodal lymphoid tissue.
- Prolonged stimulation of lymphoid proliferation eventually leads to transformation into a neoplastic process.

## Presentation

- Symptoms relating to a mass at the involved site.

## Histopathology

- Involved tissues contain a heterogeneous population of small neoplastic B-cells which surround and may overrun background reactive lymphoid follicles.
- The cells include marginal zone cells, cells resembling monocytoid cells, small lymphocytes, and scattered immunoblasts and centroblast-like cells.
- In epithelial-lined tissues, the neoplastic lymphoid cells typically infiltrate and destroy the epithelium, creating so-called lymphoepithelial lesions.

## Immunophenotype

- B-cell markers PAX5, CD20, and CD79a are positive.
- CD5, CD10, CD23, and cyclin D1 are all negative.

## Prognosis

- Tends to show indolent behaviour with prolonged disease-free remissions following treatment.



## Mantle cell lymphoma

### Definition

- A mature B-cell neoplasm composed of monomorphic, small to medium sized lymphoid cells with irregular nuclear contours and a CCND1 translocation.

### Epidemiology

- Accounts for 3–10% of all non-Hodgkin B-cell lymphomas.
- Predominantly arises in adults at a mean age of 60.

### Aetiology

- Unknown.

### Genetics

- Virtually all cases show a t(11;14) translocation involving the CCND1 (cyclin D1) and IGH genes.
- Deregulated expression of cyclin D1 results in uncontrolled proliferation of the lymphoid cells.

### Presentation

- Most patients present with lymph node involvement.
- The liver, spleen, marrow, or peripheral blood may also be involved.
- Extranodal sites may also be affected, particularly the gastrointestinal tract.

### Histopathology

- Involved tissues are replaced by sheets of monomorphic, small to medium sized lymphoid cells with irregular nuclear contours.
- Hyalinized small blood vessels and scattered epithelioid histiocytes are often present.

### Immunophenotype

- B-cell markers PAX5, CD20, and CD79a are positive.
- CD5 and cyclin D1 are positive.
- CD23 and CD10 are usually negative.

### Prognosis

- Despite its relatively bland appearance, prognosis is generally poor with a median survival of only 3–5y.

## Classical Hodgkin lymphoma

### Definition

- A lymphoid neoplasm composed of crippled neoplastic B-cells, known as Hodgkin/Reed Sternberg (HRS) cells, within a rich non-neoplastic inflammatory background.

### Epidemiology

- Bimodal age distribution with a peak at 15–35y and a smaller peak in later life.
- Men are more commonly affected than women, with the exception of the nodular sclerosis variant which has an equal gender incidence.

### Aetiology

- Unknown, though EBV infection has been implicated in some types.

### Presentation

- Most patients present with localized lymphadenopathy.
- Fever, night sweats, weight loss are common (so-called 'B symptoms').

### Histopathology

- Lymph nodes are replaced by variable numbers of neoplastic HRS cells within a rich inflammatory background.
- The textbook diagnostic Reed Sternberg cell is a very large cell with two large nuclei containing prominent eosinophilic nucleoli.
- Four histological subtypes are recognized, depending on the number and nature of the HRS cells and the reactive background: nodular sclerosis, mixed cellularity, lymphocyte-rich, and lymphocyte-depleted.

### Immunophenotype

- HRS cells are CD30– and CD15-positive with a typical membranous and Golgi staining pattern.
- PAX5 and MUM-1 are consistently positive in HRS cells whereas CD20 and CD79a are usually either negative or only weakly expressed.

### Prognosis

- Modern treatment regimes cure classical Hodgkin lymphoma in >85% of cases.

### Nodular lymphocyte-predominant Hodgkin lymphoma

A distinct subtype of Hodgkin lymphoma, nodular lymphocyte predominant Hodgkin lymphoma (NLPHL), is also recognized. NLPHL accounts for 75% of all Hodgkin lymphomas. It typically arises in young to middle-aged adults aged 30–50. The abnormal B-cells, known as lymphocyte-predominant cells, are immunophenotypically distinct from classical HRS cells; they typically lack CD30 and CD15 and strongly express CD20 and EMA. The disease behaves indolently and is rarely fatal.

## Plasma cell myeloma

### Definition

- A disseminated bone marrow-based plasma cell neoplasm associated with a serum and/or urine paraprotein.

### Epidemiology

- Incidence 3–5 per 100,000 population.
- Occurs in older adults with a mean age at diagnosis of 70y.
- There is a male predominance (1.5:1).

### Aetiology

- Unknown.

### Pathogenesis

- The neoplastic plasma cells secrete cytokines which activate osteoclasts, causing lytic bone lesions.
- Circulating paraprotein depresses normal immunoglobulin production, increasing the risk of infections.
- Free light chains passing through the kidney contribute to renal failure.

### Presentation

- Bone pain and recurrent infections.
- Anaemia, ↑ ESR, hypercalcaemia, and renal impairment are common.

### Histopathology

- Definite diagnosis requires bone marrow biopsy.
- The bone marrow contains an excess of monoclonal plasma cells present in clusters, nodules, or sheets.
- Clonality can be proven immunohistochemically by demonstrating kappa or lambda light chain restriction.

### Prognosis

- Myeloma remains an incurable disease.
- Typical survival is 3–4y from diagnosis.

# Primary amyloidosis

## Definition

- A plasma cell neoplasm associated with the deposition of AL amyloid in multiple tissues.

## Epidemiology

- Rare disease.
- Median age at diagnosis of 65y with male predominance.

## Aetiology

- The majority of patients have an underlying plasma cell neoplasm, but do not meet the criteria for a diagnosis of plasma cell myeloma.

## Pathogenesis

- AL amyloid is composed of immunoglobulin light chains secreted by monoclonal plasma cells which deposit in various tissues in a  $\beta$ -pleated sheet structure.
- Accumulated amyloid includes intact light chain and fragments of the variable NH<sub>2</sub>-terminus region.

## Presentation

- Clinical features related to the deposition of amyloid in multiple organs.
- Common sites of involvement include the skin, kidney, heart, liver, bowel, and peripheral nerves.
- Typical features include purpura, peripheral neuropathy, cardiac failure, nephrotic syndrome, and malabsorption.

## Histopathology

- Amyloid can be demonstrated in many tissues as a pink amorphous substance. Congo Red stains amyloid red under standard light microscopy and 'apple green' under polarized light.
- Bone marrow biopsies typically show a mild increase in plasma cells which may appear normal or atypical. The plasma cells are monotypic for either kappa or lambda light chains.

## Prognosis

- Poor prognosis with a median survival of only 2y from diagnosis.
- Most frequent cause of death is amyloid-associated cardiac failure.

*This page intentionally left blank*

# Skin pathology

- Eczemas 286
- Psoriasis 287
- Lichen planus 288
- Erythema multiforme 289
- Granuloma annulare 290
- Pemphigus vulgaris 291
- Bullous pemphigoid 292
- Dermatitis herpetiformis 293
- Erythema nodosum 294
- Pyoderma gangrenosum 295
- Skin infections 296
- Benign cutaneous lumps 298
- Basal cell carcinoma 300
- Squamous cell carcinoma 301
- Malignant melanoma 302
- Mycosis fungoides 304

## Eczemas

### Definition

- A group of inflammatory skin diseases characterized clinically by an erythematous papulovesicular rash and histologically by the presence of intraepidermal oedema (spongiosis).

### Atopic dermatitis

- Chronic dermatitis occurring in people with atopy.
- Very common disorder with incidences as high as 15%.
- Typically occurs in infants and children.
- Clinically causes an itchy erythematous papulovesicular rash involving the face and extensor surfaces of the arms and legs.
- Biopsies from acute lesions show epidermal spongiosis and dermal inflammation.
- Biopsies from later lesions show epidermal thickening and hyperkeratosis with mild spongiosis.

### Irritant contact dermatitis

- Inflammatory skin disease caused by direct toxic effect of an irritant.
- A common cause of occupational skin disease.
- Clinically causes erythema with vesiculation.
- Biopsies show epidermal spongiosis and dermal inflammation.

### Allergic contact dermatitis

- Inflammatory skin disease caused by a delayed-type hypersensitivity reaction to an allergen to which the patient has been sensitized to.
- A common occupational skin disease (well described in hairdressers).
- Clinically causes itchy papules and vesicles 12–48h after exposure.
- Common culprits include nickel, cosmetics, and foodstuffs.
- Biopsies show epidermal spongiosis with vesicle formation and an inflammatory infiltrate which usually includes eosinophils.

### Nummular dermatitis

- Inflammatory skin disease of unknown cause.
- Clinically shows tiny papules and vesicles that coalesce into coin-shaped patches.
- Biopsies show epidermal spongiosis and inflammation in early lesions. Older lesions show epidermal hyperplasia.

### Seborrhoeic dermatitis

- Common inflammatory skin disease affecting 1–3% of people.
- Some evidence suggests it may be the result of an abnormal immune response to *Malassezia* organisms, but this is controversial.
- Clinically shows erythematous scaly papules and plaques, sometimes with a greasy appearance, on the scalp, ears, eyebrows, and nasolabial area.
- Biopsies show variable epidermal spongiosis and hyperplasia with overlying parakeratosis centred on hair follicles.

# Psoriasis

## Definition

- A chronic relapsing skin disorder associated with abnormal hyperproliferation of the epidermis.

## Epidemiology

- Common, affecting ~2% of people.
- Mean age of onset 25y.

## Aetiology

- Current evidence suggests that psoriasis is the result of an abnormal immune reaction to an external trigger in a genetically susceptible individual.
- Factors known to trigger or exacerbate the condition include stress, infections, climate, alcohol, smoking, and trauma.
- Genome wide linkage analysis studies have identified at least nine chromosomal loci associated with psoriasis; most of these appear to be genes encoding HLA proteins, cytokines, or cytokine receptors.

## Pathogenesis

- Activated plasmacytoid dendritic cells in the skin migrate to draining lymph nodes where they induce the differentiation of naïve T-cells into type 1 and type 17 helper and cytotoxic T-cells.
- Effector T-cells circulate to the skin where they elaborate cytokines, including IL-17, IL-22, IFN- $\gamma$ , and TNF- $\alpha$ , which stimulate the hyperproliferation of epidermal keratinocytes.

## Presentation

- Typical psoriasis gives rise to well-demarcated erythematous oval plaques with adherent silvery scale.
- Sites of predilection are the elbows, knees, and scalp.
- Nail involvement is common with pitting and onycholysis.
- Guttate psoriasis is a clinical variant characterized by small, 1–5mm in size, erythematous papules. Many of these cases are preceded by streptococcal infection.
- Severe psoriasis may cause erythroderma (erythrodermic psoriasis).

## Histopathology

- Typical lesions show psoriasiform epidermal hyperplasia with thinning of the suprapapillary plates. Plaques of parakeratosis are present with a diminution of the granular layer beneath the parakeratosis.
- Collections of neutrophils are seen in the stratum corneum (Munro microabscesses) and may also be found within the stratum spinosum.
- The dermis contains dilated capillaries and an inflammatory infiltrate.

## Prognosis

- Usually runs a chronic course.
- May have a significant impact on quality of life.



## Lichen planus

### Definition

- An inflammatory skin disease associated with itchy purple papules clinically and a lichenoid reaction pattern histologically.

### Epidemiology

- Affects ~1% of the population.
- Usually arises in middle-aged adults with a slight female predominance.

### Aetiology

- Unknown.

### Pathogenesis

- Thought to represent a delayed-type hypersensitivity reaction to an unidentified epidermal antigen.

### Presentation

- The skin lesions are small, flat-topped, violaceous papules which are usually intensely itchy.
- Fine white lines (Wickham's striae) usually cross the surface.
- The lesions usually occur on the flexor aspect of the wrists, the extensor aspects of the hands, and the forearms.
- Oral involvement is common (📖 p. 86) as are genital lesions (📖 p. 183 and 📖 p. 186), particularly in men.

### Histopathology

- A heavy band-like inflammatory infiltrate containing lymphocytes and macrophages is present beneath the epidermis.
- The basal layer of the epidermis shows vacuolar damage with cytoid body formation and melanin spillage.
- The epidermis shows irregular acanthosis, hyperkeratosis, and wedge-shaped hypergranulosis.

### Prognosis

- In most cases, the disease resolves spontaneously over a variable period of time from weeks to a year.

# Erythema multiforme

## Definition

- An inflammatory skin disorder associated with distinctive targetoid lesions clinically and an interface reaction pattern histologically.

## Epidemiology

- Relatively common.
- Mainly affects young people, including children.

## Aetiology

- Most cases are linked to current or previous infections with herpes simplex virus (HSV) (which may not always be clinically apparent).
- Other infective agents have also been implicated, e.g. *Mycoplasma*.
- Drugs are also a recognized cause.

## Pathogenesis

- Thought to represent a delayed-type hypersensitivity reaction to HSV antigens transported to the skin in circulating lymphocytes.

## Presentation

- Discrete round erythematous patches, 1–2cm in size, with central discoloration which may blister ('target' lesions).
- Most cases involve the extremities.
- Mild oral involvement is common.

## Histopathology

- Biopsies show an interface dermatitis characterized by a superficial lymphohistiocytic inflammatory infiltrate with prominent basal cell vacuolar degeneration and keratinocyte apoptosis.
- Cases with marked basal cell damage may result in subepidermal clefting and blistering.

## Prognosis

- Most cases are self-limiting, but recurrent episodes are common.

## Granuloma annulare

### Definition

- An inflammatory skin disease classically associated with annular lesions clinically and necrobiotic granulomatous inflammation histologically.

### Epidemiology

- Common.

### Aetiology

- Unknown in the majority of cases.
- *Borrelia* infection has been linked in a small number of cases.

### Pathogenesis

- Current evidence suggests it represents a cutaneous reaction pattern to as yet undefined antigens.

### Presentation

- Localized lesions of granuloma annulare consist of flesh-coloured or red papules which line up to form an annular lesion of 1–5cm.
- Acral sites are usually affected, especially the knuckles and fingers.

### Histopathology

- The dermis contains a palisading granuloma, characterized by a central area of degenerate (necrobiotic) collagen surrounded by radially arranged histiocytes, lymphocytes, and fibroblasts.
- Mucin is often present within the necrobiotic focus.
- Occasionally, the process forms a more subtle ill-defined lesion in the dermis rather than a typical well-formed palisaded granuloma (interstitial granuloma annulare).

### Prognosis

- About half of cases resolve within 2y of onset, though recurrences are quite common.

# Pemphigus vulgaris

## Definition

- An immunobullous skin disease due to autoantibodies against epidermal desmosomal proteins.

## Epidemiology

- Rare with an incidence of 0.1–1 per 100,000 people per year.
- Usually affects middle-aged adults of 40–60y.

## Aetiology

- Production of autoantibodies directed against the epidermal desmosomal cadherin, desmoglein-3.

## Pathogenesis

- The autoantibody binds to the extracellular domain of desmoglein-3, leading to desmosomal damage and acantholysis.
- The traditional view was that complement fixation led to acantholysis; however, some workers have suggested that the acantholysis may be due to cytoskeletal collapse independent of the action of complement.

## Presentation

- Most cases start with oral erosions and blisters, followed weeks or months later by the development of skin lesions.
- The skin lesions are fragile blisters developing on normal or erythematous skin. The blisters easily rupture, leaving a painful area of erosion.
- The skin lesions typically occur on the face, scalp, axillae, and groins.

## Histopathology

- Biopsies show a blister cavity within the epidermis containing acantholytic keratinocytes.
- Typically, the level of the split is suprabasal such that the floor of the blister is lined by a single layer of intact basal keratinocytes.
- The acantholysis may also involve the epidermis of adnexal structures.
- There is usually an underlying dermal inflammatory infiltrate which includes many eosinophils.

## Immunofluorescence

- Direct immunofluorescence on perilesional skin reveals a deposition of IgG and C3 in the intercellular region of the epidermis.

## Prognosis

- Mortality rates are low with appropriate immunosuppressive regimes.
- Most complications are therapy-related.

## **Bullous pemphigoid**

### **Definition**

- An immunobullous skin disease due to autoantibodies against epidermal hemidesmosomal proteins.

### **Epidemiology**

- Commonest immunobullous skin disorder, but still a rare disease with an annual incidence of 7 per million population.
- Most cases arise in elderly adults aged >70.

### **Aetiology**

- Production of autoantibodies directed against epidermal hemidesmosomal proteins.
- The two key antigens are known as BPAg1 and BPAg2.

### **Pathogenesis**

- Binding of the antibody leads to fixation of complement and influx of inflammatory cells, including eosinophils.
- Direct cytotoxic action leads to the disruption of the hemidesmosomes anchoring the epidermis to the dermis and resultant separation of the entire epidermis from the dermis.

### **Presentation**

- The typical skin lesions are large tense intact blisters which develop on normal or erythematous skin.
- Sites of predilection include the lower trunk, inner thighs, forearms, axillae, and groins.

### **Histopathology**

- Biopsies show a subepidermal blister containing numerous eosinophils.
- The underlying dermis is oedematous and also contains an inflammatory infiltrate rich in eosinophils.

### **Immunofluorescence**

- Direct immunofluorescence on perilesional skin reveals linear deposition of IgG and C3 along the basement membrane zone.

### **Prognosis**

- Mortality rates are low with appropriate immunosuppressive regimes.
- Most complications are therapy-related.

# Dermatitis herpetiformis

## Definition

- An immunobullous skin disorder characterized by intensely itchy papules and vesicles, granular deposition of IgA in the papillary dermis, and a strong association with coeliac disease.

## Epidemiology

- Rare.
- Any age may be affected, but the peak incidence is young adults aged 20–40y.
- Males are affected twice as often as females.
- The condition is particularly common in Northern Europe and Ireland.
- Up to 90% of people have evidence of coeliac disease, though this may be subclinical.

## Aetiology

- IgA transglutaminase antibodies formed in the gut appear to be the key mediator.

## Pathogenesis

- IgA transglutaminase antibodies react with transglutaminase enzymes in the skin.
- Fixation of complement stimulates chemotaxis of neutrophils into the papillary dermis.
- Enzymes released from neutrophils lead to blister formation.

## Presentation

- The rash is composed of groups of papules and vesicles which are intensely itchy.
- Sites of predilection are the shoulders, back, buttocks, elbows, and knees.

## Histopathology

- Biopsies from early lesions show collections of neutrophils within the papillary dermis (papillary dermal microabscesses).
- Biopsies from established lesions show a subepidermal blister rich in neutrophils.

## Immunofluorescence

- Direct immunofluorescence of perilesional skin reveals granular deposition of IgA in the papillary dermis.

## Prognosis

- The disease is usually chronic and lifelong, but shows a dramatic response to the drug dapsone.

## Erythema nodosum

### Definition

- A syndrome characterized clinically by an acute painful erythematous nodular skin eruption and histologically by a septal panniculitis.

### Epidemiology

- Typically affects young adults with a marked predilection for women.

### Aetiology

- Numerous aetiologies have been described.
- Most common associations are sarcoidosis (📖 p. 349), infections, inflammatory bowel disease (📖 p. 104 and 📖 p. 105), and drugs.

### Pathogenesis

- Unknown, but probably represents a form of hypersensitivity reaction to infection, drug, or an underlying systemic disease.

### Presentation

- Sudden onset of red warm tender skin nodules.
- Classically involves the shins, but other sites may be affected.
- Systemic symptoms such as fever and malaise may also be present.

### Histopathology

- Biopsies show a septal panniculitis characterized by an inflammatory infiltrate centred on the septa of the subcutaneous fat.
- The inflammatory infiltrate is composed predominantly of lymphocytes and macrophages.
- Collections of histiocytes surrounded by cleft-like spaces are well described (Mieschner's radial granuloma).

### Prognosis

- The condition is usually self-limiting over a period of weeks with the skin nodules eventually fading and discolouring rather like a bruise.

# Pyoderma gangrenosum

## Definition

- An inflammatory skin disease characterized by the development of one or more large necrotic ulcers with ragged undermined violaceous borders.

## Epidemiology

- Uncommon.
- Typically affects middle-aged adults.

## Aetiology

- Unknown, though more than half of all cases are associated with a systemic disease (particularly inflammatory bowel disease and arthritis).

## Pathogenesis

- Unknown, though many immune abnormalities have been described.
- Whether it represents a form of vasculitis is controversial.

## Presentation

- The lesion begins as an erythematous pustule or nodule, typically on the lower extremity.
- Often there is a history of preceding minor trauma (pathergy).
- There is then rapid evolution into a necrotic ulcer with undermined red-purple edges.

## Histopathology

- Histology is variable and non-specific.
- There is epidermal ulceration with extensive underlying dermal inflammation and abscess formation.

## Prognosis

- Recurrence is common and more than half of patients require long-term therapy to control the disease.



## Skin infections

### Acute folliculitis

- Infection of hair follicles, usually due to *Staphylococcus (S.) aureus*.
- Presents with small red tender pustules.
- Deep extension of the acute inflammation may lead to a furuncle with more surrounding erythema and pain. Scarring may occur after healing.

### Impetigo

- Highly infectious superficial bacterial skin infection.
- Very common, particularly in children.
- Caused by either *S. aureus* or *Streptococcus (S.) pyogenes*.
- Presents with vesicles covered by a golden yellow crust, typically around the mouth and nose.

### Staphylococcal scalded skin syndrome

- A superficial blistering skin disease caused by strains of *S. aureus* producing an epidermolytic toxin.
- Seen almost exclusively in neonates and young children.
- The skin rash is initially erythematous and then extensively blisters with an appearance likened to a scald.
- Healing occurs within 2–3 weeks without scarring.

### Cellulitis

- A deep skin infection caused by *S. pyogenes*.
- Mostly occurs on the legs as an erythematous rash with oedema.
- ▶ Clinically may closely mimic deep venous thrombosis (📖 p. 37).

### Necrotizing fasciitis

- A rapidly progressive necrotizing infection of subcutaneous soft tissues.
- *S. aureus* and group A  $\beta$ -haemolytic streptococci (dubbed ‘flesh-eating bacteria’) are the most commonly cultured organisms, but infection is often polymicrobial.
- Fournier’s gangrene is a variant occurring on the scrotum (📖 p. 184).
- Rapid surgical debridement is essential to avoid systemic sepsis.

### Cutaneous tuberculosis

- Most cases are caused by haematogenous spread from a tuberculous infection elsewhere in the body.
- Lesions occur mostly on the face (particularly around the nose) as red papules and plaques with a gelatinous consistency.
- Biopsies show confluent tuberculoid granulomas in the dermis which may show central necrosis. Acid-fast bacilli are usually not demonstrable as they are too scanty.

### Non-tuberculous mycobacterial infections

- A number of non-tuberculous environmental mycobacteria may cause infection if inoculated into the skin.
- Examples include *Mycobacterium (M.) marinum* (associated with underwater injuries), *M. fortuitum/chelonae* and *M. kansasii*.

- Biopsies typically show areas of suppurative granulomatous inflammation within which small numbers of acid-fast bacilli may be found.

### **Viral warts**

- Very common skin lesions caused by human papilloma virus (HPV) infection.
- May occur anywhere on the skin in people of any age.
- Clinically appear as keratotic papules.
- Immunosuppressed individuals may have them in large numbers.
- Biopsies show marked papillomatosis with hyperkeratosis and tiers of parakeratosis. The keratinocytes show typical HPV cytopathic effects with vacuolation and large keratohyaline granules.

### **Herpes simplex**

- Caused by HSV types 1 and 2.
- Infections involve the oral and/or genital areas.
- Infection is lifelong due to viral latency within sensory ganglia.
- Recurrent episodes may be precipitated by many factors and is characterized by the onset of groups of vesicles on an erythematous base.
- Biopsies show ballooning degeneration of keratinocytes with acantholysis. Keratinocyte nuclei contain characteristic pale intranuclear inclusions.

### **Varicella zoster**

- Varicella zoster virus (VZV) is highly contagious and most individuals are infected in childhood, leading to chicken pox.
- Infection is lifelong due to viral latency within sensory ganglia.
- Reactivation of the virus in adulthood leads to herpes zoster (shingles), presenting as a band-like vesicular eruption along the distribution of a sensory nerve.

### **Molluscum contagiosum**

- Caused by molluscipoxvirus infection.
- Results in the eruption of groups of small umbilicated papules on the face, limbs, and trunk of young children or the genital region of young adults.
- Biopsies show a highly distinctive lobular epidermal proliferation in which the keratinocytes contain large basophilic cytoplasmic inclusions.

### **Dermatophytoses**

- Common superficial fungal infections caused by 'ringworm' fungi.
- Cause slowly enlarging scaly erythematous annular lesions on the body (tinea corporis), head (tinea capitis), or foot (tinea pedis).

### **Tinea (pityriasis) versicolor**

- Superficial fungal infection caused by the yeast *Malassezia globosa*.
- Presents with multiple areas of hypo- or hyperpigmentation with fine scale in young adults.
- Biopsies show budding yeasts and hyphae within the stratum corneum ('spaghetti and meatballs').

## **Benign cutaneous lumps**

### **Fibroepithelial polyps**

- Very common lesions which typically occur as multiple small pedunculated papules around the neck, axillae, and groin.
- Most are removed for cosmetic reasons or because they catch on clothing.
- Histologically, they are composed of a core of fibrovascular tissue covered by normal or hyperplastic epidermis.

### **Epidermoid cysts**

- Common cutaneous cysts typically arising on the face, neck, upper trunk, vulva, or scrotum.
- Histologically, the cyst is filled with laminated keratin and lined by squamous epithelium with a granular layer

### **Pilar (tricholemmal) cysts**

- Common cutaneous cysts which almost always occur on the scalp.
- Histologically, the cyst is lined by pale squamous epithelial cells showing abrupt keratinization without formation of a granular layer.

### **Seborrhoeic keratoses**

- Very common lesions seen in middle-aged and elderly adults.
- Appear as brown-black greasy warty nodules which are often multiple.
- May occur anywhere on the body apart from the palms and soles.
- Histologically composed of a proliferation of basaloid keratinocytes showing variable squamous differentiation, often with hyperkeratosis and horn cyst formation.

### **Lentigo simplex**

- Very common melanocytic lesion presenting as brown to black well-circumscribed macules which may occur anywhere on the body.
- Histology shows elongation of epidermal rete ridges associated with an increased number of basal melanocytes. Pigmentation is increased within the epidermis and in the papillary dermis.

### **Melanocytic naevi**

- Extremely common melanocytic lesions which are virtually universal in white individuals and may be found anywhere on the body.
- Typically show temporal evolution from junctional naevus → compound naevus → intradermal naevus.
- Histologically, junctional naevi show nests of melanocytes located at the tips of the rete ridges. Compound naevi contain a dermal population of melanocytes in addition to junctional nests. Intradermal naevi contain only dermal melanocytes.

### **Common blue naevus**

- A relatively common dermal melanocytic naevus which appears as a dark blue papule across a wide age range.
- May occur anywhere on the body, but more commonly on the hands, feet, buttocks, scalp, and face.

- Histologically composed of heavily pigmented spindled and dendritic dermal melanocytes.

### Spitz naevus

- A benign melanocytic lesion typically presenting in children or young adults as a pink or red/brown papule or nodule.
- Usually seen on the head, neck, and extremities.
- Histologically, Spitz naevi are usually compound melanocytic lesions composed of large epithelioid and/or spindled cells containing abundant eosinophilic cytoplasm and a conspicuous nucleolus.
- Spitz naevi are of particular importance histologically because the large size of the melanocytes can lead to a misdiagnosis as melanoma.

### Lipoma

- Very common benign fatty tumour.
- Presents as a slow-growing mobile painless subcutaneous lump.
- Histologically composed of lobules of mature adipocytes.

### Dermatofibroma

- Common benign fibrous tumour of skin.
- Presents as a reddish brown papule on the trunk or lower legs.
- Histologically composed of an ill-defined dermal lesion composed of short interlacing spindle cells within variable amounts of collagen, foamy macrophages, blood vessels, and inflammatory cells.

### Lobular capillary haemangioma

- Benign vascular tumour also widely known as pyogenic granuloma.
- Present as red papules or nodules which often ulcerate and bleed.
- Occurs mostly on head and neck or extremities.
- Histologically composed of a polypoid dermal lesion composed of lobules of small capillaries.

### Neurofibroma

- Common benign cutaneous nerve sheath tumour.
- Most cases are sporadic, but note that multiple neurofibromas and café-au-lait spots are associated with neurofibromatosis type 1.
- Presents as a soft flesh-coloured papule or nodule at any skin site.
- Histologically composed of a dermal or subcutaneous lesion containing Schwann cells and fibroblasts in a fibrillar background.

### Pilomatrixoma

- Common benign skin tumour showing hair matrix differentiation.
- Presents as a firm papule or nodule in a child or young adult.
- Often occur on the cheek.
- Histologically composed of nodules of basaloid cells showing transformation into anucleate eosinophilic cells ('ghost cells') in the centre of the nodules. Calcification is very common.

## Basal cell carcinoma

### Definition

- A group of malignant epidermal tumours composed of basaloid cells.

### Epidemiology

- Very common tumours accounting for 70% of all skin malignancies.
- Seen predominantly in fair-skinned adults with sun damage.

### Aetiology

- Cumulative ultraviolet (UV) radiation exposure is the key risk factor.

### Carcinogenesis

- Almost all show mutations in genes encoding proteins involved in the sonic hedgehog pathway, most commonly PTCH1.
- A smaller proportion display mutations in SMOOTHENED which encodes the protein normally inhibited by the PATCHED1 protein.

### Presentation

- Most appear as pearly papules or nodules on sun-exposed skin.
- Ulceration may occur.
- Superficial variants present as erythematous patches which can be mistaken for eczematous lesions.

### Histopathology

- The tumour is composed of groups of small basaloid cells with scanty cytoplasm which grow in a variety of patterns. The cells at the edge of the groups typically line up in a palisade (peripheral palisading).
- The tumour stroma is typically loose and mucinous.
- Artefactual retraction spaces between the tumour cells and stroma is often seen and can be a useful diagnostic feature.
- A number of morphological subtypes are recognized including nodular, superficial, infiltrative, morpoeic, and micronodular.

### Prognosis

- Show locally invasive behaviour, but metastasis is extremely rare.
- Complete excision is usually curative.
- Recurrences are more common at high-risk sites (head and neck) and with certain morphological subtypes (infiltrative, morpoeic, micronodular).

### Pathological staging of skin carcinomas

#### Primary tumour (T)

pT1: tumour measures 2cm or less in size.

pT2: tumour measures >2cm in size.

pT3: tumour invades muscle, bone, cartilage, jaws, and orbit.

pT4: tumour invades skull base, axial skeleton.

#### Regional lymph nodes (N)

pN1: single nodal metastasis measuring <3cm in size.

pN2: single nodal metastasis measuring 3–6cm in size or multiple nodal metastases, none measuring >6cm.

pN3: any nodal metastasis measuring >6cm.

# Squamous cell carcinoma

## Definition

- A malignant epidermal tumour showing squamous differentiation.

## Epidemiology

- Common tumours accounting for ~15% of all skin malignancies.
- Most arise on sun-exposed skin of elderly fair-skinned adults.

## Aetiology

- Most are related to cumulative UV radiation exposure.
- Immunosuppression increases the risk. Transplant recipients are particularly prone to developing multiple tumours.

## Carcinogenesis

- Most arise from **actinic keratoses** which are dysplastic epidermal lesions arising on sun-damaged skin.
- UV radiation, particularly UVB, induces DNA damage in growth controlling genes such as KRAS and CDK4.

## Presentation

- Skin plaques or nodules, often with a keratinous surface crust.
- Ulceration may be present.

## Histopathology

- Nests, sheets, and cords of atypical squamous epithelial cells are seen arising from the epidermis and infiltrating into the underlying dermis.
- Tumours are graded into well, moderately, or poorly differentiated, depending on the extent of keratinization.

## Prognosis

- Most are only locally infiltrative at the time of diagnosis and cured by surgical excision.
- Risk factors for recurrence or metastasis include depth of invasion, poor differentiation, perineural invasion, narrow excision, immunosuppression.

## Pathological staging of skin carcinomas

### Primary tumour (T)

pT1: tumour measures 2cm or less in size.

pT2: tumour measures >2cm in size.

pT3: tumour invades muscle, bone, cartilage, jaws, orbit.

pT4: tumour invades skull base, axial skeleton.

### Regional lymph nodes (N)

pN1: single nodal metastasis measuring <3cm in size.

pN2: single nodal metastasis measuring 3–6cm in size or multiple nodal metastases, none measuring >6cm.

pN3: any nodal metastasis measuring >6cm.

# Malignant melanoma

## Definition

- A malignant melanocytic tumour.

## Epidemiology

- Less common than basal or squamous cell carcinomas of skin, but much more frequently fatal.
- Seen predominantly in fair-skinned individuals with sun exposure.

## Aetiology

- Intermittent high-dose UV radiation exposure is the major risk factor.
- An element of genetic susceptibility may also be relevant.

## Genetics

- Melanomas arising in intermittently sun-exposed sites typically show mutations in BRAF as an early genetic event.
- Progression is associated with the accumulation of mutations in genes, including KIT, MITF, CDKN2A, TP53, and PTEN.
- The vast majority also demonstrate chromosomal aberrations in the form of gains and/or losses of chromosomal parts.

## Presentation

- Most melanomas present as pigmented skin lesions demonstrating **A**symmetry, irregular **B**orders, uneven **C**olour, and **D**iameter >6mm (the 'ABCD' acronym).

## Histopathology

- Common to all forms of malignant melanoma is the presence of a neoplastic proliferation of severely atypical melanocytes.
- If the process is confined to the epidermis, the term **melanoma in situ** may be employed.
- Once invasion into the dermis has occurred, the term **invasive melanoma** may be employed.

## Evolution

- Most melanomas initially grow as a flat lesion in a radial fashion, known as the **radial growth phase**. During this phase, there is either no dermal invasion or cells within the dermis are not able to survive and proliferate.
- With progression, the growth switches such that cells within the dermis are able to proliferate. This is known as **vertical growth phase** and is associated with the emergence of metastatic potential (Fig. 15.1).

## Prognosis

- Survival is related to the stage of the disease at diagnosis.
- Key determinants of stage are the thickness of the melanoma (known as the **Breslow thickness**) and the presence of ulceration.
- Mitotic rate is also now recognized as a strong prognostic indicator in vertical growth phase melanomas.

## TNM 7 pathological staging of malignant melanoma

### Primary tumour (T)

pT1a: tumour  $\leq 1.0\text{mm}$  thick, without ulceration, mitoses  $< 1/\text{mm}^2$ .

pT1b: tumour  $\leq 1.0\text{mm}$  thick, with ulceration or mitoses  $\geq 1/\text{mm}^2$ .

pT2a: tumour 1.01–2.0mm thick, without ulceration.

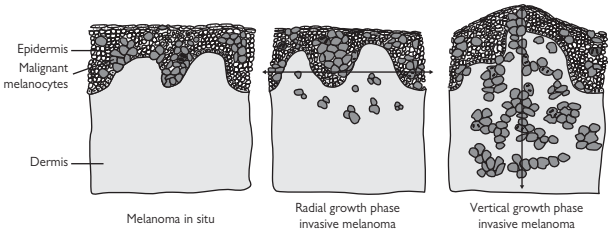
pT2b: tumour 1.01–2.0mm thick, with ulceration.

pT3a: tumour 2.01–4.0mm thick, without ulceration.

pT3b: tumour 2.01–4.0mm thick, with ulceration.

pT4a: tumour  $> 4.0\text{mm}$  thick, without ulceration.

pT4b: tumour  $> 4.0\text{mm}$  thick, with ulceration.



**Fig. 15.1** Diagrammatic representation of different stages of melanoma. Melanoma *in situ* comprises malignant melanocytes confined to the epidermis. In radial growth phase invasive melanoma, malignant melanocytes invade the dermis, but the growth of the tumour is still confined to the epidermis. In vertical growth phase invasive melanoma, the growth of the tumour switches from the epidermis to the dermis. Reproduced with permission from *Clinical Pathology*, Carton, Daly, and Ramani, Oxford University Press, p. 381, Figure 16.14.



# Mycosis fungoides

## Definition

- A low-grade T-cell lymphoma of variably epidermotropic skin-homing T-lymphocytes.

## Epidemiology

- Most common form of primary cutaneous lymphoma, but overall an uncommon disease, affecting 0.3 per 100,000 people annually.
- Usually a disease of adulthood, but occasionally affects children.

## Aetiology

- Unknown.

## Genetics

- Disease progression is associated with chromosomal aberrations, particularly involving chromosomes 8 and 17.

## Presentation

- Characterized by the sequential appearance of patches, plaques, and tumours on non-sun-exposed skin (particularly around the buttocks and trunk).
- Patches are multiple large (>10mm) flat erythematous scaly lesions.
- Plaques are elevated lesions which may develop within patches or *de novo*.
- Eventually tumour nodules, and sometimes erythroderma, supervene.
- Bone marrow, lymph nodes, and visceral organs may be involved in advanced disease.

## Histopathology

- Patch stage shows a mild upper dermal T-cell infiltrate associated with variable epidermotropism. Early disease is often difficult to diagnose as the features overlap with a number of inflammatory conditions.
- Plaque stage shows a more prominent and band-like infiltrate of T-cells with more epidermotropism. Collections of neoplastic lymphocytes within the epidermis are frequently seen (Pautrier microabscesses). Nuclear atypia of the lymphocytes is more appreciable.
- Tumour stage shows a more diffuse dermal infiltrate which may extend into subcutaneous fat. Epidermotropism may be lost.

## Immunophenotype

- Most cases show a T-helper cell phenotype, i.e. CD3+ CD4+ CD8–.

## Prognosis

- Risk of progression and death correlates with the stage of disease at presentation.
- 10-year survival rates are high (85–95%) in patch and plaque stage disease, dropping to 40% in tumour stage, and to 20% if there is nodal involvement.

# Osteoarticular pathology

- Osteoarticular malformations 306
- Osteoporosis 307
- Paget's disease 308
- Osteomalacia 309
- Osteomyelitis 310
- Benign bone tumours 311
- Malignant bone tumours 312
- Osteoarthritis 313
- Rheumatoid arthritis 314
- Spondyloarthropathies 315
- Crystal arthropathies 316
- Septic arthritis 317
- Soft tissue tumours 318

## Osteoarticular malformations

### Developmental dysplasia of the hip

- An imperfect development of the hip joint, which predisposes the joint to dislocation.
- May involve the femoral head, the acetabulum, or both.
- Affects 1–2 per 1000 live births.
- All neonates screened as part of the routine neonatal examination.
- More commonly affects the left hip.
- Four times more common in girls.
- Risk factors include a positive family history, being firstborn, breech delivery, oligohydramnios.
- Requires prompt treatment to prevent secondary osteoarthritis.

### Talipes equinovarus

- Also known as 'clubfoot'.
- A deformity in which the forefoot is adducted and supinated whilst the hindfoot points downwards.
- Affects ~1 in 1000 live births.
- Usually an isolated idiopathic abnormality, but may be associated with spina bifida or compression *in utero* secondary to oligohydramnios.
- Severity of the deformity is variable.
- Conservative treatment may be effective, otherwise surgery can be considered.

# Osteoporosis

## Definition

- A metabolic bone disease characterized by a generalized reduction in bone mass, increased bone fragility, and predisposition to fracture.

## Epidemiology

- Very common.
- Typically presents in elderly women, though people of all ages may have clinically silent disease.

## Aetiology

- Oestrogen deficiency is a key association.
- Other recognized associations include glucocorticoid therapy, Cushing's syndrome, hyperparathyroidism, hyperthyroidism, coeliac disease, and inflammatory bowel disease.

## Pathogenesis

- Bone mass in later life is determined by the peak bone mass attained in early adulthood and the subsequent rate of bone loss.
- Peak bone mass is largely genetically determined, but is modified by factors such as nutrition, physical activity, and health early in life.
- Bone loss occurs with increasing age due to decreasing bone turnover, decreasing physical activity, and reduced calcium absorption from the gut. In women, oestrogen deficiency after the menopause markedly accelerates bone loss.
- Glucocorticoids decrease osteoblastic activity and lifespan, reduce calcium absorption from the gut, and increase renal calcium loss. Sex hormone production is also suppressed, which increases bone turnover and loss.

## Presentation

- Most cases are clinically silent until fragility fractures occur.
- Classic sites of involvement are the vertebrae, distal radius, and neck of femur.
- Vertebral fractures lead to loss of height and kyphosis. May occur spontaneously, after lifting or bending down.
- Distal radius (Colles') fractures and neck of femur fractures occur following a fall, often from a standing height or less.

## Histopathology

- Cancellous bone shows thinning and disconnection of bony trabeculae.
- Cortical bone is thinned with the enlargement of Haversian canals.

## Prognosis

- Neck of femur fractures are the most problematic as these require hospital admission and surgical fixation.
- Elderly patients with significant coexisting medical problems may have a significant risk of post-operative mortality.

## Paget's disease

### Definition

- A metabolic bone disease characterized by excessive chaotic bone turnover in localized parts of the skeleton.

### Epidemiology

- Marked geographic variation, being particularly common in the UK.
- Seen mostly in older adults.

### Aetiology

- Unknown.
- A viral cause has been suggested as viral inclusions have been seen within osteoclasts of Pagetoid bone on electron microscopy.

### Pathogenesis

- The disease passes through a number of stages, all of which may be seen simultaneously within the same bone or in different bones.
- Initially, there is intense osteoclastic resorption followed by frantic bone formation by osteoblasts.
- The osteoblastic activity then becomes overexaggerated with the laying down of grossly thickened weak bone which is prone to deformity and pathological fracture.

### Presentation

- The vast majority of patients are asymptomatic, the diagnosis being made incidentally on radiology.
- Symptomatic disease usually presents with bony pain and deformity.

### Biochemistry

- ↑↑ Serum alkaline phosphatase due to the intense osteoblastic activity.
- Serum calcium is usually normal.

### Histopathology

- Bony trabeculae are thickened with a 'jigsaw' pattern of cement lines, indicating repetitive phases of bone resorption and formation.
- Cortical Haversian canals are replaced by irregular trabeculae.
- The marrow becomes densely fibrotic.

### Prognosis

- Most patients do not suffer any significant problems.
  - Potential complications include pathological fractures and deafness due to the compression of cranial nerve VIII by enlarging skull bones.
- Osteosarcoma (📖 p. 312) is the most significant complication of Paget's disease. Although it only occurs in <1% of cases, it has a very poor prognosis. Osteosarcoma should be considered in any patient known to have Paget's disease if their bony pain rapidly worsens.

# Osteomalacia

## Definition

- A metabolic bone disease characterized by inadequate mineralization of osteoid, leading to abnormally soft bones.

## Epidemiology

- Uncommon in developed countries.
- Seen mostly in the elderly.

## Aetiology

- Almost all cases are due to vitamin D deficiency.
- Common causes of vitamin D deficiency are low sun exposure, malabsorption, chronic liver disease, and chronic kidney disease.

## Pathogenesis

- Inadequate mineralization of bone matrix leads to an increase in osteoid over bony trabeculae.
- Bones become abnormally soft and prone to deformity or fracture.

## Presentation

- Diffuse bone pain and tenderness.
  - Weakness of proximal muscles.
- ▶ Many cases probably go undiagnosed due to the non-specific nature of the presenting symptoms.

## Histopathology

- Bony trabeculae are covered by an excessively thick layer of unmineralized osteoid.

## Prognosis

- Vitamin D supplementation usually results in rapid mineralization of bone and resolution of symptoms, though some deformity may remain.

## Osteomyelitis

### Definition

- Infection of a bone.

### Epidemiology

- May develop at any age.
- Acute haematogenous osteomyelitis is typically a disease of children.

### Acquisition of infection

- Haematogenous spread is typically the case in acute osteomyelitis in children.
- Penetrating trauma, e.g. open fracture.
- Iatrogenic, e.g. following a joint replacement or root canal treatment.
- Direct spread from an adjacent infection, e.g. as a complication of a foot ulcer in a diabetic.

### Microbiology

- Most infections are caused by *Staphylococcus (S.) aureus*.
- Patients with sickle cell disease are prone to *Salmonella* osteomyelitis.

### Pathogenesis

- Infection leads to an influx of acute inflammatory cells into the bone and suppurative inflammation.
- Destruction of bone leads to areas of necrotic bone known as sequestrum.
- Failure to eradicate infection may lead to chronic osteomyelitis with areas of infected necrotic bone surrounded by areas of new bone formation.

### Presentation

- Fever and pain in the affected bone.
- Children may present with failure to weight bear.

### Prognosis

- Aggressive treatment is needed with intravenous antibiotics and surgical debridement of any necrotic bone if a cure is to be achieved.
- Development of osteomyelitis following a joint replacement may lead to failure of the prosthesis.

## Benign bone tumours

### Osteochondroma

- A benign bone-forming tumour of bone.
- Typically grows as a solitary exophytic nodule from the metaphysis of a long bone close to the epiphyseal growth plate.
- Common tumour, usually found in children.
- Histologically, the lesion has an outer fibrous perichondrium, a cartilage cap, and an underlying bony stalk.

### Chondroma

- A benign cartilage-forming tumour of bone.
- Enchondromas arise in the medulla of the bone, typically in the hands and feet.
- Periosteal chondromas arise on the surface of the bone, the proximal humerus being a characteristic site.
- They are usually discovered incidentally.
- Histologically, the lesion is composed of chondrocytes set within an abundant cartilaginous matrix.

### Osteoid osteoma

- A benign bone-forming tumour of bone.
- Most commonly arises in a long bone of a child or young adult, especially the proximal femur.
- Characteristically painful, especially at night.
- Readily identified on plain radiographs as a small lucent nidus <1cm in size.
- Histologically, the lesion is well-circumscribed and consists of a hypervascular dense area of bony trabeculae surrounded by reactive bone.

### Giant cell tumour of bone

- A benign, locally aggressive neoplasm of bone that arises in the ends of long bones.
- Typically present in young adults aged 20–45 with pain and swelling over the site of the tumour.
- Histologically, the tumour is composed of sheets of neoplastic ovoid mononuclear cells interspersed with uniformly distributed, large osteoclast-like giant cells.
- Local recurrence following excision occurs in ~25% of cases. Distant metastases are very rare, but have been reported.



## **Malignant bone tumours**

### **Metastases**

- The vast majority of malignant bone tumours are metastatic.
- Most originate from carcinomas of the lung, breast, kidney, thyroid, and prostate.
- Most metastatic deposits are osteolytic, i.e. they destroy bone.
- Bony metastases of prostate carcinoma are characteristically osteosclerotic, i.e. they stimulate the formation of new bone.
- Bony metastases are one of the common causes of hypercalcaemia.

### **Osteosarcoma**

- A malignant bone-forming tumour.
- The most common malignant primary bone tumour.
- Most present between the ages of 5–25 with persistent deep pain within a long bone. A palpable mass may be present.
- Cases arising in the elderly are usually secondary to Paget's disease.
- Histologically, the tumour is composed of atypical cells which produce osteoid.
- Osteosarcoma is a highly malignant tumour which shows early and rapid haematogenous dissemination, particularly to the lungs.
- Prognosis is largely related to response to preoperative therapy. Responders have long-term survival rates of 80–90% whereas non-responders have poor survival rates of <15%.

### **Chondrosarcoma**

- A malignant cartilage-forming tumour.
- The second most common malignant primary bone tumour.
- Most occur in adults aged >50y.
- The most common site is the bones of the pelvis.
- Histologically, the tumours are composed of variably atypical cells which produce a cartilaginous matrix. Chondrosarcomas are graded histologically from 1 to 3; the vast majority are grade 1 or 2.
- Histological grade is the most important prognostic factor. The 5-year survival for grade 1 tumours is 90% whereas for grade 2 and 3 tumours, it is closer to 50%.

### **Ewing's sarcoma**

- A malignant round cell tumour of bone.
- Most occur in children or adolescents aged <20y.
- Tends to present with pain and a mass in a long bone, pelvis, or rib.
- Histology shows a small round tumour cells with scanty cytoplasm. In some cases, the tumour cells form rosette-like structures. Necrosis is commonly seen.
- Most cases show a recurrent t(11;22) chromosomal translocation which fuses the EWS gene to the FLI1 gene.
- Survival rates are <50%. Prognosis depends on the stage, anatomic location, and size of the tumour.

# Osteoarthritis

## Definition

- A group of diseases characterized by joint degradation.

## Epidemiology

- The commonest joint disease.
- ~2 million people in the UK have symptomatic disease.
- Predominantly a disease of the elderly.

## Aetiology

- In most cases, no clear underlying disorder is present (primary osteoarthritis).
- Other conditions causing injury to joints may result in secondary osteoarthritis, e.g. rheumatoid arthritis, gout.

## Pathogenesis

- The primary change appears to be damage to the articular cartilage.
- Low-grade inflammation leads to the release of metalloproteinases from chondrocytes, which degrade the cartilage matrix.
- Underlying bone is exposed which responds by becoming thickened.

## Presentation

- Joint pain, tenderness, stiffness.
- Symptoms typically worsen during the day with activity.
- Principally affects the hip, knee, spine, and small joints of the hands.

## Histopathology

- Articular cartilage is thinned and lost.
- Subchondral bone is thickened and sclerotic.

## Prognosis

- The condition tends to worsen with time and require analgesics.
- Severe disease usually requires joint replacement.

## Rheumatoid arthritis

### Definition

- A multisystem autoimmune disease in which the brunt of disease activity falls upon synovial joints.

### Epidemiology

- Common, affecting ~1% of people.
- Particularly affects young and middle-aged women.

### Aetiology

- The initial trigger remains unknown.
- Once inflammation begins, it appears to become self-perpetuating.

### Pathogenesis

- Involved joints show infiltration of the synovium by CD4+ T-cells, B-cells, plasma cells, and macrophages.
- In response, the synovium proliferates, forming a mass of hyperplastic synovium, known as **pannus**.
- The pannus erodes into the articular cartilage and destroys the joint.

### Presentation

- Symmetrical swollen painful stiff small joints of hands and feet.
- Symptoms are typically worse in morning.

### Serology

- ~70% of patients are positive for **rheumatoid factor** (RhF), an autoantibody which binds the Fc portion of IgG. RhF is often positive in other autoimmune diseases and some apparently healthy individuals.
- Newer antibodies, known as **anti-citrullinated protein antibodies**, have a much greater specificity, though are not widely available.

### Extra-articular manifestations

- Cardiac disease: ischaemic heart disease, pericarditis.
- Vascular disease: accelerated atherosclerosis, vasculitis.
- Haematological disease: anaemia, splenomegaly.
- Pulmonary disease: pulmonary fibrosis, pleuritis.
- Skin: rheumatoid nodules, erythema nodosum, pyoderma gangrenosum.
- Neurological: peripheral neuropathy, stroke.
- Deposition of serum amyloid A as B-pleated sheets in multiple organs (AA amyloidosis).

### Histopathology

- Marked synovial hyperplasia with a heavy inflammatory infiltrate of lymphocytes and plasma cells.
- Germinal centre formation within lymphoid aggregates is typical.

### Prognosis

- The disease shows variable behaviour.
- ~25% have long-term remission, ~50% have chronic mild-to-moderate disability, whilst ~25% suffer progressive disease with severe disability.

# Spondyloarthropathies

## Definition

- A group of inflammatory joint diseases, characterized by arthritis affecting the spinal column and peripheral joints and enthesitis (inflammation at the insertion site of tendons and ligaments to bone).

## Epidemiology

- Common diseases, affecting nearly 1% of people.
- Usually present in young adults aged 20–40.
- There is a slight male predominance.

## Genetics

- Strong genetic association with possession of HLA-B27 allele.

## Pathogenesis

- Traditional theories proposed that an unidentified 'arthritogenic peptide' was presented by HLA-B27 to CD8+ cytotoxic T-cells, leading to joint inflammation.
- Recent work has focused on the properties of HLA-B27 itself after discoveries that the heavy chain has a tendency to misfold and form abnormal homodimers.
- Studies in transgenic rats have demonstrated that misfolded HLA-B27 causes endoplasmic reticulum stress and production of IL-23 via the T-helper 17 axis.

## Ankylosing spondylitis

- Affects 0.5% of people, usually presenting in young adults aged 20–40.
- Lower back pain due to sacroiliitis is the typical presentation.
- Extra-articular manifestations include iritis, pulmonary fibrosis, and aortitis.

## Reactive arthritis

- Occurs within 1 month of an infection elsewhere in the body.
- Usually related to a genitourinary infection with *Chlamydia* or a gastrointestinal infection with *Shigella*, *Salmonella*, or *Campylobacter*.
- May be due to the deposition of bacterial antigens and DNA in joints, but this has not been conclusively proven.
- Typically presents with pain and stiffness in the lower back, knees, ankles, and feet. Enthesitis is also common.

## Psoriatic arthropathy

- Seen in ~5% of patients with psoriasis (📖 p. 287).
- Mostly affects the distal interphalangeal joints and may lead to severe deformation.
- Cause is unknown.

## Enteropathic arthropathy

- Seen in ~10% of patients with inflammatory bowel disease.
- Typically affects the sacroiliac and lower limb joints asymmetrically.
- Cause is unknown.

## Crystal arthropathies

### Definition

- A group of joint diseases caused by the deposition of crystals in joints.

### Pathogenesis

- Crystals are deposited in joints.
- Neutrophils ingest the crystals and degranulate, releasing enzymes that damage the joint.

### Gout

- Caused by the deposition of urate crystals in a joint.
- Most cases are related to hyperuricaemia due to impaired excretion of urate by the kidneys.
- Acute gout causes an acute painful swollen red joint. Any joint may be involved, but the first metatarsophalangeal joint is particularly characteristic.
- Individuals with high urate levels may develop chronic tophaceous gout in which large deposits of urate (tophi) occur in the skin and around joints.

### Pseudogout

- Caused by the deposition of calcium pyrophosphate in a joint.
- Pyrophosphate is a by-product of the hydrolysis of nucleotide triphosphates within chondrocytes of cartilage.
- Shedding of crystals into a joint precipitates an acute arthritis which mimics gout.
- Pseudogout is typically seen in elderly women and usually affects the knee or wrist.

### Microscopy

- Joint fluid contains neutrophils and crystals.
- Urate crystals are needle-shaped and show negative birefringence.
- Pyrophosphate crystals are rhomboid/rod-shaped and show positive birefringence.

# Septic arthritis

## Definition

- Infection within a joint.

## Epidemiology

- May occur at any age.
- Patients with pre-existing joint disease are at higher risk.

## Acquisition of infection

- Infection is usually via haematogenous spread.
- Occasionally may follow penetrating trauma.

## Microbiology

- Almost all cases are caused by *S. aureus*.

## Pathogenesis

- Establishment of infection is favoured by the relative inability of phagocytes to enter the joint space.
- Infection spreads quickly, leading to rapid and irreversible joint destruction if antibiotic treatment is not started early.

## Presentation

- ▶ An extremely painful, hot, red, swollen joint.

## Microscopy

- Joint fluid contains neutrophils, but no crystals.

## Culture

- Microbiological culture of joint fluid and blood is essential to identify the causative organism and provide antibiotic sensitivities.

## Prognosis

- ▶ Irreversible joint destruction occurs without treatment.

## Soft tissue tumours

### Lipoma

- The commonest soft tissue tumour.
- Present as a painless subcutaneous mass in the limbs or trunk of adults.
- Histologically composed of lobules of mature adipocytes.

### Angiolipoma

- Present as painful, often multiple, subcutaneous masses in adults.
- The upper limb, especially the forearm, is frequently affected.
- Histologically composed of lobules of mature adipocytes and clusters of small capillary-like vessels which often contain fibrin microthrombi.

### Spindle cell lipoma

- Present as a painless subcutaneous mass in the upper back, shoulders, or neck of adults. Marked predilection for men.
- Histologically shows a well-circumscribed lesion composed of a mixture of mature adipocytes, short spindle cells, and a fibromyxoid stroma containing thick 'ropy' collagen bundles.

### Angioleiomyoma

- Presents as a painful subcutaneous mass, typically on the lower limbs.
- More common in women.
- Histologically shows a well circumscribed lesion composed of mature smooth muscle cells arranged around thick-walled blood vessels.

### Giant cell tumour of tendon sheath

- Presents as a painless slow-growing nodule, usually on a finger or toe.
- Peak age at presentation is 20–40y with a female preponderance.
- Histologically shows a lobulated tumour composed of round mononuclear cells, osteoclast-like multinucleated cells, foamy macrophages, and haemosiderin-laden macrophages.

### Fibroma of tendon sheath

- Presents as a firm nodule attached to a tendon, usually in a finger.
- Seen in young and middle-aged adults with a male preponderance.
- Histologically shows a well-circumscribed tumour composed of bland fibroblasts and thin slit-like blood vessels in a fibrous stroma.

### Fibromatoses

- A group of locally aggressive tumours with no capacity for metastasis.
- Superficial variants occur on the palms (Dupuytren's contracture) and soles (Ledderhose's disease).
- Deep variants (desmoid fibromatosis) occur around the limb girdles, the abdominal wall, or within the abdomen, particularly the mesentery.
- Histologically, all show bland spindled fibroblasts arranged in broad long fascicles infiltrating into surrounding structures.
- Local recurrence may cause significant problems if near vital structures.

### Solitary fibrous tumour

- Presents as a slowly enlarging mass in deep soft tissues of adults.

- Histologically composed of haphazardly arranged bland fibroblastic cells with variation in cellularity and collagenization. Dilated branching blood vessels are frequently seen within the tumour.
- The vast majority are benign, though a small proportion can show malignant behaviour.

### Liposarcomas

- The most common soft tissue sarcoma.
- Presents in adulthood with a deep seated mass in an extremity, limb girdle, or the retroperitoneum.
- **Well-differentiated liposarcoma** is the most frequent type. Histologically composed of relatively mature adipocytes showing variation in cell size together with scattered bizarre hyperchromatic stromal cells. Local recurrence is common following incomplete excision, but metastasis does not occur.
- **Myxoid liposarcoma** shows small spindle cells and lipoblasts in an abundant myxoid stroma containing branching thin-walled capillaries. Characterized genetically by the chromosomal translocation t(12;16).
- **Pleomorphic liposarcoma** is the least common form. Histologically composed of markedly pleomorphic cells containing multivacuolated lipoblasts.

### Leiomyosarcoma

- Malignant tumour showing smooth muscle differentiation.
- Presents with an enlarging mass in the retroperitoneum or limbs of adults.
- Histologically composed of fascicles of atypical smooth muscle cells.
- Half of all cases metastasize and cause death.

### Rhabdomyosarcoma

- Malignant tumours showing skeletal muscle differentiation.
- **Embryonal rhabdomyosarcoma** occurs in young children, most commonly in the head and neck region or genitourinary tract.
- **Alveolar rhabdomyosarcoma** occurs in older children and adolescents, most commonly in the limbs.
- **Pleomorphic rhabdomyosarcoma** occurs in the limbs of adults and behaves very aggressively.

### Synovial sarcoma

- Malignant tumour of uncertain differentiation.
- Presents in young adults with longstanding pain and a palpable mass in deep soft tissue.
- Histologically composed of highly cellular spindle cells, often with intermingled plumper epithelioid cells.
- Genetically characterized by the chromosomal translocation t(X;18).
- Behaves aggressively with poor long-term survival.

### Pleomorphic undifferentiated sarcoma

- High-grade sarcoma in which exhaustive investigation reveals no specific line of differentiation.
- Tend to be large deep-seated tumours which behave aggressively.



*This page intentionally left blank*

# Neuropathology

- Nervous system malformations 322
- Epilepsy 323
- Head injury 324
- Cerebral infarction 325
- Intracerebral haemorrhage 326
- Subarachnoid haemorrhage 328
- Meningitis 330
- Cerebral infections 331
- Multiple sclerosis 332
- Alzheimer's disease 333
- Dementia with Lewy bodies 334
- Parkinson's disease 335
- Huntington's disease 336
- Motor neurone disease 337
- Creutzfeldt–Jacob disease 338
- Central nervous system neoplasms 340
- Guillain–Barré syndrome 342
- Myasthenia gravis 343

## **Nervous system malformations**

### **Neural tube defects**

- Due to defective closure of the neural tube during embryogenesis.
- Both genetic and environmental factors are involved.
- Maternal folate deficiency in early gestation is said to be a risk factor.
- **Anencephaly** is a uniformly fatal malformation of the anterior neural tube, leading to the absence of the brain and cranial vault.
- **Encephalocele** is a protrusion of malformed brain tissue through a midline skull defect, usually in the occipital region. Large encephaloceles are usually fatal.
- **Spina bifida** is a group of malformations of the spinal cord due to a defective closure of the caudal end of the neural tube and lack of fusion of the vertebral arches and skin coverings. There may be associated outpouchings of meninges (**meningocele**) or meninges and spinal cord (**myelomeningocele**). The latter may cause problems such as urinary incontinence, constipation, and variable degrees of motor and sensory impairment of the legs.

### **Agensis of the corpus callosum**

- Occurs if the glial bridge fails to form between the two cerebral hemispheres or if axons fail to cross it. May be complete or partial.
- Often associated with other malformations.
- May cause varying degrees of psychomotor retardation.

### **Aqueductal stenosis**

- Developmental anomaly causing a narrowing of the cerebral aqueduct.
- A component of complex malformations and may be inherited in an autosomal recessive or X-linked manner.
- Presents with congenital hydrocephalus.

### **Chiari malformations**

- Type II (Arnold–Chiari) causes a small posterior fossa with downward displacement of the cerebellar vermis and deformity of the medulla. There is also usually a lumbar myelomeningocele.
- Type I is a milder version in which the cerebellar tonsils extend into the spinal canal. Some patients may be asymptomatic.

### **Dandy–Walker malformation**

- Absent or rudimentary cerebellar vermis, leading to filling of the posterior fossa by a large cyst which represents a dilated fourth ventricle.
- May be associated with other malformations.

### **Syringomyelia**

- Fluid-filled cavity within the central grey matter of the spinal cord.
- Usually affects the cervical and upper thoracic segments. Extension of the syrinx into the medulla is known as syringobulbia.
- Expansion of the syrinx causes atrophy of the adjacent spinal cord.
- Typically presents in early adulthood with isolated loss of pain and temperature in the upper limbs due to damage to spinothalamic tracts.

# Epilepsy

## Definition

- A recurrent tendency to spontaneous episodes of abnormal electrical activity within the brain which manifest as seizures.

## Epidemiology

- Common, affecting ~1% of people.

## Aetiology

- Very often idiopathic with no clear cause found.
- May be associated with underlying structural lesions (trauma, neoplasms, malformations), metabolic conditions (alcohol, electrolyte disorders), and infections.

## Partial seizures

- Features attributable to a localized part of one hemisphere.
- In simple partial seizures, consciousness is unimpaired (e.g. a focal motor seizure).
- In complex partial seizures, consciousness is impaired (e.g. motionless staring).

## Generalized seizures

- No features referable to one hemisphere; consciousness is always impaired.
- Absence seizures ('petit mal') cause brief (<10s) pauses, e.g. stopping talking in mid-sentence and then carrying on where left off.
- Tonic-clonic ('grand mal') cause a sudden loss of consciousness with stiffening (tonic) of limbs and then jerking (clonic).
- Myoclonic jerks cause sudden violent movements of the limbs.

## Temporal lobe epilepsy

- Typical onset in late childhood and adolescence.
- Usually presents with complex partial seizures, e.g. strange feeling in gut or sense of déjà vu or strange smell followed by automatism.
- Secondary generalized tonic-clonic seizures may also occur.
- In most cases, an epileptogenic focus is present in midline temporal structures.

## Childhood absence epilepsy

- Idiopathic generalized epilepsy syndrome, affecting children aged 4–12.
- Characterized by recurrent absence seizures.
- Some children also develop tonic-clonic type seizures.

## Juvenile myoclonic epilepsy

- Idiopathic generalized epilepsy syndrome, affecting children and adolescents aged 8–20.
- Most common seizure type is a myoclonic jerk, but tonic-clonic and absence seizures may also occur.

## Head injury

### Epidemiology

- ~50,000 severe head injuries occur each year in the UK.
- Responsible for some 20% of deaths in young people aged 5–45.
- May cause severe disability in those who survive.

### Skull fracture

- Severe head injury may cause skull fracture at the site of impact.
- A marker of serious head injury with increased risk of underlying intracranial injury such as contusions and haematomas.
- Base of skull fractures may cause lower cranial nerve palsies or cerebrospinal fluid (CSF) discharge from the nose or ear.

### Cerebral contusions

- Bruises on the surface of the brain.
- Occur when the brain suddenly moves within the cranial cavity and is crushed against the skull.
- Typically, there is injury at the site of impact (the 'coup' lesion) and at the site opposite this point (the 'contrecoup' lesion).
- Oozing of blood into the brain parenchyma and associated cerebral oedema are important contributors to raised intracranial pressure.

### Extradural haematoma

- Due to haemorrhage between the dura and the skull.
- The bleeding vessel is often the middle meningeal artery which is torn following fracture of the squamous temporal bone.
- Accumulation of extradural blood is slow as the firmly adherent dura is slowly peeled away from the inner surface of the skull.
- Patients may appear well for several hours following head injury, but then quickly deteriorate as the haematoma enlarges and compresses the brain.

### Subdural haematoma

- Due to haemorrhage between the dura and arachnoid.
- Results from tearing of delicate bridging veins that traverse the subdural space to drain into the cerebral venous sinuses.
- Blood from these veins spreads freely through the subdural space, enveloping the entire cerebral hemisphere on the side of the injury.
- Often seen in elderly people following relatively minor trauma and may present with confusion.

### Traumatic axonal injury

- Typically follows sudden acceleration-deceleration injuries.
- The most severe form is known as **diffuse axonal injury** which causes immediate unconsciousness and almost inevitable death.
- Histologically, there is widespread axonal swelling with increased numbers of microglia and eventually, degeneration of the involved fibre tracts.

# Cerebral infarction

## Definition

- Ischaemic necrosis of an area of the brain.

## Epidemiology

- Common, accounting for ~80% of strokes.
- Mostly seen in the elderly.

## Aetiology

- Most are caused by thromboemboli from either the internal carotid artery or the left side of the heart, lodging in a cerebral artery.
- A small proportion is due to *in situ* thrombosis of an atherosclerotic plaque within a cerebral artery.

## Pathogenesis

- Sustained occlusion of a cerebral artery leads to ischaemic necrosis of the territory of the brain supplied by the affected artery.

## Presentation

- Rapid onset of focal central nervous system (CNS) signs and symptoms related to the distribution of the affected artery (stroke, cerebrovascular accident).
  - The majority involve the territory of the middle cerebral artery of a cerebral hemisphere, resulting in varying degrees of contralateral hemiplegia and hemiparesis, homonymous hemianopia, and dysphasia.
- Transient ischaemic attacks (sudden episodes of focal CNS signs which resolve within 24h or less) are important warning signs to the risk of future cerebral infarction.

## Macroscopy

- After 24h, the infarcted area softens and there is loss of the normal sharp definition between the grey and white matter. Cerebral oedema within and around the infarct often causes midline shift.
- From 48h to 10 days, the infarct becomes more gelatinous and the distinction between the infarct and normal brain becomes clearer.
- From 10 days to 3 weeks, the infarct liquefies and undergoes cystic change.
- In some cases, reperfusion leads to bleeding into the infarct, visible as punctate haemorrhages ('haemorrhagic infarct').

## Histopathology

- Within the first 48h, there are ischaemic neurone changes (shrunken eosinophilic neurones) with an influx of neutrophils.
- Mononuclear cells then enter to phagocytose myelin breakdown products and astrocytes proliferate as the infarct organizes over 2–3 weeks.

## Prognosis

- Mortality is 20% at 1 month, then ~10% per year.
- Common complications include pneumonia, depression, contractures, constipation, and bed sores. Emotional effects on the family may be significant.

## Intracerebral haemorrhage

### Definition

- A spontaneous (non-traumatic) bleed into the substance of the brain.

### Epidemiology

- Accounts for ~20% of strokes.
- Mostly occurs in late middle age.

### Aetiology

- Hypertension is the commonest cause.
- Rarer causes include cerebral amyloid angiopathy, rupture of an arteriovenous malformation, and coagulation disorders.

### Pathogenesis

- Most cases related to hypertension are due to ruptured Charcot–Bouchard microaneurysms.
- A haematoma forms which destroys the brain structure and causes a sudden rise in intracranial pressure.

### Presentation

- Sudden onset of focal CNS signs related to the area of the haemorrhage together with symptoms and signs of raised intracranial pressure.
- Large haemorrhages are a common cause of sudden death due to a rapid rise in intracranial pressure and tonsillar herniation.
- Even small haemorrhages within the brainstem may cause sudden death if they disrupt vital cardiorespiratory centres.

### Macroscopy

- A haematoma is seen replacing the underlying brain structure with associated mass effect (midline shift, herniation).
- Hypertensive bleeds typically involve the basal ganglia/internal capsule, pons, or cerebellum.
- Bleeds related to other causes are more likely to be lobar.

### Histopathology

- Early lesions show a blood clot surrounded by brain tissue showing hypoxic neural changes and oedema.
- Reactive astrocytes then proliferate and the damaged area organizes much like an area of infarction.

### Prognosis

- Mortality is high (>40%) due to the effects of raised intracranial pressure.

*This page intentionally left blank*



## Subarachnoid haemorrhage

### Definition

- Bleeding into the subarachnoid space.

### Epidemiology

- Incidence of 8 per 100,000 per year.
- Most occur in adults aged 35–65.

### Aetiology

- Most commonly due to the rupture of a **berry aneurysm**.
- It has been hypothesized that a congenital defect in the tunica media of the cerebral vessels leads to aneurysm formation later in life due to atherosclerosis and hypertension.
- Most do not rupture.

### Pathogenesis

- Most berry aneurysms arise at sites of arterial bifurcation at the base of the brain (Fig. 17.1).
- The most common sites are around the anterior communicating artery (40%), the middle cerebral artery (34%), the internal carotid artery (20%), and the posterior cerebral artery (4%).
- Rupture of the aneurysm usually results in extensive bleeding through the subarachnoid space. The haemorrhage may extend into the brain tissue as well.

### Presentation

- Sudden severe headache, often described as like being struck on the back of the head.
- May be precipitated by exertion or straining.
- There may be unconsciousness or instant death in severe cases.

### Macroscopy

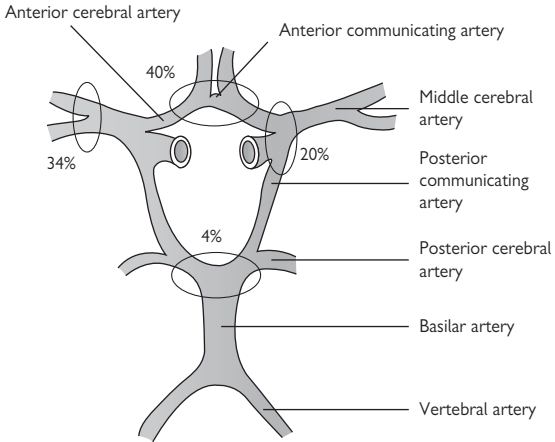
- Blood is present within the subarachnoid space, often with abundant clot around the circle of Willis at the base of the brain.
- After clearing the blood clot, the ruptured berry aneurysm may be found in the circle of Willis.

### Histopathology

- The aneurysm sac itself is composed of a thick fibrous intimal layer and an outer adventitial layer. No muscular media is present.

### Prognosis

- One third dies instantly from tonsillar herniation caused by a massive rise in intracranial pressure.
- One third becomes unconscious with a high risk of mortality or permanent neurological deficit.
- One third has a good outcome provided there is no re-bleeding.



**Fig. 17.1** Diagram of the circle of Willis showing common sites of berry aneurysm formation. Reproduced with permission from *Clinical Pathology*, Carton, Daly, and Ramani, Oxford University Press, p. 426, Figure 18.6.

# Meningitis

## Definition

- Infection of the subarachnoid space.

## Epidemiology

- Incidence of viral meningitis of ~11 per 100,000 per year.
- Incidence of bacterial meningitis of ~3 per 100,000 per year.

## Microbiology

- Viruses are the most common cause, usually echoviruses or coxsackie viruses.
- Most cases of bacterial meningitis are caused by *Neisseria meningitidis* or *Streptococcus pneumoniae*. *Escherichia coli* and group B streptococci are important causes in neonates.

## Pathogenesis

- Bacteria usually reach the meninges via the bloodstream from the nasal cavity, often following a viral upper respiratory tract infection.
- Both the meningococcus and the pneumococcus have capsules which render them resistant to phagocytosis and complement.
- The bacteria enter the subarachnoid space where the blood-brain barrier is weak, e.g. the choroid plexus.
- Once in the CSF, the bacteria multiply rapidly and stimulate an acute inflammatory response within the meninges.

## Presentation

- Headache, fever, neck stiffness, photophobia.
- The symptoms are usually more severe in bacterial meningitis.

## Microbiology

- Examination of CSF fluid obtained through lumbar puncture shows a predominance of lymphocytes in viral meningitis and many neutrophils in bacterial meningitis.
- Gram staining helps narrow down the likely cause in cases of bacterial meningitis.
- Culture of CSF and/or blood cultures should grow the causative organisms in cases of bacterial meningitis.
- No organism will be cultured in cases of viral meningitis.

## Prognosis

- Viral meningitis usually runs a mild course with complete recovery.
- Bacterial meningitis is a much more serious, potentially life-threatening, infection if not treated early with appropriate antibiotics. Survivors of severe cases may be left with permanent neurological sequelae, including hearing loss, learning difficulties, paralysis, and epilepsy.

## Cerebral infections

### Encephalitis

- Infection of the brain parenchyma.
- Viruses are the most common cause, usually herpes simplex virus (HSV).
- HSV encephalitis occurs following reactivation of the virus in the trigeminal ganglion from which the virus can pass into the temporal lobe.
- Simultaneous perioral involvement may be a clue to the diagnosis.
- Patients present with confusion, behavioural changes, and altered consciousness. Seizures may occur in severe cases.
- Imaging of the brain may highlight abnormalities in the temporal lobe.
- Polymerase chain reaction (PCR) on a CSF sample can identify the virus.
- Histologically, there is a necrotizing inflammation with typical herpetic intranuclear inclusions within neurones and glial cells.

▶▶ Urgent antiviral treatment is essential.

### Cerebral abscess

- Foci of infection associated with the destruction of brain tissue.
- Usually bacterial infections, often with a mixture of organisms.
- Most arise by direct spread from an infection in a paranasal sinus, the middle ear, or a tooth.
- Can also arise from haematogenous spread, usually from septic emboli originating from infective endocarditis.
- Presents with symptoms of an infected intracranial mass, i.e. headache, nausea, vomiting, fever, seizures, and localizing neurological signs.
- CT scanning is usually diagnostic.
- Treatment requires surgical drainage and prolonged antibiotics.
- Considerable risk of mortality (20%) and morbidity (50% of survivors are left with persistent neurological deficits or epilepsy).

### Progressive multifocal leukoencephalopathy

- Caused by the JC virus of the polyoma group of papovaviruses.
- Seen virtually exclusively in the immunocompromised.
- Infection causes multiple foci of demyelination within white matter which may coalesce into larger cystic areas.
- Histologically, viral inclusions are found within the nuclei of astrocytes, macrophages, and oligodendrocytes within the demyelinated areas.
- Diagnosis relies on presenting neurological features, characteristic brain MRI findings, and the presence of JC virus DNA in the CSF.
- Mortality may be up to 50% within the first 3 months.

# Multiple sclerosis

## Definition

- A relapsing and remitting demyelinating disease of the CNS in which episodes of neurological disturbance affect different parts of the CNS at different times.

## Epidemiology

- Peak age of onset at 20–30y.
- Females slightly more commonly affected.
- Striking geographical variation with annual incidence rates up to 1 in 500 at highest latitudes and near absence near the equator.

## Aetiology

- Precise cause remains unknown.
- Hypothesized that immune-mediated demyelination is triggered by an infective organism acquired during childhood in genetically susceptible individuals.

## Pathogenesis

- Episodes of demyelination lead to attacks of acute neurological deficit which develop over a period of a few days and remain for a few weeks before there is recovery of symptoms.
- In the early stages of the disease, a complete recovery from an episode of demyelination is the rule.
- As the disease progresses, recovery is slower and residual deficit remains as axons begin to die. Eventually, extensive axonal death results in permanent neurological disability.

## Presentation

- Blurred vision/loss of colour vision due to optic nerve demyelination.
- Vertigo and incoordination due to cerebellar demyelination.
- Eye movement disorders due to brainstem demyelination.
- Patchy numbness and tingling in a limb with progression to paraplegia, incontinence, and sexual dysfunction due to spinal cord demyelination.

## Macroscopy

- Well-circumscribed grey plaques are present within the white matter of the CNS.
- Sites of predilection include the optic nerves, periventricular white matter, brainstem, and cervical spinal cord.

## Histopathology

- Active plaques contain a prominent inflammatory infiltrate with destruction of myelin sheaths.
- Established plaques show complete loss of myelin with a reduction in oligodendrocytes. Axons numbers are normal or slightly reduced.

## Prognosis

- Most patients suffer progressive disease and complications related to disability (pneumonia, urinary tract infections, pressure sores, etc.).

# Alzheimer's disease

## Definition

- A neurodegenerative disease characterized clinically by dementia and histopathologically by neuronal loss in the cerebral cortex in association with numerous amyloid plaques and neurofibrillary tangles.

## Epidemiology

- Most common cause of dementia.
- Increasing incidence with age (5% people aged >65, 20% of people aged >80).
- Represents an enormous social and financial burden to health care.

## Aetiology

- Unknown in the vast majority of cases.
- A very small proportion of cases are familial, linked to genetic mutations in amyloid precursor protein (APP) on chromosome 21.

## Pathogenesis

- Current evidence suggests Alzheimer's is a 'proteinopathy' related to abnormal accumulation of A $\beta$  amyloid and the protein *tau*.
- A $\beta$  peptides are derived from APP by the action of secretase enzymes.
- Precisely how the accumulation leads to neuronal loss is unclear.

## Presentation

- Typically begins with memory loss, particularly day-to-day memory and new learning. Over time, there is increasing disability in managing daily activities such as finances and shopping.
- Loss of motor skills then causes difficulty in dressing, cooking, and cleaning.
- Later in the disease, there is agitation, restlessness, wandering, and disinhibition. This may cause considerable upset to family and carers.
- Terminal stages cause reduced speech, immobility, and incontinence.

## Macroscopy

- Brain weight reduced, often to <1000g.
- Cortical atrophy, particularly in the temporal lobe and hippocampus.

## Histopathology

- The key microscopic features are the presence of abundant **neuritic plaques** and **neurofibrillary tangles** in the cerebral cortex, associated with loss of neurones and synapses.
- Neuritic plaques are spherical collections of tortuous neuritic processes surrounding a central amyloid core. The key component of the amyloid core is the A $\beta$  protein.
- Neurofibrillary tangles are neuronal cytoplasmic inclusions composed of paired helical filaments, the main constituent of which is *tau* protein.

## Prognosis

- Death occurs ~10y from diagnosis, often from terminal pneumonia.

## Dementia with Lewy bodies

### Definition

- A neurodegenerative disease characterized clinically by dementia and histopathologically by the presence of Lewy bodies in cortical and subcortical neurones.

### Epidemiology

- Second most common cause of dementia.
- ~5% of people aged >85 are affected.
- Slightly more common in men.

### Aetiology

- Unknown.

### Pathogenesis

- Presumably the accumulation of Lewy bodies within neurones leads to damage and cellular loss.

### Presentation

- Progressively worsening dementia very similar to Alzheimer's.
- Useful distinguishing features from Alzheimer's include fluctuating levels of cognition, recurrent visual hallucinations, and features of parkinsonism.

### Macroscopy

- Cerebral atrophy, particularly in the temporal and parietal lobes.
- Loss of pigment from the substantia nigra.

### Histopathology

- Intracytoplasmic inclusions known as Lewy bodies are present within neurones of cortical grey matter and subcortical nuclei.
- Lewy bodies are composed of  $\alpha$ -synuclein, ubiquitin, and parkin.
- Changes typical of Alzheimer's (amyloid plaques and neurofibrillary tangles) are also often present, though areas severely involved in Alzheimer's (e.g. the hippocampus) are usually spared.

### Prognosis

- Highly variable, but survival following diagnosis is usually 5–7y.

# Parkinson's disease

## Definition

- A neurodegenerative disorder characterized clinically by parkinsonism and histologically by neuronal loss and Lewy bodies concentrated in the substantia nigra.

## Epidemiology

- Occurs mostly in the elderly.
- Prevalence of 1% in people aged >60.

## Aetiology

- Unknown in the majority of cases.
- Rare cases are due to inherited mutations in PARK1 on chromosome 4 which encodes  $\alpha$ -synuclein, a component of Lewy bodies.

## Pathogenesis

- Neurones from the substantia nigra connect to the putamen and globus pallidus where they release dopamine and control movement.
- Lack of dopamine release results in movement disorder.

## Presentation

- Tremor, rigidity, and bradykinesia (parkinsonism).
- Note that parkinsonism is not specific to Parkinson's disease; it merely reflects a dysfunction of the substantia nigra system. Other causes of parkinsonism include drugs, toxins, infections, and trauma.

## Macroscopy

- Pallor of the substantia nigra and locus ceruleus.

## Histopathology

- Loss of pigmented neurones from the substantia nigra.
- Residual neurones contain intracytoplasmic inclusions known as Lewy bodies.

## Prognosis

- Treatment with dopaminergic drugs eases the symptoms of parkinsonism, but does not slow the progression of the disease.
- The speed of progression varies considerably between individuals.



# Huntington's disease

## Definition

- An inherited neurodegenerative disorder caused by a mutation of the HTT gene.

## Epidemiology

- Worldwide prevalence 5–10 per 100,000 population, but there is considerable geographical variability.
- Most cases present between 35–45y, but can occur at any age.
- Men and women are affected equally.
- Inherited in an autosomal dominant fashion.

## Genetics

- HTT contains a sequence of CAG trinucleotide repeats which usually number less than 36.
- Mutant HTT has more than 36 trinucleotide repeats. The higher the number of trinucleotide repeats, the fuller the penetrance and the younger the age of onset.
- Instability of the repeat sequences tends to result in their expansion in each successive generation, a phenomenon known as **anticipation**.

## Pathogenesis

- Huntingtin, the protein coded by HTT, interacts with many other proteins and has many biological functions. It is expressed in all cells, but is present in highest concentration in the brain and testis.
- Mutated huntingtin is thought to be cytotoxic to certain cell types, most notably neurones in the caudate nucleus and putamen.

## Presentation

- Uncontrolled random jerky movements (chorea).
- Over time, there is motor, neuropsychiatric, and cognitive decline, ultimately terminating in dementia.

## Macroscopy

- Striking atrophy of the caudate nucleus and putamen.
- Cortical atrophy may also be present.

## Histopathology

- Marked neuronal loss from the caudate nucleus.
- Surviving neurones contain abundant amounts of huntingtin protein.

## Prognosis

- Survival is on average 20y from the onset of symptoms, but this is dependent on the length of triplet repeats.
- Death is usually due to pneumonia or cardiac failure (abnormal huntingtin is expressed in cardiac muscle).

## Motor neurone disease

### Definition

- A group of neurodegenerative diseases characterized by the selective loss of motor neurones.

### Epidemiology

- Annual incidence of 1–5 people per 100,000.
- Men slightly more commonly involved than women.
- Most present between ages 50–70y old.

### Aetiology

- Most cases are idiopathic with no clear cause.
- ~10% are inherited in a familial fashion.
- A number of genes have been linked to familial motor neurone disease, including SOD1, TDP-43, and FUS.

### Pathogenesis

- Little is still known, though research into familial cases has provided interesting insights into the disease.
- TDP-43 and FUS are both RNA/DNA binding proteins with very similar molecular structures.
- Theories suggest that defects in RNA metabolism may be a key event leading to motor neurone degeneration.

### Presentation

- Asymmetric weakness, wasting, fasciculation, spasticity of limb muscles.
- Difficulty swallowing, chewing, speaking, coughing, and breathing.
- Cognitive changes may also occur.

### Macroscopy

- The anterior roots of the spinal cord are atrophic.

### Histopathology

- Selective loss of motor neurones is seen within the motor cortex and anterior horns of the spinal cord.
- In sporadic cases, residual motor neurones contain inclusions containing ubiquitin and TDP-43.

### Prognosis

- The disease is usually progressive and fatal within a few years.
- Death is usually from aspiration pneumonia.

## Creutzfeldt–Jacob disease

### Definition

- A spongiform encephalopathy caused by the accumulation of an abnormal form of prion protein (PrP) which is resistant to breakdown.

### Epidemiology

- Rare, but the most form of common human prion disease.
- Annual incidence of ~1 per 1,000,000.

### Aetiology

- Sporadic cases are thought to be due to chance spontaneous conversion of PrP into the abnormal form.
- Familial cases are due to inherited mutations in the PRP gene which predispose the protein to converting into the abnormal form.
- Variant Creutzfeldt–Jacob disease (CJD) is thought to be transmitted through the consumption of beef contaminated with abnormal PrP derived from cows with bovine spongiform encephalopathy (BSE).

### Pathogenesis

- Presence of abnormal PrP promotes the refolding of normal native PrP proteins into the abnormal form.
- An exponential increase in abnormal PrP results in cell death.

### Presentation

- Sporadic CJD typically presents in the middle-aged and elderly with an obvious neurological illness that follows a rapidly progressive course.
- Variant CJD is clinically distinct. It affects younger people aged <30 and initially presents with psychiatric symptoms followed by cerebellar ataxia and dementia.

### Histopathology

- Sporadic CJD is associated with vacuolation of grey matter (spongiform change) with neuronal loss and gliosis.
- Variant CJD also shows spongiform change, neuronal loss, and gliosis together with numerous so-called 'florid plaques' composed of deposits of amyloid forms of PrP.

► Florid plaques are the neuropathological hallmark of variant CJD and do not occur in other forms of CJD.

### Prognosis

- No specific treatment currently exists and the disease is usually fatal.

*This page intentionally left blank*

## Central nervous system neoplasms

### Astrocytic tumours

- Most common primary intracranial neoplasms in adults.
- Cause is unknown.
- Usually arise in the cerebral hemispheres and may present with headaches, seizures, or focal neurological signs.
- Histologically, there is a spectrum of differentiation with corresponding increasing WHO grades and worse outcome.
- Low-grade astrocytomas are characterized by mutations of P53 and overexpression of PDGFR-A.
- Evolution into a higher grade tumour is characterized by mutations in RB and P16.
- **Diffuse astrocytoma** (WHO grade II) shows only a slight increase in glial cellularity compared to normal brain and mild nuclear atypia. Average survival is ~5y.
- **Anaplastic astrocytoma** (WHO grade III) is more cellular with greater nuclear atypia and presence of mitotic figures. Average survival is ~3y.
- **Glioblastoma** (WHO grade IV) is a highly aggressive neoplasm composed of atypical astrocytes similar to those seen in anaplastic astrocytoma, but with superadded areas of necrosis and vascular proliferation. Average survival is <1y.

### Oligodendroglial tumours

- Usually arise in the cerebral hemispheres and present with neurological signs or seizures.
- Loss of heterozygosity at chromosomes 1p and 19q is common.
- Progression to anaplastic histology is associated with the loss of 9p and 10q and mutations in CDKN2A.
- **Oligodendroglioma** (WHO grade II) is a well-differentiated neoplasm, composed of cells resembling normal oligodendrocytes with round nuclei and fine chromatin surrounded by clear cytoplasm. Calcification is very commonly seen. Average survival is 10y.
- **Anaplastic oligodendroglioma** (WHO grade III) is an oligodendroglial neoplasm in which there are areas of higher cellularity, atypia, and increased mitotic activity. Average survival is 2–3y.

### Ependymal tumours

- Tumours arising from the ependymal-lined ventricular system.
- In adults, most arise in the spinal cord.
- In children, most arise around the fourth ventricle.
- Histologically, most are well-differentiated (WHO grade II) neoplasms, composed of cells with regular round nuclei in a fibrillary background. The cells may form glandular structures and perivascular rosettes in which the cells radially arrange around blood vessels.
- Children with posterior fossa tumours have a 5-year survival of ~50%.
- The outcome for adult patients with spinal tumours is better.

### Meningiomas

- Tumours composed of neoplastic meningotheial cells.
- Most are smooth well-circumscribed neoplasms adherent to the dura mater. Infiltration of the overlying skull can occur.
- Most are low-grade tumours (WHO grade I) with a low risk of recurrence following surgical excision.
- **Atypical meningiomas** (WHO grade II) grow more aggressively with a higher rate of local recurrence and so may require radiotherapy following surgical excision. Histologically, these are distinguished by increased mitotic activity and cytological atypia or necrosis.
- **Anaplastic meningiomas** (WHO grade III) are aggressive malignant tumours composed of markedly atypical meningotheial cells with very high mitotic activity.

### Medulloblastoma

- A primitive embryonal tumour occurring predominantly in children and arising exclusively within the cerebellum.
- Grows rapidly and presents with hydrocephalus.
- The tumour can disseminate through the CSF system with growth of secondary tumour masses elsewhere in the CNS.
- Histologically, the tumour is very cellular and composed of mitotically active small cells with hyperchromatic nuclei and scant cytoplasm.
- Like all embryonal tumours, the tumour grows very rapidly and is fatal without treatment. With treatment, 5-year survival is ~75%.

### Primary CNS lymphomas

- Lymphomas arising in the CNS in the absence of disease elsewhere.
- Strong association with immunosuppression.
- Most common type is **diffuse large B-cell lymphoma** (📖 p. 278) which, histologically, is composed of sheets of large atypical B-lymphoid cells.

### CNS metastases

- Typically occur at the junction between grey and white matter.
- Most common malignancies to show CNS metastasis are breast carcinoma, lung carcinoma, renal carcinoma, and malignant melanoma.

## Guillain–Barré syndrome

### Definition

- An acute demyelinating polyneuropathy which usually follows 1–2 weeks after an upper respiratory tract or gastrointestinal infection.

### Epidemiology

- Rare disease.
- Annual incidence 1–2 per 100,000.

### Aetiology

- Common triggers are *Campylobacter jejuni*, *Mycoplasma*, cytomegalovirus (CMV), HIV, VZV, and EBV.
- Other associations include vaccination, surgery, and malignancy.
- In many cases, no clear cause can be identified.

### Pathogenesis

- Theories suggest that the immune response mounted to an antigen on a pathogen cross-reacts with peripheral nerve myelin.
- Demyelination leads to an acute polyneuropathy.

### Presentation

- Sudden onset of tingling and numbness of fingers and toes.
  - Over a period of weeks, the weakness then spreads proximally.
- ▶ Progressive ventilatory failure is the main danger.

### Prognosis

- ~85% make a complete or near complete recovery.
- 10% are unable to walk unaided at 1y.

# Myasthenia gravis

## Definition

- An autoimmune disease caused by the production of autoantibodies directed against the nicotinic acetylcholine receptor (nAChR) at the neuromuscular junction.

## Epidemiology

- Uncommon disease with an annual incidence of 20 per 100,000.
- Mostly seen in women aged <50 and men aged >50y.

## Aetiology

- Precisely what leads to the production of the autoantibody is unclear.
- Interestingly, up to 75% of patients have an abnormality of the thymus, either a neoplasm (thymoma) or hyperplasia.
- The autoantibodies may be generated in the abnormal thymus.

## Pathogenesis

- The nAChR is the receptor at the motor end plate through which the neurotransmitter acetylcholine acts to stimulate muscular contraction.
- Autoantibodies binding to the nAChR limit depolarization at the end plate and thus impair muscular contraction.

## Presentation

- The key feature is muscular fatiguability.
- Muscle groups affected are, in order, extraocular, bulbar, face, neck, limb girdle, and trunk.
- Symptoms can be very subtle and the diagnosis is easily missed or mistaken for other conditions.

## Prognosis

- Most patients respond to medical treatment and have relapsing, but not progressive, symptoms.
- Patients with an aggressive form of thymoma may have a lower life expectancy.



*This page intentionally left blank*

# Multisystem diseases

Systemic lupus erythematosus 346

Systemic sclerosis 348

Sarcoidosis 349

Vasculitis 350

## Systemic lupus erythematosus

### Definition

- A multisystem autoimmune disease characterized by autoantibody production against a number of nuclear and cytoplasmic autoantigens.

### Epidemiology

- Incidence of 4 per 100,000 people per year.
- Most cases occur in women of childbearing age.
- More common in Africans and Asians.

### Aetiology

- Unknown for certain.
- One theory is that defective phagocytosis of apoptotic bodies leads to priming of the immune system to intracellular self-antigens.

### Pathogenesis

- Activation of autoreactive B- and T-cells leads to formation of immune complexes between autoantibodies and self-antigens.
- Circulating immune complexes become deposited in tissues such as the skin, joints, and kidneys where they stimulate inflammation and tissue damage (Fig. 18.1).

### Presentation

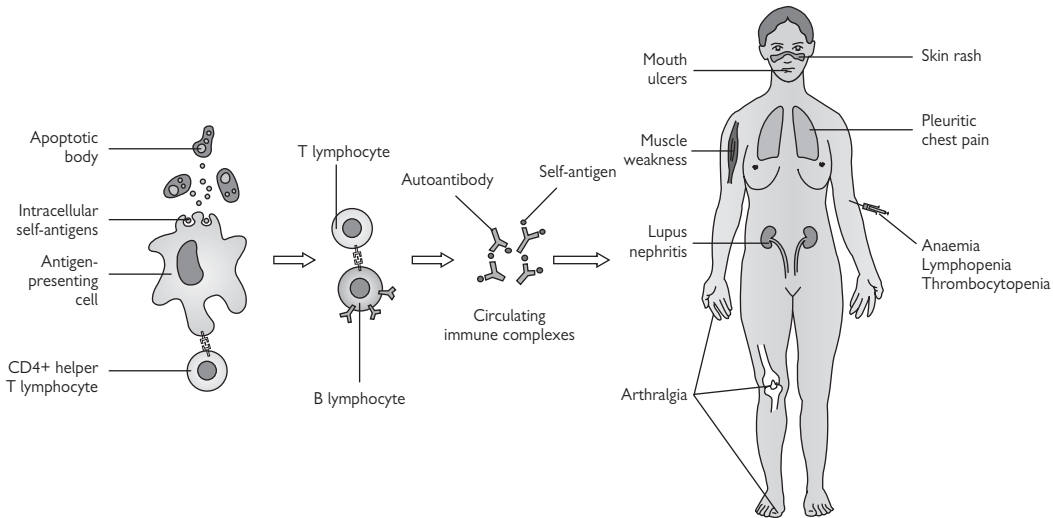
- Protean manifestations, depending on sites of involvement.
- Fatigue, weight loss, and low-grade fever are common.
- Joint involvement causes arthralgia.
- Skin involvement causes scaly red lesions on sun-exposed sites.
- Pulmonary involvement causes pleuritis and pleural effusion. Pneumonitis may also occur, leading to pulmonary fibrosis.
- Renal involvement causes a glomerulonephritis (lupus nephritis), leading to chronic kidney disease.
- Haematological involvement causes anaemia, lymphopenia, and thrombocytopenia.

### Immunology

- >95% have anti-nuclear antibodies.
- 60% have anti-double stranded DNA antibodies.
- 20–30% have anti-Smith antigen antibodies.
- 20–30% have anti-phospholipid antibodies which cause a hypercoagulable state.

### Prognosis

- 15-year survival from diagnosis is 80%.
- Deaths are usually related to severe renal and lung involvement.



**Fig. 18.1** Postulated pathogenesis of systemic lupus erythematosus. Defective phagocytosis of apoptotic bodies leads to the priming of the immune system to intracellular antigens and activation of autoreactive B- and T-lymphocytes. Circulating immune complexes formed between autoantibodies and self-antigens then become deposited in various tissues around the body (skin, joints, kidneys), stimulating inflammation and tissue damage. Reproduced with permission from *Clinical Pathology*, Carton, Daly, and Ramani, Oxford University Press, p. 478, Figure 21.1.

## Systemic sclerosis

### Definition

- A multisystem autoimmune disease in which fibrous tissue accumulates in multiple organs.

### Epidemiology

- Rare disease with annual incidence of 2–10 per million.
- Most cases arise in women aged 30–40y.

### Aetiology

- Unknown.

### Pathogenesis

- An abnormal immune response to an unidentified trigger results in production of cytokines such as IL-4 and TGF- $\beta$  that stimulate collagen deposition by fibroblasts.

### Presentation

- **Limited systemic sclerosis** (SS) usually starts with longstanding Raynaud's phenomenon. Then there is gradual tightening and thickening of the skin of the fingers, face, and neck. Calcium deposition is common, particularly in the finger pads. Small bowel involvement and pulmonary hypertension may occur as late complications after 10–15 years.
- **Diffuse systemic sclerosis** presents more abruptly with widespread skin thickening, contractures, and skin ulcers. Visceral involvement occurs early with pulmonary fibrosis. An important complication is severe hypertension, leading to acute renal failure ('scleroderma renal crisis').

### Immunology

- Anti-nuclear antibodies present in 65%.
- Anti-centromere antibodies present in 70–80% of limited SS.
- Anti-topoisomerase (Scl70) antibodies present in 40% of diffuse SS.

### Prognosis

- No cure at present.
- Immunosuppressive regimes are used for organ involvement or progressive skin disease.
- Deaths are usually related to renal and lung disease.

# Sarcoidosis

## Definition

- A multisystem disease of unknown cause in which tissues are infiltrated by granulomas.

## Epidemiology

- Prevalence of 10–20 per 100,000 population in the UK.
- Peak age of onset 20–40y.
- Those of African descent tend to show more severe disease.

## Aetiology

- Unknown.

## Pathogenesis

- Presumably the granulomatous inflammation is a reaction to an as yet unidentified antigen.

## Presentation

- Virtually any organ may be involved, but the commonest sites are lymph nodes, lungs, and skin.
- Acute sarcoidosis tends to present suddenly with manifestations such as erythema nodosum (📖 p. 294), anterior uveitis, and seventh cranial nerve palsy. Bilateral hilar lymphadenopathy is frequently present on chest radiography.
- Chronic sarcoidosis is more insidious and is characterized by lupus pernio (cutaneous sarcoidosis of the nose), pulmonary fibrosis, and posterior uveitis.

## Histopathology

- Involved tissues contain non-necrotizing granulomas.
- The typical sarcoidal granuloma is well circumscribed with little surrounding lymphoid inflammation (so-called 'naked' granulomas).
- Variable degrees of fibrosis may accompany the granulomas.
- No other explanation for the presence of granulomas can be found (e.g. pathogens, foreign material, tumour).

## Prognosis

- Acute sarcoidosis tends to behave favourably with spontaneous resolution within 1–2y of diagnosis.
- Chronic sarcoidosis is associated with a higher risk of complications such as progressive lung fibrosis, leading to respiratory failure and right ventricular failure (📖 p. 50).

## Vasculitis

### Definition

- A group of conditions in which inflammation and damage to blood vessels is the primary underlying pathology.

### Giant cell (cranial or temporal) arteritis

- A vasculitis of medium and large vessels which preferentially affects head and neck arteries. Most patients are adults aged >50y.
- Presents over weeks or months with fever, anorexia, weight loss.
- Involvement of the temporal artery causes headache, scalp tenderness, and jaw claudication.
- $\Delta$  Involvement of ocular vessels can cause blindness.
- Aortic involvement occurs in ~25% of cases and may lead to thoracic or abdominal aortic aneurysm formation.
- Positive temporal artery biopsies show a lymphohistiocytic infiltrate with disruption of the media. A giant cell reaction is often present.
- Only 60% of patients with clinical evidence of disease show biopsy evidence of arteritis as the pattern of involvement may be focal.

### Polyarteritis nodosa

- A systemic medium vessel vasculitis, leading to areas of aneurysm formation and narrowing in involved vessels.
- A rare disease if diagnostic criteria are strictly applied.
- Main organs involved are gastrointestinal tract (abdominal pain), nervous system (peripheral nerve palsies), and muscles (muscle aches).
- Imaging showing areas of vessel narrowing and aneurysm formation is high suggestive. Biopsy proof of a necrotizing vasculitis is also helpful.

### Wegener's granulomatosis

- A systemic small vessel vasculitis characterized by dominant upper respiratory tract, lung, and renal involvement and c-ANCA positivity.
- Presents with nasal symptoms  $\pm$  acute renal failure  $\pm$  pulmonary symptoms.
- Renal biopsies show a focal segmental necrotizing glomerulonephritis with crescent formation (identical to microscopic polyangiitis).
- Lung biopsies show large 'geographical' areas of necrotizing granulomatous inflammation and a necrotizing vasculitis.
- Aggressive immunosuppression is needed to prevent mortality.

### Microscopic polyangiitis

- A systemic small vessel vasculitis characterized by dominant renal and lung involvement and p-ANCA positivity.
- Most patients are adults with a median age of 55.
- Presents with acute renal failure  $\pm$  pulmonary symptoms.
- Renal biopsies show a focal segmental necrotizing glomerulonephritis with crescents (identical to Wegener's granulomatosis).
- Lung biopsies show marked alveolar haemorrhage and a necrotizing capillaritis within alveolar septa.
- Aggressive immunosuppression is needed to prevent mortality.

# Index

## A

- abdominal aortic aneurysm 35
- acanthomas 11
- acinar cell carcinoma 139
- acinic cell carcinoma 87
- acromegaly 253
- actinomycosis 86
- activated protein C resistance 268
- acute appendicitis 103
- acute B-lymphoblastic leukaemia 269
- acute drug-induced interstitial nephritis 152
- acute haemorrhagic gastritis 92
- acute lower limb ischaemia 33
- acute myeloid leukaemias 270
- acute phase proteins 6
- acute renal failure 144
- acute respiratory distress syndrome 64
- acute tubular injury 151
- adaptive immunity 8–9
  - antibody-mediated immunity 8
  - cell-mediated immunity 8
- Addison's disease 243
- adenocarcinoma 11
  - breast 226
  - cervical 192
  - colorectal 110
  - endometrial 196
  - gastric 94
  - lung 78
  - oesophageal 90
  - ovarian 206
  - pancreatic ductal 135
  - prostatic 176
  - sinusoidal 60
- adenoid cystic carcinoma 87
- adenomas 11
- adenomatoid malformation 58
- adenomatoid tumour, testicular 181
- adrenal cortical adenoma 244
- adrenal cortical carcinoma 246
- TNM staging 247
- adult polycystic kidney disease 165
- alcoholic liver disease 118
- allergic fungal sinusitis 59
- alternative pathway 6
- Alzheimer's disease 333
- amyloidosis 283
  - laryngeal 62
- anaemia
  - of chronic disease 257
  - iron deficiency anaemia 256
  - megaloblastic anaemias 258
  - pernicious anaemia 258
- anal cancer 113
- anal fissure 113
- anal tags 113
- anaphylaxis 10
- anaplastic thyroid carcinoma 238
- Ancylostoma duodenale* 101
- angina, unstable 43
- angina pectoris 42
- angiokeratomas, scrotal 184
- angioliomyoma 318
- angiomyofibroblastoma, vulval 187
- angiomyolipoma 166
- angiomyxoma, deep, vulval 187
- annular pancreas 132
- anorectal abscess 113
- anorectal fistula 113
- antibacterial agents 17
- antibody-mediated immunity 8
- antibody-mediated (type 2) hypersensitivity 10
- antifungal agents 17
- anti-glomerular basement membrane disease 153
- antimicrobial agents 17
- antiviral agents 17
- aortic aneurysm, abdominal 35
- aortic coarctation 41
- aortic dissection 34
- aortic regurgitation 51
- aortic stenosis 51
- aortic valve, bicuspid 41
- apoptosis 4
- asthma 69
- astrocytic tumours 340
  - anaplastic astrocytoma 340
  - diffuse astrocytoma 340
  - glioblastomas 340
- atherosclerosis 28–9
- atrial septal defect 40
- atrioventricular septal defect 40
- atrophy 3
- autoimmune gastritis 92
- autoimmune hepatitis 120

## B

- bacteria 16
- bacterial pneumonia 72
- bacterial vaginosis 190
- Bartholin duct cysts 187
- basal cell carcinoma 300
- basal-like carcinoma, breast 226
- benign fibroblastic polyps 109
- benign prostate hyperplasia 174
- bicuspid aortic valves 41
- bile duct adenoma 126
- biliary hamartoma 126
- blue naevus 298
- bone tumours 311–12
  - chondroma 311
  - chondrosarcoma 312
  - Ewing's sarcoma 312
  - giant cell tumour of bone 311
  - metastases 312
  - osteochondroma 311
  - osteoid osteoma 311
  - osteosarcoma 312
- Borrelia burgdorferi*, Lyme disease 25
- Breslow thickness 302
- bronchiectasis 65
- bullous pemphigoid 292

## C

- C-reactive protein 6
- Campylobacter* 100
- cancer 11
- candidiasis
  - oral cavity 86
  - oesophageal 88
  - vaginal 190
- carcinogenesis 12–13
- cardiomyopathies 52
  - arrhythmogenic right ventricular cardiomyopathy 52



- cardiomyopathies (*Cont.*)
    - hypertrophic
      - cardiomyopathy 52
    - idiopathic dilated
      - cardiomyopathy 52
  - caseous necrosis 4
  - cell-mediated immunity 8
  - cellular angiofibroma,
    - vulval 187
  - cellular death 4
  - cellulitis 296
  - central nervous system
    - neoplasms 340
      - astrocytic tumours 340
      - CNS metastases 341
      - ependymal tumours 340
      - medulloblastoma 341
      - meningiomas 341
      - oligodendroglial
        - tumours 340
      - primary CNS
        - lymphomas 341
  - cerebral contusions 324
  - cerebral infarction 325
  - cerebral infections 331
  - cerebral abscess 331
  - encephalitis 331
    - progressive multifocal
      - leukoencephalopathy 331
  - cervical carcinoma 192
    - FIGO staging 193
  - cervical glandular
    - intraepithelial neoplasia (CGIN) 192
  - cervical intraepithelial
    - neoplasia (CIN) 192
  - cervical screening 194
  - chemical/reactive
    - gastritis 92
  - childhood renal
    - tumours 170
      - clear cell sarcoma 170
    - congenital mesoblastic
      - nephroma 170
      - nephroblastoma (Wilms
        - tumour) 170
      - rhabdoid tumour 170
  - Chlamydia trachomatis* 208
  - cholecystitis 129
  - chondroma 311
  - chondrosarcoma 312
  - choriocarcinoma,
    - gestational 211
  - chromophobe renal cell
    - carcinoma 168
  - chronic kidney disease 142
    - complications 142
    - stages and prevalence 143
  - chronic lower limb
    - ischaemia 32
  - chronic lymphocytic
    - leukaemia 271
  - chronic myelogenous
    - leukaemia 272
  - chronic obstructive
    - pulmonary disease 71
  - chronic renal failure 143
  - chronic viral hepatitis 117
  - cirrhosis 119, 125
  - classical pathway 6
  - clear cell carcinoma
    - endometrial 196
    - ovarian 206
    - renal 168
  - clear cell sarcoma 170
  - Clostridium difficile* 100
  - coagulative necrosis 4
  - coarctation of aorta 41
  - coeliac disease 98
  - colitis
    - collagenous 106
    - lymphocytic 106
    - microscopic 106
    - ulcerative 105
  - colorectal carcinoma 110
    - NHS bowel cancer
      - screening
        - programme 111
      - TNM staging 111
  - colorectal polyps 108
    - adenomatous polyps 21.2
    - benign fibroblastic
      - polyps 109
    - hyperplastic polyps 108
    - inflammatory polyps 108
    - juvenile polyps 109
    - leiomyomas 109
    - mucosal prolapse 108
    - sessile serrated
      - adenomas 108
  - colposcopy 194
  - complement 6
  - condylomas 183
    - vulval 187
  - congenital adenomatoid
    - malformation 58
  - congenital diaphragmatic
    - hernia 58
  - congenital heart disease 40
  - congenital mesoblastic
    - nephroma 170
  - connective tissue
    - neoplasms 11
  - corpus luteum cysts 200
  - cranial arteritis 350
  - Creutzfeldt—Jacob
    - disease 338
  - Crohn's disease 104
  - cryptorchidism 159
  - crystal arthropathies 316
    - gout 316
    - pseudogout 316
  - Cushing's syndrome 253
  - cystadenoma, ovarian
    - mucinous 204
    - serous 204
  - cystic fibrosis 66
  - cystic nephroma 166
  - cystic renal diseases 165
  - cytomegalovirus 101
- ## D
- deep angiofibroma 187
  - deep vein thrombosis 37
  - dementia with Lewy
    - bodies 334
  - dermatitis
    - herpetiformis 293
  - dermatofibroma 294
  - dermatophytoses 297
  - dermoid cyst 204
  - developmental dysplasia of
    - hip 306
  - diabetes mellitus 232
  - diabetic nephropathy 146
  - diaphragmatic hernia 58
  - diffuse large B-cell
    - lymphoma 278
  - dilated cardiomyopathy 52
  - diverticular disease 112
  - duct ectasia 216
  - ductal carcinoma, invasive,
    - breast 226–7
  - ductal carcinoma *in situ*,
    - breast 225
  - duodenal atresia 84
  - duodenitis 97
  - dysplasia 3, 11
- ## E
- eclampsia 212–13
  - ectopic pancreas 132
  - ectopic pregnancy 209
  - eczemas 286
    - allergic contact
      - dermatitis 286
    - atopic dermatitis 286
    - irritant contact
      - dermatitis 286
    - nummular dermatitis 286
    - seborrhoeic
      - dermatitis 286
    - vulval 186
  - embryonal
    - rhabdomyosarcoma
      - paratesticular 181
      - vaginal 191
  - endocarditis, infective 53
  - endometrial carcinoma 196
    - FIGO staging 197
  - endometrial intraepithelial
    - neoplasia 196
  - endometrioid
    - adenocarcinoma 196
  - endometriosis 195
  - Entamoeba histolytica* 101

*Enterobius vermicularis* 101  
 ependymal tumours 340  
 epidermoid cysts,  
   scrotal 184  
 epidermoid cysts 298  
 epididymal cyst 181  
 epididymitis 181  
 epilepsy 323  
   childhood absence 323  
   juvenile myoclonic 323  
   temporal lobe 323  
 epithelial neoplasms 11  
 epithelial surfaces, innate  
   immunity 6  
 erythema migrans 25  
 erythema multiforme 289  
 erythema nodosum 294  
*Escherichia coli* 100  
 essential hypertension 31  
 essential  
   thrombocythaemia 274  
 Ewing's sarcoma 312  
 exomphalos 84  
 extradural haematoma 324  
 extrahepatic bile duct  
   carcinoma 130  
 extranodal marginal zone  
   lymphoma 279

## F

familial adenomatous  
   polyposis (FAP) 108  
 fat necrosis, breast 218  
 fibroadenoma 220  
 fibrocystic change,  
   breast 219  
 fibroepithelial polyps 298  
 fibroepithelial stromal  
   polyp 191  
 fibroma, oral 86  
 fibroma of tendon  
   sheath 318  
 fibromatoses 318  
 focal nodular hyperplasia 126  
 focal segmental  
   glomerulosclerosis 148  
 follicular adenoma 237  
 follicular carcinoma 238  
 follicular cysts 200  
 follicular lymphoma 277  
 folliculitis 296  
 Fournier's gangrene 184  
 fungal sinusitis 59  
 fungi 16

## G

gangrene 4, 184  
 gastric adenoma 93  
 gastric carcinoma 94  
   TNM 7 pathological  
   staging 95

gastric polyps 93  
 fundic gland 93  
 gastric adenoma 93  
 gastric xanthoma 93  
 hyperplastic polyp 93  
 inflammatory fibroid  
   polyp 93  
 gastritis 92  
   acute haemorrhagic 92  
   autoimmune 92  
   chemical-reactive 92  
*Helicobacter* 92  
   iron pill 92  
 gastrointestinal  
   malformations 84  
 gastrointestinal stromal  
   tumours 96  
 gastroschisis 84  
 genitourinary  
   malformations 158  
   cryptorchidism 159  
   hypospadias 159  
   pelviureteric junction  
     obstruction 158  
   posterior urethral  
     valves 159  
   renal agenesis 158  
   renal dysplasia 158  
   renal fusion 158  
   rotational anomalies 160  
   ureteral duplication 158  
   vesicoureteric reflux 158  
 gestational  
   choriocarcinoma 211  
 giant cell arteritis 350  
 giant cell myocarditis 54  
 giant cell tumour of tendon  
   sheath 318  
*Giardia lamblia* 101  
 Gleason score 177  
 glucose-6-phosphate  
   dehydrogenase (G6PD)  
   deficiency 260  
 goitre, nodular 236  
 gout 316  
 granular cell tumour,  
   vulval 187  
 granuloma annulare 290  
 granulomatous  
   inflammation 5  
 Graves' disease 235  
 Guillain—Barre  
   syndrome 342  
 gynaecomastia 229

## H

haemangioma 126  
   liver 126  
   lobular capillary 295  
 haemophilia 267  
 haemorrhoids 113  
 Hashimoto's thyroiditis 234

head injury 324  
   cerebral contusions 324  
   extradural haematoma 324  
   skull fracture 324  
   subdural haematoma 324  
   traumatic axonal injury 324  
 healing 5  
*Helicobacter* gastritis 92  
 helminths 16  
 hepatic adenoma 126  
 hepatitis  
   acute viral 116  
   autoimmune 120  
   chronic viral 117  
 hepatocellular  
   carcinoma 127  
 hereditary  
   haemochromatosis 124  
 hereditary  
   spherocytosis 259  
 herpes simplex 297  
 Hirschsprung's disease 85  
 HIV and AIDS 18–19  
 Hodgkin lymphoma 281  
 human immunodeficiency  
   virus (HIV) 18–19  
 human papillomavirus  
   (HPV) 62, 113, 188,  
   192, 297  
 humoral immunity 8  
 Huntington's disease 336  
 hydatidiform mole 210  
 hydrocele 181  
 hyperplasia 3  
 hypersensitivity  
   pneumonitis 76  
 hypersensitivity  
   reactions 10  
   anaphylaxis 10  
   antibody-mediated  
     (type 2) 10  
   immediate (type 1) 10  
   immune complex-  
     mediated (type 3) 10  
   T-cell-mediated  
     (type 4) 10  
 hypertension 31  
 hypertensive  
   nephropathy 145  
 hypertrophic  
   cardiomyopathy 52  
 hypertrophy 3  
 hypospadias 159

## I

idiopathic dilated  
   cardiomyopathy 52  
 idiopathic pulmonary  
   fibrosis 74–5  
 idiopathic  
   thrombocytopenic  
   purpura 264

- IgA nephropathy 150  
 immediate (type 1)  
   hypersensitivity 10  
 immune complex-mediated (type 3)  
   hypersensitivity 10  
 immunity  
   adaptive immunity 8–9  
   innate immunity 6  
 immunoglobulins 8  
 imperforate anus 85  
 impetigo 296  
 infantile polycystic kidney disease 165  
 infectious  
   mononucleosis 21  
 infective endocarditis 53  
 inflammation 5  
   acute inflammation 5  
   chronic inflammation 5  
   granulomatous inflammation 5  
 inflammatory fibroid polyp 93  
 innate immunity 6  
   acute phase proteins 6  
   complement 6  
   epithelial surfaces 6  
   phagocytes 6  
 intermittent claudication 32  
 intestinal infections 100  
 intestinal obstruction 102  
 intracerebral  
   haemorrhage 326  
 intraductal papilloma,  
   breast 222  
 intrahepatic  
   cholangiocarcinoma 128  
 iron deficiency anaemia 256  
 iron pill gastritis 92  
 ischaemia  
   acute lower limb 33  
   chronic lower limb 32  
   myocardial ischaemia 42
- J**  
 juvenile polyposis 109
- K**  
 kala-azar 26  
 Kaposi's sarcoma 18
- L**  
 large cell carcinoma,  
   lung 78  
 laryngomalacia 58  
 lectin pathway 6  
 left ventricular failure 49  
 leiomyoma 11  
 colorectal 109  
 oesophageal 89  
 renal 167  
 uterine 198  
 leiomyosarcoma 11  
   soft tissue 319  
   uterine 199  
 leishmaniasis 26  
 lentigo simplex 298  
 leukaemia  
   acute B-lymphoblastic leukaemia 269  
   acute myeloid leukaemia 270  
   chronic lymphocytic leukaemia 271  
   chronic myelogenous leukaemia 272  
 leukoencephalopathy,  
   progressive multifocal 331  
 lichen planus 86, 183, 186, 288  
 lichen sclerosus 183, 186  
 lichen simplex chronicus 186  
 lipoma 11, 299, 318  
 liposarcoma 11, 181, 319  
 myxoid 319  
 pleomorphic 319  
 well-differentiated 319  
 liquefactive necrosis 4  
 lobular capillary haemangioma 295  
 lung carcinoma 78  
   adenocarcinoma 78  
   large cell carcinoma 78  
   small cell carcinoma 78  
   squamous cell carcinoma 78  
   TNM 7 staging 79  
 Lyme disease 25  
 lymphocytes 8  
 lymphocytic colitis 106  
 lymphoma 11  
   diffuse large B-cell lymphoma 278  
   extranodal marginal zone lymphoma 279  
   follicular lymphoma 277  
   Hodgkin lymphoma 281  
   mantle cell lymphoma 280  
   nodular lymphocyte-predominant Hodgkin lymphoma 281  
   primary CNS lymphomas 341  
   testicular lymphomas 180
- M**  
 malaria 22  
 male breast disease 229  
 malignancy 11  
 malignant melanoma 11  
   cutaneous 302  
   sinonasal 60  
   urethral 182  
 malignant mesothelioma 82  
 mannose-binding lectin 6  
 mantle cell lymphoma 280  
 mastitis 216  
 Meckel's diverticulum 84  
 medullary cystic disease 165  
 medullary sponge kidney 165  
 medullary thyroid carcinoma 238  
 medulloblastoma 341  
 megaloblastic anaemias 258  
 melanocytic naevi 298  
 membrane attack complex 6  
 membranous  
   nephropathy 149  
 meningiomas 341  
   anaplastic 341  
   atypical 341  
 meningitis 330  
 metaplasia 3  
 metastasis 12  
 microbes 16  
 microscopic colitis 106  
 microscopic polyangitis 350  
 minimal change disease 147  
 mitral regurgitation 51  
 mitral stenosis 51  
 molluscum  
   contagiosum 297  
 motor neurone disease 337  
 mucinous carcinoma  
   breast 226  
   colorectal 110  
   ovarian 206  
 mucinous cystadenoma 204  
 mucocele 87  
 mucoepidermoid carcinoma 87  
 mucous membrane pemphigoid 86  
 multiple organ failure 30  
 myasthenia gravis 343  
 mycobacteria 11  
*Mycobacterium avium* 100  
*Mycobacterium fortuitum* 296  
*Mycobacterium kansasii* 296  
*Mycobacterium marinum* 296  
*Mycobacterium tuberculosis* 20  
 mycosis fungoides 304  
 myelodysplastic syndromes 276  
 myelofibrosis 275  
 myelogenous leukaemia 272  
 myocardial infarction  
   non-ST-elevation 44  
   ST-elevation 46–7

myocardial ischaemia 42  
myocarditis 54

## N

naevi  
  blue naevus 298  
  melanocytic naevi 298  
  Spitz naevus 299  
nasopharyngeal  
  angiofibroma 61  
nasopharyngeal  
  carcinoma 61  
*Necator americanus* 101  
necrosis 4  
  caseous 4  
  coagulative 4  
  liquefactive 4  
necrotizing fasciitis 296  
*Neisseria gonorrhoeae* 208  
neoplasia 11  
nephroblastoma  
  (Wilms' tumour) 170  
neuroblastoma 250  
neurofibroma 296  
NHS bowel cancer  
  screening 111  
NHS breast cancer  
  screening 228  
NHS cervical screening  
  programme 194  
nodular goitre 236  
nodular lymphocyte-  
  predominant Hodgkin  
  lymphoma 281  
non-alcoholic fatty liver  
  disease 119  
non-ST-elevation  
  myocardial infarction 44  
norovirus 100

## O

obstructive  
  nephropathy 155  
oesophageal atresia 84  
oesophageal carcinoma 90  
oesophagitis 88  
  Barrett's 88  
  drug-induced (pill) 88  
  eosinophilic 88  
  infectious 88  
  reflux 88  
olfactory neuroblastoma 60  
oligodendroglial  
  tumours 340  
  anaplastic oligodendro-  
  glioma 340  
  oligodendroglioma 340  
oncocyoma, renal 166  
oncoproteins 13  
osteoarthritis 313

osteoarticular  
  malformations 306  
osteochondroma 311  
osteomalacia 309  
osteomyelitis 310  
osteoporosis 307  
osteosarcoma 312  
ovarian cysts 200  
ovarian fibroma 204  
ovarian tumours  
  benign 204  
  borderline epithelial 205  
  carcinomas 206

## P

Paget's disease 308  
pancreas divisum 132  
pancreatic cystic  
  tumours 138  
  intraductal papillary  
  mucinous  
  neoplasm 138  
  mucinous cystic  
  neoplasms 138  
  serous cystic  
  neoplasms 138  
  solid pseudopapillary  
  neoplasm 138  
pancreatic ductal  
  carcinoma 135  
pancreatic endocrine  
  tumours 136  
pancreatic  
  malformations 132  
pancreatitis  
  acute 133  
  chronic 134  
papillary adenoma,  
  renal 166  
papillary hidradenomas 187  
papillary renal cell  
  carcinoma 168  
papillary thyroid  
  carcinoma 238  
papillomas 11  
  intraductal, breast 222  
  Schneiderian 59  
  squamous 62, 86  
parathyroid adenoma 241  
parathyroid carcinoma 242  
parathyroid hyperplasia 240  
Parkinson's disease 335  
patent ductus arteriosus 40  
pelvic inflammatory  
  disease 208  
pelviureteric junction  
  obstruction 158  
pemphigus vulgaris 86, 291  
peptic duodenitis 97  
pericardial effusion 55  
pericarditis 55  
pernicious anaemia 258  
Peyronie's disease 183  
phaeochromocytoma 248  
phagocytes 6  
phyllodes tumours 221  
pillar (tricholemmal)  
  cysts 298  
pilomatrixoma 298  
pituitary adenoma 252  
  acromegaly 253  
  Cushing's syndrome 253  
plasma cell myeloma 282  
*Plasmodia* protozoa 22  
pleomorphic adenoma 87  
pleural effusion 80  
*Pneumocystis pneumonia* 18  
  pneumonitis,  
  hypersensitivity 76  
pneumothorax 81  
polyarteritis nodosa 350  
polycystic kidney disease  
  adult 165  
  infantile 165  
polycystic ovarian  
  syndrome 202  
polycythaemia vera 273  
posterior urethral  
  valves 159  
pre-eclampsia 213  
primary amyloidosis 283  
primary myelofibrosis 275  
primary sclerosing  
  cholangitis 122  
progressive multifocal  
  leukoence-  
  phalopathy 331  
proliferative disease,  
  breast 224  
prostate carcinoma 176  
  Gleason score 177  
  TNM 7 staging 177  
prostatic urethral polyp 182  
protein C and S  
  deficiency 268  
*Proteus mirabilis* 160  
protozoa 16  
pseudogout 316  
psoriasis 287  
  vulval 186  
psoriatic arthropathy 315  
pulmonary fibrosis 75  
pulmonary hypertension 68  
pulmonary sequestration 58  
pulmonary  
  thromboembolism 67  
pyoderma  
  gangrenosum 295  
pyogenic granuloma 86

## R

radial scar, breast 223  
reflux nephropathy 154  
renal agenesis 158

- renal cell carcinoma 168  
 TNM 7 staging 169  
 renal dysplasia 158  
 renal fusion 158  
 renal tumours, benign 166  
 angiomyolipoma 166  
 cystic nephroma 166  
 leiomyoma 167  
 oncocytoma 166  
 papillary adenoma 166  
 renomedullary interstitial  
 cell tumour 167  
 respiratory failure 63  
 respiratory tract  
 malformations 58  
 congenital (cystic)  
 adenomatoid  
 malformation 58  
 congenital diaphragmatic  
 hernia 58  
 laryngomalacia 58  
 pulmonary  
 sequestration 58  
 rhabdoid tumour, childhood  
 renal 170  
 rhabdomyoma, genital 191  
 rhabdomyosarcoma 319  
 alveolar 319  
 embryonal 319  
 paratesticular 181  
 vaginal 191  
 pleomorphic 319  
 rheumatoid arthritis 314  
 right ventricular failure 50  
 rotavirus 100
- S**
- salivary gland diseases 87  
*Salmonella* 100  
 sarcoidosis 349  
 sarcomas 11  
 Schneiderian papillomas 59  
 scrotal diseases 184  
 angiokeratomas 184  
 epidermoid cysts 184  
 Fournier's gangrene 184  
 scrotal calcinosis 184  
 scrotal squamous cell  
 carcinoma 184  
 seborrhoeic keratoses 298  
 septic arthritis 317  
 serous carcinoma  
 endometrial 196  
 ovarian 206  
 serous cystadenoma 204  
 sex-cord stromal ovarian  
 tumour 204  
 sexually transmitted  
 diseases 208  
*Shigella* 100  
 shock 30  
 sickle cell disorders 262
- sinonasal diseases  
 allergic fungal sinusitis 59  
 polyps 59  
 Schneiderian  
 papillomas 59  
 sinonasal malignancies 60  
 adenocarcinoma 60  
 malignant melanoma 60  
 olfactory  
 neuroblastoma 60  
 squamous cell  
 carcinoma 60  
 undifferentiated  
 carcinoma 60  
 sinonasal polyps 59  
 sinusitis, allergic fungal 59  
 skin infections 296  
 acute folliculitis 296  
 cellulitis 296  
 cutaneous  
 tuberculosis 296  
 dermatophytoses 297  
 herpes simplex 297  
 impetigo 296  
 molluscum  
 contagiosum 297  
 necrotizing fasciitis 296  
 non-tuberculous  
 mycobacterial  
 infections 296  
 staphylococcal scalded  
 skin syndrome 296  
 tinea (pityriasis)  
 versicolor 297  
 varicella zoster 297  
 viral warts 297  
 skin tumours  
 basal cell carcinoma 300  
 common blue naevus 298  
 dermatofibroma 294  
 epidermoid cyst 298  
 fibroepithelial polyps 298  
 lentigo simplex 298  
 lipoma 299  
 lobular capillary  
 haemangioma 295  
 malignant melanoma 302  
 melanocytic naevi 298  
 mycosis fungoides 304  
 neurofibroma 296  
 pilar (tricholemmal)  
 cyst 298  
 pilomatrixoma 298  
 seborrhoeic keratosis 298  
 Spitz naevus 299  
 squamous cell  
 carcinoma 301  
 skull fracture 324  
 small bowel infarction 99  
 small cell carcinoma,  
 lung 78  
 soft tissue tumours 318  
 angioleiomyoma 318
- angioliopoma 318  
 fibroma of tendon  
 sheath 318  
 fibromatoses 318  
 giant cell tumour of  
 tendon sheath 318  
 leiomyosarcoma 319  
 lipoma 318  
 liposarcoma 319  
 pleomorphic  
 undifferentiated  
 sarcoma 319  
 rhabdomyosarcoma 319  
 solitary fibrous  
 tumour 318  
 spindle cell lipoma 318  
 synovial sarcoma 319  
 solitary fibrous tumour 318  
 spindle cell lipoma 318  
 Spitz naevus 299  
 spondyloarthropathies 315  
 ankylosing spondylitis 315  
 enteropathic  
 arthropathy 315  
 psoriatic arthropathy 315  
 reactive arthropathy 315  
 squamous cell  
 carcinoma 11  
 anal 113  
 cervical 192  
 laryngeal 62  
 lung 78  
 oesophageal 90  
 oral cavity 86  
 penile 183  
 scrotal 184  
 sinonasal 60  
 skin 301  
 vaginal 191  
 vulval 188  
 squamous papilloma 62, 86  
 ST-elevation myocardial  
 infarction 46  
 staphylococcal scalded skin  
 syndrome 296  
*Staphylococcus*  
*saprophyticus* 160  
 subarachnoid  
 haemorrhage 328  
 subdural haematoma 324  
 syphilis 24  
 systemic lupus  
 erythematosus 346  
 systemic sclerosis 348
- T**
- T-cell-mediated (type 4)  
 hypersensitivity 10  
 talipes equinovarus 306  
 temporal arteritis 350  
 testicular tumours 178,  
 180-1

- germ cell tumours 178
    - TNM staging 179
  - non-germ cell tumours 180
    - Leydig cell tumour 180
    - Sertoli cell tumour 180
    - testicular lymphomas 180
  - tetralogy of Fallot 40
  - thalassaemias 261
  - thrombophilia 268
    - activated protein C resistance 268
    - protein C and S deficiency 268
    - prothrombin G20210A mutation 268
  - thrombosis, deep vein 37
  - thrombotic thrombocytopenic purpura 265
  - thyroid carcinomas 238
    - TNM 7 staging 239
  - tinea (pityriasis) versicolor 297
  - transitional cell carcinoma 206
  - transposition of great arteries 40
  - Treponema pallidum* 24
  - tricholemmal cysts 298
  - trichomoniasis 190
  - tuberculosis 20, 296
  - tumour suppressor genes 12
- U**
- ulcerative colitis 105
  - unstable angina 43
  - ureteral duplication 158
  - urethral carcinomas 182
  - urethral caruncle 182
  - urethritis 182
  - urinary calculi 164
  - urinary tract infection 160
  - urinary tract obstruction 162–3
  - urothelial carcinomas 172
    - in situ* 173
    - infiltrating 173
    - TNM 7 staging of bladder carcinomas 173
    - TNM 7 staging of renal pelvis and ureter carcinomas 173
  - uterine leiomyomas 198
  - uterine leiomyosarcomas 199
- V**
- vaginal carcinoma 191
  - vaginal infections 190
  - vaginal intraepithelial neoplasia (VAIN) 191
  - vaginal tumours 191
  - valvular heart disease 51
    - aortic regurgitation 51
    - aortic stenosis 51
    - mitral regurgitation 51
    - mitral stenosis 51
  - varicella zoster 297
  - varicocele 181
  - varicose veins 36
  - vasculitis 350
    - giant cell (cranial/temporal) arteritis 350
    - microscopic polyangiitis 350
    - polyarteritis nodosa 350
    - Wegener's granulomatosis 350
  - ventricular septal defect 40
  - vesicoureteric reflux 158
  - viral warts 297
  - viruses 16
  - vocal cord nodules 62
  - vocal cord polyp 62
  - von Willebrand disease 266
  - vulval carcinoma 188
    - FIGO staging 189
  - vulval intraepithelial neoplasia (VIN) 188
  - vulval skin diseases 186
  - vulval tumours 187–8
  - vulvovaginal candidosis 190
- W**
- Warthin's tumour 87
  - Wegener's granulomatosis 350
  - Wilms' tumour 170
  - Wilson's disease 123
- Z**
- Zoon's balanitis 183