

# ELSEVIER MOSBY

The Curtis Center  
170 S Independence Mall W 300E  
Philadelphia, Pennsylvania 19106

Wounds and Lacerations: Emergency Care and Closure  
Copyright © 2005, Mosby, Inc. All rights reserved.

ISBN: 0-323-02307-X

No part of this publication may be reproduced or transmitted in any form or by any means, electronic or mechanical, including photocopying, recording, or any information storage and retrieval system, without permission in writing from the publisher. Permissions may be sought directly from Elsevier's Health Sciences Rights Department in Philadelphia, PA, USA: phone: (+1) 215 238 7869, fax: (+1) 215 238 2239, e-mail: [healthpermissions@elsevier.com](mailto:healthpermissions@elsevier.com). You may also complete your request on-line via the Elsevier homepage (<http://www.elsevier.com>), by selecting 'Customer Support' and then 'Obtaining Permissions'.

## NOTICE

Emergency medicine is an ever-changing field. Standard safety precautions must be followed, but as new research and clinical experience broaden our knowledge, changes in treatment and drug therapy may become necessary or appropriate. Readers are advised to check the most current product information provided by the manufacturer of each drug to be administered to verify the recommended dose, the method and duration of administration, and contraindications. It is the responsibility of the licensed health care provider, relying on experience and knowledge of the patient, to determine dosages and the best treatment for each individual patient. Neither the publisher nor the author assumes any liability for any injury and/or damage to persons or property arising from this publication.

The Publisher

Previous editions copyrighted 1997, 1991.

### Library of Congress Cataloging-in-Publication Data

Trott, Alexander.

Wounds and lacerations : emergency care and closure / Alexander T. Trott.—3rd ed.  
p. ; cm.

Includes bibliographical references and index.

ISBN 0-323-02307-X

1. Skin—Wounds and injuries—Treatment. 2. Soft tissue injuries—Treatment. 3. Surgical emergencies. I. Title.

[DNLM: 1. Wounds and Injuries—therapy. 2. Emergencies. 3. Suture Techniques. 4.

Wound Healing. WO 700 T858w 2005]

RD520.T76 2005

617.1'026—dc22

2004059713

Acquisitions Editor: *Todd Hummel*

Project Manager: *David Saltzberg*

Printed in the United States of America

Last digit is the print number: 9 8 7 6 5 4 3 2 1



---

# Contributors

*Javier A. Gonzalez del Rey, MD*

Professor of Clinical Pediatrics, University of Cincinnati College of Medicine;  
Professor of Clinical Pediatrics, Associate Director, Division of Emergency Medicine, Director, Residency Training Program, Cincinnati Children's Hospital Medical Center, Cincinnati, Ohio

*Gregg A. DiGiulio, MD*

Associate Professor of Clinical Pediatrics, University of Cincinnati School of Medicine; Medical Director, Division of Emergency Medicine, Cincinnati Children's Hospital Medical Center, Cincinnati, Ohio

To Buffy, Hays, Alexandra, and Jacqueline. They are the four corners of my life, with the beautiful and wise Jennifer firmly anchored in the center.



---

## Preface to the Third Edition

**T**he third edition of *Wounds and Lacerations: Emergency Care and Closure* actually represents the fifth version of this work. The first version was created in 1979 as a manual for medical students at the University of Cincinnati College of Medicine. It was so well received that formal publication was the next logical step—at least, so I thought. Nothing like it had been published before, and wound care, up to that point, had been taught by word of mouth, resident to student. To my surprise, because there was so little published on emergency medicine topics, the publishing industry did not snap it up. It was not until 1991, when Mosby published its first edition of this work, that wound care found its deserved place in formal medical literature.

To a certain extent, the science and practice of wound care mirrors medical progress in general. Before 1980, wound care taught at the bedside was considered “gospel.” Since that time revolutions have taken place in both the science of wound care and the manner in which information is passed on and taught. It is not good enough to rely on one’s clinical experience alone. Now this “experience” has to be supported by the available scientific evidence. Reliance solely on experience has been shown to lead to unsupported variations in care. Although not all of the studies are blinded or controlled, where available, the recommendations in this edition are accompanied by the available science and evidence. From wound cleansing to the choice of closure method, each step of caring for lacerations and wounds is supported by benchwork and clinical studies. Advances in wound care adhesives have been rapid and promising. Sale of wound adhesives over the counter is controversial but indicative of their usefulness and safety.

The addition of a chapter on chronic wounds recognizes this growing health problem and the fact that many of these wounds are cared for in emergency and clinic facilities. Wound care centers, which include hyperbaric oxygen facilities, can be included in emergency departments.

All of the chapters, clinical recommendations, and supportive material have been updated where necessary. Revisions of the pediatric and anesthesia chapters have been significant and important. Finally, the addition of color makes the illustrations even more effective and greatly enhances the text.

# Emergency Wound Care: An Overview

GOALS OF WOUND CLOSURE  
PATIENT EXPECTATIONS

RISKS OF WOUND CARE

Superficial wounds, including lacerations, bites, small burns, and punctures, are among the most common problems faced by emergency physicians and other providers of urgent and primary care. Each year in emergency departments, 12.2 million patients with wounds are managed.<sup>1</sup> This group represented 11% of the 108 million emergency department visits in the United States in 2000.<sup>1</sup> For the most part, these wounds can be managed without great difficulty or complications. The natural healing forces of the skin and body determine the ultimate outcome and scar appearance of the wound to a much greater degree than any intervention. There are wounds and lacerations, however, that require a keen understanding of wound anatomy and healing physiology and considerable technical expertise to achieve the best outcome. The experienced practitioner knows the difference and chooses management techniques best suited to enhance, not hinder, natural healing.

Of 1000 patients whose clinical findings were entered into a wound registry, 74% of the patients were male with an average age of 23.<sup>2</sup> The average laceration was 1 to 3 cm in length, and 13% were considered significantly contaminated. Most wounds (51%) occurred on the face and scalp followed by the upper (34%) and lower (13%) extremities. The remainder occurred on various sites of the truncal areas and proximal extremities.

The most common complication of wound care is infection. Approximately 3.5% to 6.3% of laceration wounds in adults treated in the emergency department become infected.<sup>3,4,5</sup> Infection is more likely to occur with bite wounds, in lower extremity locations, and when foreign material is retained in the wound. The rate of infection in children is only 1.2% for lacerations of all types.<sup>6</sup>

## GOALS OF WOUND CLOSURE

Because wounding is an uncontrolled event and there are biologic limitations to healing, the wounded skin and related structures cannot be perfectly restored. Despite the best of care, a few sutured wounds become infected. All wounds heal by scarring. The three major goals of wound care are to eliminate complications, restore function, and reduce scarring as much as possible. Each step of wound care serves to achieve these goals. Careful attention to each step leads to the best possible outcome.

- *Hemostasis*: All bleeding from the wound except minor oozing should be controlled, usually with gentle, continuous pressure, before wound closure.
- *Anesthesia*: Effective local anesthesia before wound cleansing allows the caregiver to clean the wound thoroughly without fear of causing unnecessary pain.

- *Wound irrigation:* Irrigation is the most important step in reducing bacterial contamination and the potential for wound infection.
- *Wound exploration:* Wounds caused by glass or at risk for deep structure damage should be explored. Radiographs and functional testing do not always identify foreign bodies or injured tendons.
- *Removal of devitalized and contaminated tissue:* Visibly devitalized and contaminated tissue that could not be removed through wound cleansing and irrigation needs to be completely but judiciously débrided.
- *Tissue preservation:* At the time of emergency department or primary closure, tissue excision should be resisted. It is best to tack down what remains of viable tissue, especially in complicated wounds. Because of the natural contraction of wounds, cosmetic revisions done later can be accomplished successfully if sufficient tissue remains. Unnecessary tissue excision can lead to a permanent, uncorrectable, and unsightly scar.
- *Closure tension:* When laceration edges are being brought together, they should just barely “touch.” Excessive wound constriction when knot tying strangulates the tissue, leading to a poor outcome. If necessary, tension-reducing techniques, such as the placement of deep sutures and undermining, can be applied.
- *Deep sutures:* Because all sutures act as foreign bodies, as few deep sutures as possible are to be placed in any wound.
- *Tissue handling:* Rough handling of tissues, particularly when using forceps, can cause tissue necrosis and increase the chance of wound infection and scarring.
- *Wound infection:* Antibiotics are no substitute for wound preparation and irrigation. If the decision is made to treat the patient with antibiotics, the initial dose is most effective when administered intravenously as soon as possible after wounding.
- *Dressings:* Wounds heal best in a moist environment provided by a properly applied wound dressing.
- *Follow-up:* Well-understood verbal and written wound care instructions and timely return for a short follow-up inspection or suture removal at the proper interval are essential to complete care.

---

## PATIENT EXPECTATIONS

One of the most important aspects of wound care is understanding and managing the patient’s reaction to a wound. Patients often have many preconceptions about wound care and expectations of the outcome, which are often unrealistic. Patient concerns include the pain during repair and afterward, scar formation, time in the emergency department, loss of function, infection, cost of care, and missed work. Patients sometimes believe that wounds can be repaired without scar formation. All wounds leave behind a scar, a fact that has to be conveyed to all patients. In an observational survey of 724 patients with lacerations, researchers were able to determine the relative importance of the concerns and potential outcomes listed previously.<sup>7</sup> For all lacerations, the most important aspects of care were avoiding infection, preserving normal function, cosmetic outcome, and pain of repair. In patients with facial lacerations, cosmetic outcome was the most important outcome, and for all other lacerations, preserving function ranked first.

---

## RISKS OF WOUND CARE

A fact of life of patient care in the United States is the risk of liability. Wounds cared for in emergency departments are often considered “minor.” Yet in a study of closed malpractice

claims against emergency physicians in Massachusetts, wounds were the most common source of those claims.<sup>8</sup> Of the 109 claims, 32% involved retained foreign bodies and another 34% were caused by allegedly undiagnosed injuries to tendon or nerve.

The most common retained foreign body is glass.<sup>9</sup> Patients who receive injuries from glass cannot report accurately whether the glass remains in the wound.<sup>10</sup> Radiographs are recommended for most of these wounds. Under study conditions, more than 95% of glass, of all types, as small as 0.5 mm, can be visualized by radiography.<sup>11</sup> In the clinical setting, however, fragments can be missed. In addition to radiographs, wound exploration is recommended in potentially glass-bearing wounds (see Chapter 16).

Tendon injuries of the hand are not always apparent. The patient can appear to have normal hand function but have a laceration of one or more tendons. The most commonly missed injury is to the extensor tendon.<sup>12</sup> Extensor tendons are cross-linked at the level of the metacarpals. An injury to a tendon proximal to the adjacent tendon cross-link can give the appearance of normal extensor function. Tendons also can be partially severed and retain function. A good understanding of the complex functional anatomy of the hand and thorough testing of each tendon reveal most complete injuries. Only exploration can define accurately the extent of partial injuries, however.

If a claim is made against an emergency physician, the care of the patient is most likely to be compared with what a specialist would have done in a similar circumstance. In other words, physicians who do not practice emergency medicine often define the "standard of care." An example of this dilemma is an infected wound. If an infection results from a sutured laceration, specialists often opine that prophylactic antibiotics should have been administered. Currently, there are no solid, evidenced-based data that antibiotics prevent traumatic skin wound infections. Because antibiotics are administered frequently without firm science, however, it is important for emergency physicians to follow local practice or relevant guidelines that address these circumstances. Ultimately a careful approach to each individual wound, based on sound principles and scientific data, reduces the risks of wound care and leads to the achievement of the desired goals stated earlier.

## REFERENCES

1. Advance data, Vital Health Statistics, #326, April 22, 2002.
2. Hollander JE, Singer AJ, Valentine S, Henry MC: Wound registry: development and validation, *Ann Emerg Med* 25:675-685, 1995.
3. Gosnold JK: Infection rate of sutured wounds, *Practitioner* 218:584-591, 1977.
4. Rutherford WH, Spence R: Infection in wounds sutured in the accident and emergency department, *Ann Emerg Med* 9:350-352, 1980.
5. Thirlby RC, Blair AJ, Thal ER: The value of prophylactic antibiotics for simple lacerations, *Surg Gynecol Obstet* 156:212-216, 1983.
6. Baker MD, Lanuti M: The management and outcome of lacerations in urban children, *Ann Emerg Med* 19:1001-1005, 1990.
7. Singer AJ, Mach C, Thode HC Jr, et al: Patient priorities with traumatic lacerations, *Am J Emerg Med* 18:683-686, 2000.
8. Karcz A, Korn R, Burke MC, et al: Malpractice claims against physicians in Massachusetts: 1975-1993, *Am J Emerg Med* 14:341-345, 1996.
9. Kaiser CW, Slowick T, Spurling KP, et al: Retained foreign bodies, *J Trauma* 43:107-111, 1997.
10. Montano JB, Steele MT, Watson WR: Foreign body retention in glass-caused wounds. *Ann Emerg Med* 21:1365-1368, 1992.
11. Tanberg D: Glass in the hand and foot, *JAMA* 248:1872-1874, 1982.
12. Guly HR: Missed tendon injuries, *Arch Emerg Med* 8:87-91, 1991.

# Patient Evaluation and Wound Assessment

## INITIAL STEPS

- Patient Comfort and Safety
- Initial Hemostasis
- Jewelry Removal
- Pain Relief
- Wound Care Delay
- Children with Lacerations
- Severe Soft Tissue Injuries

## WOUND EVALUATION AND DOCUMENTATION

- Basic History
- Screening Examination
- Wound Assessment
- Procedure Documentation
- Patient Disposition and Follow-Up

**B**efore wound or laceration repair is initiated, a thorough evaluation of the patient must be carried out. All wounds, no matter how trivial, can be the result of a serious underlying disorder or the manifestation of a life-threatening or limb-threatening injury. The combination of wound characteristics, anatomic sites, and underlying host conditions affects the management of every wound. Each patient is unique and requires individualized treatment. The basic history, general physical examination survey, and wound area examination help define the repair strategy and identify more serious injuries or problems that may necessitate more specialized or intensive care.

## INITIAL STEPS

### Patient Comfort and Safety

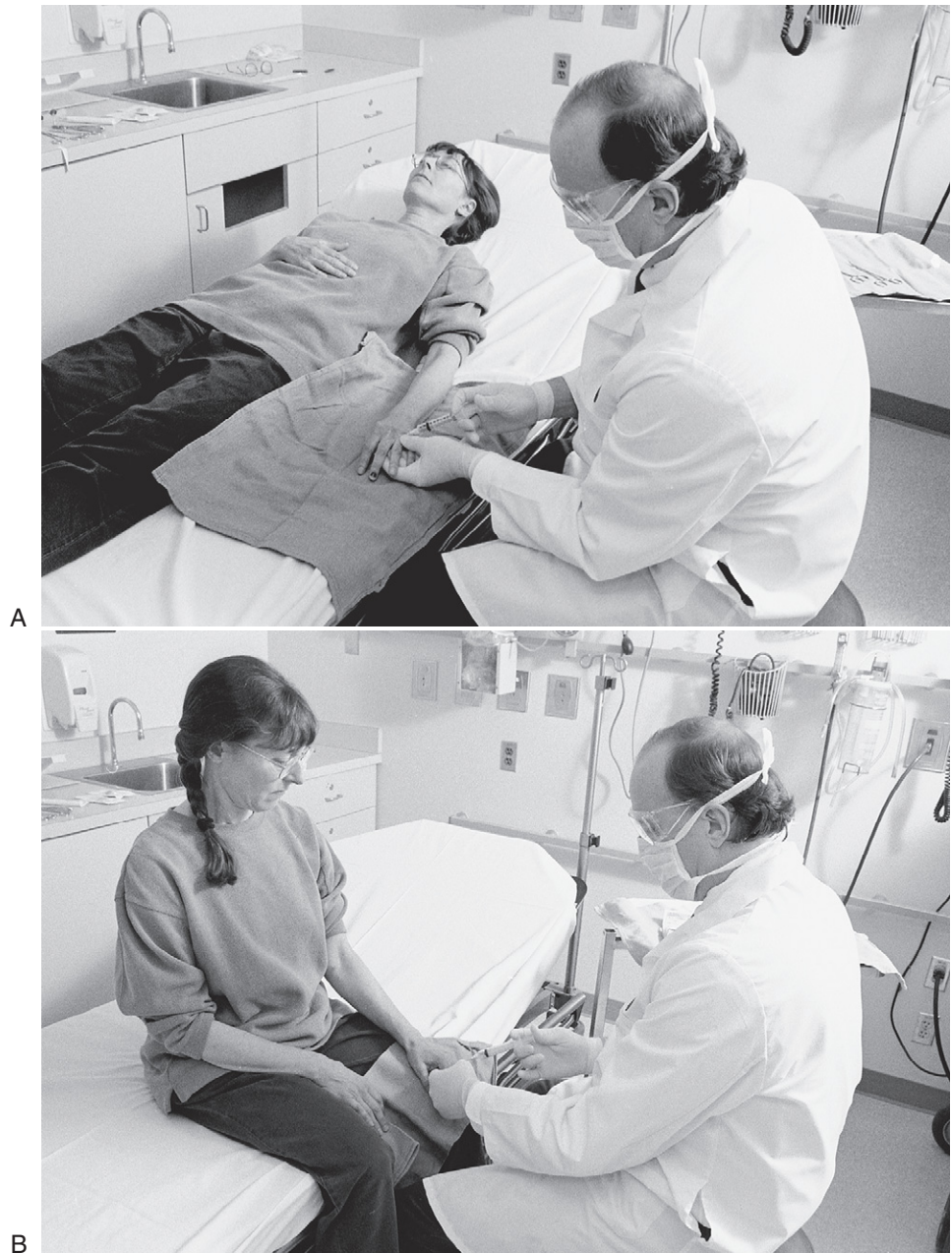If there is the slightest question about a patient's ability to cope with his or her injury, the patient is placed in a supine position on a stretcher. Loss of blood, deformity, and pain are sufficient to provoke vasovagal syncope (fainting), which can cause further injury from an unexpected fall during evaluation or treatment. Fig. 2-1 shows the recommended and not recommended patient positions for evaluation and treatment of emergency wound care problems. The attire of the caregiver, who is observing universal precautions, should be noted. Because wound care can be strenuous, the caregiver should be comfortable and relaxed before proceeding. Note the seated position in Figure 2-1A.

Relatives or friends accompanying the patient also can respond in a similar manner. As a rule, relatives and friends are encouraged to sit in the waiting area unless the physician or nurse determines that staying with the patient would be beneficial (e.g., to comfort an injured child). The parent or friend should be asked if he or she feels comfortable with that arrangement.

### Initial Hemostasis

Any bleeding can be stopped with simple pressure and compression dressings. There is no need for dramatic clamping of bleeders. Clamping is reserved for the actual exploration and





**Figure 2-1** **A**, Correct position for patient during assessment and treatment. The patient and caregiver are in comfortable positions. **B**, Incorrect patient position. Any pain or apprehension can cause the patient to undergo a vasovagal response. From the sitting position, the patient can be injured during a fall.

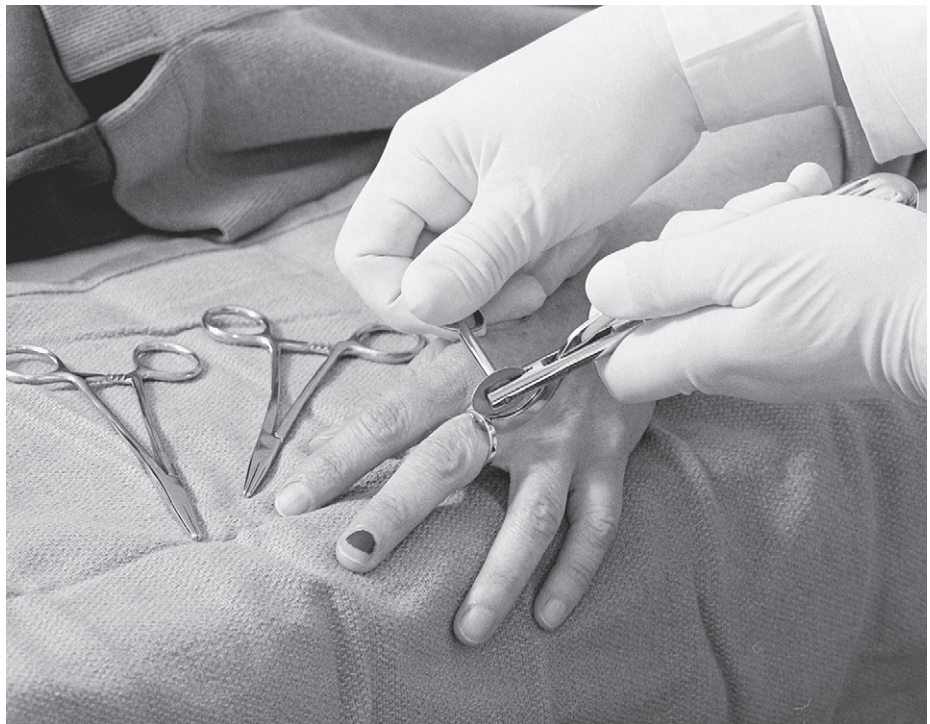repair of the wound under controlled, well-lighted conditions. Blind application of hemostats in an actively bleeding wound can lead to the crushing of normal nerves, tendons, or other important structures.

### Jewelry Removal

Rings and other jewelry must be removed from injured hands or fingers as quickly as possible. Swelling of the hand or finger can progress rapidly after wounding, causing rings to act as constricting bands. A finger can become ischemic, and the outcome can be disastrous. Most items of jewelry can be removed with soap or lubricating jelly. Occasionally, ring cutters have to be used (Fig. 2-2). The sentimental value of a wedding ring should never be allowed to impede good medical judgment. A jeweler always can restore a ring that has been cut or damaged during removal. Another technique for ring removal that does not require cutting is described in Chapter 13.

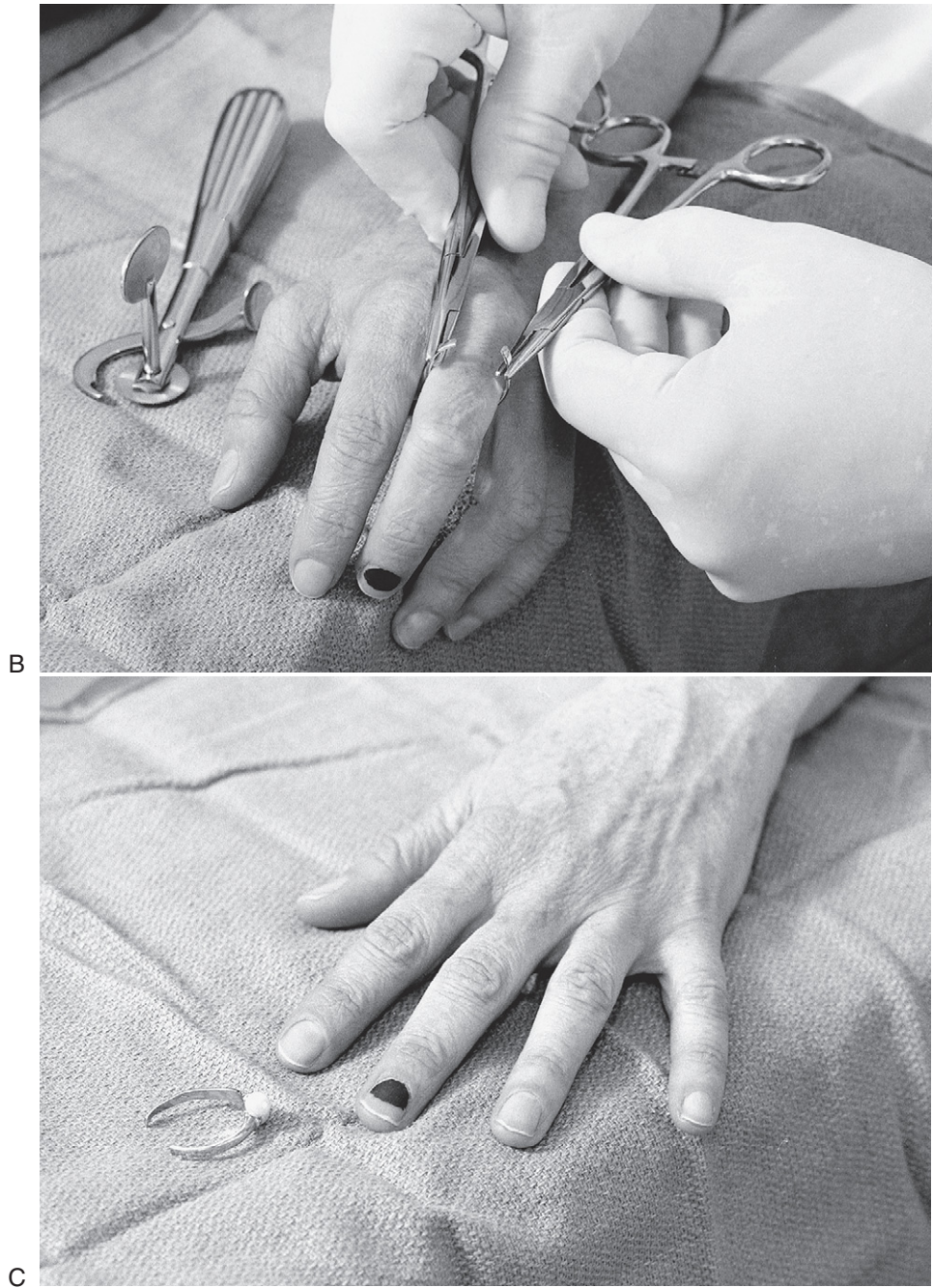### Pain Relief

Pain relief begins with gentle, empathic, and professional handling of the patient. Occasionally, it is necessary to give pain-reducing or sedative medications to patients being treated in the emergency wound care setting. Sedation and specific pain relief measures are discussed more completely in Chapter 6.



A

**Figure 2-2** A, Ring removal. Rings can be removed with a ring-cutting device. A through-and-through cut is made in the thinnest portion of the ring. *(Continued)*



C

**Figure 2-2** Cont'd. **B**, Large hemostats are clamped to each side of the cut portion. Taking care not to harm the finger, the ring is gently pried open. **C**, After removal, the ring can be repaired by a jeweler and restored to its original shape.

## Wound Care Delay

If there is going to be a delay from initial wound evaluation to repair, the wound is covered with a saline-moistened dressing to prevent drying. The dressing need not be soaked and dripping wet. Delays that extend beyond 1 hour require that the wound be thoroughly cleansed and irrigated before the saline dressing is applied.<sup>1</sup> If extended delays are inevitable, antibiotics occasionally are considered to suppress bacterial growth. If antibiotics are administered, they should be given early to provide the maximal protective benefit.<sup>2,3</sup> Chapter 9 discusses further recommendations for the early administration of antibiotics.

## Children with Lacerations

Particular care has to be taken with children who have wounds and lacerations. The pain and fear generated by the experience can be reduced significantly by a few simple measures. The child should be allowed to remain in the parent's lap for as long as possible before the wound repair. Most of the physical examination can be carried out at that time. If hemostasis is required and if the parent is willing to cooperate, he or she can be allowed to tamponade small, bleeding wounds. Parents also can apply topical anesthetics. Careful judgment has to be used when handling children and their parents. It is common for some parents to be unable to tolerate the sight of their child in pain, and they often do better in the waiting room while care is being delivered. It is remarkable how some children stop crying when the parent has left the treatment area. Pediatric considerations in wound care are discussed in detail in Chapter 5.

## Severe Soft Tissue Injuries

Providers of emergency wound care occasionally are confronted with patients who have severe, but not life-threatening, soft tissue injuries, usually of the distal upper or lower extremities. Power tools, industrial machines, farm implements, and mowers commonly cause these injuries. Patients often present with extensive skin lacerations, combined with varying degrees of nerve, tendon, or vascular involvement. On the patient's arrival at the emergency department, several steps, outlined here, are carried out to ensure the stability and comfort of the patient and to evaluate and protect the injured limb. These injuries may include an amputated part; guidelines for the management of that part are described in Chapter 13.

- **ABCs (airway, breathing, circulation):** Because of the severity of these injuries, the airway and vital signs are assessed to ensure the stability of the patient. A brief history and general system survey are carried out to rule out any secondary injuries or modifying conditions.
- **Hemorrhage:** Any bleeding, as described earlier, is controlled by direct pressure. Tourniquets are indicated only for severe bleeding that cannot be controlled by direct pressure, a rare occurrence. Should a tourniquet be necessary, proper technique must be observed. When feasible, a blood pressure cuff is used and inflated to a pressure of 250 mm Hg or greater. It is allowed to remain at that pressure for no longer than 20 to 30 minutes. If necessary, the cuff can be deflated for 5 minutes and reinflated for 20 more minutes. During that time, arrangements for urgent operative intervention are made.
- **Pain relief:** The most effective pain relief for severe hand or foot injuries is nerve blockade with local anesthetics. Nerve blocks are performed only after sensory and motor function is evaluated and documented (see Chapter 6 for nerve block techniques). Pain relief also can be accomplished with parenteral (intravenous or intramuscular) medications, meperidine (Demerol), 25 to 50 mg, or morphine, 2 to 5 mg. These medications can be supplemented with promethazine (Phenergan), 12 to 25 mg.

- *Antibiotic prophylaxis:* Because of the severe nature of these wounds, they are susceptible to infection. The most common organisms cultured from these wounds are *Staphylococcus aureus* and  $\beta$ -hemolytic streptococci.<sup>4</sup> Coliforms and anaerobes are cultured in smaller numbers. The most feared organisms are the soil-borne *Clostridium* species, but these rarely cause infection. Wounds caused by tools and industrial machines are predominantly contaminated with gram-positive organisms.<sup>5</sup> Farm implements and gardening tools that come in contact with soil have a higher proportion of coliforms. These differences have implications in the selection of antibiotics. For clean, non-soil-laden wounds, a first-generation cephalosporin provides adequate coverage. In patients with severe allergies to penicillin or cephalosporins, vancomycin can be given. In soil-laden wounds, the addition of an aminoglycoside provides good coverage. It cannot be overemphasized that antibiotics are no substitute for aggressive wound cleansing, irrigation, and débridement.
- *Wound evaluation:* A functional examination is carried out and documented. Loss of pulses or circulation is a serious finding and requires emergent intervention. Sensory and motor function is evaluated and documented. Tendon function is tested by individual or group action when possible. All severe soft tissue wounds are radiographed to assess bone integrity and the presence of foreign bodies.
- *Wound management:* For the most part, little can be done for these wounds in the emergency department. Loose, gross contaminants can be removed. After evaluation, the wound is covered with sterile gauze pads and a wrap is moistened with sterile saline. Appropriate splints are applied as indicated.
- *Consultation:* These wounds require definitive care by consultants with expertise in managing severe extremity and soft tissue injuries. Most commonly, plastic or hand specialists are consulted early after the arrival of the patient. The operating team is notified early as well to prepare for the definitive care of the patient in the operative room.

---

## WOUND EVALUATION AND DOCUMENTATION

### Basic History

The historical items collected and recorded in the wound care patient's medical record need not be lengthy and excruciatingly detailed. Key facts, such as mechanism, age of wound, allergies, and tetanus immunization status, are virtually always pertinent.

The patient's current and past medical history and present medications are frequently elements of the wound care assessment. Diseases such as diabetes and peripheral vascular disease can increase the risk of wound infection and cause delayed or poor wound healing.<sup>6,7</sup> Corticosteroids are known to affect the normal healing process adversely.<sup>8</sup> Finally, a careful detailing of allergies is necessary to prevent an untoward reaction to local anesthetics or antibiotics that might be administered to the patient. Table 2-1 presents the basic history and physical examination elements of a wound care charting document.<sup>9</sup>

### Screening Examination

The examination of every patient with a laceration or injury includes assessing the basic vital signs. Each vital sign can provide information pertinent to the management of the patient. Hypotension and tachycardia are the classic signs of hypovolemia. Innocuous-looking scalp wounds can bleed profusely, causing clinically significant blood loss with concomitant hypotension. Because alcohol is a cutaneous vasodilator, this complication is common in intoxicated patients.

Wounds and lacerations are often the result of or the cause of systemic problems and illnesses. Patients who fall and sustain minor injuries may need to be questioned and

TABLE 2-1 *Elements Recommended for Documentation of Wound Evaluation and Care\**

<b>Wound History</b>
Mechanism of injury—what happened, possible foreign body
Age of wound—when did it happen
Associated symptoms—systemic, numbness, loss of function
<b>Past/Social History</b>
Underlying disorders—diabetes, seizures
Allergies—drugs, anesthetics
Date of last tetanus
Medications—anticoagulants, corticosteroids
Vocation/avocation
Handedness
<b>Physical Examination</b>
Vital signs
General/system findings as appropriate
Wound description
Location
Length/extent
Depth
Condition—clean, contaminated, sharp, irregular
Functional examination—as appropriate
<b>Procedure</b>
Anesthesia—type, amount
Wound cleansing—agent, irrigation
Exploration/débridement
Suture type, size, number
Dressing type
<b>Disposition</b>
Wound care instructions (see Chapter 22)
Interval for suture removal

\*Elements vary by patient and circumstances.

examined for causes of syncope. When caused by blunt trauma, a scalp laceration has the possibility of being associated with a serious intracranial injury. In addition to the wound assessment, a trauma-oriented neurologic examination is often necessary.

A rapid general survey of the patient can reveal other injuries not reported. Because of the nature of a traumatic occurrence, patients often cannot report accurately all that has happened to them. A man who falls on an outstretched hand may be aware only of a bleeding hand laceration on arrival at the emergency department. An underlying radial head fracture might be revealed only when the caregiver examines the elbow and provokes pain.

## Wound Assessment

When the wound is examined, several features and findings must be noted and recorded in the medical record (see Table 2-1). Each wound characteristic and examination finding

becomes a significant variable that influences repair decisions and all aspects of care, including wound preparation, anesthesia, closure strategy, and dressing choice.

### **Procedure Documentation**

After performing the wound care intervention, whether suturing, foreign body removal, or burn care, a succinct but detailed procedure note is entered into the record. The elements of the procedure note for suturing are outlined in Table 2-1.

### **Patient Disposition and Follow-Up**

When care is completed, instructions for wound care, return for suture removal, and follow-up care are provided to the patient and documented. Details of follow-up care are discussed in Chapter 22.

## **REFERENCES**

1. Robson MC, Duke WF, Krizek TJ: Rapid bacterial screening in the treatment of civilian wounds, *J Surg Res* 14:426-430, 1973.
2. Burke JF: The effective period of preventive antibiotic action in experimental incisions and dermal lesions, *Surgery* 50:161-168, 1961.
3. Morgan WJ, Hutchinson D, Johnson HM: The delayed treatment of wounds of the hand and forearm under antibiotic cover, *Br J Surg* 67:140-141, 1980.
4. Charalambous CP, Zipitis CS, Kumar R, et al: Soft tissue infections of the extremities in an orthopaedic center, *J Infect* 46:106-110, 2003.
5. Hoffman RD, Adams BD: Antimicrobial management of mutilating hand injuries, *Hand Clin* 19:33-39, 2003.
6. Altemeier W: Principles in the management of traumatic wounds and in infection control, *Bull NY Acad Med* 55:123-138, 1979.
7. Hunt T: Disorders of wound healing, *World J Surg* 4:271-277, 1980.
8. Pollack S: Systemic medications and wound healing, *Int J Dermatol* 21:489-496, 1982.
9. American College of Emergency Physicians: Clinical policy for the initial approach to patients presenting with penetrating extremity trauma, *Ann Emerg Med* 23:1147-1156, 1994.

# Anatomy of Wound Repair

## ANATOMY OF THE SKIN AND FASCIA

Epidermis and Dermis  
(Skin or Cutaneous Layer)  
Superficial Fascia (Subcutaneous Layer)  
Deep Fascia

## SKIN TENSION LINES

## ALTERATIONS OF SKIN ANATOMY

The primary anatomic focus in surface wound care is the skin. Underlying the skin are two equally important structures, the superficial (subcutaneous) fascia and the deep fascia. The skin is a complex organ that provides basic protection against mechanical trauma, heat injury, and bacterial invasion. The skin regulates heat loss and gain through its rich vascular network and sweat glands. It contains the sensory organs that register stimuli from the environment. The fasciae not only act as a supportive base to the skin, but also carry nerves and vessels that eventually branch into it.

All the layers of the skin and fascia are present in every body site, but they vary considerably in thickness. Most skin is 1 to 2 mm thick, but thickness can increase to 4 mm over the back. This variability often dictates the choice of suture needles. Larger, stronger needles are required to penetrate the skin on the palms of the hand and soles of the feet. Small, delicate needles should be used on the thin skin of the eyelids. Knowledge of these and other properties of the skin, which are discussed in the following section, helps in the choice of the correct wound care materials and appropriate closure techniques.

## ANATOMY OF THE SKIN AND FASCIA

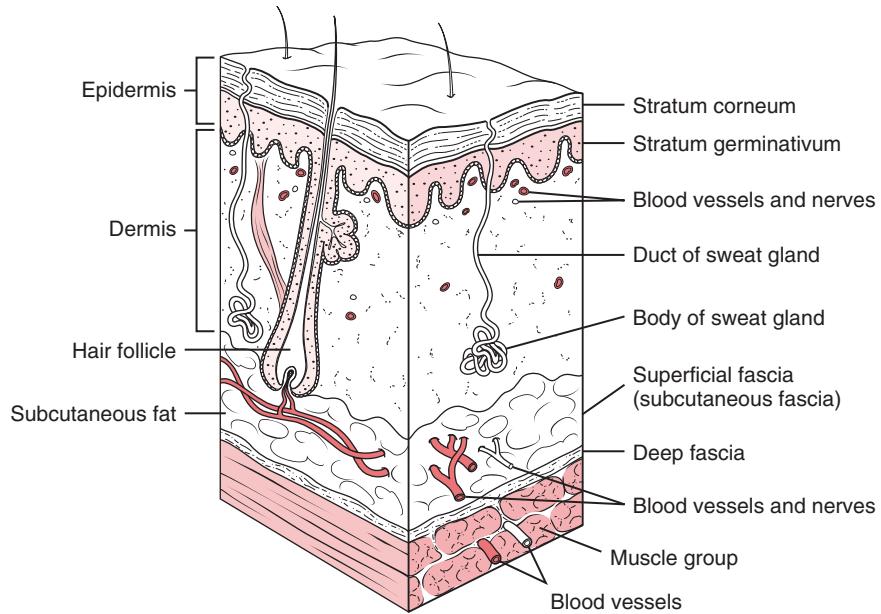
Although the skin and fascia comprise a complex system of organs and anatomic features, it is the layer arrangement that is most important for wound closure (Fig. 3-1). These layers include the epidermis, dermis, superficial fascia (commonly referred to as the subcutaneous or subcuticular layer), and deep fascia. These layers should be thought of as planes that need to be carefully and accurately reapproximated when disrupted by trauma. Each one has its own set of characteristics that are important to proper wound closure and healing.

### Epidermis and Dermis (Skin or Cutaneous Layer)

The epidermis is the outermost layer of the skin. It is also called the *cutaneous layer*. The epidermis consists entirely of squamous epithelial cells and contains no organs, nerve endings, or vessels. Its primary function is to provide protection against the ingress of bacteria and toxic chemicals and the inappropriate egress of water and electrolytes.

There are four microscopic layers of the epidermis, of which two are important in surface wound care. The stratum germinativum, or basal layer, is the parent layer for new cells.





**Figure 3-1** Anatomy of the skin illustrating structures pertinent to wound repair.

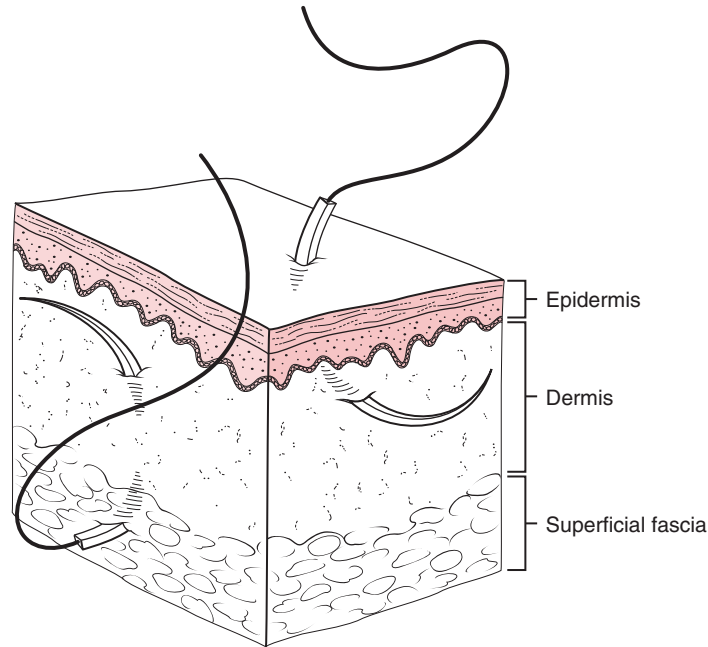
This layer provides the cells for new epidermis formation during wound healing after injury. The stratum corneum is the keratinized or horny layer that is derived from migrating and maturing basal cells. This is the outermost, visible layer and gives skin its final cosmetic appearance.

Although the epidermis is an anatomically separate layer, it is only a few cell layers thick. During wound repair, it cannot be seen by the naked eye as separate from the dermis. Correct approximation of the epidermis naturally results from careful apposition of the lacerated edges of the dermis.

The dermis lies immediately beneath the epidermis. It is much thicker than the epidermis and is composed primarily of connective tissue. The main cell type in the dermis is the fibroblast, which elaborates collagen, the basic structural component of skin. Other cells found in the dermis are macrophages, mast cells, and lymphocytes. Along with fibroblasts, these components are active during wound healing.

The dermis is composed of two layers, the papillary dermis and the reticular dermis. The richly vascular papillary dermis interdigitates with the epidermis and provides nutrients to that layer. The deeper reticular dermis contains the bulk of adnexal structures of the skin. These include the hair follicles and vascular plexus. Nerve fibers branch and differentiate into specialized nerve endings that invest both layers of the dermis.

The dermis is the key layer for achieving proper wound repair. It is easily identifiable and provides the anchoring site for percutaneous and deep sutures (Fig. 3-2). Every effort is made to cleanse, remove debris, and accurately approximate the dermal edges to allow for optimal wound healing with minimal scar formation. If dermis is devitalized or severely damaged, sharp débridement often is necessary to remove it. Tissue excision and trimming must include only that which is truly unsalvageable, however. Because dermal defects are replaced by scar tissue, any unnecessary dermis removal increases the size and prominence of that scar.



**Figure 3-2** Demonstration of either percutaneous or deep suture closure. The needle is anchored in the dermis for each suture placement.

### Superficial Fascia (Subcutaneous Layer)

Deep to the dermis is a layer of loose connective tissue that encloses a varying amount of fat. Fat makes the superficial fascia easily recognizable in a laceration. Superficial fascia provides insulation against heat loss and some measure of protection against trauma.

There are several consequences of injury to this layer. Devitalized fat can promote bacterial growth and infection.<sup>1</sup> In contrast to dermis, the superficial fascia can be liberally débrided so that any devitalized portion can be excised completely. Injuries to the superficial fascia also have the potential for creating “dead” space. Failure to evacuate contaminants and clots in this space can lead to an increased risk of infection.

The sensory nerve branches to the skin travel in the superficial fascia just deep to the dermis. When injecting a local anesthetic, the needle is directed along the plane between the dermis and superficial fascia (see Fig. 6-1). Anesthetic spreads easily along the “floor” of the dermal layer and quickly abolishes sensation from the skin.

### Deep Fascia

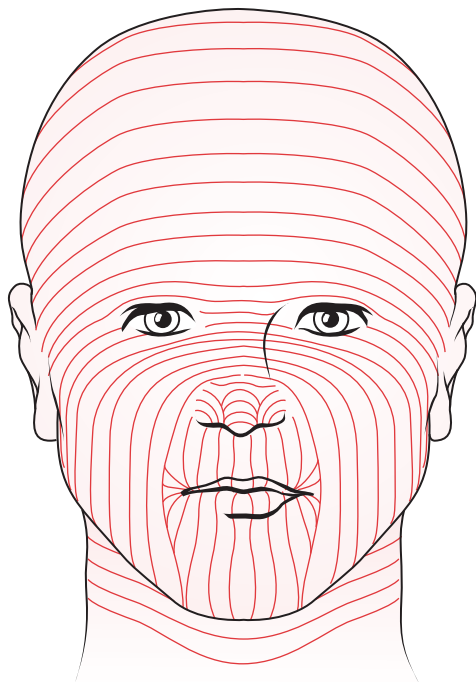
Deep fascia is a relatively thick, dense, and discrete fibrous tissue layer. It acts as a base for the superficial fascia and as an enclosure for muscle groups. This layer is recognized as an off-white sheath for the underlying muscles. The main function of the deep fascia is to support and protect muscles and other soft tissue structures. It also provides a barrier against the spread of infection from the skin and superficial fascia into muscle compartments. Lacerations of the deep fascia are easily recognized and require closure to reestablish the protective and supportive functions of this layer.

## SKIN TENSION LINES

There are two types of skin tension—static and dynamic—that have an important impact on the final scar structure of healed lacerations. Because *all* wounds scar, knowledge of skin tension is required when considering repair strategy or educating the patient about eventual healing outcome.

Because it clings tautly to the body framework, skin is under constant static tension.<sup>2</sup> Static tension lines are commonly called *Langer's lines*. The arrangement, orientation, and distensibility of collagen fibers cause most wounds to retract open. The degree to which wound edge retraction, or "gaping," takes place is an indicator of how wide the resulting scar might be. Gaping of 5 mm or greater indicates significant tension and increased risk for wide scar formation.<sup>3</sup> In a study of poor outcomes of laceration repair, wound width was found to be a significant factor.<sup>4</sup> Lacerations of the lower extremity, particularly over the anterior tibia, tend to retract under great tension and scar conspicuously. A horizontal laceration of the skin of the eyelid is under little tension with little gaping. These lacerations become virtually unnoticeable with time.

Static skin tension plays an important role in wound edge débridement and revision. It is tempting to excise jagged wound edges to convert an irregular laceration into a straight one. If the wound is already gaping because of static tension, débridement of tissue might increase the force necessary to pull the new straight edges together. Scar width is increased, and the purpose of the edge excision is defeated. An irregular laceration under little tension often heals with a less noticeable scar than a straight wound under greater tension. As a rule, a ragged wound with viable tissue edges is repaired best by putting the "puzzle pieces" back

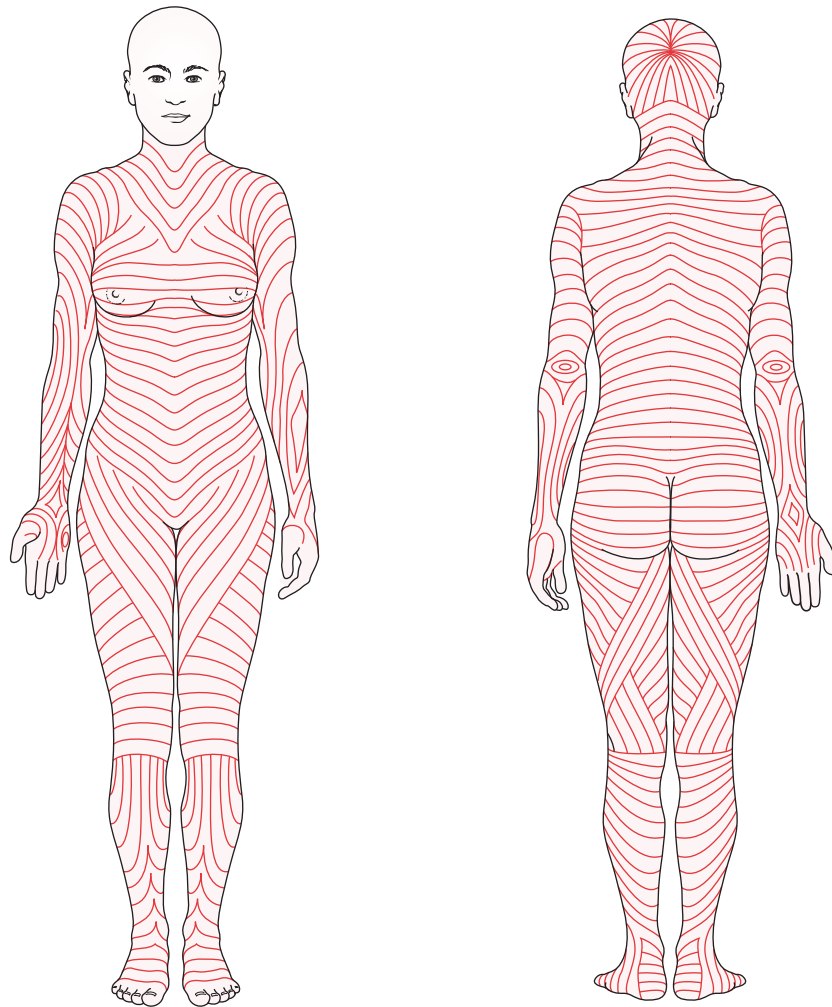


**Figure 3-3** Skin tension lines of the face. Incisions or lacerations parallel to these lines are less likely to create widened scars than incisions that are perpendicular to these lines. (Adapted from Simon R, Brenner B: *Procedures and techniques in emergency medicine*, Baltimore, 1982, Williams & Wilkins.)

together to preserve as much tissue as possible. If the wound needs later revision, the “extra” tissue will be welcomed by the plastic surgeon.

Different from static forces but equally important are dynamic forces on the skin, illustrated by Kraissl’s lines in Figures 3-3 and 3-4.<sup>5</sup> These forces are created by the underlying pull of muscles in any given body area and correspond to wrinkles created by compression of the skin during muscle contraction.<sup>6</sup> These forces are most dramatically visible in the face during the various changes in facial expression. Lacerations that are perpendicular to these lines tend to heal with wider scars than do lacerations that are parallel. In choosing elective incisions of the face, surgeons apply the scalpel to correspond with these lines.

Ultimately the final appearance of a scar is determined in part by static and dynamic forces, and the patient should be counseled accordingly. The patient is advised that it takes



**Figure 3-4** Skin tension lines of the body surface. (Adapted from Simon R, Brenner B: Procedures and techniques in emergency medicine, Baltimore, 1982, Williams & Wilkins.)

at least 6 months for scar contraction and collagen remodeling to diminish and 1 year for these forces to stabilize before a wound takes on its final shape.<sup>7</sup> During this time, the wound undergoes many visible changes. If the scar is still worrisome to the patient after this time elapses, tension-relieving procedures, such as W-plasty or Z-plasty, can be applied to improve the appearance of the scar. Whenever the cosmetic outcome is in doubt at the time of injury or the issue is raised by the patient, consultation with a plastic surgeon can be considered.

---

## ALTERATIONS OF SKIN ANATOMY

Often, there are clinical situations in which the anatomic structure of the skin is altered so much that it requires special wound care. The most common skin changes in this setting are changes caused by aging and long-term corticosteroid administration.<sup>8,9</sup>

In aging, there is a flattening of the dermoepidermal junction with an accompanying decrease in the prominence of the dermal papillae. This effacement seems to result in a reduction of vascularity and nutrient supply to the epidermis. The dermis itself loses its thickness and becomes increasingly acellular and avascular. The net result is that the tensile strength of the dermis decreases significantly, which makes it less resistant to injury. More important to wound care is that the dermis does not support sutures well: They tend to “tear” the skin or cause ischemia because the dermis has a low resistance to suture tension. Although sutures can be effective in younger patients, wound tapes are more appropriate in many lacerations that occur in older people.

Corticosteroids have a profound effect on collagen deposition through inhibition of collagen fiber synthesis and accelerated collagen degradation. The dermis becomes atrophic, thin, and poorly resistant to trauma. Small vessels seem to become increasingly fragile and readily cause ecchymoses in response to even the most trivial trauma. As in aging, the poor quality of the skin makes it less able to support sutures. Skin tapes or simple bandages are often preferable for managing these wounds.

## REFERENCES

1. Haury B, Rodeheaver G, Vensko J, et al: Debridement: an essential component of traumatic wound care, *Am J Surg* 135:238-242, 1978.
2. Thacker IG, Iachetta FA, Allaire PE, et al: Biomechanical properties: their influence on planning surgical excisions. In Krizek TI, Hoopes PE, editors: *Symposium on basic science in plastic surgery*, St. Louis, 1975, Mosby.
3. Edlich RF, Rodeheaver GT, Morgan RF, et al: Principles of emergency wound management, *Ann Emerg Med* 17:1284-1302, 1988.
4. Singer AJ, Quinn JV, Thode HC Jr: Determinants of poor outcome after laceration and surgical incision repair, *Plast Reconstr Surg* 110:429-435, 2002.
5. Kraissl C: The selection of lines for elective surgical incisions, *Plast Reconstr Surg* 8:1-28, 1951.
6. Borges A, Alexander J: Relaxed skin tension lines, Z-plasties on scars and fusiform excision of lesions, *Br J Plast Surg* 15:242-254, 1962.
7. Hollander JE, Blaski B, Singer AJ, et al: Poor correlation of short- and long-term cosmetic appearance of repaired lacerations, *Acad Emerg Med* 2:983-987, 1995.
8. Gilchrist B: Age-related changes in skin. In Cape R, Coe R, Rossman I, editors: *Fundamentals of geriatric medicine*, New York, 1983, Raven Press.
9. Warrenfeltz A, Graham W: Avulsion injuries in patients receiving corticosteroids, *Am Fam Pract* 11:74-81, 1975.

# CHAPTER 4

## Surface Injury and Wound Healing

### MECHANISM OF INJURY

- Shearing
- Tension
- Compression

### NORMAL WOUND HEALING

- Immediate Response to Injury: Hemostasis
- Inflammatory Phase
- Epithelialization
- Neovascularization
- Collagen Synthesis
- Wound Contraction and Remodeling
- Scar Management and Revision

### CATEGORIES OF WOUND HEALING

- Primary Closure (Primary Intention)

- Secondary Closure (Secondary Intention)
- Tertiary Closure (Delayed Primary Closure)

### FACTORS COMPLICATING WOUND HEALING

- Wound Characteristics
- Wound Infection
- Technical Factors
- Anatomic Factors
- Associated Conditions and Diseases
- Drugs

### SUTURE MARKS

### KELOID AND HYPERTROPHIC SCAR FORMATION

Many of the elements of scar formation are beyond the control of the operator repairing a traumatic wound. In contrast to surgical incisions, wounds and lacerations are not planned with regard to location, length, depth, or cosmetic concerns. Wounds caused at random present a variety of biologic and technical problems that need to be solved to produce the best repair result. It is incumbent on the operator to have a thorough understanding of the mechanisms of injury and the process of wound healing to increase the chances of achieving a cosmetically acceptable scar. Age, race, body region, skin tension lines, associated conditions and diseases, drugs, type of wound, and technical considerations all affect scar formation. The choice of repair strategy depends on these and other factors. Finally, knowledge of the spectrum of wound healing ensures that patients with traumatically induced wounds receive the proper advice and counseling.

### MECHANISM OF INJURY

The mechanism of injury is important because it is a significant determinant in the choice of management technique and in estimating the probability of wound infection. The injury mechanism also plays a role in scar formation and in the eventual cosmetic outcome. The mechanism of injury can be described as three forces that are applied to the skin under injury conditions: shearing, tension, and compression forces.<sup>1,2</sup> Table 4-1 lists the various causes of emergency department wounds and their frequency.

#### Shearing

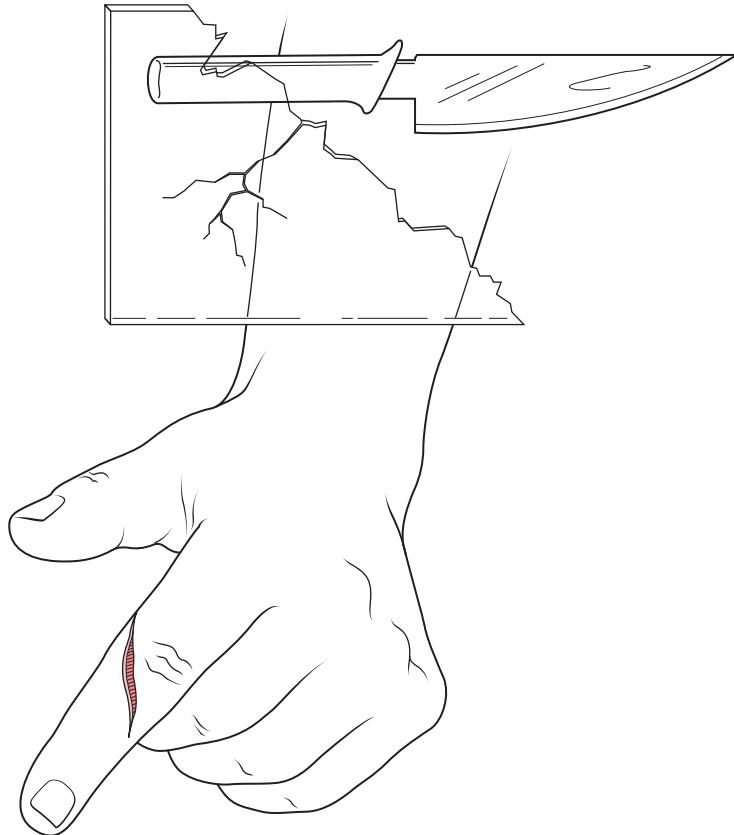
Shearing injuries, which result in a simple dividing of tissues, are caused by sharp objects, such as knives or glass (Fig. 4-1). This mechanism accounts for most lacerations seen in the

TABLE 4-1 *Etiology of Traumatic Wounds\**

Cause of Wound	No. of Cases*
Blunt object	417 (42%)
Sharp (nonglass)	338 (34%)
Glass	133 (13%)
Wood	35 (4%)
Bites	
Human	5 (1%)
Dog	29 (3%)
Other	15 (2%)
Totals	972 (99%)

\*Taken from a study of 1000 wounds. The etiology of the wound was not described in 28 cases.

From Hollander JE, Singer AJ, Valentine S, Henry MC: Wound registry: development and validation, *Ann Emerg Med* 25:675-685, 1995.



**Figure 4-1** Examples of injuring objects and a resulting laceration caused by shearing forces.

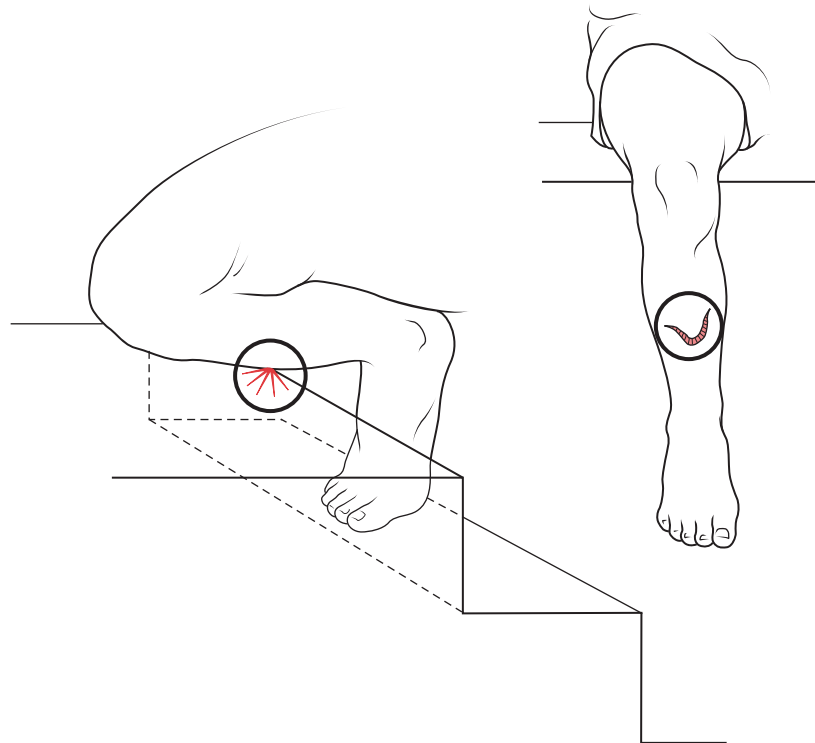
emergency department.<sup>3</sup> The skin is divided traumatically, but little energy is imparted to the tissues and minimal cell destruction occurs. These lacerations can be repaired primarily (primary intention), and they have a low incidence of wound infection. The resulting scar usually is thin and cosmetically acceptable.

### Tension

Tension injuries occur as a result of a blunt or semiblunt object striking the skin at a glancing angle (Fig. 4-2). Under these conditions, a triangular flap, a partial avulsion, of skin often is created. Because the blood supply is interrupted on two sides of the flap, ischemia can occur, leading to devitalization and necrosis. The remaining blood vessels entering the flap from the base have to be preserved by careful handling and special suturing techniques, which are described in Chapter 11. If the flap base is distally based (i.e., the flap tip points back against the regional arterial flow), the compromise is even greater. The energy necessary to create this type of wound is greater than that caused by shearing forces. The combination of potential ischemia and greater cell destruction can increase the risk of wound infection. These wounds also tend to lead to greater scar formation.

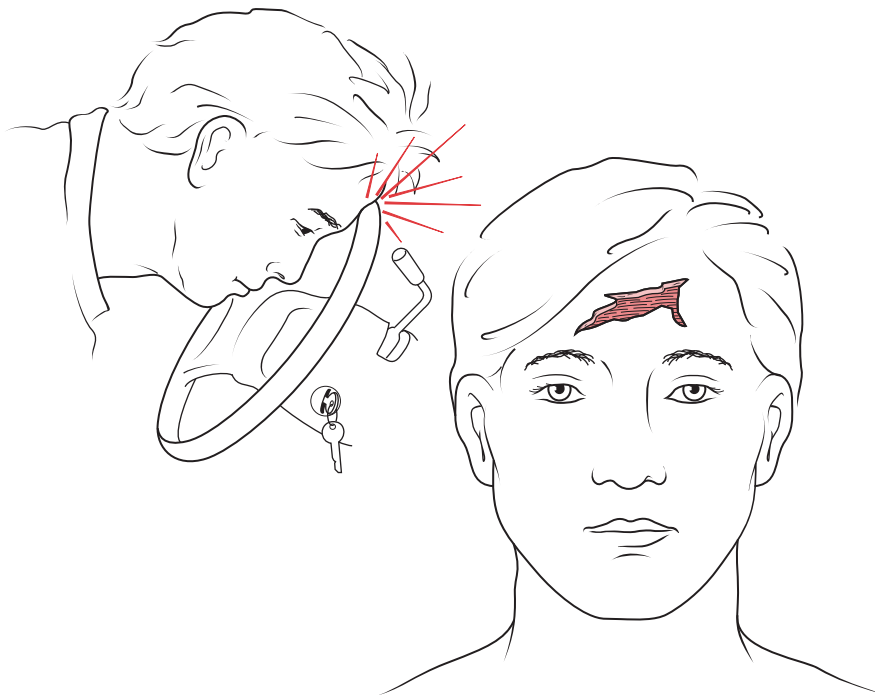
### Compression

Crushing or compression injuries occur when a blunt object strikes the skin at right angles (Fig. 4-3). These lacerations often have ragged or shredded edges and are accompanied by significant devitalization of skin and superficial fascia (subcutaneous tissue). Under these



**Figure 4-2** Example of the mechanism of injury and the resulting flaplike laceration caused by tension forces.





**Figure 4-3** Example of the mechanism and result of an injury caused by compression forces.

conditions, there is increased susceptibility to infection.<sup>4</sup> These wounds require extensive cleansing, irrigation, and débridement. Despite a meticulous primary repair, the resulting scars can be cosmetically poor in appearance.

---

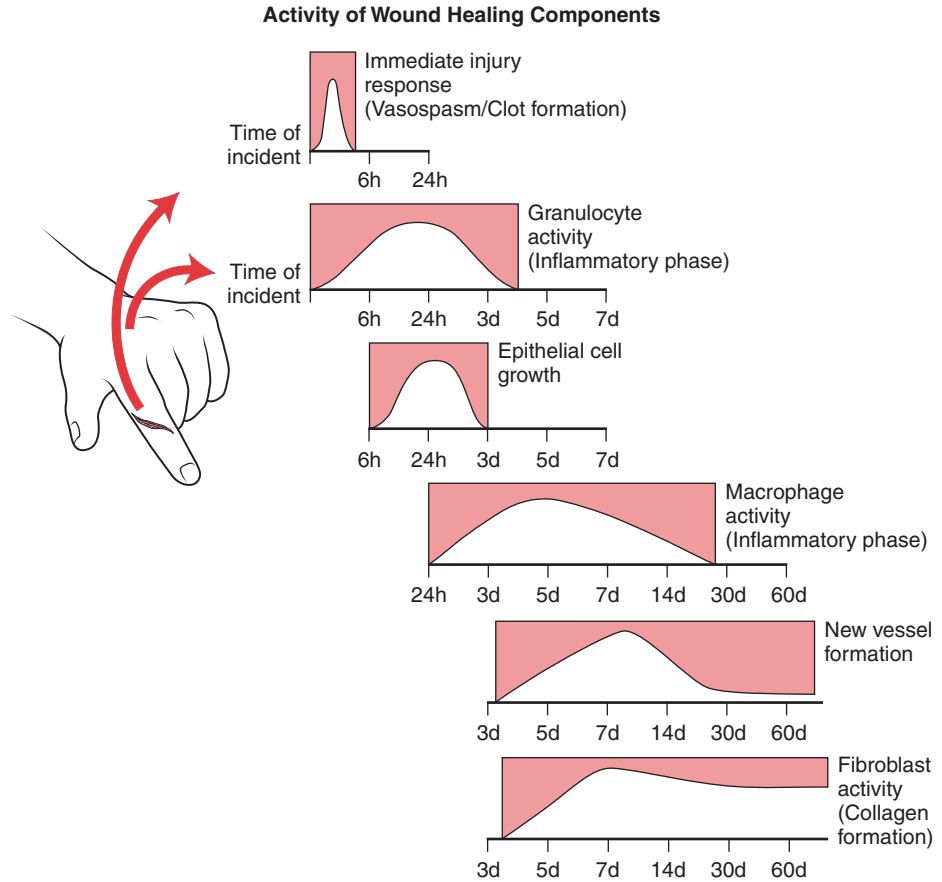
## **NORMAL WOUND HEALING**

When injury has occurred, by whatever mechanism, normal wound healing proceeds unimpeded, unless there is undue interference from infection, tissue devitalization, poor repair technique, or underlying conditions such as diabetes and healing-inhibiting drugs. In recent years, there has been an explosion in research on and knowledge of the biochemical aspects of wound healing, specifically of growth factors.<sup>5</sup> Virtually all healing events—inflammation, angiogenesis, epithelialization, fibroblast growth, scar remodeling—are under the control of specific mediators derived from a variety of sources, including platelets, macrophages, and lymphocytes. These mediators, particularly growth factors, already are being applied therapeutically in chronic wounds.<sup>6</sup> The future of acute wound care promises to bring biochemical interventions that will enhance wound healing considerably.

Although wound healing commonly is described as a discrete event, it is actually a continuum of overlapping phases. For the sake of clarity, these phases are described separately and their interrelationships are graphically depicted in Figure 4-4.

### **Immediate Response to Injury: Hemostasis**

At the moment of injury, several events take place that culminate in rapid hemostasis. The traumatic insult causes changes in skin architecture that result in wound edge retraction and



**Figure 4-4** The various components of wound healing and their time frames.

tissue contraction, which lead to compression of small venules and arterioles. Vessels also undergo intense reflex vasoconstriction for 10 minutes. Platelets begin to aggregate in the lumens of the severed vessels and on the exposed wound surfaces. The clotting cascade is activated by tissue clotting factors, and within minutes, the wound begins to fill with a hemostatic coagulum. As hemostasis is secured, vasoactive amines are released into the wound region, leading to the dilation of uninjured capillaries and the initiation of wound exudation.

### Inflammatory Phase

When hemostasis has been achieved and exudation begins, the inflammatory response rapidly follows. The complement system is activated, and chemotactic factors, which attract granulocytes to the wound area, are released. These cells are followed shortly by lymphocytes. Peak granulocyte numbers can be found 12 to 24 hours after the injury is sustained. The chief function of granulocytes and lymphocytes seems to be the control of bacterial growth and the suppression of infection. These cells are aided by immunoglobulins that are included in the wound exudate. In most simple wounds, granulocyte counts diminish markedly after 3 days.

After 24 to 48 hours, macrophages can be detected in large numbers, and, by day 5, they are the predominant inflammatory cells in the wound area. These cells play a major role in the inflammatory responses and in the early fibroblast and collagen formation. Their first responsibility seems to be phagocytosis and ingestion of wound debris. As part of this process, these cells return usable substrates (amino acids and simple sugars) back to the wound exudate. Macrophages also seem to be important in stimulating fibroblast reproduction and neovascularization. Finally, these remarkable cells produce and release a chemotactic factor that attracts more of its kind to the wound region.

### Epithelialization

While the inflammatory response proceeds, epithelial cells at the stratum germinativum, or basal layer of the epidermis, undergo morphologic and functional changes. Within 12 hours, intact cells at the wound edge begin to form pseudopod-like structures that facilitate cell migration. Replication takes place, and the cells begin to move over the wound surface. An advancing layer can be seen traveling over the damaged dermis and under the hemostatic coagulum. When these cells reach the inner wound area, they begin to meet other advancing epithelial extensions. The original cuboidal shape of the epithelial cells is regained, and desmosomal attachments to other cells are made. Continued replication eventually reestablishes the normal layers of epidermis. After repair for lacerations caused by shearing forces, initial epithelialization can take place within 24 to 48 hours, but the architecture and thickness of this layer continually change over the months of the wound maturation process.

### Neovascularization

The phenomenon of new vessel formation is crucial to wound repair. These vessels replace the old injured network and bring oxygen and nutrients to the healing wound. Neovascularization is evident by day 3 and is most active by day 7; this explains the marked erythematous appearance of the wound at the time of suture removal. Vascularity decreases rapidly by day 21, with continued regression as the wound matures. New vessels form loops of capillaries that are surrounded by actively growing fibroblasts. These two components on the wound surface give it the classic appearance referred to as *granulation*. Granulation tissue is seen most often in open wounds that are allowed to heal by secondary intention.

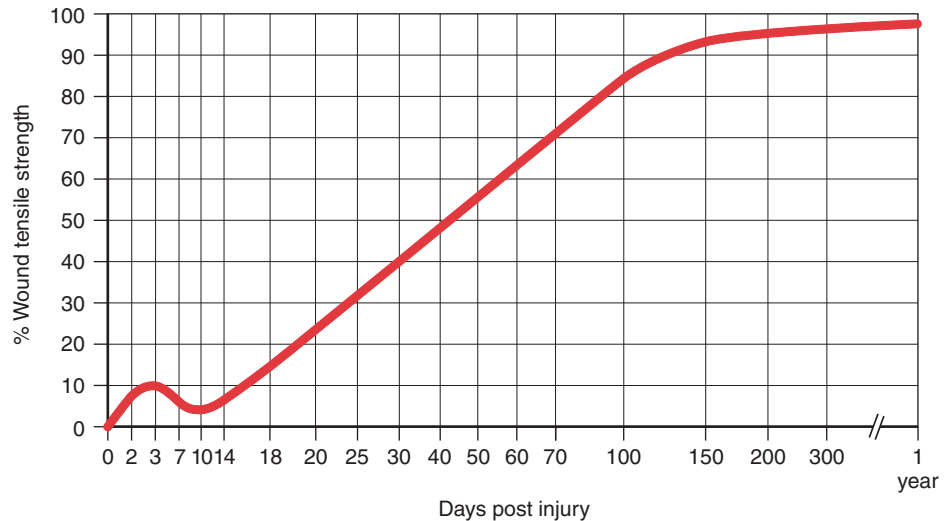
### Collagen Synthesis

With the establishment of a vascular supply and stimulation by macrophages, fibroblasts rapidly undergo mitosis. They begin to produce new collagen fibrils by day 2. Peak synthesis occurs between days 5 and 7, and the wound has its greatest collagen mass by 3 weeks. By then, the wound is devoid of inflammatory infiltrate and edema.

New collagen is laid down in a random, amorphous pattern. It is a gel with little tensile strength. Over the months, however, this gel continually remodels itself, creating an organized basket-weave pattern that is achieved by the cross-linking of collagen fibers. For this to proceed without excess collagen formation, collagen lysis takes place. Hydrolysis and collagenase activity break down old and damaged collagen, permitting ingestion by macrophages. New collagen takes its place. The balance between synthesis and lysis creates a vulnerable period approximately 7 to 10 days after injury, when the wound is most prone to unwanted opening or dehiscence. The wound has only 5% of its original tensile strength at 2 weeks and 35% at 1 month (Fig. 4-5). Final tensile strength is not achieved for several months.

### Wound Contraction and Remodeling

Every wound undergoes scar remodeling over several months. With this remodeling comes some degree of wound contraction. It is most pronounced in full-thickness skin losses.



**Figure 4-5** Percentage of tensile strength that develops in a wound in the days and months after injury.

The scar that forms gradually contracts centripetally over the wound defect through the action of specialized fibroblasts called *myofibroblasts*. Contraction pulls normal surrounding skin over the defect. Practically speaking, a properly everted suture line contracts to a flat, cosmetically acceptable scar, whereas a wound closed with the edges already inverted forms an unsightly depression in the epidermis that stands out because of shadow formation from incident light (see Chapter 10).

As scars remodel, they change appearance as well. In a study of scar appearance at suture removal versus appearance 6 to 9 months later, there was little correlation.<sup>7</sup> Biologic determinants, such as skin tension, wound remodeling, and body location, ultimately determine final scar appearance. Patients need to be advised that the final appearance may not be evident for 6 months to 1 year. Only then can scar revision be considered.

### Scar Management and Revision

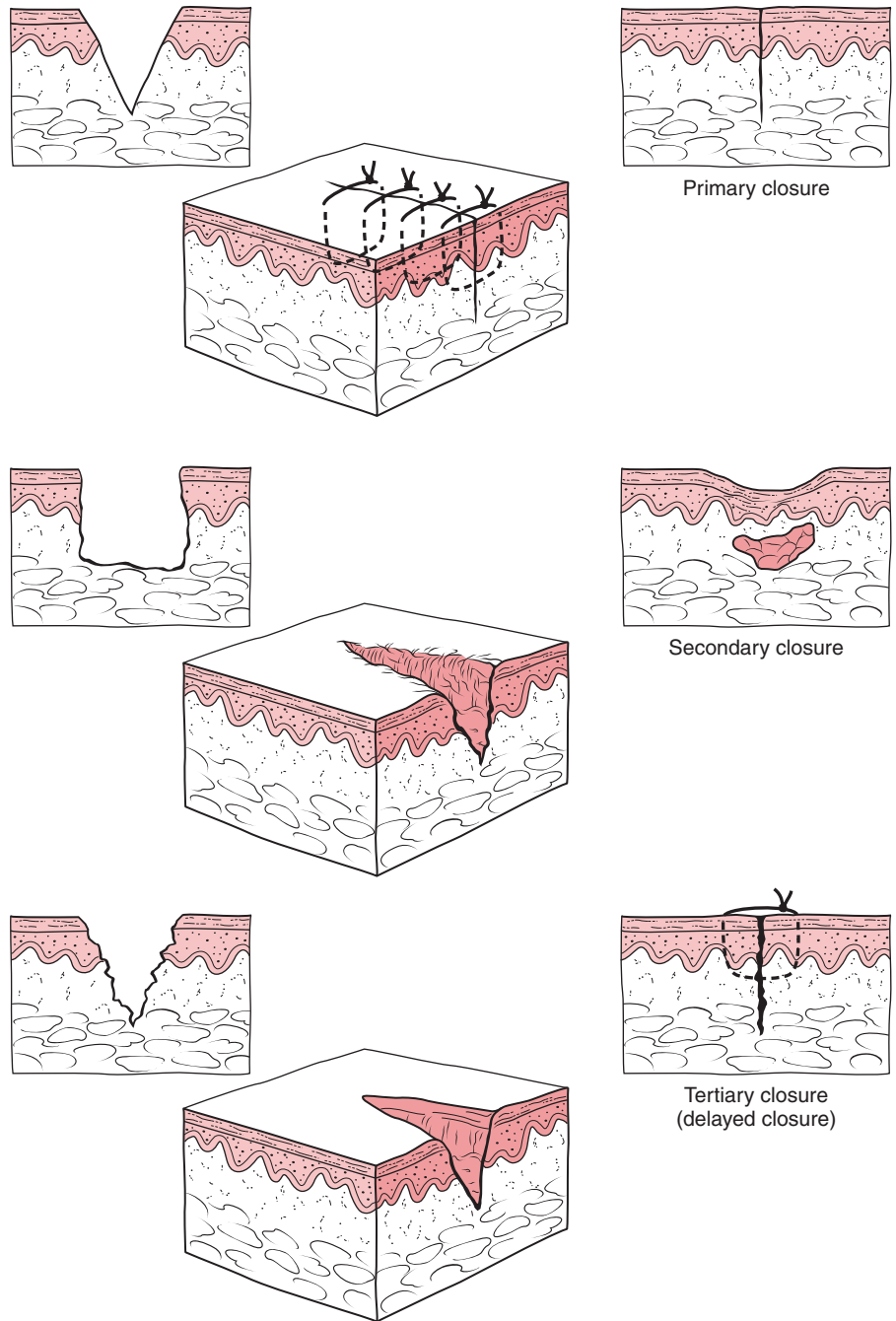
In a small but significant number of cases, the final scar result is unsightly and unacceptable to the patient. There are many surgical and nonsurgical techniques to modify that result. Z-plasty and dermabrasion are surgical interventions that have been shown to alter scar appearance effectively and favorably.<sup>8,9</sup> Nonsurgical techniques include cryotherapy, pressure dressings, radiation therapy, and intralesional corticosteroids and antimetabolites.<sup>10</sup>

At the time of wounding, it is important to identify patients who have a history of keloid or hypertrophic scar formation. For these patients, interventions need to be started shortly after the initial repair. Techniques shown to be effective for these patients are laser therapy, pressure dressings, and intralesional corticosteroids.<sup>10,11</sup> These patients need to be referred to specialists skilled in these therapies during the initial phases of wound healing.

---

## CATEGORIES OF WOUND HEALING

For clinical purposes, wound healing often is categorized into three types of closure or intentions: primary, secondary, and tertiary (Fig. 4-6). Based on time from injury, level of



**Figure 4-6** Primary closure is accomplished by closing the wound with sutures at the time of presentation to the emergency department. Secondary closure occurs as a result of natural healing without intervention other than cleansing and débridement. Tertiary closure (delayed primary closure) is carried out approximately 4 to 5 days after the injury.

contamination, and degree of tissue devitalization, this classification guides the choice of closure strategy.

### Primary Closure (Primary Intention)

Primary closure can be carried out only on lacerations that are relatively clean and minimally contaminated, with minimal tissue loss or devitalization. Shearing forces most often create these wounds. They can be closed with sutures, wound tapes, or staples. Repair of wounds is optimal when carried out within 6 to 8 hours (often referred to as the “golden period”) from the time of injury. In practice, this period can vary from 6 to 24 hours according to body region, level of contamination, and degree of tissue devitalization. The risk for hand and foot infection increases significantly after 4 to 6 hours.<sup>12</sup> Some practitioners feel comfortable closing uncomplicated facial lacerations 24 to 36 hours after injury.<sup>9,13</sup>

Because there are no hard and fast rules that govern every possible situation, the following recommendation is made: Any injury that can be converted to a fresh-appearing, slightly bleeding, nondevitalized wound, with no visible contamination or debris after aggressive cleansing, irrigation, and débridement, is a candidate for primary closure.

### Secondary Closure (Secondary Intention)

Skin infarctions, ulcerations, abscess cavities, punctures, small cosmetically unimportant animal bites, and partial-thickness (dermal base preserved) abrasions often are better left to heal by secondary intention. They are not closed with sutures and are allowed to heal gradually by granulation and eventual reepithelialization. After an appropriate program of wound care, they can become candidates for later skin coverage, if necessary, by grafting. These wounds have a pronounced inflammatory response and are prone to significant wound contraction over time.

### Tertiary Closure (Delayed Primary Closure)

Certain wounds are candidates for closure after being cleansed, débrided, and observed for 4 to 5 days.<sup>14-16</sup> These are wounds that are too contaminated to close primarily but that have not suffered significant tissue loss or devitalization. Wounds that fall into this category are often older; excessively contaminated with soil, feces, saliva, or vaginal secretions; caused by human or animal bites (see Chapter 15); or the result of high-velocity missiles, such as bullets. Wounds created after exploration for and removal of noninert foreign bodies also are candidates. The rationale for closure after 4 days is shown in Figure 9-1, which illustrates the incidence of wound infection after injury at varying times from the original injury. The technique for delayed wound closure is described in Chapter 9. With delayed closure techniques, the infection rate is 4%, similar to the rate of clean, primarily closed wounds.<sup>17</sup>

---

## FACTORS COMPLICATING WOUND HEALING

There are many sources of potential interference with uncomplicated wound healing. Only recently, however, has a study been done to determine the patient and wound characteristics that are most likely to be associated with poor cosmetic outcome after laceration and incision repair. In a multivariate analysis of factors, the most likely characteristics were associated tissue trauma, use of electrocautery, incomplete wound edge apposition, extremity location, and wound width.<sup>18</sup> These and other factors are discussed subsequently and summarized in Box 4-1.

## BOX 4-1

**Interference with Wound Healing****Technical Factors**

Inadequate wound preparation  
 Excessive suture tension  
 Reactive suture materials  
 Local anesthetics

**Anatomic Factors**

Static skin tension  
 Dynamic skin tension  
 Pigmented skin  
 Oily skin  
 Body region

**Associated Conditions and Diseases**

Advanced age  
 Severe alcoholism  
 Acute uremia  
 Diabetes  
 Ehlers-Danlos syndrome  
 Hypoxia  
 Severe anemia  
 Peripheral vascular disease  
 Malnutrition

**Drugs**

Corticosteroids  
 Nonsteroidal antiinflammatory drugs  
 Penicillamine  
 Colchicine  
 Anticoagulants  
 Antineoplastic agents

**Wound Characteristics**

As discussed previously, the mechanism of the wound has a direct bearing on scar formation. Sharp, incisional wounds heal with minimal scarring compared with wounds caused by avulsion or crushing. Wide wounds, or wounds involving significant surface area, such as burns, cause noticeable scarring. Deep wounds, which cause significant injury to structures below the skin, tend to leave behind surface depressions or irregularities. When the normal, orderly arrangement of epithelial, dermal, and subcutaneous architecture is altered by wounding, it can never return fully to its original state or configuration.

**Wound Infection**

The most common and serious complication of wound and laceration repair is infection. Because all accidentally induced wounds occur in unsterile conditions, they have to be considered contaminated with bacteria and other organisms on arrival to the emergency department. The stratum corneum of the epidermis normally acts as an effective barrier against the penetration of bacteria into the deeper layers of the skin and superficial fascia. Any violation of the epidermis provides a pathway for bacterial invasion. Not only do environmental microorganisms find their way into wounds, but also the skin, which is populated with a variety of indigenous microflora, can harbor a potentially infective inoculum of pathogenic bacteria.<sup>19</sup> Areas of the body with high concentrations of bacteria include scalp, perineum, axillae, mouth, feet, and nail folds. The trunk and proximal extremities are sparsely populated.

A crucial factor in determining whether contaminating bacteria go on to cause an established wound infection is the time elapsed from injury to cleansing and repair. It has been established that 100,000 ( $10^5$ ) bacteria per gram of tissue constitute an infective inoculum.<sup>3</sup> Wounds with counts less than that number heal without event. If bacterial counts are greater than that number, the risk of infection increases manyfold.<sup>20</sup> In a series of patients studied in an emergency department, it was observed that wounds less than 2.2 hours old contained 100 ( $10^2$ ) bacteria per gram of tissue.<sup>21</sup> Wounds that were 3 hours old harbored  $10^2$  to  $10^6$  bacteria per gram of tissue. Wounds more than 5 hours old consistently grew more than  $10^6$  bacteria per gram of tissue. Despite experimental support for bacterial growth and invasion early after injury, the true clinical significance has not been established. It remains prudent, however, to cleanse and irrigate wounds in a timely manner. If antibiotics are considered necessary, early administration is appropriate.

### Technical Factors

Soil, in particular clay, can impair healing in two ways.<sup>22</sup> First, the threshold infective inoculum is reduced to  $10^2$  bacteria, even in the presence of a small amount of dirt.<sup>23</sup> Second, soil and grit of any kind can lead to permanent tattooing if not aggressively removed. Consultation with a plastic surgeon may be indicated if wound cleansing and débridement cannot eliminate grit that is visibly embedded in the epidermis and superficial dermis.

Excessive tension created by improper suture technique can cause unnecessary wound ischemia.<sup>24</sup> Ischemia promotes cellular necrosis with greater inflammatory and scarring responses. Deep sutures, undermining, and increasing the number of sutures per laceration are methods that can reduce the danger of excessive tension.

Because tissue reactivity and inflammation vary with different suture materials, these materials can have differing effects on the healing process.<sup>25</sup> Although silk has excellent mechanical properties, it has a propensity for causing marked tissue reactivity. Nylon and polypropylene are the least reactive of the nonabsorbable materials. Absorbable sutures act as foreign material, and excessive numbers can increase the risk of infection and may provoke a greater scarring response.<sup>26,27</sup> Wound tapes and staples are the least reactive of wound closure alternatives and are associated with low infection rates even in contaminated wounds.

Experiments have shown that local anesthetics can cause retardation of wound healing.<sup>28</sup> This negative effect is enhanced by increasing concentrations of local anesthetics and the use of epinephrine in anesthetic solutions.<sup>23</sup> There is no question, however, that local anesthetics need to be used in wound care. Judicious amounts at the lowest concentrations possible are recommended.

### Anatomic Factors

Body region and skin tension lines have a significant effect on wound healing, specifically on final scar morphology (see Chapter 3). Wounds over the anterior thorax or the extremities heal with the most evident scars, whereas wounds of the eyelid heal with the least obvious scars. Pigmented and oily skin also tends to heal with greater scar formation than fairer, less oily skin.

### Associated Conditions and Diseases

Several conditions and diseases cause an alteration in wound healing. Advanced age has been implicated in slower healing of wounds.<sup>29</sup> If an older patient is basically healthy, however, normal healing and scar formation ultimately take place.<sup>30</sup> Wound healing can be retarded in a patient with chronic alcoholism who has advanced liver disease and impaired



protein synthesis. Acute uremia has long been thought to impede healing.<sup>31</sup> In patients with uremia, there is an inhibition of fibroblast growth and a decrease in tensile strength during wound healing. Patients with diabetes also have numerous problems with wound healing.<sup>32</sup> Not only do they have an increased chance of wound infection, but also there is retardation of neovascularization and collagen synthesis. A rare disease that causes problems with collagen formation and wound healing is Ehlers-Danlos syndrome.<sup>33</sup>

Any condition that leads to failure of oxygen and nutrient delivery to the wound profoundly affects wound healing.<sup>34</sup> Shock, severe anemia, peripheral vascular disease, and malnutrition all fall into this category. Patients with severe underlying diseases, such as advanced cancer, hepatic failure, and severe cardiovascular disease, are subject to poor wound healing. Victims of major trauma, particularly individuals who have undergone prolonged shock and complicated resuscitations, also are at risk for poor wound healing.

## Drugs

Numerous drugs and pharmacologic preparations alter wound healing.<sup>35</sup> Drugs that seem to have negative effects include corticosteroids, nonsteroidal antiinflammatory drugs (aspirin, phenylbutazone), penicillamine, colchicine, anticoagulants, and antineoplastic agents. Of these drugs, corticosteroids have the most profound effect on healing and interfere with the process at many points. They adversely alter the inflammatory response, fibroblast activity, neovascularization, and epithelialization. Nonsteroidal antiinflammatory drugs depress the normal inflammatory response and can decrease overall wound tensile strength. Anticoagulants and aspirin increase the possibility of wound hematoma formation with subsequent delays in healing time. Although in theory antineoplastic agents have a good reason to inhibit wound healing, in actual practice it is not clear that they do so in a clinically significant manner.

Vitamins C and A, zinc sulfate, and anabolic steroids have a generally positive effect on wound repair.<sup>35</sup> Vitamin C deficiency profoundly impairs collagen formation, but normal synthesis can be restored with administration of ascorbic acid. Vitamin A and anabolic steroids are able to reverse corticosteroid-induced suppression of the inflammatory response. Zinc deficiency seems to play a role in slowing the healing process. Correction of the deficiency reverses that effect. Use of zinc ointments in non-zinc-deficient patients can cause a cross-linking failure during collagen maturation.<sup>36</sup> Experimental evidence that zinc sulfate can retard wound contraction supports this observation.<sup>36</sup>

---

## SUTURE MARKS

Skin suture marks can be an unsightly and unnecessary complication of laceration repair. There are several causes of suture marks, some within and some out of the control of the operator.<sup>37</sup> The causes are the following:

- *Skin type*: Some areas of the skin, including the skin of the back, chest, upper arms, and lower extremities, are more prone to retaining suture marks than others. On the face, skin of the lower third of the nose and cheeks adjacent to the nasal alae also is vulnerable. Suture marks are unusual on the eyelids, palms of the hands, and soles of the feet.
- *Keloid tendency*: Keloid formers have a higher risk of suture mark formation.
- *Suture tension*: Excessive suture tension during knot tying can cause tissue constriction, which increases the risk for larger, more obvious suture marks.
- *Stitch abscess*: Occasionally a small abscess forms adjacent to the suture itself. Because suture material is a foreign body, the risk of abscess formation, although small, is inherent. Silk and braided sutures are more likely to provoke an inflammatory response at the suture site than monofilament nylon or metallic staples.<sup>24</sup>

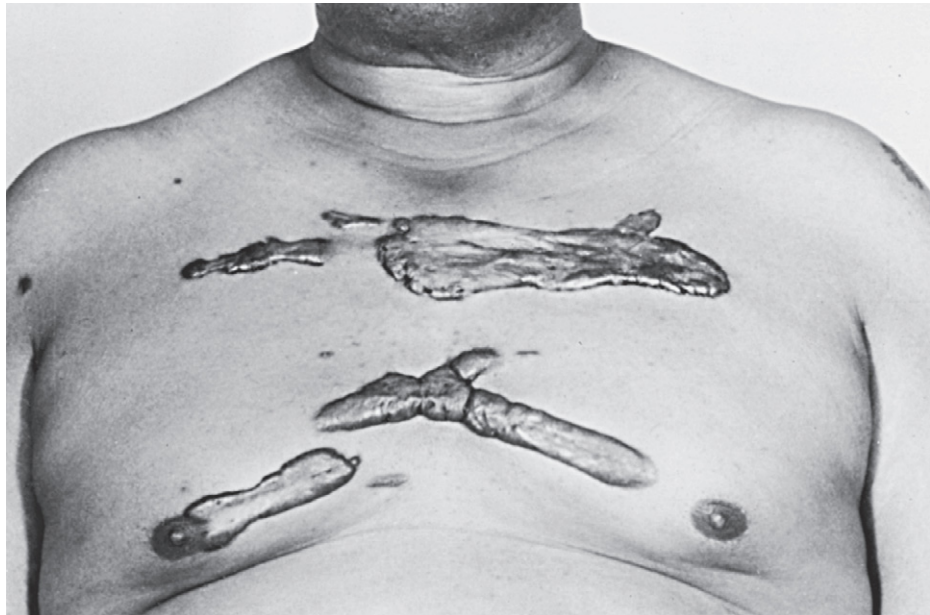- *Duration sutures left in place:* Sutures remaining in place for 14 days or longer uniformly leave behind suture marks.<sup>37</sup> By 14 days, epithelialization of the suture track occurs and a permanent epithelial “plug” is left behind. Conversely, no suture marks remain if sutures are removed before 7 days. The period between 7 and 14 days is less predictable with regard to retention and permanency of suture marks. These findings are independent of needle type or suture size.

---

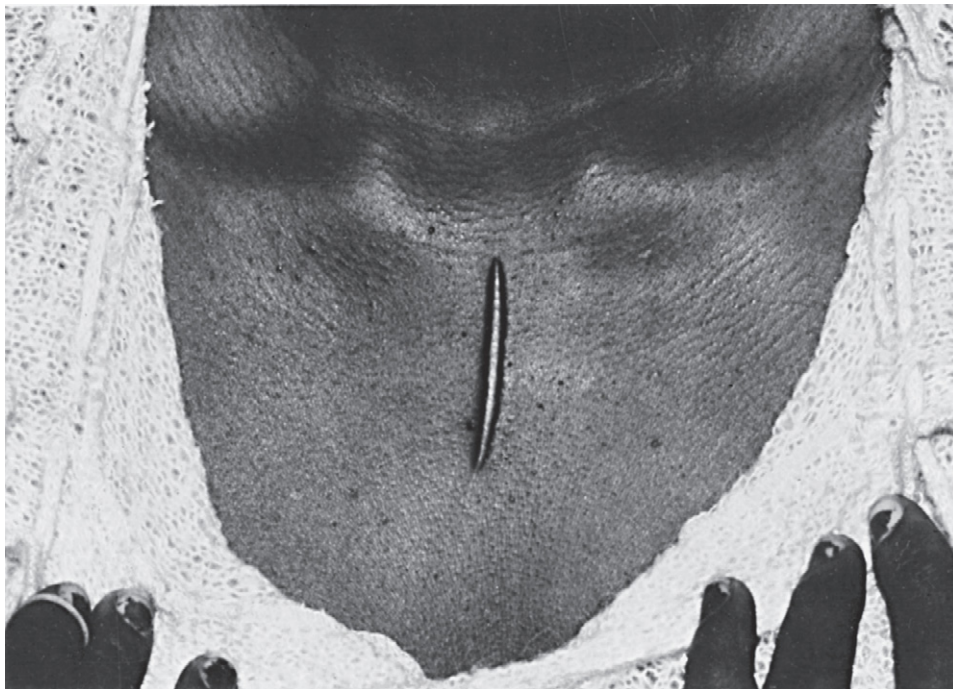## KELOID AND HYPERTROPHIC SCAR FORMATION

A keloid is an inappropriate accumulation of scar tissue that originates from a wound and extends beyond its original boundaries (Fig. 4-7). Keloids are more common in blacks but can occur in darkly pigmented skin areas of people of different races. These scars more commonly tend to be located on the ears, upper extremities, lower abdomen, and sternum. Eventual outcome and treatment depend on early recognition of keloid formation and prompt therapy.

Hypertrophic scars also have excessive bulk, but in contrast to keloids, they are confined to the original borders of the wound (Fig. 4-8). They tend to occur in areas of tissue stress, such as flexion creases across joints. The cause of this excessive scar response is not known. Physical therapy and splinting can be used during healing in patients who have a history of hypertrophic scarring. Interventions to minimize these abnormal scar formations are discussed in the section on scar management and revision.



**Figure 4-7** Example of a keloid scar. The scar extends beyond the margins of the original wound.



**Figure 4-8** Example of a hypertrophic scar. The scar remains confined to the original borders of the wound.

## REFERENCES

1. Edlich R, Rodeheaver G, Thacker J: Technical factors in the prevention of disease. In Simmons RL, Howard RJ, Henriksen AI, editors: *Surgical infectious diseases*, New York, 1982, Appleton-Century-Crofts.
2. Trott AT: Mechanisms of surface soft tissue trauma, *Ann Emerg Med* 17:1279-1283, 1988.
3. Edlich RF, Rodeheaver GT, Morgan RF, et al: Principles of emergency wound management, *Ann Emerg Med* 17:1284-1302, 1988.
4. Cardany R, Rodeheaver GT, Thacker TG, et al: The crush injury: a high risk wound, *J Am Coll Emerg Physicians* 5:965-970, 1976.
5. Howell JM: Current and future trends in wound healing, *Emerg Med Clin North Am* 10:655-663, 1992.
6. Trott AT: Chronic skin ulcers, *Emerg Med Clin North Am* 10:823-845, 1992.
7. Hollander JE, Blasko B, Singer AJ, et al: Poor correlation of short- and long-term cosmetic appearance of repaired lacerations, *Acad Emerg Med* 2:983-987, 1995.
8. Hove CR, Williams EF 3rd, Rodgers BJ: Z-plasty: a concise review, *Facial Plast Surg* 17:289-294, 2001.
9. Poulos E, Taylor C, Solish N: Effectiveness of dermasanding (manual dermabrasion) on the appearance of surgical scars: a prospective, randomized, blinded study. *Am Acad Dermatol* 48:897-900, 2003.
10. Chang CW, Ries WR: Nonoperative techniques for scar management and revision, *Facial Plast Surg* 17:283-288, 2001.
11. Alster T: Laser scar revision: comparison study of 585-nm pulsed dye laser with and without intra-lesional steroids, *Dermatol Surg* 29:25-29, 2003.
12. Morgan WJ, Hutchinson D, Johnson HM: The delayed treatment of wounds of the hand and forearm under antibiotic cover, *Br J Surg* 67:140-141, 1980.
13. Chisholm CD: Wound evaluation and cleansing, *Emerg Med Clin North Am* 10:665-672, 1992.
14. Brown SE, Allen HH, Robins RN: The use of delayed primary wound closure in preventing wound infections, *Am J Obstet Gynecol* 127:713-717, 1977.
15. Dimick AR: Delayed wound closure: indications and techniques, *Ann Emerg Med* 17:1303-1304, 1988.

16. Johnson BW, Scott PG, Brunton JL, et al: Primary and secondary healing in infected wounds: an experimental study, *Arch Surg* 117:1189-1193, 1982.
17. Weiss Y: Delayed closure in the management of the contaminated wound, *Int Surg* 67(4 Suppl):403-404, 1982.
18. Singer AJ, Quinn JV, Thode HC Jr: Determinants of poor outcome after laceration and surgical incision repair, *Plast Reconstr Surg* 110:429-435, 2002.
19. Marples M: Life on the human skin, *Sci Am* 220:108-115, 1969.
20. Krizek TJ, Robson MC, Kho E: Bacterial growth and skin graft survival, *Surg Forum* 18:518-520, 1967.
21. Robson MC, Duke WF, Krizek TJ: Rapid bacterial screening in the treatment of civilian wounds, *J Surg Res* 16:299-306, 1974.
22. Rodeheaver GT, Pettry D, Turnbull V: Identification of the wound infection-potentiating factors in soil, *Am J Surg* 128:8-14, 1974.
23. Haurly BB, Rodeheaver GT, Pettry D, et al: Inhibition of nonspecific defenses by soil infection-potentiating factors, *Surg Gynecol Obstet* 144:19-24, 1977.
24. Price P: Stress, strain, and sutures, *Ann Surg* 128:408-421, 1948.
25. Swanson N, Tromovitch T: Suture materials: properties, uses and abuses, *Int J Dermatol* 21:373-378, 1982.
26. Edlich RF, Rodeheaver G, Kuphal J, et al: Technique of closure: contaminated wound, *J Am Coll Emerg Physicians* 3:375-381, 1974.
27. Losken HW, Auchincloss JA: Human bites of the lip, *Clin Plast Surg* 11:773-775, 1984.
28. Morris T, Appleby R: Retardation of wound healing by procaine, *Br J Surg* 67:391-392, 1980.
29. Grove G: Age-related differences in healing of superficial skin wounds in humans, *Arch Dermatol Res* 272:381-385, 1982.
30. Goodson W, Hunt T: Wound healing and aging, *J Invest Dermatol* 73:88-91, 1979.
31. Colin J, Elliot P, Ellis H: The effect of uraemia upon wound healing: an experimental study, *Br J Surg* 60:793-797, 1979.
32. Hunt T: Disorders of wound healing, *World J Surg* 4:271-277, 1980.
33. Cohen I, McCoy B, Biegelmann, R: An update on wound healing, *Ann Plast Surg* 3:264-272, 1979.
34. Hotter A: Physiologic aspects and clinical implications of wound healing, *Heart Lung* 11:522-530, 1982.
35. Pollack S: Systemic medications and wound healing, *Int J Dermatol* 21:491-496, 1982.
36. Soderberg T, Hallmans G: Wound contractions and zinc absorption during treatment with zinc tape, *Scand J Reconstr Surg* 16:255-259, 1982.
37. Crikelair GF: Skin suture marks, *Am J Surg* 66:631-639, 1958.

# Wound Care and the Pediatric Patient

*Javier A. Gonzalez del Rey, MD, and Gregg A. DiGiulio, MD*

## GENERAL APPROACH AND CALMING TECHNIQUES

Assessing the Child  
Handling Parents

## RESTRAINT FOR WOUND CARE

## PEDIATRIC PATIENT SEDATION

## LOCAL ANESTHETIC TECHNIQUES

## CHOICE OF CLOSURE MATERIALS

## SPECIAL CONSIDERATIONS FOR DIFFERENT ANATOMIC SITES

Scalp  
Face  
Hand  
Foot  
Perineum/Straddle Injuries

## WOUND AFTERCARE

Children commonly present to emergency departments with lacerations; lacerations represent approximately 30% to 40% of all injuries seen in a pediatric emergency department.<sup>1,2</sup> Estimates of the annual rate of lacerations are 50 to 60 per 1000 children.<sup>3,4</sup>

Lacerations commonly involve younger children who lack the experience, common sense, and motor coordination of older children. Boys are involved twice as often as girls. Lacerations frequently result from falls from stairways, bicycles, and furniture.<sup>5</sup> In children, lacerations occur most often on the head (60% of the time), followed in frequency by upper and lower extremities.<sup>5</sup> Overall, lacerations are a common type of pediatric injury requiring functional and cosmetic evaluation by a physician.

## GENERAL APPROACH AND CALMING TECHNIQUES

### Assessing the Child

The child with a laceration represents not only a technical challenge, but also an emotional challenge for the caregiver, the child, and the parent. Realizing this, it is important to take time to explain the procedure, the approach, and possible discomforts to the child and the parents. Time spent preparing the child is time gained in the end.

Assuming that there are no life-threatening or limb-threatening injuries, the clinician first should obtain the history while gaining the child's confidence. The clinician should not undress the child or examine the wound immediately. A rapport should be established by talking directly to the child using age-appropriate terms. The clinician can involve toddlers by asking them how they got their "boo-boo," but the clinician should not expect an adequate history; the specifics are better obtained from the parent. Children 4 years old and older frequently can give the history, which gives them a sense of control.

TABLE 5-1 *Childhood Development Abilities by Age*

Age (Yr)	Development Issues	Fears	Techniques
Infancy	Minimal language Feel like an extension of parents Sensitive to physical environment	Stranger anxiety	Keep parents in sight Address possible hunger Use warm hands Keep room warm
Toddler 1-3	Receptive language more advanced than expressive See themselves as individuals Assertive will	Brief separation Pain	Maintain verbal communication Examine in parent's lap Allow some choices (if possible)
Preschool 3-5	Excellent expressive skills Rich fantasy life Magical thinking	Long separation Pain Disfigurement	Allow expression Encourage fantasy and play Encourage participation in care
School age 5-10	Fully developed language Understanding of body structure and function Able to reason and compromise Experience with self-control	Disfigurement Loss of function Death	Explain procedures Explain pathophysiology and treatment Project positive outcome Stress child's ability to master situation Respect physical modesty
Adolescence 10-19	Self-determination Decision making Realistic view of death	Loss of autonomy Loss of peer acceptance Death	Allow choices and control Stress acceptance by peers Respect autonomy

Adapted from Stein MT: Interviewing in a pediatric setting. In Dixon SD, Stein MT, editors: Encounters with children, ed 2, St Louis, 1992, Mosby.

Distraction or imagery can be effective at any age. The clinician can ask about toys, friends, siblings, or favorite colors at an age-appropriate level. A general understanding of the developmental milestones is invaluable in enabling the physician to interact appropriately with children. Table 5-1 summarizes the developmental abilities for children at different ages.<sup>6</sup>

Child life specialists have been used successfully in inpatient settings for distraction during painful procedures. In recent years, more pediatric emergency departments are employing child life specialists. Although there is limited documentation as to their effectiveness in the outpatient setting, one study found that child life specialists had a positive effect in reducing fears and improving satisfaction in children 11 to 14 years old requiring repair for a facial laceration.<sup>7</sup> In our experience, a child life specialist is of great value in distracting children of all ages undergoing painful procedures, including laceration repair.

The history should focus on the events of the injury and the potential for injury to other areas of the body. Physical abuse should be considered when the history is not consistent with the injury or when the event cannot be explained by the developmental age of the patient (e.g., a 6-month-old *climbing* onto and falling from a counter). Also, some specific injury patterns should raise suspicion of abuse, including immersion pattern, linear marks or lacerations consistent with a belt or hanger, or an unusual location not usually prone to injury. A social services referral is necessary for any case in which abuse is suspected.

Special attention should be paid to the immunization status. Simply asking the parent if the child's shots are up-to-date most often elicits a positive response whether or not this is actually true. It is better to inquire about the number of "shots" and the age when the last one was given.

Next, the wound is assessed. Allowing the child to remain with the parent for as long as possible facilitates the examination. The physician can gain the child's confidence by telling him or her that initially the physician is just going to "look." The physician should continue to involve the parent in the evaluation process so that the child knows that the physician is there to help. Generally, kindness and patience should be accompanied by a thorough and directed approach. The examination should begin away from the injury, especially in a toddler or younger child. If the injury is on the hand or face, the physician should start by playing gently with a foot so that the child realizes that the physician is not going to hurt him or her and slowly advance to the site of the injury. Direct probing of the wound is painful and should not be done until after anesthesia is achieved. In cases in which hemostasis is necessary, pressure should be applied; this often can be done safely by the parent.

When the wound is evaluated, time should be taken to explain the procedure to the child and the parent. The clinician should use words that the child can understand ("numbing medicine," "I'm going to make this spot go to sleep," "magic string [suture material]—it's magic because it doesn't hurt"). The clinician should tell the child which part of the procedure may be uncomfortable and for how long. The parents should be allowed to participate as much as their level of comfort allows. A parent can be of great help in calming and distracting the child, and if the parent wants to be at the bedside, encourage him or her to stay. The parents should be given the option, however, of going to the waiting area if close by. Some parents cannot tolerate invasive treatment of their child, but this lack of tolerance should not be perceived as a lack of caring.

If the child does appear to be distressed or in pain, the physician should stop the procedure and evaluate the cause of the discomfort. If the discomfort is assessed to be related to fear, the physician should reassure family members by telling them why he or she thinks fear and not pain is the cause of the cry. The family should be encouraged to help distract the child. An extremely anxious child may need sedation (see later). If pain is the cause of the child's cry, the physician should discuss with the family and child the available options. These options include using more anesthetic or all parties agreeing that the pain of injecting additional anesthetic is not necessary for "one more stitch." The physician should involve the parents in the care and decisions about care and give them a sense of control, which ultimately leads to a more satisfying experience for all.

### Handling Parents

Parents may be upset because their child has been injured and may appear angry. Fear of the outcome or guilt because the child was injured when they were supposed to be their child's protector often underlies the parents' behavior. The physician can allay parents' fears by explaining the procedure, involving them in the process, and informing them of the expected outcome. Regardless of the circumstances, any exhibition of judgmental behavior by the caregiver is unwarranted.

Often parents bring in their child for seemingly minor cuts and wounds. Although this situation can be frustrating in a busy office or emergency department, the parent may be seeking a professional opinion as to whether the wound requires a formal repair. Sometimes local care and a bandage is the most appropriate care. Most parents can accept the care decision, no matter how minor, when clearly explained.

The caregiver should explain to the parent and child the proposed management of the wound and that he or she will do everything possible to alleviate pain by using an anesthetic.

A parent can be a great ally when faced with a frightened child, so the parent should be allowed to participate if he or she so desires. Parents should be questioned, however, about their tolerance for the procedure. If there is any risk for vasovagal syncope in a parent, he or she should leave the care area. Parents should be warned that the child may cry with touching or the sensation of pressure, and this does not always indicate pain. If the child appears to feel pain, the physician should strongly consider reanesthetizing the area; this greatly enhances parental satisfaction.

The clinician should explain what to expect from the laceration repair. Overall satisfaction is greatly improved if the parent understands the healing process and the truth that the laceration repair decreases but does not completely eliminate scarring. The discussion should include the changing appearance of the scar over time and the fact that all wounds scar and their final appearance may not be known for several months.

Verbal and written follow-up instructions are as important as the procedure itself. Printed discharge instructions detailing wound care, the signs and symptoms of infection, and the timing of suture removal are recommended. During the time of the visit, parents are frequently anxious and may not recall the myriad verbal instructions given to them.

---

## RESTRAINT FOR WOUND CARE

Most children are frightened and anxious about being in a physician's office or an emergency department. A conscientious physician spends time with the patient and parents to minimize this anxiety. If the previously described calming techniques do not allay the fears of an uncooperative child, restraints may be necessary. Whether or not to use restraints often can be determined by initial observation of the child's behavior and parental report of the child's overall ability to cooperate. The need for restraints seems to be lessened by the use of topical anesthetics, which eliminates the pain of infiltration. Should restraint be necessary, there are several methods available, including physical, chemical, and "imagery."

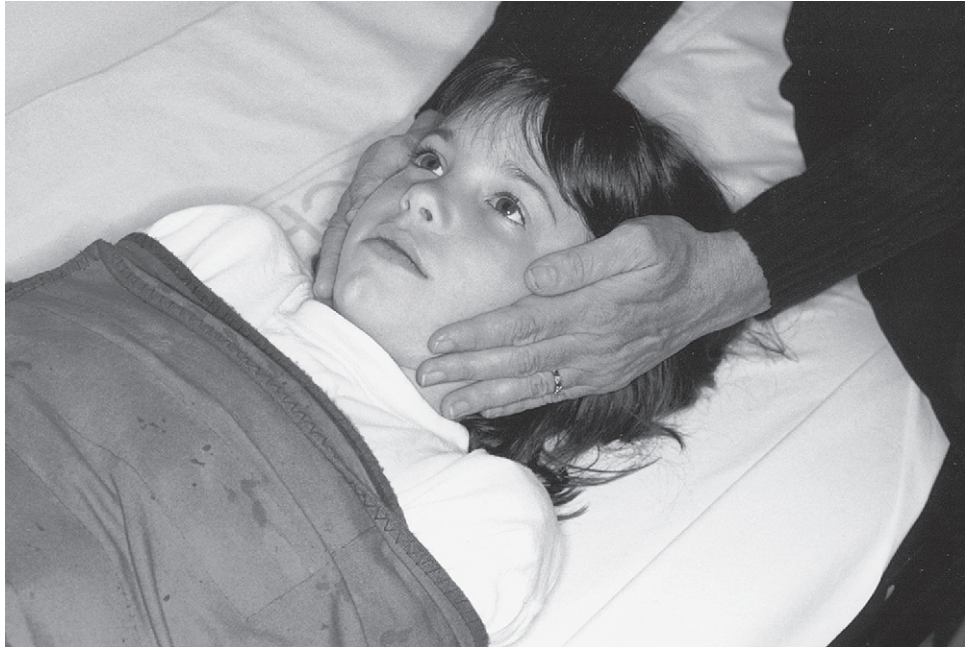Physical restraints should be considered in a preverbal child because imagery and verbal calming techniques are ineffective. Their limited language and ability to comprehend their situation makes it difficult for preverbal children to cooperate with caregivers. Papoose boards are usually well tolerated, and it is our experience that once in place, an infant or toddler frequently becomes less agitated after infiltration is performed. In our setting, the child life specialist is invaluable in calming the child and reducing the stress of the procedure and restraint.

Regardless of the method used, the caregiver always must take the time to explain the need for restraints to the parents. Restraints protect the child and caregiver during the procedure and ensure the best result. Their use is not without complication, however. Restraints limit the child's protective reflexes should he or she vomit. Excessive crying increases gastric pressure, and together with a full stomach the possibility of emesis increases. Suction should be readily available, and the child should be turned to a lateral decubitus position while in the papoose if emesis occurs.

Even when restraints are used, the assistance of a nurse or technician is necessary to maintain immobilization of the head for facial lacerations or of an extremity for hand, arm, foot, or leg lacerations. These personnel need formal training in restraining techniques. When immobilizing the face of a child, the holder needs to use his or her palms rather than fingertips to prevent bruising and to achieve better head control (Fig. 5-1). Care always is taken to maintain an unobstructed airway and a thorax free to provide adequate ventilation.

Mental imagery can be used with children who are 4 years old and older. The outcome frequently relates to the verbal abilities of the individual child. Imagery includes distraction or fantasy. The caregiver should ask the child to talk about his or her friends, favorite toys,





**Figure 5-1** When restraining a pediatric patient for a facial repair, the head is held with the palms of the hands. The airway remains unobstructed, and undue pressure with fingertips is avoided.

or what activities he or she likes. Alternatively the child can describe what makes him or her feel good. Keeping up-to-date on the latest toys can be invaluable. Often a parent can be an ally and help distract the child if he or she is permitted and wants to be at the bedside. An assistant also can play an important role in encouraging imagery and distracting the child.

---

## **PEDIATRIC PATIENT SEDATION**

Despite caregivers' best efforts, there is the occasional child who does not cooperate. When the child's inability to cooperate interferes with the physician's ability to perform an adequate repair or poses a danger to the caregivers or to the child himself or herself, the physician can consider the use of pharmacologic sedation. The type, location, and complexity of the laceration and the emotional state of the child determine the type of sedative to use. In small, simple lacerations, the risk of sedation may outweigh the benefits. In our experience and by using the previously described techniques, we are able to repair most lacerations, including facial lacerations, without the use of sedatives.

For repair of a laceration, the physician usually induces conscious or light sedation. In this state, the child maintains protective reflexes, maintains his or her own airway, and is able to respond to a directed command. All sedation techniques can evolve into deep sedation, which is a more depressed state of consciousness in which the child is not easily aroused and cannot maintain protective reflexes or an open airway. Titrating the sedative dose to the desired level of sedation may help prevent the evolution of conscious to deep sedation. In the office or emergency department, conscious sedation should be limited to children with

American Society of Anesthesiologists classifications I and II (class I is a normally healthy patient; class II is a patient with mild systemic disease).<sup>8</sup>

Choosing the appropriate method of sedation should take into consideration the following questions: Is the procedure painful? Does the child need to be motionless? What is the duration of the procedure? What safety resources are available for the procedure? When was the patient's last meal? In general, the time of the last meal must be considered when deciding on whether or not to sedate a child. The relative risk of providing sedation must be weighed against the risk of delaying the procedure.

The room where sedation is performed must have equipment available for airway and cardiovascular interventions for children of all ages and sizes. The physician must have the ability to handle a sudden change in the child's status. Whenever sedatives are used, there should be one practitioner present whose sole job is to monitor the patient and assist in any resuscitative measures that become necessary.<sup>9</sup> Continuous monitoring of pulse oximetry and pulse and intermittent documentation of respiratory rate and blood pressure are necessary in all of these patients. We recommend that each institution develop a policy appropriate to its setting using the American Academy of Pediatrics Guidelines for Sedation, the American College of Emergency Physicians Guidelines for Pediatric Sedation, or the American Society of Anesthesiology practice guidelines for nonanesthesiologists.<sup>7,8,10,11</sup> Monitoring of any child who has received a sedative continues until discharge criteria are met. Discharge criteria include an ability to converse at an age-appropriate level, the ability to maintain the airway, stable cardiovascular function, and the ability to sit unaided. Regardless of the agent used, parents should be informed of the type of sedative to be used and potential side effects. Consent should be documented in accordance with hospital, local, and state requirements.

Sedative agents can be administered orally, intranasally, parenterally, rectally, or through inhalation. Table 5-2 lists some commonly used agents and gives dosing recommendations. For each agent that the physician uses, he or she should become familiar with the dose, administration, and side effects. The most common, significant side effect is respiratory depression, although cardiovascular changes also can occur.

Fentanyl is a synthetic opioid agonist 100 times more potent than morphine. It commonly is used in combination with a sedative (e.g., midazolam) for conscious sedation.<sup>12</sup> The benefits of this agent are rapid onset, short duration, and predictability. Fentanyl must be used with caution, especially when combined with another sedative agent, because of an increased risk of respiratory depression. It should be titrated in 1  $\mu\text{g}/\text{kg}$  increments with a maximal dose of 5  $\mu\text{g}/\text{kg}$  over 1 hour. Higher doses administered rapidly can induce chest wall rigidity with impaired ventilation. Morphine and meperidine (Demerol) also are commonly used for analgesia, but because of their longer half-life and their requirement for prolonged monitoring before discharge, these agents are not the first choice for short procedures.

Midazolam is a short-acting benzodiazepine frequently used as a sedative in children.<sup>13</sup> The main attributes of this drug are the provision of effective anxiety reduction and anterograde amnesia, combined with a favorable overall safety profile.<sup>14-16</sup> To help calm a mildly anxious child, midazolam can be administered intravenously, orally, or intranasally. The intranasal route is limited by discomfort of application because of the volume necessary and by a burning sensation. If the intranasal route is chosen, the operator uses the intravenous solution and draws it into a tuberculin syringe; the needle is removed, and with the child supine, the dose is administered in aliquots of two drops per nostril over 2 to 5 minutes. The solution can be irritating to the mucosa, and it is prudent to warn the child and parent of a stinging sensation. Sedation usually occurs within 5 to 10 minutes. Because of a significant and variable first-pass effect, there is considerable variation in the dose required to induce sedation. Oral syrup is available (2 mg/mL) and is given at a dose of 0.25 to 0.5 mg/kg with

TABLE 5-2 Selected Drugs for Sedation and Analgesia

Medication	Recommended Dose	Route of Administration	Additional Instructions
Fentanyl (Sublimaze)	1–3 µg/kg	IV	Titrate slowly (1 µg/kg/min); effect within min; maximal dose 5 µg/kg over 1 hr
Morphine	0.1–0.15 mg/kg	IV	Effect within min; maximal dose 10 mg over 1 hr for opioid-naive patients; 20 mg over 1–2 hr for patient who take opioids often
Midazolam (Versed)	0.1–0.15 mg/kg	IV	Titrate over 3 min to desired effect; effect within 3–5 min; maximal initial dose 5 mg
	0.3–0.5 mg/kg	PO	Add to juice; effect delayed 20–30 min; maximal initial dose 10 mg; may repeat in 30 min if patient not sedated well
	0.2–0.3 mg/kg	IN	Slowly drip into nostrils; effect delayed 5–10 min; maximal dose 10 mg
Diazepam (Valium)	0.2 mg/kg	IM	Effect delayed 10–15 min; maximal dose 8 mg
	0.1–0.2 mg/kg	IV	Titrate over 3 min to desired effect; maximal initial dose 10 mg
Chloral hydrate	50–75 mg/kg	PO, PR	Effect delayed 30–60 min; may repeat an additional 25–50 mg/kg in 30 min if patient not sedated well; maximal dose 100 mg/kg; consider use for noninvasive procedures such as CT, ultrasound, and echocardiogram
<b>Reversal Agents</b>			
Naloxone (Narcan)	0.1 mg/kg, maximal	IV, IM	For opiate reversal (fentanyl, morphine); repeat in 5 min if no effect
Flumazenil (Romazicon)	0.01 mg/kg or 0.2 mg	IV	For benzodiazepine reversal (midazolam, diazepam); repeat 0.2 mg/min up to 1 mg if no effect

CT, computed tomography; IM, intramuscular; IN, intranasal; IV, intravenous; PO, oral; PR, per rectum.

an onset of action of 10 to 30 minutes. The maximal dose is 20 mg. In children 6 months to 6 years old, 1 mg/kg is sometimes necessary. When effective, the child often becomes mildly sedated, and the caregiver and parents can talk with the child through the procedure. Rarely, a paradoxical reaction occurs, and the child can become more agitated and anxious. Chloral hydrate is a mild sedative with an excellent safety record. Its major drawbacks are the relatively long time to onset and long duration of action.<sup>17</sup>

Nitrous oxide in concentrations less than 50% has been used commonly in pediatric dentistry. It is completely painless and has anxiolytic, sedative, and mild analgesic properties. It has been used as an adjunct to local infiltration or nerve block in wound repair.<sup>18</sup> New portable devices have made this modality available to emergency departments. There are some drawbacks, however. The delivery and scavenging systems are expensive, and because of the need for cooperation, nitrous oxide should be used only in children older than 4 years.<sup>19–22</sup> It also has been reported to carry some risk to caregivers.<sup>23</sup> It is unique compared with other methods of sedation in that it is an inhaled agent, and its administration is titrated by the patient, which makes it an effective modality in the emergency department.

Ketamine (4 mg/kg intramuscularly) is a dissociative agent that provides effective sedation without loss of airway reflexes. Its effectiveness and safety have been shown in children in a variety of painful emergency department procedures. Some disadvantages include increased secretions and the possibility of hallucinations (emergent reactions).

Propofol is another agent that is gaining popularity for procedural sedation in children in the emergency department. This drug is classified as a nonopioid, nonbarbiturate, sedative-hypnotic agent.<sup>19</sup> It traditionally has been used in the management of fracture reduction, abscess drainage, wound exploration, and ocular examination after ocular burn.<sup>24</sup> There is limited experience, however, for its use in procedural sedation in children with lacerations. Because of the potential side effects, further study is necessary before routine use can be recommended.

Some drug combinations, such as meperidine, promethazine, and chlorpromazine, have been used for sedation with good results in children.<sup>25</sup> Because this combination is difficult to titrate, and because of the development of other faster and safer agents, many caregivers no longer recommend this combination.

No matter which agent or combination is used, sedation does not imply analgesia, meaning pain control, and a local anesthetic still must be used. The operating room should be considered in children with complex lacerations or medical conditions that could increase the risks involved in conscious sedation. At our institution, we rarely are required to sedate a child with an uncomplicated laceration. We believe this is so because of the frequent use of LET (lidocaine 4%, epinephrine 0.1%, and tetracaine 0.5% solution or gel), which eliminates the pain of injection, and use of distracting techniques and certified child life specialists when available. In cases when conscious sedation is required, we are most comfortable using midazolam, fentanyl, or these agents in combination because of the user's ability to titrate to the desired level of consciousness, or ketamine.

---

## LOCAL ANESTHETIC TECHNIQUES

The area always should be anesthetized before cleansing and irrigation. Wound cleansing is painful, and often the adequacy of anesthesia can be assessed during irrigation. Cleansing and irrigation techniques are the same for children and adults and are described fully in Chapter 7.

Topical anesthetics such as LET are being used more frequently and are as effective as other local anesthetics.<sup>26,27</sup> This preparation provides anesthesia without causing the discomfort associated with an injection and does not distort the local anatomy. Another potential advantage that we have noted is that we need to use physical restraints less often when we use LET. This solution should not be used in areas of end artery flow, such as fingers, toes, and ears. Studies have shown that the application of LET at triage significantly reduces total treatment time for children with simple lacerations.<sup>28</sup>

These topical anesthetics should be used before wound cleansing and repair. The caregiver saturates a small pledget of cotton or piece of gauze that is of similar size to the wound with the solution. The maximal dose is 0.1 mL/kg. Any blood coagulum is removed from the wound. The pledget is placed directly into the wound and can be held in place by a Band-Aid, Tegaderm, or tape or held directly by the parent using gloves to prevent absorption through the fingers. The pledget is left in place for 20 to 25 minutes. The pharmacy also can make a gel preparation of LET. The gel preparation can be placed directly in the wound and covered with a Band-Aid. Effective application usually blanches the skin around the wound. The caregiver should show the parents the blanched skin and its significance. Topical and local anesthetic techniques are discussed further in Chapter 6.

Regional blocks are another useful method of anesthesia for children. They do not distort the anatomy at the site of the injury and may be less traumatic because they often

require one or at most two injections, as opposed to the multiple injections required for local anesthesia. Digital, infraorbital, mental, and supraorbital blocks are probably the most commonly used, although all of the blocks described in Chapter 6 may be used in children.

---

## CHOICE OF CLOSURE MATERIALS

A wide array of suture materials and sizes is available to the practitioner. Personal preferences often determine which material is used. In general, the choice of material to use is the same as described for adults. In children, there are particular situations that may be more amenable to other means of closure. Because suture removal often is fraught with the same anxiety and difficulties as suture application, the use of absorbable suture sometimes is the best option. For nail bed and scalp lacerations, we often use chromic gut. If the sutures still remain at 7 days, we ask the parent to facilitate removal by gently rubbing the material with gauze. This should be done parallel to the wound to minimize the potential for wound dehiscence. Skin staples are a fast, effective method of closing scalp lacerations, especially in an uncooperative child. They have the same cosmetic outcome as standard sutures.

Skin tapes are an alternative method of repair for simple lacerations. The advantage is that they are easy to apply, they leave no marks, and follow-up is not necessary. The tapes are not reliable, however, for infants and young children, who may remove them. Tissue adhesive, although used in Europe and Canada, is not presently available for routine use in the United States. In anticipation of approval of tissue adhesives, closure techniques using these agents are discussed in Chapter 14.

---

## SPECIAL CONSIDERATIONS FOR DIFFERENT ANATOMIC SITES

### Scalp

Careful examination and palpation of the wound is necessary to ensure that there is no skull fracture. If the mechanism of injury is unlikely to cause a fracture or if an adequate examination can be performed, radiographs are not necessary. Further exploration of the wound can be performed when the laceration is anesthetized. Direct observation of the periosteum and skull is frequently possible. Cotton-tipped swabs can be used to assist in probing, especially in smaller lacerations.

Simple, small scalp lacerations that are not grossly contaminated, are not actively bleeding, and have not interrupted the galea may be closed using the hair-tie technique. An adequate length of hair from opposite sides of the wound is necessary. The caregiver twists the hair strands on both sides of the suture line, pulls them across the wound, and knots them (the number of knots should be equal to the number of stitches that normally would have been used in the care of this wound). Postclosure wound care is similar to that of a routine scalp closure. The knot is allowed to grow away from the wound edge and can be cut free in 1 to 2 weeks. As previously noted, chromic gut can be used to close scalp wounds to eliminate the return visit for suture removal.

### Face

An assistant is invaluable and necessary when closing facial wounds in children. The assistant is needed to maintain immobilization, and this is best accomplished if he or she uses firm, consistent pressure, being careful to use the flat surfaces of his or her hands or forearms (see Fig. 5-1) to immobilize the head. Use of fingertips, which causes localized pressure and pain, should be avoided. When closing chin lacerations, firm, consistent pressure can be applied to

keep the jaw closed and minimize “quivering” of the chin. Bandages are difficult to maintain on a toddler’s face or scalp, and the frequent application of an antibiotic ointment is recommended to keep the wound moist and promote healing.

## Hand

Difficulties arise primarily during the evaluation of pediatric hand lacerations. Cooperation for formal nerve and tendon function is difficult to obtain. Young children are unable to follow commands and verbalize the concepts of numbness and paresthesias. Often the practitioner must rely on observation rather than formal testing. The resting position of the extremity should be observed. Is there a consistency to the amount of resting flexion between digits? An extended finger while the others are flexed raises the suspicion of a tendon injury and should prompt further investigation. The clinician should watch for spontaneous movement of the injured part. Does the child withdraw from touch or noxious stimuli? When anesthesia is obtained, does the depth of the wound suggest tendon or nerve involvement?

In children younger than 5 years old, the classic sensory examination is modified. Two methods are available to determine the sensory innervation in the area distal to the wound. The first method is based on the principle that denervated fingers do not sweat. If you run the body of a clean plastic pen along an area with normal innervation, the sweat creates a slight drag. In a denervated area, the pen moves swiftly. Another popular method is the submersion test. Normal skin becomes wrinkled after 20 minutes of being underwater. Denervated skin usually remains smooth.

Frequently the final answer cannot be determined at the initial encounter. Under such circumstances, only the skin should be closed, and serial examinations over the next few days help clarify if there is any nerve or tendon involvement. Consultation with a hand specialist is indicated at this time. Most hand surgeons reevaluate the initial injury within 3 to 5 days. Tendon or neuronal repair can be done within the first 3 weeks after the injury with good results. Fingertip avulsions are common pediatric injuries. These injuries occur in toddlers when windows and doors close on their fingers. Older children are more prone to injuries from sharp objects.

In cases of complete fingertip amputation, several studies have shown superior results when the fingertip is allowed to regenerate on its own.<sup>29-36</sup> The granulation tissue that develops contains neural buds and provides superior sensation compared with a graft. In cases of partial amputation or a flap laceration of the fingertip, the flap may be reattached when blood clots are removed. In most cases, an x-ray is obtained to exclude the presence of a fracture. For a distal tuft fracture, copious irrigation should be followed by the use of prophylactic antibiotics. More proximal, open fractures should be managed in consultation with a hand specialist. In cases in which the laceration involves the nail bed, the same principles described in Chapter 13 should be used. Formal splinting of the injury after repair protects the repair and the injury. The prognosis of these injuries depends on how much of the tip is involved. These injuries may take weeks for complete healing. It is advisable to arrange follow-up with a plastic or an orthopedic surgeon.

## Foot

Foot injuries present the problems and challenges of the injury itself and the difficulties that the injury causes in ambulation. Unless the child is older than 6 to 8 years old, crutches are not recommended because of insufficient motor coordination. Younger children may need to be carried or encouraged to crawl. The clinician should be prepared to commiserate with the stress that this can impose on the family.

Puncture wounds present their own unique controversies. No prospective studies have addressed this common entity. Although some authors recommend routine coring for puncture wounds, we discourage this because coring is uncomfortable, increases local pain, makes ambulation difficult, and does not have proven efficacy.<sup>37</sup> Every puncture wound has the potential to harbor foreign material, however, which increases the risk of infection. Most foreign bodies are not radiodense and are difficult to find on probing. Removal of any organic material or identifiable foreign body is recommended, and opening the wound with a small incision may be necessary in these instances. Chapter 16 discusses plantar puncture wounds further.

Serious complications can occur for puncture wounds through tennis shoes. *Pseudomonas* osteomyelitis has been reported in 4% of these cases.<sup>38</sup> It is our opinion, and most authors agree, that antibiotics are not routinely required after puncture wounds to the feet. If cellulitis develops within the first few days of the injury, antibiotic coverage is needed and is directed toward *Staphylococcus* and *Streptococcus* species. The quinolones that are frequently used in adults are relatively contraindicated in preadolescents because of a concern for inhibition of cartilage growth and development. *Pseudomonas* osteomyelitis should be considered in cases of persistent inflammation despite adequate antistaphylococcal coverage or increasing bone tenderness over time.<sup>38</sup>

### Perineum/Straddle Injuries

Careful and complete examination is necessary when evaluating injuries to the perineum, or straddle injuries. Blunt straddle injuries occur when the perineum strikes a fixed object, such as the crossbar of a bicycle. This mechanism is associated with trauma to the labia and posterior fourchette.<sup>39</sup> If there is a penetrating injury, such as occurs with falling onto a fence post, vaginal injury is more likely.<sup>40</sup> If there is any concern of vaginal lacerations, unexplained bleeding, or lacerations involving the rectum, a complete examination is required.<sup>41</sup> Often the use of general anesthesia and a referral to a subspecialist are necessary. Straddle injuries can be accompanied by trauma to the urethra and concomitant urinary retention.<sup>42</sup> Foley catheterization sometimes is necessary if watchful waiting is unsuccessful. Small superficial labial lacerations can be sutured in the emergency department. Because children are afraid of a stranger manipulating their genitalia, sedation usually is recommended even in small lacerations. Chromic gut or any other appropriate absorbable material is recommended to avoid the stress and anxiety of suture removal.

---

### WOUND AFTERCARE

Wound care after a laceration repair is the same as previously described. Bandages and dressings should be applied but need to be secured adequately because of the child's curiosity. Materials such as Coban may be used, but the clinician should be careful to avoid creating a tourniquet effect. Sutures in general can be removed earlier than is done for the adult. Oral and written discharge instructions are given. Instructions must be clear and concise, indicating possible complications, follow-up care, and timing of suture removal. Written instructions are invaluable because parents often may not recall the details of the instructions when the child is discharged.

Other important issues are related to the psychological well-being of the child. The clinician always should give a reward, such as a sticker. The parents should be encouraged to minimize the stress of the accident by making the event a positive experience and not a punishment. Throughout the encounter, the clinician should try to engage the child, gain his or her confidence, and possibly become a friend. In the end, the clinician is rewarded with a satisfying experience for all involved.

## REFERENCES

1. Chenoweth A: Health problems of infants and children. In Wallace HM, Gold EM, Liss EF, editors: *Maternal and child health practices*, Springfield, Ill, 1973, Charles C. Thomas.
2. Izant RJ, Hubay CA: Annual injury of 15,000,000 children: a limited study of childhood accidental injury and death, *J Trauma* 6:65-74, 1966.
3. Manheimer DI, Dewey J, Mellinger GD, Corsa L: Fifty thousand child-years of accidental injuries, *Public Health Rep* 81:519-533, 1966.
4. Rivara FP, Bergman AB, LoGerfo JF, Weiss, NS: Epidemiology of childhood injuries: II. Sex differences in injury rates, *Am J Dis Child* 136:502-506, 1982.
5. Baker MD, Selbst SM, Lanuti M: Lacerations in urban children, *Am J Dis Child* 144:87-92, 1990.
6. Dixon SD, Stein MT: Encounters with children: pediatric behavior and development, St. Louis, 1992, Mosby.
7. Krebel M, Clayton C, Graham C: Child life programs in the pediatric emergency department, *Pediatr Emerg Care* 12:13-25, 1996.
8. American Academy of Pediatrics: Guidelines for monitoring and management of pediatric patients during and after sedation for diagnostic and therapeutic procedures, *Pediatrics* 89:257-262, 1992.
9. American Society of Anesthesiologists: Practice guidelines for sedation and analgesia by non-anesthesiologists, *Anesthesiology* 84:450-471, 1996.
10. American College of Emergency Physicians: The use of pediatric sedation and analgesia, *Ann Emerg Med* 22:626-627, 1993.
11. Hoffman GM, Nowakowski R, Troshynski TJ: Risk reduction in pediatric procedural sedation by application of an American Academy of Pediatrics/American Society of Anesthesiologists process model, *Pediatrics* 109: 236-243, 2002.
12. Billmire DA, Neale HW, Gregory RO: Use of IV fentanyl in the outpatient treatment of pediatric facial trauma, *J Trauma* 25:1079-1080, 1985.
13. Feld LH, Negus JB, White PF: Oral midazolam preanesthetic medication in pediatric outpatients, *Anesthesiology* 73:831-834, 1990.
14. Diamant MJ, Stanley P: The use of midazolam for sedation of infants and children, *AJR Am J Roentgenol* 150:377-378, 1988.
15. Hennes HM, Wagner V, Bonadio WA, et al: Effect of oral midazolam on anxiety of preschool children during laceration repair, *Ann Emerg Med* 19:1006-1009, 1990.
16. Levine MF, Spahr-Schopfer IA, Hartley E, et al: Oral midazolam premedication in children: the minimum time interval for separation from parents, *Can J Anaesth* 40:726-729, 1993.
17. American Academy of Pediatrics: Use of chloral hydrate for sedation in children, *Pediatrics* 92:471-473, 1992.
18. Gamis AS, Knapp JF, Glenski JA: Nitrous oxide analgesia in a pediatric emergency department, *Ann Emerg Med* 18:177-181, 1989.
19. Dula DJ, Skindzielewski JJ, Snover SW: The Scavenger device for nitrous oxide administration, *Ann Emerg Med* 12:759-762, 1983.
20. Flomenbaum N, Gallagher EJ, Eagen K, et al: Self-administered nitrous oxide: an adjunct analgesic, *J Am Coll Emerg Physicians* 8:95-97, 1979.
21. Griffin GC, Campbell VD, Jones R: Nitrous oxide-oxygen sedation for minor surgery: experience in a pediatric setting, *JAMA* 245:2411-2413, 1981.
22. Stewart RD: Nitrous oxide sedation/analgesia in emergency medicine, *Ann Emerg Med* 14:139-148, 1985.
23. Rowland AS, Baird DD, Weinberg CR, et al: Reduced fertility among women employed as dental assistants exposed to high levels of nitrous oxide, *N Engl J Med* 327:993-997, 1992.
24. Bassett K, Anderson J, Pribble C, Guenther E: Propofol for procedural sedation in children in the emergency department, *Ann Emerg Med* 42:773-782, 2003.
25. Terndrup TE, Cantor RM, Madden CM: Intramuscular meperidine, promethazine, and chlorpromazine: analysis of use and complications in 487 pediatric emergency department patients, *Ann Emerg Med* 18:528-533, 1989.
26. Schilling CG, Bank DE, Borchert BA, et al: Tetracaine, epinephrine and cocaine versus lidocaine, epinephrine and tetracaine for anesthesia of lacerations in children, *Ann Emerg Med* 25:203-208, 1995.
27. Terndrup TE: Pain control, analgesia and sedation. In Barkin RM, editor: *Pediatric emergency medicine: concepts and clinical practice*, St. Louis, 1992, Mosby.
28. Priestley S, Kelly AM, Chow L, Powell C, Williams A: Application of topical local anesthetic at triage reduces treatment time for children with lacerations: a randomized control trial, *Ann Emerg Med* 42:34-40, 2003.
29. Allen MJ: Conservative management of finger tip injuries in adults, *Hand* 12:257, 1980.
30. Ashbell TS, Kleinert HE, Putcha SM, et al: The deformed finger nail, a frequent result of failure to repair nail bed injuries, *J Trauma* 7:177, 1967.
31. Douglas BS: Conservative management of guillotine amputation of the finger in children, *Aust Pediatr J* 8:86, 1972.
32. Farrell RG, Disher WA, Nesland RS, et al: Conservative management of fingertip amputations, *J Am Coll Emerg Physicians* 6:273, 1977.



33. Fox JW, Golden GT, Rodeheaver G, et al: Nonoperative management of fingertip pulp amputation by occlusive dressings, *Am J Surg* 133:255, 1977.
34. Holm A, Zachariae L: Fingertip lesions: an evaluation of conservative treatment versus free skin grafting, *Acta Orthop Scand* 45:382, 1974.
35. Lamont RP, Ciccedro JJ, Frascione RJ, et al: Open treatment of fingertip amputations, *Ann Emerg Med* 12:358, 1983.
36. Louis DS, Palmer AK, Burney RE: Open treatment of digital tip injuries, *JAMA* 244:697, 1980.
37. Fitzgerald R, Cowan J: Puncture wounds of the foot, *Orthop Clin North Am* 6:965-972, 1975.
38. Fischer MC, Goldsmith JF, Gilligan PH: Sneakers as a source of *Pseudomonas aeruginosa* in children with osteomyelitis following puncture wounds, *J Pediatr* 106:607-614, 1985.
39. Bond GR, Dowd MD, Landsman I: Unintentional perineal injury in prepubescent girls: a multicenter, prospective report of 56 girls, *Pediatrics* 95:628-631, 1995.
40. Dowd MD, Fitzmaurice L, Knapp JF, Mooney D: The interpretation of urogenital findings in children with straddle injuries, *J Pediatr Surg* 29:7-10, 1994.
41. Muram D: Genital tract injuries in the prepubertal child, *Pediatr Ann* 15:616, 1986.
42. Levne PM, Gonzalez ET: Genitourinary trauma in children, *Urol Clin North Am* 12:53, 1985.

# Infiltration and Nerve Block Anesthesia

## PHARMACOLOGY OF LOCAL ANESTHETICS

- Mechanism of Blockade
- Onset of Action
- Duration of Anesthesia
- Differential Blockade
- Addition of Epinephrine

## TOXICITY OF LOCAL ANESTHETICS

### ALLERGY TO LOCAL ANESTHETICS

- Management of Allergic Responses
- Alternatives for Allergic Patients

## PATIENT SEDATION

### ANESTHETIC SOLUTIONS

- Lidocaine
- Lidocaine with Epinephrine
- Mepivacaine
- Bupivacaine
- Articaine

## REDUCING THE PAIN OF ANESTHESIA

- Anesthetic Buffering
- Anesthetic Warming
- Choice of Needles

## ANESTHESIA TECHNIQUES

- Topical Anesthesia
- Direct Wound Infiltration
- Parallel Margin Infiltration (Field Block)
- Supraorbital and Supratrochlear Nerve Blocks (Forehead Block)
- Infraorbital Nerve Block
- Mental Nerve Block
- Auricular Block
- Digital Nerve Blocks (Finger and Toe Blocks)
- Median Nerve Block
- Ulnar Nerve Block
- Radial Nerve Block
- Sural and Tibial Nerve Blocks (Sole of Foot Blocks)

**E**ffective anesthesia is essential for successful patient intervention and wound repair. As with any procedure, success depends on a thorough understanding of the properties of anesthetic solutions and injection techniques. The choice of anesthetics and techniques must be individualized for every patient. The type, location, and extent of the wound and estimated length of time for repair are variables that make each patient unique. Besides technical considerations, patients have differing emotional characteristics and responses. Patients often fear that injections and needles will cause excessive pain. A clear explanation of the procedure and gentle handling gain the confidence of the patient and ease any apprehension.

## PHARMACOLOGY OF LOCAL ANESTHETICS

Although the knowledge and science of local anesthetics are extensive, there are characteristics and behaviors of these solutions specific to the wound care setting. These characteristics are described in the following sections: mechanism of blockade, onset of action, duration of anesthesia, differential blockade, and addition of epinephrine.

## Mechanism of Blockade

On injection, local anesthetics infiltrate tissues and diffuse across neural sheaths and membranes. They act by interfering with neural depolarization and transmission of impulses along axons. Prevention of sodium influx across nerve membranes is considered the physiologic basis for impulse conduction blockade. As sodium influx decreases, there is a decrease in the rate of rise in amplitude of the polarization. As a result, there is inadequate formation of action potential, and with no action potential, there is no nerve impulse. Without nerve impulses, anesthesia is achieved.

## Onset of Action

Although onset of action is just one of many physiologic actions of local anesthetics, it is important to a busy emergency physician because the saving of even a few minutes can contribute to the overall effectiveness of that physician in a hectic emergency department. The onset of action is influenced by technique of injection; concentration of the solution; nerve fiber diameter; total dose; the addition of epinephrine; pH manipulations; and physiochemical determinants, such as  $pK_a$ , lipid solubility, and protein binding. Local infiltration of a laceration brings on rapid anesthesia. If the anesthetic is delivered at the interface of the superficial fascia and dermis, nerve fibers are vulnerable to immediate blockade. Wound cleansing and suturing can begin almost immediately. A slightly shorter onset of action is yielded by 2% solutions than by 1% solutions, but clinically speaking, this effect is negligible.<sup>1</sup> The addition of epinephrine and the buffering of local anesthetics also can shorten the onset of action and are discussed later in this chapter.

When blocking larger nerve trunks, such as digital nerves, onset of action is significantly slower. Technique of delivery is crucial, and knowledge of anatomy can mean the difference between a successful and an unsuccessful blockade. A bolus of local anesthetic delivered immediately adjacent to a digital nerve can lead to complete digital anesthesia within 1 to 2 minutes. Poor technique and delivery of that bolus even 2 or 3 mm from the nerve trunk can delay onset of action or lead to inadequate blockade and the need for repeat injection.

The two most commonly used wound care anesthetics, lidocaine (Xylocaine 1% and 2%, with and without epinephrine) and mepivacaine (Carbocaine 1% and 2%), have similar physiochemical profiles with similar onsets of action. Bupivacaine (Marcaine 0.25% and 0.5%) has physiochemical properties that delay onset of action but in return provides much greater duration of action than does lidocaine or mepivacaine.

## Duration of Anesthesia

Protein binding of local anesthetic solutions is the primary determinant of duration of action. Bupivacaine, which is 95% protein bound, remains in the sodium channel longer than lidocaine (64% bound) and mepivacaine (78% bound). Duration of action is significantly affected by vasoactivity of the anesthetic, blood supply of the region anesthetized, and addition of epinephrine to anesthetic solutions. Of the commonly used anesthetics, lidocaine produces the most vasodilation. The duration of action can be significantly shortened in areas such as the face. In addition, vasodilation can cause excessive bleeding in a wound during repair. The addition of epinephrine to lidocaine eliminates unwanted bleeding and extends the action of lidocaine by 1 hour for facial lacerations and 5 hours for extremity injuries.<sup>2</sup> Bupivacaine without epinephrine also extends the duration of action 2 to 4 hours compared with lidocaine alone.

## Differential Blockade

Myelin sheath coverings of nerve fibers within axons vary in diameter and thickness. Fibers that carry stimuli from pain receptors in the skin have no myelin sheath and have the smallest diameter. The sensations of pressure and touch and motor impulses are transmitted

by larger, myelinated fibers. The thin pain fibers are blocked more rapidly and easily by local anesthetic solutions. This fact is significant in wound care because a solution of 1% lidocaine might block pain stimuli only and not the sensation of touch and pressure. An overly anxious patient may react to touch and pressure as if it were pain. A higher concentration of lidocaine or mepivacaine (e.g., 2%) abolishes all awareness of stimuli and allows for unimpeded repair. Adding epinephrine to these solutions achieves the same effect.

### Addition of Epinephrine

Adding epinephrine to local anesthetic solutions increases the duration of action and the amount of drug that can be used. Epinephrine not only extends the duration of action of lidocaine, but also it increases the intensity of the block without an increase in concentration of the anesthetic in the neuron.<sup>3</sup> The extended action lasts 1.3 times to 10 times longer than the action of lidocaine alone.<sup>2</sup> The extension of time is shorter on the face than on other body locales. The most useful property of epinephrine is to decrease the amount of bleeding in a wound during laceration repair. There are potential but infrequent complications to its use. The most serious side effect, ischemia, can occur if epinephrine-containing anesthetics are improperly injected into fingers, toes, tip of the nose, pinna of the ear, or penis. In susceptible patients, palpitations and tremors can occur. Because the concentrations used are low (1:100,000 or 1:200,000) and the amounts small, risk is limited. Aspiration before injection is crucial when using anesthetic solutions with epinephrine to avoid the potential serious consequences of direct intravascular bolusing. Known coronary artery disease and hypertension are relative contraindications to the use of these solutions.

---

## TOXICITY OF LOCAL ANESTHETICS

The injection of local anesthetics can cause three toxic reactions: cardiovascular reactions, excitatory central nervous system effects, and vasovagal syncope secondary to pain and anxiety. Cardiovascular reactions include hypotension and bradycardia and are caused by a myocardial inhibitory effect of the anesthetic.<sup>4</sup> Local anesthetic solutions can cause excitatory phenomena in the central nervous system that ultimately can culminate in seizure activity. The cardiovascular and central nervous system effects commonly are caused by an inadvertent injection of a solution directly into a vessel, causing a bolus effect on the heart or brain. A key principle in the use of local anesthetics is always aspiration of the syringe before injection to check for blood return. If blood is aspirated, the needle has to be moved to avoid injecting the solution into a vein or artery.

The most common reaction to local anesthetics is vasovagal syncope (fainting). The anxiety and pain of injection can cause dizziness, pallor, bradycardia, and hypotension. This reaction can largely be avoided with gentle handling of the patient, proper counseling, and slow and careful injection technique. No anesthetic infiltration is ever carried out on a patient who is not in the supine position. Preferably the patient should be placed so that he or she cannot see the injection being administered. Local complications to anesthetic infiltration are unusual but can include infection, hematoma formation, and, potentially, permanent nerve damage to peripheral nerves anesthetized during block procedures.

Treatment of toxic reactions is largely supportive. The airway is appropriately protected, and ventilations are maintained. Hypotension and bradycardia usually are self-limited and can be reversed by placing the patient in the Trendelenburg position. An intravenous line is started with normal saline, and a bolus of 250 to 500 mL is infused to counteract hypotension in any patient who does not respond to that maneuver. Cardiac monitoring with frequent vital signs is instituted. Seizures also are self-limited but may need to be controlled by intravenous diazepam (Valium).

---

## ALLERGY TO LOCAL ANESTHETICS

Allergic reactions are uncommon with the newer amide local anesthetics, such as lidocaine, mepivacaine, and bupivacaine. Reactions were more frequent with the older ester solutions, procaine (Novocain) and tetracaine.<sup>5</sup> Multiple-dose vials still contain the preservative methylparaben, which has been implicated as a possible mediator of allergic responses.<sup>1</sup> Allergic reactions are characterized by either delayed appearances of skin rashes or the acute onset of localized or general urticaria. Rarely, outright anaphylactic shock can occur. True allergic responses occur in less than 1% of patients receiving local anesthetics.<sup>5</sup> This observation was confirmed in a study of 59 patients who reported prior reactions to local anesthetic agents. None responded adversely to skin testing and provocative drug challenge.<sup>6</sup>

### Management of Allergic Responses

Allergic responses are managed in the standard manner with airway control; establishment of intravenous access; and administration of epinephrine, diphenhydramine, and steroids as needed.

### Alternatives for Allergic Patients

Because patients cannot always describe accurately a prior adverse reaction to a local anesthetic and it is usually impossible to perform skin testing in an emergency department setting, the clinician may be faced with a patient who is truly allergic to local anesthetics. The following strategies are suggested:

- For calm patients who have small lacerations, no anesthetic should be used. Often the pain of injection exceeds the pain of placing two or three sutures.
- Ice placed directly over the wound can provide a short period of decreased pain sensation.
- Because the preservative methylparaben has been implicated in allergic reactions, local anesthetic preparations for spinal, epidural, and intravenous anesthesia should be used. They are preservative-free. They can be obtained from the operating room of the hospital.
- If the allergy-causing drug can be identified as an ester (tetracaine, benzocaine, chlorprocaine, cocaine, procaine), it can be substituted with an amide (lidocaine, mepivacaine, bupivacaine, diphenhydramine [Benadryl]).
- Diphenhydramine has similar properties to standard local anesthetics.<sup>7</sup> Compared with lidocaine, it provides adequate anesthesia for laceration repair for at least 30 minutes.<sup>8</sup> Compared with lidocaine, it is not as effective for procedures longer than 30 minutes. A 50-mg (1-mL) vial is diluted in a syringe with 4 mL of normal saline to produce a 1% solution. Local infiltration is carried out in the usual manner. Diphenhydramine is more painful to inject than lidocaine, and this pain is not reduced by buffering.<sup>9,10</sup>

---

## PATIENT SEDATION

Patient sedation for emergency procedures has become a common strategy in the emergency department. Wound care can cause significant anxiety and discomfort, and patients can benefit by the administration of anxiolytics or pain relievers that supplement local anesthesia. Opiates, such as fentanyl and meperidine (Demerol), and the benzodiazepines, midazolam and diazepam, can be delivered orally or parenterally for this purpose. They also can be given in combination for good effect. Other sedative agents that have been studied in this setting include nitrous

TABLE 6-1 *Agents for Sedation in Wound Care Procedures*

Agent(s)	Initial Dose*	Route
Midazolam	0.03–0.05 mg/kg	IV
	0.2–0.3 mg/kg	Intranasal <sup>†</sup>
	0.3–0.5 mg/kg	Oral
Diazepam	0.05–0.10 mg/kg	IV
Fentanyl	0.5–1.0 µg/kg	IV
	20–25 µg/kg	Oral transmucosal <sup>†</sup>
Meperidine	1–2 mg/kg	IV, IM
DPT <sup>‡</sup>	2:1:1 mg/kg (maximum 50:25:25 mg in children)	IM <sup>†</sup>

\*Often two doses are needed to obtain adequate sedation in many patients. The use of additional doses should be based on individual responses. In the elderly, smaller doses should be used in an incremental fashion.

<sup>†</sup>Suggested for pediatric sedation and analgesia.

<sup>‡</sup>Demerol (meperidine)/Phenergan (promethazine)/Thorazine (chlorpromazine).

IV, intravenous; IM, intramuscular.

From Yealy DM, Dunmire SM, Paris PM: Pharmacologic adjuncts to painful procedures. In Roberts TR, Hedges TR, editors: Clinical procedures in emergency medicine, Philadelphia, 1991, Saunders.

oxide; ketamine; and the combination “cocktail” of meperidine, promethazine (Phenergan), and chlorpromazine (Thorazine). Commonly used sedative agents are summarized in Table 6-1.

Midazolam is an effective anxiolytic that comes in oral, intranasal, parenteral, and rectal forms.<sup>11-13</sup> Intravenously, it achieves sedation in 3 to 5 minutes and has an elimination half-life of 1 hour. Alone or in combination with fentanyl, it has become a commonly used emergency department sedative. When midazolam is administered intranasally, orally, or rectally, the onset of action is slower and the elimination half-life is longer. Because of midazolam’s bitter taste, it becomes more acceptable when mixed with fruit juice. Intranasally, it can cause a burning sensation. Hypoxia and oversedation are the most significant, but uncommon, side effects. Administration must be in a controlled setting with readily available airway and resuscitation equipment. The reversal agent, flumazenil, is effective if needed to reverse the actions of this benzodiazepine.

Fentanyl is a synthetic opioid with properties that make it an excellent agent for immediate pain relief and support invasive procedures.<sup>14</sup> Peak effect after intravenous administration is 2 minutes with a duration of action of 30 to 90 minutes. In contrast to other opioids, fentanyl does not commonly cause nausea and vomiting (<1% of patients). Its most serious side effect is respiratory depression, which can be reversed readily with naloxone.

The response to sedation varies between adults and children. Adults can tolerate midazolam and fentanyl in combination with excellent results. In children, the addition of fentanyl to midazolam has been shown to cause increased side effects, however, without improving the response to pain.<sup>15</sup> See Chapter 5 for sedation techniques for children.

A well-studied sedation method commonly used since the 1950s is the combination of meperidine, promethazine, and chlorpromazine.<sup>16</sup> Onset of action after intramuscular administration is approximately 30 minutes with a duration of action of 1.5 to 2 hours. Serious complications, such as hypoxia, are uncommon, but vomiting can occur in 10% to 15% of patients. Full recovery (i.e., back to normal activity) averages almost 20 hours.<sup>16</sup> The newer, shorter-acting agents have effectively replaced this drug combination.

Although ketamine has been in use for years to sedate pediatric patients for invasive procedures, there is less experience in its use in the emergency department.<sup>14</sup> Most experience with ketamine use is in the intravenous or intramuscular form. This drug can cause a dissociative reaction in the patient during administration and an emergence reaction in which there is misperception of visual and auditory stimuli by the patient. Ketamine has been studied more recently in its oral form in patients requiring laceration repair.<sup>17</sup> Significant anxiety reduction and sedation were noted without the occurrence of major side effects. Minor side effects occur in 26% of patients, however. Parenteral ketamine requires significant experience and operator comfort with its sedation profile. Further studies of its oral use in wound care are needed to delineate fully its appropriate use in that setting.

Nitrous oxide is a sedative and an analgesic substance that can provide effective procedure sedation. Equipment requirements and operator experience make this method of sedation of limited usefulness in laceration repair and wound care.

The "best" sedative for anxious and frightened patients, particularly children, is an empathic, calm, and sensitive approach resulting from experience. Most patients, if handled appropriately, can overcome their anxiety and cooperate with laceration repair and minor wound care. Active sedation has its place for complex and painful procedures, but the style and demeanor of the physician or nurse cannot be overemphasized.

Techniques, agents, and doses for sedation of children are discussed in Chapter 5. Conscious sedation for adults is summarized in Box 6-1.

---

## ANESTHETIC SOLUTIONS

Three anesthetic solutions are commonly used for local infiltration and simple nerve block (Table 6-2): lidocaine, mepivacaine, and bupivacaine. The amide derivatives have largely replaced the older ester compounds such as procaine.

### Lidocaine

Lidocaine is the most commonly used anesthetic solution. The drug has a rapid onset of action that is almost immediate in local infiltration. Lidocaine's tissue-spreading properties are good, and it readily penetrates nerve sheaths. Duration of action for nerve blocks is approximately 75 minutes (range 60 to 120 minutes). Although there is no clear information in the literature concerning the duration of action for direct wound infiltration, the anesthetic effect seems to wear off much sooner, in approximately 20 to 30 minutes. A small group of patients seem to metabolize lidocaine rapidly and require repeated local injections.

### Lidocaine with Epinephrine

With the addition of epinephrine 1:100,000, the duration of action is increased and local hemostasis is better achieved. The maximal allowable doses of lidocaine and the other local anesthetics are summarized in Table 6-2. The addition of epinephrine increases the duration of action and reduces bleeding. It is effective for most laceration repairs and foreign-body retrievals. I have found it the most useful anesthetic combination for common wound care problems requiring a local anesthetic. Anesthetics with epinephrine are contraindicated in anatomic areas with terminal circulation, such as the fingers, toes, ears, and nose. In a study comparing lidocaine 2% with and without epinephrine for digital blocks, there were no ill effects of vasoconstriction and the anesthesia was more effective in the epinephrine group.<sup>18</sup> Although one study should not lead to elimination of a time-honored caution against the use of epinephrine in digital blocks, it does open the question to further investigation.

## BOX 6-1

**Procedure for Conscious Sedation in Painful Wound Care and Abscess Drainage Interventions**

1. Establish an intravenous infusion of normal saline (18G catheter preferred in adults) in the supine patient with the bed rails in the up position.
2. Pulse, respiratory rate, blood pressure, and level of consciousness should be recorded initially, *after every dose of each agent, and every 5 to 10 minutes throughout the procedure.*
3. Continuous monitoring of oxygen saturation with a pulse oximeter probe (to maintain at >95% or no less than 3% to 5% less than the initial value) must be performed. Supplemental oxygen via nasal prongs can be administered based on need. ECG monitoring is optional but suggested in the elderly or patients with a cardiac history.
4. A resuscitation cart with a bag-valve mask, oral and nasal airways, endotracheal tubes, and a functioning laryngoscope must be nearby. Suction equipment and naloxone should be at the bedside.
5. Administer 1 mg of midazolam over 30 to 60 seconds; if after 3 to 5 minutes there is no evidence of mild sedation (subjective relaxation by the patient with mild drowsiness and normal or minimally altered speech), additional 1-mg doses can be administered in a similar fashion, up to a maximum of 0.1 mg/kg.\* The goal is *mild sedation and anxiolysis*, achievable in most patients with 1 to 2 mg of midazolam.
6. Reassess clinical status (see 2).
7. Administer fentanyl† 100 µg (2 mL) over 60 seconds; this may be repeated in 0.5 to 1 µg/kg (50 to 100 µg) increments every 3 to 5 minutes until adequate analgesia and sedation have been obtained (slurred speech, ptosis, drowsy, but responsive to painful and verbal stimuli, and good analgesia with initial stages of procedure). The maximal total dose recommended is 5 to 6 µg/kg.\*
8. Administer local anesthesia if indicated (this often helps gauge effectiveness of systemic analgesia).
9. Perform the procedure. Additional doses of fentanyl may be required based on the response and length of the procedure.
10. If hypoxemia, deep sedation, or slowed respirations unresponsive to external stimuli are seen during or after procedure, ventilation should be assisted with a bag-valve mask, and naloxone (0.4- to 0.8-mg increments) should be administered. Naloxone should not be given routinely at the termination of procedures because it abruptly reverses all analgesia.
11. Continue close observation until the patient is awake and alert, and discharge the patient only after a minimum 1 hour of further observation. Instruct the patient not to drive or operate dangerous machinery for at least 6 hours.

From Yealy DM, Dunmire SM, Paris TML: Pharmacologic adjuncts to painful procedures. In Roberts TR, Hedges TR, editors: *Clinical procedures in emergency medicine*, Philadelphia, 1991, Saunders.

\*For children, fentanyl alone is suggested in 0.5-µg/kg increments up to a maximal total dose of 2 to 3 µg/kg.

†Sublimaze, 50 µg/mL.

**Mepivacaine**

Mepivacaine is widely used as an emergency wound anesthetic but has some properties that are different from lidocaine. The drug has a slightly slower onset of action: 6 to 10 minutes for a simple block. The duration of action is 30 to 60 minutes, longer than lidocaine. Mepivacaine has less of a vasodilatory effect than lidocaine and usually does not require the use of epinephrine for local wound area hemostasis.

**Bupivacaine**

Bupivacaine is an amide that is becoming more widely used in emergency wound care. It is an effective anesthetic, but its chief drawback is that it has slow onset of action, approximately



TABLE 6-2 *Local Anesthetics for Wound Care*

Agent	Concentration	Infiltration	Onset of Action		
			Block (min)	Duration of Action for Blocks (min)	Maximal Allowable Single Dose
Lidocaine (Xylocaine)	1%, 2%	Immediate	4-10	30-120	4.5 mg/kg of 1% (30 mL per average adult)
Lidocaine with epinephrine	1%	Immediate	4-10	60-240	7 mg/kg of 1% (50 mL per average adult)
Mepivacaine (Carbocaine)	1%, 2%	Immediate	6-10	90-180	5 mg/kg or 1% (40 mL per average adult)
Bupivacaine (Marcaine, Sensorcaine)	0.25%, 0.5%	Slower	8-12	240-480	3 mg/kg of 0.25% (70 mL per average adult)
Topical anesthesia	See text	5-15 min	—	20-30	2-5 mL of mixture

8 to 12 minutes for simple blocks of small nerves. The main advantage of bupivacaine is its duration of action, which is considerably longer than lidocaine and mepivacaine. In a study comparing lidocaine with bupivacaine, no significant difference was noted in the pain of local infiltration, onset of action, and level of satisfactory anesthesia.<sup>19</sup> Because the anesthetic effects of bupivacaine lasted four times longer than those of lidocaine and significantly extended the period of pain relief, bupivacaine was recommended by the authors to be considered for anesthesia of lacerations sutured in the emergency department.

### Articaine

Articaine hydrochloride 4% (Septocaine) is an amide local anesthetic that has been used in Europe and other parts of the world for years but has been approved for use in the United States only more recently. The only preparation available contains 1:100,000 epinephrine. Articaine is particularly effective in dental procedures because of its ability to penetrate hard tissues such as bone. It has yet to be studied for nondental procedures but can be used for facial and oral blocks. Onset of action is 1 to 6 minutes and the duration of action is approximately 1 hour. Its safety profile is similar to other local caine anesthetics.<sup>20</sup>

## REDUCING THE PAIN OF ANESTHESIA

### Anesthetic Buffering

Local anesthetic solutions are maintained at an acidic pH to ensure stability of the preparation and solubility. The low pH decreases the concentration of nonionized anesthetic, which is contrary to its mechanism of action. As a consequence, injection of unbuffered local anesthetic causes significant discomfort to the patient, and the solution has to undergo a pH change in the tissues to effect blockade.

It makes physiologic sense to add bicarbonate to local anesthetic solutions to reduce the pain of injection, and there are ample studies to support this practice.<sup>21-23</sup> In addition, buffering reduces the time to onset of anesthesia and increases the intensity of the blockade. Buffering does reduce the shelf life of local anesthetics, however, and the excessive addition of bicarbonate can cause visible precipitation within the anesthetic vials. It seems that

lidocaine alone when buffered with bicarbonate has a shelf life of at least 7 days.<sup>24</sup> Buffering also has been shown to degrade epinephrine, up to 20% of the total, within 24 hours in open containers exposed to light.<sup>25,26</sup> Buffered solutions containing epinephrine do not show any significant epinephrine degradation in a 72-hour period if kept in a closed container that is stored in the dark. Shelf life studies of buffered mepivacaine and bupivacaine have not been done.

The following techniques are recommended for the buffering of local anesthetics:

- *Lidocaine*: 1 mL of bicarbonate per 9 mL of 1% lidocaine; buffering of 2% solutions may cause precipitates; shelf life 7 days
- *Mepivacaine*: 0.5 to 1 mL of bicarbonate per 9 mL of mepivacaine; shelf life unknown after 24 hours
- *Bupivacaine*: 0.1 mL of bicarbonate per 20 mL of bupivacaine; shelf life unknown after 24 hours

When mixing a 20-mL lidocaine or mepivacaine vial, 2 mL of anesthetic is removed and replaced with 2 mL of bicarbonate. This technique not only ensures the correct buffering mixture, but also maintains the original volume of solution in the vial. Because shelf life is shortened, the vial should be marked or labeled with the date of preparation.

Bicarbonate is available in solutions of 8.4% sodium bicarbonate stored as 50 mEq/50 mL (1 mEq/mL). Multidose vials of this preparation are available. An easily available supply of bicarbonate, although an expensive and inefficient use of this preparation, is the standard 50-mL 8.4% sodium bicarbonate Abboject syringe used during major patient resuscitations.

### Anesthetic Warming

The warming of local anesthetics has not been shown conclusively to reduce the pain of anesthetic injection. Some investigators have reported a benefit, but others have not.<sup>25,27</sup> The added effort of warming either vials or syringes of anesthetic to 37°C to 40°C and rapidly injecting the solution before cooling might not add real value to the care of the patient.

### Choice of Needles

Experienced operators doing wound care often limit themselves to 27G or 30G needles. Not only is a small gauge likely to reduce the pain of needle insertion, but also it reduces the rate of injection. Rapid injection and tissue expansion is significantly more painful than slow injection.<sup>25</sup>

Considerable experience is necessary in handling small-diameter needles. They bend easily, and it can be difficult to judge the amount of anesthetic injected without observing plunger movement past the syringe hatch marks. It is recommended that inexperienced operators become familiar with the properties of a 25G needle before proceeding to smaller 27G and 30G needles. A 25G, 1½-inch needle can be used for most local infiltration procedures and facial and digital blocks.

---

## ANESTHESIA TECHNIQUES

Most minor lacerations and wounds can be managed by administering a local anesthetic directly into or around (parallel to) the wound area. Other wounds are best served by the application of a nerve block. The following are descriptions of the techniques for administering local anesthetics most useful in emergency wound and laceration repair.

### Topical Anesthesia

#### Indications

Topical anesthesia is an established method to anesthetize uncomplicated lacerations.<sup>5</sup> Pediatric patients are ideal candidates for this technique. It requires no injection and can be administered by the parent. Because of the profuse vascularity of the face and scalp,

lacerations of those areas are more effectively anesthetized than the trunk or proximal extremities. Because of tissue absorption of topical agents, this technique is best limited to lacerations of 5 cm or less. Contraindicated sites include the finger, toe, nose, pinna of the ear, and penis. Care is taken to avoid mucous membranes. The death of a 7½-month-old infant whose nasal mucous membranes and lips were inadvertently exposed to 10 mL of the solution underscores the need to be cautious.<sup>28</sup>

Experimentally, TAC (tetracaine-adrenaline-cocaine) has been associated with a higher potential for wound infection.<sup>29</sup> In a study of 158 primarily pediatric patients, however, this potential for increased infection was not observed when TAC was compared with local needle infiltration.<sup>30</sup>

In emergency departments with triage systems, topical anesthesia can shorten the patient's emergency department length of stay and improve the efficiency of care. Topical anesthetics can be applied at the triage for appropriate wounds.<sup>31</sup> Wounds can be cleansed and repaired in a shortened time frame with good outcomes and improved patient satisfaction.

Numerous topical anesthetic mixtures have comparable efficacy. They can be divided into solutions that do or do not contain cocaine. This ingredient increases the cost and raises issues of storage and handling. Because cocaine was one of the original components of TAC and this preparation has proven efficacy, it remains in use, but preparations without cocaine are comparable in their effectiveness and are gaining favor with practitioners. Topical anesthetics are commonly prepared as liquids but can be mixed in gels.<sup>32</sup> Gels can decrease the risk of mucosal exposure and possibly reduce the total dose delivered. The following is a range of topical anesthetic alternatives:

- *TAC*: The original preparation contains tetracaine (0.5%), epinephrine (1:2000 concentration), and cocaine (11.8%)
- *TAC, ½ strength*: Tetracaine (1%), epinephrine (1:2000), and cocaine (4%)<sup>33</sup>
- *TAC, ¼ strength*: Tetracaine (0.25%), epinephrine (1:4000), and cocaine (5.9%)<sup>34</sup>
- *LAT (lidocaine-adrenaline-tetracaine)*: Tetracaine (1%), epinephrine (1:2000), and lidocaine (4%)<sup>35</sup>
- *TLE (topical lidocaine-epinephrine)*: Lidocaine (5%) and epinephrine (1:2000)<sup>36</sup>

These figures represent the final concentrations and dilutions when calculated amounts of each ingredient are combined and brought to a predetermined volume with saline. Preparation of a topical anesthetic solution should be carried out by or under the supervision of a pharmacist.

### Technique

A 2 × 2 inch sponge is saturated but should not be dripping with solution. The sponge is placed in and around the laceration and left for at least 20 minutes. Shorter application times are associated with higher failure rates. When the sponge is fashioned to conform to the wound, it can be secured with tape, and the caregiver or parent should apply gentle manual pressure over the taped sponge. Gloves are recommended to prevent absorption by the caregiver. Common errors include failure to place a sponge fold into the wound, "dabbing" the wound, or releasing the manual pressure prematurely. For small lacerations, cotton swabs soaked with the solution can be used.

Complete anesthesia is reached when a zone of blanching is observed around the wound. The maximal dose of the solution is 2 to 5 mL. The average wound requires 2 to 3 mL. In approximately 5% of wounds, supplemental infiltration is required to achieve complete anesthesia.<sup>34</sup>

### Direct Wound Infiltration

#### Indications

Direct infiltration through the wound is indicated for most minimally contaminated lacerations in anatomically uncomplicated areas. Injecting directly into the wound is technically

easy to do, and because intact skin is not pierced, needle-stick pain is less. Some patients may express concern, or even alarm, at this prospect. Explaining the advantage of less pain allays those fears.

### Anatomy

The proper plane of injection is immediately beneath the dermis at the junction of the superficial fascia (Fig. 6-1). Tissue resistance is less in this plane, and sensory nerves are reached easily by the spreading solution. Trying to inject directly into the dermis meets with great resistance. Injecting deep down into the fatty fascia unnecessarily delays onset.

### Technique

Direct infiltration can be carried out with 25G, 27G, or 30G needles of varying lengths ( $\frac{1}{2}$  inch to  $1\frac{1}{4}$  inches). The needle is inserted through the open wound into the superficial fascia (subcutaneous fat) parallel to and just deep to the dermis (Fig. 6-2). A small bolus of anesthetic solution is injected. The needle is removed, and another bolus is injected at an adjacent site just inside the margin of anesthesia of the previous injection. This practice ensures greater patient comfort. This process is repeated until all edges and corners of the wound are anesthetized. A simple laceration approximately 3 to 4 cm in length requires 3 to 5 mL of an anesthetic solution.

### Parallel Margin Infiltration (Field Block)

#### Indications

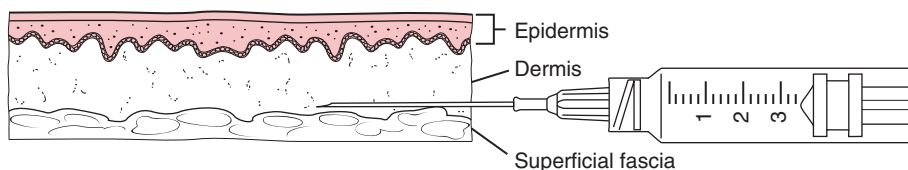
Parallel margin infiltration is an alternative to direct wound infiltration and has the advantage of requiring fewer needle sticks. It is preferred in wounds that are grossly contaminated so that the needle does not inadvertently carry debris or bacteria into uncontaminated tissues, although this potential complication has not been clearly documented.

#### Anatomy

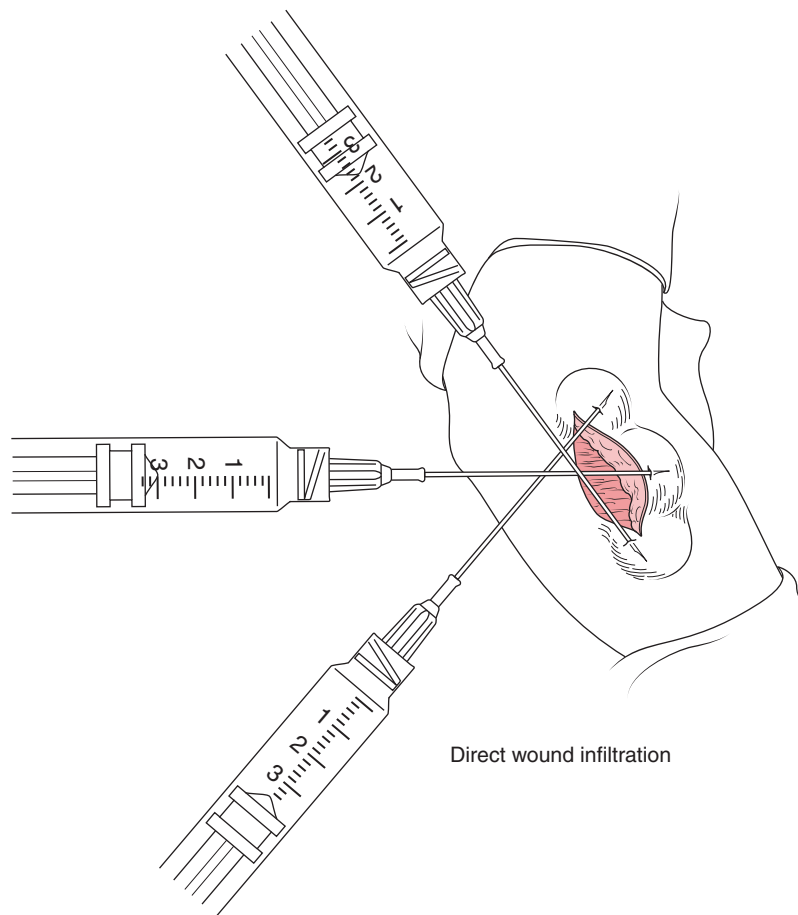
The same plane as described earlier for direct wound infiltration is used, but it is approached through intact skin.

#### Technique

Parallel infiltration requires a  $1\frac{1}{4}$ - to 2-inch needle at least 25G in diameter. The needle is inserted into the skin at one end of the laceration. The needle is advanced to the hub parallel to the dermis–superficial fascia plane (Fig. 6-3). Aspiration is followed by slow injection of a “track” of anesthetic as the needle is withdrawn down the tissue plane to the insertion site. The needle is reinserted at the distal end of the first track, where the skin is beginning to become anesthetized. The second insertion (if needed) is less painful. Reinsertion and injection are repeated on all sides of the wound until complete infiltration has been achieved.



**Figure 6-1** The plane of anesthesia for local skin infiltration is just below the dermis at the junction of the superficial fascia (subcutaneous tissue).



**Figure 6-2** Direct infiltration of the wound is accomplished by multiple adjacent depositions of anesthetic solution to anesthetize the full length of the wound on either side.

### **Supraorbital and Supratrochlear Nerve Blocks (Forehead Block)**

#### **Indications**

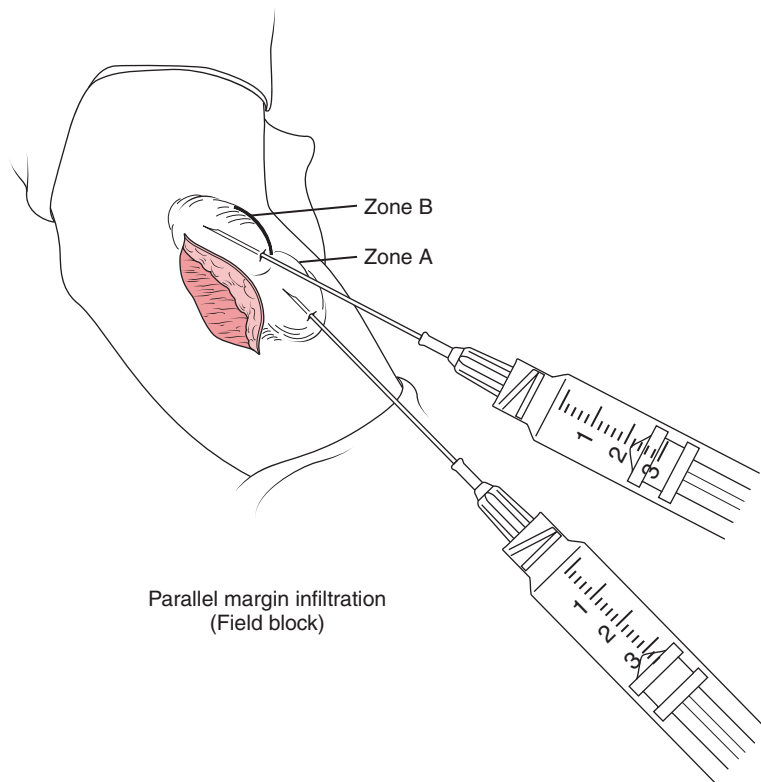
Supraorbital and supratrochlear nerve blocks are used for extensive lacerations and wounds of the forehead and anterior scalp.

#### **Anatomy**

The supraorbital and supratrochlear nerves supply sensation to the forehead and anterior scalp and exit from foramina located along the supraorbital ridge (Fig. 6-4).

#### **Technique**

The easiest manner to block the nerves and their many branches is to lay a continuous subcutaneous track at brow level as shown in Fig. 6-5. The actual injection technique is similar to that discussed earlier in the section on parallel margin infiltration. The plane of injection is just superficial to the bony plane. The needle is inserted to bone, then advanced until the



**Figure 6-3** Parallel margin infiltration is accomplished by laying down adjacent tracks of anesthesia parallel to the wounded edge. Zone A represents the first track. The second track is begun by inserting the needle at the end point of zone A in an area that is anesthetized.

hub is reached. The track laid down floods the nerves as they exit the foramina in the supra-orbital rim.

### **Infraorbital Nerve Block**

#### *Indications*

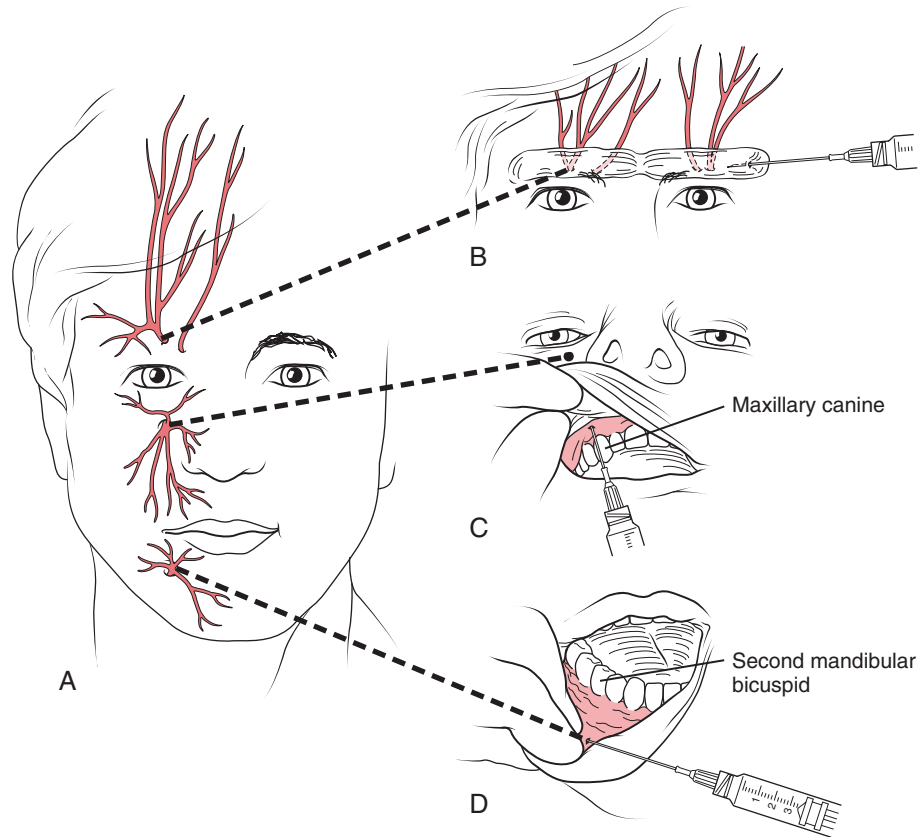
Lacerations of the upper lip are common. Local anesthetic infiltration can cause anatomic distortion leading to difficulty with exact wound edge approximation and repair. An infra-orbital nerve block can circumvent this problem. This block also can be used to repair lacerations of the lateral-inferior portion of the nose and lower eyelid.

#### *Anatomy*

The location and distribution of the infraorbital nerve is illustrated in Figure 6-4A. The infra-orbital foramen is located approximately 1.5 cm below the inferior rim of the orbit and 2 cm from the lateral edge of the nose. This foramen can often be palpated (Fig. 6-6A).

#### *Technique*

The infraorbital nerve can be approached intraorally and extraorally, although the intraoral route has been shown to be significantly less painful. By the intraoral route, the upper lip is



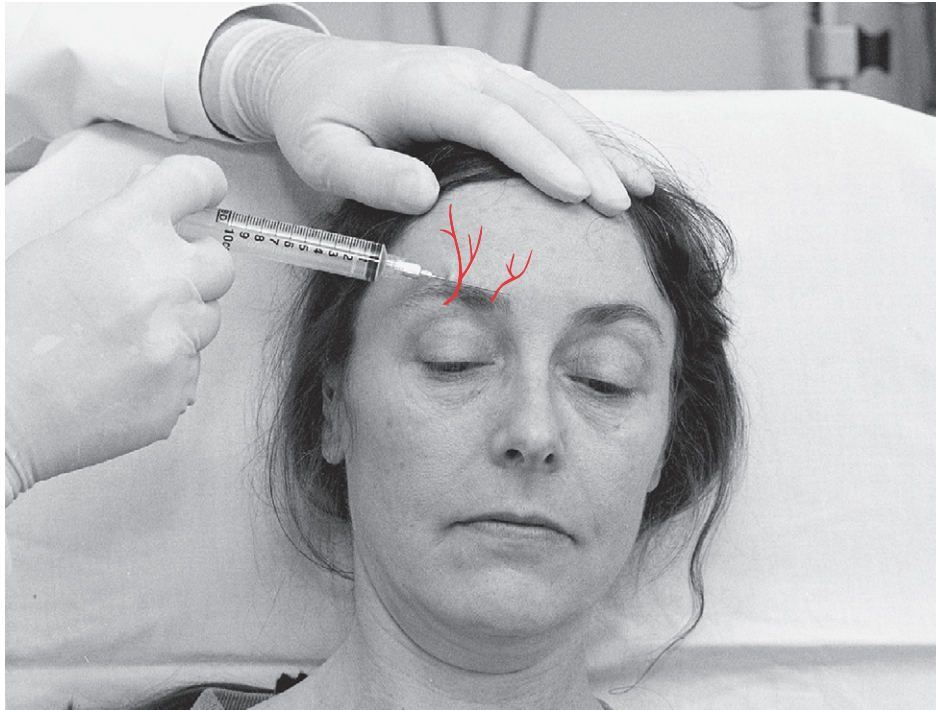**Figure 6-4** A, Position and course of the supraorbital, supratrochlear, infraorbital, and mental nerves. B, Technique for deposition of anesthesia to accomplish a supratrochlear and supraorbital (forehead) nerve block. C, Intraoral technique to anesthetize the infraorbital nerve. D, Intraoral technique to anesthetize the mental nerve.

retracted, revealing the maxillary canine tooth. Before actual injection, the site of needle entry into the buccal mucosa can be pretreated with a topical anesthetic such as viscous lidocaine (Xylocaine Viscous). A cotton-tipped applicator soaked in this solution is applied to the gingival-buccal margin for 1 to 2 minutes before the insertion of the needle (Fig. 6-6B). The needle is introduced at the gingival-buccal margin at the anterior margin of the maxillary canine (Fig. 6-6C). It is advanced parallel and just superficial to the maxillary bone until the infraorbital foramen is reached. If paresthesia results, the needle is pulled back slightly before injection to avoid injecting into the foramen and causing unwanted pressure on the nerve. The operator deposits 1 to 3 mL of anesthetic, and anesthesia results within 4 to 6 minutes. If there is uncertainty about the precise location of the nerve, injection is carried out by depositing multiple small boluses in a “fan” configuration.

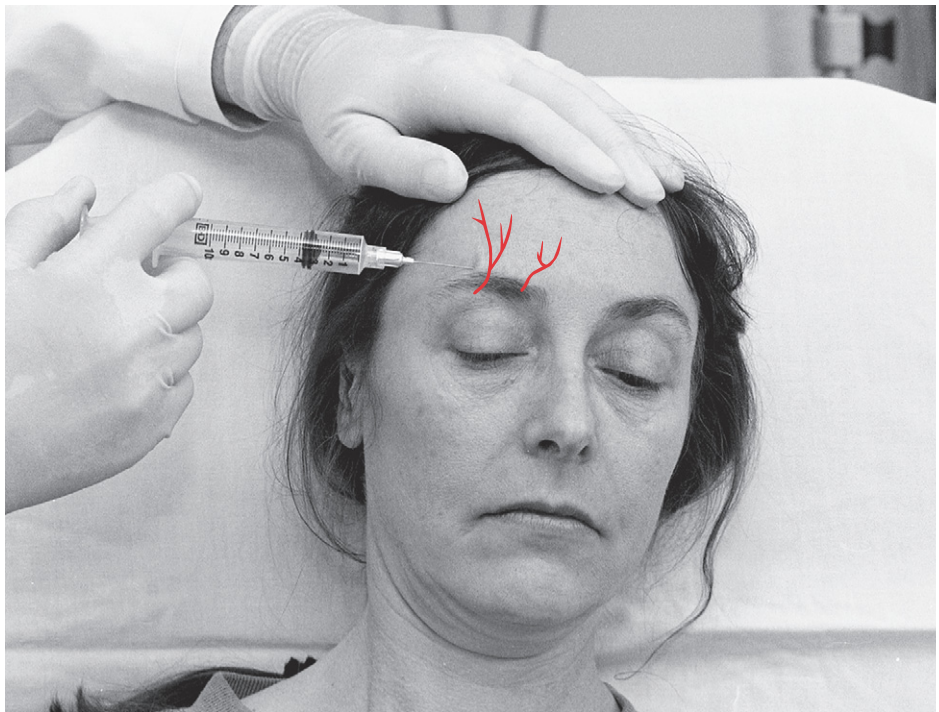
### Mental Nerve Block

#### Indications

Mental nerve block is used to repair lower lip lacerations without distorting the anatomy by local infiltration.



A



B

**Figure 6-5** Forehead block. **A**, Note the path of the supratrochlear and supraorbital nerves that originate from the superior orbital rim. The needle is inserted to its hub at the plane adjacent to the bone itself. **B**, Anesthetic is laid down in a continuous track as the needle is withdrawn slowly across the path of the nerves.



### Anatomy

The mental nerve foramen lies just inferior to the second mandibular bicuspid, midway between the upper and lower edges of the mandible, and 2.5 cm from the midline of the jaw. This nerve provides sensation to the lower half of the lip but only a portion of the chin. The mental foramen can be palpated as shown in Fig. 6-7A.

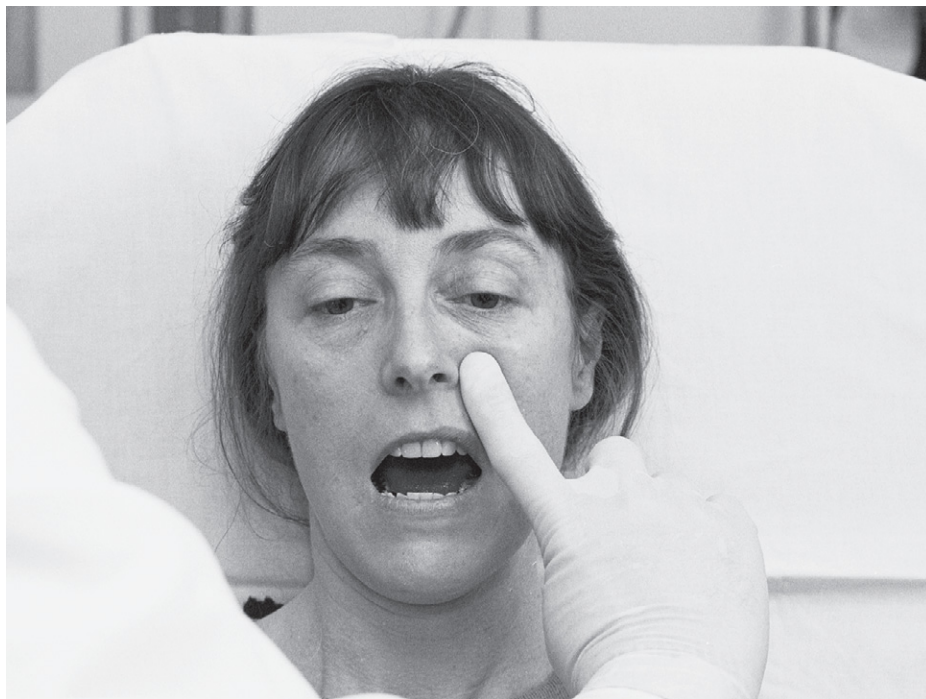### Technique

The mucosal injection site can be pretreated with viscous lidocaine as described earlier for the infraorbital nerve block (Fig. 6-7B). The lower lip is retracted, and the needle is introduced at the gingival-buccal margin inferior to the second bicuspid (Fig. 6-7C). When the foramen is approximated, 1 to 2 mL of anesthetic is injected after careful aspiration. Full anesthesia is achieved within 4 to 6 minutes. The fanning technique can be applied here as well.

### Auricular Block

#### Indications

Lacerations of the auricle of the ear are common. The skin is tightly adherent to the cartilaginous skeleton, and the deposition of an anesthetic for large or complicated wounds can



A

**Figure 6-6** Infraorbital nerve block. **A**, The infraorbital foramen can be palpated before injection. **B**, A cotton-tipped applicator soaked in a topical anesthetic, lidocaine gel, is applied to the mucosal site where the needle will be inserted. **C**, With gentle retraction of the lip, using the maxillary canine as the landmark, the needle is advanced, and anesthetic is deposited at the infraorbital foramen. Note the path of the nerve as it exits the foramen. (Continued)

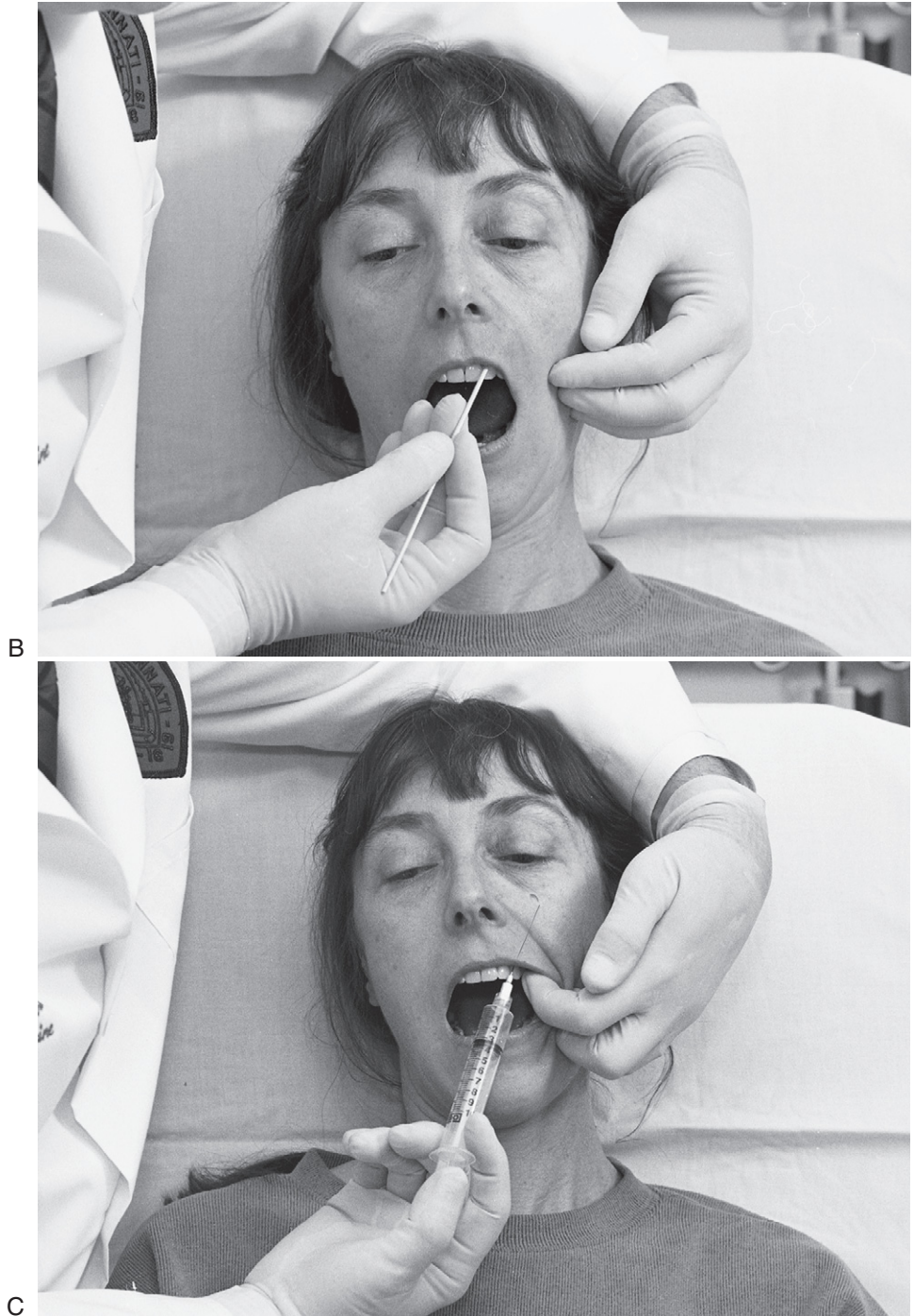

Figure 6-6 Cont'd.

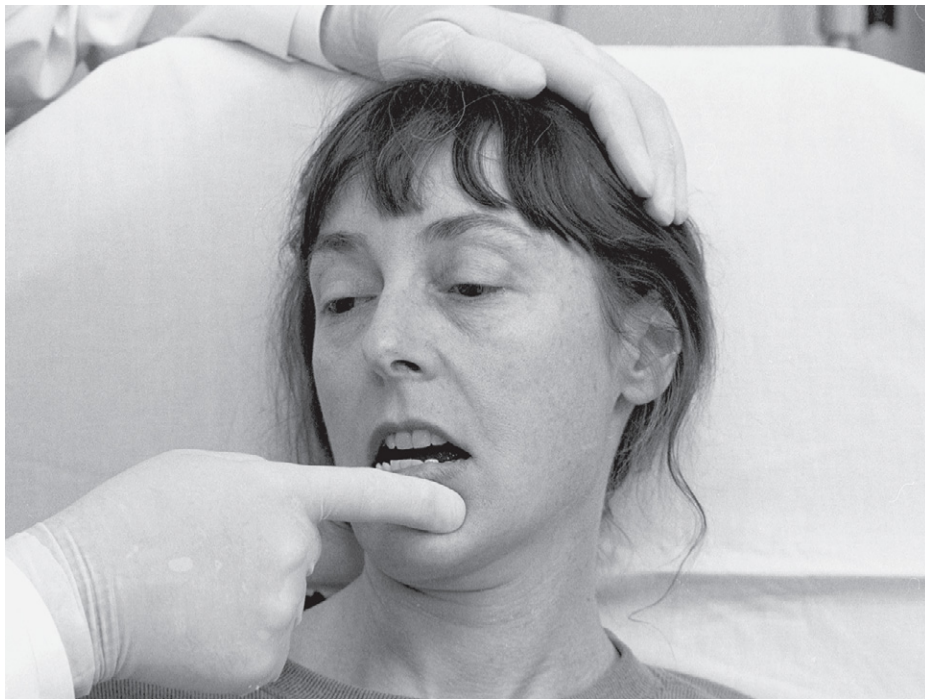be difficult or may excessively distort the local tissue relationships. The auricular block is indicated for extensive repairs of the ear.

### Anatomy

Sensory innervation of the auricle arises from branches of the auriculotemporal, greater auricular, and lesser occipital nerves. Sensory supply to the meatus derives additionally from the branch of the vagus. For this reason, an auricular block does not always completely block the meatal opening.

### Technique

The technical goal of the auricular block is to achieve circumferential anesthesia around the ear. Beginning just below the lobule, the operator fully inserts a 1½- to 2-inch 25G needle attached to a preloaded syringe with 10 mL of anesthetic (without epinephrine) into the sulcus behind the ear, parallel and just superficial to the bone (Fig. 6-8). Approximately 2 to 3 mL of anesthetic is left in a track back to the insertion site. Without leaving the insertion site, the needle is redirected anterior to the lobule and tragus. A similar track is left in that area. The syringe is reloaded if necessary. Starting at a point just behind the superior portion of the helix, a similar track is left behind the superior portion of the ear. Without leaving the injection site, a bolus of anesthetic is deposited backward from the tragus. Anesthesia should be complete in 10 to 15 minutes.

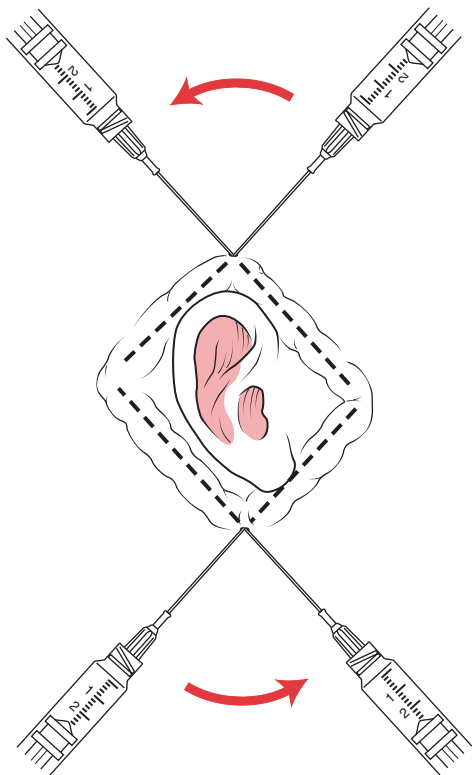


A

**Figure 6-7** Mental nerve block. **A**, The mental nerve foramen can be palpated before injection. **B**, Lidocaine gel is applied to the mucosal injection site. **C**, Using the second bicuspid as the landmark, the needle is advanced, and the anesthetic is deposited at the foramen. Note the path of the nerve as it exits the foramen. (Continued)

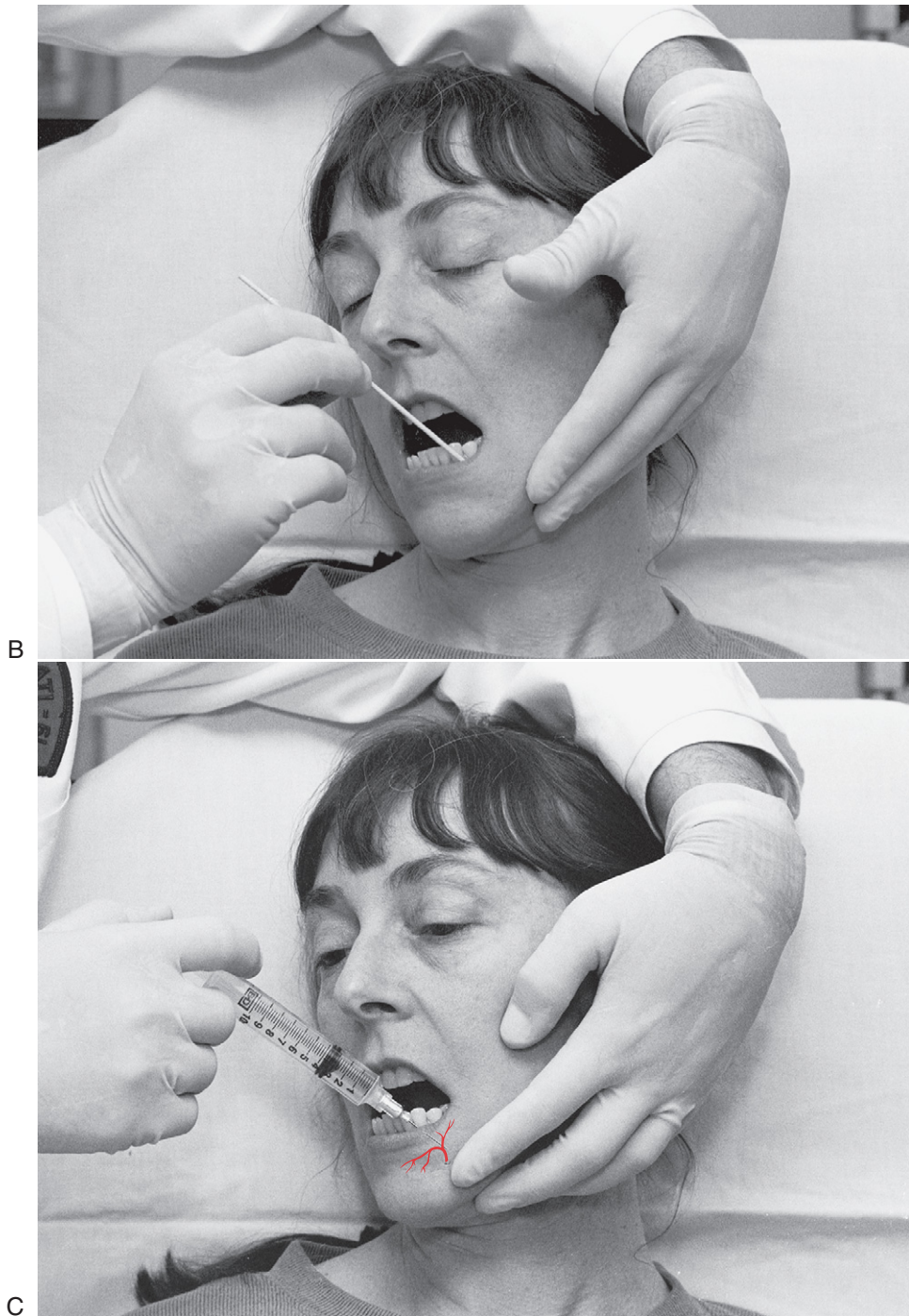

Figure 6-7 Cont'd.



**Figure 6-8** Technique to achieve field anesthesia of the ear.

## Digital Nerve Blocks (Finger and Toe Blocks)

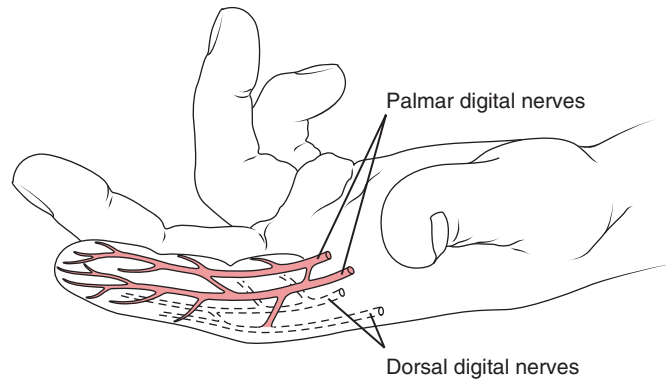
### Indications

The most common nerve block in minor wound care is the digital block. The block is the anesthetic method recommended for lacerations distal to the level of the midproximal phalanx of the finger or toe. It is the procedure preferred for nail removal, paronychia drainage, and repair of lacerations of the digits. A study has shown that digital block, as described here, is more effective and less painful than the metacarpal block to achieve finger anesthesia.<sup>37</sup>

One of the most commonly stated cautions about digital blocks is not to use vasoconstrictors, such as epinephrine, with the anesthetic. There is a theoretical concern that the vasoconstrictor can cause digital ischemia and permanent damage. Two studies that compare digital blocks with and without epinephrine have been published.<sup>18,38</sup> No complications were reported in either study.

### Anatomy

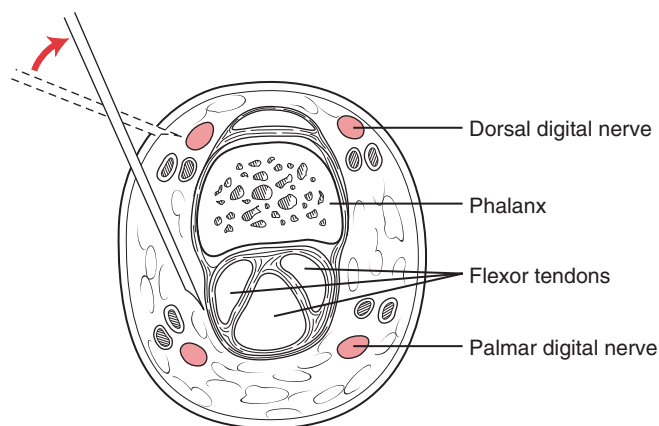
There are four digital nerves for each finger or toe, including the thumb and great toe (Fig. 6-9). The palmar digital nerves have the most extensive sensory distribution and are responsible for distal finger and fingertip sensation, including the nail bed. Although the dorsal nerves have a lesser distribution, there is sufficient overlap with the palmar nerves that all four branches on each finger must be blocked to achieve complete digit anesthesia. The digital nerves are immediately adjacent to the phalanges, and these structures act as landmarks for locating the nerves.



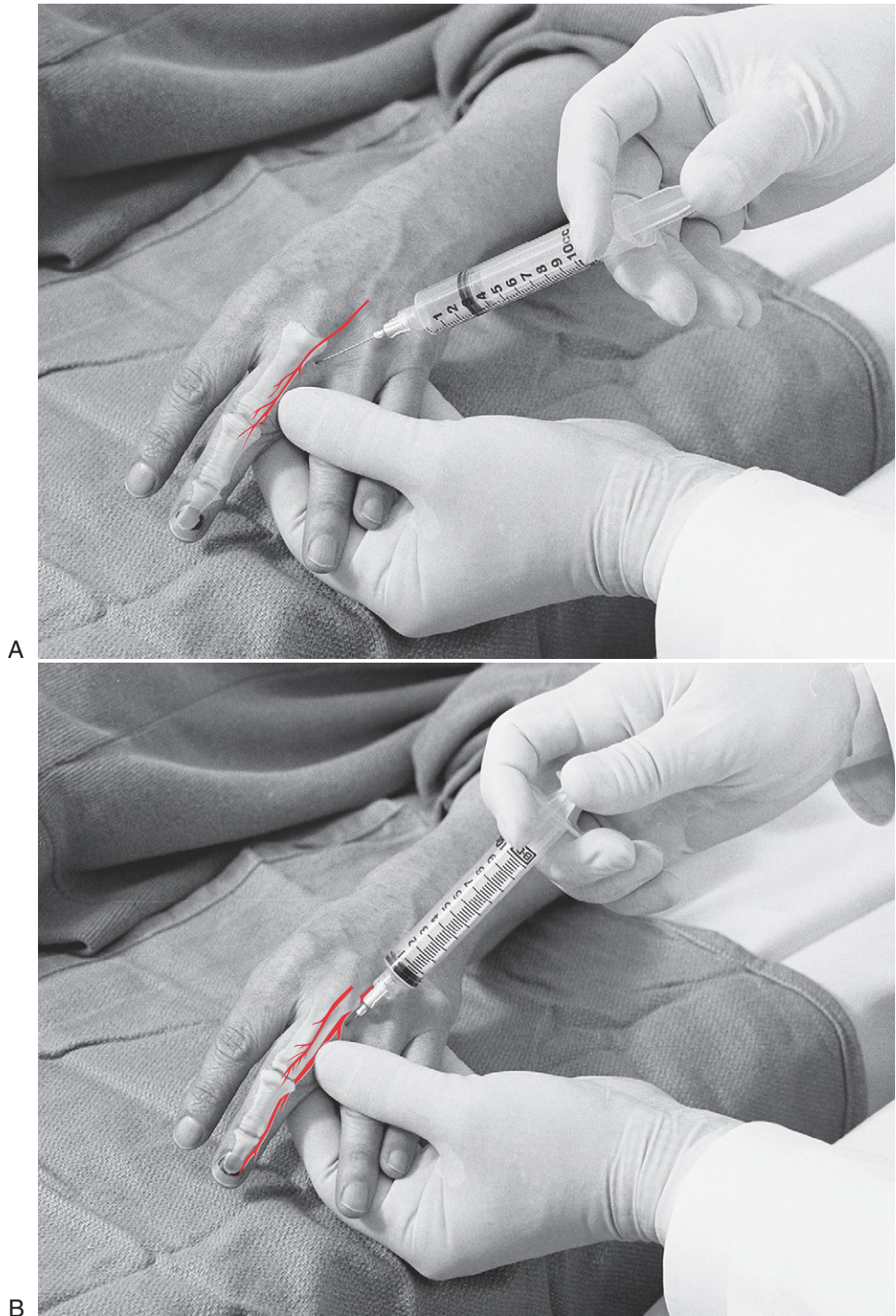
**Figure 6-9** Four digital nerves of the digit. The two palmar digital nerves are dominant and provide sensation to the volar surface of the finger and the entirety of the volar pad and nail bed area.

### Techniques

**Technique for digital block.** Needle size can vary from 25G to 30G. Small-gauge needles, 27G and 30G, require experience and technical comfort of the operator. The technique requires two needle sticks and four small injections of anesthetic. Figure 6-10 illustrates the approach to the dorsal digital nerve followed by redirecting the needle to the palmar nerve. No more than a total of 4 mL of 1% lidocaine without epinephrine or 1% mepivacaine is recommended. The needle is introduced into the dorsolateral aspect of the proximal phalanx in the portion of the web space just distal to the metacarpophalangeal joint (Fig. 6-11). Deposition into the web space prevents buildup of excessive pressure on the digital nerves and blood vessels. The needle is advanced until it touches bone. Approximately 0.5 mL of anesthetic is delivered to the dorsal digital nerve. The needle is withdrawn slightly and

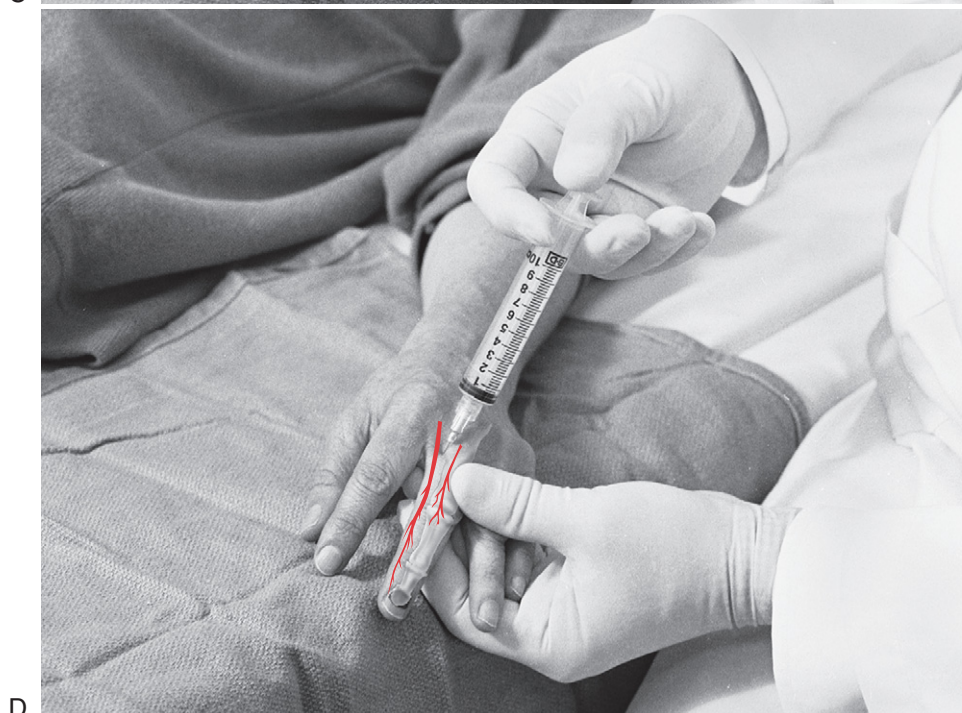
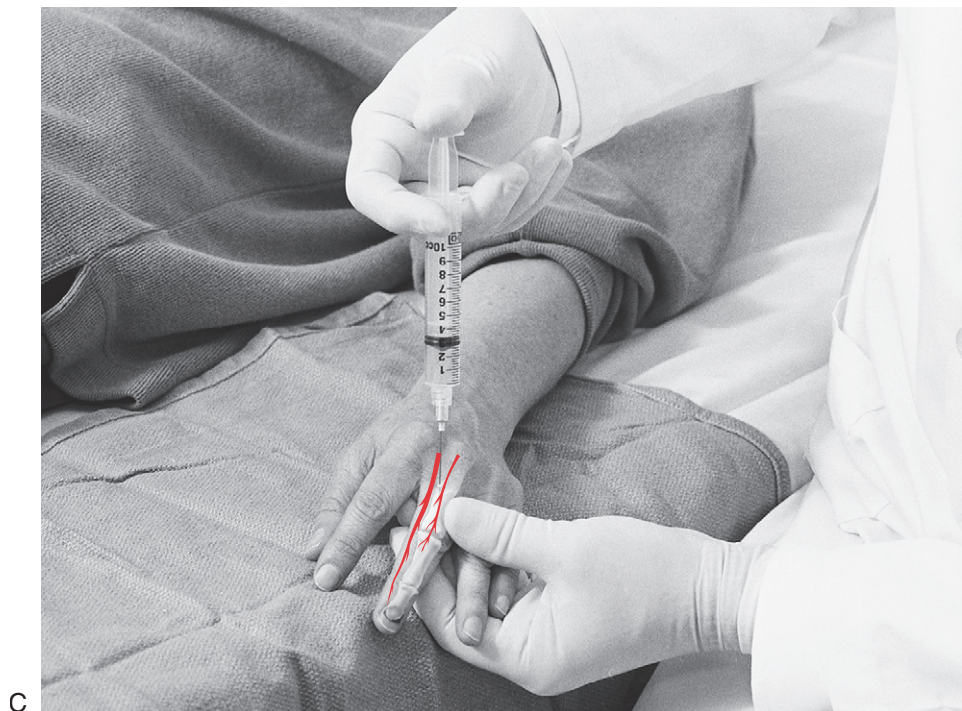
**Figure 6-10** Digital nerve block. To block a digit effectively, all four nerves, dorsal and volar, are approached as illustrated. The needle is introduced dorsally to anesthetize the dorsal nerve first. Without reinserting the needle, it is redirected toward the volar nerve, and anesthetic is deposited. The same procedure is done on the opposite side of the same digit to complete the block.



**Figure 6–11** Digital nerve block. Note the course of the volar and digital nerves. **A**, Within the web space, the needle is introduced and advanced toward the dorsal digital nerve. **B**, After deposition of the anesthetic, the needle is redirected, without withdrawing it from the skin, toward the volar nerve, and anesthetic is deposited. **C** and **D**, The same steps are repeated on the opposite side of the same digit.

*(Continued)*



**Figure 6-11** Cont'd.



redirected adjacent to the bone of the phalanx to the volar surface of the digit, and 1 mL of solution is deposited at the site of the volar or palmar nerve. The procedure is repeated on the opposite side of the digit to achieve full finger or toe anesthesia. A complete block usually is achieved within 4 to 5 minutes. Maintaining close proximity of the nerve to the bone at all times ensures good blockade because the course of the nerve is adjacent to bone. Figure 6-12 illustrates the digital nerve block technique for the thumb.

**Alternative technique for digital block.** An alternative technique for achieving digital anesthesia is by single injection, using a volar approach.<sup>39</sup> This technique provides anesthesia for the volar, or palmar, surface of the digit and the fingertip, including the nail bed and cuticles. Only the palmar digital nerves are blocked; the dorsal surface, with sensory innervation from the small dorsal digital nerves, remains sensate. In 10% of patients, this technique can cause pain at the injection site for 24 hours after the block.<sup>39</sup> It resolves by 48 hours, however.

A 27G needle is preferred with approximately 2 to 3 mL of 2% lidocaine or mepivacaine in an appropriate syringe. The skin is prepared carefully with alcohol or povidone-iodine. The needle is inserted at right angles directly into the palmar flexor crease of the digit, through the flexor tendons, to bone. With gentle but insistent pressure applied to the plunger of the syringe, the needle is withdrawn gradually until fluid flows easily into the tendon sheath. Anesthetic quickly flows out of the tendon sheath along the vincular vessels until it surrounds the main digital nerves.

**Toe block technique.** Because the second to fifth toes are relatively thin at the proximal phalanx, a single midline dorsal needle stick can be used to anesthetize both sides of the toe. After depositing the anesthetic on one side, the needle is withdrawn and passed down the opposite side without leaving the original puncture site (Fig. 6-13). The standard digital technique described earlier is best for the great toe.

## Median Nerve Block

### Indications

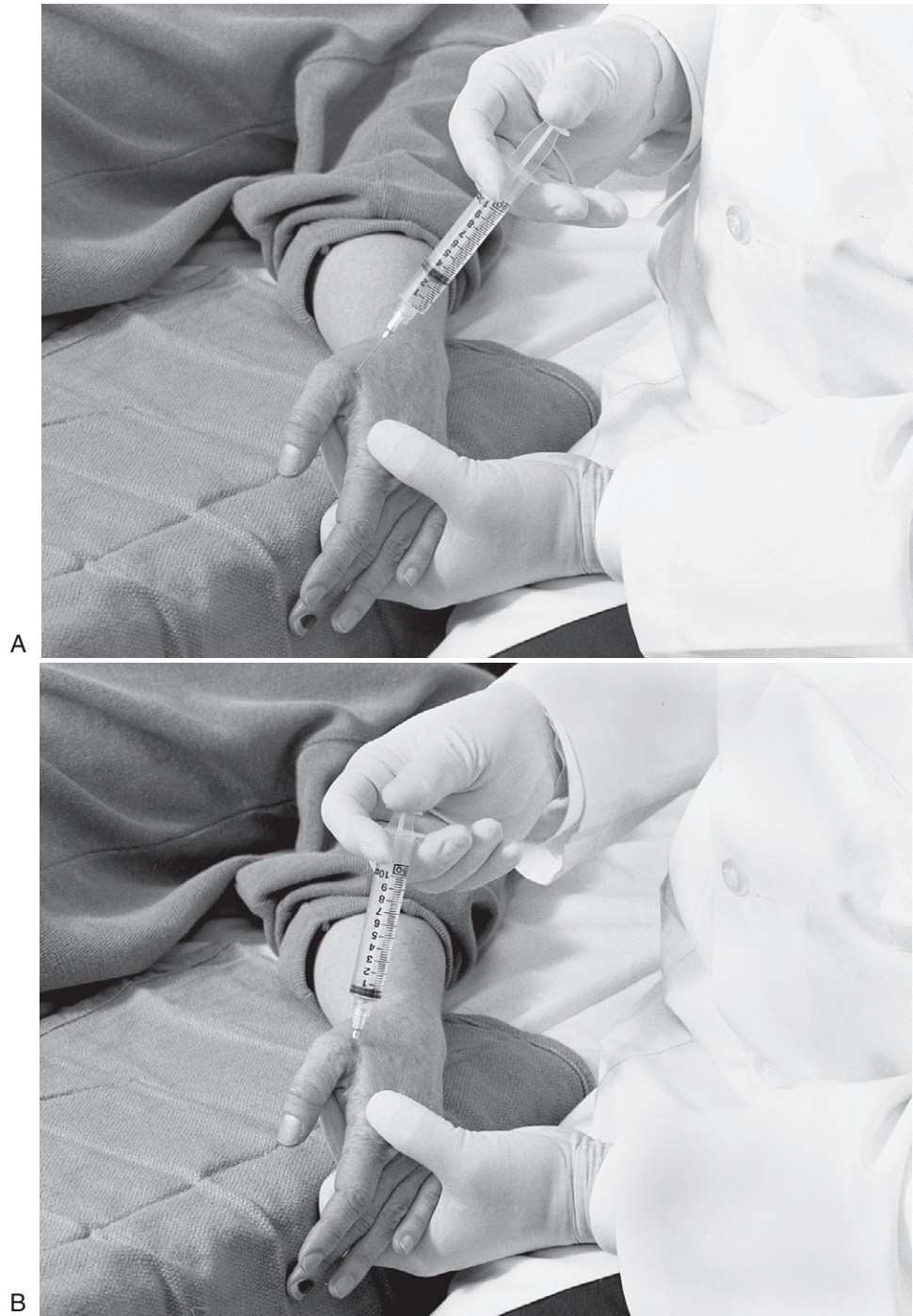
Median nerve block is used for lacerations and wounds of the palmar aspect of the thumb, index, and middle fingers and the radial half of the palm.

### Anatomy

The median nerve can be found at the proximal flexor crease of the wrist between the palmaris longus and the flexor carpi radialis tendon (Fig. 6-14). The two tendons can be identified by having the patient voluntarily close the fingers into a fist and slightly flex the wrist. Some patients do not have a palmaris longus tendon, in which case the nerve is just radial to the flexor sublimis tendons of the fingers, which usually lie below the palmaris longus tendon. The nerve also can be located 1 cm to the ulnar side of the flexor carpi radialis.

### Technique

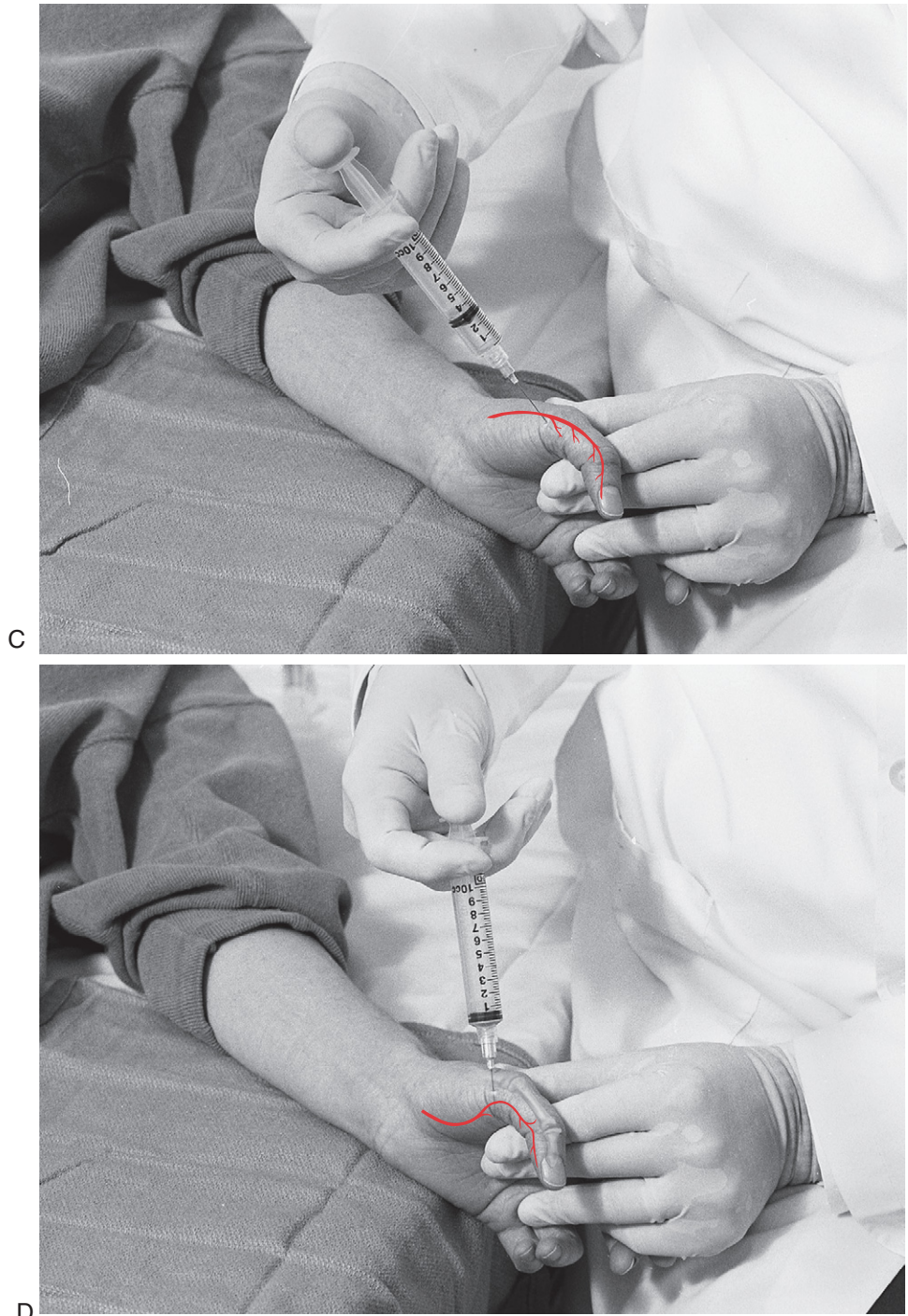
On identifying the palmaris longus tendon, a 25G needle is introduced immediately radial to it (Fig. 6-15). The needle is passed just deep to the flexor retinaculum. A “popping” sensation can be felt as the needle traverses the dense retinaculum. An attempt is made to elicit paresthesias by passing the needle slowly deeper into the wrist. If paresthesias are elicited, 2 mL of solution is deposited adjacent to but not into the nerve. If none are elicited, 3 to 5 mL of solution is injected, from deep to superficial as a track. Anesthesia might not be complete for at least 20 minutes.



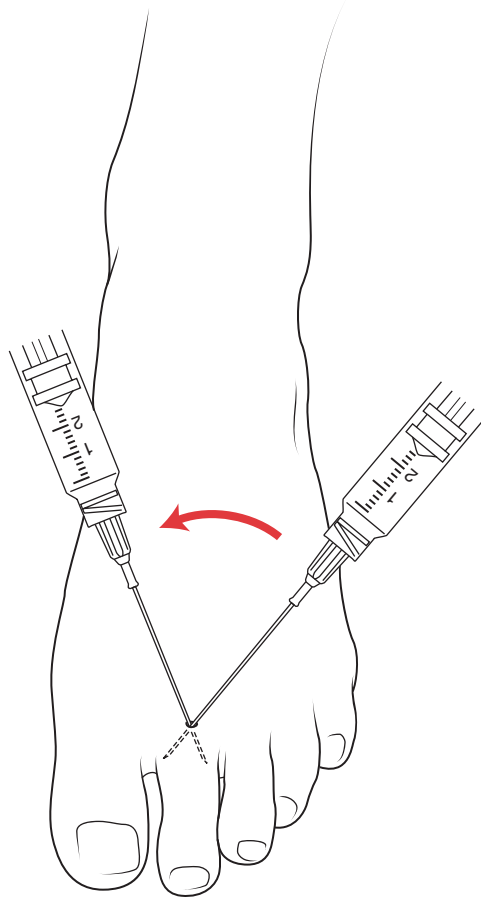
A

B

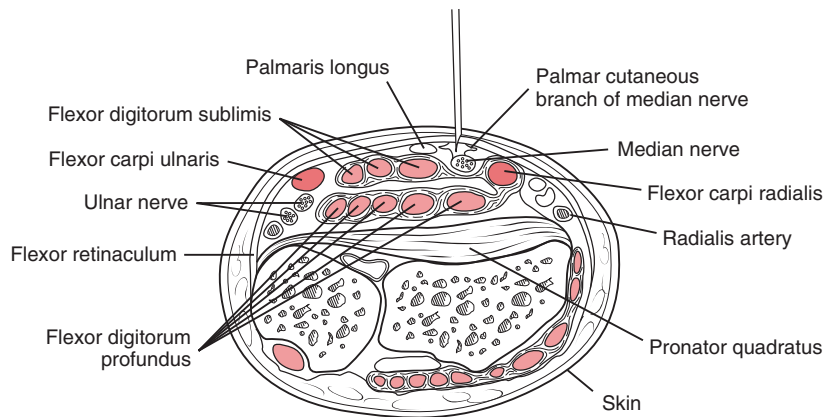
**Figure 6-12** Thumb block. The basic procedure for digital block can be carried out for the thumb. Note the nerve pathways as illustrated. **A**, Within the web space, the ulnar dorsal digital nerve to the thumb is blocked. **B**, Through the same injection site, the ulnar volar nerve is blocked after redirection of the needle. (Continued)



**Figure 6-12** Cont'd. **C**, The radial dorsal digital nerve is approached as illustrated. **D**, After redirection, the radial volar nerve is blocked.

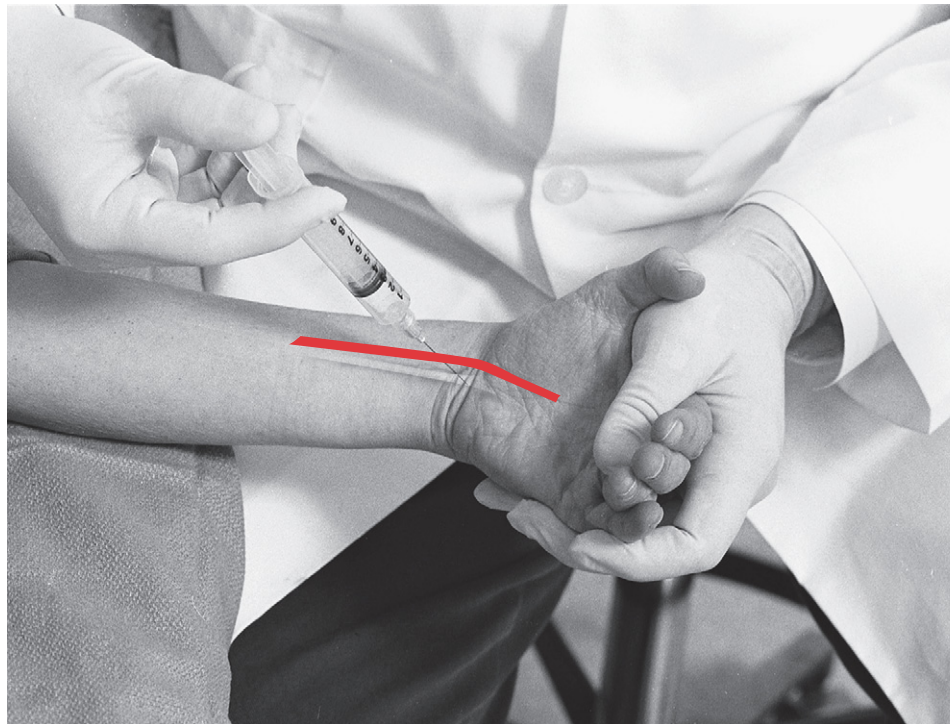

**Figure 6-13** Technique to provide anesthetic to toes other than the great toe (see text).



**Left wrist (palm up)**

**Figure 6-14** Cross-sectional anatomy of the wrist. Note the positions of the palmaris longus, flexor digitorum sublimis, and median nerve.



**Figure 6-15** Median nerve block. Note the position and path of the palmaris longus and median nerves. Immediately radial to the palmaris longus tendon, the needle is inserted throughout the flexor retinaculum toward the median nerve as described in the text.

## Ulnar Nerve Block

### Indications

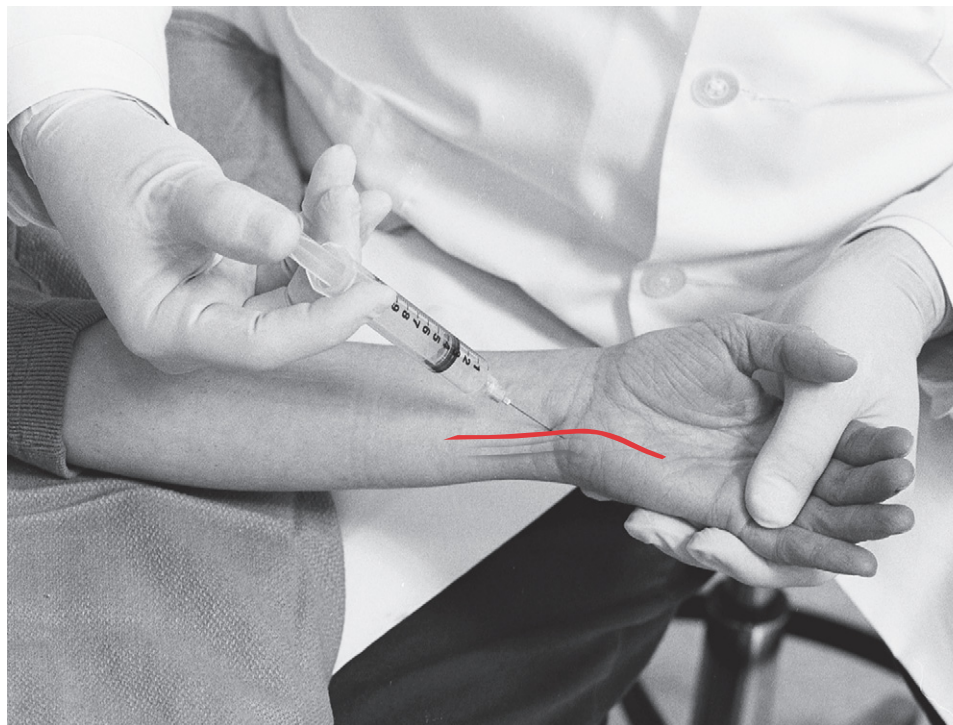
Ulnar nerve block is used for repair of wounds to the ulnar dorsal and palmar aspects of the hand, fifth finger, and ulnar side of the fourth finger.

### Anatomy

The ulnar nerve has two branches that provide sensory innervation to the ulnar side of the hand. The palmar branch of the ulnar nerve is found immediately radial to the flexor carpi ulnaris tendon at the proximal wrist crease. It accompanies the ulnar artery. The dorsal branch of the ulnar nerve divides from the palmar branch approximately 4 to 5 cm proximal from the wrist and courses under the flexor carpi ulnaris tendon to the dorsal-ulnar side of the hand. Because of this division, both branches must be blocked to achieve successful anesthesia.

### Technique

Using a 25G, 1¼- to 2-inch needle, attached to a 10- to 12-mL syringe, the operator enters the wrist at the radial border of the flexor carpi ulnaris tendon (Fig. 6-16). The operator deposits anesthetic carefully and only after aspiration to prevent inadvertent ulnar arterial injection. If a paresthesia is elicited, 3 to 5 mL is deposited. If no paresthesia occurs, in a small fanlike action, the anesthetic is deposited. The nerve also can be approached from the ulnar



**Figure 6-16** Ulnar nerve block. The ulnar nerve lies deep to the flexor carpi ulnaris tendon as shown. The needle is inserted at the radial border of the tendon and directed toward the nerve. Because the nerve lies adjacent to the ulnar artery, great care is taken to aspirate before injection. See text.

aspect of the wrist. By inserting the needle lateral to the same tendon and slipping under it, the nerve can be blocked using the same amount of anesthetic. A block is achieved in 8 to 12 minutes. A separate branch, originating proximal to the wrist, of the ulnar nerve innervates the dorsum of the hand. To block that branch, a subcutaneous track of anesthetic is laid down from the dorsal midline of the wrist to the ulnar border of the flexor carpi ulnaris tendon.

### **Radial Nerve Block**

#### *Indications*

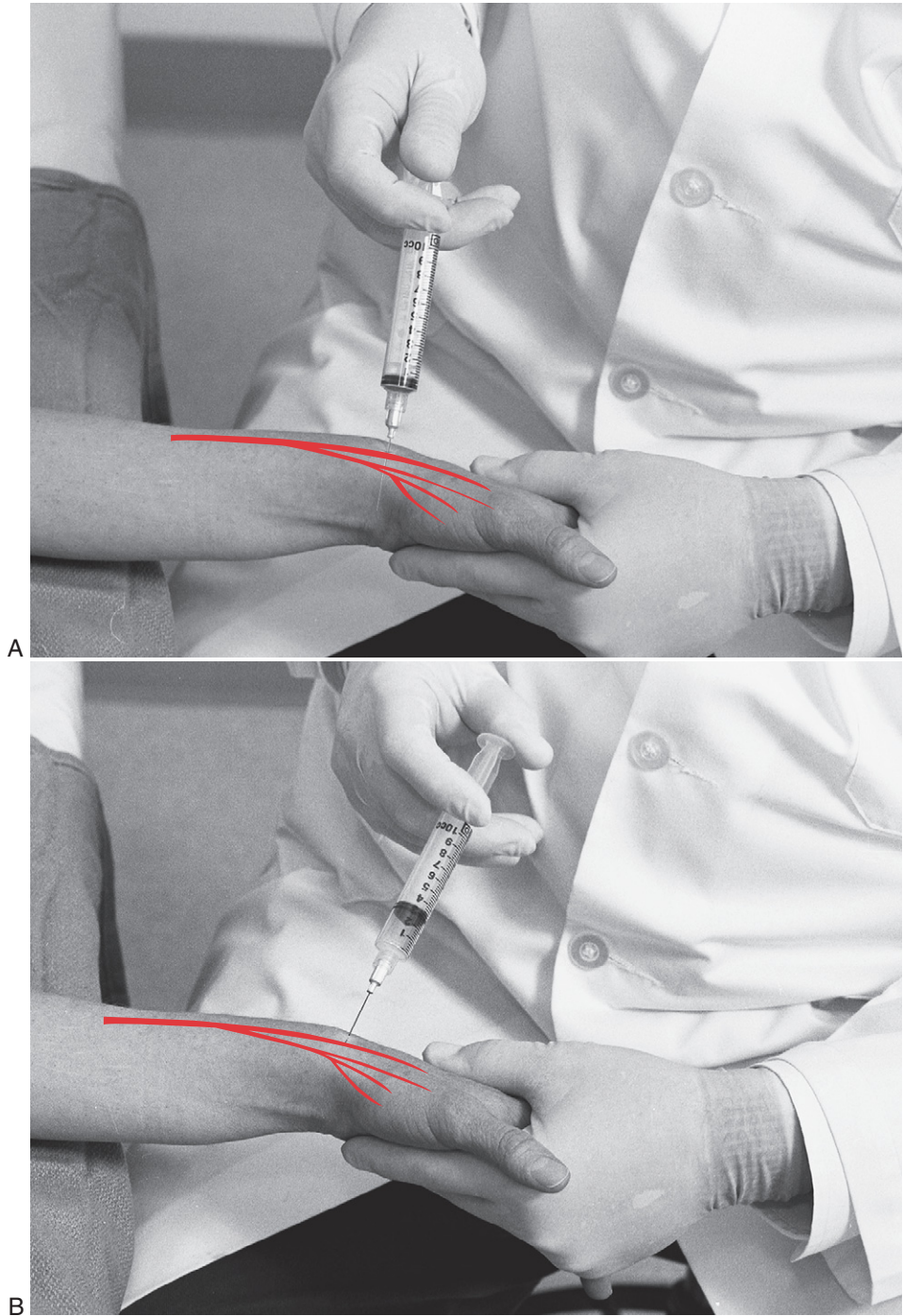
Radial nerve block is used for wounds located on the dorsum of the thumb, index, and middle fingers and the radial portion of the dorsum of the hand.

#### *Anatomy*

Approximately 7 cm proximal to the wrist, a superficial cutaneous branch leaves the main radial nerve. At the level of the wrist, this branch begins to fan out into several rami that provide sensory innervation to the dorsoradial aspect of the hand. These rami lie in the superficial fascia just deep to the skin.

#### *Technique*

Starting at the dorsoradial aspect of the wrist, a continuous subcutaneous track of anesthetic is laid down to block all the sensory branches (Fig. 6-17). The technique is similar to that



**Figure 6-17** Radial nerve block. **A**, Note location and branching of the radial nerve. The needle is introduced to its hub. **B**, A continuous track of anesthetic is laid down as the needle is withdrawn across the branches of the radial nerve.

described for ulnar nerve blockade. Approximately 10 mL of anesthetic is required. For this block to abolish sensation, 8 to 12 minutes is necessary.

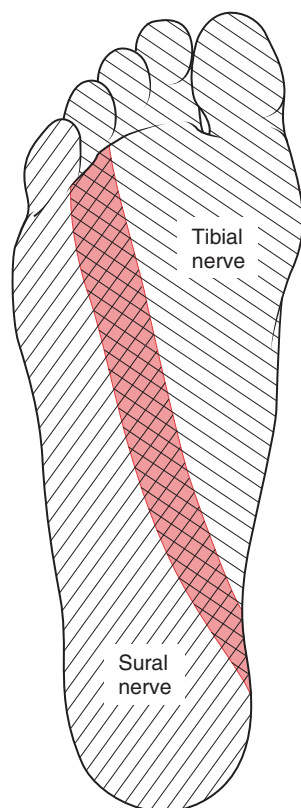
### Sural and Tibial Nerve Blocks (Sole of Foot Blocks)

#### Indications

One of the most painful areas in which to inject local anesthetic is the sole of the foot. This area is commonly injured and subject to puncture wounds, lacerations, and the embedding of foreign bodies. Sural and tibial nerve blocks are recommended. These blocks are much less painful to the patient than direct infiltration.

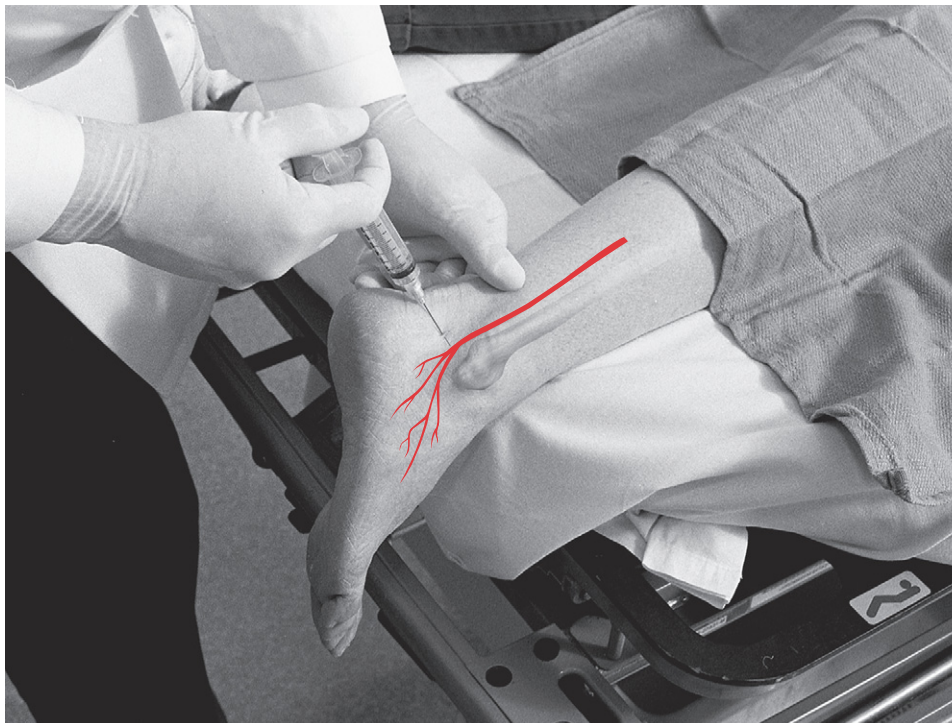
#### Anatomy

The sural nerve courses behind the fibula and lateral malleolus to supply the heel and lateral aspect of the foot. The tibial nerve can be found between the Achilles tendon and the medial malleolus. It can be located easily because it accompanies the posterior tibial artery at that level. This nerve supplies a large portion of the sole and medial side of the foot. As denoted in Fig. 6-18, there is some overlap of distribution of these nerves and some overlap of sensation with the anteriorly located saphenous and superficial peroneal nerves. Complete anesthesia is not always



**Figure 6-18** Plantar surface of the foot. Distribution of sural and tibial nerve sensory component. There is overlap between the two distributions.





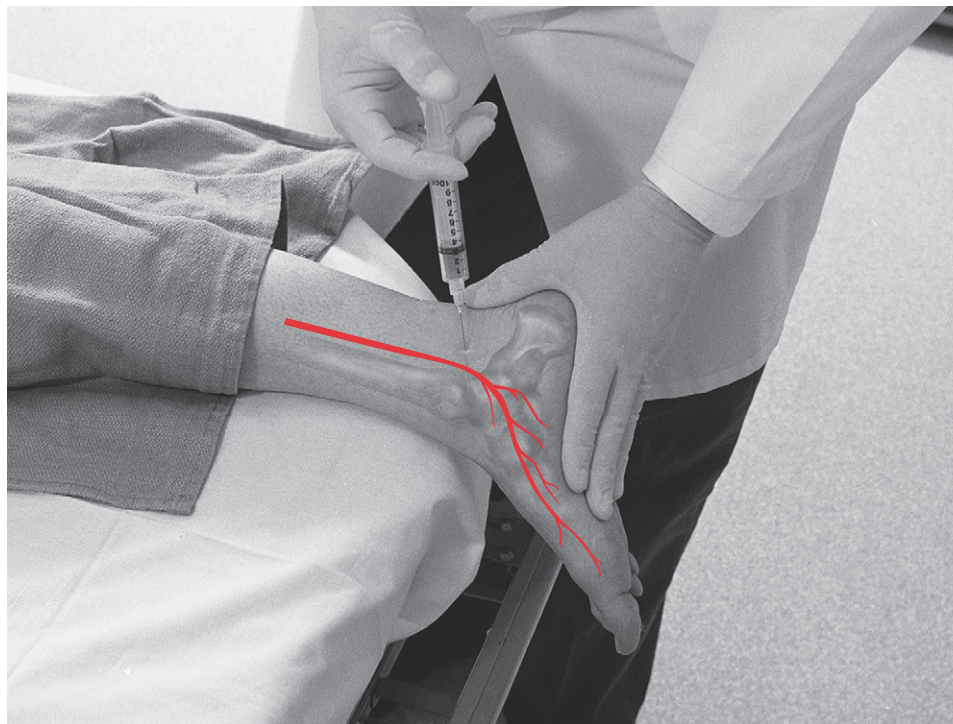
**Figure 6-19** Sural nerve block. Note the path of the sural nerve and its relationship to the tip of the fibula. Because of the branching of the nerve, the injection is carried out in a fanlike manner to create an effective block.

achieved by a single block. It can be supplemented by local infiltration with minimal discomfort to the patient because of the preexisting partial anesthesia from the block.

### Techniques

**Technique for sural nerve block.** The needle is introduced just lateral to the Achilles tendon approximately 1 to 2 cm proximal to the level of the distal tip of the lateral malleolus (Fig. 6-19). The needle is directed to the posterior medial aspect of the fibula, and 5 mL of anesthetic is deposited after aspiration of the syringe. To ensure that all the branches of the sural nerve are properly infiltrated, a fan-shaped motion is made with the needle, and multiple small boluses are delivered.

**Technique for posterior tibial nerve block.** The posterior tibial artery is palpated as a landmark. The needle is passed adjacent to the Achilles tendon toward the posterior tibial artery behind the medial malleolus (Fig. 6-20). When the area of the artery is approximated, careful aspiration of the syringe is carried out. If there is no blood return, 5 mL of anesthetic is injected. Blocks of the posterior tibial and sural nerve take approximately 10 to 15 minutes to achieve appropriate anesthetic levels.



**Figure 6-20** Posterior tibial nerve block. Note the path of the nerve and its relationship to the tibial medial malleolus. Because the nerve travels in conjunction with the posterior tibial artery, care is taken to aspirate before injection.

## REFERENCES

1. Mather M, Cousins M: Local anesthetics and their current clinical use, *Drugs* 18:185-205, 1979.
2. Todd K, Berk WA, Huang R: Effect of body locale and addition of epinephrine on the duration of action of a local anesthetic agent, *Ann Emerg Med* 21:723-726, 1992.
3. Sinnott CJ, Cogswell LP III, Johnson A, et al: On the mechanism by which epinephrine potentiates lidocaine's peripheral nerve block, *Anesthesiology* 98:181-188, 2003.
4. deJong R: Toxic effects of local anesthetics, *JAMA* 239:1166-1168, 1978.
5. Norris RL: Local anesthetics, *Emerg Med Clin North Am* 10:707-718, 1992.
6. Chandler MJ, Grammer LC, Patterson R: Provocative challenge with local anesthetics in patients with a prior history of reaction, *J Allergy Clin Immunol* 79:883-886, 1987.
7. Pollack CV, Swindle GM: Use of diphenhydramine for local anesthesia in "caine"-sensitive patients, *J Emerg Med* 7:611-614, 1989.
8. Dire DJ, Hogan DE: Double-blinded comparison of diphenhydramine versus lidocaine as a local anesthetic, *Ann Emerg Med* 22:1419-1422, 1993.
9. Ernst AA, Marvez-Valls E, Nick TG, Wahle M: Comparison trial of four injectable anesthetics for laceration repair, *Acad Emerg Med* 3:228-233, 1996.
10. Singer AJ, Hollander JE: Infiltration pain and local anesthetic effects of buffered versus plain 1% diphenhydramine, *Acad Emerg Med* 2:884-888, 1995.
11. Hennes HM, Wagner V, Nonadio WA, et al: The effect of oral midazolam on anxiety of preschool children during laceration repair, *Ann Emerg Med* 19:1006-1009, 1990.
12. Shane SA, Fuchs SM, Khine H: Efficacy of rectal midazolam for the sedation of preschool children undergoing laceration repair, *Ann Emerg Med* 24:1065-1073, 1994.
13. Yealy DM, Ellis JH, Hobbs GD, Moscati RM: Intranasal midazolam as a sedative for children during laceration repair, *Am J Emerg Med* 10:584-587, 1992.

14. Berman D, Graber D: Sedation and analgesia, *Emerg Med Clin North Am* 10:691-705, 1992.
15. Klein EJ, Diekema DS, Paris CA, et al: A randomized clinical trial of oral midazolam plus placebo versus oral midazolam plus oral transmucosal fentanyl for sedation during laceration repair, *Pediatrics* 109:894-897, 2002.
16. Terndrup TE, Dire DJ, Madden CM, et al: A prospective analysis of intramuscular meperidine, promethazine, and chlorpromazine in pediatric emergency department patients, *Ann Emerg Med* 20:31-35, 1991.
17. Qureshi FA, Mellis PT, McFadden MA: Efficacy of oral ketamine for providing sedation and analgesia to children requiring laceration repair, *Pediatr Emerg Care* 11:93-97, 1995.
18. Andrades PR, Olguin FA, Calderon W: Digital blocks with and without epinephrine, *Plast Reconstr Surg* 111:1769-1770, 2003.
19. Fariss BL, Foresman PA, Rodeheaver GT, et al: Anesthetic properties of bupivacaine and lidocaine for infiltration anesthesia, *J Emerg Med* 5:275-282, 1987.
20. Malamed SF, Gagnon S, Leblanc D: Articaine hydrochloride: a study of the safety of a new amide local anesthetic, *J Am Dent Assoc* 132:177-185, 2001.
21. Bartfield JM, Crisafulli KM, Raccio-Robak N, Salluzzo RF: The effects of warming and buffering on pain of infiltration of lidocaine, *Acad Emerg Med* 2:254-258, 1995.
22. McKay W, Morris R, Mushlin P: Sodium bicarbonate attenuates pain on skin infiltration with lidocaine, with or without epinephrine, *Anesth Analg* 66:572-574, 1987.
23. Orlinsky M, Hudson C, Chan L, Deslauriers R: Pain comparison of unbuffered versus buffered lidocaine in local wound infiltration, *J Emerg Med* 10:411-415, 1992.
24. Bartfield JM, Homer PJ, Ford DT, Sternklar P: Buffered lidocaine as a local anesthetic: an investigation of shelf life, *Ann Emerg Med* 21:16-19, 1992.
25. Arndt KA, Burton C, Noe JM: Minimizing the pain of local anesthesia, *Plast Reconstr Surg* 72:676-679, 1983.
26. Murakami CS, Odland PB, Ross BR: Buffered local anesthetics and epinephrine degradation, *J Dermatol Surg Oncol* 20:192-195, 1994.
27. Mader TJ, Playe SJ, Garb JL: Reducing the pain of local anesthetic infiltration: warming and buffering have a synergistic effect, *Ann Emerg Med* 23:550-554, 1994.
28. Dailey RH: Fatality secondary to misuse of TAC solution, *Ann Emerg Med* 17:159-160, 1988.
29. Barker W, Rodeheaver GT, Edgerton MT, et al: Damage to tissue defenses by a topical anesthetic agent, *Ann Emerg Med* 11:307-310, 1982.
30. Pryor G, Kilpatrick W, Opp D: Local anesthesia in minor lacerations: topical TAC versus lidocaine infiltration, *Ann Emerg Med* 9:568-571, 1980.
31. Priestley S, Kelly AM, Chow L, et al: Application of topical local anesthetic at triage reduces treatment time for children with lacerations: A randomized controlled trial. *Ann Emerg Med* 42:34-40, 2003.
32. Bonadio WA, Wagner VR: Adrenaline-cocaine gel topical anesthetic for dermal laceration repair in children, *Ann Emerg Med* 21:1435-1438, 1992.
33. Vinci RJ, Fish SS: Efficacy of topical anesthesia in children, *Arch Pediatr Adolesc Med* 150:466-469, 1996.
34. Bonadio WA, Wagner V: Half-strength TAC topical anesthetic, *Clin Pediatr* 27:495-498, 1988.
35. Ernst AA, Marvez-Valls E, Nick TG, Weiss SJ: LAT (lidocaine-adrenaline-tetracaine) versus TAC (tetracaine-adrenaline-cocaine) for topical anesthesia in face and scalp lacerations, *Am J Emerg Med* 13:151-154, 1995.
36. Blackburn PA, Butler KH, Hughes MJ, et al: Comparison of tetracaine-adrenaline-cocaine (TAC) with topical lidocaine-epinephrine (TLE): efficacy and cost, *Am J Emerg Med* 13:315-317, 1995.
37. Knoop KJ, Trott AT, Syverud S: Comparison of digital versus metacarpal block for repair of finger injuries, *Ann Emerg Med* 23:1296-1300, 1994.
38. Wilhelmi BJ, Blackwell SJ, Miller JH, et al: Do not use epinephrine in digital blocks: myth or truth? *Plast Reconstr Surg* 107:393-397, 2001.
39. Brutus JP, Baeten Y, Chahidi L, et al: Single injection digital block: comparison between three techniques, *Chir Main* 21:182-187, 2002.

# Wound Cleansing and Irrigation

## WOUND CLEANSING SOLUTIONS

Povidone-Iodine  
Chlorhexidine  
Nonionic Surfactants  
Hexachlorophene  
Quaternary Ammonium Compounds  
Hydrogen Peroxide

## PREPARATION FOR WOUND CLEANSING

Hand Washing  
Personnel Precautions

Wound Area Hair Removal  
Anesthesia  
Foreign Material  
Wound Soaking  
Wound Periphery Cleansing  
Irrigation

## CLEANSING SETUP AND PROCEDURES

Cleansing and irrigation are the foundation of good wound care. These steps can be time-consuming and tedious. It is essential, however, that all contaminants and devitalized tissue are removed before wound closure. If they are not, the risks of infection and a cosmetically poor scar are greatly increased. Neither clever suturing technique nor the use of prophylactic antibiotics can replace meticulous cleansing and irrigation and, if needed, judicious débridement.

## WOUND CLEANSING SOLUTIONS

Several skin-cleansing preparations are available commercially (Table 7-1). Most of the clinical data that compare the efficacy of these agents come from studies of elective surgery patients or experiments on laboratory animals.<sup>1-4</sup> Only in more recent years have there been reports detailing the use of skin-cleansing preparations in emergency departments.<sup>5-7</sup> Based on these studies and the properties of the cleansing solutions, guidelines for use in emergency wound care can be suggested.

### Povidone-Iodine

Povidone-iodine (Betadine) is a complex of the potent bactericidal agent iodine and the carrier molecule povidone. On contact with tissues, the carrier complex slowly releases free iodine. Gradual release decreases tissue irritation and reduces potential toxicity while preserving the agent's germicidal activity. Povidone-iodine is effective against gram-positive and gram-negative bacteria, fungi, and viruses.<sup>8</sup> It is currently in widespread use for hand washing, preoperative skin preparation, and cleansing of traumatic wounds. Compared with other agents, such as chlorhexidine, quaternary ammonium compounds, and hexachlorophene, povidone-iodine seems to have a greater bactericidal effect against gram-negative bacteria.<sup>1,3,9,10</sup> In contrast to chlorhexidine and hexachlorophene, povidone-iodine has a shorter protective effect against bacterial buildup on the skin after hand washing and seems to be less effective than these agents for that purpose.<sup>11</sup>

TABLE 7-1 *Summary of Wound Cleansing Agents*

Skin Cleanser	Antibacterial Activity	Tissue Toxicity	Systemic Toxicity	Potential Uses
Povidone-iodine surgical scrub	Strongly bactericidal against gram-positive and gram-negative bacteria	Detergent can be toxic to wound tissue	Painful to open wounds Other reactions extremely rare	Hand cleanser
Povidone-iodine solution	Same as povidone-iodine scrub	Minimally toxic to wound tissue	Extremely rare	Wound-periphery cleanser
Chlorhexidine	Strongly bactericidal against gram-positive organisms, less strong against gram-negative bacteria	Detergent can be toxic to wound tissue	Extremely rare	Hand cleanser Alternative wound periphery cleanser
Poloxamer 188	No antibacterial activity	None known	None known	Wound cleanser (particularly useful on face)
Hexachlorophene	Bacteriostatic against gram-positive, poor activity against gram-negative bacteria	Detergent can be toxic to wound tissue	Teratogenic with repeated use	Alternative hand cleanser
Hydrogen peroxide	Weak antibacterial agent	Toxic to red blood cells	Extremely rare	Wound cleanser adjunct

Povidone-iodine is manufactured as a solution by itself (povidone-iodine solution) or in conjunction with an ionic detergent (povidone-iodine scrub preparation). The detergent in the scrub preparation seems to be toxic to several normal tissues and to components of an open wound.<sup>1,12</sup> Excessive exposure of open wounds to scrub solutions by wound scrubbing or soaking is not recommended. Scrub solutions were designed for preoperative preparation of intact skin before operative incisions.

Povidone-iodine, without the detergent, is distributed most commonly as a 10% solution. When diluted to a 1% concentration or lower, it can be applied safely to wounds and retains its bactericidal activity.<sup>13</sup> The inherent lack of clinical toxicity of povidone-iodine without detergent was shown with 225 patients undergoing ophthalmologic surgery.<sup>14</sup> Povidone-iodine 10% solution, diluted with saline, was used to prepare the eye and its surrounding structures for surgery. There was no reported corneal, conjunctival, or skin toxicity. Adverse and allergic reactions are extremely rare, even when the solution is used in known iodine-allergic patients.<sup>15</sup>

### Chlorhexidine

Chlorhexidine (Hibiclens) is an antibacterial biguanide that is effective against gram-positive bacteria. This agent also is effective against gram-negative bacteria, but slightly less so than povidone-iodine.<sup>9</sup> Its action against viruses is uncertain.<sup>8</sup> Repeated use can lead to buildup on the skin and prolonged suppression of hand bacterial count.<sup>16</sup> For this reason, it is an excellent hand-washing preparation. Under normal conditions of use, chlorhexidine has an exceedingly low toxicity. The skin cleanser contains an ionic detergent similar to the povidone-iodine scrub preparation, however, and direct contact with an open wound is discouraged.<sup>14</sup>

### Nonionic Surfactants

Newer and potentially useful wound cleansers are the nonionic surfactants pluronic F-68 (Shur-Cleans) and poloxamer 188 (Pharma Cleans).<sup>17</sup> These are surface-active agents with the cleansing properties of soap but virtually no tissue toxicity, including to the eye and cornea. There are no demonstrable adverse effects in wounds and lacerations. Poloxamer 188 has been used successfully in a trial of more than 3000 patients without serious side effects.<sup>18</sup> The major drawback of the nonionic surfactants is that they have no antibacterial activity.<sup>19</sup> For this reason, alternative cleansing agents, such as povidone-iodine, are preferable for contaminated wounds. Conversely, surfactants are well suited for use on the face because they are nontoxic to the eye, and the face is naturally resistant to infection.

### Hexachlorophene

Hexachlorophene (pHisoHex) is a bacteriostatic agent with good activity against gram-positive bacteria, but it is not effective against gram-negative organisms.<sup>20</sup> Although this skin cleanser previously enjoyed widespread popularity as a cleansing agent, it has been replaced by povidone-iodine and chlorhexidine. In recent years, new discoveries of its potential toxicity and teratogenicity have led to a further decline in its use.<sup>3</sup> Because hexachlorophene has a cumulative and protective buildup in the skin, it remains an alternative for hand washing before wound care procedures.

### Quaternary Ammonium Compounds

Quaternary ammonium compounds (Zephiran) have characteristics that render them virtually useless in wound care.<sup>21</sup> These compounds have a limited gram-negative spectrum, and *Pseudomonas* can proliferate in stored solutions. Quaternary ammonium compounds are inactivated by soap, blood, and organic matter. Previously popular in the operative setting, these agents have no modern utility.

### Hydrogen Peroxide

Without a clear scientific basis, as if by tradition alone, hydrogen peroxide is used commonly in emergency wound care. As it comes into contact with blood and tissue peroxidase, hydrogen peroxide makes visible bubbles from liberated oxygen. The reaction causes foaming that is thought to dislodge bacteria, debris, and other contaminants from small crevices in tissues. This effect gives the appearance of cleansing activity, but this agent has many drawbacks. It is naturally hemolytic, and the oxygen bubbles have been shown to separate new epithelial cells from granulation tissue.<sup>22</sup> The germicidal action of hydrogen peroxide is weak and brief at best.<sup>8</sup> In a controlled study of appendectomies, hydrogen peroxide topically applied to the incision site before suture closure did not reduce the infection rate compared with the control.<sup>23</sup> Under experimental wound conditions, it can delay healing.<sup>22</sup> Because of its hemolytic effect, hydrogen peroxide is best limited to a role as an adjunctive agent for wounds encrusted with blood.

---

## PREPARATION FOR WOUND CLEANSING

Before cleansing and irrigating a laceration or wound, several issues, including hand washing, personnel precautions, hair removal, anesthesia, foreign material, wound soaking, wound periphery cleansing, and irrigation, have to be considered.

### Hand Washing

Because of the unsterile nature of traumatic wounds, fixed-time hand washing with preoperative scrubbing techniques is not necessary. Although a simple, brief hand washing suffices

before each procedure, it is necessary to ensure that the fingernails have been well cleaned because they harbor more bacteria than other parts of the hand.<sup>21,24</sup> Chlorhexidine is a good choice for hand washing. As a skin cleanser, it is well tolerated by users. With repeat washings, it builds up in the skin, with an accompanying prolonged antibacterial effect, and it does not stain clothing the way povidone-iodine does. Compliance with hand washing among emergency personnel has been shown to be poor.<sup>25</sup> Nurses have been observed to comply (hand washing after patient contact before proceeding to the next contact) after 58.2% of patient contacts; residents, after 18.6%; and faculty, after 17%. Hand washing is just one of the defenses against the risks.

An advance in hand washing has made it much easier to comply with this requirement. Newer alcohol-based products allow for rapid, self-drying application. These agents are equally efficacious as soap-based products in reducing bacterial counts and have equivalent cleansing power.<sup>26</sup>

### Personnel Precautions

Because preparing and cleansing a wound brings wound care personnel into contact with blood and other secretions, it is recommended that appropriate protective gloves and eyewear be worn at all times. Gowns also are recommended but not always practical.

The main infective agents that are of concern in the emergency department are hepatitis B and C and human immunodeficiency virus (HIV). The prevalence of HIV in urban emergency department patients has been reported to be 4% to 5%.<sup>27</sup> More important, 25% of these patients are unaware of their HIV-positive status on presentation.<sup>11</sup> It is common for practitioners to be diligent about protecting themselves during major trauma resuscitations. The bleeding laceration is no less of a threat when suture needles, tissue scissors, and scalpel blades are being used.

### Wound Area Hair Removal

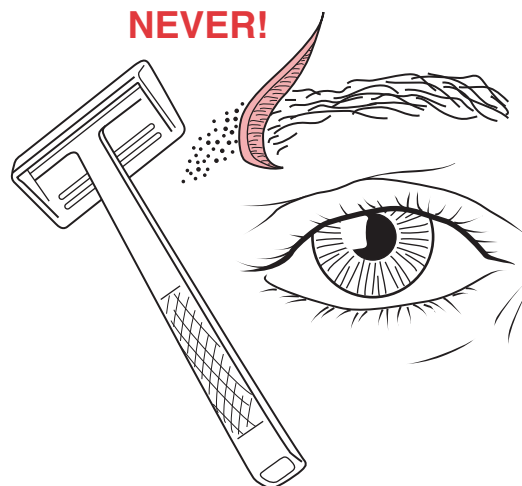
It is common practice to shave hair around lacerations and other wounds before repair. Although there are no studies concerning hair removal in the wound care setting, shaving has the potential to increase the wound infection rate. Close shaving of intact skin can cause small dermal wounds that can act as portals of entry for bacterial invasion and possible infection.<sup>21</sup> Two studies of patients, shaved versus not shaved for elective surgery, showed an increase in postoperative wound infection rates in the shaved groups.<sup>28,29</sup> Although hair shafts harbor bacteria, structures such as roots, glands, and follicles do not contain high bacterial counts under normal conditions.<sup>24</sup> Hair can be cleansed easily and successfully using standard techniques for applying antiseptic solutions.<sup>30</sup>

A case for hair removal can be made on technical grounds. In areas such as the scalp, it is much easier to close lacerations without having the suture material become entangled with hair. Hair that is inadvertently buried in wounds can result in wound infection.<sup>31</sup> Clipping hair around the wound with scissors and shaving with a recessed blade razor are techniques for hair removal that avoid dermal damage.

The only site from which hair is absolutely not shaved or clipped is the eyebrow (Fig. 7-1). Hair regrowth of the brow is unpredictable in many patients, and return to the original appearance cannot be guaranteed. Eyebrow hair can be cleansed readily, and the brow borders provide excellent landmarks for laceration alignment during wound closure.

### Anesthesia

Because wound cleansing can be uncomfortable if not outright painful, most wounds should be anesthetized before cleaning. Not only is the patient more comfortable, but also the



**Figure 7-1** Because hair grows inconsistently on the eyebrow, this structure is never shaved.

cleansing can be more vigorous and effective. Techniques for administering anesthetics are discussed fully in Chapter 6.

An issue that often arises concerning the administration of anesthetics before wound cleansing is whether bacteria can be embedded further into a wound if a needle is passed through a contaminated surface. There is no clear scientific evidence that needles can spread bacteria beyond the wound margins.<sup>32</sup> In clean, sharp wounds, this issue is of no concern, and direct wound infiltration can be carried out safely. For wounds that are visibly and heavily contaminated, the parallel injection technique or an appropriate nerve block can be used, if need be, to avoid this hypothetical complication.

### Foreign Material

As part of wound preparation, it is important to determine the presence or absence of foreign bodies in the wound. Foreign materials of all types should be considered harmful, with the potential for causing infection if left in the tissues. In addition, retained foreign objects are one of the most common reasons for malpractice suits brought against emergency physicians.<sup>33</sup> Although irrigation removes most debris, direct visualization and removal by instruments often are required. An alert patient can report the “sensation” of a foreign body still in the wound. Radiographs are particularly useful to find tooth fragments, metallic objects, and glass. It is a popular misconception that glass cannot be visualized by x-ray; 90% of all glass ( $\geq 0.5$  mm) can be detected by radiograph.<sup>35</sup> The removal of foreign bodies is discussed in more detail in Chapter 16.

### Wound Soaking

Wound soaking is a common practice in wound care. Soaking is believed to loosen debris, break up blood coagulum, and help sterilize the wound. Under experimental conditions, however, povidone-iodine solution was unable to penetrate beyond 1.5 mm of tissue despite 20 minutes of wound soaking.<sup>6</sup> Although bacterial counts are lowered with soaking in povidone-iodine solution, significant contamination remains. Wound soaking has some value in loosening, softening, and removing gross contaminants from the skin surrounding the wound, but it is not a substitute for thorough mechanical skin cleansing and wound irrigation.



## Wound Periphery Cleansing

The main purpose for periphery wound cleansing or “scrubbing” is to remove any visible contamination and dried blood. Periphery cleansing alone is insufficient for wound preparation without accompanying irrigation. The end point of skin cleansing is when the area surrounding the wound or laceration is visibly clean. There is no fixed scrubbing time. If the skin itself cannot be cleansed of all particulates, the risk for “tattooing” increases. Visible particulate matter “ground” into the skin can become permanently entrapped within the epidermis and dermis of the skin. These particulates need to be removed by sharp débridement. Because tattooing can have serious cosmetic consequences on the face, consultation and referral to a facial plastic surgeon should be considered if routine measures fail.

Scrubbing within the wound itself is controversial. In experimental wounds, scrubbing with surgical sponges has not been shown to decrease the incidence of infection and may produce mechanical trauma to the exposed tissues.<sup>19</sup> The mechanical action of a surgical sponge can be effective in removing gross contaminants and debris from within a wound. Because of the potential for tissue damage, scrubbing within a wound is best reserved for wounds with visible contaminants. The porosity of the surgical sponges used for wound cleansing is also an issue. The standard, common surgical sponge has 45 pores per linear inch. Sponges with 90 pores per linear inch (Optipore) are less irritating to tissues.<sup>21</sup> If handled gently, standard sponges are minimally traumatic, and the increased expense of higher porosity sponges may not justify their use.

## Irrigation

“The solution to pollution is dilution” is an old maxim of wound care that still rings true today. Wound irrigation is the most effective way to remove debris and contaminants from within a laceration.<sup>18</sup> Irrigation also is the most effective method of reducing bacterial counts on wound surfaces.<sup>35,36</sup> In comparing methods of irrigation for highly contaminated wounds, high-pressure streams (5 to 70 psi) of saline are clearly superior to low-pressure streams, such as those that might be obtained with a bulb-type syringe (0.5 to 1 psi).<sup>37</sup> Current practice is based on work done with a 35-mL syringe attached to a 19G catheter.<sup>27</sup> This system develops 7 to 8 psi and is effective in reducing debris and bacterial contamination from the types of wounds and lacerations managed by emergency caregivers. Pulsatile lavage, which develops 50 to 70 psi, is effective at lowering bacterial counts and wound infection rates.<sup>38</sup> Significant amounts of irrigation fluid can dissect well beyond the wound margins, however.<sup>39</sup> Pulsatile lavage systems are suited for larger, heavily contaminated wounds best managed by surgical specialists in the operating room.

Traditionally, saline has been used as the irrigant of choice. It is sterile and compatible with body tissues. More recently, its primacy as the best fluid for this task has been challenged. In a large prospective trial of 530 pediatric patients comparing saline with running tap water, there was no difference in wound infection rates between groups (2.8% versus 2.9%).<sup>39</sup> These were simple wounds with low levels of contamination. Further study of a wide range of wounds has to be carried out before irrigation with running tap water can become a recommended practice.

---

## CLEANSING SETUP AND PROCEDURES

The following are suggested guidelines for wound cleansing and preparation:

- *Patient position:* As in any procedure, proper preparation is essential. The patient is placed in a comfortable position, usually supine (see Fig. 2-1). It is impossible to predict how the patient will react to the discomfort of wound cleansing, the sight of blood, or the appearance of a wound. Vasovagal reactions (fainting) can occur if the

patient is upright. Patients can sustain injuries by falling to the floor during the procedure. It also is prudent to ask relatives to leave the area or at least to monitor their response to blood and the procedures that are being performed. Onlookers can experience vasovagal syncope as well.

- **Anesthesia:** For the most part, a wound or laceration should be anesthetized before periphery cleansing and irrigation. The pain of cleansing can inhibit the operator and lead to poor cooperation from the patient. The result is an incompletely cleansed wound.

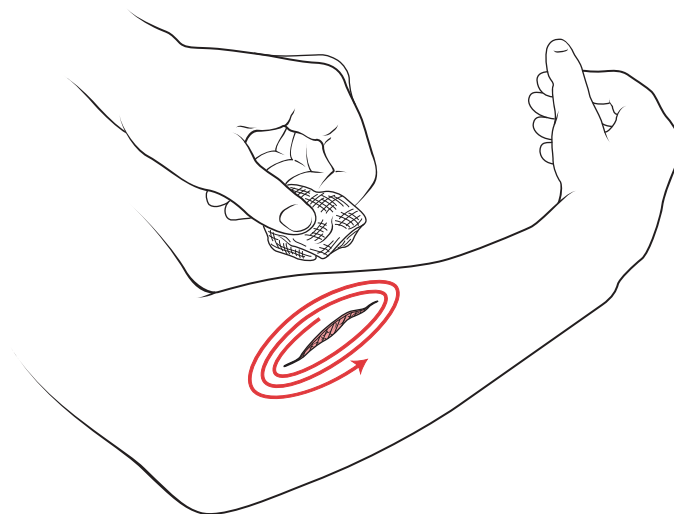
- **Supplies and set-up:**

A single medium or large metal basin can be used for periphery cleansing and irrigation. A solution of 10 to 20 parts saline and 1 part 10% povidone-iodine solution is mixed in the bowl.

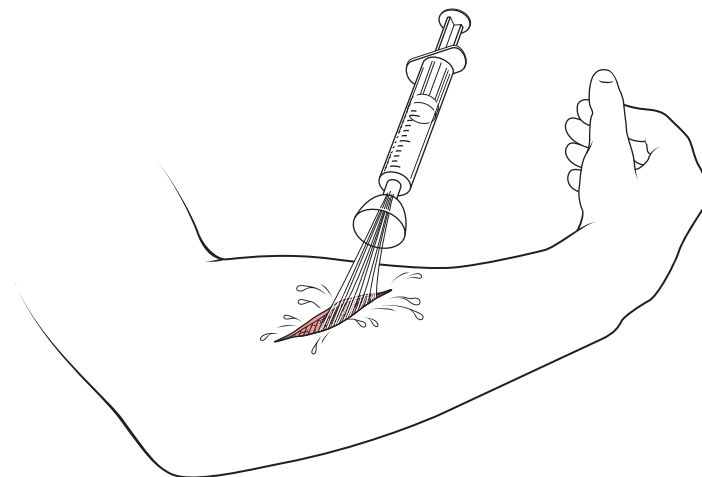
A packet of several  $4 \times 4$  surgical sponges can be placed directly in the solution or to the side of the bowl.

A 20- to 35-mL syringe attached to a Zerowet splash shield is recommended for irrigation. This shield reproduces the 5 to 8 psi of an 18G or 19G catheter. If the Zerowet shield is unavailable, a splash guard can be fashioned out of a  $4 \times 4$  sponge pierced in the center by an intravenous catheter. Another option is to puncture the bottom of a plastic medicine cup and place it over the syringe and needle or catheter. The Zerowet has been shown to be effective for caregiver protection from irrigant splatter.<sup>27</sup>

- **Cleansing technique:** The sponges are used for periphery cleansing and discarded after use. Soiled sponges are never returned to the bowl. If there is significant contamination or debris within the wound itself, the sponges can be used for mechanical, in-the-wound débridement. The technique for scrubbing the wound periphery is illustrated in Figure 7-2. It is essential to be gentle and to start at the wound itself. The cleansing motion is circular, with gradually larger circles away from the wound. The sponge is then discarded. At no time should the sponge be brought from the periphery back toward the wound; this maneuver carries unwanted



**Figure 7-2** Note the spiral technique of scrubbing a wound periphery by beginning at the center and moving away to the periphery without crossing back over the actual wound area.



**Figure 7-3** Technique for wound irrigation. The shield is held close to the wound.

organisms from unsterile skin areas back to the area of the cleansed wound site. There is no specified amount of time for periphery cleansing. Scrubbing continues until the skin is visibly free of contaminants and dried blood.

- **Irrigation:** After periphery cleansing, the wound is irrigated with the syringe and splash shield (Fig. 7-3). Periphery cleansing and irrigation can be alternated until there are no visible skin or wound contaminants. The amount of irrigation fluid can vary from 100 to 250 mL or more, depending on the level of contamination of the wound. The syringe and splash shield are held close to the wound so that the force of the stream is not dissipated by distance. Whatever cannot be irrigated out of the wound is removed by mechanical scrubbing with a sponge or sharp débridement.
- **Débridement:** If visible contamination remains despite thorough cleansing and irrigation, sharp débridement is carried out with tissue scissors or a surgical scalpel with a no. 15 blade. Ultimately, other strategies, such as wound excision, might be necessary to handle wounds that cannot be managed with these steps. Strategies for the difficult wound are discussed in Chapter 9.

Cleansing is complete and a wound is ready to close when, literally, the wound looks clean to the eye. There should be no visible contaminants, and the tissue should appear pink and viable. Usually there is slight fresh bleeding. A sterile sponge can be laid over the wound until the operator is ready to proceed with repair.

## REFERENCES

1. Berry AR, Watt B, Goldacre MJ: A comparison of the use of povidone-iodine and chlorhexidine in the prophylaxis of postoperative wound infection, *J Hosp Infect* 3:55-63, 1982.
2. Custer J, Edlich RF, Prusak M, et al: Studies in the management of the contaminated wound, *Am J Surg* 121:572-575, 1971.
3. Kaul A, Jewett J: Agents and techniques for disinfection of the skin, *Surg Gynecol Obstet* 152:677-685, 1981.
4. Valente JH, Forti RJ, Freundlich LF, et al: Wound irrigation in children: saline solution or tap water? *Ann Emerg Med* 41:609-616, 2003.
5. Dire DJ, Welch AP: A comparison of wound irrigation solutions used in the emergency department, *Ann Emerg Med* 19:704, 1990.
6. Gravett A, Sterner S, Clinton J, et al: A trial of povidone-iodine in the prevention of infection in sutured lacerations, *Ann Emerg Med* 16:167-171, 1987.

7. Howell JM, Stair TO, Howell AM, et al: The effect of scrubbing and irrigation with normal saline, povidone iodine, and ceftazolin on wound bacterial counts in a guinea pig model, *Am J Emerg Med* 11:134-138, 1993.
8. Harvey S: Antiseptics and disinfectants; fungicides; ectoparasiticides. In Goodman A, Goodman L, Gilman A, editors: *The pharmacologic basis of therapeutics*, New York, 1980, Macmillan.
9. Dineen P: Hand washing degerming: a comparison of povidone-iodine and chlorhexidine, *Clin Pharmacol Ther* 23:63-67, 1978.
10. Synder I, Finch R: Antiseptics, disinfectants, and sterilization. In Craig C, Stitzel R, editors: *Modern pharmacology*, Boston, 1982, Little, Brown.
11. Jue J, Stevens P, Hedberg K, Modesitt S: HIV seroprevalence in emergency department patients, *Acad Emerg Med* 2:773-783, 1995.
12. Faddis D, Daniel D, Boyer J: Tissue toxicity of antiseptic solutions, *J Trauma* 17:895-897, 1977.
13. Berk WA, Welch RD, Bock BF: Controversial issues in clinical management of the simple wound, *Ann Emerg Med* 21:72-80, 1992.
14. Caldwell DR, Kasti PR, Cook J, et al: Povidone-iodine: its efficacy as a preoperative conjunctival and periocular preparation, *Ann Ophthalmol* 16:577-588, 1984.
15. Shelanski H, Shelanski M: PVP-iodine: history, toxicity, and therapeutic uses, *J Int Coll Surg* 25:727-734, 1956.
16. Cawthorn SJ, Parums DV, Gibbs NM, et al: Extent of mesorecta spread and involvement of lateral resection margin as prognostic factors after surgery for rectal cancer, *Lancet* 333:1055, 1990.
17. Bryant CA, Rodeheaver GT, Reem EM, et al: Search for a nontoxic surgical scrub solution of periorbital lacerations, *Ann Emerg Med* 13:317, 1984.
18. Edlich RF, Rodeheaver GT, Morgan RF, et al: Principles of emergency wound management, *Ann Emerg Med* 17:1284-1302, 1988.
19. Rodeheaver GT, Smith SL, Thacker JG: Mechanical cleansing of contaminated wounds with a surfactant, *Am J Surg* 129:241, 1975.
20. White J, Duncan A: The comparative effectiveness of iodophor and hexachlorophene surgical scrub solutions, *Surg Gynecol Obstet* 135:890-892, 1972.
21. Edlich RF, Rodeheaver GT, Thacker JG, et al: Technical factors in wound management: fundamentals of wound management in surgery, South Plainfield, NJ, 1977, Chirurgecom, Inc.
22. Gruber RP, Vistnes L, Pardoe R: The effect of commonly used antiseptics on wound healing, *Plast Reconstr Surg* 55:472, 1975.
23. Lau HY, Wong SH: Randomized, prospective trial of topical hydrogen peroxide in appendectomy wound infection, *Am J Surg* 142:393-397, 1981.
24. Pecora D, Landis R, Martin E: Location of cutaneous microorganisms, *Surgery* 64:1114-1117, 1968.
25. Meengs MR, Giles BK, Chisholm CD, et al: Hand washing frequency in an emergency department, *Ann Emerg Med* 23:1307-1312, 1994.
26. Hillburn J, Hammond BS, Fendler EJ: Use of alcohol hand sanitizer as an infection control strategy in an acute care facility, *Am J Infect Control* 31:109-116, 2003.
27. Sloan EP, McGill BA, Zalenski R, et al: Human immunodeficiency virus and hepatitis B virus seroprevalence in an urban trauma population, *J Trauma* 38:736-741, 1995.
28. Cruse P, Foord R: A five-year prospective study of 23,649 surgical wounds, *Arch Surg* 107:206-209, 1973.
29. Seropian R, Reynolds B: Wound infections after preoperative depilatory versus razor preparation, *Am J Surg* 121:251-254, 1971.
30. Winston KR: Hair and neurosurgery, *Neurosurg* 31:320-329, 1992.
31. Mahlor D, Rosenberg L, Goldstein J: The fate of buried hair, *Ann Plast Surg* 5:131-138, 1980.
32. Kelly AM, Cohen M, Richards D: Minimizing the pain of local infiltration anesthesia for wounds by injection into the wound edges, *J Emerg Med* 12:593, 1994.
33. Trautlein JJ, Lambert RL, Miller J: Malpractice in the emergency department—review of 200 cases, *Ann Emerg Med* 13:709-711, 1984.
34. Tandberg D: Glass in the hand and foot, *JAMA* 248:1872-1874, 1982.
35. Madden J, Edlich RF, Schauerhamer R, et al: Application of principles of fluid dynamics to surgical wound irrigation, *Curr Top Surg Res* 3:85, 1971.
36. Rodeheaver GT, Pettry D, Thacker JG, et al: Wound cleansing in high pressure irrigation, *Surg Gynecol Obstet* 141:357, 1975.
37. Stevenson TR, Thacker JG, Rodeheaver GT, et al: Cleansing the traumatic wound by high pressure syringe irrigation, *J Am Coll Emerg Physicians* 5:17, 1976.
38. Pigman EC, Karch DB, Scott JL: Splatter during jet irrigation cleansing of a wound model: a comparison of three inexpensive devices, *Ann Emerg Med* 22:1563-1567, 1993.
39. Wheeler CB, Rodeheaver GT, Thacker JG, et al: Side effects of high pressure irrigation, *Surg Gynecol Obstet* 143:775, 1976.

# Instruments and Suture Materials

## BASIC INSTRUMENTS AND HANDLING

Needle Holders  
Forceps and Skin Hooks  
Scissors  
Hemostats  
Knife Handles and Blades

## SUTURE MATERIALS

Absorbable Suture Materials  
Nonabsorbable Suture Materials

## NEEDLE TYPES

It is not necessary to have large numbers of instruments and suture materials for emergency wound care. Wounds and lacerations can be managed with a few well-chosen instruments and a few wound closure products. Although the type of instruments remains relatively constant, each wound has differing requirements for wound closure materials. Absorbable and nonabsorbable sutures and a variety of wound tapes and staples can be selected according to the specific patient problem. In the future, wound adhesives are likely to come into widespread use. The following are guidelines for the selection of suture materials and the choice and proper handling of instruments. Tapes, staples, and adhesives are discussed in Chapter 14.

## BASIC INSTRUMENTS AND HANDLING

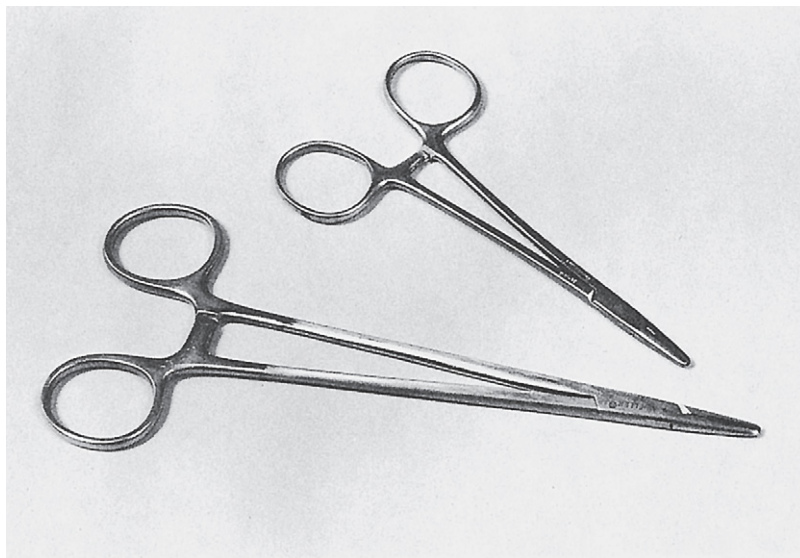
Wound care can be carried out with the following set of instruments: needle holders, tissue forceps, skin hooks, suture scissors, iris (tissue) scissors, hemostats, a knife handle, and appropriate knife blades. For simple lacerations that do not require sharp débridement or revision, a needle holder, forceps, and suture scissors suffice. A bewildering array of instruments is currently available through the major suppliers of surgical instruments, but only the types and configurations of instruments necessary to manage wounds and lacerations are discussed here. Also, numerous disposable instrument sets meet the needs of many emergency wound care problems.

### Needle Holders

Because most lacerations are closed with relatively small suture materials, the needle holder need not be bulky or large. A 4½-inch Webster needle holder with serrated carbide-tipped jaws can accommodate most curved suture needles (Fig. 8-1). Occasionally, large needles are used, and a 6-inch Webster needle holder is necessary.

### *Technique for Handling Needle Holder*

Just as important as the choice of needle holder is the technique used for holding and arming it with the needle. Figure 8-2 shows the right way and wrong way to hold the instrument during introduction of the needle into tissue for routine emergency laceration closure.



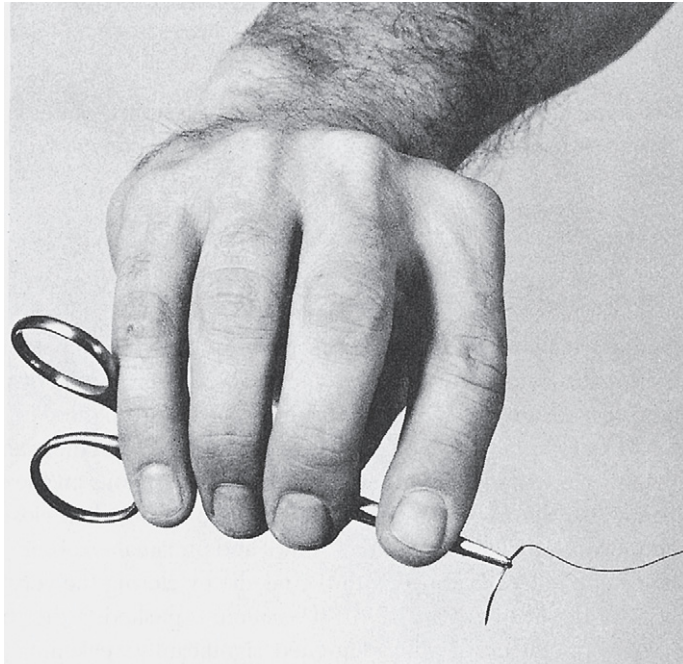
**Figure 8-1** Needle holders used in emergency wound care: 4½-inch and 6-inch Webster-style needle holders with serrated carbide-tipped jaws.

The rings are used only to clamp and unclamp the jaws by closing and releasing the locking mechanism. When introducing the needle into the skin, better precision can be gained by grasping the needle holder close to the jaws in the manner illustrated. This precision is particularly important when closing lacerations on the face. The technique of maintaining the fingers in the ring is more common when closing cosmetically less important surgical incisions or large truncal and proximal extremity wounds.

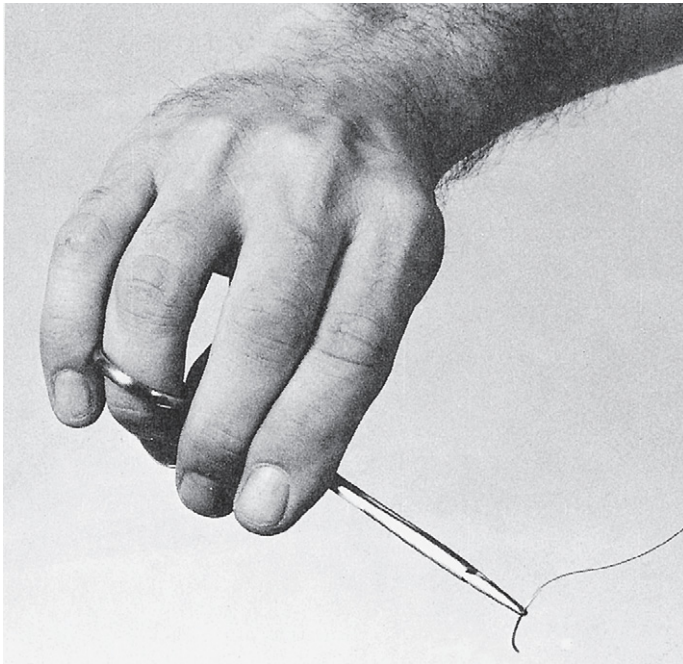
The needle holder is armed with the needle by closing the tip of the jaws onto the body of the needle (Fig. 8-3). If the needle is pushed farther back into the jaws of the instrument, the curve is flattened, significantly weakening the needle and making it susceptible to breakage. The needle itself is grasped at right angles, approximately one third of the way down the body shaft from the end to which the suture is attached.

### Forceps and Skin Hooks

Grasping and controlling tissue with forceps or skin hooks during skin closure is essential to proper suture placement. Whenever force is applied to skin or other tissues, however, inadvertent damage to cells can occur if an improper instrument or technique is used. Skin hooks are preferable to forceps because the “crushing” or “pincer” effect of forceps is eliminated. Proper use of skin hooks requires considerable skill and practice. Forceps still are widely used and are safe when proper technique is applied. The currently recommended forceps are 4¾-inch Adson forceps with small teeth (Fig. 8-4). Teeth decrease the need to apply excessive force to grasp and secure tissue. Forceps without teeth are to be discouraged because the flat surface of their jaws tends to crush tissue more easily.

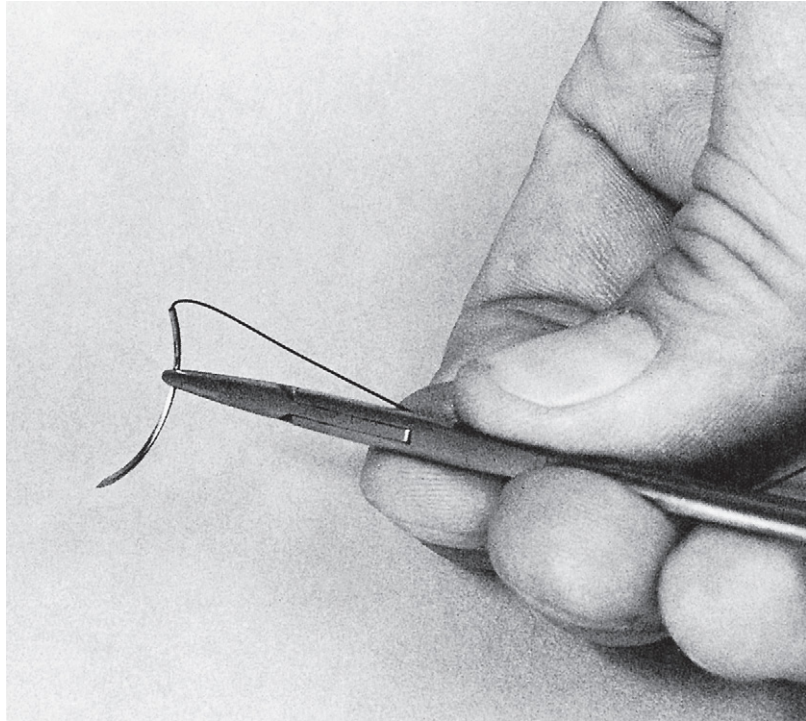


A

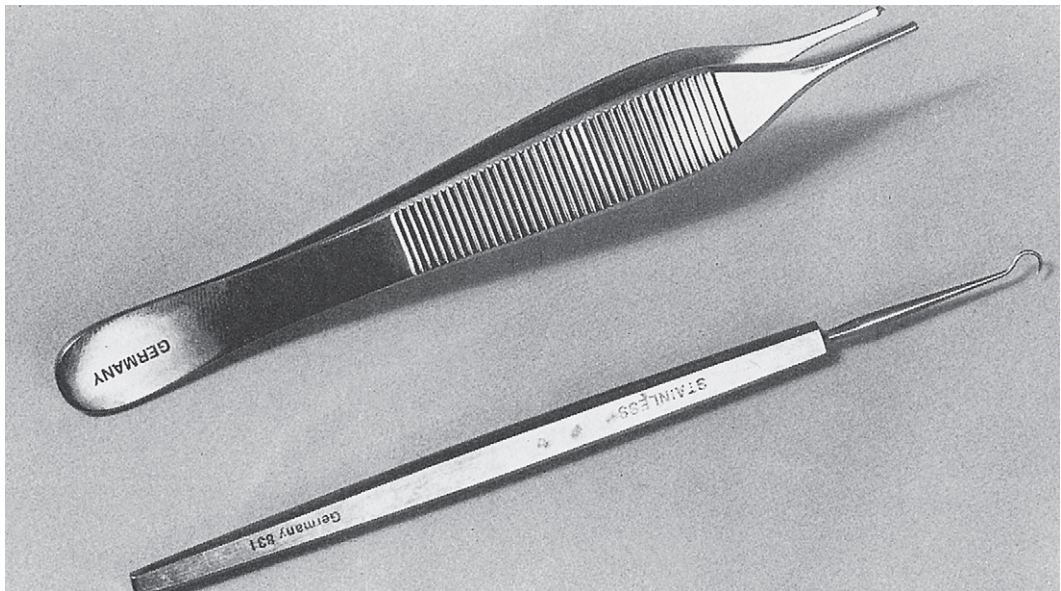


B

**Figure 8-2** Technique for properly holding the needle holder. **A**, The correct way allows for proper needle entry into the skin. **B**, The incorrect way—the finger holes are not used when introducing the needle holder into the skin.



**Figure 8-3** Technique for arming a needle holder. The needle is held approximately one third of the way from the swage and is grasped at the tip of the needle holder. The angle of the needle to the holder is exactly 90 degrees.



**Figure 8-4** Tissue grasping instruments: 4 $\frac{3}{4}$ -inch Adson forceps with fine teeth, and standard plastic skin hook.

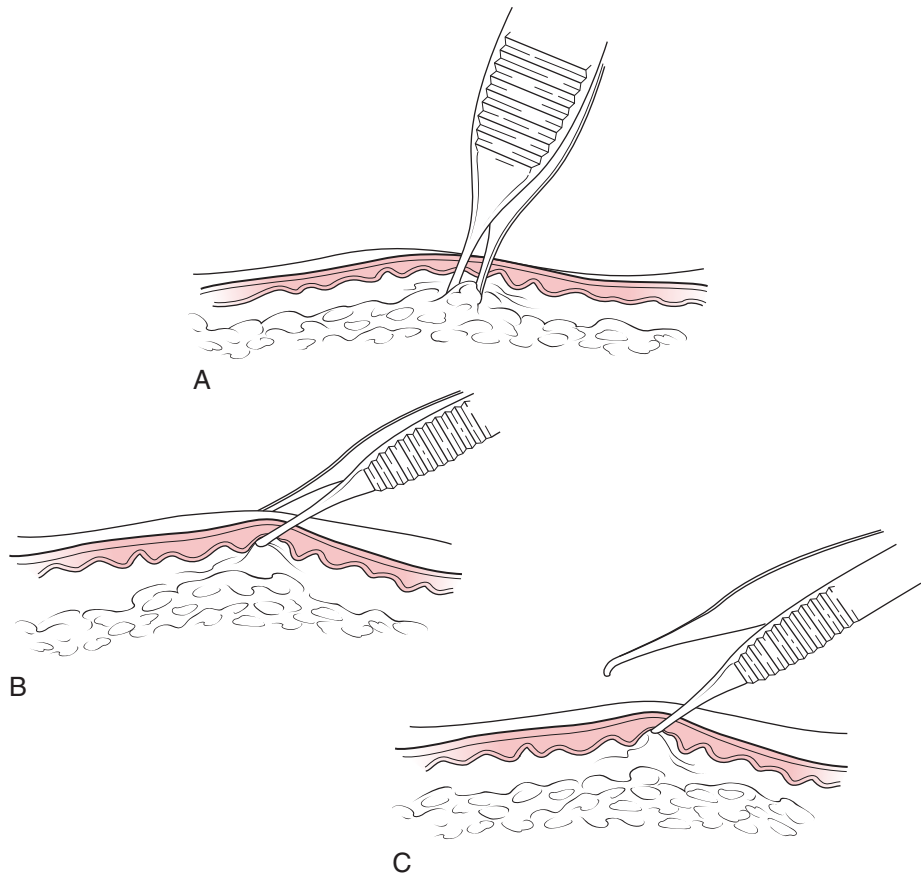


### Technique for Handling Forceps


When handling tissue, the jaws of the forceps are never closed on skin itself. The epidermis and dermis are avoided in favor of the superficial fascia (subcutaneous tissue). By grasping superficial fascia gently, the wound edge is stabilized for needle placement and inadvertent damage to the dermis is avoided (Fig. 8-5). Forceps also can serve as a surrogate skin hook as illustrated. The needle entry point can be immobilized and supported without closing the jaws.

Figure 8-6 illustrates the correct and incorrect methods for grasping forceps. The “pencil grasp” technique allows for better control of the forceps and tends to diminish the amount of force delivered to the tissue.

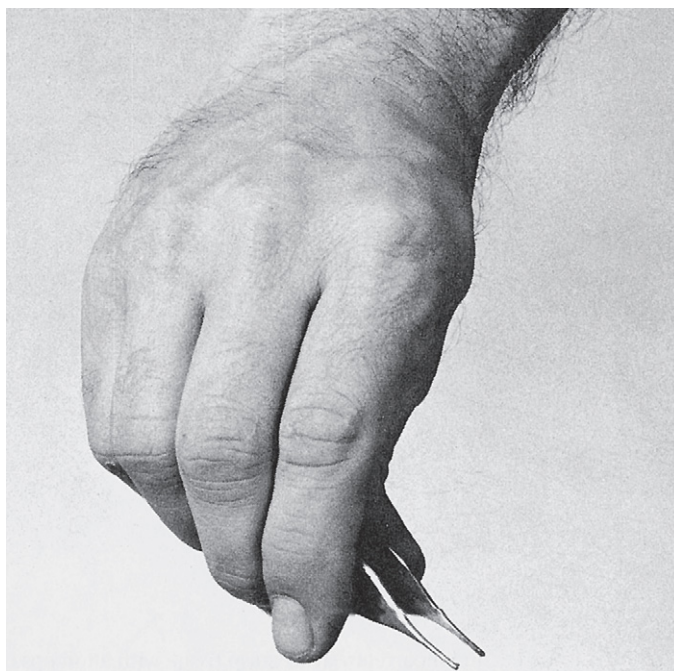
Skin hooks have the appearance of miniature retractors, but the hook portion has pointed tips to control dermis or superficial fascia. Piercing the epidermis is avoided because it can create an unnecessary puncture mark. Skin hooks are inserted directly into the wound, and the hook portion is used to gain purchase on the dermis or superficial fascia. In this manner, the epidermis is avoided.



**Figure 8-5** The correct and incorrect way to grasp tissue with a forceps. **A**, The correct way is to grasp the tissue by the superficial fascia (subcutaneous tissue). **B**, The incorrect way to grasp tissue is by crushing the dermis and epidermis between the jaws of the forceps. **C**, Forceps can be used like a skin hook to retract or stabilize the wound edge for exploration or suture needle placement.

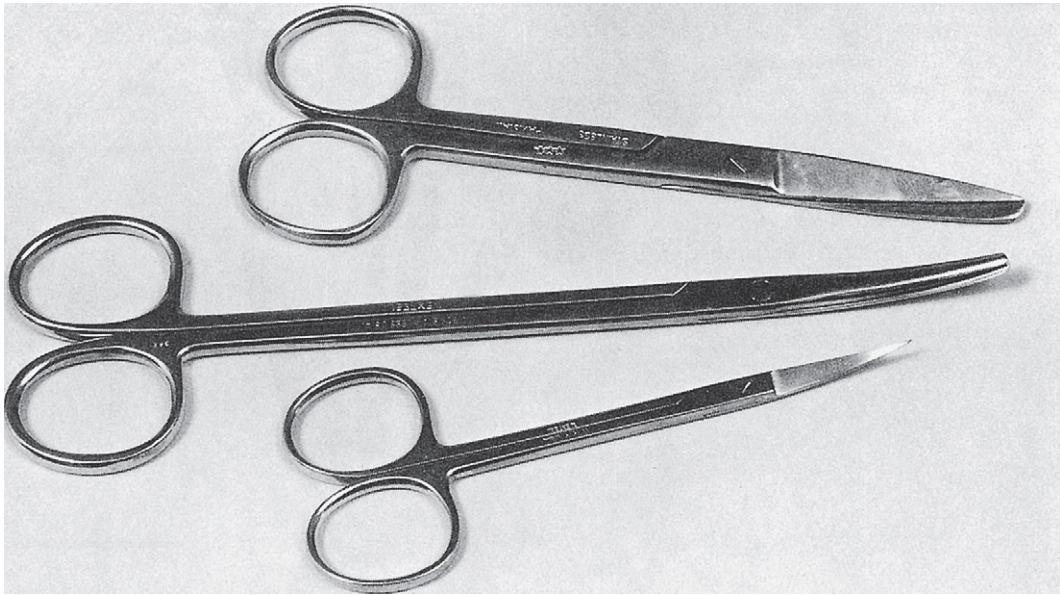


A



B

**Figure 8-6** The correct and incorrect way to hold the forceps manually. **A**, The forceps is held in the pencil grasp fashion as the correct technique. **B**, The incorrect technique is to grasp the forceps.



**Figure 8-7** Scissors. All-purpose suture scissors (*top*); Metzenbaum dissection scissors (*middle*); curved iris or tissue scissors (*bottom*).

## Scissors

Three types of scissors are useful in emergency wound care: iris or tissue scissors, dissection scissors, and suture scissors (Fig. 8-7). Curved and straight, 4-inch iris scissors are used to assist in débridement and wound revision. These scissors are extremely sharp and provide excellent precision in cutting tissue for whatever task. They are delicate, however, and are not recommended for cutting sutures. Occasionally, when small sutures have been used in the face area, iris scissors can be used for their removal.

For heavier tissue revision, as might be necessary for wound undermining, blunt-tipped, 6-inch Metzenbaum dissection scissors are recommended. Iris scissors are too small and delicate for this task, and the larger Metzenbaum scissors can overcome this shortcoming.

Standard 6-inch, single blunt-tip, double-sharp suture scissors are most useful for cutting sutures, adhesive tape, sponges, and other dressing materials. Because of their size and bulk, these scissors are durable and practical.

### *Technique for Scissor Tip Control*

Whenever scissor tip control is essential, such as cutting close to the knots of deep or dermal closures with absorbable sutures, the technique illustrated in Fig. 8-8 is recommended. The tips of the scissors are brought gently down to the knot. Just before cutting, the tips are rotated slightly to avoid cutting the knot itself.

## Hemostats

Hemostats have three functions in emergency wound care. Originally, hemostats were designed to clamp small blood vessels for hemorrhage control. Another use is to grasp and secure superficial fascia during undermining and débriding wounds. Finally, this instrument



**Figure 8-8** Proper technique for tip control for scissors.

is an excellent tool for exposing, exploring, and visualizing the deeper areas of a wound. Two types of hemostats commonly are used in wound care (Fig. 8-9). For general use, the standard hemostat is recommended. Finer work in small wounds is often best served by the 5-inch curved mosquito hemostat with fine serrated jaws.

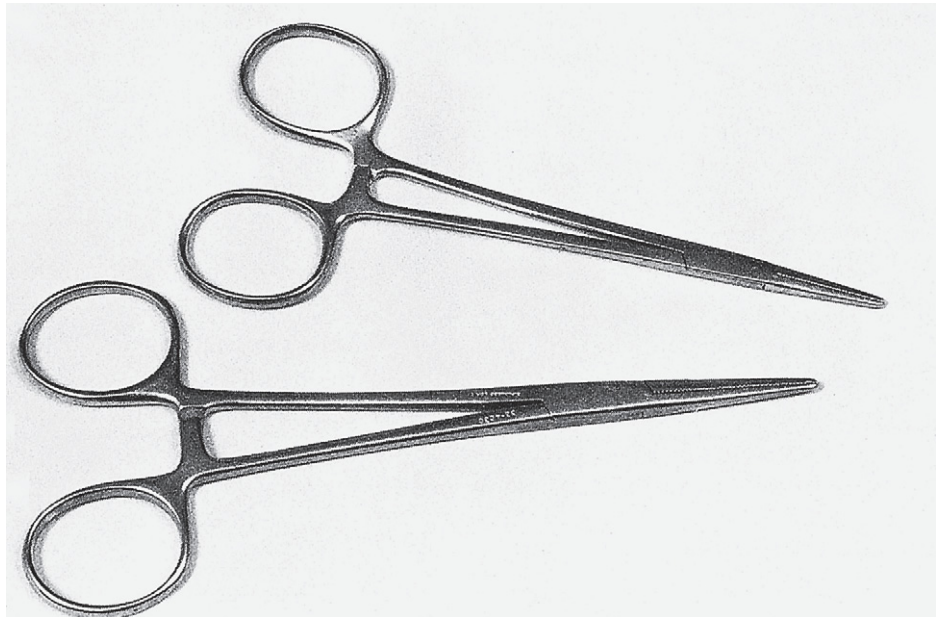
### **Knife Handles and Blades**

The choice of a knife handle can be limited to the no. 3 standard Bard/Parker-style knife handle. Generally, three blade configurations are necessary for a variety of tasks (Fig. 8-10). The no. 10 blade is not usually needed in emergency wound care but occasionally is helpful for larger excisions during wound revision. Commonly used and quite versatile is the no. 15 blade, which is small and well suited for precise débridement and wound revision. This blade also is preferred for foreign-body excision and the intricate work necessary around eyes, lips, ears, and fingertips. The no. 11 blade is configured ideally for incision and drainage of superficial abscesses. It also can be used to help remove small sutures such as might be placed in the face.

---


### **SUTURE MATERIALS**

Several criteria must be met before a particular suture can be used to close a laceration. A good suture must have appropriate tensile strength to resist breakage, good knot security



**Figure 8-9** Hemostats. Mosquito hemostat (*top*); standard hemostat (*bottom*).

to prevent unraveling, pliability and workability in handling, low tissue reactivity, and the ability to resist bacterial infection. Currently, there are two main classes of suture materials: absorbable and nonabsorbable. In general, absorbable sutures are placed deep for closure of dead space in large wounds or to reduce closure tension. Nonabsorbable sutures are used most commonly for percutaneous or skin closure.



**Figure 8-10** Knife handle and no. 11 (*left*), no. 10 (*middle*), no. 15 (*right*) knife blades.

### Absorbable Suture Materials

Polyglycolic acid (PGA) (Dexon) currently is in widespread use as an absorbable suture material (Table 8-1). PGA is a synthetic, braided polymer. When compared with plain or chromic catgut, PGA is much less reactive and is experimentally better able to resist infection from contaminating bacteria.<sup>1</sup> PGA has excellent knot security and maintains at least 50% of its tensile strength for 25 days.<sup>2</sup> The main drawback of PGA is that it has a high friction coefficient and “binds and snags” when wet. For this reason, some experience is required to pass this material properly through tissues and “seat” the throws during knotting.

The manufacturer has modified PGA (Dexon Plus) by coating it with poloxamer 188, an agent that significantly reduces the friction and drag through tissues. Although handling has become easier with this modification, more throws (four to six) are required to prevent knot slippage than for plain PGA (three to four). The main uses of PGA are for deep closures of superficial fascia (subcutaneous tissue) in wounds and ligation of small bleeding vessels to effect hemostasis.

TABLE 8-1 *Absorbable Suture Materials*

Material	Structure	Tissue Reaction	Tensile Strength	Tissue Half-Life (Days)	Uses and Comments
Gut	Natural	++++	++	5-7	For mucosal closures, rarely used
Chromic gut	Natural	++++	++	10-14	For oral mucosa, perineal, and scrotal closures; can be annoying to patients because of stiffness
Polyglycolic acid (Dexon)	Braided	++	+++	25	For subcutaneous closure; coated version easier to use but requires more knots (Dexon-Plus)
Polyglactin 910 (Vicryl)	Braided	++	++++	28	Comes dyed and undyed; do not use dyed on face; irradiated polyglactin excellent for mucosal closures
Polyglyconate (Maxon)	Monofilament	+	+++++	28-36	For subcutaneous closure; less reactive and stronger than polyglycolic acid and polyglactin
Polydioxanone (PDS)	Monofilament	+	++++	36-53	For subcutaneous closures that need high degree of security; stiffer and more difficult to handle than polyglycolic acid or polyglyconate

An older and less commonly used absorbable suture material is gut. Gut is an organic material manufactured from sheep intestines. A newer form of this suture is gut treated with chromium trioxide to retard absorption in tissues. Compared with PGA, plain gut and chromic gut appear to have inferior tensile strength and wound security.<sup>3,4</sup> The main use of chromic gut is to close lacerations within the oral mucosa, perineum, and scrotal skin. Wounds within the bounds of the oral cavity tend to heal rapidly and do not require prolonged suture support. Chromic gut is absorbed more rapidly than PGA on the oral mucosa and does not require suture removal.<sup>5</sup>

Polyglactin-910 (Vicryl) is braided synthetic polymer also used for deep closures. It has similar dry tensile strength compared with PGA but maintains *in vivo* strength somewhat longer. However, PGA has greater knot security. Polyglactin-910 can be modified by irradiation, which greatly increases its tissue absorption.<sup>6</sup> This quality makes polyglactin-910 ideal for closure of oral mucosa, scrotal skin, scalp, and perineum. The suture can be placed, and because of rapid absorption, no return visit is necessary for removal.

Two monofilament absorbable suture materials, polyglyconate (Maxon) and polydioxanone (PDS), have some advantages over PGA and polyglactin-910. The main advantage of these suture materials is that they maintain their *in vivo* tensile strength longer than PGA and the other absorbable suture materials.<sup>1,7</sup> They also appear to have greater knot security and lower friction coefficients. Polyglyconate is less stiff and easier to handle than polydioxanone. Because they are monofilaments, they enjoy the theoretical advantage of creating a lower potential for infection.

An irradiated polyglactin-910, Vicryl-Rapide,<sup>8</sup> is an important and versatile absorbable suture material. It breaks down and is absorbed within 7 to 10 days. Its major advantage is that it can be used for skin closure without the need for removal. When Vicryl-Rapide was used to close skin around the orbit, the results were excellent.<sup>9</sup> The most important finding was that there were no suture marks visible at 2 months after repair. Similar results have been found with scalp lacerations.<sup>10</sup> It also can be used in intraoral and vaginal mucosa wound closures.

A newer, effective absorbable suture is poliglecaprone (Monocryl).<sup>11</sup> This suture material has a high initial tensile strength and low tissue reactivity. It has excellent handling characteristics, with low friction and good knot security. Another intriguing finding is that Monocryl causes less hypertrophic scar formation compared with Vicryl-Rapide.<sup>12</sup> Monocryl is a monofilament, whereas Vicryl-Rapide is multifilament, and this difference might account for the reduced scar formation. With many patients with this tendency, it is important know that there is a suture material with a lower potential for hypertrophic scar formation.

### Nonabsorbable Suture Materials

Of all the nonabsorbable suture materials, monofilament nylon (Ethilon, Dermalon) is used most commonly for surface, percutaneous closure (Table 8-2). The monofilament configuration makes it minimally tissue reactive and able to resist infection from experimental wound contamination compared with braided suture material.<sup>2</sup> Nylon has tensile strength that ensures wound security. The main disadvantage of nylon is the difficulty in achieving good knot security. Because monofilaments have greater memory (the tendency to return to their packaged shape) than braided sutures, they tend to unravel if not tied correctly. At least four to five carefully fashioned "throws" or knots are required to achieve a secure final knot.

The polymer polypropylene (Prolene) is another nonabsorbable monofilament. Polypropylene appears to be stronger than nylon and has better overall wound security.<sup>4</sup> It also is less reactive and is able to resist infection at least as well as nylon.<sup>2</sup> It has greater memory than nylon, however, and is more difficult to work with. The main uses of polypropylene are for percutaneous and subcuticular pull-out closures.

A newer monofilament suture material is polybutester (Novafil).<sup>13</sup> Polybutester appears to be stronger than other monofilaments. This material does not have significant

TABLE 8-2 *Nonabsorbable Suture Materials*

Material	Structure	Tissue Reaction	Tensile Strength	Knot Security	Uses and Comments
Silk	Braided	++++	++	++++	Easy to handle but has increased potential for infection
Nylon (Ethilon, Dermalon)	Monofilament	++	+++	++	Commonly used in skin closure but high degree of memory; requires several throws for secure closure
Polypropylene (Prolene)	Monofilament	+	++++	+	High degree of memory, low tissue adhesion; good for subcuticular pull-out technique
Dacron (Mersilene)	Braided	+++	++	++++	Easy to handle, good knot security; similar to silk but less risk to tissue for inflammation and infection
Polybutester (Novafil)	Monofilament	+	++++	++++	Excellent handling, strength, and security; expands and contracts with changes in tissue edema

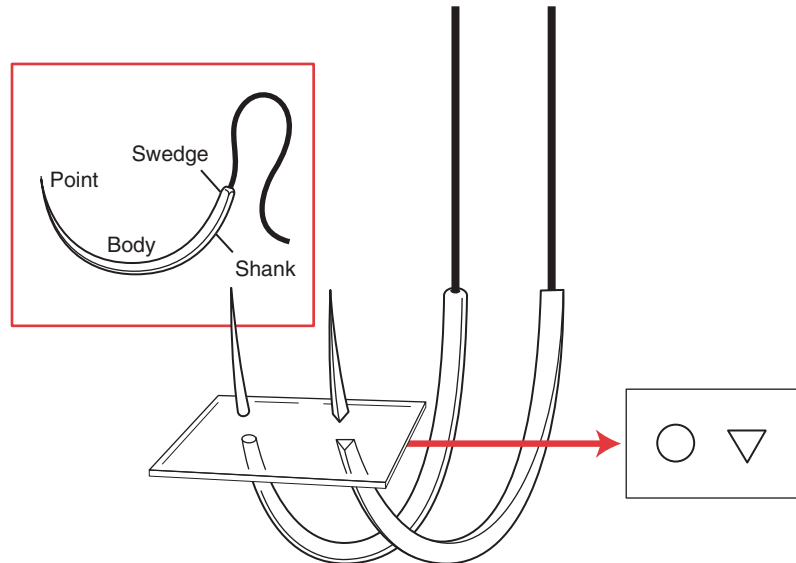
memory and does not maintain its packaging shape the way nylon and polypropylene do. For this reason, it is reported to be easier to work with, and it has greater knot security. A unique feature of polybutester is that it has the capacity to adapt or “stretch” with increasing wound edema. When the edema subsides, polybutester resumes its original shape. Compared with nylon, this suture material has a lower risk of causing hypertrophic scarring.<sup>14</sup> The ability to adapt to the swelling and changing configuration of a healing wound is credited for this reduction in risk.

Less commonly used for minor wound care problems are braided, nonabsorbable suture materials, including cotton, silk, braided nylon, and multifilament Dacron. Until the advent of synthetic fibers, silk was the mainstay of wound closure. It is the most workable of sutures and has excellent knot security. The usefulness and popularity of silk have declined, however, because of its propensity for causing tissue reactivity and infection.<sup>2,4</sup> Research has shown that, similar to silk, the braided synthetics have a greater tendency to cause wound infection when exposed to contaminating bacteria.<sup>2,15</sup> These materials have excellent workability and knot security, however. Because of the properties just mentioned, braided sutures are useful on the face, where maximal control and precision are needed. The earlier removal time of facial sutures and the natural resistance of the face to infection make the chance of inflammation and infection developing almost negligible.

## NEEDLE TYPES

Similar to instruments and suture materials, a bewildering array of needles is manufactured for wound closure. Most wound closures can be accomplished, however, with a few needles. Curved needles have two basic configurations: tapered and cutting (Fig. 8-11). For wound





**Figure 8-11** Basic needle configurations: The standard round, tapered needle (*left*); the reverse cutting needle (*right*). The sharp edge is on the convex portion of the needle.

and laceration care, the cutting needle is used almost exclusively. Needles that now are commonly referred to as cutting needles are reverse cutting needles. The needle is made in such a way that the outer edge is sharp so as to allow for smooth and atraumatic penetration of the skin, and the inner portion is flattened so that the needle puncture wound is not inadvertently enlarged as the suture passes through the hole and the knot is tied.

Needles come in two grades, cuticular and plastic. These grades differ significantly in their usefulness for wound care. Cuticular needles are less expensive but noticeably less sharp than plastic grade needles. The increased sharpness of plastic needles allows the operator to control entry and passage of the needle better through tissues. Plastic needles also are less traumatic. Although they are more expensive, these needles are recommended for emergency wound and laceration repair. There are a bewildering number of code designations for needles. Cuticular needles can be recognized by the letters *C* (cuticular) or *FS* (for skin). Plastic grade needle codes usually start with the letter *P*.

## REFERENCES

1. Bourne RB, Bitar H, Andreae PR: In vivo comparison of four absorbable sutures: Vicryl, Dexon Plus, Maxon, and PDS, *Can J Surg* 31:43-45, 1988.
2. Edlich R, Panek PH, Rodeheaver GT, et al: Physical and chemical configuration of sutures in the development of surgical infection, *Ann Surg* 177:679-687, 1973.
3. Howes E: Strength studies of polyglycolic acid versus catgut sutures of the same size, *Surg Gynecol Obstet* 137:15-20, 1973.
4. Swanson N, Tromovitch T: Suture materials 1980s: properties, uses, and abuses, *Int J Dermatol* 21:373-378, 1982.
5. Holt G, Holt J: Suture materials and techniques, *Ear Nose Throat J* 60:23-30, 1981.
6. Tandon SC, Kelly J, Turtle M, Irwin ST: Irradiated polyglactin 910: a new synthetic absorbable suture, *J R Coll Surg Edinb*, 40:185-187, 1995.
7. Rodeheaver GT, Powell TA, Thacker TJ, et al: Mechanical performance of monofilament synthetic absorbable sutures, *Am J Surg* 154:544-547, 1987.

8. Martelli H, Catena D, Rahon H: Skin sutures in pediatric surgery: use of a fast-resorbing synthetic thread, *Presse Med* 20:2194-2198, 1991.
9. Talbot AW, Meadows AE, Tyers AG, et al: Use of 7/0 Vicryl (coated polyglactin 910) and 7/0 Vicryl-rapide (irradiated polyglactin 910) in skin closure in ophthalmic plastic surgery, *Orbit* 21:1-8, 2002.
10. Aderriotis D, Sandor GK: Outcomes of irradiated polyglactin 910 Vicryl Rapide fast-absorbing suture in oral and scalp wounds, *J Can Dent Assoc* 65:345-347, 1999.
11. Labagnara J Jr: A review of absorbable suture materials in head and neck surgery and introduction of monocryl: a new absorbable suture, *Ear Nose Throat J* 74:409-415, 1995.
12. Niessen FB, Spauwen PH, Kon M: The role of suture material in hypertrophic scar formation: Monocryl vs. Vicryl-Rapide, *Ann Plast Surg* 39:254-260, 1997.
13. Bernstein G: Polybutester suture, *J Dermatol Surg* 14:615-616, 1988.
14. Trimbos JB, Smeets M, Verdel M, Hermans J: Cosmetic result of lower midline laparotomy wounds: polybutester and nylon skin suture in a randomized clinical trial, *Obstet Gynecol* 82:390-393, 1993.
15. Alexander J, Kaplan J, Altemeier W: Role of suture materials in the development of wound infection, *Ann Surg* 165:192-199, 1967.

# Decisions Before Closure: Timing, Débridement, and Consultation

## TIMING OF CLOSURE

Primary Closure (Primary Intention)  
 Secondary Closure (Secondary Intention)  
 Tertiary Closure (Delayed Primary Closure)

## WOUND EXPLORATION

Techniques for Wound Exploration

## HEMOSTASIS

Tourniquet Hemostasis

## TISSUE DÉBRIDEMENT AND EXCISION

Technique for Simple Excision and Wound Edge Revision  
 Technique for Full Wound Excision

## SURGICAL DRAINS

## IMMEDIATE ANTIBIOTIC THERAPY

## GUIDELINES FOR CONSULTATION

Standard of Care  
 Logistics of Care  
 Cosmetics and Patient Expectation  
 Continuity of Care

**B**efore proceeding with definitive management, such as suture placement, several issues have to be considered and decisions made that are separate from the choice of closure method. Time from the injury, tissue condition, level of contamination, and potential for foreign material all are factors that affect the total care. The following questions capture this phase of emergency wound care:

- What is the proper timing of wound closure—primary, open, or delayed?
- Which wounds need invasive exploration?
- What are the appropriate measures to achieve wound hemostasis to facilitate exploration and repair?
- When and how is a wound débrided?
- Under what conditions is a drain placed?
- What are the indications for immediate intravenous antibiotic administration?
- When should consultation be obtained?

## TIMING OF CLOSURE

Determining the time of injury is important for wound repair. The chance of developing a wound infection increases with each hour that elapses from the time of injury.<sup>1</sup> Traditionally, it has been taught that there is a “golden” period within which a wound or laceration can be

safely closed primarily (*primary intention*). The exact length of that period is influenced by factors such as the mechanism of injury, anatomic location, and level of contamination. As a rough guideline, 6 to 8 hours from the time of injury has been considered a safe time interval within which to repair the average uncomplicated laceration. This period can range from 3 hours for heavily contaminated wounds of the foot to 24 hours or more for clean lacerations of the face. A complete discussion of primary, secondary, and tertiary (delayed) closure is found in Chapter 4. The following is a summary with recommendations for wound closure.

### Primary Closure (Primary Intention)

Lacerations that are relatively clean and uncontaminated, with minimal tissue loss or devitalization, are considered for primary closure. Repair of these wounds usually is necessary within 6 to 8 hours from the time of injury on most regions of the body. Wounds of the highly vascular face and scalp often can be sutured 24 hours after injury.<sup>2</sup> Because there are no definitive rules that govern every possible situation, the following recommendation is offered: Any injury, regardless of the time from injury, that can be converted to a fresh-appearing, slightly bleeding, nondevitalized wound, with no visible contamination or debris after aggressive cleansing, irrigation, and débridement, can be considered for primary closure.

### Secondary Closure (Secondary Intention)

Skin infarctions, ulcerations, abscess cavities, punctures, small cosmetically unimportant animal bites, and partial-thickness (abrasions, second-degree burns) tissue losses often are better left to heal by secondary intention. Wound care consists of thorough cleansing, irrigation, and débridement of devitalized or contaminant-impregnated tissue. These wounds are not closed with sutures and are allowed to heal gradually by granulation and eventual reepithelialization.

### Tertiary Closure (Delayed Primary Closure)

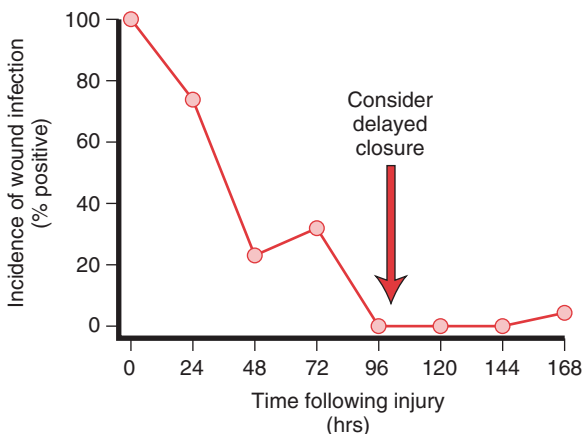
Some wounds are candidates for delayed closure.<sup>3</sup> Bite wounds and lacerations beyond the golden period can be considered for this technique. Although there are no technical contraindications to sutures or staples, these wounds have a high bacterial count and excessive devitalized tissue. In a study of human bites to the face, primary closure led to a 40% wound infection rate.<sup>4</sup> None of the wounds closed after débridement and 48 hours of antibiotics became infected. Delayed wounds can be “converted” to “fresh” ones by cleansing, irrigation, and débridement followed by a 3- to 5-day period during which the natural host defenses reduce the bacterial load to acceptable minimal levels (Fig. 9-1).<sup>3,5</sup> Antibiotics can aid these defenses.

### Technique for Delayed Primary Closure

The clinician cleanses, irrigates, and débrides as much as possible during the initial encounter. The wound is packed with saline-moistened, fine-mesh gauze or gauze sponges. The wound is covered with a bulky, absorbent gauze dressing. Oral antibiotics are administered after initial care before delayed closure. Dicloxacillin or a first-generation cephalosporin is appropriate. Erythromycin can be given to patients who have a significant history of allergy to the penicillins.

If no signs of infection or excessive discomfort develop beforehand, the patient should return in 4 to 5 days. If the wound appears clean and uninfected, it can be closed with sutures, tapes, or staples. Dermal (deep) or subcutaneous sutures are avoided in this setting. These wounds can accumulate excessive granulation tissue during the 4- to 5-day period. This tissue can be excised judiciously to permit better wound edge apposition. The intervals for suture or staple removal are the same as for primary closure starting at the time of closure. Delayed closure is associated with a low (2% to 3%) infection rate.<sup>5,6</sup>

**Figure 9–1** Graph showing the incidence of wound infection risk after injury and optimal timing of tertiary or delayed wound closure. (Adapted from Edlich R, Rodeheaver GT, Morgan RF, et al: A manual for wound closure, St Paul, Minn, 1979, Surgical Products Division, 3M.)



## WOUND EXPLORATION

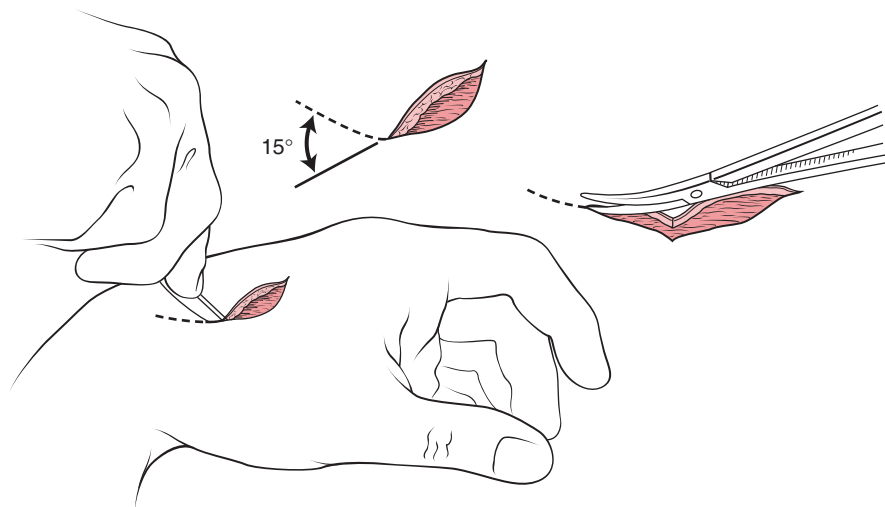
Surface wounds and lacerations require thorough inspection and direct exploration if necessary. It is always important to evaluate the functional status of the relevant nerves, tendons, arteries, joints, and other related structures of the wounded area and to remain alert for potentially occult, serious underlying structural damage. Although more specific information is included in other chapters and sections specific to special anatomic sites and problems, the following are general guidelines for wound exploration:

- Suspicion of a foreign body, particularly if it is potentially organic, such as wood or plant material. Radiographs are taken before exploration when glass, gravel, or metallic foreign bodies are suspected.
- Lacerations in the proximity of joint capsules.
- Lacerations over tendons, particularly if functional testing of the hand or foot is “normal.” It is common to find serious partial tendon lacerations solely by direct visualization. Unrepaired partially lacerated ( $\geq 50\%$ ) tendons can undergo delayed rupture within 12 to 48 hours if untreated.
- Scalp lacerations that are large or are caused by a significant force. Unrecognized skull fractures can be found by exploration and palpation of the skull through the wound.
- Lip lacerations, if a tooth or fragment of a tooth cannot be accounted for. A radiograph is another method to reveal missing teeth.

## Techniques for Wound Exploration

Often the wound can be exposed adequately with a hemostat by separation of the wound edges. In other cases, the hemostat can be used to grasp the superficial fascia (subcutaneous tissue) of one wound edge while the tissue forceps are applied to the other edge to retract and gain exposure. If available, small self-restraining retractors (mastoid or Wheatlander retractors) are recommended. A second pair of hands is optimal. An assistant can retract the wound with small retractors or skin hooks.

If exposure is still not adequate, a small wound extension incision can be made through the dermis with a knife handle and a no. 15 blade or with iris scissors. The extension begins at one wound end and should proceed carefully to avoid accidental injury to underlying



**Figure 9-2** Technique to extend a wound for better deep-structure exploration and evaluation. The incision is at a slight angle from the original axis of the wound and parallel to underlying structures.

structures (Fig. 9-2). On the face, extension incisions are made parallel to the skin tension lines discussed in Chapter 3. When the epidermis and dermis are divided, the superficial fascia (subcutaneous tissue) is not incised but is spread apart gently with forceps or tissue scissors to reveal any suspected foreign body or tendon or joint capsule injury.

## HEMOSTASIS

Wounds often bleed actively, particularly during assessment and exploration. In addition to the problem of adequate wound visualization with active bleeding, hematomas can cause an increase in the rate of wound infection and delay the healing process.<sup>7</sup>

The simplest and most effective way to stop bleeding is by applying direct pressure to the wound with hand-held surgical 4 × 4 sponges. Continuous pressure has to be applied for a minimum of 10 minutes. Because of the time involved, sponges secured with an Ace wrap can be substituted if the wound is in an anatomic area that lends itself to wrapping.

An epinephrine-moistened (1:100,000) sponge applied, also with pressure, to the wound for 5 minutes often suffices in cases in which direct pressure fails. Epinephrine is contraindicated, however, for use on the fingers, toes, ears, penis, and tip of the nose. Packing the wound with hemostatic gelatin foam (Gelfoam) is another hemostatic strategy. Gelfoam is useful only for persistent oozing or minor capillary bleeding. Arterial “pumpers,” even small ones, wash the Gelfoam out of the wound.

Direct clamping with a hemostat and a hand-tied ligature with an absorbable suture is reserved for larger, single-bleeding vessels that can be directly visualized under optimal conditions of lighting, instrument preparation, and operator comfort. “Blind” clamping in a bleeding wound, in hopes of grasping the bleeder, is strongly discouraged. Unnecessary tissue damage can occur, particularly in areas where important structures such as nerves and tendons are likely to be found.

Definitive hemostasis of the extremity can be achieved by the use of tourniquets. Strict observance of proper technique and the time limits of application is imperative.

Complications of tourniquets include ischemia of the extremity, compression damage of blood vessels and nerves, and jeopardy to marginally viable tissues.<sup>8</sup>

### **Tourniquet Hemostasis**

#### *Indications*

Tourniquet hemostasis can help identify correct tendons, joint capsules, nerves, and vessels and can help locate difficult-to-find foreign bodies. Repair can proceed without interference from a bloody field. Débridement of marginally devitalized tissue is not carried out in a bloodless field because the distinction between exsanguinated and truly ischemic tissue cannot be made.

#### *Technique for Large-Extremity Tourniquet Application*

Before placement of a single-cuff sphygmomanometer, the extremity is elevated. The clinician firmly applies an elastic bandage, the Esmarch technique, by starting at the fingers or toes and proceeding proximally to the site of the anticipated cuff placement, preferably the upper arm or thigh. The cuff is inflated to a pressure higher than the patient's systolic pressure but not to exceed 250 mm Hg. The clinician clamps the cuff tubing with a hemostat instead of closing the air release valve to prevent slow leakage of air and to ensure a rapid release method if needed. The clinician removes the elastic bandage and proceeds with the exploration. The purpose of the elastic bandage is to exsanguinate the extremity to prevent venous backflow bleeding.

Patient discomfort becomes apparent by 30 to 45 minutes of cuff time, but by then, the procedure will have been completed.<sup>9</sup> The maximal cuff inflation time is 1 hour, although a limit of 30 minutes is recommended to ensure patient safety.

#### *Technique for Digital Tourniquet Application*

The clinician unfolds a 4 × 4 gauze sponge to its fullest length and folds it in half so it appears to be an 8-inch band. The band is moistened with saline. The clinician wraps the band firmly around the finger, starting at the tip and proceeding to the base. A Penrose drain is stretched around the base of the finger in a slinglike fashion, and a hemostat is applied to the drain to form a tight "ring" at the base of the finger. The sponge wrapping is removed. A Penrose drain also can be substituted for the gauze sponge wrap.

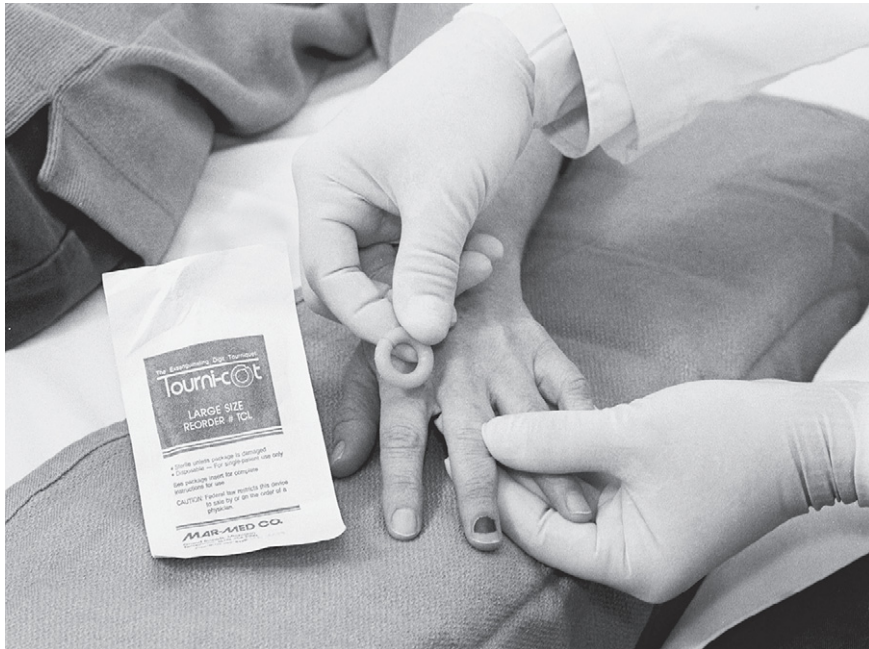There are preformed rubber disposable tourniquets (Tourni-Cot) that "roll" onto the finger and exsanguinate it before coming to rest at the digit base (Fig. 9-3). After use, they can be cut off easily with scissors. These tourniquets are easier to apply and are effective in most cases in which the digit circumference can accommodate them. The maximal allowable tourniquet time for a finger is 20 to 30 minutes.

---

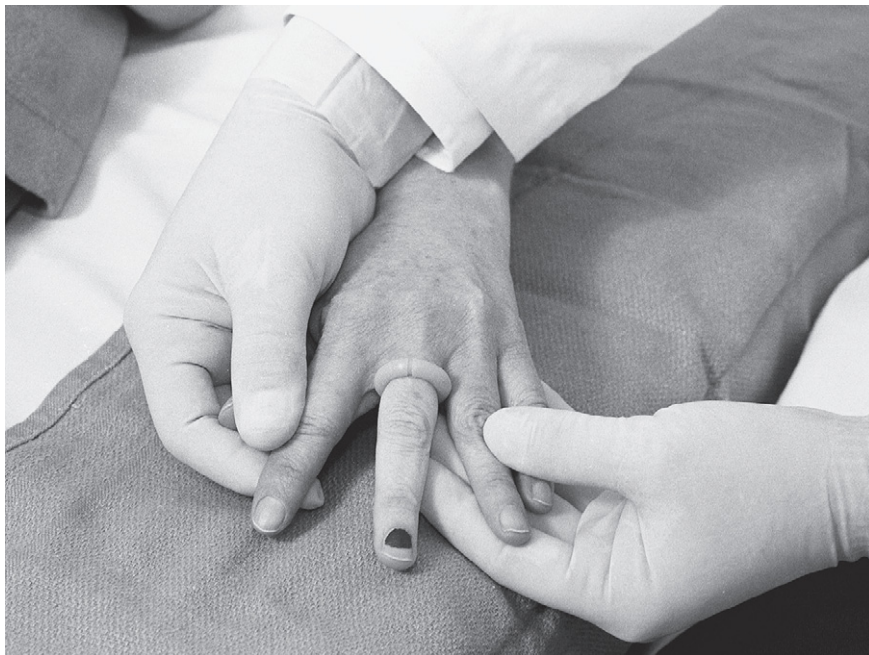## **TISSUE DÉBRIDEMENT AND EXCISION**

Before actual suturing and knot tying, the wound has to be made free of contaminants and devitalized tissue.<sup>10</sup> Devitalized tissue can be recognized by its shredded, ischemic, or blue-black appearance. Occasionally, these appearances can be misleading, and true demarcation between viable and devitalized skin cannot be made until 24 hours after wounding.<sup>11</sup> One overriding principle of wound débridement is to spare as much skin, epidermis and dermis, as possible immediately after the injury. Subcutaneous fat can be liberally débrided. Revision of the complex wound can be made at later interventions by consultant surgeons. The surgeons will be grateful for as much preserved skin as is possible to leave at the wound site.

Static skin tension plays an important role in wound edge débridement and revision. It is tempting to excise jagged wound edges to convert an irregular laceration into a straight one. If the wound is already gaping because of static tension, débridement of tissue increases the tension necessary to pull the new edges together. The resulting scar might be wider and more noticeable than it would have been by piecing together the original irregular edges.



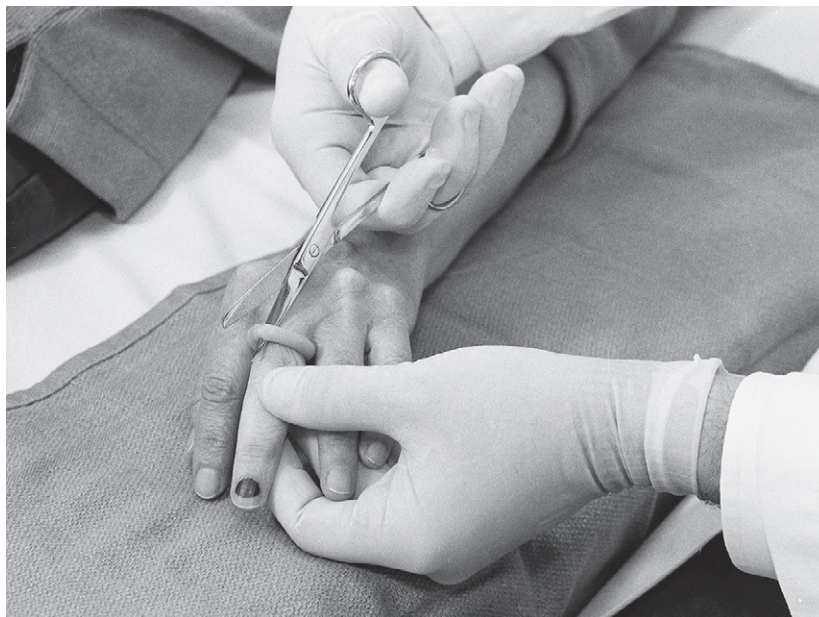A



B

**Figure 9-3** Tourniquet hemostasis for finger injuries. **A**, Example of rubber digital tourniquet. Available in different sizes. **B**, The tourniquet is placed on the finger by rolling it from the nail to the base of the digit. (Continued)





C

**Figure 9-3** Cont'd. **C**, To avoid disturbing the repaired wound, the tourniquet is removed by cutting it off with scissors.

### Technique for Simple Excision and Wound Edge Revision

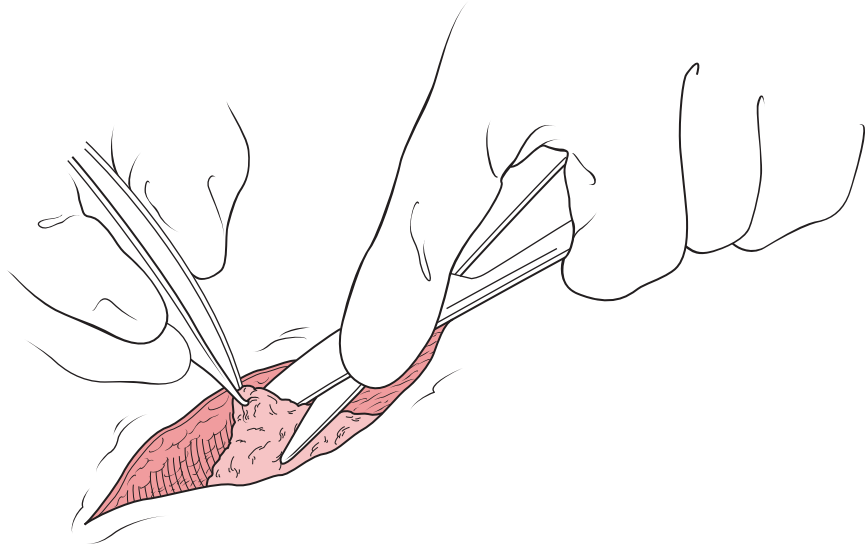
Most débridement can be carried out by simple, minimal excision of debris-laden tissue bits, using tissue forceps and iris scissors (Fig. 9-4). Superficial fascia (subcutaneous fat) under the skin can be freely excised without concern for deleterious cosmetic results. Soiled, devitalized fatty tissue is a fertile substrate for the growth of bacteria with subsequent development of infection.<sup>12</sup> More care has to be taken in débriding and excising epidermis and dermis. The best principle is to trim as little skin as possible, particularly on the face. It is preferable to repair wound edges in a jigsaw-like pattern than to excise the irregular edges only to be left with a wound under excessive tension.

The proper method to trim a dermal wound edge is shown in Figure 9-5. Iris (tissue) scissors or a no. 15 blade can be used. The wound edge is cut or incised at a slight angle so that the epidermal surface of the skin edge juts out slightly farther than the dermal portion. In this manner, when the wound is closed, it naturally everts with the proper suture placement technique and resulting suture loop configuration.

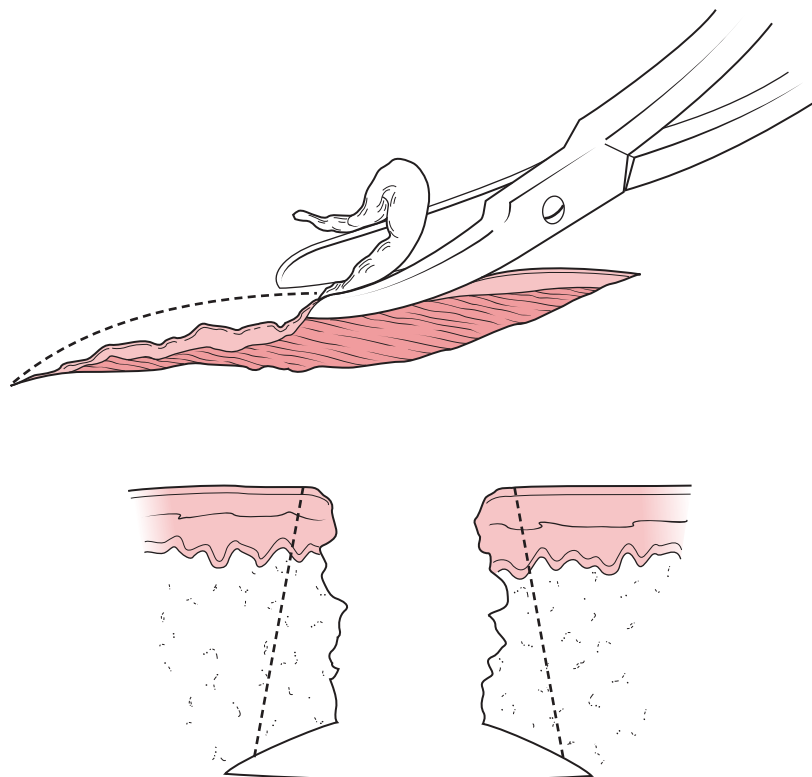
### Technique for Full Wound Excision

Full wound excisions are reserved for injuries in which all wound edges are devitalized and are obviously impossible to salvage. There also must be sufficient tissue redundancy in the anatomic location of the wound. If redundancy is inadequate, excision creates a gap or defect that can be closed only under excessive tension. Areas where there is sufficient tissue to accommodate excision include the chest, abdomen, arms, and thighs. Whenever there is doubt about this procedure, it is best to consult a surgical specialist.

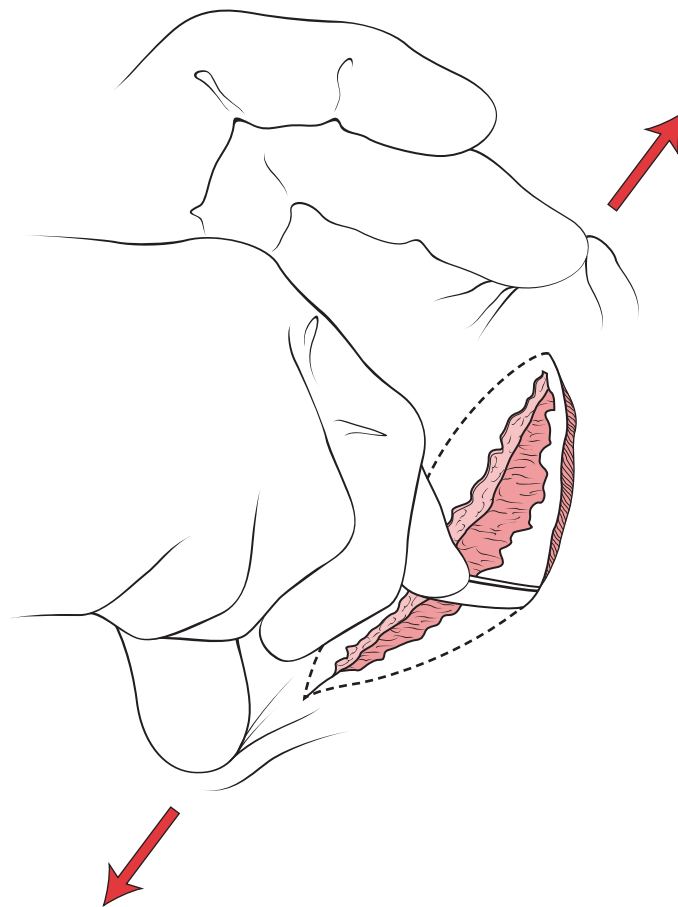
The clinician uses the scalpel with a no. 15 blade to outline the tissue to be removed by partially incising or "scoring" the dermis (Fig. 9-6). Generally the excision is lenticular



**Figure 9-4** Technique to débride deep dermis and superficial fascia (subcutaneous fat).



**Figure 9-5** Technique for excision by careful tissue scissor trimming of devitalized epidermis and dermis. Note the angle of excision, which facilitates wound-edge eversion during percutaneous closure.



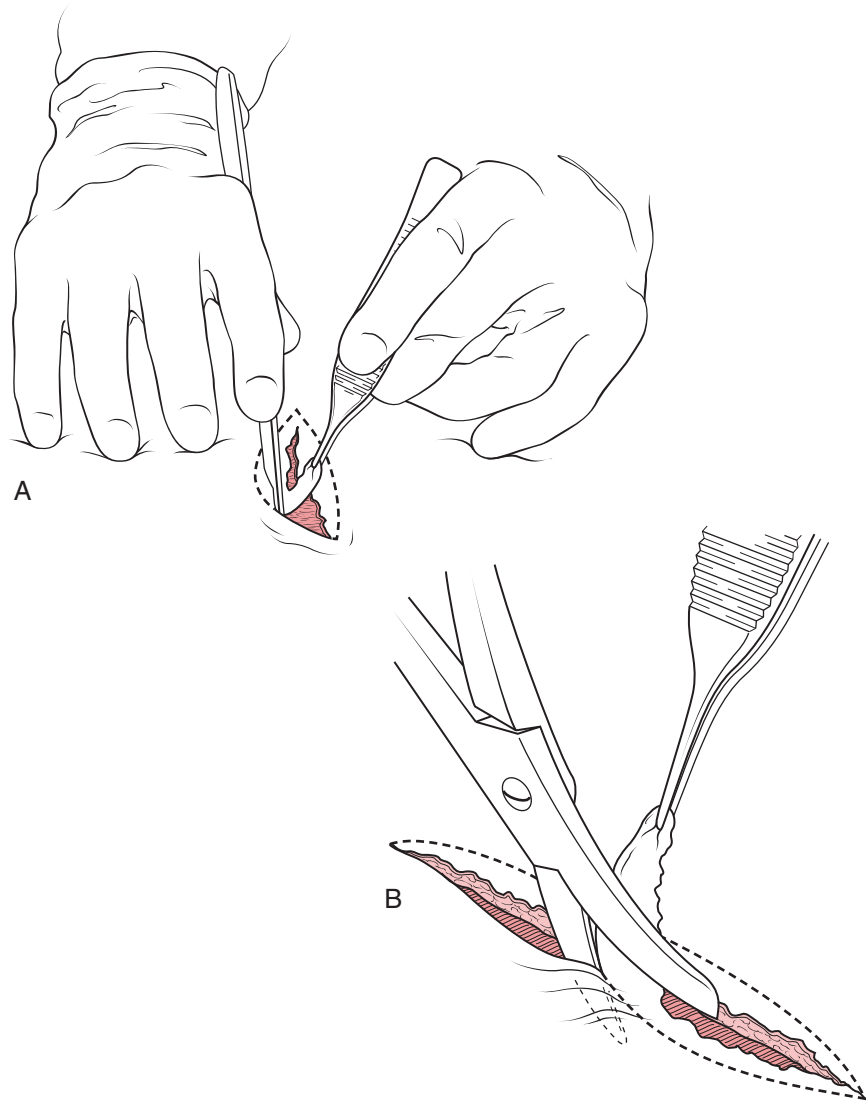
**Figure 9-6** Technique for incising or “scoring” the epidermis and dermis before full wound excision. The fingers are used to provide tension to the skin and the axis of the wound. This tension facilitates easier application of the scalpel to the skin.

(i.e., shaped like an ellipse). To achieve proper closure without excessive tension or creating tissue “humps” at either end of the wound, the length of the ellipse should exceed the width by at least a 3:1 ratio. When the ellipse is defined, the clinician uses the scalpel or iris scissors, or both in combination, to complete the excision (Fig. 9-7). The wound edges are incised at the same angle as described for dermal edge trimming. Not only do the edges have to be excised, but also the excised tissue has to be released from its base in the superficial fascia (subcutaneous tissue). Considerable bleeding often ensues, and hemostatic measures may have to be used before proceeding to closure. Excisions usually require deep (dermal) and percutaneous sutures for closure.

---

### **SURGICAL DRAINS**

Surgical drains for emergency wound care are controversial. Drains can act as retrograde conduits for contaminating bacteria from either the wound or the skin. Under experimental



**Figure 9-7** Technique for full wound excision. **A**, The scalpel can be used to excise the wound in its entirety. **B**, Tissue scissors can be used to follow the original wound outline created by the “scoring” of the epidermis and dermis with the scalpel blade.

wound conditions, subinfective inocula of bacteria have been shown to greatly increase the infection rate in drained versus undrained control wounds.<sup>13</sup> For this reason, they should be used only for wounds in which the benefit clearly outweighs the risk. Drains are indicated to remove large collections of pus or blood or to assist in eliminating large pockets of dead space. As a general rule, wounds that can be managed in an emergency department do not need drains.

---

## IMMEDIATE ANTIBIOTIC THERAPY

For simple, uncomplicated wounds and lacerations, there is no good clinical or investigative evidence that systemic antibiotics provide protection against the development of wound infection.<sup>12,14-17</sup> Occasionally, however, the physician is faced with a wound or laceration that necessitates the consideration of immediate antibiotic coverage during or even before wound management itself. Under these conditions, there is experimental evidence that antibiotic action rapidly decreases in effectiveness if it is not initiated within 3 to 4 hours of the injury.<sup>1</sup> If intravenous antibiotics are thought necessary by the physician, they need to be administered without delay. The following are situations in which the immediate administration of intravenous antibiotics should be considered:

- Complex or mutilating wounds, especially of the hand or foot (e.g., lawn-mower or chain-saw injuries)
- Grossly contaminated wounds with penetrating debris and “ground-in” foreign material
- Lacerations in areas of lymphatic obstruction and lymphedema
- Extensive lacerations of the ear and its cartilaginous skeleton
- Suspected penetration of bone (open fractures), joints, or tendons
- Amputation injuries, especially where replantation is a consideration
- Extensive or distal extremity animal bite wounds (see Chapter 15)
- Significant lacerations in patients with preexisting valvular heart disease
- Presence of disease or drugs causing immunosuppression or altered host defenses (e.g., diabetes)

The initial intravenous antibiotic of choice is usually a first-generation cephalosporin, such as cefazolin (Kefzol, Ancef). For penicillin-allergic patients, ciprofloxacin and clindamycin are reasonable alternatives. For animal bites, the recommended agents are discussed in Chapter 15. It is recommended that a wound culture be taken before initiation of antibiotics to assist in later modification of therapy if necessary.

---

## GUIDELINES FOR CONSULTATION

Inevitably, physicians are faced with wounds, lacerations, and related problems that cause them to consider consulting a specialist. There are no definitive rules governing consultations. Because there are many different circumstances under which a consultation might be considered, it is impossible to make comprehensive recommendations. In addition, each emergency physician has his or her own level of expertise, experience, and comfort. The following guidelines are based on practice realities governing emergency care.

### Standard of Care

Driven largely by the legal system, medical care often is defined in terms of some standard. In the case of wound care, emergency physicians often are held to the same standard of care as might be practiced by a surgical specialist. In reality, there is no fixed standard for any specialty or type of care. Through board certification, emergency physicians are qualified to provide emergency wound care. The “practice” line between an emergency physician and a surgical specialist is blurred, however. Each practitioner of wound care has to understand his or her strengths and limitations and act accordingly. It also is important to have knowledge of community-defined patterns of care. In some locales, only specialists perform tendon repairs, whereas in others, emergency physicians comfortably treat extensor tendon lacerations.

### Logistics of Care

Certain wounds technically can be managed by emergency physicians, but the time necessary to close the wound would significantly impede the operation of the emergency department. If direct physician involvement time exceeds 30 minutes, consultation might be considered.

### Cosmetics and Patient Expectation

Patients or family members often have expectations that "specialists" need to be involved in the care and repair of wounds. Parents frequently request a "plastic" surgeon for their child's facial laceration. If the emergency caregiver can repair the laceration confidently, most parents can be made comfortable with a clear explanation of the actual repair needed and the skills of the caregiver. Some patients or relatives are fixed on the need for a specialist, however. Usually, it is best to accede to those wishes.

### Continuity of Care

Certain wounds, particularly wounds of the hand, require close follow-up and rehabilitation. It may be best to involve a specialist in the initial care to ensure continuity. It is a common arrangement between emergency physicians and hand specialists to have the emergency physician do the primary closure with follow-up care going to the specialist. Specific circumstances include uncomplicated injuries to tendon or digital nerves. The emergency physician does the initial injury assessment and skin closure. The specialist can follow the patient and schedule a delayed repair of the tendon or nerve. This collaboration can be extremely successful and is built on trust between the different caregivers.

## REFERENCES

1. Robson M, Duke W, Krizek T: Rapid bacterial screening in treatment of civilian wounds, *J Surg Res* 14:426-430, 1973.
2. Losken HW, Auchinloss JA: Human bites of the lip, *Clin Plast Surg* 11:159-161, 1984.
3. Dimick AR: Delayed wound closure: indications and techniques, *Ann Emerg Med* 17:1303-1304, 1988.
4. Stierman KL, Lloyd KM, De Luca-Pytell DM, et al: Treatment and outcome of human bites in the head and neck, *Otolaryngol Head Neck Surg* 128:795-801, 2003.
5. Bender JS: Factors influencing outcome in delayed primary closure of contaminated abdominal wounds: a prospective analysis of 181 consecutive patients, *Am Surg* 69:252-255, 2003.
6. Smilanich RP, Bonnet I, Kirkpatrick JR: Contaminated wounds: the effect of initial management on outcome, *Am Surg* 61:427-430, 1995.
7. Altemeier W: Principles in the management of traumatic wounds and infection control, *Bull N Y Acad Med* 55:123-138, 1979.
8. Lammers RL: Principles of wound management. In Roberts JR, Hedges JR, editors: *Clinical procedures in emergency medicine*, Philadelphia, 1985, WB Saunders.
9. Roberts JR: Intravenous regional anesthesia, *J Am Coll Emerg Physicians* 6:261-264, 1977.
10. Haury B, Rodeheaver GT, Vensko J, et al: Debridement: an essential component of wound care, *Am J Surg* 135:238-242, 1978.
11. Edlich RF, Rodeheaver GT, Morgan RF, et al: Principles of emergency wound management, *Ann Emerg Med* 17:1284-1302, 1988.
12. Haughey R, Lammers R, Wagner D: Use of antibiotics in the initial management of soft tissue hand wounds, *Ann Emerg Med* 10:187-192, 1981.
13. Magee C, Rodeheaver GT, Golden GT, et al: Potentiation of wound infection by surgical drains, *Am J Surg* 131:547-549, 1976.
14. Grossman J, Adams J, Kunec J: Prophylactic antibiotics in simple hand lacerations, *JAMA* 245:1055-1056, 1981.
15. Hutton P, Jones B, Law D: Depot penicillin as prophylaxis in accidental wounds, *Br J Surg* 65:549-550, 1978.
16. Rutherford W, Spence R: Infection in wounds sutured in the accident and emergency department, *Ann Emerg Med* 9:350-352, 1980.
17. Thirlby R, Blair A: The value of prophylactic antibiotics for simple lacerations, *Surg Gynecol Obstet* 156:212-216, 1983.

# CHAPTER 10

## Basic Laceration Repair: Principles and Techniques

### DEFINITION OF TERMS

### BASIC KNOT-TYING TECHNIQUES

### PRINCIPLES OF WOUND CLOSURE

Layer Matching  
Wound Edge Eversion

Wound Tension

Dead Space

Closure Sequence and Style

Each wound and laceration has different technical requirements that have to be met to effect closure properly. By understanding the basic principles that underlie the technical requisites of wound care, lacerations and wounds can be closed with the best chance for an optimal result. During actual closure, every attempt is made to match each layer evenly and to produce a wound edge that is properly everted. Proper knot-tying technique is paramount to facilitate eversion and to prevent excessive tension on the wound edge. When necessary, dead space is closed, and finally, sutures are spaced and sequenced to provide the best and most gentle mechanical support.

### DEFINITION OF TERMS

Several techniques and maneuvers used in wound care are referred to by terms that can be confusing. These terms are defined so that the reader thoroughly understands the material contained in this chapter.

- *Bite*: A bite is the amount of tissue taken when placing the suture needle in the skin or fascia. The farther away from the wound edge that the needle is introduced into the epidermis, the bigger the bite.
- *Throw*: Each suture knot consists of a series of throws. A square knot is fashioned with two throws. Because of nylon's tendency to unravel, several additional throws are necessary to secure the final knot when this material is used.
- *Percutaneous closure (skin closure)*: Sutures, usually of a nonabsorbable material, that are placed in skin with the knot tied on the surface are called percutaneous closures. They also are referred to as skin closures.
- *Dermal closure (deep closure)*: Sutures, usually of an absorbable material, that are placed in the superficial (subcutaneous) fascia and dermis with the knot buried in the wound are called deep closures.
- *Interrupted closure*: Single sutures, tied separately, whether deep or percutaneous, are called interrupted sutures.

- *Continuous closure (running suture)*: A wound closure accomplished by taking several bites that are the full length of the wound, without tying individual knots, is a continuous or running suture. Knots are tied only at the beginning and end of the closure to secure the suture material. Continuous closures can be percutaneous or deep.

---

## BASIC KNOT-TYING TECHNIQUES

Several knots can be used to tie sutures during wound closure. The most common is the surgeon's knot (Fig. 10-1). The advantage of this knot is that the double first throw offers better knot security, and there is less slipping of the suture material as the wound is gently pulled together during tying. The wound edges remain apposed while the second and subsequent single throws are accomplished. The knot-tying sequence shown in Figure 10-1 illustrates the proper instrument technique required to obtain a surgeon's knot. The instrument tie can be used for almost all knots, whether for deep or superficial closures.

Occasionally, it is necessary to perform a hand tie. Hand ties in emergency wound care are most useful for ligating vessels to achieve hemostasis. After a small bleeding vessel is clamped with the tip of a hemostat, an absorbable suture is brought around the vessel held by the hemostat and tied in the manner illustrated in Figure 10-2. Because two hands are necessary for this tie, an assistant often is required to hold the hemostat and display the tie so that the vessel can be encircled easily with the suture.

---

## PRINCIPLES OF WOUND CLOSURE

### Layer Matching

When closing a laceration, it is important to match each layer of a wound edge to its counterpart. Deep fascia, when opened traumatically, is closed to deep fascia. Superficial fascia has to meet superficial fascia. Finally, dermis to dermis necessarily brings epidermis to epidermis. Failure to appose layers meticulously can cause improper healing with an unnecessarily large scar (Fig. 10-3).

### Wound Edge Eversion

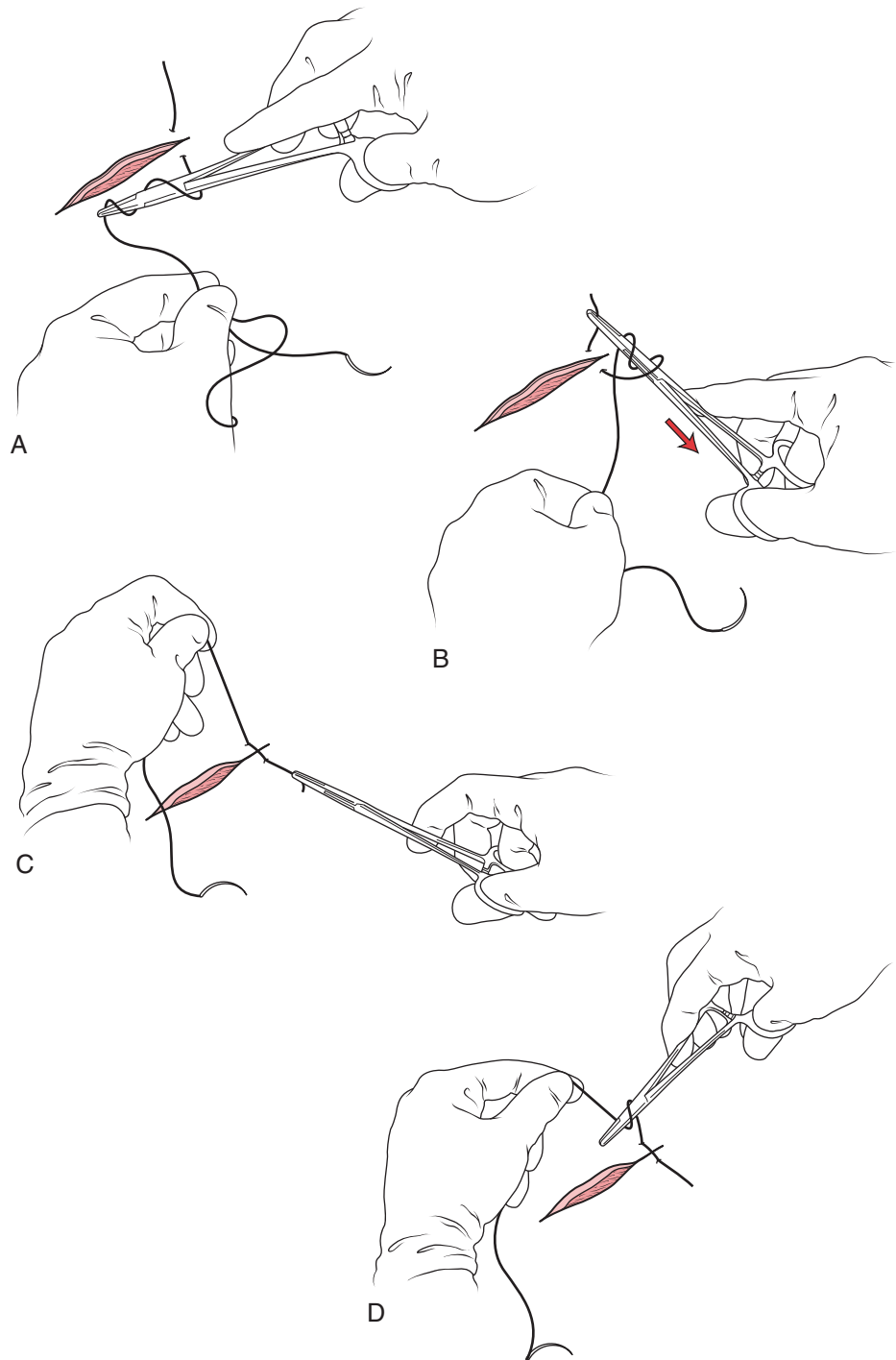
Just as important as layer matching is proper wound edge eversion during the initial repair. Because of the normal tendency of scars to contract with time, a slightly raised wound edge above the plane of the normal skin gradually flattens with healing and has a final appearance that is cosmetically acceptable (Fig. 10-4). Wounds that are not everted contract into linear pits that become noticeable cosmetic defects because of their tendency to cast shadows.

### Techniques for Wound Edge Eversion

The key to achieving proper wound edge eversion is to use the correct technique for introducing the needle into the skin and producing the proper suture configuration. As illustrated in Figure 10-5, the point of the needle should pierce the epidermis and dermis at a 90-degree angle before it is curved around through the tissues. To ensure a 90-degree angle, the needle holder has to be held in the manner described in Chapter 8. It is mechanically difficult to maneuver the needle correctly if the operator's fingers remain in the finger rings of the needle holder. Figure 10-5 illustrates the correct and incorrect final configuration of an interrupted suture to achieve wound edge eversion.

**Vertical mattress suture.** Another useful method for wound edge eversion is the vertical mattress suture. This suture is placed by first taking a large bite of tissue approximately 1 to 1.5 cm away from the wound edge and crossing through the tissue to an equal distance





**Figure 10-1** A-G, Sequence for instrument tie of a standard percutaneous suture closure. Note the surgeon's knot and final square knot configuration in the inset illustration in G. (Continued)

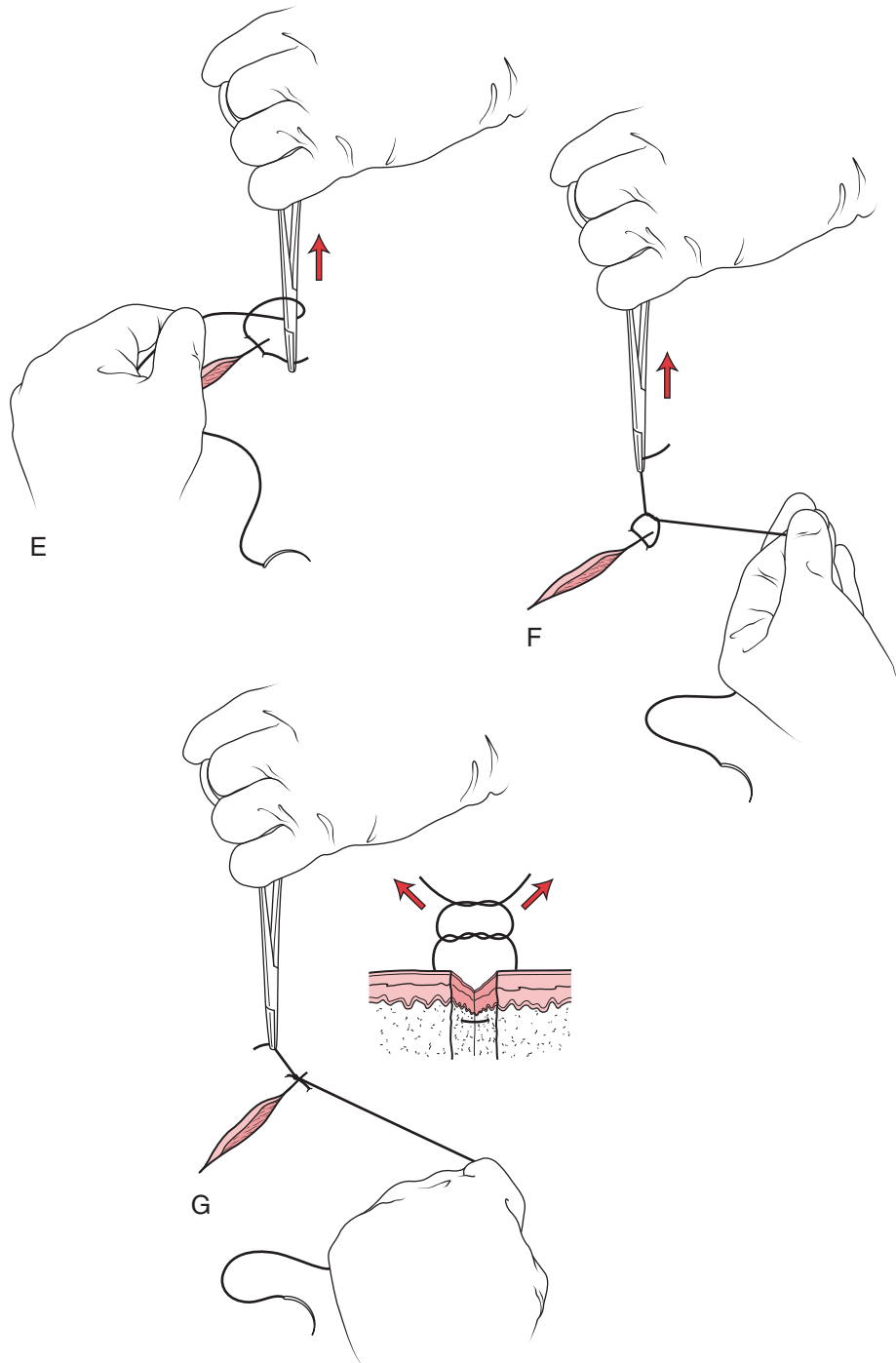
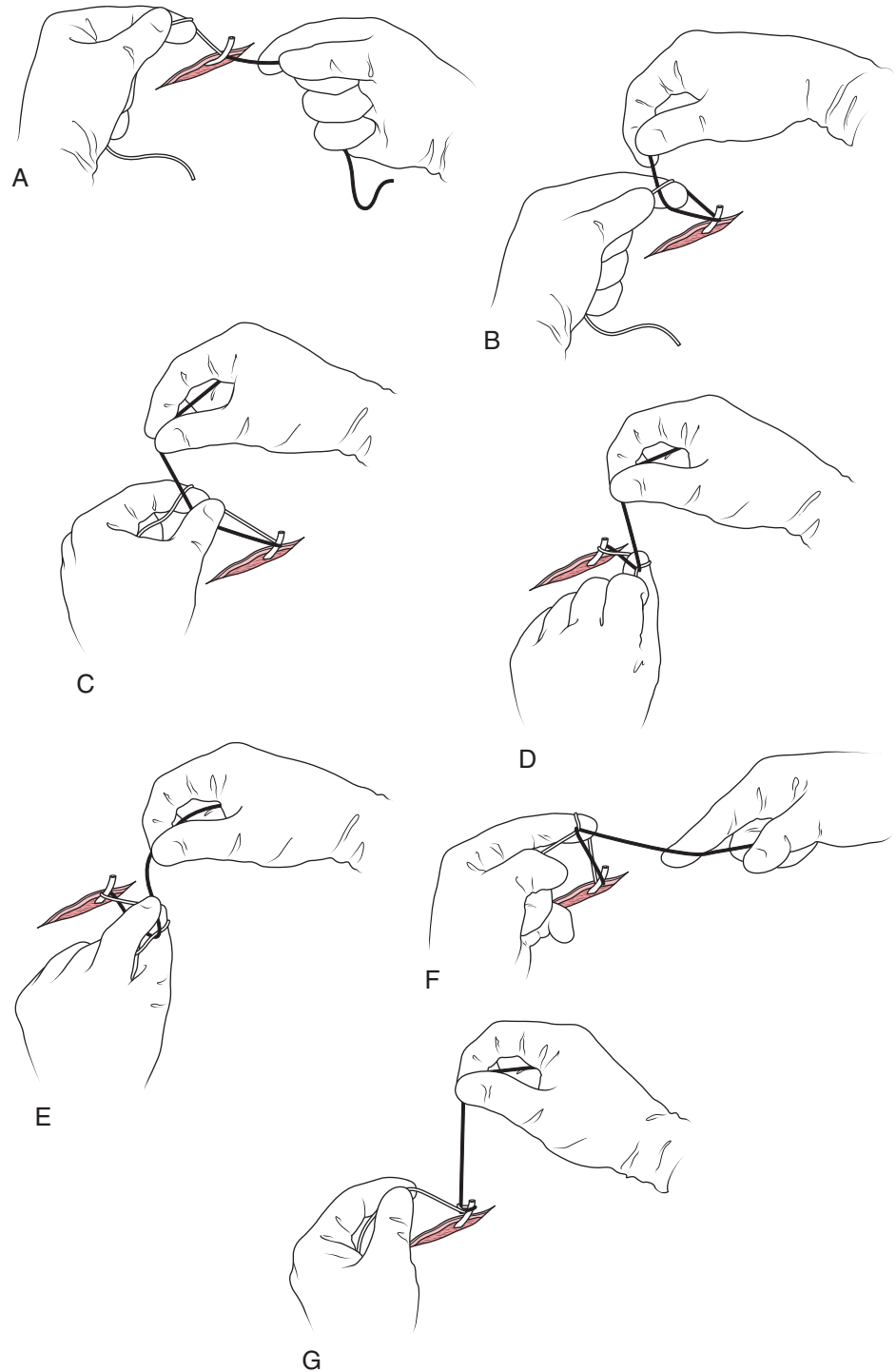


Figure 10-1 Cont'd.



**Figure 10-2** A-M, Sequence for a two-handed tie of hemostat-clamped vessels for hemostasis.

(Continued)

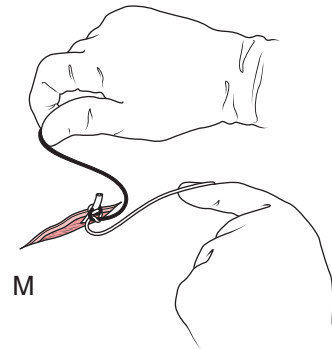
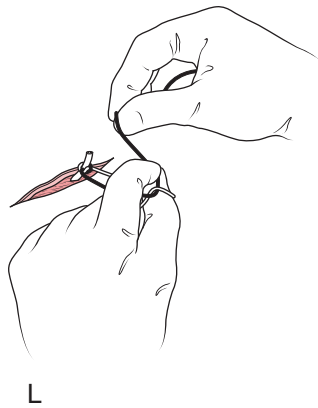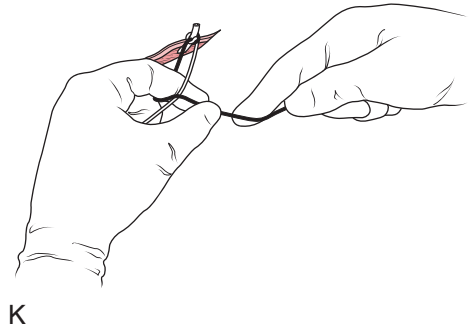
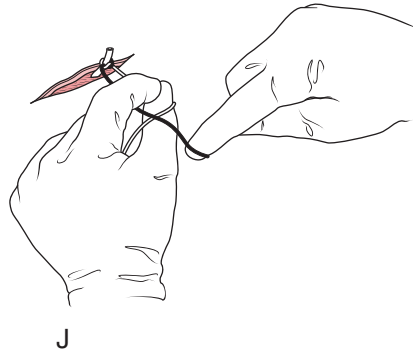
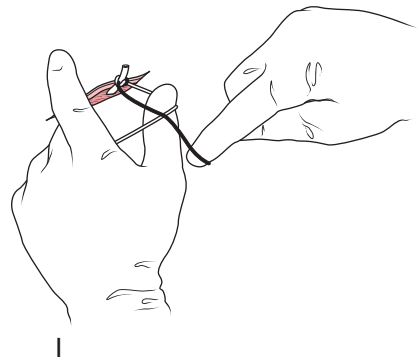
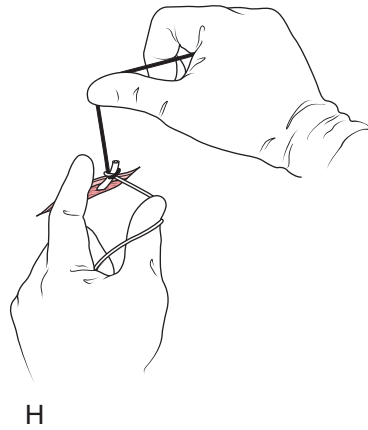
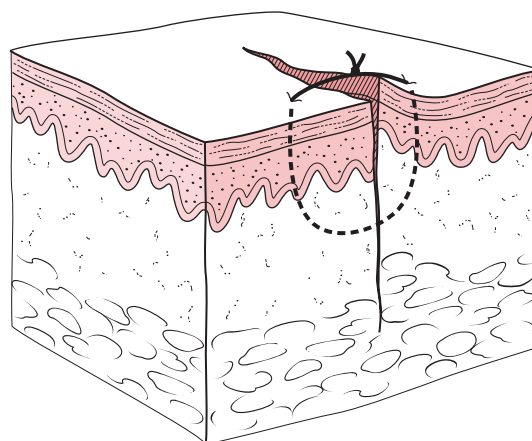
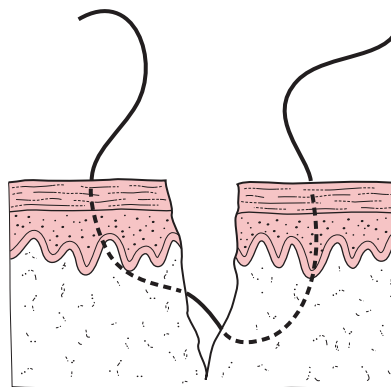


Figure 10-2 Cont'd.

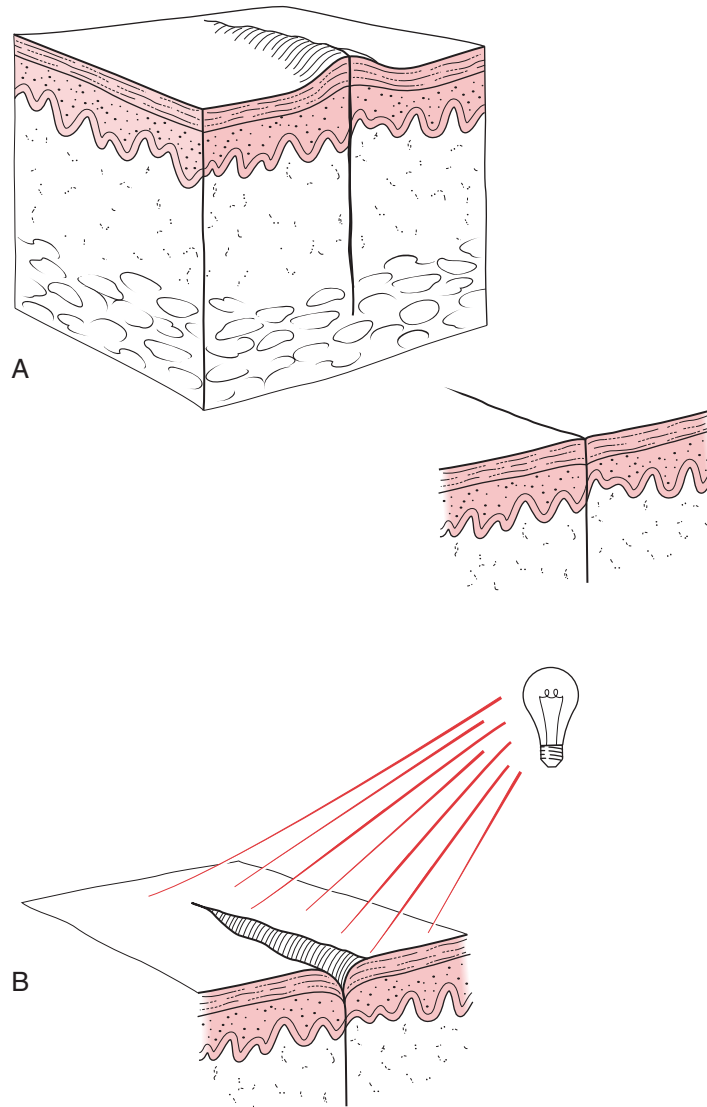


**Figure 10-3** Incorrect technique to provide for layer matching.

on the opposite side of the wound. The needle is reversed and returned for a small bite (1 or 2 mm) at the epidermal/dermal edge to approximate closely the epidermal layer (Fig. 10-6). The vertical mattress suture is helpful in areas of lax skin (e.g., elbow, dorsum of hand), where the wound edges tend to fall or fold into the wound. Another advantage of the vertical mattress suture is that it can act as a deep and a superficial closure all in one suture. Some wounds are not deep enough to accommodate a separate, absorbable suture but still need some deep support to close dead space. This technique can meet that need.

A modification of the vertical mattress suture, the shorthand technique, allows the suture to be placed more rapidly.<sup>1</sup> Instead of taking the large bite first, as described earlier, the small bite is taken, then the large one. By placing simultaneous traction on the trailing and leading portions of the suture after the small bite, the wound edges are elevated so that the needle easily takes the large bite.

**Horizontal mattress suture.** Another technique, the horizontal mattress suture, can be used to achieve wound edge eversion (Fig. 10-7). The needle is introduced into the skin in the usual manner and is brought out at the opposite side of the wound. A second bite is taken

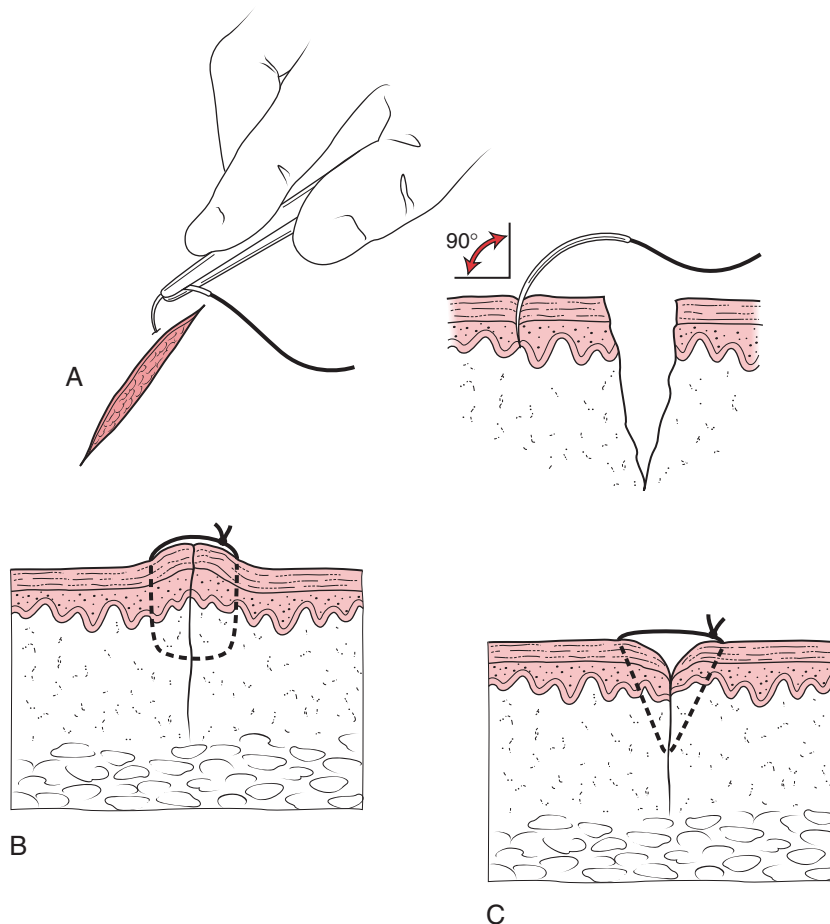


**Figure 10-4** Wound edge eversion. **A**, Correct technique allows for a slight rise of the wound edges above the skin plane. These edges eventually contract to flatten out at the skin plane. **B**, Wound edges that are not properly everted contract below the skin plane and allow incident light to cause unsightly shadows.

approximately 0.5 cm adjacent to the first exit and is brought back to the original starting edge, also 0.5 cm from the initial entry point. The knot is tied, leaving an everted edge. This is a suture technique often used in closing hand (palm and dorsum) lacerations.

### Wound Tension

Whenever wound edges are brought together by suturing, there is inevitable tension created in the tissue within the suture loop. It is important to minimize tension to preserve capillary

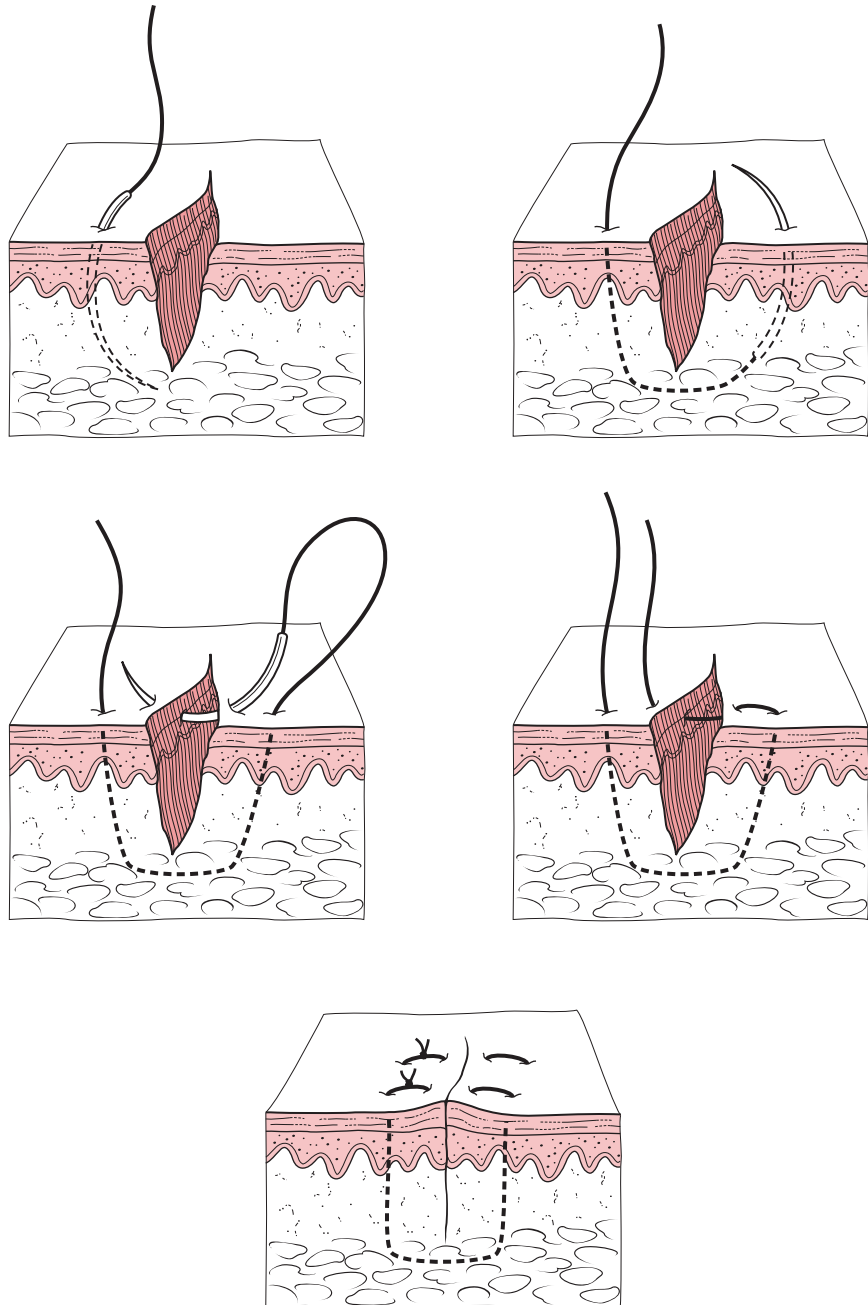


**Figure 10-5** Technique for proper wound edge eversion. **A**, The suture needle is introduced at a 90-degree angle to the epidermis. **B**, The proper configuration of the suture should be square or bottle shaped. This configuration is difficult to achieve in practice; however, this figure illustrates the correct principle. **C**, The incorrect technique of needle placement and suture configuration leads to wound edge inversion, which leads to “pitting” of the eventual scar.

blood flow to the wound edge. Excessive force exerted on the tissue leads to ischemia and can cause some degree of cellular necrosis.<sup>2</sup> Necrosis provokes a more intense inflammatory response with the eventual formation of an irregular, cosmetically unacceptable scar. When tying knots, the first throw is crucial. As the wound edges are brought together, they are allowed just barely to touch. Bringing the edges together more forcibly by making the first throw too tight promotes ischemia. Wound edges tend to become slightly edematous after repair; a small amount of slack between them disappears. The addition of edema to a suture line that already is too tight can be disastrous.

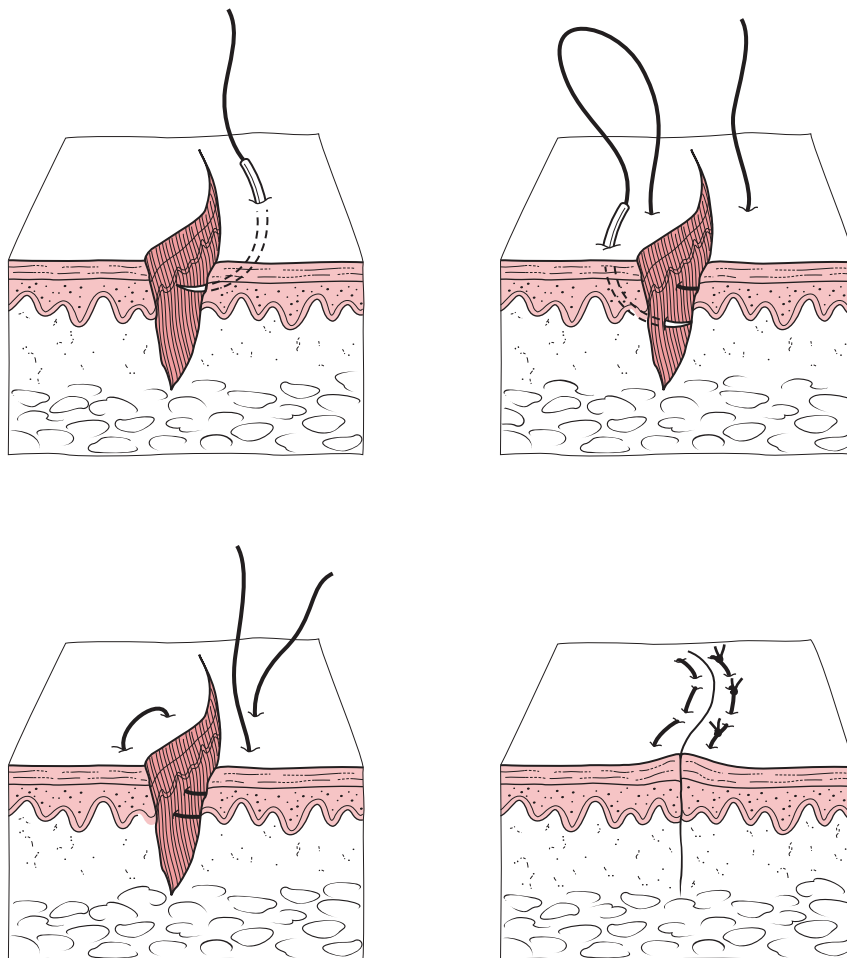
### Techniques for Reducing Wound Tension

**Deep closures.** Proper placement of deep closures to bring the dermis close together before suture closure reduces final wound edge tension. Figure 10-8 illustrates the method for



**Figure 10-6** Technique for a vertical mattress suture. The second bite barely passes through the dermis to provide meticulous apposition of the epidermal edges.

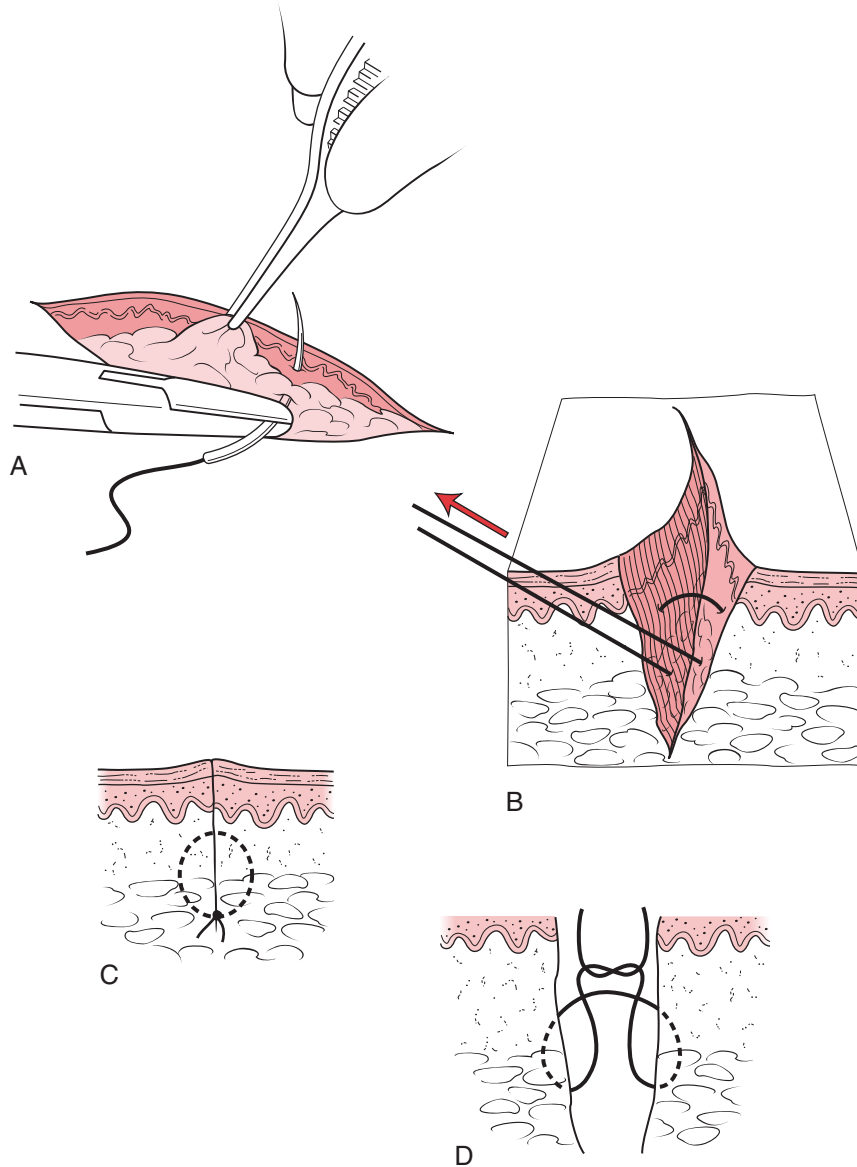




**Figure 10-7** Technique for placing a horizontal mattress suture.

placing and tying deep closures. To start this suture, the needle is introduced into the superficial fascia, close to the underside of the dermis. Then the needle is brought up through the dermis. At this point, the needle has to be rearmed with the needle holder. The needle is introduced into the dermis of the matching opposite wound edge and carried down into the superficial fascia to complete the second bite.

Crucial to this technique is that the trailing and leading portions of the suture remain on the same side of the portion of the suture that crosses from dermis to dermis. In this manner, when the knot is tied, it is buried. If the trailing edges are on opposite sides of the dermal crossing, the knot is pushed superficially and interferes with epidermal healing. Three or four throws are adequate to secure the knot, and the suture ends are cut close to the knot itself, leaving no more than 2-mm "tails." The temptation to place numerous deep closures must be resisted. These sutures act as foreign bodies and become a nidus for wound infection.<sup>3</sup> They also provoke a greater healing response and can increase the total bulk of a scar.

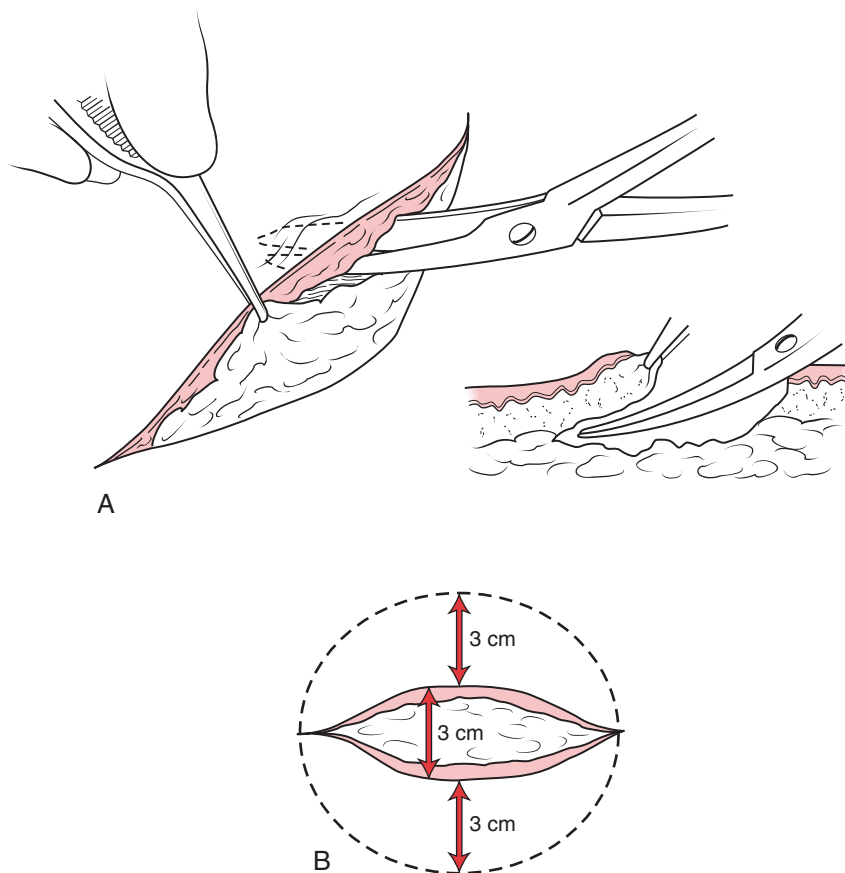


**Figure 10-8** Technique for placing a deep suture. **A**, Suture placement is initiated by driving the needle from deep in the wound to superficial. **B**, The needle is driven superficial to deep on the opposite side of the wound. The leading and trailing sutures come out on the same side of the cross suture. **C**, This same-side technique allows for the knot to be tied deep and away from the wound surface. **D**, If the same-side technique is not followed, the knot is forced to the wound surface by the cross suture and may protrude out of the wound.

Only as many sutures as are necessary to accomplish the task of reducing wound tension should be placed.

**Wound undermining.** Another technique for reducing tension is wound undermining. Undermining releases the dermis and superficial fascia from their deeper attachments, allowing the wound edge to be brought together with less force. Anatomic areas where undermining is useful include the scalp, forehead, and lower legs, particularly over the tibia, where the skin is under a great deal of natural tension. Caution has to be exercised in deciding to undermine because this procedure can spread bacteria into deeper tissues and create a deeper, larger dead space.

The technique for undermining is illustrated in Figure 10-9A. For most minor wound care problems, the proper tissue plane for wound undermining is between the superficial fascia (subcutaneous tissue) and deep fascia overlying the muscle. Staying in this plane maintains the integrity of the blood and nerve supply to the skin (dermis and epidermis). Metzenbaum dissection scissors (or for smaller wounds, iris scissors) can be inserted parallel to the deep

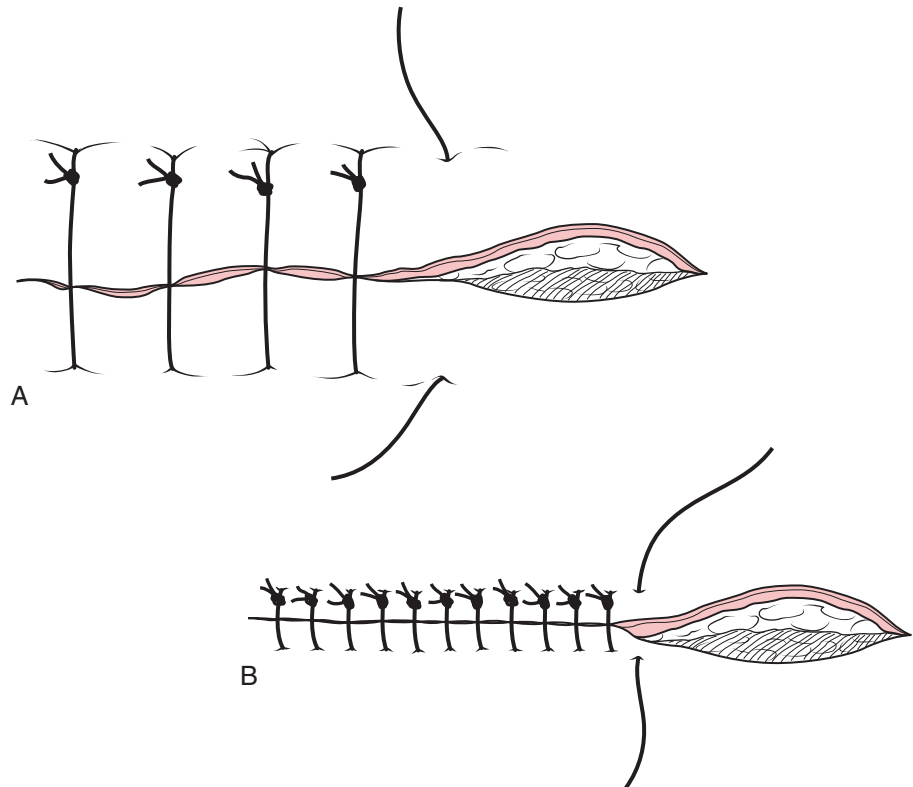


**Figure 10-9** Technique for tissue undermining. **A**, Scissors are used for dissection at the dermal-superficial fascia level. Tissue spreading is preferred to cutting the sharp edges. **B**, The zone of undermining.

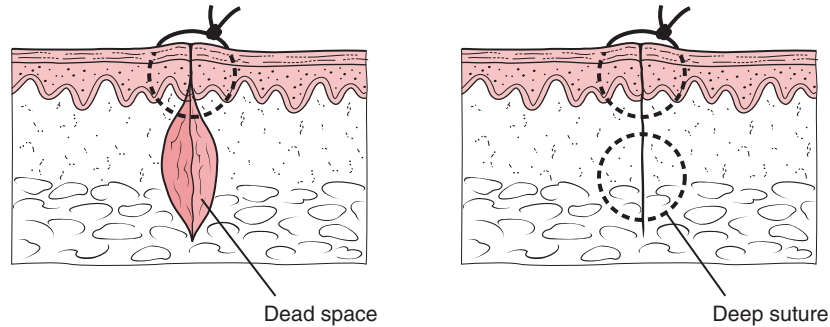
fascia where it joins the superficial fascia. The instrument is spread gently to create a plane of dissection. Undermining also can be carried out with a no. 15 blade on a standard knife handle. The blade is rotated away from the deep fascia and used as a combination cutting instrument and probe. Actual cutting is kept to a minimum to prevent excessive bleeding.

Wounds are undermined from end to end, to a distance from the wound edge that approximates the extent of "gapping" of the wound edges. In other words, if a wound gaps open 3 cm from edge to edge, undermining is carried out to 3 cm under the dermis, perpendicularly away from the wound edge. A common mistake in using this technique is to fail to include the wound ends. Figure 10-9B illustrates the proper zone of undermining during dissection.

**Additional suture placement.** Placing more sutures closer together also reduces wound tension (Fig. 10-10). Mechanically, a greater number of sutures lessens the total force exerted on each suture, reducing potential tissue compression. The caregiver has to keep in mind, however, that sutures act as foreign bodies and can potentiate infection. When closing a wound, a balance has to be struck between the number of sutures used and the desired tension reduction.



**Figure 10-10** A technique for reducing wound tension. **A**, A few sutures, placed far apart and far from the wound edges, will increase wound tension. **B**, More sutures placed closer together and closer to the wound edges will reduce tension.



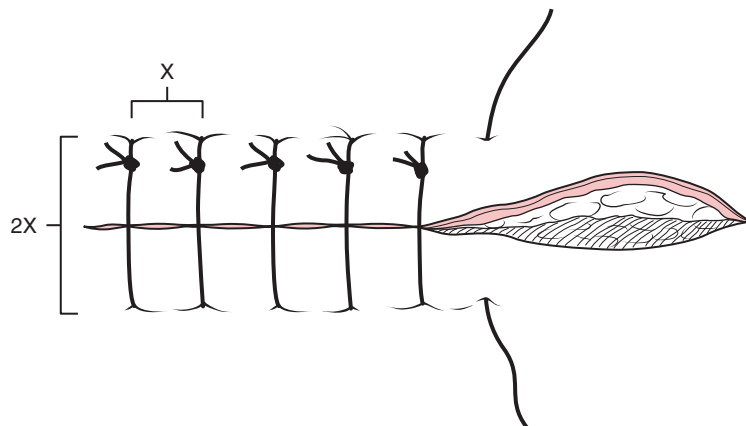
**Figure 10-11** Example of dead space and a two-layered closure to obliterate that space.

### Dead Space

In the past, it was axiomatic that no open or dead spaces should be left behind during wound closure. These spaces tend to fill with hematoma and can act as potential sites for wound infection (Fig. 10-11). Hematoma formation in these areas also can delay wound healing. There is experimental evidence, however, that suture closure of these spaces, when they are contaminated with bacteria, increases the chance of wound infection.<sup>2</sup> It is recommended that deep closures be used only to close dead space in clean, minimally contaminated wounds. Even in these cases, as few sutures as possible should be used.

### Closure Sequence and Style

Students learning wound care often ask how close together sutures should be placed. As a general rule, sutures are placed just far enough from each other so that no gap appears between the wound edges. As a general guideline, the distance between sutures is equal to the bite distance from the wound edge (Fig. 10-12); however, the great variability of



**Figure 10-12** Example of closure style and sequence. The knots should be placed evenly on one side of the wound. Knots directly over the wound increase inflammation and scar tissue formation.

lacerations dictates that experience rapidly teaches the practitioner the proper distances at which sutures should be placed to close the wound.

The final appearance of a suture line should be neat and organized. The knots are aligned to one side of the laceration. In addition to appearing orderly, knots are placed away from the wound edge to prevent a further inflammatory response that can be provoked by an increased amount of foreign material directly over the healing surface. Aligning of the knots to one side or the other contributes to wound edge eversion.

## REFERENCES

1. Jones SJ, Gartner M, Drew G, et al: The shorthand vertical mattress stitch: evaluation of a new suture technique, *Am J Emerg Med* 11:483-485, 1993.
2. Crikelair G: Skin suture marks, *Am J Surg* 96:631-639, 1958.
3. Edlich RF, Panek PH, Rodeheaver GT, et al: Physical and chemical configuration of sutures in the development of surgical infection, *Ann Surg* 177:679-687, 1973.

# Complex Wounds: Advanced Repair Techniques

## RUNNING SUTURE CLOSURE

Description  
Technique for Continuous Over-and-Over (Running) Suture

## BEVELED (SKIVED) WOUNDS

Description  
Technique for Closure of a Beveled Edge

## PULL-OUT SUBCUTICULAR CLOSURE

Description  
Technique for Pull-Out Subcuticular Closure

## SUBCUTICULAR RUNNING SUTURE

Description  
Technique for Subcuticular Running Suture

## CORNER STITCH

Description  
Technique for Closing a Corner

## PARTIAL AVULSION, FLAP WOUNDS

Description  
Technique for Preparing and Repairing a Complicated Flap  
Technique for Closing Flaps with Nonviable Edges: V-Y Closure  
Technique for Closing a Wound with a Completely Nonviable Flap

## GEOGRAPHIC LACERATIONS

Description  
Technique for Closure of Geographic Wounds

## COMPLETE AVULSIONS

Description  
Technique for Converting a Triangle to an Ellipse  
Technique for Closing a Circular or Irregular Defect

## DOG-EAR DEFORMITIES

Description  
Technique for Closing a Dog Ear

## PARALLEL LACERATIONS

Description  
Technique for Closure of Parallel Lacerations

## THIN-EDGE, THICK-EDGE WOUNDS

Description  
Technique for Closing a Thin-Edge, Thick-Edge Wound

## LACERATION IN AN ABRASION

Description  
Technique for Closing a Laceration in an Abrasion

## WOUNDS IN AGED SKIN

Description  
Techniques for Closing Wounded Aged Skin

Most lacerations and wounds are straightforward and can be closed with the basic techniques described in Chapter 10. Some wounds are more complicated, however, and present with a variety of technical challenges. This chapter describes some of the more complicated wound problems that can be encountered in a wound care setting. Techniques for “solving” these “puzzles” are suggested.

---

## RUNNING SUTURE CLOSURE

### Description

Lacerations, usually caused by simple shearing forces, can be quite long and time-consuming to close. Lacerations often are caused by slash wounds from a knife or piece of glass. The continuous “over-and-over” (running) suture technique can be used when time is a factor.<sup>1</sup> Wounds greater than 5 cm in length can be considered for this technique. The time saved is beneficial to the person repairing the wound because he or she can return quickly to other emergency department duties. There are drawbacks to this technique. If one loop of the suture breaks or is imperfectly positioned, the whole process has to be repeated. Wound edge eversion can be difficult to control with this technique. Continuous sutures are reserved for straight lacerations in healthy, viable skin that would not collapse in with suturing. If this technique is applied to curved lacerations, it can create a “purse-string” effect that bunches up the wound. Another technique that can be used for long, straight lacerations is wound stapling (see Chapter 14).

### Technique for Continuous Over-and-Over (Running) Suture

The technique for continuous over-and-over suturing is shown in Figure 11-1A. The closure is started with the standard technique of a percutaneous interrupted suture, but the suture is *not* cut after the initial knot is tied (see Fig. 11-1A). The needle is used to make repeated bites, starting at the original knot and making each new bite through the skin at a 45-degree angle to the wound direction (Fig. 11-1B through 11-1F). The cross stays of suture, on the surface of the skin, are at a 90-degree angle to the wound direction. The final bite is made at a 90-degree angle to the wound direction to bring the suture out next to the previous bite exit (Fig. 11-1G). The final bite is left in a loose loop. The loop acts as a free end of suture for knot tying. The first throw of the final knot is made by looping the suture end held in the hand around the needle holder, then grasping the free loop (Fig. 11-1H). The first throw is snugged down to skin level (Fig. 11-1I). The knot is completed in the standard instrument-tie manner with several more throws at skin level (Fig. 11-1J and 11-1K).

---

## BEVELED (SKIVED) WOUNDS

### Description

A common problem in layer matching is the beveled-edge, or “skived,” laceration. Beveled edges are created when the striking angle of the wounding object is not perpendicular, but the angle and force are not acute enough to create a true flap deformity.

### Technique for Closure of a Beveled Edge

A common misconception about the repair of a beveled-edge wound is that a larger bite is taken from the thin edge of the laceration than from the bigger edge. The opposite technique is the solution to proper layer matching. The technique for closing a beveled laceration is shown in Figure 11-2. By taking unequal bites as shown, the edge is brought into correct apposition with the opposite edge. If sufficient tissue redundancy exists in the wound area, excision of the edges can equalize the wound so that simple sutures can close the wound.

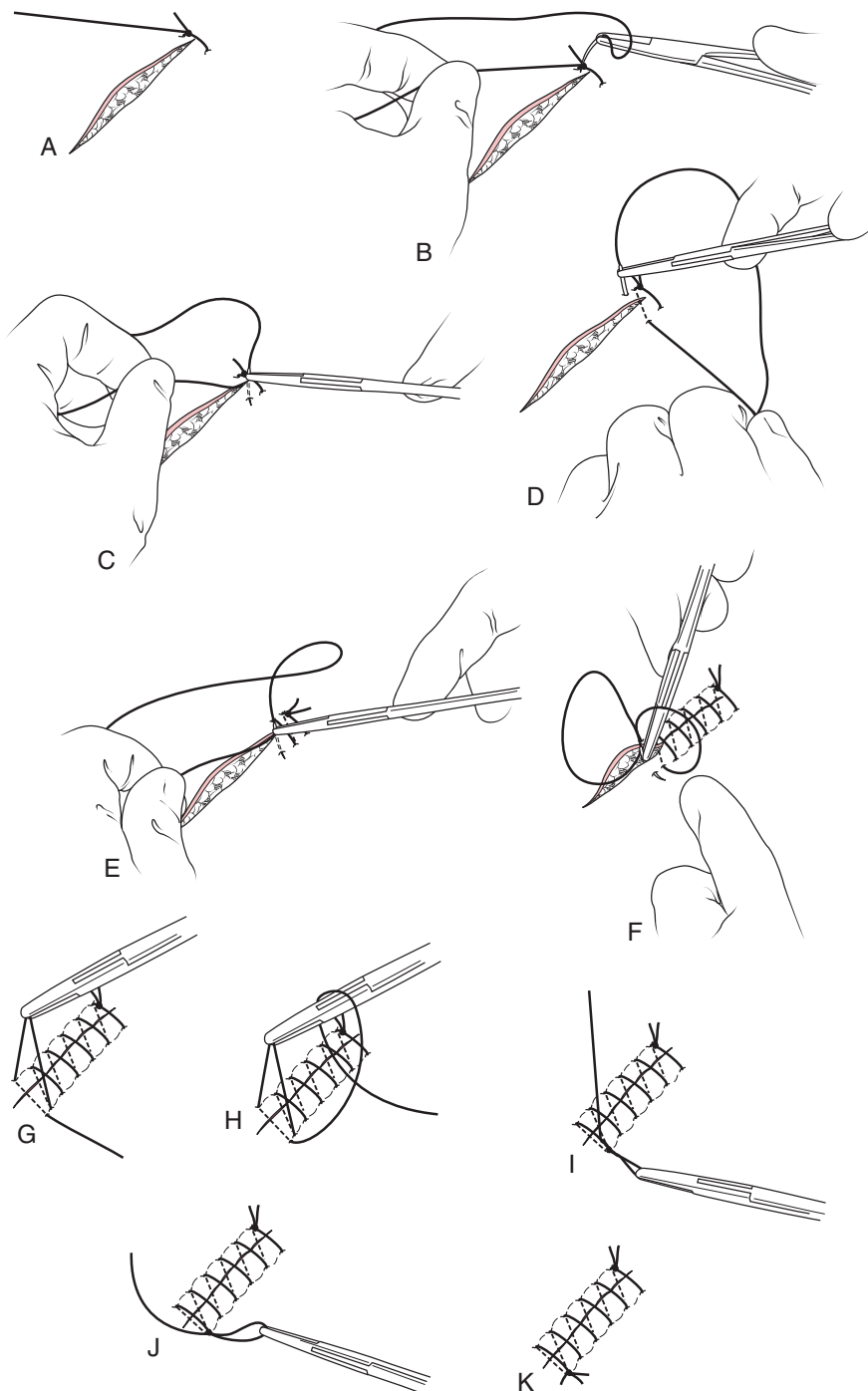
---

## PULL-OUT SUBCUTICULAR CLOSURE

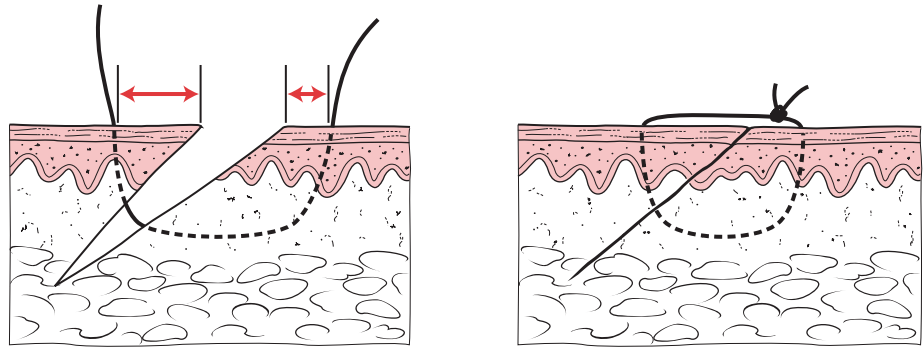
### Description

A favorite technique of plastic surgeons is the pull-out subcuticular stitch using a non-absorbable suture material, such as polypropylene (Prolene). This suture material is stiffer





**Figure 11-1** A-K, Technique for continuous over-and-over suture (running suture). The needle bites are made at a 45-degree angle to the axis of the wound. By taking bites at this angle, the cross stay of the suture at the skin surface is at a 90-degree angle to the wound axis. See text for complete description of technique.

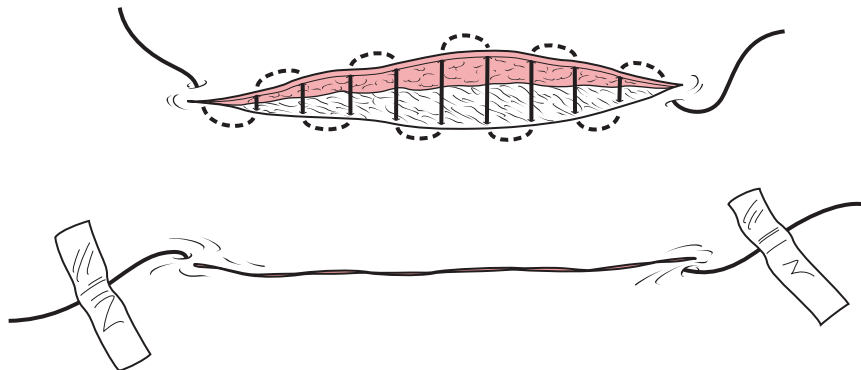


**Figure 11-2** Technique for closing a beveled edge. There is a larger bite taken on the larger wound edge; there is a smaller bite taken on the flap portion of the wound edge.

and stronger than nylon and allows for easier removal.<sup>2</sup> A newer, nonabsorbable suture material, polybutester (Novofil), also is useful for this technique.<sup>3</sup> The pull-out closure is limited to straight lacerations less than 4 cm long because the suture would be too hard to extract at removal time. Children have naturally higher skin tension, so this technique is thought by some clinicians to be superior for children because it prevents suture marks. Despite this fact, the pull-out subcuticular closure has no distinct advantage over percutaneous closure when final wound and scar appearance is compared.<sup>4</sup> Another use for this technique is for closure of lacerations over which splinting materials or plaster will be placed. It also can be used in patients who are at risk for keloid formation to prevent keloid formation at the needle puncture sites.

### Technique for Pull-Out Subcuticular Closure

Before placement of a pull-out subcuticular closure, the superficial fascia (subcutaneous tissue) has to be apposed adequately with absorbable suture to bring the dermis close to approximation. The actual closure is begun by passing the needle of 4-0 or 5-0 nylon or polypropylene 1 to 1.5 cm from the wound end through the dermis layer and bringing it out of the wound parallel to and through the plane of the dermis. Subsequent bites are made (Fig. 11-3) parallel to the dermis at a depth of 2 to 3 mm into the dermis. Each bite should



**Figure 11-3** Technique for pull-out dermal closure. See text for complete description of technique.

“mimic” the other with regard to bite size and dermal depth on each side of the wound until the “tail” is brought out at the opposite end of the wound. The beginning and final tail can be secured by wound tape. In the face, this suture can remain in place for 7 days. This technique often is used in conjunction with wound taping to match dermal and epidermal layers accurately. The suture is removed merely by pulling on one end with forceps or a needle holder and sliding the suture out of the dermal layer.

---

## SUBCUTICULAR RUNNING CLOSURE

### Description

Surgeons often use a subcuticular running closure to close straight incisions. It can suffice to close the wound alone or can be supplemented with interrupted skin sutures. In wound care, this closure should be reserved for straight, clean lacerations with sharp, nondevitalized wound edges. It can be used to close wounds that have been excised or trimmed where the edges are left fresh and straight.

### Technique for Subcuticular Running Suture

A nonabsorbable suture material (e.g., Dexon, Vicryl, PDS, or Maxon) can be used. As for other running sutures, one strand is used, without interruption, for the entire laceration. As shown in Figure 11-4, the suture is anchored at one end of the laceration. The plane chosen is either the dermis or just deep to the dermis in the superficial subcutaneous fascia. While maintaining this plane, “mirror image” bites are taken horizontally the full length of the wound. The final bite leaves a trailing loop of suture (see Fig. 11-4) so that the knot can be fashioned for final closure. This technique commonly is supplemented with wound tapes, particularly if some degree of gapping of the edges remains.

---

## CORNER STITCH

### Description

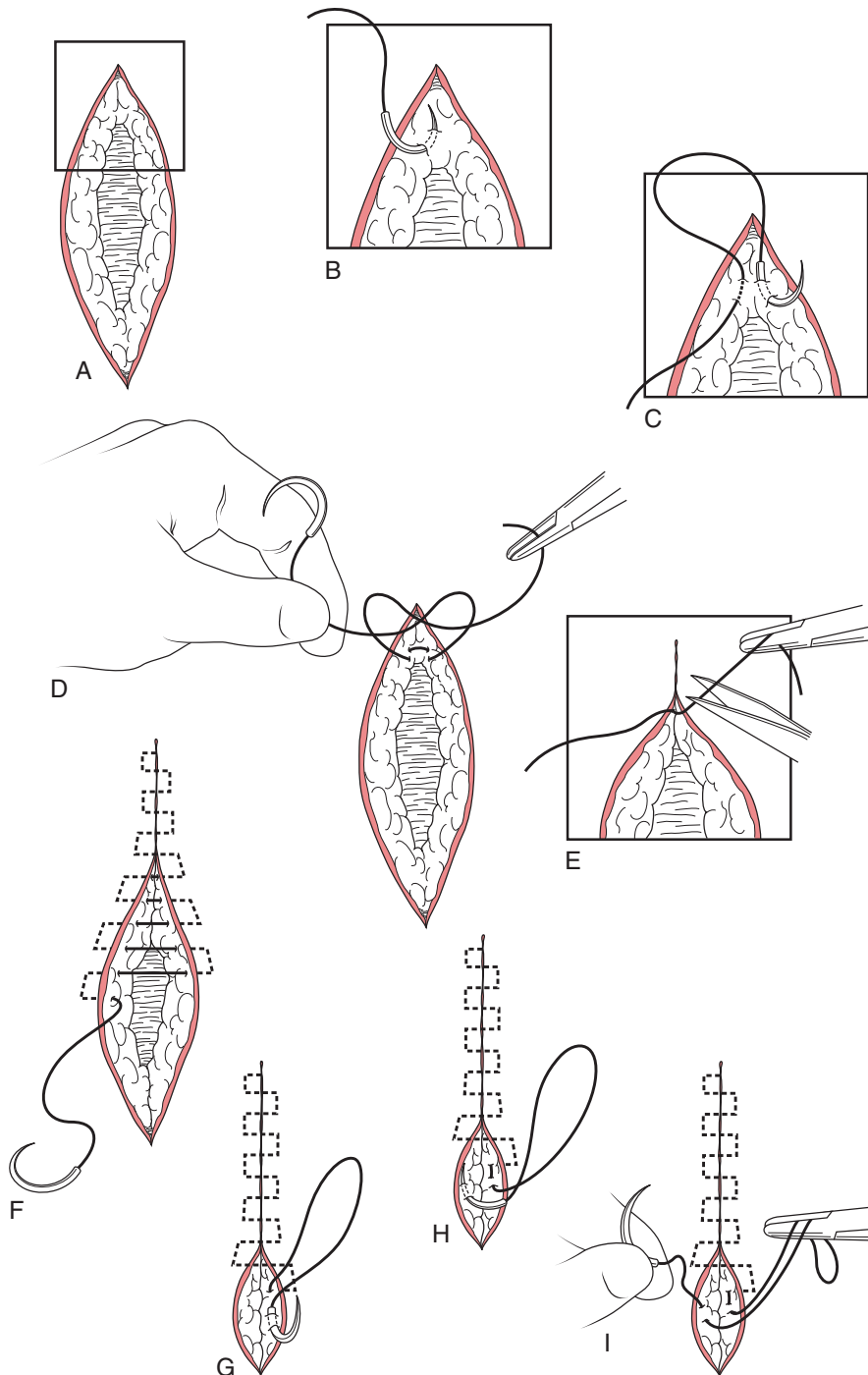
Many wounds are irregular and jagged, with corners that need to be secured during closure. Corners and flaps are particularly vulnerable because they receive their blood supply only from an intact base. Improper suturing of the tip of a corner can compromise an already tenuous vascularity.

### Technique for Closing a Corner

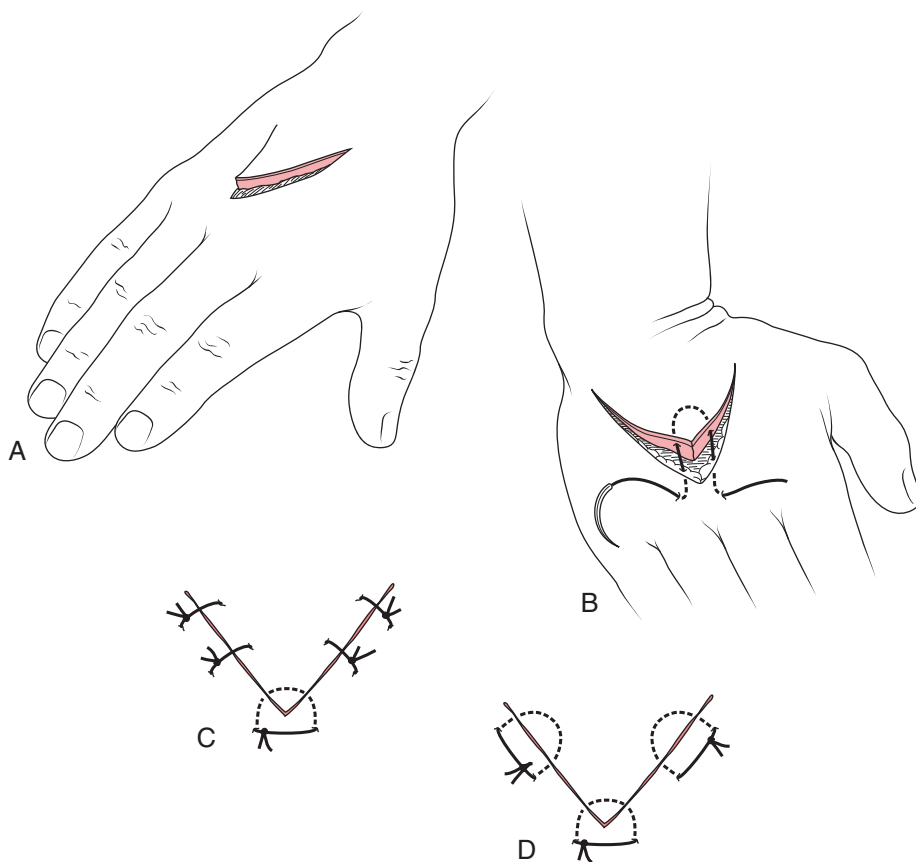
A simple technique to secure a corner without interrupting the small capillaries at the tip is shown in Figure 11-5. The technique used is the half-buried horizontal mattress suture. The suture is introduced percutaneously, through the skin in the noncorner portion of the wound. The needle is brought through the dermis, then passed *horizontally* through the corner dermis and brought back to the same plane of dermis on the opposite side of the noncorner portion. Finally, it is led out through the epidermis.

The key to this suture is that the flap portion of the suture passes horizontally through the dermis and not vertically through the epidermis and the dermis. When the tip is in place with the corner stitch, the remainder of the flap can be closed with interrupted percutaneous or half-buried horizontal mattress sutures, which should be placed far enough from the tip to allow for unrestricted dermal circulation.

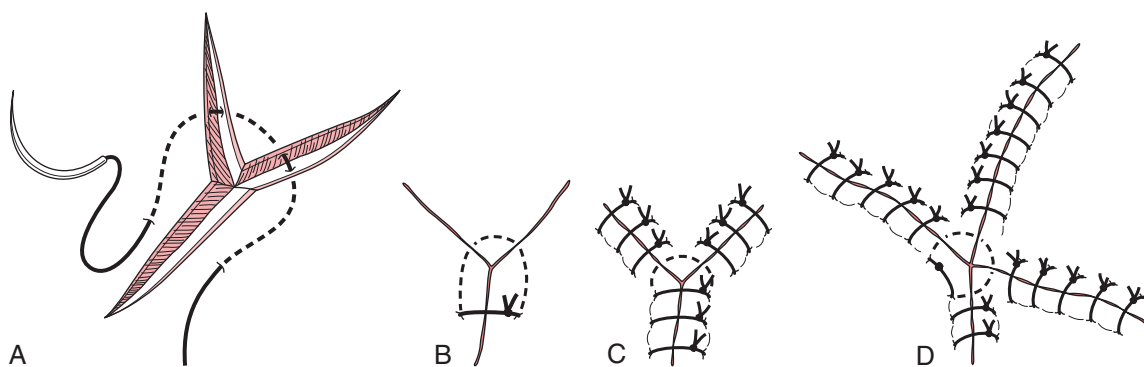
A single corner stitch can encompass several corners of stellate lacerations by capturing all of the corners of flaps (Fig. 11-6) until the final percutaneous reexposure is completed to tie the knot. The corner suture is one of the most useful suture techniques in emergency wound and laceration care for complex wound closure.



**Figure 11-4** A-I, Technique for subcuticular running suture. See text for complete description of technique.



**Figure 11-5** A-D, Technique for closing a corner (flap stitch). See text for complete description of technique.



**Figure 11-6** A-D, Technique for using the corner stitch to close a stellate or multiflap laceration.

## PARTIAL AVULSION, FLAP WOUNDS

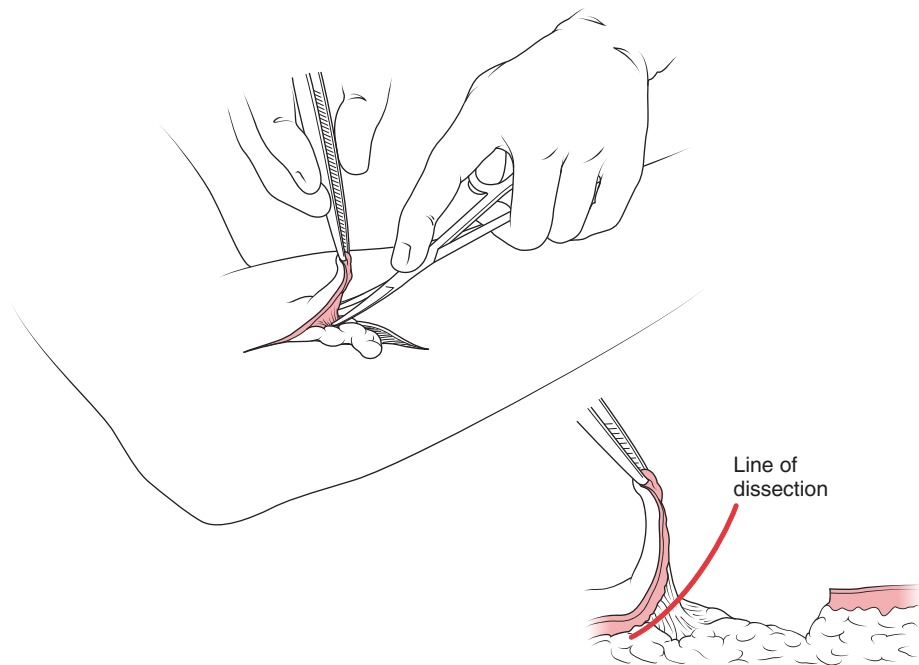
### Description

Flap lacerations are the result of forces that tear up, or avulse, a flap of skin from the subcutaneous tissue. The vascular supply of a complicated flap is even more tenuous because it derives blood from only its intact dermal attachment. A general rule for viability is that the flap base should exceed flap length by a ratio of 3:1.<sup>5</sup> Flaps with lower ratios are less likely to survive. The rule varies according to anatomic site and other considerations. A long, narrow-based flap is in greater jeopardy than a short, broad-based flap.

Flaps that are distally based have the tip pointing opposite to the natural cutaneous arterial flow. They rely solely on venous backflow for oxygen and nutrients. The repair technique has to be meticulous, gentle, and dictated by the condition of the flap, the width of the total wound, and the anatomic location. Flaps that are proximally based usually have adequate perfusions, but the repair has to be no less careful.

### Technique for Preparing and Repairing a Complicated Flap

Excessive fatty superficial fascia (subcutaneous tissue) on the underside or dermal part of the flap can impair healing when it is secured with sutures. A raw dermal surface is preferable to damaged fat when the flap is replaced in the laceration defect. In this sense, flaps are similar to grafts. To improve the chance of flap survival during early healing, it is best to remove the excessive fat from the flap before suturing (Fig. 11-7). Iris scissors can be used to trim the fat until only a fresh tissue surface remains.

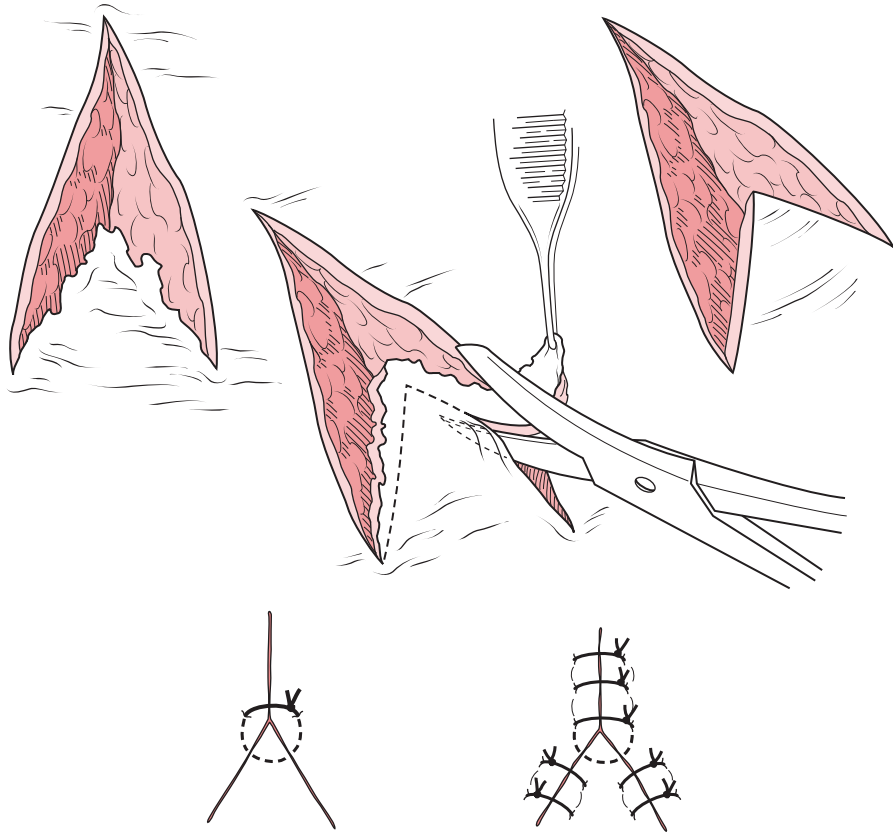


**Figure 11-7** Technique for defatting the base of a flap for better union and vascularization to occur after suture anchoring. Fat is removed at the dermal–superficial fascia plane.

If the flap is otherwise in good condition with viable edges, the initial suture is the half-buried mattress suture described earlier for corner closure. The remainder of the flap can be closed with the same suture technique for the corner closure with simple interrupted percutaneous sutures.

### Technique for Closing Flaps with Nonviable Edges: V-Y Closure

Often flaps have damaged edges that are not viable, in which case the edges can be excised to create a smaller but more viable flap. Figure 11-8 shows how this flap is secured by converting a V closure to a Y closure to accommodate the smaller amount of tissue available. With iris scissors, the edges of the flaps are trimmed back to viable tissue. The remaining flap is not large enough, however, to accommodate the resultant defect. By using a modified corner stitch technique, the flap tip can be brought together with the wound edges in a Y configuration. The remainder of the wound is closed with small-bite percutaneous interrupted sutures. Similar to the previously mentioned complicated flap, defatting also is recommended if appropriate.



**Figure 11-8** Technique for closure of flaps with nonviable edges: the V-Y closure. The edges of the flap are excised. The remaining flap is not large enough to fill the defect; a corner stitch is placed to close the wound as a Y instead of its original V configuration.

### Technique for Closing a Wound with a Completely Nonviable Flap

Some flaps are beyond revision or repair. In this case, closure can be achieved by “ellipsing” the flap (Fig. 11-9) and completely closing the wound by following the 3:1 ratio rule for ellipse closure (see Chapter 9). In some cases, there is insufficient tissue redundancy so that ellipsing is not feasible and the wound has to be considered for open healing (secondary intention) or grafting.

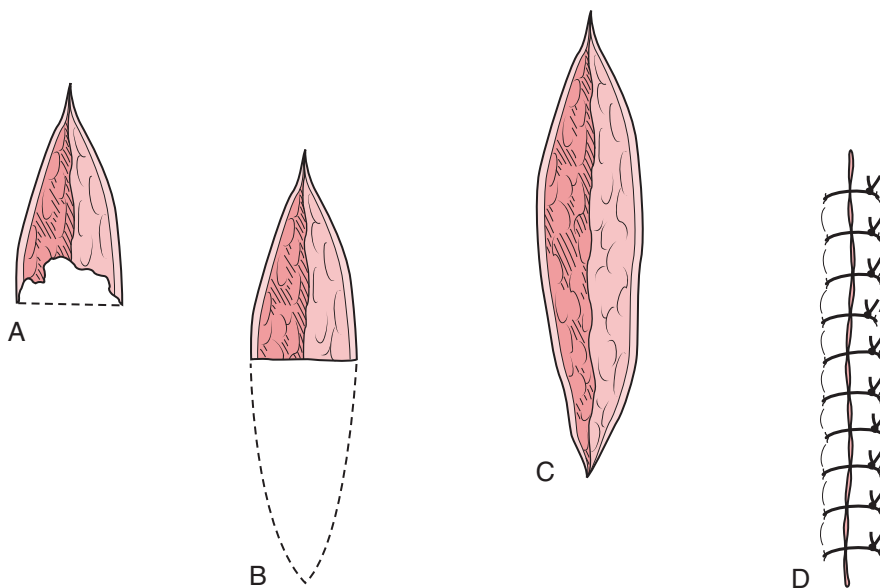
## GEOGRAPHIC LACERATIONS

### Description

One of the most challenging wounds is the *geographic laceration*, a wound that can be irregular in configuration and depth. These lacerations are caused by differential forces occurring at the same time to create a complex wound. Closure requires some creativity.

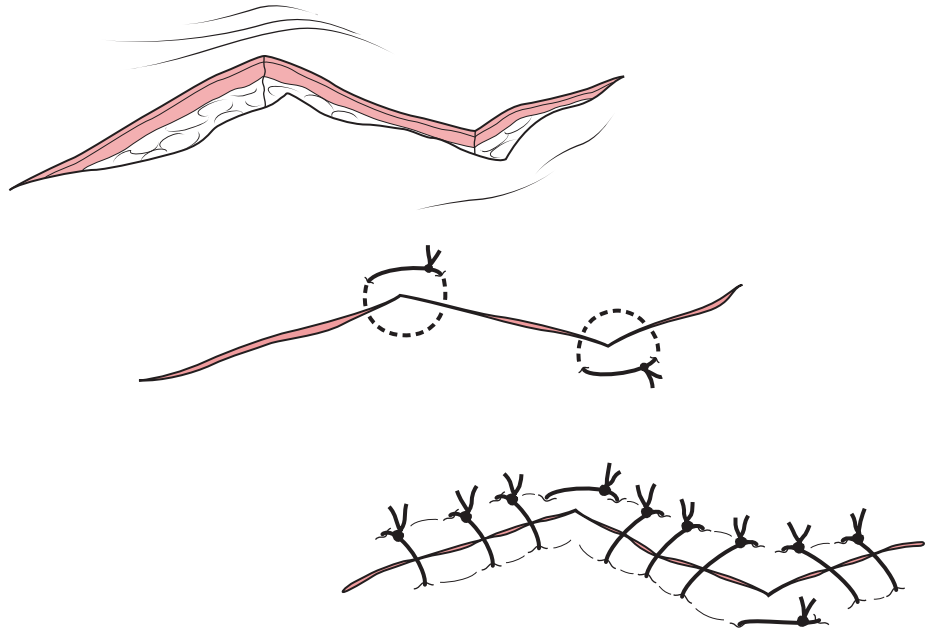
### Technique for Closure of Geographic Wounds

The first principle in closure of geographic wounds is to appose the natural geographic points (Fig. 11-10). After that, simple percutaneous interrupted sutures might suffice, but a creative mix of different techniques and suture sizes ultimately might be required. Closure techniques may appear unorthodox, but for traumatic wounds, the maxim “whatever works” should be followed to obey basic closure principles and achieve the best possible result.



**Figure 11-9** A–D, Technique for closure of a wound with a completely nonviable flap. In this case, a complete ellipse can be fashioned and closed primarily.





**Figure 11-10** Technique for closure of geographic wounds. Obvious geographic points are apposed first with either simple percutaneous sutures or corner sutures.

## COMPLETE AVULSIONS

### Description

When tissue is lost or avulsed through the primary wounding event, several considerations have to be addressed. Full-thickness losses are identified by the complete loss of dermis. Superficial fascia (subcutaneous fat) “shows” through the wound. Partial-thickness losses are identified by the raw appearance of underlying dermis without its covering epidermis. Partial-thickness losses, especially when intact dermal elements are visible, heal well without aggressive intervention. Generally, any full-thickness defects less than or equal to 1 to 2 cm<sup>2</sup> in area, can be left to heal by open healing (secondary intention). This rule also applies to wounds on fingertips.

Full-thickness gaps or defects that are greater than 2 cm<sup>2</sup> in area need to be considered for grafting. Whenever questions about the possibility of grafting arise, consultation with a specialist is recommended. Some defects can be closed primarily, without grafting, and suggested techniques are described subsequently.

### Technique for Converting a Triangle to an Ellipse

If the avulsion defect is configured as a triangle, conversion of that defect to an ellipse can be made by extending with excision the “defect” (Fig. 11-9B to 11-9D). If the basic 3:1 length-to-width rule (see Chapter 9) can be maintained during this process, the whole defect can be closed with a few dermal (deep) supporting sutures and a line of percutaneous sutures with the result of a simple, single suture line. Undermining may be required to bring the

wound edges together to reduce wound edge tension. There must be sufficient tissue redundancy to perform this closure successfully.

### Technique for Closing a Circular or Irregular Defect

The simplest way to close a circular or irregular defect is to turn it into an ellipse as shown in Figure 11-11. If the defect is too great, a double V-Y closure technique can be used. In this case, the defect is covered by two sliding pedicle flaps created by a no. 15 blade (Fig. 11-12). It is crucial not to disturb the fascial attachments of the flaps and interrupt the blood supply. The dermis is incised without including the subcutaneous tissue to allow the flaps to move forward on their vascular base into the gap.

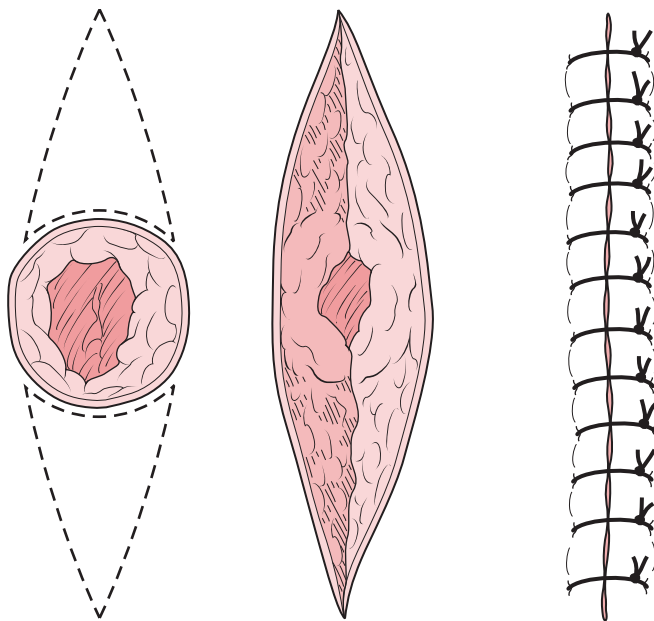
## DOG-EAR DEFORMITIES

### Description

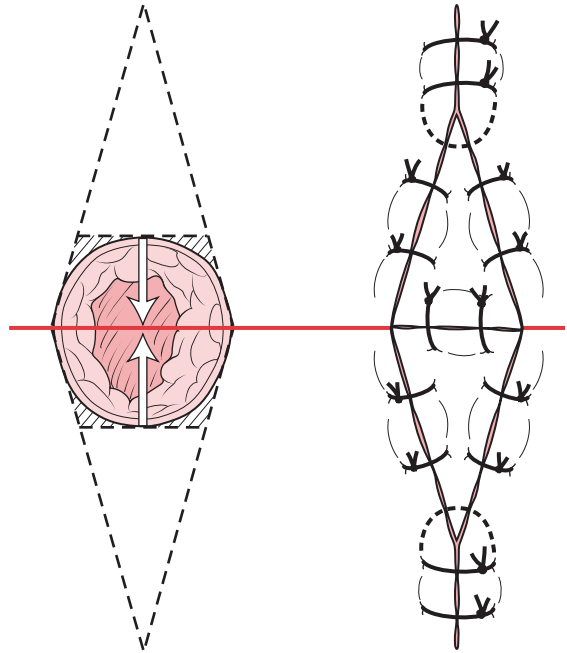
Trying to close a laceration evenly, particularly if it has a curving configuration, can lead to bunching of one or both of the wound edges as the suture closure proceeds. One edge of the wound can become redundant and can lead to the creation of a “dog ear.”

### Technique for Closing a Dog Ear

To correct a dog-ear deformity, an incision is made with a no. 15 blade, beginning at the end of the wound and at a 45-degree angle from the direction of the laceration on the side of the redundancy (Fig. 11-13). The redundant tissue flap is excised along an imaginary line that directly corresponds with the incision. The remaining portion of tissue fits the new configuration of the laceration incision and is appropriately sutured. The final outcome is a slightly angulated wound with a “hockey-stick” appearance.



**Figure 11-11** Technique for closure of a circular defect by the ellipse method.



**Figure 11-12** Technique for closure of a circular or irregular defect by advancing flap pedicles to effect a double V-Y closure. (Adapted from Zukin D, Simon R: *Emergency wound care: principles and practice*, Rockville, Md, 1987, Aspen Publishers.)

## PARALLEL LACERATIONS

### Description

Two or more parallel lacerations that are in close proximity are often the result of self-inflicted wounds on the wrists or forearms. They are usually superficial, but because of the nature of the anatomic site, these wounds can result in significant injuries to the underlying flexor structures of the wrist. Careful functional testing of nerves and tendons with wound exploration often is necessary before closure.

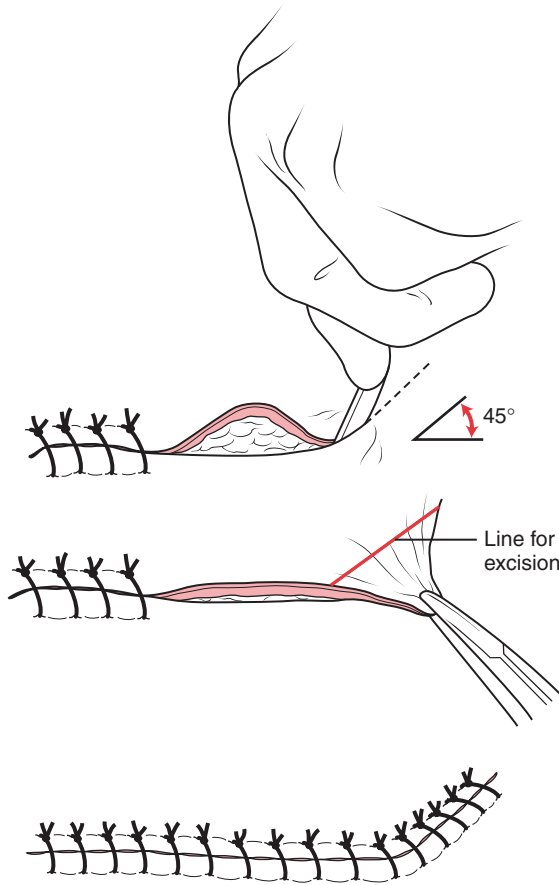
### Technique for Closure of Parallel Lacerations

After close inspection and exploration to rule out tendon or nerve damage, the caregiver will choose from several methods for closing parallel lacerations without compromising the blood supply to the tissue "strips" between lacerations. Some wounds can be closed with the horizontal mattress suture, modified to cross all lacerations (Fig. 11-14A). Wound tapes are particularly effective if the lacerations are superficial (Fig. 11-14B). Finally the alternating percutaneous approach can be used if the vascular supply of the tissue would not be compromised (Fig. 11-14C).

## THIN-EDGE, THICK-EDGE WOUNDS

### Description

Occasionally a wound in which the thickness of one edge is markedly different from the other wound edge can be created. There is unequal dermal loss during injury. To appose the two edges properly, simple percutaneous interrupted sutures do not suffice. The thin edge has to be elevated to meet the appropriate layers of the full-thickness edge.



**Figure 11-13** Technique for closure of redundant tissue, or a dog ear. The incision is made approximately at a 45-degree angle from the original axis of the wound. See text for complete description of technique.

### Technique for Closing a Thin-Edge, Thick-Edge Wound

A technique for closing a thin-edge, thick-edge wound is to use the half-buried horizontal suture in the manner shown in Figure 11-15. The thin edge (dermis lost) is captured by the suture and is brought up to match the thick edge (dermis preserved).

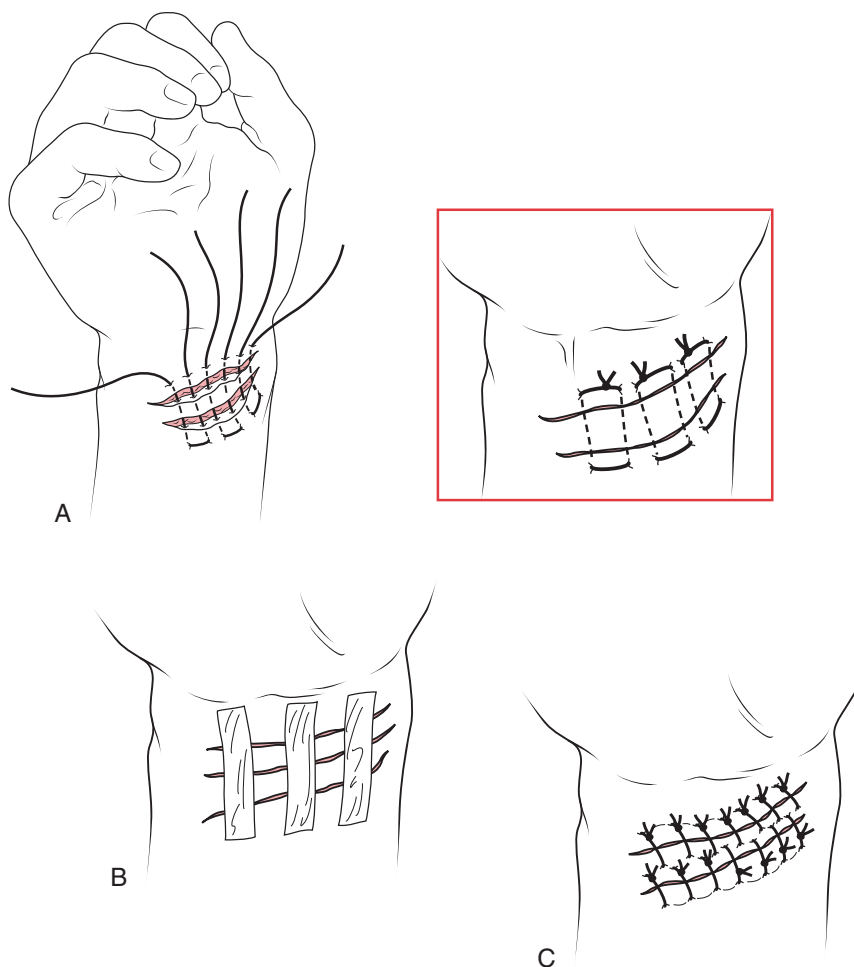
## LACERATION IN AN ABRASION

### Description

Another complex wound is the loss of surface skin accompanied by a laceration in the defect.

### Technique for Closing a Laceration in an Abrasion

The laceration can be repaired by using the deep (dermal) closure with the knot buried under the wound surface (see Chapter 10). When the laceration is closed (Fig. 11-16), the defect can be managed by allowing it to close by secondary intention or grafting.

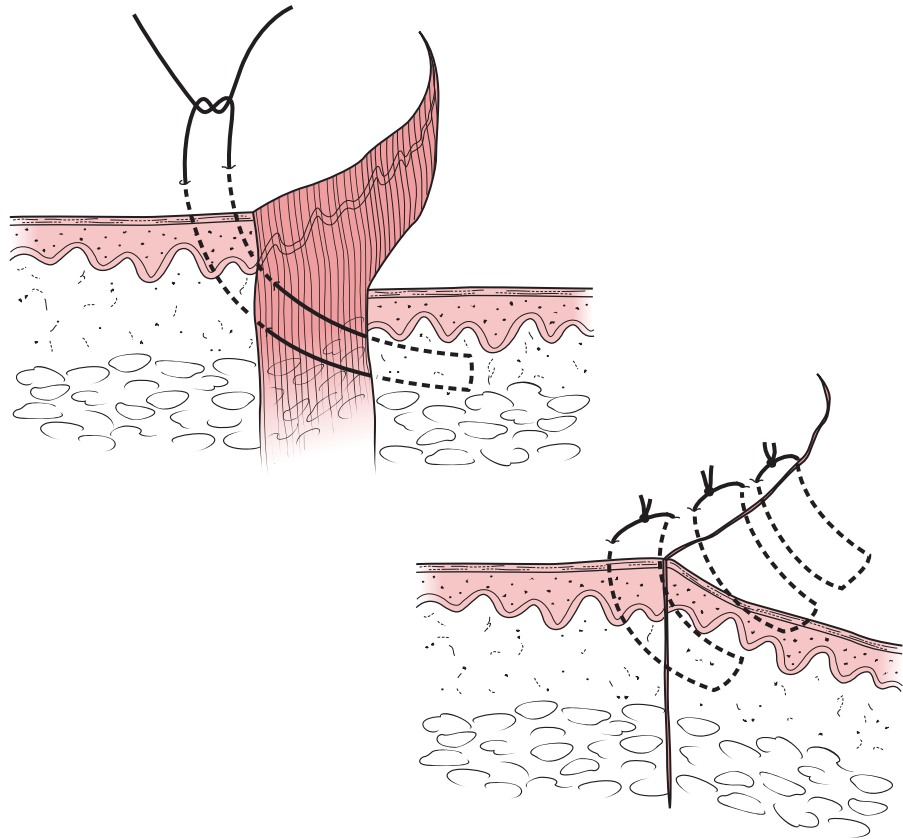


**Figure 11-14** Three techniques for closure of parallel lacerations. **A**, The horizontal mattress technique is used to cross all lacerations for closure. **B**, Wound tapes can be used to close these lacerations. **C**, If the island of tissue is wide enough, alternating sutures can be used on each laceration. It is necessary, however, to be careful not to compromise vascular supply when using this technique. (Adapted from Zukin D, Simon R: *Emergency wound care: principles and practice*, Rockville, Md, 1987, Aspen Publishers.)

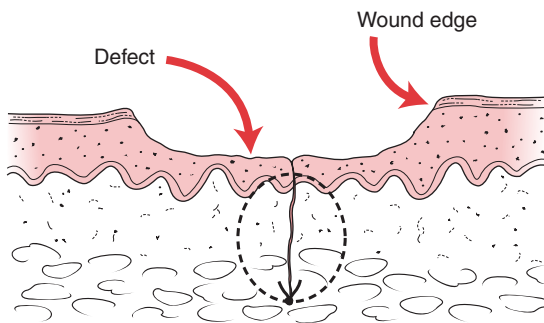
## WOUNDS IN AGED SKIN

### Description

People with older, thinner skin are subject to large partial avulsions of skin even if the traumatic forces involved are minor. In addition to the laceration, the skin separates at the dermal–superficial fascia plane (subcutaneous layer) resulting in a flap. The skin is thin and friable and does not hold sutures well. Patients on long-term, large-dose corticosteroid therapy have altered skin biomechanics that result in similar disruptions.



**Figure 11-15** Technique for closure of a thin-edge, thick-edge laceration. The horizontal mattress technique is used; however, one portion is buried and not brought through the opposite side of the wound surface.



**Figure 11-16** Technique for closure of a laceration within a deep abrasion. The deep-suture technique is used, and the abraded surface is avoided.

## Techniques for Closing Wounded Aged Skin

It is important not to close aged, friable skin under tension. Attempts to do so can risk the already tenuous vascularity of the skin and result in a large area of tissue loss. If the wound cannot be brought back together properly without undue tension, it is best to leave a gap for later grafting. Under these conditions, consultation with a specialist is recommended.

If the wound edges can be apposed easily, the simplest method to close friable, elderly skin is to use wound tapes. Applying the tapes is technically not difficult. Because of their adherence, wound tapes are allowed to fall off on their own or are removed carefully so as not to disrupt the delicate, early, collagenous bonds of healing.

Another closure method is to appose the edges with horizontal mattress sutures (see Fig. 10-7). The configuration of this suture allows for maximal "gathering" of tissue, and minimal "tearing" forces are applied.

### REFERENCES

1. Wong NL: Review of continuous sutures in dermatologic surgery, *J Dermatol Surg Oncol* 19:923-931, 1993.
2. Swanson NA, Tromovitch TA: Suture materials, 1980s: properties, uses, and abuses, *Int J Dermatol* 21:373-378, 1982.
3. Bernstein G: Polybutester suture, *J Dermatol Surg* 14:615-616, 1988.
4. Winn HR, Jane JA, Rodeheaver GT: Influence of subcuticular sutures on scar formation, *Am J Surg* 133:257-259, 1977.
5. Grabb WC: Introduction to the clinical aspects of flap repair. In Grabb WC, Myers MB, editors: *Skin flaps*, Boston, 1975, Little, Brown.

# CHAPTER 12

## Special Anatomic Sites

### SCALP

- Preparation for Closure
- Uncomplicated Lacerations
- Galeal Lacerations
- Compression Lacerations with Irregular Margins
- Avulsion or Scalping Lacerations
- Aftercare

### FOREHEAD

- Preparation for Closure
- Uncomplicated Lacerations
- Complex Lacerations
- Aftercare

### EYEBROW AND EYELID

- Preparation for Closure
- Closure of Extramarginal Lid Lacerations
- Closure of Intramarginal Lid Lacerations
- Closure of Eyebrow Lacerations
- Aftercare

### CHEEK OR ZYGOMATIC AREA

- Preparation for Closure
- Closure of Uncomplicated Cheek Lacerations
- Deep or Through-and-Through Lacerations
- Aftercare

### NASAL STRUCTURES

- Preparation for Closure
- Skin Lacerations
- Nostril and Cartilage Wounds
- Septal Hematoma
- Lacerations with Bone Involvement
- Aftercare

### EAR

- Preparation for Repair
- Uncomplicated Lacerations
- Lacerations Involving Cartilage
- Perichondral Hematoma
- Aftercare

### LIPS

- Preparation for Closure
- Uncomplicated Lacerations
- Complicated and Through-and-Through Lacerations
- Aftercare

### ORAL CAVITY

- Preparation for Repair
- Buccal Mucosal and Gingival Lacerations
- Tongue Lacerations
- Aftercare
- Dental Trauma

### PERINEUM

- Preparation for Closure
- Lacerations of the Penis and Scrotum
- Lacerations of the Introitus
- Aftercare

### KNEE

- Aftercare

### LOWER LEG

- Aftercare

### FOOT

- Aftercare

Although the wound closure principles and suture techniques discussed in Chapters 10 and 11 can be applied to all lacerations and wounds, several areas of the body have unique anatomic considerations that require special attention. Particular emphasis is placed on facial wounds because of cosmetic concerns. Initial management and wound closure are crucial to eventual scar formation and the final appearance of the injury. Table 12-1 is a reference guide for choice of suture material and size for each anatomic region of the body. Because of the hand's importance and complexity, it is covered separately in Chapter 13.



TABLE 12-1 *Suggested Guidelines for Suture Material and Size for Body Region*

Body Region	Percutaneous (Skin)	Deep (Dermal)
Scalp	5-0/4-0 monofilament*	4-0 absorbable <sup>†</sup>
Ear	6-0 monofilament	—
Eyelid	7-0/6-0 monofilament	—
Eyebrow	6-0/5-0 monofilament	5-0 absorbable
Nose	6-0 monofilament	5-0 absorbable
Lip	6-0 monofilament	5-0 absorbable
Oral mucosa	—	5-0 absorbable <sup>‡</sup>
Other parts of face/forehead	6-0 monofilament	5-0 absorbable
Trunk	5-0/4-0 monofilament	3-0 absorbable
Extremities	5-0/4-0 monofilament	4-0 absorbable
Hand	5-0 monofilament	5-0 absorbable
Extensor tendon	4-0 monofilament	—
Foot/sole	4-0/3-0 monofilament	4-0 absorbable
Vagina	—	4-0 absorbable <sup>‡</sup>
Scrotum	—	5-0 absorbable <sup>‡</sup>
Penis	5-0 monofilament	—

\* Nonabsorbable monofilaments:

Nylon (Ethilon, Dermalon)

Polypropylene (Prolene)

Polybutester (Novafil)

<sup>†</sup> Absorbable materials for dermal and fascial closures:

Polyglycolic acid (Dexon, Dexon Plus)

Polyglactin 910 (Vicryl)

Polydioxanone (PDS [monofilament absorbable])

Polyglyconate (Maxon [monofilament absorbable])

<sup>‡</sup> Absorbable materials for mucosal and scrotal closure:

Chromic gut

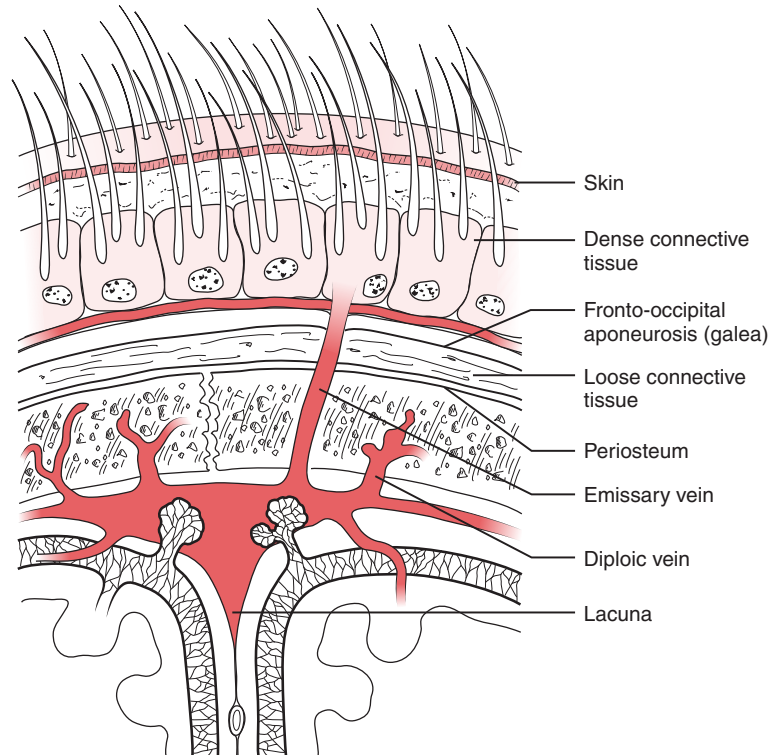
Polyglactin 910 (Vicryl)

## SCALP

The scalp extends anteriorly from the supraorbital ridges to the external occipital protuberance posteriorly. Laterally the boundaries are the temporal lines. There are five layers of the scalp: skin (epidermis, dermis), dense superficial fascia, galea aponeurotica, loose areolar connective tissue, and periosteum (Fig. 12-1). The skin is densely covered with hair. Ragged lacerations often are closed without regard to cosmetics under the assumption that hair will hide the scar. Most men experience some balding in their lifetime, however, a fact that must be taken into consideration during wound closure.

Underlying the skin is a dense layer of connective tissue that corresponds to the superficial fascia. This layer is richly invested with arteries and veins. Although this profuse vascularity protects against the development of infection, the denseness of the connective tissue tends to hold vessels open when the scalp is lacerated. For this reason, even small lacerations can cause considerable bleeding, leading to hypovolemia and hypotension.

The next layer is the galea aponeurotica. It is a dense, tendon-like structure that covers the skull and inserts into the frontalis muscle of the forehead anteriorly and into the



**Figure 12-1** Cross-sectional anatomy of the scalp. Note the emissary vein; it can act as a conduit for bacteria to brain tissues if the scalp wound becomes infected.

occipitalis muscle posteriorly. Failure to repair large, horizontal lacerations of the aponeurosis can cause the frontalis muscle to contract asymmetrically, which can cause a significant cosmetic deformity of the forehead. Closure of galea lacerations also is important for protection of the loose connective tissue that is vulnerable to infection.

Blood and bacteria can spread easily from a laceration of the skin through the injured galea to the loose connective tissue. Within this layer are emissary veins that drain into the skull and intracranial veins. Infection of this space can lead to osteomyelitis or brain abscess. Beneath the loose connective tissue layer is the periosteum of the skull itself. The periosteum can be mistaken for the galea but is not as dense, and it does not readily accept sutures without the risk of tearing.

### Preparation for Closure

Because of the scalp's propensity to bleed profusely, hemorrhage control is necessary before attempts at closure. Hemorrhage is worsened if alcohol is present, a finding in 50% of patients with scalp lacerations.<sup>1</sup> Trying to suture a bleeding scalp wound can be difficult and frustrating. The vessels do not lend themselves to easy clamping or ligation because they are encased in the dense connective tissue. Direct pressure, applied in the manner described, is the most efficacious way to gain hemostasis. First, gross contaminants, if present, are removed immediately with a brief cleansing or irrigation. Then the wound is covered with sterile, saline-moistened sponges and compressed with an elastic bandage. This bandage can

be left in place for 30 to 60 minutes. After compression, significant bleeding usually has been brought under control.

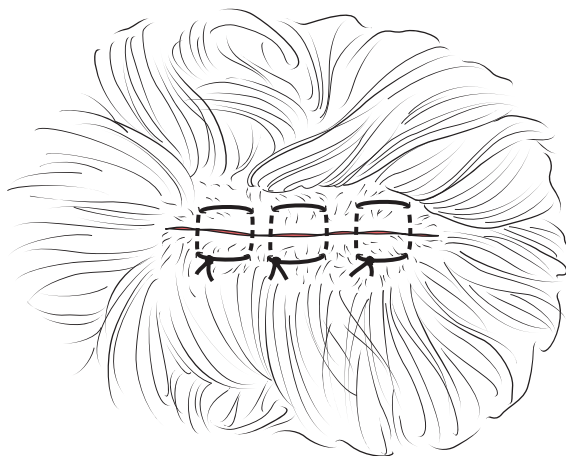
After pressure bandage removal and wound evaluation have been performed, an anesthetic can be administered, and repair can take place under more controlled conditions. Because scalp lacerations frequently occur in intoxicated patients, the strategy of waiting for hemostasis has the added benefit of allowing the patient to “settle down” before any attempts at intervention are made. Another solution to profuse bleeding is to proceed with wound closure using the horizontal mattress technique with large bites (Fig. 12-2). Under these conditions, an assistant can control the bleeding temporarily by putting upward traction on hemostats fixed to the galea. When the wound is closed, the bleeding usually ceases.

Anesthesia for scalp wounds can be accomplished by the direct or parallel wound technique using lidocaine with epinephrine. This solution further controls bleeding if necessary. Visual inspection and digital palpation of large wounds are recommended to identify galeal or bone injuries. The periosteum frequently is injured during trauma. Injuries to this layer often can be seen or palpated through a laceration. Because of its close adherence to the bone, a laceration of the periosteum can be mistaken for a skull fracture. Skull radiographs are recommended to rule out a true fracture, even when an actual break is not found.<sup>1</sup> Radiographs cannot be relied on fully, however, because true fractures not seen on radiographs are common. Despite this dilemma, the real issue is not the presence or absence of a fracture but whether brain injury has occurred.

Hair removal before closure is necessary only if hair interferes with the actual closure and knot tying. Hair is not contaminated with high levels of bacteria and can be cleansed easily with standard wound preparation solutions.<sup>2</sup> In a study of 68 patients with traumatic scalp lacerations, no wound infections were documented in patients whose hair had not been removed before closure.<sup>3</sup> If removal is necessary for mechanical reasons, clipping with scissors or shaving with a recessed blade razor suffices.<sup>4</sup> Shaving at skin level can increase the chance for wound infection.<sup>5,6</sup>

### Uncomplicated Lacerations

Uncomplicated, shearing lacerations can be closed with nonabsorbable 5-0 or 4-0 monofilament nylon, staples, or absorbable chromic gut suture. The last-mentioned material often is



**Figure 12-2** Horizontal mattress suture technique for closure of scalp wounds with uneven or macerated edges.

preferred for children because suture removal becomes unnecessary. Some practitioners find this strategy equally effective for adults. A new suture material, absorbable irradiated polyglactin-910 (Vicryl Rapide), also can be used to close scalp wounds without the need for later removal.<sup>7</sup> Closure outcomes with this material are similar to other methods, with low rates of dehiscence and infection.<sup>8</sup> The most common suture closure method is the percutaneous interrupted technique. The use of staples is common for scalp wounds. Stapled wounds heal the same as wounds treated with standard closure methods.<sup>9,10</sup> In children, the cosmetic outcome of stapled scalp lacerations is no different than the outcome of lacerations closed with standard sutures.<sup>11</sup>

A simple, "low-tech" approach to scalp laceration closure is hair braiding. Because hair removal is not necessary for scalp laceration cleansing and repair, the hair itself can become the closure material.<sup>12</sup> This technique works best for straight and superficial lacerations with enough hair to tie in small knots. The wound is cleansed and irrigated (see Chapter 7). About 10 to 20 hairs on each side of the wound are moistened with saline or water and clumped together to form a "thread." The two threads are tied together in a simple square knot. Forceps can be used to tighten the knot to prevent slippage. A small amount of cyanoacrylate glue (Dermabond) can be applied to the knot to increase security. Sutures and staples provide more overall wound security but require return for removal.

### Galeal Lacerations

Because the galea is a key anchoring structure for the frontalis muscle, large frontal galeal lacerations need to be repaired separately with 3-0 or 4-0 absorbable sutures to prevent a serious cosmetic deformity from developing. If the frontalis muscle loses its anchoring point at the muscle-galeal junction along the frontal scalp line, facial expressions dependent on that muscle appear distorted and asymmetric. Closure of large galeal lacerations in other areas of the scalp also is recommended to protect the loose connective tissue layer from infection.

### Compression Lacerations with Irregular Margins

Often lacerations of the scalp are caused by blunt rather than sharp shearing forces. The wound and its edges are irregular and macerated. Simple closure with percutaneous, interrupted sutures can be difficult under these conditions. The scalp does not have excessive tissue redundancy, so débridement has to be kept to a minimum, or the wound cannot be approximated without abnormally high tension. The rich vascularity of the scalp allows for eventual successful healing even if less than optimal tissues are brought together. After judicious wound edge trimming, the horizontal mattress suture technique is recommended to approximate the remaining edges (see Fig. 12-2). This technique also is useful for closing an excessively bleeding wound.

Compression injuries can result in complex, stellate lacerations. Judicious débridement is advised. The corner closure (flap) technique described in Chapter 11 often approximates all of the corners and flaps in one suture. The remainder of the repair is carried out with simple percutaneous or half-buried mattress sutures.

### Avulsion or Scalping Lacerations

High-speed forces that are delivered in a tangential manner to the scalp can cause large flaps or complete loss of portions of the scalp. Associated intracranial injury also can occur. These wounds are best managed by a consultant. Preserved portions of complete scalp avulsions, similar to other amputated parts, are wrapped in saline-moistened gauze, placed in a plastic bag, and cooled over ice. It is possible that they might be reimplanted in the defect by using grafting or microvascular anastomosis techniques.

## Aftercare

After repair, it sometimes is necessary to place a temporary (24-hour), light-pressure compression wrap with an elastic bandage over the scalp dressing of large lacerations to prevent formation of wound hematoma. The patient can be instructed to remove the bandage after the recommended compression period.

Most scalp lacerations do not require dressing, just a thin layer of an antibacterial ointment. Scalp sutures are left in place for 7 to 9 days for adults and 5 to 7 days for children. Gentle bathing of the scalp can commence 24 hours after closure. Daily application of ointment after cleansing is recommended.

---

## FOREHEAD

The forehead is a common site of injury in children and adults. It also is of paramount cosmetic importance because of its visibility. Three principles govern the initial repair of a forehead injury, as follows:

- Skin tension lines that parallel skin creases play a major role in the outcome of any laceration. A laceration that is perpendicular to dynamic skin tension lines tends to heal with a more visible scar than one that is parallel to these lines (see Chapter 3).
- The forehead has little excess tissue to permit extensive revisions and excisions. The temptation to excise ragged wounds has to be assessed carefully or resisted. A small defect inadvertently can become larger by overaggressive repair efforts.<sup>13</sup> It is often best to preserve as much tissue as possible just by “tacking down” ragged tissue tags so that later cosmetic revisions can be made when conditions are more favorable.
- Whenever possible, few dermal (deep) absorbable sutures should be placed. Excessive tissue reaction with increased scar size can result from deep sutures.

## Preparation for Closure

Anesthesia for small or single lacerations of the forehead can be accomplished by the direct or parallel injection techniques, using an anesthetic with epinephrine to decrease bleeding. Large or multiple lacerations often are managed best by a forehead block (see Chapter 6). This block reduces the number of needle-sticks and prevents distortion of the tissues to allow for more accurate wound edge approximation.

When anesthesia is achieved, the wound can be explored for any bony abnormality or foreign body; radiographs are recommended when the suspicion for either is raised. Large pieces of glass can be discovered under small and innocuous-appearing wounds. After gentle scrubbing with a sponge, irrigation, and débridement with the tip of a no. 11 blade, most foreign material should have been removed. Any remaining permanent material can be surgically removed. Every effort is made to remove potential tattooing objects at the time of the first repair. When in doubt, consultation with a specialist should be considered.

## Uncomplicated Lacerations

Most lacerations can be closed with the simple percutaneous technique using a 6-0 monofilament nonabsorbable suture. Deeper lacerations may require placement of a few supporting dermal (deep) 5-0 absorbable sutures. The percutaneous technique in any laceration should be performed by taking small bites (close to the wound edge) with several sutures rather than large bites with few sutures. This technique reduces wound edge tension and allows for more accurate wound edge apposition.

## Complex Lacerations

### *Multiple Small Flaps, Lacerations, and Abrasions (Windshield Injury)*

One of the most daunting wounds is a “windshield” injury, characterized by multiple lacerations, abrasions, gouges, and small flaps. The anesthetic technique of choice is the forehead block. Flaps that are smaller than 5 mm in width and length are tacked down with single 6-0 percutaneous nonabsorbable sutures (Fig. 12-3). Larger flaps can be closed by using the corner technique. Partial-thickness abrasions and shallow gouges (<5 to 10 mm wide and 1 to 2 mm deep) can be left to heal by secondary intention. Other lacerations are closed as necessary with percutaneous sutures. A petroleum-based antibiotic ointment applied three times a day suffices as a dressing. Because of cosmetic concerns, a consultant might be helpful, especially if the wounds are severe. Consultation also is appropriate if the estimated time of repair would interfere with an emergency physician’s other duties, even if there is little technical challenge.

### *Ragged-Edge Lacerations, Large Flaps, and Tissue Defects*

Lacerations with ragged and macerated edges can be trimmed as described in Chapter 9. If the unevenness or maceration is not extensive, complete excision is an option if the laceration is parallel to the skin tension lines and there is sufficient tissue redundancy. Lacerations perpendicular to skin tension lines have less tissue redundancy and cannot tolerate wide excision. The principle of tissue preservation has to be kept in mind when considering excision. When there is any doubt about tissue availability for excision, the caregiver should try to preserve what is viable or obtain a consultation.

Large avulsion flaps and near-scalping injuries are prone to what is called the *trapdoor phenomenon*, in which congestion and lymphedema lead to unsightly bulging of the flap after repair. The flaps are U-shaped with the base in a superior position on the forehead. These injuries are best managed by a consultant.



**Figure 12-3** Small abrasions/lacerations, caused by a windshield injury, often can be closed by using simple, single, percutaneous sutures or single corner sutures.

## Aftercare

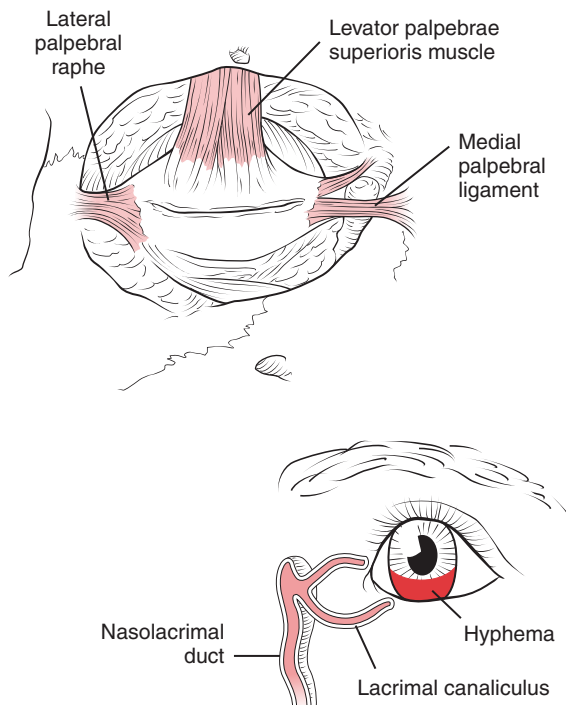
Facial lacerations usually do not require dressings. Daily application of an antibacterial ointment after gentle cleansing is recommended for protection and to allow for easier suture removal (by reducing crusting). Cotton swabs moistened with a mild soap and water solution or hydrogen peroxide are useful for cleaning in and around facial lacerations. Facial sutures are removed within 3 to 5 days to prevent suture mark formation. Larger lacerations (>2 cm) are supported by wound tape for 1 week after suture removal.

## EYEBROW AND EYELID

The eye and periorbital tissues are susceptible to serious injury by relatively minor trauma. Figure 12-4 illustrates various structures that must be checked for damage before repair proceeds. If any of the important anatomic parts discussed here are involved, immediate referral to a consultant is recommended.

Lacerations of the medial lower lid can injure the tear duct apparatus (lacrimal canaliculus and nasolacrimal duct) or the medial palpebral ligament at the medial canthus. Copious tears running down the cheek of the patient are a sign of possible tear duct injuries. A laceration of the medial palpebral ligament displaces the lid apparatus laterally, giving the appearance that the patient is "cross-eyed."

The levator palpebrae muscle is responsible for maintaining the eyelid in its normal position when open. Interruption of the muscle causes traumatic ptosis. Injury to the muscle is suspected when periorbital fat can be seen to extrude from a laceration of the upper lid.



**Figure 12-4** Important anatomic structures that can be injured during eye trauma. The integrity of these structures must be confirmed before the closure of any laceration (see text).

Periorbital fat signifies that the orbital septum has been violated. The levator muscle originates from the septum; any septum injury risks this muscle.

Close inspection of the eye itself is necessary to rule out a hyphema, corneal abrasions, and foreign bodies. Of these injuries, hyphema is the most serious. It is caused by a direct blow to the eye and is recognized by a blood layer in the anterior chamber of the eye in patients in the upright position. In patients who are supine, blood distributes evenly in the anterior chamber over the iris and gives the iris a different color from the opposite iris. The patient also complains of decreased vision in the affected eye. Having the patient sit up reveals the hyphema as the blood settles with gravity.

### Preparation for Closure

It is best to deliver an anesthetic to the eyelid by direct wound infiltration, using a small 27G or 30G needle. Epinephrine-containing anesthetics are not necessary. For the eyebrow, the same technique is used, but epinephrine in the anesthetic can be useful to control minor bleeding. Special care is taken to minimize spillage of cleansing agents into the eye to prevent unnecessary corneal irritation. Povidone-iodine solution (not a detergent-containing solution) diluted 1:10 with saline and nonionic surfactants (Shur-Clens) are the cleansing agents of choice.<sup>14</sup> Inadvertent spilling of these preparations can be prevented by holding a folded 4 × 4 sponge over the closed eyelid margin to absorb free solution. The caregiver should never shave the hair from the lid margin or brow because of the unpredictability of hair regrowth in these locations.

### Closure of Extramarginal Lid Lacerations


Extramarginal lacerations are usually horizontal and occur most commonly in the upper lid. If extramarginal lacerations are simple and superficial, they can be repaired with a single layer of 6-0 nonabsorbable suture material (Fig. 12-5). No dressing is applied. These lacerations heal well enough that scars become virtually unnoticeable with time.

Until more recently, nonabsorbable suture was the only material recommended for skin closure of the face. In practice, some physicians have started closing face and eyelid lacerations with rapidly absorbable polyglactin-910 (Vicryl Rapide). The principal advantage is that these sutures do not require a return visit for removal. The rapid resorption property of this material causes the sutures to fall away naturally within 7 to 10 days. In a study of periorbital skin wounds closed with 7-0 Vicryl Rapide, healing was observed to be equal to healing with nonabsorbable nylon.<sup>15</sup> No suture marks were present at 2 months in the Vicryl Rapide group.

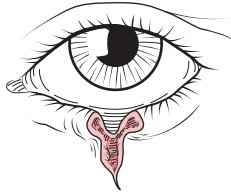
### Closure of Intramarginal Lid Lacerations

Intramarginal lacerations involve the lid margin and, similar to lip lacerations, require extremely precise repair to ensure proper alignment. Abnormal eversion (ectropion) or inversion (entropion) is a complication of improper alignment. Intramarginal injuries probably are best left to a consultant for repair (Fig. 12-6).

**Figure 12-5** Extramarginal lacerations of the upper lid are usually horizontal and can be closed with a simple row of percutaneous closures.







**Figure 12-6** A vertical, intramarginal lid laceration is best left to a consultant to repair.

### Closure of Eyebrow Lacerations

Simple, uncomplicated eyebrow lacerations can be closed with a 5-0 nonabsorbable monofilament. As previously mentioned, the eyebrow is never shaved or trimmed. Occasionally, one or two dermal (deep) closures are necessary to approximate the superficial fascia. Great care is taken to align the brow margins properly to prevent a cosmetic deformity. Alignment sutures at the superior and inferior margins of the brow hair are placed to initiate closure. Deep sutures, if required, can be placed after the alignment sutures.

If the laceration has particularly ragged or macerated edges, trimming or careful excision can be carried out. A basic principle to observe is that any débridement has to be parallel to the brow hair shafts (Fig. 12-7). Failure to observe this principle can lead to an unnecessary defect after the repair.

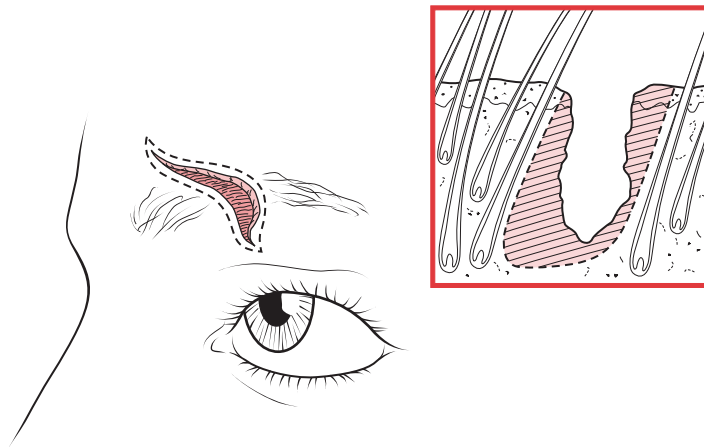
### Aftercare

No dressing is necessary for lid or brow lacerations. Daily cleansing followed by application of an antibacterial ointment is recommended. Sutures are removed in 3 to 5 days in children and adults.

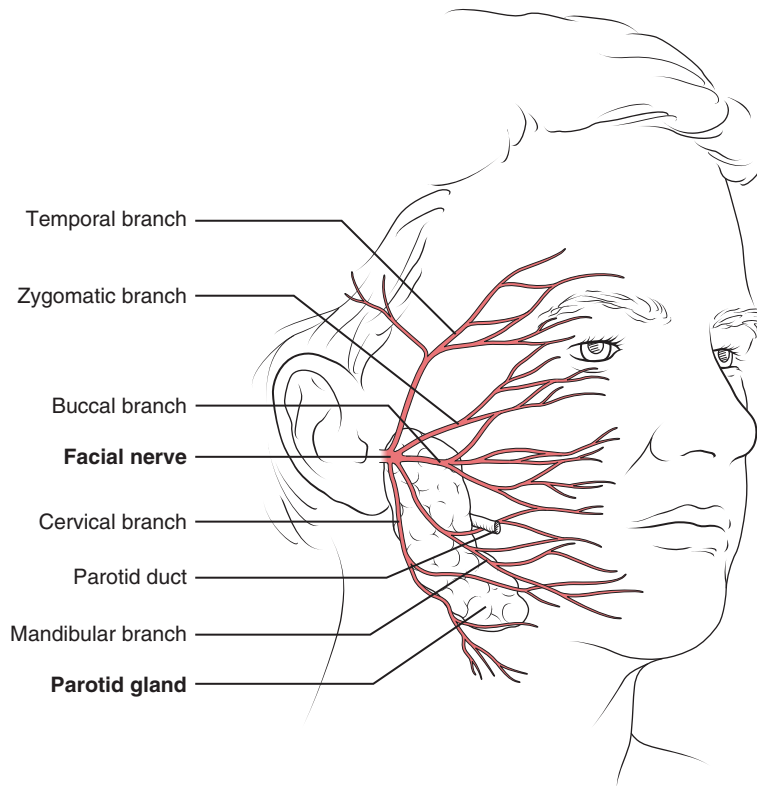
---

## CHEEK OR ZYGOMATIC AREA

There are two major structures underlying the cheek area, just anterior to the ear, that can be injured by penetrating lacerations: the parotid gland and the facial nerve (Fig. 12-8). If the



**Figure 12-7** Most eyebrow lacerations can be closed without tissue débridement. If macerated or devitalized tissue must be removed, however, it is important to excise this tissue parallel to the hair shaft. This excision technique prevents an unsightly cosmetic defect.



**Figure 12-8** The parotid gland and facial nerve underlie the zygomatic and cheek areas. Any lacerations anterior to the ear must be assessed carefully for injuries to the various branches of the facial nerve, parotid gland, or parotid duct.

parotid gland is injured, salivary fluid can be seen leaking from the wound. Inspection of the inside of the mouth often reveals bloody fluid coming from the opening of the parotid duct located on the buccal mucosa of the cheek at the level of the upper second molar tooth.

Lacerations of this region also can injure the facial nerve. It is necessary to test all five branches of the nerve to ensure that each one is intact. The temporal branch is tested by having the patient contract his or her forehead and elevate the brow. The function of the zygomatic branch is observed by having the patient open and shut his or her eyes. The act of sniffing with flaring of the nasal alae is also evidence for preserved function of that branch. Buccal and mandibular branches innervate the lips during the acts of smiling and frowning. Finally, the cervical branch is tested by having the patient shrug the neck through contraction of the platysma muscle.

### Preparation for Closure

The cheek is anesthetized and cleansed in the standard manner described earlier and in Chapters 6 and 7. Care is taken to avoid spilling cleansing solutions onto the eye.

### Closure of Uncomplicated Cheek Lacerations

Standard percutaneous technique using 6-0 monofilament closes most lacerations. Many people have natural creases in the skin of the cheek and face. These creases have the same importance cosmetically as the vermilion border of the lip. Proper alignment of them has to

be given special attention. Often the initial percutaneous suture is placed to align with the crease before proceeding with the remainder of the closure.

### Deep or Through-and-Through Lacerations

Complex lacerations that travel deep into the soft tissues of the cheek or those that penetrate the oral cavity are at risk for injuring the parotid gland or facial nerve as mentioned earlier. If neither the parotid gland nor the facial nerve is injured, repair can proceed. If there is any doubt, a consultant is required. The oral cavity portion of a penetrating laceration is left open unless it is large (>3 to 5 cm). Large mucosal lacerations are closed with 5-0 chromic gut suture. The external wound is irrigated and closed with 6-0 monofilament.

### Aftercare

Dressings are usually unnecessary for lacerations in this area. Daily cleansing and application of an antibacterial ointment allow for easier suture removal at the 3- to 5-day interval for children and adults.

---

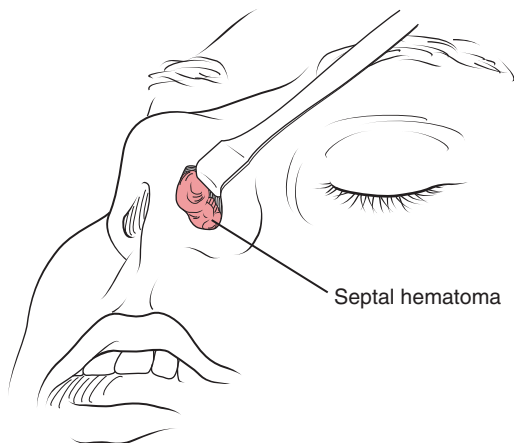
## NASAL STRUCTURES

The nose is composed of a bony and a cartilaginous skeleton. Similar to the ear, direct blows to the nose can cause the formation of a hematoma that compresses the cartilaginous septum (Fig. 12-9). If not drained, this hematoma can lead to collapse through pressure necrosis of this important structure. Lacerations of the nose are common and often are associated with fractures. Radiographs do not always identify fractures, and palpation is a more sensitive indicator of bone injury and displacement.

The skin of the nose is inflexible with little redundancy. It also tears easily with percutaneous suture placement. Consequently, repairs have to be done with great care. Any débridement should be considered only in consultation with a facial specialist.

### Preparation for Closure

Before preparation and closure, the nose is inspected for the injuries mentioned in the previous section. Septal hematoma is recognized by its bluish, bulging appearance in the area of Kiesselbach's area (anterior septal area). The preferred method of examination is with a



**Figure 12-9** Septal hematoma in the area of the anterior nasal septum. Failure to drain this hematoma leads to septal necrosis and collapse.

nasal speculum and an appropriately powerful light source. Penlights and otoscopes might be inadequate.

Anesthesia of the nose is best accomplished by the direct wound infiltration technique with a 27G or 30G needle, using an agent without epinephrine. Nasal blocks are difficult to achieve and usually are reserved for major repairs. Cleansing of the nose is done using povidone-iodine solution and saline irrigation.

### **Skin Lacerations**

Most skin lacerations can be repaired with 6-0 nonabsorbable percutaneous monofilament sutures. Sutures are placed with small bites because nasal skin tends to invert. The skin also is torn easily, so great care has to be taken to avoid creating excessive tension. If tension is present, the placement of one or two deep 6-0 or 5-0 absorbable sutures supports the percutaneous sutures. Complex and irregular skin wounds have to be handled carefully. Because there is little redundancy of nasal skin, débridement has to be minimal. The best strategy is to “tack down” small tags or flaps percutaneously or to obtain consultation.

### **Nostril and Cartilage Wounds**

Nostril lacerations involve the rim with skin, cartilage, and mucosal injuries. Alignment of the rim is crucial to prevent “notching.” The skin is closed with 6-0 nonabsorbable suture, and the mucosa is sutured with 5-0 or 6-0 absorbable suture. Placement of sutures in the cartilage is not necessary during repair. Closing the skin and mucosa over the cartilage ensures adequate healing. Complete coverage of cartilage is mandatory because of its tendency to develop chronic chondritis if exposed. Avulsion and mutilating injuries of either the skin or the cartilage are best managed by a consultant.

### **Septal Hematoma**

A hematoma over the septal cartilage is drained with a hockey-stick or crescent-shaped incision (Fig. 12-10). The incision is always made in the dependent portion of the hematoma. To prevent reaccumulation, an anterior nasal pack is placed with petroleum jelly (Vaseline)–impregnated gauze, and the patient is referred to a consultant within 24 to 48 hours for follow-up. When packing is placed, antibiotics often are recommended to prevent sinus infection. Amoxicillin and trimethoprim-sulfamethoxazole (Bactrim) are reasonable choices.

### **Lacerations with Bone Involvement**

Uncomplicated lacerations of the skin over nondisplaced nasal fractures can be closed using previously described techniques. Complex lacerations with fracture displacement, mucosal injury from bone fragmentation, or extensive cartilage involvement are best managed by a consultant.

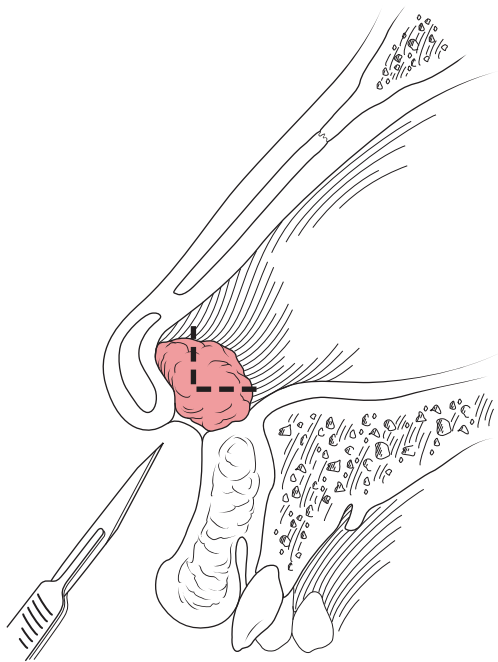
### **Aftercare**

Dressings are optional for nasal lacerations. Often a simple Band-Aid suffices. Percutaneous sutures are removed in 3 to 5 days in children and adults. The value of antibiotics for nasal lacerations is unclear. The natural vascularity of the face is protective against infection. Any decision to use antibiotics is based on the circumstances of individual cases.

---

## **EAR**

The ear consists of a cartilaginous skeleton covered by tightly adherent skin with little intervening superficial fascia (subcutaneous tissue). A direct blow to the ear can cause a



**Figure 12-10** Technique to drain a septal hematoma. A no. 11 blade is used to create a hockey-stick incision. After drainage, the nose is packed with petroleum jelly (Vaseline)-impregnated gauze. (Adapted from Zukin D, Simon R: *Emergency wound care: principles and practice*, Rockville, Md, 1987, Aspen Publishers.)

hematoma to form, usually in the area of the antihelix, with a resultant breakdown of the cartilage caused by pressure between the skin and cartilage (Fig. 12-11). The eventual result is the well-known “cauliflower” ear. The most important objective for repair of open wounds is coverage of any exposed cartilage. Failure to do so leads to chondritis and breakdown.

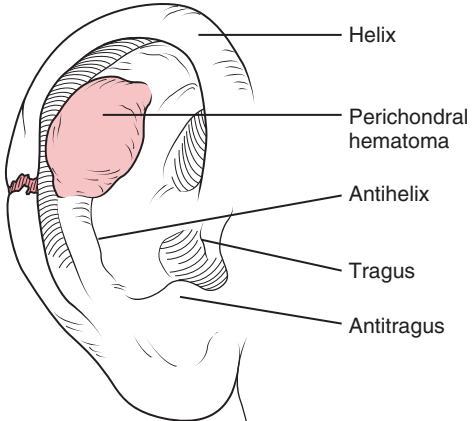
### Preparation for Repair

In addition to inspecting the external ear for hematoma formation and cartilage injury, the internal canal and tympanic membrane are visualized to complete the examination. Blunt injuries to the ear can cause perforations of the tympanic membrane. The most significant injury that can accompany lacerations to the ear is a basilar skull fracture, which can be recognized by hemotympanum or Battle’s sign (ecchymosis of the mastoid area).

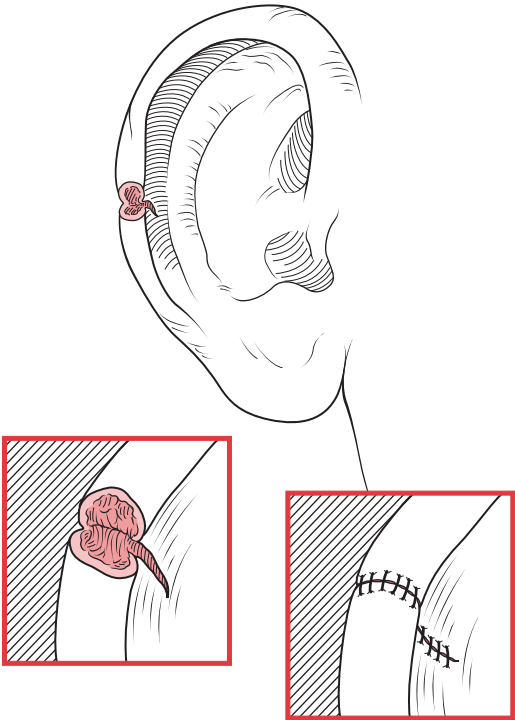
Small, uncomplicated lacerations to the ear can be anesthetized by direct infiltration with a 27G or 30G needle using an anesthetic solution without epinephrine. The needle is introduced carefully between the skin and the cartilage, and only a small amount of anesthetic is deposited to minimize distortion of the wound edges. For large, complex lacerations and wounds, the ear block described in Chapter 6 can be used. Cleansing is done with povidone-iodine solution and irrigation. Because of the complicated topography of the ear, cotton-swab applicators can be particularly useful for cleansing and removing dried blood in crevices.

### Uncomplicated Lacerations

Simple lacerations of the helix and lobule that do not involve cartilage can be closed with interrupted 6-0 nonabsorbable monofilament sutures (Fig. 12-12). To prevent wound edge inversion, small 1- to 2-mm bites are taken. If débridement is necessary, it should be kept to a minimum to prevent exposure of the cartilage. Sutures are removed 4 to 5 days after repair.



**Figure 12-11** Anatomy of the external ear. Note the presence of perichondral hematoma; hematoma formation can occur after blunt trauma to the ear and can accompany lacerations.



**Figure 12-12** Simple noncartilaginous lacerations of the ear are closed with either interrupted or running percutaneous skin sutures.

### Lacerations Involving Cartilage

Sharp, shearing lacerations that penetrate cartilage can be managed by carefully apposing the skin overlying the cartilaginous interruption. The skin is sufficiently adherent and supporting so that sutures do not have to be placed through the cartilage itself to bring together the lacerated cartilage edges. In addition, cartilage tears easily and does not hold sutures well. Sharp, through-and-through lacerations can be managed by suturing the anterior and posterior portions of the laceration. The cartilage comes together without sutures. Care is taken to ensure that the skin over the helix rim is everted so that scar contraction does not cause notching.

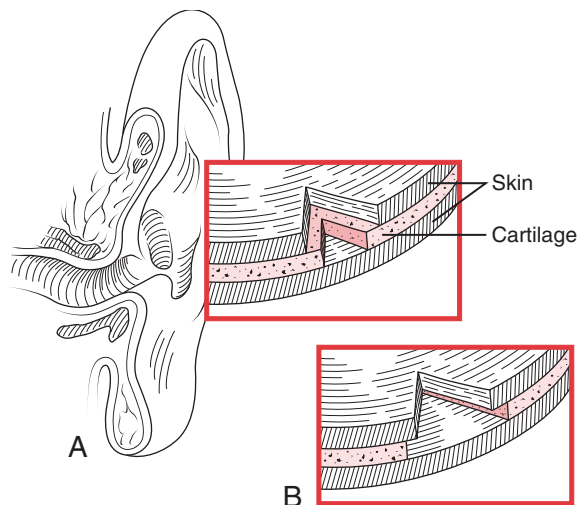
Irregular wounds that involve cartilage have to be managed with two principles in mind: (1) Débridement must be kept to a minimum, and (2) no cartilage must be left exposed. If cartilage is exposed and the skin cannot be brought together over it without undue tension, it can be débrided conservatively to match the skin and cartilage edges. A total of 5 mm of cartilage can be sacrificed without deforming the cartilaginous skeleton. No sutures are placed in the cartilage (Fig. 12-13). Complex cartilage injuries require consultation.

### Perichondral Hematoma

When a perichondral hematoma is present, it has to be drained adequately. There is a 72-hour window for hematoma drainage beyond which the risk of cauliflower ear increases.<sup>16</sup> A small incision is made over the hematoma, and the hematoma is evacuated from the space between the perichondrium and the cartilage. Placement of a small rubber drain is optional. After drainage, a mastoid dressing is placed (see Chapter 20). The dressing is removed in 24 hours and the site is inspected for reaccumulation. More often than not, complex lacerations and hematomas of the ear are best cared for by or under the guidance of a consultant.

### Aftercare

Because the ear is difficult to dress, it is often left open. Daily gentle cleansing, followed by application of an antibacterial ointment, is recommended. If there is any question of possible perichondral blood accumulation after the patient is discharged, a mastoid dressing is recommended (see Chapter 20). Sutures are removed after 4 to 5 days for adults and 3 to 5 days



**Figure 12-13** **A**, Cartilage that extends beyond the margins of the skin injury can be trimmed back, by using tissue scissors, to ensure complete coverage anteriorly and posteriorly by skin. **B**, Skin is closed with simple percutaneous sutures. No sutures are necessary for the cartilage. (Adapted from Zukin D, Simon R: Emergency wound care: principles and practice, Rockville, Md, 1987, Aspen Publishers.)

for children. When cartilage is involved or a septal hematoma has been drained, antibiotic prophylaxis is recommended. Choices include dicloxacillin, a first-generation cephalosporin, or amoxicillin with clavulanate. Erythromycin or clindamycin can be used in a penicillin-allergic patient. Uncomplicated, noncartilaginous injuries do not require antibiotics.

## LIPS

Lacerations of the lip can cause devastating cosmetic defects if not properly and meticulously repaired. A misalignment by 1 mm of the vermilion border, or “white line,” can be noticed by a casual observer. It is a defect that cannot be revised easily after primary healing has taken place. Other important anatomic structures include the mucosal border (the portion of the lip that divides the intraoral and extraoral portion of the lip) and the underlying orbicularis oris muscle. Each of these structures requires careful and exact apposition to achieve the best structural and cosmetic result. Vertical through-and-through lacerations often violate all three of these structures.

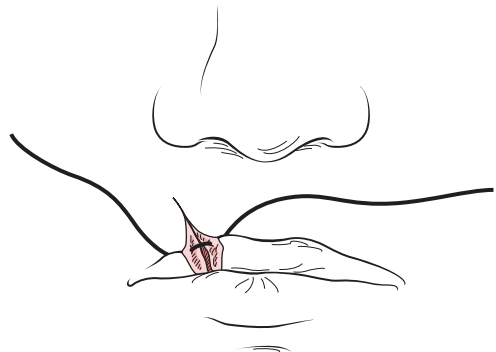
### Preparation for Closure

Although the mouth is replete with bacteria, and a lip laceration would not remain clean during the repair procedure, cleansing is carried out only to remove gross debris and dirt. If any teeth are broken, a careful search is done in the wound for teeth fragments. Retained tooth particles can cause marked inflammation and infection leading to a complete breakdown of any attempted repair. Whenever a portion of a tooth cannot be accounted for, a lateral radiograph of the face using soft tissue technique can reveal the missing fragment.

Anesthesia for lip repairs is best accomplished by either an infraorbital nerve block for the upper lip or a mental nerve block for the lower lip (see Chapter 6). Direct infiltration of the laceration can cause excessive distortion of the lip and create difficulties when an attempt to align wound edges properly is made.

### Uncomplicated Lacerations

Most lip lacerations do not require extensive revision or débridement. The key to closure is proper alignment of the anatomic structures listed previously. If the vermilion border is violated and the laceration is superficial, the repair begins with placement of the first suture, with careful precision, through that border on each side of the wound (Fig. 12-14). When alignment is judged to be appropriate, the remainder of the wound is closed with 6-0 nonabsorbable monofilament sutures. If the mucosal border is violated, it also is aligned meticulously. As a general



**Figure 12-14** The major goal when closing any lip laceration is to align the appropriate borders. Initial suture placement and alignment of the vermilion border are shown. When the vermilion border or white line is aligned, the remainder of the laceration is closed.



rule, if the laceration extends beyond the mucosal border into the oral cavity, 5-0 absorbable suture, such as chromic gut, is used to close that portion. Irradiated polyglactin 910 (Vicryl) is also recommended because it does not “stiffen” as much as gut, and it is absorbed rapidly.

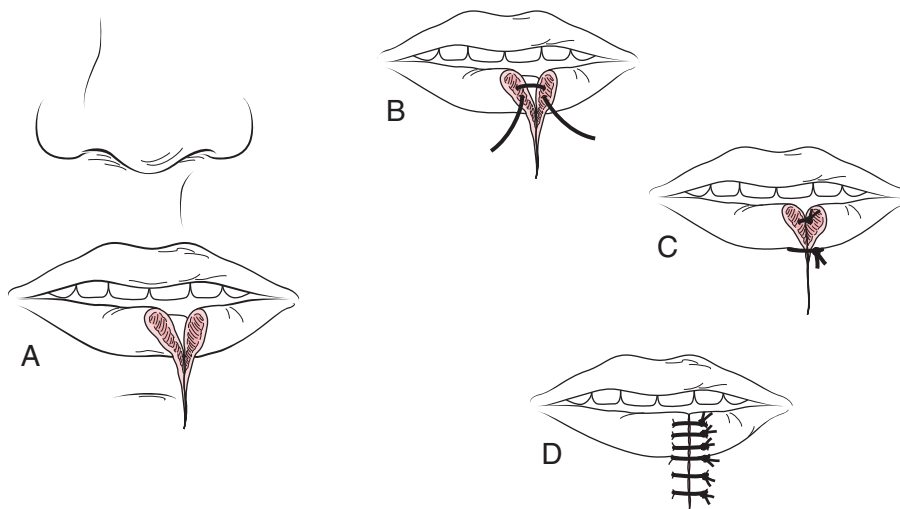
### Complicated and Through-and-Through Lacerations

In contrast to many other structures of the face, the lip can be revised, and significant portions of devitalized tissue (25% of the upper or lower lip) can be excised without causing significant deformity except for the area of the upper lip just below the nose, the philtrum, and the oral commissures. Considerable judgment is required to deal with these cosmetic problems in image-conscious patients who have high expectations for excellent results. Consultation is advised for lacerations and injuries that would affect the patient’s appearance.

Repair of a vertical through-and-through laceration is illustrated in Figure 12-15. The repair begins with closure of the vermilion border. Next, the orbicularis oris muscle is reapproximated carefully with deep 5-0 absorbable suture material, such as polyglycolic acid. The deep sutures should include the fibrous covering of the muscle to ensure anchoring. The remainder of the repair proceeds with 6-0 nonabsorbable sutures for the skin and exposed lip. For the oral cavity portion inside the mucosal border, 5-0 absorbable sutures are used.

### Aftercare

No dressing is placed on the lips. The patient is reminded not to bring excessive pressure to bear on the suture line while the sutures are in place. Rinsing the mouth after eating is recommended to prevent small particulate matter from penetrating the suture line. Extraoral sutures are removed after 4 to 5 days in adults and 3 to 5 days in children to prevent the formation of suture marks. A controlled study of intraoral lacerations suggests that there is some



**Figure 12-15** A, Demonstration of a through-and-through laceration of the lip involving the orbicularis oris muscle. B, Closure of the orbicularis oris muscle is carried out by using absorbable deep sutures, such as polyglycolic acid. C, When the orbicularis oris muscle is approximated, the vermilion border or white line is approximated. D, The remainder of the laceration is closed with simple percutaneous monofilament nylon sutures.

benefit to administering oral penicillin V potassium (Penicillin VK) four times daily for 5 days as prophylaxis against infection.<sup>17</sup> Erythromycin or clindamycin may be considered as alternatives for a penicillin-allergic patient.

## ORAL CAVITY

The oral cavity consists of several structures, each of which requires separate considerations during management and repair. These are the buccal mucosa, gingiva, teeth, salivary glands and ducts, tongue, mandible, and alveolar ridge of the maxillary bone. Injuries to the oral cavity can be a potential threat to airway patency.

### Preparation for Repair

Other than airway considerations, the most important part of the evaluation of the oral cavity is the determination of the integrity of salivary structures, bone, and teeth. Visual inspection and palpation are necessary to complete the examination. Particularly troublesome are teeth, fragments of which must be accounted for if possible. They can lodge easily in the mucosa and the deep tissue of the lip, where they can cause severe inflammation and infection if not removed before closure. If there is any question about the location of a tooth or fragment, radiographs of the soft tissues should be obtained.

### Buccal Mucosal and Gingival Lacerations

As a general rule, lacerations of either the buccal mucosa or the gingiva heal without repair if the wound edges are not widely separated or if flaps are not present. Wounds that gape open (usually  $\geq 2$  to 3 cm) need only one to three sutures for closure. Flaps that interpose between teeth can be excised or closed; 5-0 chromic gut or another absorbable material can be used. The oral cavity tissues heal remarkably fast, and most lacerations, even large ones, close without sutures. After repair, the patient is instructed to eat soft food and to rinse the mouth gently after each meal.

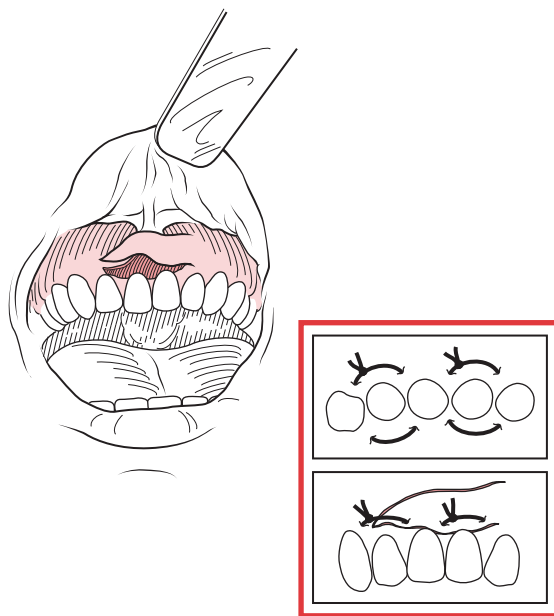
Occasionally a flap of tissue is created during injury to the gingiva overlying the mandibular or maxillary ridge. Because of the lack of support by thin supporting tissues, the gingival flap cannot be sutured easily. A technique illustrated in Figure 12-16 shows how sutures are brought circumferentially around teeth to provide the necessary anchor for the repair; 4-0 or 5-0 chromic gut or other absorbable material is used.

### Tongue Lacerations

Repairing a lacerated tongue can be challenging. Small lacerations that do not gape widely when the tongue is extended heal without intervention. Lacerations that gape widely, actively bleed, are flap shaped, or involve muscle probably need closure. The key to the repair of these lacerations is to gain the confidence of the patient. With frightened children, gaining confidence is often difficult, and the patient might be best served in a surgical setting where sedation and anesthesia can be delivered. An assistant is required to control the tongue with dry gauze sponges, or a towel clip is placed in the previously anesthetized tip. A bite-block can be fashioned to prevent injury to the assistant or the operator. The wound area is anesthetized by direct infiltration without epinephrine. The tongue heals rapidly and can be closed with an absorbable suture (e.g., 4-0 chromic, polyglycolic acid, or Vicryl). The sutures are placed in large bites to include the mucosa and muscle.

### Aftercare

For the first 2 or 3 days after repair of an intraoral laceration, soft foods and liquids are recommended. Rinsing the oral cavity after eating also is helpful.



**Figure 12-16** Avulsion of gingival/mucosal tissue. The technique to close this injury is shown. The sutures are brought around the teeth and through the avulsed tissue flap. (Adapted from Zukin D, Simon R: Emergency wound care: principles and practice, Rockville, Md, 1987, Aspen Publishers.)

### Dental Trauma

Teeth often are loosened by trauma to the oral cavity. Minimal loosening (<2 mm), as determined by gentle “rocking” of the tooth between the examining fingers, usually reverses without intervention. Marked loosening or subluxation with an accompanying fracture of the alveolar ridge needs to be repaired with dental stabilization.

Intact teeth also can become avulsed. These teeth can be replaced in an anatomically intact socket, but the prognosis for salvage decreases with each minute that passes. On arrival in the emergency department, an attempt should be made to insert the avulsed tooth in the socket if possible.<sup>18</sup> If the socket contains debris, gentle removal is tried. Vigorous intervention should be avoided. The tooth can be handled by the crown but not by the root. To avoid damage to the periodontal ligament, cleaning of the tooth is not recommended. Even saline may be harmful to ligament cells.

If the tooth cannot be reinserted easily, it can be “stored” in one of three ways until a dentist or oral surgeon can be consulted. The three storage methods are (1) between the buccal mucosa and gum of the patient’s mouth, (2) in Hank’s solution, or (3) in milk.<sup>19</sup> Saline is avoided. After 30 minutes outside of the socket, the prognosis for salvage worsens rapidly. Even if the periodontal ligament survives and the tooth reattaches, later root canal intervention is necessary to deal with the sequelae of the loss of neurovascular supply.

### PERINEUM

Injuries to the perineum (i.e., penis, scrotum, and female introitus) can involve important structures that need special attention. During the examination of wounds of the perineum, the urethra, corpora, testicles, and rectum must be assessed. Blood coming from the urethral meatus or difficulty urinating suggests urethral injury. The shaft of the penis is covered by thin skin; violation of the corpora cavernosa or spongiosum often accompanies lacerations of the penis. The testicle is covered with a capsule-like fibrous covering called the *tunica albuginea*.

Interruption of the corpora or tunica requires repair by a specialist. Most labial lacerations are uncomplicated, but occasionally the female urethra or rectum is involved.

### Preparation for Closure

Wounds to the perineum are prepared with a cleansing agent and are irrigated with saline as previously described. Uncomplicated lacerations can be anesthetized directly with lidocaine or bupivacaine. Care is taken not to use epinephrine-containing solutions for anesthetizing the penis because of potential ischemia and constriction of end arteries.

### Lacerations of the Penis and Scrotum

Because the skin of the penis is so thin, lacerations are closed with a single layer of nonabsorbable suture (e.g., 5-0 nylon). Closure of the scrotal skin is carried out with chromic gut sutures that fall out within 10 days. If chromic material is unavailable, another absorbable suture material can be substituted, but it may not fall out as soon. Healing occurs rapidly, and removal of sutures from the rugated skin, which can be difficult, is unnecessary.

### Lacerations of the Introitus

Lacerations of the labia can involve the deeper supporting muscles. If that is the case, closure has to occur in two layers to ensure reapproximation of the muscles. The skin over the labia majora can be closed with a nonabsorbable material, such as nylon or polypropylene. The labia minora is covered with mucosa and can be closed with absorbable material. Uncomplicated lacerations of the vagina, unless they are extensive, heal without sutures. Extensive or complex wounds are best referred to consultants.

### Aftercare

Dressings for the genital area are hard to fashion. Gauze sponges supported by an athletic supporter are an option for men. Perineal pads are suggested for women. Hygiene of the genital area is important; daily gentle cleansing with soap and water is acceptable. Topical antibiotic ointment (Neosporin) applied after bathing and before dressing application is recommended. Sutures of the penis are removed in 7 to 10 days for adults and 6 to 8 days for children.

---

## KNEE

Careful examination of knee lacerations is important because of the structures that can be damaged. The peroneal nerve, patellar tendon, medial and lateral collateral ligaments, and patella all have to be tested for function and integrity before repair. Of particular importance is the joint space itself. If penetration is suspected, 50 mL of normal saline with a few drops of methylene blue is injected into the joint, in a sterile fashion, at a site distant from the laceration. Arthrocentesis technique is used. If the capsule is violated, the dye leaks out of the laceration. For more subtle injuries, fluorescein dye can be used with an ultraviolet light detection lamp.

Knee lacerations can be contaminated with grit and ground-in dirt. Although time-consuming, meticulous cleansing, irrigation, and débridement are often necessary to render the wound ready to close. Uncomplicated, nonpenetrating lacerations are closed with monofilament nylon after local anesthetic infiltration. Occasionally, deep (dermal) sutures using an absorbable material are required.

### Aftercare

The key to good healing of knee lacerations is proper immobilization and elevation for several days. Crutches can be used for at least 48 to 72 hours if the extensor surface of the knee

is involved or the wound is extensive. Knee flexion can be reduced by the application of a bulky dressing. Sutures are removed in 10 to 14 days for adults and 8 to 10 days for children.

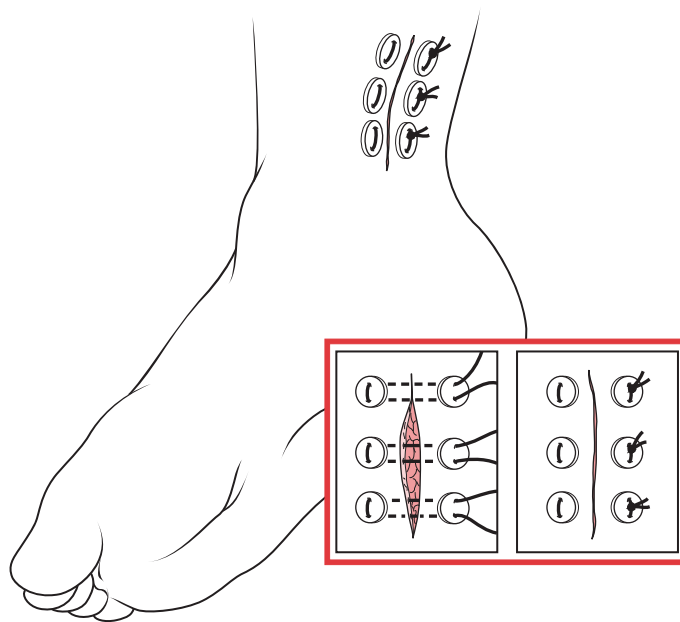
## LOWER LEG

The most vexing consideration with lower leg (shin) lacerations is the significant tension that occurs at the wound edge. Skin overlying the tibia is under higher natural tension than most other regions of the body. Figure 12-17 illustrates a technique for approximating the wound edges with as little tension as possible; 4-0 monofilament nylon is passed through sterile cotton-retaining pledgets obtained from the operating room. This technique allows for even distribution of tension along the wound edge without tearing. This pledget technique is particularly useful for older and thinner skin. Undermining and deep suture placement can assist in reducing tension.

Another technique for the closure of avulsion/flap wounds of the shin in older patients is the use of wound tapes.<sup>20</sup> Tapes avoid the problem of skin tearing with sutures and staples. Tapes can be left on until they naturally fall off. This technique allows for minimal potential disruption of the healing wound.

## Aftercare

Elevation is an important element for lacerations and wounds of the lower leg. Dependent edema should not be allowed to develop. Sutures are removed after 8 to 12 days for adults and 6 to 10 days for children.



**Figure 12-17** Because of the high tension usually associated with lacerations in the lower leg (shin area), sterile cotton pledgets can be used as support for 3-0 or 4-0 monofilament nylon sutures. (Adapted from Zukin D, Simon R: Emergency wound care: principles and practice, Rockville, Md, 1987, Aspen Publishers.)

## FOOT

The foot is anatomically complex and has similarities to the hand. Complete lacerations to the flexor tendons need to be repaired as they are in hands (see Chapter 13). Extensor tendons can be treated with primary skin closure and splinting. Consultation is recommended under these circumstances. Anesthesia for the plantar surface of the foot is carried out best by a posterior tibial nerve or sural nerve block (see Chapter 6). Occasionally, this method of administering anesthesia needs to be supplemented by local infiltration. Superficial dorsal lacerations are closed with 4-0 or 5-0 monofilament nylon. Lacerations of the plantar surface, or sole, can be closed with 3-0 monofilament. Lacerations of the web spaces between the toes have the same significance as lacerations of web spaces of the hand. There are no crucial structures passing through these areas, and repair of the skin alone should suffice.

## Aftercare

Similar to any lower extremity injury, elevation is an important adjunct to care. Crutches are useful, particularly for wounds on the plantar surface. Sutures are removed in 10 to 12 days for adults and 8 to 10 days for children.

## REFERENCES

1. Fullarton GM, MacEwen CJ, MacMillan R, et al: An evaluation of open scalp wounds, *Arch Emerg Med* 4:11-16, 1987.
2. Pecora D, Landis R, Martin E: Location of cutaneous microorganisms, *Surgery* 64:1114-1117, 1968.
3. Howell JM, Morgan JA: Scalp laceration repair without prior hair removal, *Am J Emerg Med* 6:7-10, 1988.
4. Edlich R: Special considerations in wound management, *Am J Emerg Med* 19:1089, 1990.
5. Cruse P, Foord R: A five year prospective of 23,649 surgical wounds, *Arch Surg* 107:206-209, 1973.
6. Seropian R, Reynolds B: Wound infections after preoperative depilatory versus razor preparation, *Am J Surg* 121:251-254, 1971.
7. Tandon SC, Kelly J, Turtle M: Irradiated polyglactin-910: a new synthetic absorbable suture, *J R Coll Surg Edinb* 40:185-187, 1995.
8. Aderiotis D, Sandor GK: Outcomes of irradiated polyglactin 910, *J Can Dent Assoc* 65:345-347, 1999.
9. George TK, Simpson DC: Skin wound closure with staples in the accident and emergency department, *J R Coll Surg Edinb* 30:54-56, 1985.
10. Roth JH, Windle BH: Staple versus suture closure of skin incisions in a pig model, *Can J Surg* 31:19, 1988.
11. Abu NGA, Dayan PS, Miller S, et al: Cosmetic outcome of scalp wound closure with staples in the pediatric emergency department: a prospective, randomized trial, *Pediatr Emerg Care* 18:171-173, 2002.
12. Aoki N, Oikawa A, Sakai T: Hair-braiding closure for superficial wounds, *Surg Neurol* 46:150-151, 1996.
13. Duschoff IM: About face, *Emerg Med* Nov:25-77, 1974.
14. Edlich RF, Rodeheaver CJ, Morgan RF, et al: Principles of wound management, *Ann Emerg Med* 17:1284-1302, 1988.
15. Talbot AW, Meadows AE, Tyers AG, et al: Use of 7/0 Vicryl (coated polyglactin 910) and 7/0 Vicryl-Rapide (irradiated polyglactin 910) in skin closure in ophthalmic plastic surgery, *Orbit* 21:1-8, 2002.
16. Burr WE: Auricular hematoma: treatment options, *Aust NZ J Surg* 57:391-392, 1987.
17. Steele MT, Sainsbury CR, Robinson WA, et al: Prophylactic penicillin for intraoral wounds, *Ann Emerg Med* 18:847-852, 1989.
18. Bringhurst L, Herr RD, Aldous JA: Oral trauma in the emergency department, *Am J Emerg Med* 11:486-490, 1993.
19. Trope M: Clinical management of the avulsed tooth, *Dent Clin North Am* 39:92-112, 1995.
20. King MT: Flap wounds of the skin, *Injury* 12:354-359, 1981.

# CHAPTER 13

## The Hand

### INITIAL TREATMENT

#### TERMINOLOGY

#### PATIENT HISTORY

#### EXAMINATION OF THE HAND

Nerve Testing  
Tendon Function

#### CIRCULATION

#### RADIOGRAPHY

#### WOUND EXPLORATION

### SELECTED HAND INJURIES AND PROBLEMS

Uncomplicated Lacerations  
Fingertip Injuries  
Tendon Lacerations  
Nerve Injuries  
Amputated Parts  
Paronychia  
Felon  
Pressure Injection Injuries

### ANTIBIOTICS FOR HAND WOUNDS

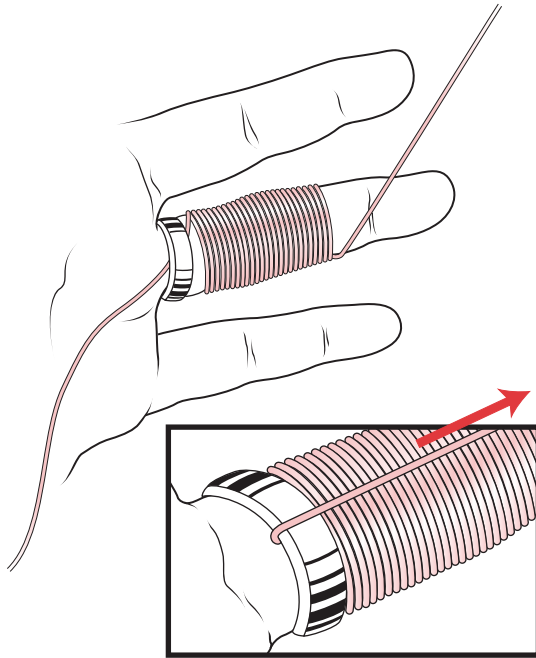
### DRESSINGS AND AFTERCARE

A thorough understanding of the structure and function of the hand is essential to its care, even for seemingly minor injuries and problems. The complexity and relative density of important structures make the hand particularly vulnerable to injury with the added risk of serious, permanent impairment. With the use of conventional terminology, information concerning the examination can be recorded properly in the medical record and communicated to others. This chapter discusses problems that are appropriately managed by emergency wound care personnel. When there is any doubt concerning the proper course of management, every attempt is made to initiate an appropriate consultation.

### INITIAL TREATMENT

Before a thorough and careful examination of a patient with an injured hand can take place, certain preparatory steps must be taken. Except for the most trivial injuries, the patient is best managed by placement on a stretcher on arrival at the medical care facility. Hand injuries often are painful and provoke anxiety. Placing the patient in a supine position prevents unexpected vasovagal syncope. The recumbent position allows for easy placement of the hand in an elevated position to decrease the swelling that occurs after injury.

Any rings or constricting jewelry are removed to prevent ischemia of a digit. Most rings can be removed by using a lubricant and applying gentle, persistent traction. Ring removal from swollen fingers can be accomplished by using a specially designed ring cutter and spreading the ring open with two Kelly clamps applied to the edges of the cut portion (see Fig. 2-2). Patients who are concerned about damaged rings can be reassured that jewelers can restore rings to their original condition. Another method for the removal of rings is shown in Figure 13-1. Umbilical tape or O-silk suture can be wrapped firmly around the finger and passed under the ring with a small forceps. The ring is extracted as the tape or suture is unwound proximally to the ring.



**Figure 13-1** The technique to remove a ring by finger wrapping with large silk suture or umbilical tape. The suture is begun distally over the distal interphalangeal joint and brought back to the ring. The tail end portion of the wrap is brought under the ring, usually with a small hemostat. The removal of the ring is begun by unraveling the wrap and tugging on the string that is proximal to the ring portion. As it unravels, the ring gently travels forward distally over the finger.

Most patients attempt to bandage the injured hand before proceeding to a medical care facility. These hastily fashioned, unsterile dressings should be removed carefully. Until treatment can be administered, sterile sponges moistened with normal saline should be applied, followed by a 2- or 3-inch gauze wrap. Any active bleeding requires manual pressure with gauze sponges. An extremity tourniquet rarely is needed to stop excessive hemorrhage.

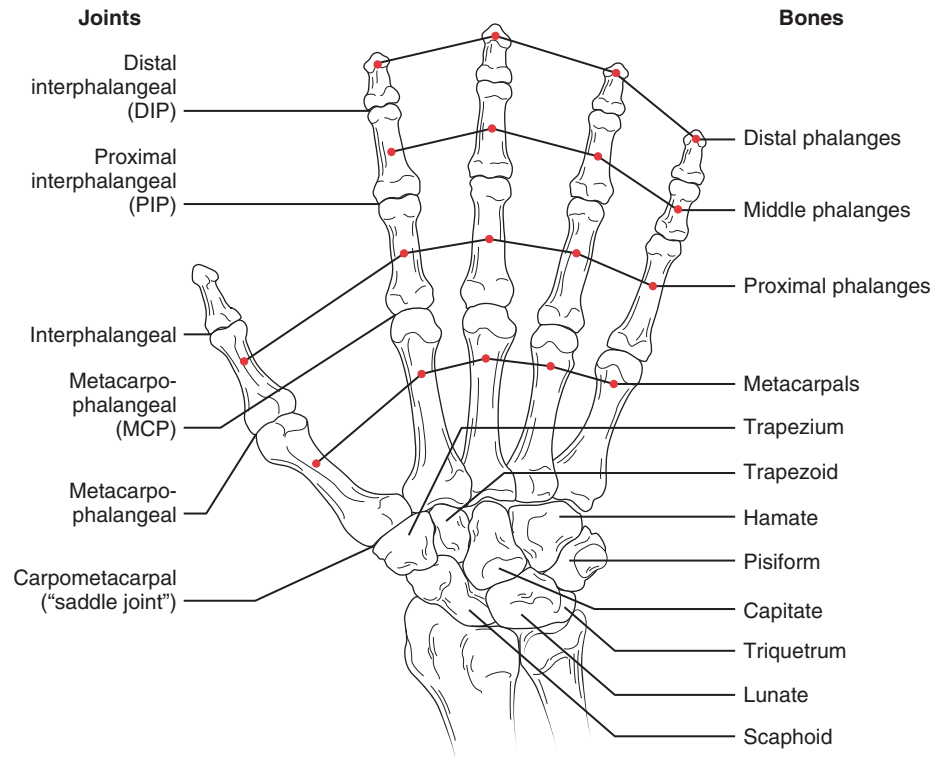
If the wound is grossly contaminated with soil or other debris and if there will be a delay before treatment is administered, the hand is cleaned gently with a wound-cleansing agent followed by irrigation with normal saline.<sup>1</sup> The chance of infection increases with each passing hour from the time of injury to repair. Early cleansing and irrigation can extend this safe period.

It is a common but unsupported practice to soak hand injuries in a wound-cleansing solution before repair. Soaking is believed to loosen debris and help kill contaminating bacteria, but there is no scientific evidence to support these beliefs.<sup>2,3</sup> Brief extremity immersion is recommended only to help remove gross soil and debris from the area surrounding the wound before proper skin cleansing and wound irrigation.

## TERMINOLOGY

Knowledge of conventional terminology is required to properly document and communicate information about injuries of the hand and fingers. All lacerations and wounds can be located accurately by the use of appropriate terms. A ½-inch laceration on the back of the index finger at the first knuckle is described accurately as “a 1-cm superficial laceration of the index finger on the dorsal surface at the proximal interphalangeal joint.” Figures 13-2 and 13-3 illustrate the various descriptive landmarks and joints. The back of the hand is the *dorsal* surface, whereas the palm side is the *palmar* or *volar* surface. Common landmarks of the palm are the thenar and hypothenar eminences. The digits are best remembered and recorded,





**Figure 13-2** Descriptive anatomy of the joints and bones of the hand.

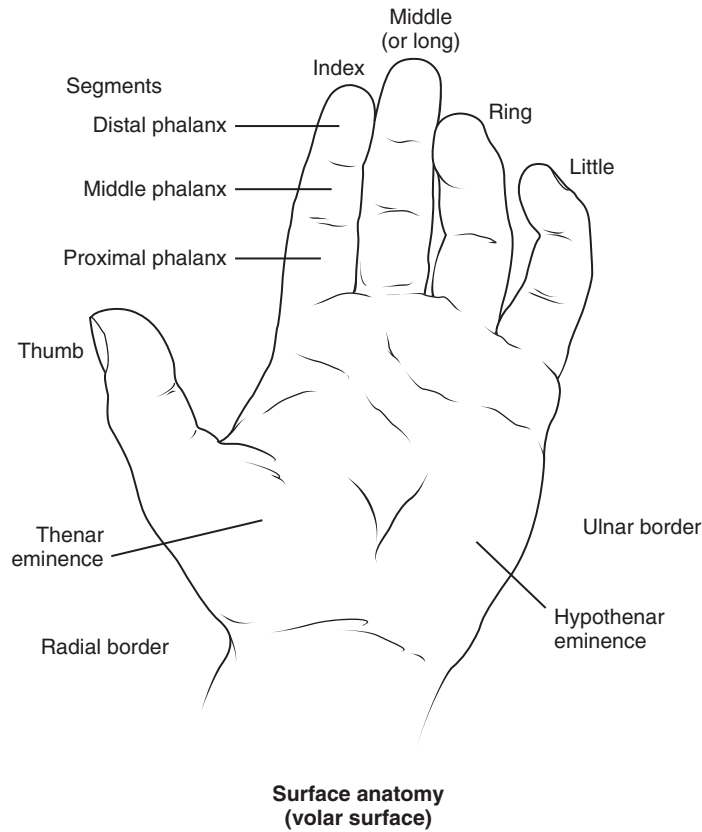
when necessary, as the thumb, index, middle, ring, and little finger. Each segment of the finger is named for the underlying bony phalanx. Although the joints are descriptive of their location, it is the convention to use the abbreviations noted in Figure 13-2.

Instead of using terms such as *inside* and *outside* or *medial* and *lateral*, the sides of the hands and fingers are referred to as *radial* and *ulnar*. This convention eliminates the confusion elicited by the other terms. Any injury to any surface on the side of the hand or finger corresponding to the radius is so described. A laceration of the side of the little finger is either radial or ulnar depending on whether it is on the side of the ulna or the radius (see Fig. 13-3).

## PATIENT HISTORY

Certain key historical facts help determine the timing and choice of repair and other supportive treatment. As previously discussed, the amount of time that has elapsed from the time the injury occurred influences the decision of when to repair the wound. Clean wounds that are caused by shearing forces probably can be safely repaired 6 to 8 hours after the injury. Wounds caused by tension and compression mechanisms are more vulnerable and should be considered for closure sooner. Severely contaminated wounds or wounds caused by mutilating forces are best left for consultation and possible delayed closure. This decision is made on a case-by-case basis.

A seemingly innocuous mechanism of injury is the puncture wound of the hand. Although the entry point is quite small and innocent appearing, special care has to be taken



**Figure 13-3** Descriptive anatomy of the surface of the hand. Note the ulnar and radial borders.

not to miss a transected nerve or tendon. In addition, the possibility of a foreign body being retained in a puncture wound has to be considered, and a radiographic examination should be carried out when the suspicion is raised.

Other historical points of importance are the patient's hand dominance, history of prior hand deformities, profession, and hobbies. Although these considerations are seemingly not very important for patients with emergency lacerations and wounds, a simple matter of a mismanaged fingertip injury can significantly affect an activity such as playing the guitar. For a guitar player, every step is taken to preserve the nail matrix. Preservation attempts might not be as crucial for an individual who does not require this anatomic part for either a job function or hobby.

Any allergies the patient may have should be verified when taking the history. Many drugs, including tetanus toxoid, local anesthetics, pain medications, and a variety of antibiotics, are given to patients with hand injuries.

## EXAMINATION OF THE HAND

The actual examination of the injured hand consists of careful inspection of the wound and thorough functional testing. Nerve function is evaluated by assessment of motor and

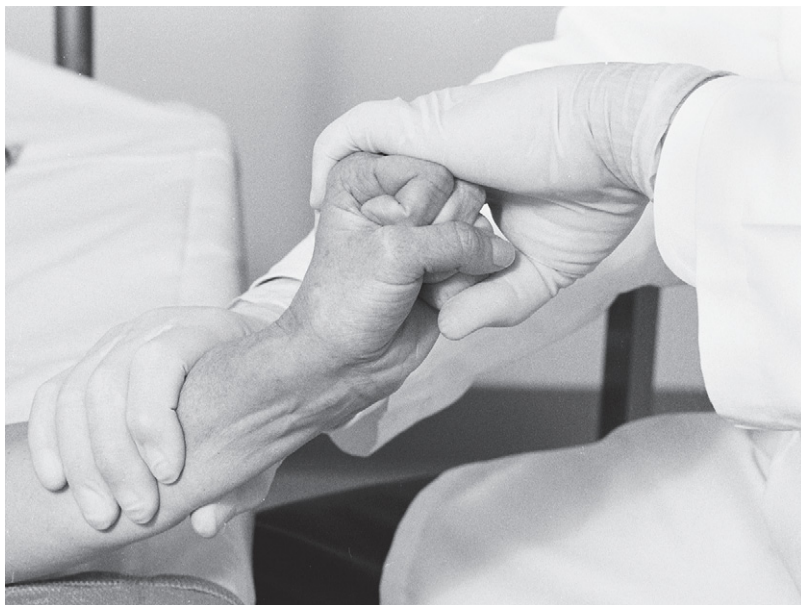sensory components. The integrity of tendons most often can be determined by specific functional maneuvers. Because tendons often are only partially severed and function is preserved, direct visualization by exploration frequently is necessary. In emergency wounds, circulation is so profuse that severed, bleeding vessels that travel in neurovascular bundles often are better indicators of nerve injury than actual threats to perfusion of the hand or finger. When necessary, radiographs are obtained to assist in the examination to rule out fractures or foreign bodies. Finally, there is no substitute for exploration and direct visualization to discover structural damage of any type.

## Nerve Testing

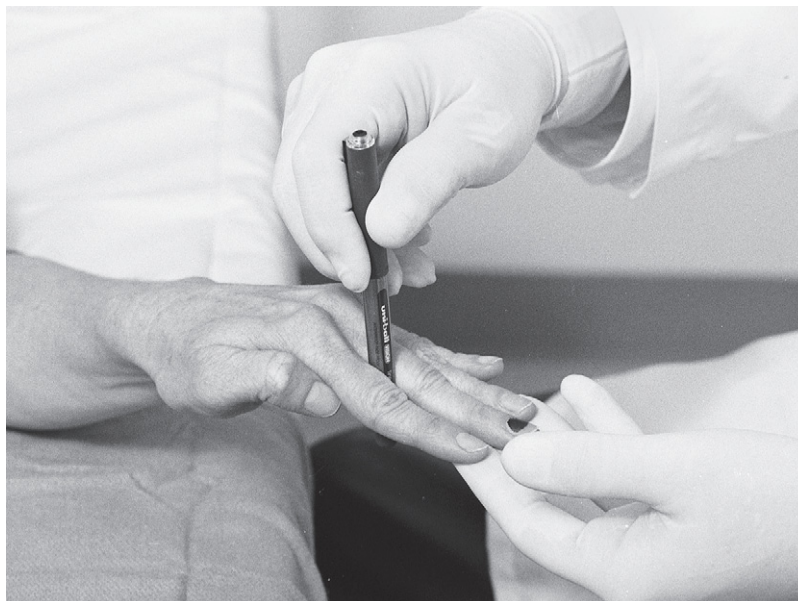### Motor Function

Three major nerves are responsible for motor and sensory function of the hand. The radial nerve innervates the extrinsic muscles of the forearm that are responsible for extension of the wrist and fingers. This nerve does not innervate any muscle within the confines of the hand itself. The motor function of this nerve is tested by having the patient dorsiflex his or her wrist and fingers against a resisting force, such as the examiner's hand (Fig. 13-4). Intact motor strength, as provided for by an intact radial nerve, should prevent the examiner from overcoming the dorsiflexed wrist when a good deal of counterforce is applied.

In addition to the flexor carpi ulnaris and part of the flexor digitorum profundus, the ulnar nerve innervates most of the intrinsic muscles of the hand itself, including all of the interossei muscles and the little and ring finger lumbricals. The motor portion of this nerve is responsible for the ability of the fingers to spread and close in a fanlike manner. A specific test for ulnar motor function is to have the patient adduct (close) the fingers against an



**Figure 13-4** Testing for radial nerve function. With the patient's fist dorsiflexed, the examiner tries to "break" the resistance created by the dorsiflexion.



**Figure 13-5** Testing for ulnar nerve function. The patient is asked to resist the examiner's attempt to pull an object, such as a pen, from between the adducted fingers.

object, such as a pen (Fig. 13-5). With an intact nerve, the examiner cannot easily remove the object. Each finger can be tested in this manner.

The median nerve provides motor innervation to wrist flexors, the flexor digitorum superficialis, part of the flexor digitorum profundus (shared with the ulnar nerve), and the remaining intrinsic muscles of the hand, most notably the muscles of the thumb that are responsible for opposition. To some degree, opposition also is mediated by the adduction component of the interossei as supplied to the ulnar nerve. The testing maneuver is completed by having the patient oppose his or her thumb with the tip of the little finger. A properly made "ring" consisting of the thumb and little finger should be hard to break by the examiner if the median nerve is intact (Fig. 13-6).

### **Sensory Function**

A variety of stimuli can be delivered to the skin of the hand to test sensory function. Gross touch with a blunt object is the easiest but least specific. It can be useful, however, for rapid screening to assess the possibility of nerve damage, especially when comparison testing of the injured and noninjured hands is done. If there is a nerve injury, the patient often is able to report a difference in feeling. Pinprick stimulus is the most commonly used modality for testing. Pinprick is useful when alternated with blunt stimulus. In a complete nerve transection, the patient cannot tell the difference between a blunt and a sharp stimulus. Pinprick testing nevertheless is difficult to assess on the fingertips, especially in a manual laborer whose finger pads are covered with thick calluses.

A more accurate method of assessing sensory function is two-point discrimination.<sup>4</sup> A paper clip can be fashioned so that two ends can be opened or closed to varying distances



**Figure 13-6** Testing for median nerve function. The thumb is apposed to the little finger to form a tight ring. This ring should not be easily broken by the examiner.

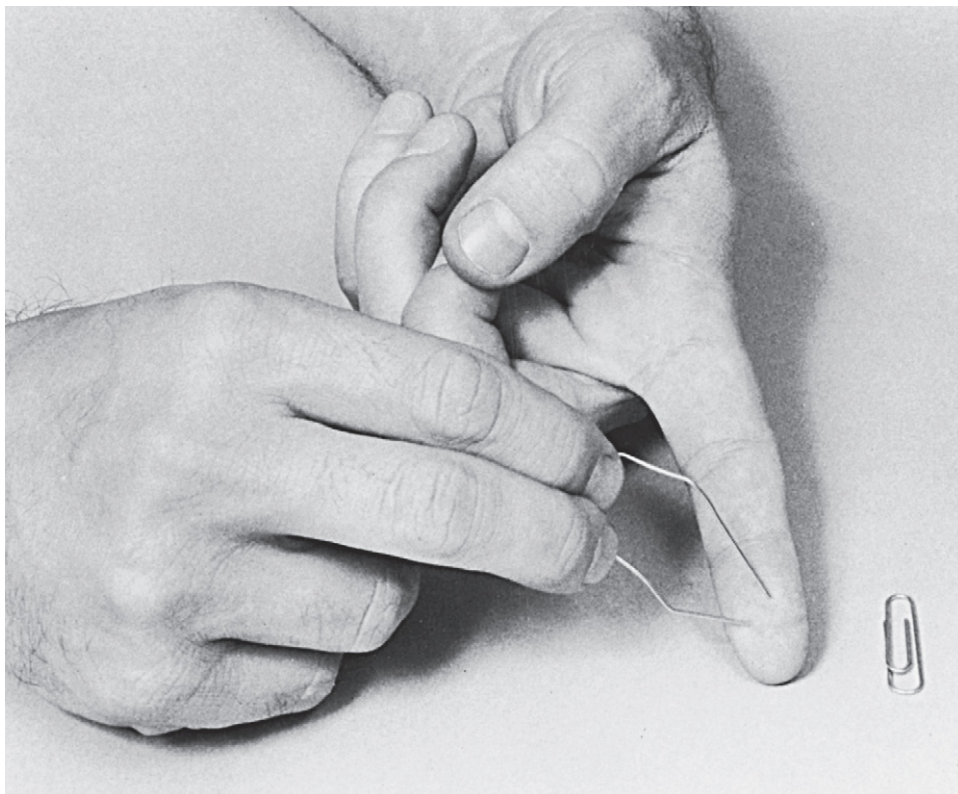
from each other (Fig. 13-7). A patient with a normally innervated fingertip should be able to distinguish two simultaneously delivered stimuli 6 mm or more apart from each other. Most patients can tell a difference down to 3 mm. When identification of separate stimuli is reported by the patient at 8 mm apart or more, the examination is clearly abnormal.

Of the major nerves, the radial nerve provides the least important sensory innervation to the hand. This nerve supplies sensation to the radial portion of the dorsum of the hand, the dorsum of the thumb, and the proximal portion of the dorsal side of the second and third digits and half of the ring finger (Fig. 13-8). To test gross radial sensory function rapidly, a stimulus is supplied to the first web space, an area of pure radial distribution.

Sensory distribution of the ulnar nerve includes the dorsal and volar surfaces of the ulnar side of the hand, the entire fifth digit, and the ulnar half of the fourth digit. To test an intact sensory component of the ulnar nerve, an appropriate stimulus is delivered to the area of purest ulnar distribution, the tip of the fifth digit.

The remainder of the hand is innervated by the median nerve. The area of sensory distribution comprises the radial side of the palm; volar surfaces of the thumb, index, and middle fingers; and the radial half of the ring finger. As depicted in Figure 13-8, median nerve innervation extends to the fingertips of the thumb, index, and middle fingers, including the dorsal portion of the distal phalanges. Pure median sensation can be found at the tip of the index finger.

More common than injuries to the major nerves are injuries and lacerations to the digital nerves that lie within the hand itself. There are four digital nerves for each digit. The two palmar nerves (Fig. 13-9) are the largest and most important. (The others are the dorsal



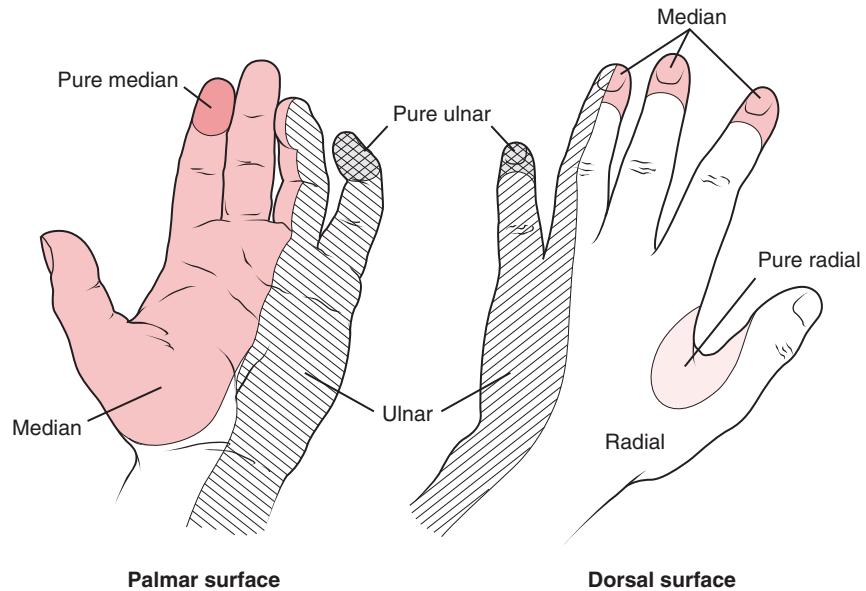
**Figure 13-7** Technique for testing sensory nerve function by two-point discrimination. A paper clip is bent in a manner to provide variable distance stimuli. See text for a complete description.

digital nerves.) Sensation is carried through these two nerves to the palmar surface and the nail bed area of the fingertip. A laceration or puncture wound to the palmar or dorsal surface of the hand or to any individual digit requires careful sensory testing of the digits distal to the injury.

As previously described, a variety of stimuli can be used for sensory testing. The most accurate method of detecting a nerve injury in this setting is the two-point discrimination test. Objective documentation of digital nerve injuries is not always possible at the time of the first examination immediately after injury. Patient pain, anxiety, and factors such as the presence of callused hands can interfere with two-point testing. Even though stimulus testing is inconsistent and does not clearly document nerve injury, any subjective “numbness” reported by the patient has to be taken seriously and consultation with a hand specialist should be considered. Under these circumstances, it is common to close the skin and refer the patient for evaluation within a few days after the initial care.

### **Tendon Function**

Tendon function can be difficult because of the number and complexity of the tendons to be tested. General principles behind tendon function and testing are discussed in this section.

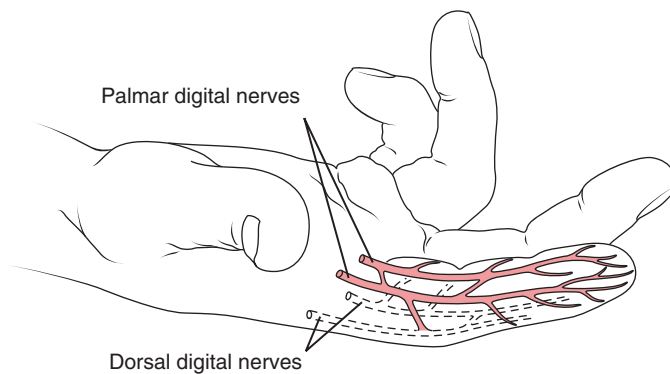


**Figure 13-8** The distribution of the three major nerves providing sensory innervation of the hand. Note the areas of pure median, ulnar, and radial sensation.

Table 13-1 lists each of the musculotendinous units in the hand and its related nerve control.

### *Extensor Function*

Extensor tendon function can be tested simply by having the patient extend his or her fingers against the force of the examiner (Fig. 13-10). Although this maneuver appears to be easy enough, there are complexities of the tendon anatomy that can cause confusion when

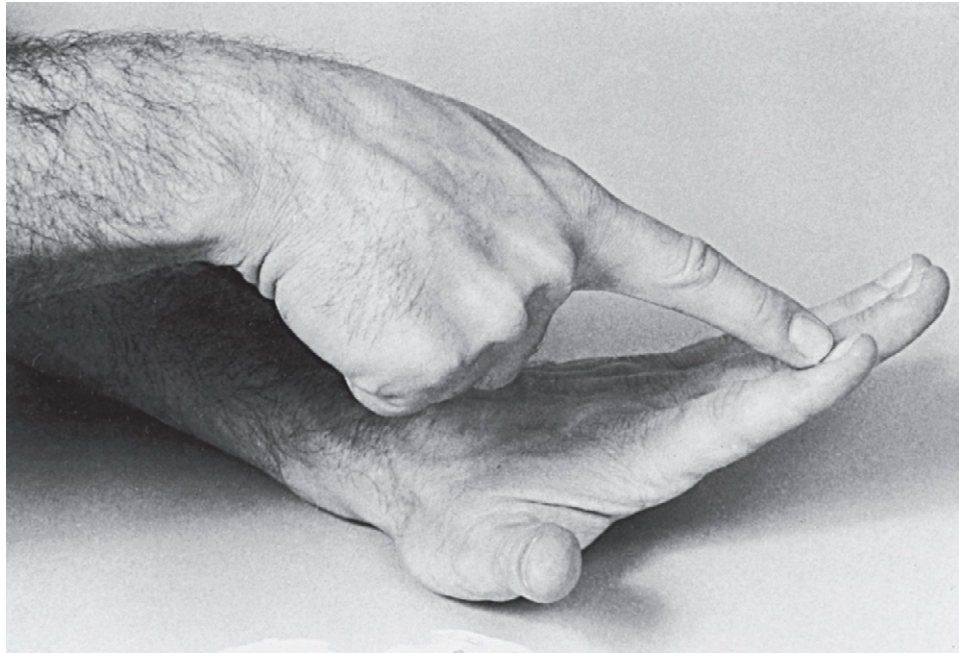

**Figure 13-9** Each digit is supplied by four digital nerves. The palmar digital nerves predominate and provide most of the sensation to the volar aspect of the finger and fingertip proximal to the distal interphalangeal joint. The nail bed often is included in the palmar digital nerve distribution.

TABLE 13-1 *Components of Hand Function*

Joint/Action	Musculotendinous Unit	Nerve Control
<b>Wrist</b>		
Flexion	Flexor carpi radialis Palmaris longus Flexor carpi ulnaris	Median Median Ulnar
Extension	Extensor carpi radialis Extensor carpi ulnaris	Radial Radial
Radial deviation	Extensor carpi radialis Flexor carpi radialis	Radial Median
Ulnar deviation	Extensor carpi ulnaris Flexor carpi ulnaris	Radial Ulnar
<b>Metacarpophalangeal</b>		
Flexion	Interosseous Lumbrical	Ulnar Median/ulnar
Extension	Extensor digitorum communis Extensor indicis proprius Extensor digiti minimi	Radial Radial Radial
Adduction	Dorsal interossei	Ulnar
Abduction	Volar interossei	Ulnar
<b>Proximal Interphalangeal</b>		
Flexion	Flexor digitorum sublimis	Median
Extension	Interosseous Lumbricals Extensor digitorum communis Extensor indicis proprius Extensor digiti minimi	Ulnar Ulnar/median Radial Radial Radial
<b>Distal Interphalangeal</b>		
Flexion	Flexor digitorum profundus	Median/ulnar
Extension	Same for proximal interphalangeal joint	
<b>Thumb-Carpometacarpal</b>		
Flexion/adduction	Adductor pollicis Flexor pollicis brevis Dorsal interosseous Flexor pollicis longus	Ulnar Ulnar Ulnar Median
Extension/abduction	Extensor pollicis longus Extensor pollicis brevis Abductor pollicis longus Abductor pollicis brevis	Radial Radial Radial Median
Opposition	Abductor pollicis brevis Flexor pollicis brevis Opponens pollicis	Median Median Median
<b>Thumb-Metacarpophalangeal</b>		
Flexion	Flexor pollicis longus Thenar intrinsic	Median Median/ulnar
Extension	Extensor pollicis brevis	Radial
<b>Thumb-Interphalangeal</b>		
Flexion	Flexor pollicis longus	Median
Extension	Extensor pollicis longus	Radial



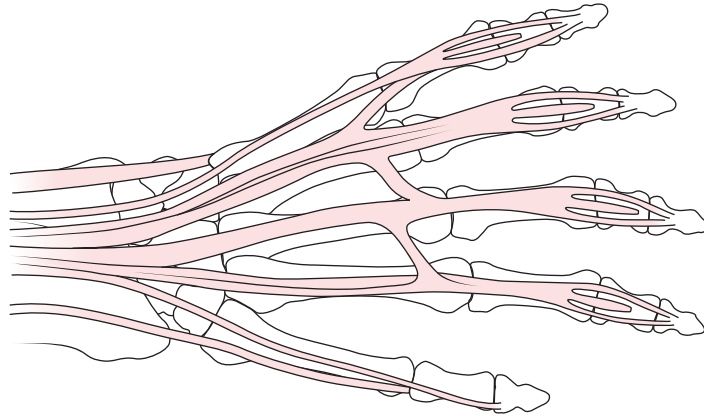


**Figure 13-10** Testing the extensor tendon function. Each finger is extended against a resisting force. This force should not be easily overcome.

results of the examination are interpreted. The wrist itself has three main extensor tendons that are responsible for proper extension at the wrist. If these tendons are cut, the wrist can be extended by the finger extensors but with far less force and can be overcome easily by the examiner. The thumb is served by an abductor and two extensor tendons. If one is cut, the second still can function. Each finger has one main extensor tendon responsible for extension with power. The second and fifth digits, however, have small accessory tendons that can extend these fingers weakly if the main extensors are knocked out of action.

Another anatomic point that possibly can cause misinterpretation in the examination for extension of the digits is that as extensor tendons cross the wrist, they flatten out and interconnect with other extensors over the dorsum of the hand (Fig. 13-11). Weak extension of a severed tendon can occur by the action of the adjacent interconnecting tendon. These interconnections also can prevent severed extensor tendons from slipping back into the forearm after they are cut. This anatomic property of extensors makes anastomosis easier for extensors than for flexor tendons because the two severed ends can be readily retrieved during repair.

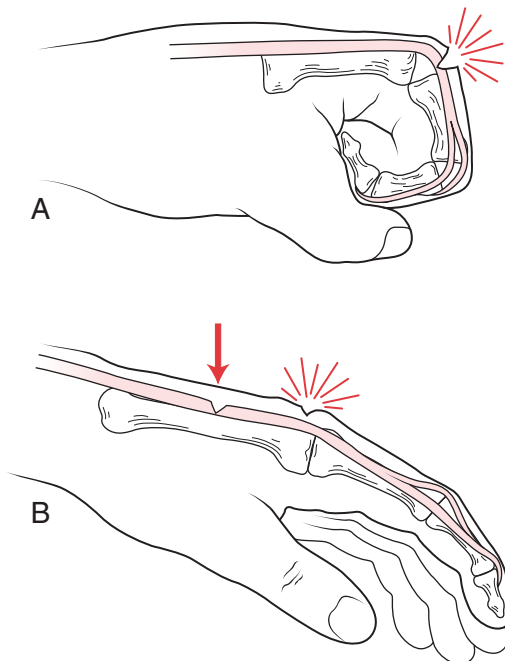
Whenever there is doubt about extensor tendon function, careful exploration has to be carried out through the laceration itself. Extensor tendons are superficial and can be identified easily with proper and gentle exposure. A key factor to remember is that the position of the hand at the time of examination and exploration may be different from the position of the hand during injury. If that should be the case, the actual laceration to the tendon may be at a location away from the laceration on the skin (Fig. 13-12). Active flexion/extension of the finger to cause the tendon to slide back and forth is encouraged during the exploration.



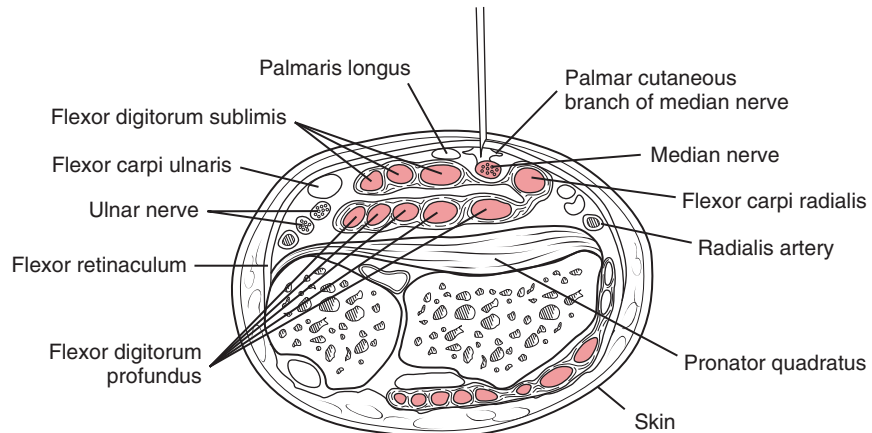
**Figure 13-11** Extensor tendon anatomy of the hand. Note in particular the cross-linkages of extensor tendons at the distal metacarpal level. Severance of an extensor tendon proximal to these cross-linkages can give the examiner the false sense that the affected digit can be extended because of the help that cross-linkage provides through the adjacent tendon.

### Flexor Function

The thumb has only one flexor tendon, but the index, middle, ring, and little fingers have two main flexor tendons. The volar surface of the wrist is a complex and vulnerable area, replete with important structures. As illustrated in Figure 13-13, the median nerve lies just deep and radial to the palmaris longus, the most superficial tendon. Even trivial-appearing lacerations to the wrist can cause serious tendon and nerve damage.



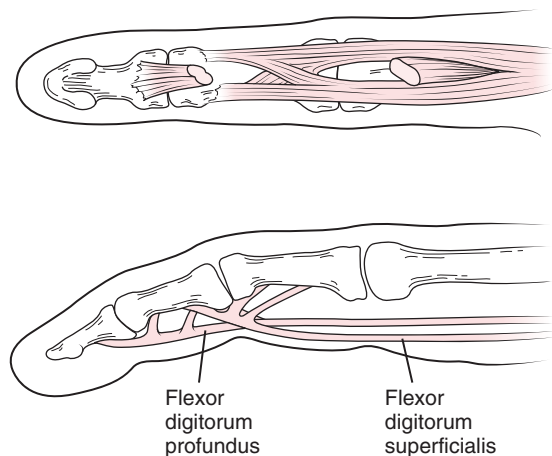
**Figure 13-12** Tendon-skin wound mismatch. **A**, A tendon can be partially lacerated in one position, such as a closed fist. **B**, When the wound is explored, however, the tendon injury might be missed because the site of the tendon injury has retracted when the hand is extended for care. The examiner must perform the exploration by trying to recreate the position of injury.



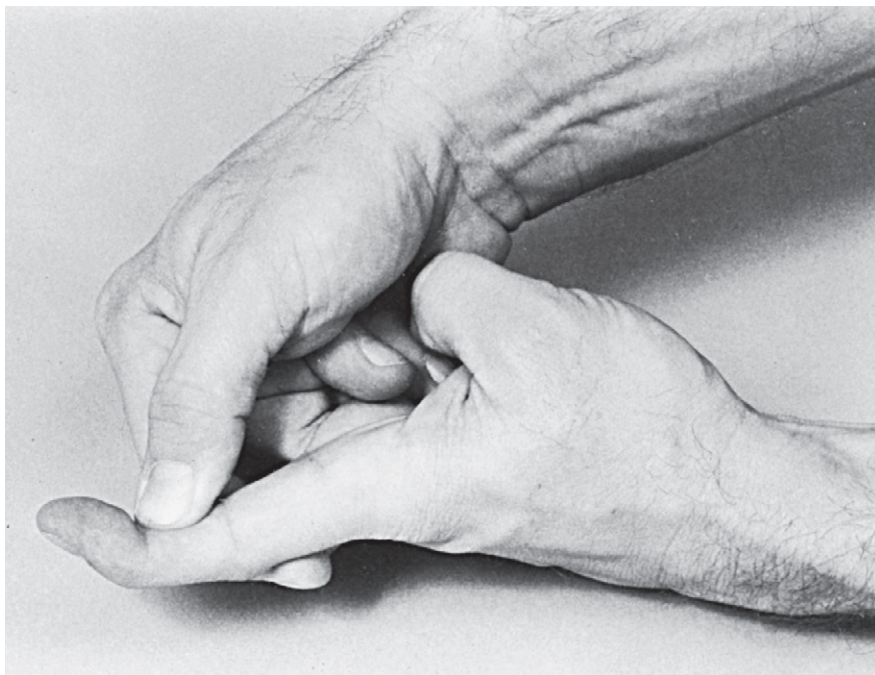**Figure 13-13** Cross-sectional anatomy of the wrist. Note in particular the superficial location of the median nerve. Any visible tendon laceration, such as to the palmaris longus, has to raise the suspicion of an injury to the median nerve.

The flexor tendons to each finger are paired. The flexor digitorum profundus tendons are responsible for power and mass action, such as is needed for gripping. These tendons run deep to the flexor digitorum sublimis tendons, but at the level of the middle phalanx, the profundus splits through the sublimis and goes on to attach to the distal phalanx (Fig. 13-14). To test profundus function, the action of the sublimis tendon has to be blocked by holding each digit, one at a time, in extension at the middle phalanx (Fig. 13-15). The patient is asked to flex the distal phalanx, which now can be accomplished only through the action of the profundus. During this maneuver, 60 degrees of flexion is normal.

The flexor digitorum sublimis tendons are responsible for the positioning of the fingers so that power flexion can take place. These tendons run superficial to the deep tendons until they are split at the distal portion of the middle phalanx by the profundi. The sublimis tendons attach to the proximal portion of the middle phalanx. To test for sublimis action, the



**Figure 13-14** Note the relationship of the flexor digitorum profundus to the flexor digitorum superficialis. The profundus splits through the superficialis, which is attached on the middle phalanx. The profundus attaches to the distal phalanx.



**Figure 13-15** Testing for function of the flexor digitorum profundus. The distal phalanx of the finger is forcibly flexed, while the action of the superficialis tendon is blocked. Only the profundus can flex the distal phalanx.

profundus group has to be blocked by the examiner. As illustrated in Figure 13-16, the examiner holds all the fingers in extension except the one being tested. The patient is asked to flex the finger fully at the metacarpophalangeal and proximal interphalangeal joint. If the sublimis is lacerated, the patient is unable to flex that finger.

---

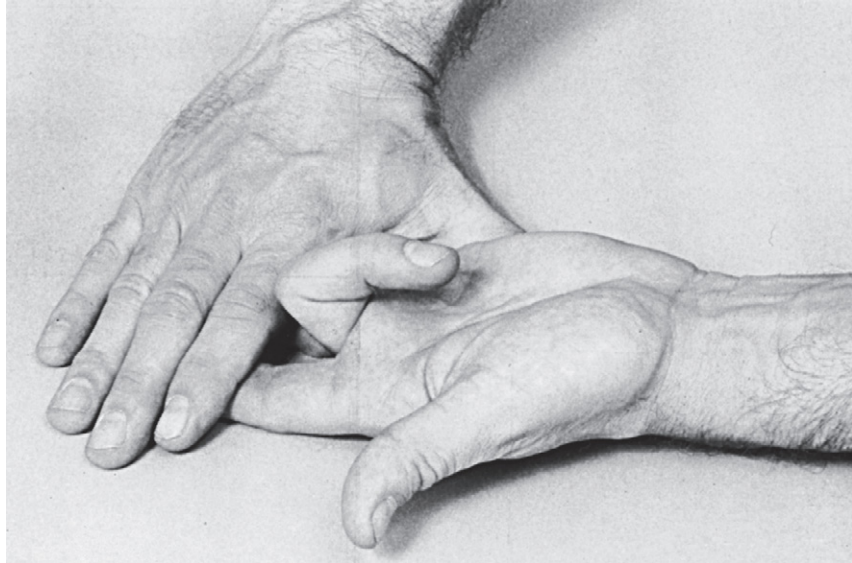## CIRCULATION

The circulation of the hand is extraordinarily rich and redundant (Fig. 13-17). Most people can have complete loss of either the radial or the ulnar arteries and maintain adequate perfusion. Loss of perfusion because of damage to the vessels usually results from an extensive injury not ordinarily repaired by emergency wound care personnel, and consultation is obtained. Although pulses are always documented in any hand injury, the best indicators of perfusion are color, skin blanching with pressure, temperature, and capillary refill at the nail bed. Because arteries travel with nerves in neurovascular bundles, profuse arterial bleeding of the digit should raise the suspicion of an accompanying digital nerve injury.

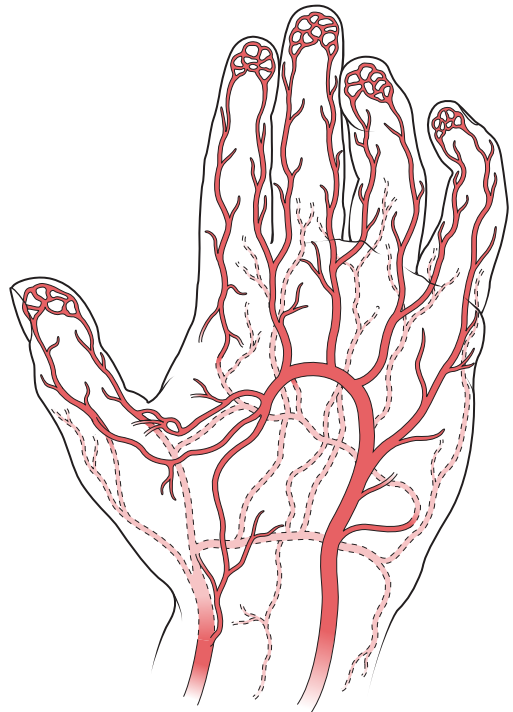
---

## RADIOGRAPHY

Radiographs are used liberally to assist in the evaluation of the hand. For any blunt trauma associated with a laceration, underlying fractures must be ruled out. Not only do hand fractures require careful and sometimes specialized management, but also a fracture with a laceration has to be considered an open fracture. Open fractures usually are managed by consultants.



**Figure 13-16** Testing for function of the flexor digitorum superficialis. The mass action of the profundus can be blocked by holding the nontested fingers in extension. The tested finger can be flexed only at the proximal interphalangeal joint by the superficialis tendon.



**Figure 13-17** The profuse and redundant vascularity of the hand. It is common to be able to sacrifice either the radial artery or the ulnar artery and still have complete perfusion of the hand. Lacerations of the digital arteries arouse suspicion of a lacerated digital nerve.

Foreign bodies frequently are associated with hand injuries. Radiographic examinations are particularly useful to detect metal and other debris. Contrary to a common misconception among clinicians, almost all types of glass, in 90% of cases, are easily detectable by radiographs (see Chapter 16).<sup>5</sup>

---

## WOUND EXPLORATION

Ultimately, each laceration of the hand should be explored gently and carefully just before repair. Despite normal functional testing, partial tendon lacerations and violation of joint capsules might remain undetected until exploration is carried out. This procedure usually is accomplished by retracting the wound with an Adson forceps or a skin hook and using a mosquito clamp to spread open the deeper tissue for a good look, preferably in a bloodless field. Because small wounds can harbor serious injury to underlying structures, extension of the skin laceration sometimes is necessary to gain adequate exposure. Chapter 9 provides further details concerning tourniquet application, wound extension, and exploration. If there is a doubt about an injury to an important structure of the hand, the advice of a specialist should be sought.

---

## SELECTED HAND INJURIES AND PROBLEMS

Although there is a large variety of wounds and lacerations to the hand, the wounds and lacerations described here are those that are commonly managed and repaired by emergency wound care personnel. Serious, complex injuries, especially ones that cause functional deficits, are best cared for by specialists. Animal bites and burns to the hands are discussed in Chapters 15 and 17.

### Uncomplicated Lacerations

The principles and techniques of wound repair discussed in Chapter 10 also apply to closing hand lacerations. Most lacerations of the dorsal and volar surfaces of the hand can be anesthetized by direct wound infiltration (see Chapter 6). Large lacerations can be managed by wrist blocks. Wounds beyond the proximal phalanx are best anesthetized with digital blocks.

Débridement of the hand, when indicated, is carried out with great caution. Excessive removal of skin can lead to failure of adequate coverage, eventual wound contraction, and a resulting functional deficit. Fat is a good substrate for bacterial growth, and less care has to be taken when débriding away contaminated and devitalized tissue. Injured fat does not regenerate, however, and the padding role that fat provides the volar surface of the hand can be endangered. In cases in which large amounts of fat must be sacrificed, the opinion of a consultant is recommended.

Because of the number of important structures that lie within the small confines of the hand, deep closures with any suture material are discouraged. Any “foreign” material can provoke inflammation and tissue scarring that might interfere with such important and vulnerable functions as tendon gliding. By closing the skin alone, little dead space is left behind in hand injuries. In addition, natural tension across the wound usually is minimal in hand lacerations, and deep closures are not needed to reduce that tension.

The recommended suture material for skin closure is 5-0 nonabsorbable monofilament nylon. Only as many sutures as are necessary to achieve appropriate wound edge approximation are placed. Hand lacerations heal with little scarring, and no purpose is served by excessive sutures in search of the perfect repair. Simple interrupted technique suffices for most wounds. Skin on the hand tends to invert with closure, however, particularly on the dorsal surface. In this case, the horizontal mattress technique is useful.

## Fingertip Injuries

The management of fingertip injuries is controversial. There are few actual controlled studies of fingertip and fingernail problems. The strategies and choices of repair techniques vary considerably among personnel who take care of these problems. The issue of whether to remove the nail after an injury evokes widely varying opinions. Certain principles guide the repair process, however. These are preservation of finger length, nail growth capacity, fingertip padding, and sensation.<sup>6</sup>

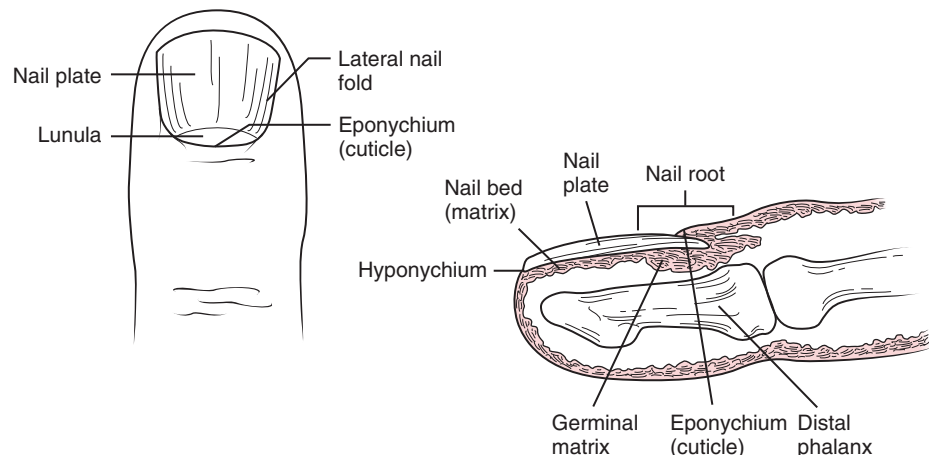
The fingertip and fingernail apparatus form a complex anatomic and functional unit (Fig. 13-18). The fleshy volar pad is replete with nerve endings and capillaries. There is sufficient soft tissue to pad the fingertip and distal phalanx effectively against undue trauma. Preservation of sensation of the fingertip is crucial to all manual activities. Even with full-thickness loss of the finger pad, healing and regeneration of tissue usually can be relied on to restore a functional pad. Numerous fibrous bands called *septa* anchor the skin to the underlying bone structure (Fig. 13-19). These structures prevent sliding or slipping of the skin during use of the fingers. Septa should be kept anatomically intact whenever possible.

The nail apparatus has several components. The nail itself is divided into the nail root, which is the portion that lies under the eponychium, and the nail plate, which adheres to the sterile matrix. The matrix also has two parts, the germinal matrix from which new nail is generated, and the sterile matrix, or nail bed, over which the nail passes during normal growth. The eponychium, commonly referred to as the cuticle, is the fold of skin that overlies the nail root. One of the main principles of nail management is to prevent the eponychium from adhering and scarring down onto the germinal matrix. Should this take place, nail regeneration can be impaired significantly. Techniques to prevent this occurrence are discussed in the following sections.

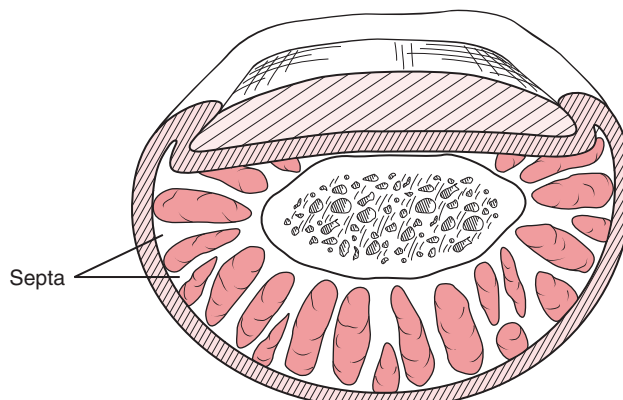
Fingertip injuries can be divided into three groups: (1) blunt injuries (subungual hematoma), (2) nail and nail bed lacerations, and (3) avulsion injuries with tissue loss. Foreign bodies lodged under a fingernail are discussed in Chapter 16.

### Blunt Injuries (Subungual Hematoma)

The treatment of subungual hematoma is controversial and depends on the clinical training and personal experience of the physician. Until recently, there have not been many studies to clarify the issues surrounding this problem and provide guidance.



**Figure 13-18** Anatomy of the distal finger and nail components.



**Figure 13-19** The fibrous septa that connect the skin to the underlying phalanges. The septa provide stability to the soft tissue of the finger.

It has been thought and taught that the presence of a large hematoma (>50% of the nail surface) signifies a probable laceration of the nail bed and the need for nail removal and repair. In a study of 47 patients, 60% with a large hematoma had a nail bed laceration.<sup>7</sup> If a distal phalanx fracture also was present, the likelihood of a laceration increased to 97%. The authors concluded that nail removal, with nail bed repair, should be carried out in patients with large hematomas (at least 50% of the nail). Smaller hematomas could be treated with trephination alone.

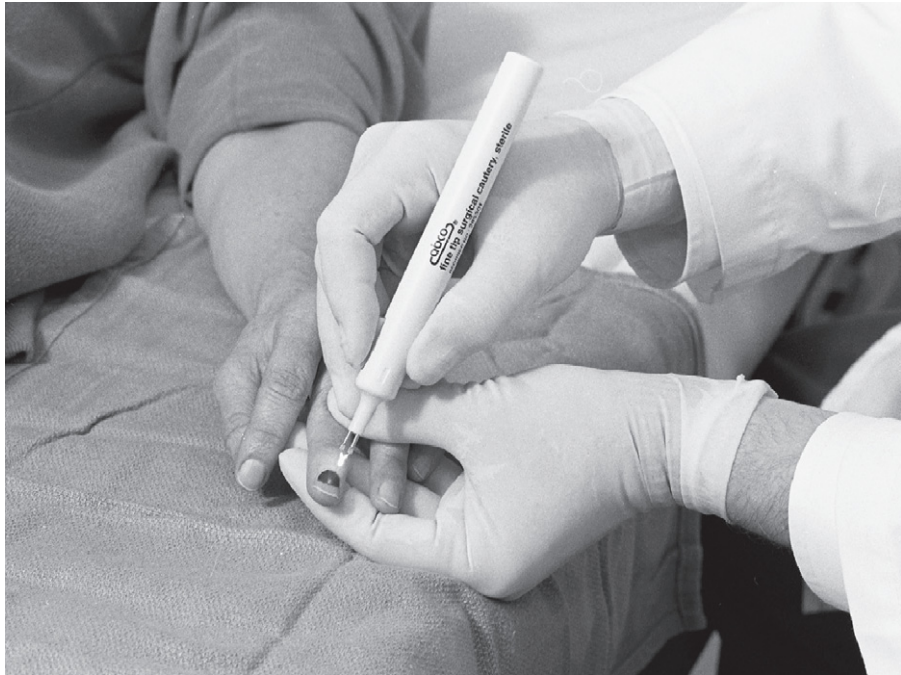The argument for limited nail removal and nail bed repair is supported by a study of 45 patients with subungual hematoma who were followed for at least 6 months posttreatment.<sup>8</sup> All patients, including 16 patients with a 50% hematoma and 14 with distal phalanx fracture, had trephination as their *only* treatment. They were splinted for protection for 1 week. The outcome was uniformly good, with no wound infections, osteomyelitis, or significant later nail deformities. Excluded from the study were patients with nail disruption and prior existing nail deformities.

A more recent comparison of simple trephination versus nail removal and bed repair showed a better outcome in the simple trephination group.<sup>9</sup> There were more complications in the repair group, and the cost was four times that of trephination. Both of these studies are consistent with the author's experience. Regardless of the size of the hematoma or the presence of a tuft fracture, simple trephination is preferable if the nail remains well attached to the bed.

Nail trephination can be carried out by a variety of methods. A heated paper clip creates an appropriate-diameter drainage hole, but this technique requires considerable practice and skill. The clip has to be heated until it is red hot and transferred quickly to the nail. Heat is lost quickly, and the procedure commonly has to be repeated to gain full nail penetration. To create a drainage site, 18G needles and no. 11 scalpel blades can be used employing a rotating or drilling motion. The drainage holes are often small and close prematurely with a blood clot. There is considerable pressure brought to bear on the fingertip when applying this technique. More effective and less painful is a battery-powered drill.

The most efficacious and least painful device is the disposable electric cautery, which can be handled like a pencil and placed with ease and precision over the hematoma (Fig. 13-20). The drainage hole is adequate, and the patients tolerate the procedure well when they understand that the heat tip will not burn them. With appropriate technique, when the heat tip passes through the nail, heat is rapidly dissipated by the underlying hematoma.






**Figure 13-20** Electric cautery to penetrate a nail to drain a subungual hematoma.

The following guidelines are offered for the evaluation and management of subungual hematomas:

- Trephination alone is appropriate for subungual hematomas of any size in which the nail remains attached and there is not deformity of the fingertip suggesting a displaced fracture. Even if a nail bed laceration or nondisplaced tuft fracture is present, healing proceeds without event, and full function is restored to the finger with splinting.
- Nail removal is reserved for patients in whom the nail is already partially avulsed, torn, or deformed from this injury. Under these circumstances, when the nail is removed, as described in the following section, the bed is inspected, and lacerations are repaired.
- Although subungual hematomas with associated fractures technically can be considered open fractures, in reality they do not need to be treated as such. Antibiotics are not indicated if the nail is left in place.

### ***Nail Bed Lacerations***

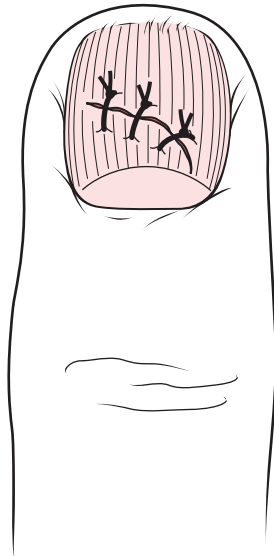
Exposed nail bed lacerations of the matrix, caused by blunt trauma, are repaired by careful repositioning of the wound edges and suturing with 5-0 or 6-0 absorbable suture material. If intact, an avulsed or removed nail can be replaced, for temporary splinting purposes, under the eponychium (Fig. 13-21). The main reason for using the nail as a splint is to prevent adhesions and granulation tissue buildup between the eponychium and germinal matrix of the bed. It also serves to splint any accompanying fracture and mold the healing wound site. To maintain the nail in place, two 5-0 nonabsorbable sutures can be placed through trephined holes (see Fig. 13-21). If the nail cannot be used, a small piece of nonadherent dressing such as Adaptic or a Penrose drain can be tucked under the eponychium (Fig. 13-22). The nail or packing is usually left in place for 7 to 10 days.



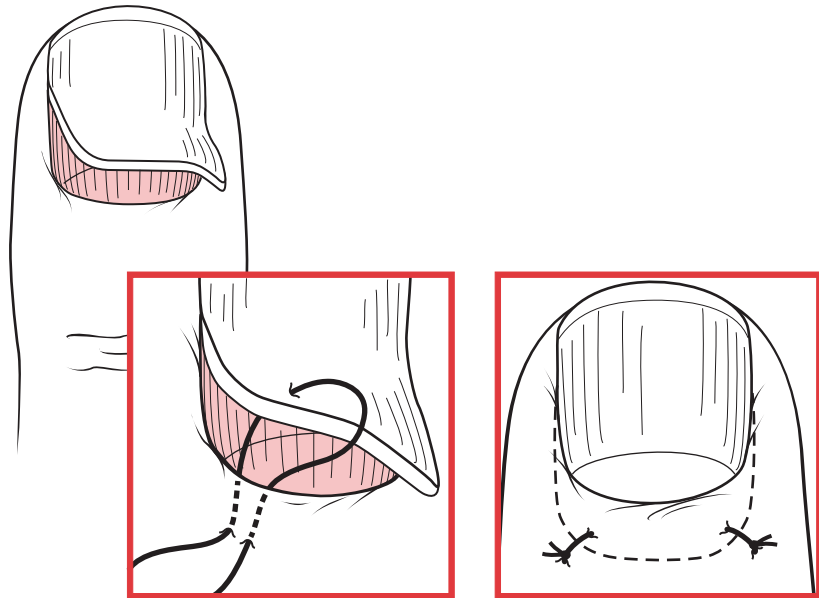
**Figure 13-21** Nail bed injury. If the decision has been made to remove the nail, and a laceration of the bed is discovered, this laceration is repaired with 6-0 absorbable suture (e.g., polyglycolic acid). The nail, if removed intact, can be replaced as a splint for 7 to 10 days. The nail prevents adherence of the germinal matrix to the eponychium. The nail is anchored by placing sutures as shown in the lateral aspect of the plate.

Crush injuries of the fingertip in children can be complicated with the extent not evident during the first emergency department visit.<sup>10</sup> The swelling, pain, and tissue distortion can make treatment decisions difficult. For these complex injuries, cleansing, tissue preservation, antibiotics, dressing, and referral are recommended. Closure can be delayed 2 weeks with good long-term results.<sup>10</sup>

In less complicated injuries, it is common for the nail root to avulse partially from the bed under the cuticle (eponychium). If the remainder of the nail appears intact and is



**Figure 13-22** Nail bed injury. If the nail is in no condition to be replaced, a small stent is fashioned to separate the eponychium from the germinal matrix. This stent or packing is removed within 5 to 7 days.



**Figure 13-23** Nail root avulsion. Occasionally the proximal aspect of a nail root is avulsed. The technique illustrated shows how this nail root can be replaced under the cuticle. This is an injury more commonly seen in children.

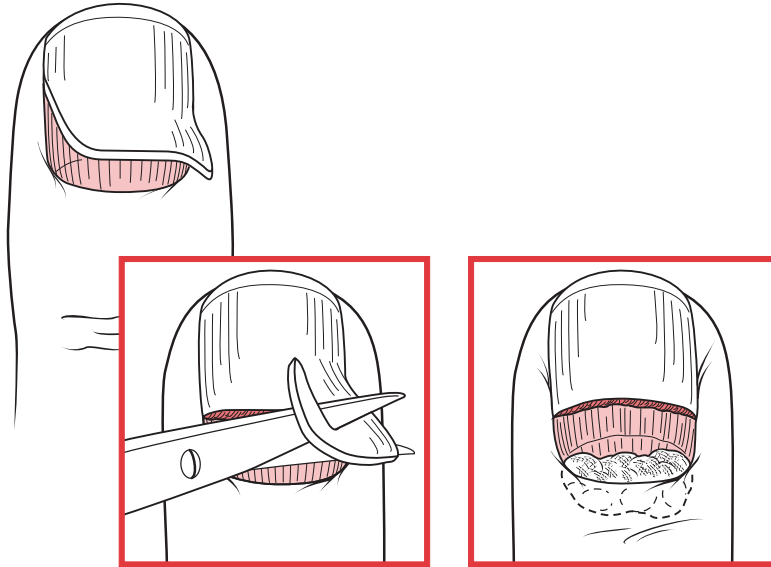
attached firmly to the nail matrix, the nail root can be replaced by the nail root retrieval technique (Fig. 13-23). If this procedure is too difficult to accomplish, the nail root is excised, and the eponychium is packed with a nonadherent dressing material for 10 to 14 days for the same reasons described earlier (Fig. 13-24). A new nail eventually grows out and extrudes the remaining portion of the old nail.

Lacerations of the fingertip and nail apparatus caused by sharp or shearing forces usually can be managed by simple suturing. Transverse lacerations through the nail plate and matrix can be repaired by removing the distal portion of the nail plate to expose the lacerated nail bed. Repair of the matrix is carried out with 6-0 absorbable suture (Fig. 13-25). Maintaining the integrity of the nail root prevents nail growth problems with the germinal matrix.

Longitudinal lacerations through the matrix and eponychium require careful repair of both structures. The nail bed is repaired with 6-0 absorbable suture (Fig. 13-26). The eponychium and surrounding skin are closed with nonabsorbable material such as nylon. If the nail plate is removed in its entirety, a nail replacement or packing for 10 to 14 days, as previously described, is necessary to prevent eponychial adherence to the germinal matrix. Only the nonabsorbable sutures are removed after 10 to 12 days.

### *Nail Removal Technique*

When the decision is made to remove the nail, the techniques illustrated in Figure 13-27 are suggested. A small hemostat or iris scissors is inserted under the nail plate along the nail bed. The instrument is advanced slowly as it is spread open to lift the nail plate off the matrix. This process is carried back through to the nail root and germinal matrix area. Care is taken to avoid undue injury to the nail bed and germinal matrix. The eponychium also is gently pushed away from the nail plate. When the nail plate has been loosened, a hemostat is used

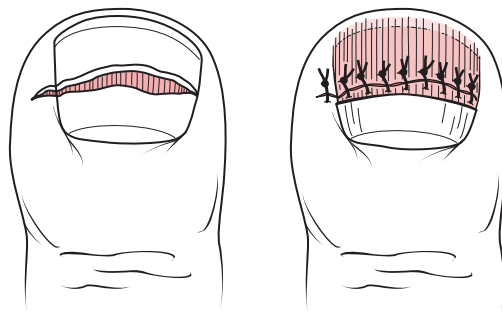


**Figure 13-24** Nail root avulsion. If the nail root cannot be replaced, the nail root can be excised, and a small Penrose drain or Adaptic packing is placed under the eponychium for 5 to 7 days. A new nail germinates and extrudes the remainder of the old portion.

to grasp the nail plate firmly and pull it out from under the eponychium. The nail does not always come off easily, and some measure of force must be applied.

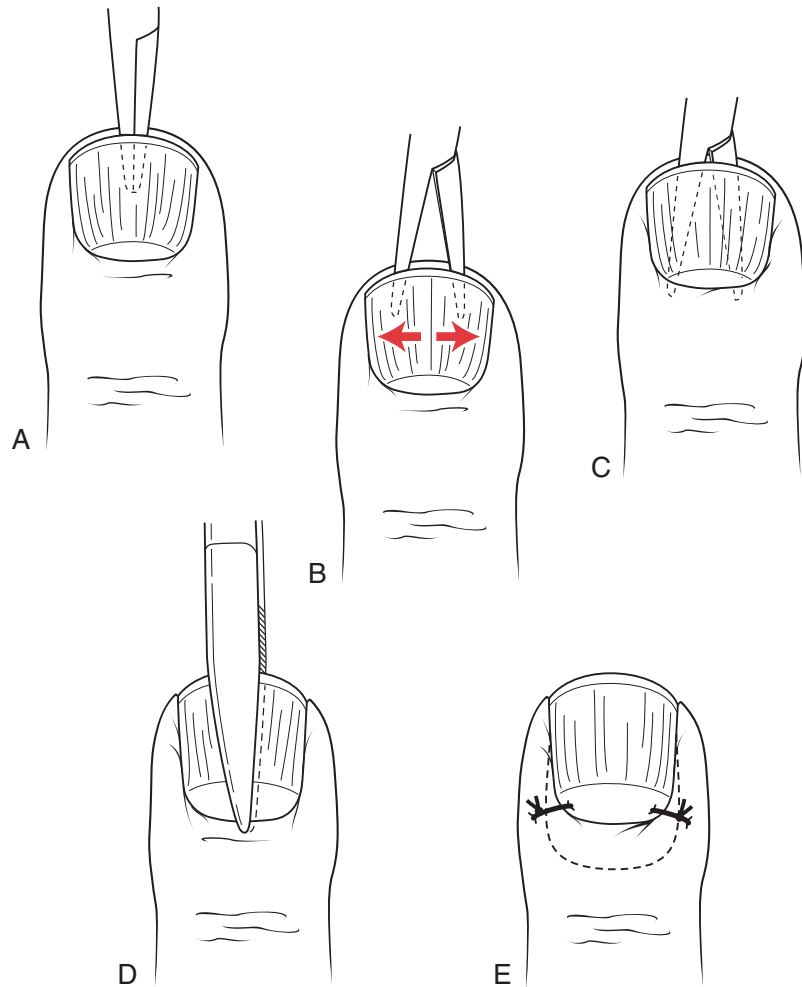
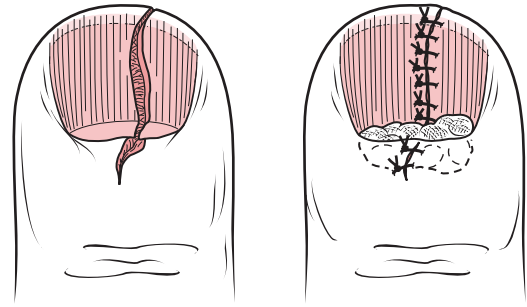
### Avulsion Injuries

Another area of controversy in fingertip management surrounds avulsion injuries with loss of tissue (Fig. 13-28). At issue is whether to close these avulsions by grafting or whether to leave them to heal spontaneously. There is consensus that any fingertip avulsion with less than 1 cm<sup>2</sup> area of tissue loss and no accompanying bone or nail bed injury can be managed by allowing spontaneous healing to take place.<sup>11</sup> Also at issue are avulsion injuries of larger areas or bone exposure. Losses of 1.8 × 2.6 cm, even with bone exposed, in pediatric and adult age groups, have been treated successfully without grafting.<sup>12-16</sup> When bone was exposed, spontaneous soft tissue covering of the distal phalanx occurred with adequate pad formation.<sup>16,17</sup> When comparing complication rates and time lost from work, conservative

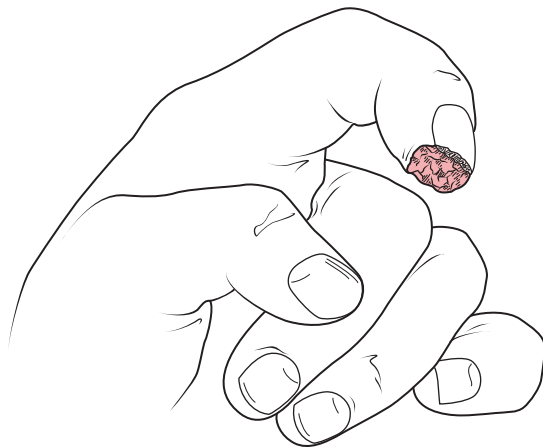

**Figure 13-25** Transverse lacerations of the nail bed often can be managed by leaving the nail root intact. The proximal portion of the nail is excised with tissue scissors proximally to the injury. The nail bed is repaired with absorbable suture. The nail continues to grow over the suture line well after the sutures have been absorbed.

**Figure 13-26** Longitudinal lacerations of the nail bed often are best closed by removal of the nail entirely. When the nail bed is repaired, a Penrose drain or Adaptic packing is used to separate the eponychium from the germinal matrix for at least 5 to 7 days.



**Figure 13-27** Technique for removal of a nail. **A**, Introduce a small hemostat or iris scissors between the nail and the nail bed. **B**, Gently dissect the nail from the nail bed. **C**, Extend the dissection all the way back to the germinal matrix. **D**, Grasp the nail firmly and remove it from the nail bed. **E**, If the nail plate remains intact, it can be replaced as a splint or stent and anchored as shown with two 5-0 nonabsorbable sutures.



**Figure 13-28** Avulsion injury of the fingertip.

management is comparable to grafting.<sup>18</sup> In one study, the infection rate of the conservatively managed group was markedly lower than that of surgically grafted patients.<sup>19</sup> The one area in which conservative management seems less optimal compared with more meticulous surgical repair is when the nail bed is involved and repair is indicated. Unrepaired nail matrices tend to lead more frequently to deformed nails.<sup>19</sup>

Guidelines for the management of avulsion injuries are offered as follows:

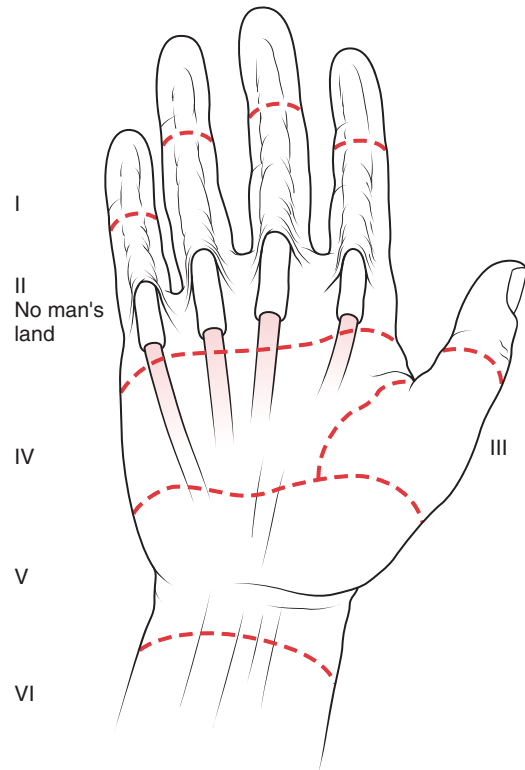
- If the defect is less than 1 cm in diameter and no bone is exposed, spontaneous healing is the treatment of choice.
- For losses greater than 1 cm, but with an intact nail apparatus and no bone exposure, conservative management can be considered an alternative to grafting. Children do well with conservative treatment. Local practice, which may necessitate consultation, often dictates the management of these injuries.
- For avulsions with nail apparatus involvement, repair or revision of the matrix is necessary. Consultation may be required.
- For injuries with exposed bone, consultation is recommended to assist in the decision regarding the treatment choice.

Proper dressings for fingertip avulsions include a nonadherent base, such as Xeroform or Adaptic, with a sponge covering and gauze wrapping as described in Chapter 20. As discussed later, antibiotics are suggested for injuries with exposed bone.

### Tendon Lacerations

All lacerations of flexor tendons (in the upper or lower extremity) are referred to specialists for care. An emergency wound care setting is no place to repair flexor tendon injuries. Besides requiring a controlled surgical environment, these tendons are managed most effectively by trained surgeons using the proper instruments and magnification. Under the best of circumstances, flexor tendon injuries present considerable technical challenges, and repair can be fraught with complications. Injuries in zone II, known as *no man's land*, present the greatest challenge to the caregiver (Fig. 13-29).

In many cases, flexor tendon lacerations can be repaired primarily 3 weeks postinjury.<sup>20</sup> Anastomoses done within 7 to 10 days may have a better outcome.<sup>21</sup> After 3 weeks, reconstructive procedures have to be used. With agreement from the consultant, the skin can be closed and arrangements made for follow-up evaluation and a decision regarding formal

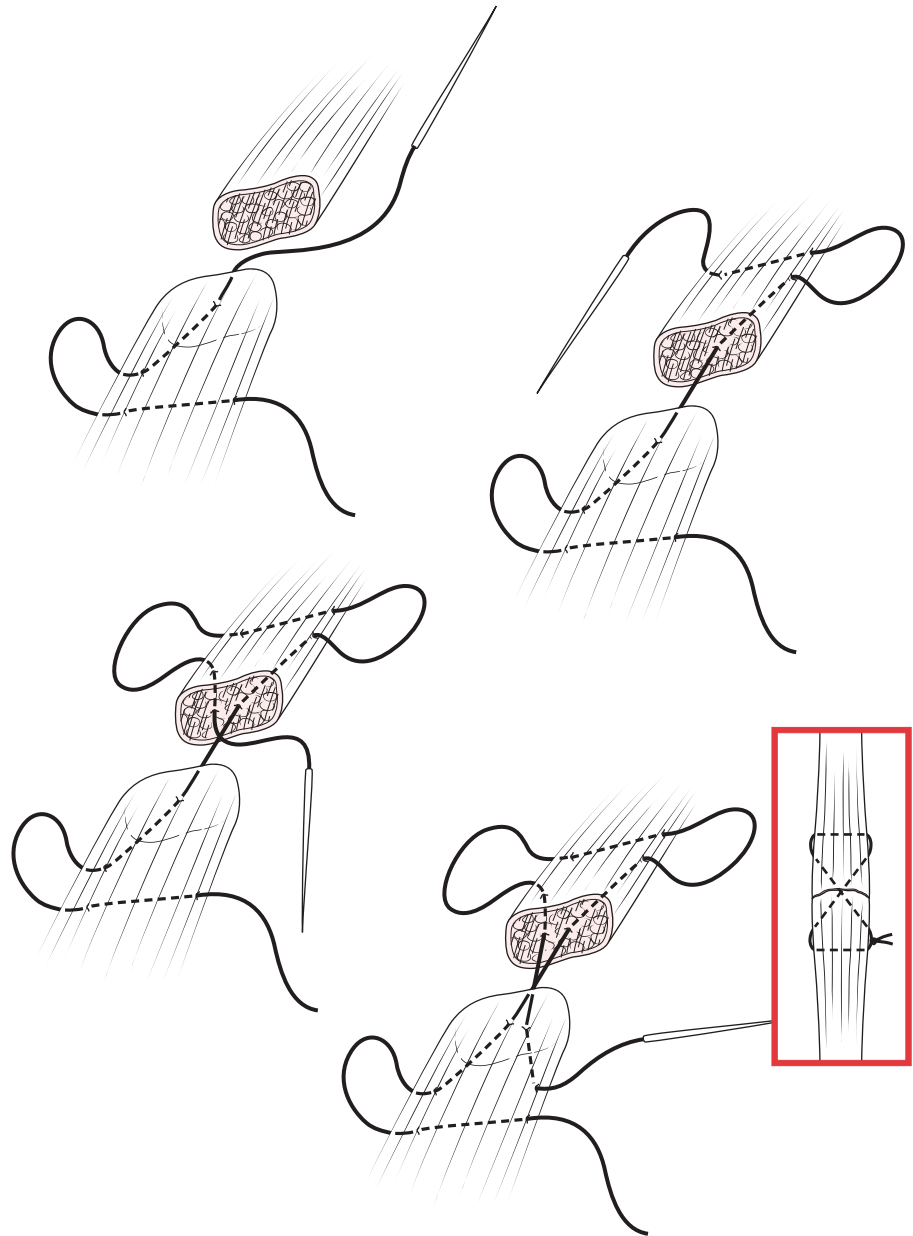


**Figure 13-29** Zones of tendon repair. The hand can be divided into zones that have different implications when considering tendon repair strategy and technique. Injuries in zone II, also referred to as *no man's land*, are difficult to repair because of the complex and close relationship of the tendons and surrounding structures.

tendon repair. The skin closure is done after standard skin cleansing and irrigation. A splint is placed. An intravenous dose of a first-generation cephalosporin is administered in the emergency department, followed by oral cephalosporin or dicloxacillin. Clindamycin can be given to the allergic patient. For injuries with excessive contamination, skin loss, unstable bony skeleton, or missing tissue, immediate operative intervention may be necessary.

Simple, single lacerations of an extensor tendon on the dorsum of the hand, between the distal wrist and metacarpophalangeal joints (zone VI), can be repaired in the emergency wound care area by appropriately trained wound care personnel.<sup>22</sup> It is recommended that training for extensor tendon repair include several supervised repairs under the guidance of a specialist. It is important to master appropriate techniques and understand proper splinting and the necessary follow-up care. The specialist should agree with the plan of care because he or she will take over the aftercare.

Single extensor tendons can be repaired in the emergency department under the following circumstances: (1) if the injury is between the distal wrist and the metacarpophalangeal joints (zone VI), (2) if the skin and tendon wounds are sharp and not heavily macerated or contaminated, (3) if the injury is less than 8 hours old, (4) if the two ends of the tendon are easily visualized, (5) if appropriate instruments are available to minimize trauma to the tissues, and (6) if the patient is cooperative and will comply with follow-up care. The technique for repairing an extensor tendon is shown in Figure 13-30. A 4-0 nonabsorbable suture, such as nylon or polypropylene, on a straight needle is passed through the tendon in the figure-eight pattern until it is secure. The skin is closed with 5-0 nonabsorbable suture material. A plaster splint



**Figure 13-30** The figure-eight technique to reappose sharply divided lacerated extensor tendons. See text for further explanation.



is placed on the palmar surfaces of the forearm-wrist-hand-digit, over the appropriate non-adherent base and the gauze sponge/wrap surface dressing. The wrist is placed at a 30-degree angle of extension, and the metacarpophalangeal joints are placed at a 20-degree angle of flexion. The fingers are only slightly flexed. The splint remains in place for 3 weeks; however, the patient is referred much sooner to the consultant for follow-up care.

On careful exploration of a laceration of the hand, it is common to discover partially lacerated extensor or flexor tendons. The management of these injuries is controversial. Unrepaired, these injuries have been reported to rupture, cause “triggering,” or become entrapped.<sup>20</sup> Successful treatment of these injuries has been reported with skin closure alone followed by splinting.<sup>23,24</sup> Treatment can be guided by cross-sectional size of the laceration. As a general rule, if the tendon is more than 50% transected, it should be repaired as if fully severed. Lesser injuries can be trimmed to prevent triggering or entrapment. Appropriate splinting, rehabilitation, and follow-up care are carried out under the direction of the specialist.

### Nerve Injuries

Lacerations associated with sensory or motor deficits of one of the major nerves of the upper extremity require immediate referral to a consultant. Injuries to the digital nerves can be handled differently, however. Surgical repair is indicated if two-point discrimination exceeds 10 mm.<sup>25</sup> For uncomplicated severed nerves, delayed repair can have significant advantages over early repair.<sup>26,27</sup> The repair setting and time are better controlled, the cut nerve ends and epineurium are better delineated, and early skin closure is an effective barrier against infection. The delayed repair is done through a sterile field and incision. In the emergency department, with consultative support, simple skin suturing is done, a dressing is placed, and the patient is referred to the specialist within 1 to 2 days. Nerve repair can be carried out on an elective basis 10 days postinjury. When the injury is complicated by contamination, tissue devitalization, or associated injuries, early consultation is recommended.

### Amputated Parts

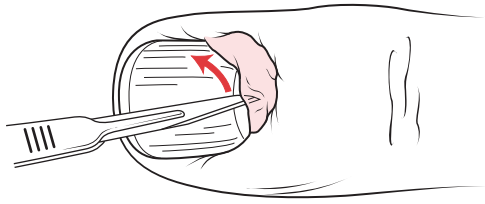
Emergency physicians often are involved in the early management of patients with amputated parts. Although the injury is not within the realm of emergency wound care personnel to manage, proper handling of the injured extremity and severed part is important, especially if there is a chance of reimplantation by a specialist.

The injured extremity is gently cleansed and wrapped in lightly saline-moistened gauze sponges followed by gauze wrapping. A tourniquet rarely is needed to stop hemorrhage because natural vasospasm and platelet plugging of the severed vessels occurs rapidly after injury. It is common to administer a dose of intravenous first-generation cephalosporins to the patient as prophylaxis.

The severed part is placed in a dry sterile sponge wrapping. Saline soaking causes unnecessary and unwanted edema and makes reimplantation much more difficult. The wrapped severed part is placed in a small plastic wrap or bag. The bag and its contents can be put in a container with ice to cool the tissue. Great care has to be taken to ensure that ice does not come into direct contact with the severed part so as not to cause necrosis from freezing. When these steps have been taken, the patient can wait for the specialist or be transported to an appropriate care facility.

### Paronychia

The most common hand infection is a paronychia.<sup>28</sup> A paronychia is an infection of the eponychium, and it usually is associated with a collection of pus between the eponychium and the nail root. The infection is localized most often to one side of the eponychium, the lateral nail fold. It can include the eponychium in the midline, however, or proceed in

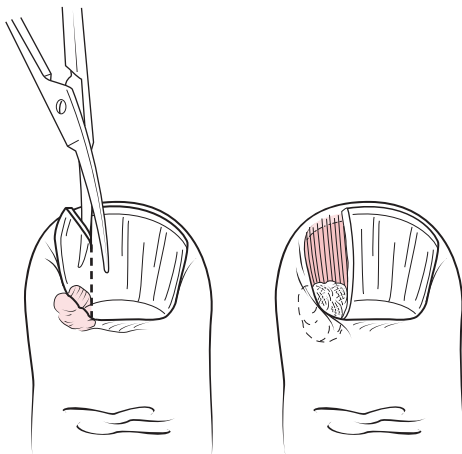


**Figure 13-31** Technique for draining a simple paronychia. The no. 11 blade is brought between the nail and the eponychium parallel to the nail plate. This simple maneuver drains most paronychias.

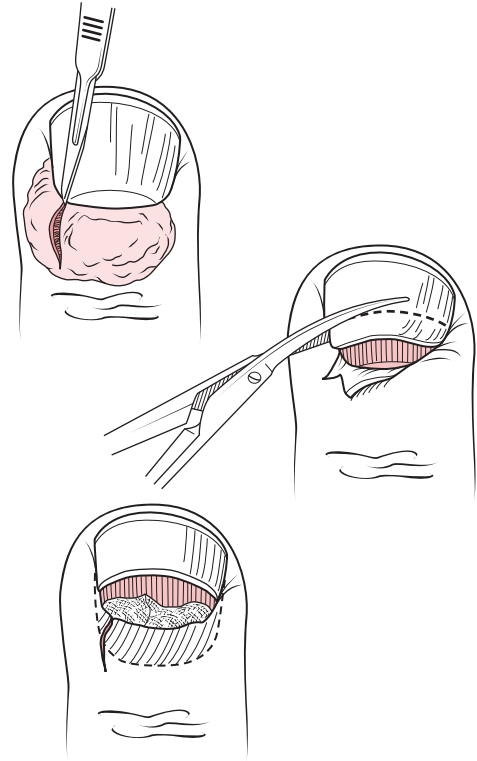
“horseshoe” fashion to involve the entire eponychium. Pus also can invade the space under the nail plate. The most common bacteria found in a paronychia are gram-positive cocci, either *Streptococcus pyogenes* or penicillin-resistant *Staphylococcus aureus*.<sup>28,29</sup>

The simplest and most effective manner to drain a paronychia is to insert a no. 11 blade between the eponychium and the nail plate and gently sweep the blade to elevate the eponychium (Fig. 13-31). With deft technique in a calm patient, this procedure can be done with anesthesia. Otherwise, a digital block is performed before drainage. After drainage, a simple adhesive bandage (Band-Aid) dressing is applied. The patient is instructed to remove the Band-Aid and soak the finger in warm, soapy water twice a day. Band-Aids can be reapplied between soakings. Some authorities recommend placing drains under the eponychium. Uncomplicated paronychia in patients without risk factors, such as diabetes, does not necessitate these measures. Antibiotics often are prescribed but are unnecessary if the pus is completely drained and there is no surrounding digital cellulitis. If there is cellulitis, a first-generation cephalosporin or clindamycin (for allergic patients) can be prescribed for 7 days.

Occasionally a paronychia extends below the nail plate between the nail and matrix. Pus can be seen through the semitranslucent nail. If pus is suspected to be in this space, partial or complete nail removal is recommended. Merely sweeping a no. 11 blade under the eponychium does not suffice. Figure 13-32 shows a method of partial nail removal to accomplish the drainage of the paronychia and the pus under the nail plate. A paronychia that involves the entire eponychium and nail root area can be managed as illustrated in Figure 13-33. An incision of the eponychium is made to free the nail root for removal. Occasionally the entire nail



**Figure 13-32** When a paronychia extends below the nail and insinuates between the nail bed and nail plate, partial nail removal must take place. When nail removal is accomplished, a small packing or drain is left in place for 5 to 7 days.

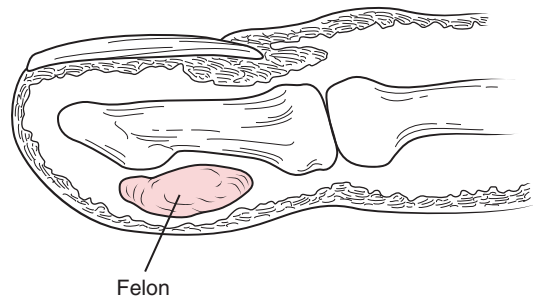


**Figure 13-33** A complex "horseshoe" paronychia usually needs to be drained by incising the paronychia directly and removing either a portion or all of the nail. Packing is left in place for 5 to 7 days to prevent adherence of the eponychium to the germinal matrix.

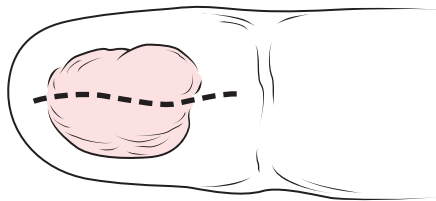
must be removed to effect complete drainage. Antibiotics often are recommended for complex paronychia. Antibiotics for hand wounds are discussed subsequently.

### Felon

A felon is an infection with a collection of pus in the pulp space of the fingertip (Fig. 13-34). The finger pad is quite swollen and exceedingly tender. The most common bacteria found in these infections are *S. pyogenes* and penicillin-resistant *S. aureus*.<sup>28,29</sup> Several methods to drain felons have been recommended over the years. The so-called fish-mouth and lateral



**Figure 13-34** Felon in the pulp of the finger space.



**Figure 13-35** Technique for draining a felon. The incision is made directly over the area of maximal tenderness and fluctuance.

incisions that cut through the supporting fibrous septa of the finger pad are thought to increase the occurrence of unnecessary sequelae.<sup>30</sup>

The simplest technique to drain a felon is to make a longitudinal incision directly through the finger pad on the volar surface of the digit into the pulp space and pus collection (Fig. 13-35).<sup>30</sup> The incision is kept open with a small loose-fitting wick made of a nonadherent dressing material or a small sliver of rubber, such as part of a Penrose drain or a rubber band. The drain is removed at follow-up at 48 hours, after which a soaking routine similar to the one used for paronychia is encouraged. Patients then are started on antibiotics (see later).

### Pressure Injection Injuries

An injury to the hand that is caused by a high-pressure injection device, such as a paint sprayer or grease gun, initially seems benign. Through a pinhole, such a device can create a needle-thin stream that can have a pressure of 15,000 lb/inch<sup>2</sup>. A variety of paints, petroleum, and other chemicals can easily pierce the skin and, under the pressure created, spread throughout the hand along natural tissue planes and tendon sheaths. Grease and paint are the two most common substances.<sup>31</sup>

The entry wound is often no more than a small puncture. The most common site of entry is the tip of the index finger, a result of "testing" to see if the device works. Some of the injectable chemicals, such as the petroleum, do not cause an immediate reaction or pain. The patient often has minimal complaints. The combination of the small wound and relative lack of symptoms is deceptive. These injuries can progress over hours to marked pain, swelling, and inflammation of the entire hand. They require immediate consultation. Some authorities recommend fasciotomies of the hand before significant swelling develops to forestall ischemia created by an increase in tissue pressure from the intense reaction, to remove the chemical, and to debride necrotic tissue. The overall incidence of amputation has been reported to be 48%.<sup>31</sup>

---

### ANTIBIOTICS FOR HAND WOUNDS

The use of antibiotics in patients with hand injuries is largely empirical because there are few definitive, well-designed studies examining their use. Several studies have shown that prophylactic antibiotics are of no value in uncomplicated lacerations of the hand.<sup>3,10,32</sup> In more complicated injuries, such as avulsions of the fingertip, antibiotics often are prescribed, but there are no definitive studies to support this practice. Some studies have found that antibiotics are of no value.<sup>13,15</sup>

It is common to treat fingertip injuries with prophylactic antibiotics. In a large study of 299 patients treated without antibiotics for injuries ranging from simple lacerations to avulsions, only two infections developed.<sup>33</sup> One group found a decrease in the infection rate with the use of antibiotics when bone was exposed under severe crushing forces.<sup>34</sup> It has not even been shown in the face of a paronychia that antibiotics improve outcome. Despite this

controversy, some recommendations that rely more on traditional practice and clinical judgment can be made. Antibiotics should be used in the following situations:

- Wounds greater than 8 hours old
- Wounds caused by a crushing mechanism in which some tissue compromise is suspected
- Contaminated or soiled wounds in which extensive cleansing and débridement have been necessary
- Fingertip avulsions with exposed bone
- Open fractures
- Tendon or joint involvement
- Mammalian bites (see Chapter 15 for further discussion and special circumstances)
- Complex paronychia with pus under the nail
- Felons
- Immunocompromised patients or patients who have diabetes

The choice of antibiotics for hand injuries also generates debate. First-generation cephalosporins, which are effective against most of the common gram-positive and gram-negative organisms that are implicated in wound care, are a good first choice<sup>35</sup>; these include cephalexin (Keflex), cephadrine (Velosef), and cefadroxil (Duricef). For penicillin-allergic patients, the macrolides (erythromycin, azithromycin) and clindamycin (Cleocin) are appropriate. For antibiotics to have any value, they must be administered as soon as possible in the emergency department, preferably within 3 to 4 hours from the time of injury.<sup>36</sup> For maximal effectiveness, the initial dose should be given intravenously. A recommended intravenous first-generation cephalosporin preparation is cefazolin (Ancef); clindamycin (Cleocin) can be used for penicillin-allergic patients. For prophylaxis, the duration of administration is 4 to 5 days.

---

## DRESSINGS AND AFTERCARE

The basic finger dressing is described in Chapter 20. Xeroform is a popular nonadherent base, as is Adaptic. The latter is probably less adherent in wounds in which there is more exudate and crusting. All fingertips are well padded with gauze sponges. A metal protective splint is recommended for patients who are going to return to work or resume manual activities.

Most hand wounds are best followed up within 48 hours with dressing removal for inspection. If a suture line becomes infected, suture removal and wound cleansing with thorough irrigation are carried out as soon as possible. Infections of the hand can be disastrous and often spread rapidly to important structures from a small nidus. Most sutures of the hand are removed in 8 to 10 days.

## REFERENCES

1. Custer J, Edlich RF, Prusak M, et al: Studies in the management of the contaminated wound, *Am J Surg* 121:572-575, 1971.
2. Lammers RL, Fourre M, Callahan ML, et al: Effect of povidone-iodine and saline soaking on bacterial counts in acute, traumatic, contaminated wounds (Abstract), *Ann Emerg Med* 19:709, 1990.
3. Roberts AHN, Teddy PJ: A prospective trial of prophylactic antibiotics in hand lacerations, *Br J Surg* 64: 394-396, 1977.
4. Gellis M, Pool R: Two-point discrimination distances in the normal hand and forearm, *Plast Reconstr Surg* 59:57-63, 1977.
5. Tanberg D: Glass in the hand and foot, *JAMA* 248:1872-1874, 1982.
6. Margles S: Principles of management of acute hand injuries, *Surg Clin North Am* 60:665-685, 1980.
7. Simon RR, Wolgin M: Subungual hematoma: association with occult laceration repair, *Am J Emerg Med* 5: 302-304, 1987.
8. Seaberg DC, Angelos WJ, Paris PM: Treatment of subungual hematomas with nail trephination, *Am J Emerg Med* 9:209-210, 1991.

9. Roser SE, Gellman H: Comparison of nail bed repair versus nail trephination for subungual hematomas in children, *J Hand Surg (Am)* 24A:1166-1170, 1999.
10. Giddins GE, Hill RA: Late diagnosis and treatment of crush injuries of the fingertip in children, *Injury* 29:447-450, 1998.
11. Louis D, Palmer A, Burney R: Open treatment of digital tip injuries, *JAMA* 244:697-698, 1980.
12. Douglas BS: Conservative management of guillotine amputation of the finger in children, *Aust Pediatr J* 8:86-89, 1972.
13. Fox JW, Golden GT, Rodeheaver G, et al: Nonoperative management of pulp amputation by occlusive dressings, *Am J Surg* 133:255-256, 1977.
14. Ipsen T, Frandsen PA, Barfred T: Conservative treatment of fingertip injuries, *Injury* 18:203-205, 1987.
15. Lamont RP, Cicero JJ, Frascione RJ, et al: Open treatment of fingertip amputations, *Ann Emerg Med* 12:358-360, 1983.
16. Young WA, Andrassy RJ: Conservative management of fingertip amputations in children, *Texas Med* 79:58-60, 1983.
17. Farrell RC, Disher WA, Nesland RS, et al: Conservative management of fingertip amputations, *J Am Coll Emerg Physicians* 6:243-246, 1977.
18. Holm A, Zachariae L: Fingertip lesions: an evaluation of conservative treatment versus free skin grafting, *Acta Orthop Scand* 45:382-392, 1974.
19. Chow S, Ho E: Open treatment of fingertip injuries in adults, *J Hand Surg (Am)* 7A:470-476, 1982.
20. Steinberg DR: Acute flexor tendon injuries, *Orthop Clin North Am* 23:125-141, 1992.
21. Tottenham VM: Effects of delayed therapeutic intervention following zone II flexor tendon repair, *J Hand Ther* 8:23-26, 1995.
22. Blair WF, Steyers CM: Extensor tendon injuries, *Orthop Clin North Am* 23:141-149, 1992.
23. McGeorge DD, Stillwell JH: Partial flexor tendon injuries: to repair or not (Abstract), *J Hand Surg (Br)* 17B:176, 1992.
24. Wray R, Weeks P: Treatment of partial tendon lacerations, *Hand* 12:163-166, 1980.
25. Siddiqui A, Benjamin CI, Schubert W: Incidence of neurapraxia in digital nerves, *J Reconstr Microsurg* 16:95-98, 2000.
26. Millesi H: Reappraisal of nerve repair, *Surg Clin North Am* 61:321-340, 1981.
27. Wyrick JD, Stern PJ: Secondary nerve reconstruction, *Hand Clin* 8:587-597, 1992.
28. Bell M: The changing pattern of pyogenic infections of the hand, *Hand* 8:298-302, 1976.
29. Eaton R, Butsch D: Antibiotic guidelines for hand infections, *Surg Gynecol Obstet* 130:119-121, 1970.
30. Kilgore ES, Brown LG, Newmeyer WL, et al: Treatment of felons, *Am J Surg* 130:194-197, 1975.
31. Vasilevski D, Noorbergen M, Depierreux M: High-pressure injection injuries to the hand, *Am J Emerg Med* 18:820-824, 2000.
32. Worlock P, Boland P, Darrell J, et al: The role of prophylactic antibiotics following hand injuries, *Br J Clin Pract* 34:290-292, 1980.
33. Zook EG, Guy R, Russell RC: A study of nail bed injuries, *J Hand Surg Am* 9A:247-252, 1984.
34. Sloan JP, Dove AF, Maheson AN, et al: Antibiotics in open fractures of the distal phalanx, *J Hand Surg (Br)* 12B:123-124, 1987.
35. Gilbert DN, Moellering RC Jr, Sande MA, editors: *Sanford guide to antimicrobial therapy*, 33rd edition, 2003, Antimicrobial Therapy Inc. Hyde Park, VT.
36. Edlich RF, Smith OT, Edgerton MT: Resistance of the surgical wound to antimicrobial prophylaxis and its mechanism of development, *Am J Surg* 126:583-586, 1973.

# Tissue Adhesives and Alternative Wound Closure

## TISSUE ADHESIVES

Adhesive Wound Closure Technique  
Adhesive Closure Aftercare  
Adhesive Runoff and Removal

## WOUND TAPING

Indications for Taping

Taping Technique

Tape Aftercare

## WOUND STAPLING

Indications for Stapling

Stapling Technique

Staple Aftercare

Of all the components of wound care and closure, the most important advances have been in closure materials and methods. Since the approval of tissue adhesives by the U.S. Food and Drug Administration in 1998, physicians have rapidly adopted tissue adhesives for laceration and surgical incision closure. Ease of application and comparable outcomes to standard closure techniques have facilitated their acceptance.

Over the years, the use of wound staples has become established and routine in wound care. Emergency physicians value staples because they are easy to apply, they save time, and they have good outcomes. Staples are particularly useful for scalp and truncal lacerations. After they were introduced in the 1980s, wound tapes commonly were used for straight lacerations and surgical incisions. Their use for lacerations has waned gradually over the years, and with the advent of adhesives, an alternative has become available.

## TISSUE ADHESIVES

Tissue adhesives are relatively new to wound and laceration closure in the United States; they were approved by the Food and Drug Administration in 1998. Since the 1980s, tissue adhesives have been used successfully in Europe, Canada, the Middle East, and Asia. These compounds derive from the cyanoacrylate adhesives used in common household super glues. Formulated for medical purposes, they are well tolerated, effective, and nontoxic.<sup>1</sup>

Until 1998, *n*-butylcyanoacrylate (Histo-Acryl Blue) was the most commonly used tissue adhesive worldwide.<sup>2</sup> In 1998, a new compound, octylcyanoacrylate (Dermabond), was released for general use.<sup>3</sup> Dermabond has many advantages over Histo-Acryl Blue. Dermabond contains a plasticizer that makes it flexible and useful for irregular or moving surfaces. Dermabond has a bacterial protection effect and a higher breaking strength. Finally, in contrast to Histo-Acryl Blue, Dermabond is packaged sterilely and can be stored at room temperature. In the United States, Dermabond is currently the tissue adhesive with the most desirable characteristics for wound care.

Dermabond can be used in many wounds and lacerations ordinarily closed with sutures, tapes, or staples. It is particularly effective for lacerations on the face. There are no

limits to laceration length, and it can be used over joints if properly splinted.<sup>4</sup> Dermabond is an improvement over sutures for closure of wounds of thin, aged, or corticosteroid-affected skin. If easy approximation can be achieved, Dermabond closes wounds with flaps and corners. Tissue adhesives are not used on mucous membranes or hair-bearing or weight-bearing areas. The following criteria can guide the decision to use tissue adhesives:

- Fresh lacerations, within “golden period”
- Laceration under low tension, easy to approximate
- Edges clean and even, close with no gaps
- Little or no blood oozing
- Adhesive runoff can be controlled or avoided

The cosmetic result of wounds closed with adhesives is indistinguishable from that of sutured wounds.<sup>1,5,6</sup> Investigators have followed wounds for 3 months and have used “blinded” observers who could not tell the difference between adhesive-closed wounds and sutured pediatric lacerations.<sup>5</sup> For reasons of convenience and patient comfort, parents prefer closure of their children’s lacerations with wound adhesives when asked to compare with previous experiences with standard suturing techniques.<sup>7</sup> It has been reported, however, that children occasionally pick off the glue with their fingers.<sup>8</sup> These wounds have been closed successfully with sutures as delayed primary closures. Finally, although not statistically significant, the infection rate for adhesive-closed wounds tends to be lower than that for sutured wounds, and under experimental conditions, adhesive-closed wounds resist contamination more than sutured wounds do.<sup>2</sup>

The most attractive features of wound adhesives are short wound closure time and no requirement for anesthesia. Wound closure time is approximately 20% to 50% of the time necessary for standard suturing.<sup>5,6,8</sup> Adhesives polymerize within seconds after application, and the wound needs manual support for only 30 to 60 seconds after application of the adhesive. Wounds closed with adhesives are at greater risk for breaking open immediately after closure than sutured wounds.<sup>2</sup> After 7 days, there is no difference, however, in tensile or bursting strength between adhesive-closed and sutured lacerations. Less technical expertise is required for adhesive closures, and patients do not have to return for suture removal.<sup>1,2</sup>

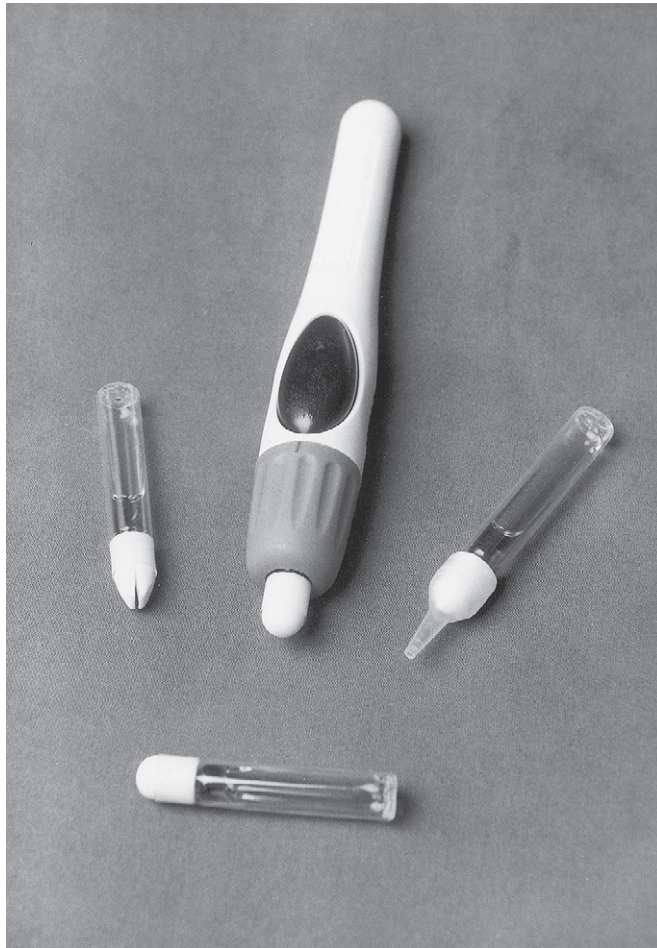
In emergency wound care, wound adhesives are restricted to skin surfaces, and care has to be taken to prevent penetration into the wound. Cyanoacrylates applied within tissue can cause acute inflammatory responses, giant cell reactions, inclusion body formation, and seromas.<sup>9</sup> Subcutaneously or within organs, they can remain in tissues for extended periods (>1 year).<sup>10</sup> Cyanoacrylates have accumulated an excellent and safe record for use in wound care.<sup>1,11</sup> In large amounts, cyanoacrylates generate exothermic heat that can cause pain. In wound care, small amounts of adhesive are applied externally, and the adhesives peel off after the wound is healed.

### Adhesive Wound Closure Technique

Dermabond comes in a sterile, plastic-covered glass vial with an applicator tip (Fig. 14-1). Until recently, there was only one choice of adhesive viscosity and applicator tip. Because of concerns with runoff of adhesive from wounds, a new, higher viscosity formulation has been introduced.<sup>12</sup> When compared with the low-viscosity formulation, the higher viscosity adhesive had significantly less runoff from the wound area. Otherwise the outcomes were comparable. The standard applicator tip is rounded and has a tendency to depress or invert the wound edges if excessive pressure is applied during application. A new, chisel tip is more versatile and allows for even application of adhesive without undue pressure on the wound edges to cause inversion. The procedure for application of adhesive is as follows (Fig. 14-2):

- After wound cleansing and any necessary débridement, any significant bleeding should be controlled. The wound does not have to be strictly dry, however, because polymerization occurs in the presence of a liquid, either water or blood.

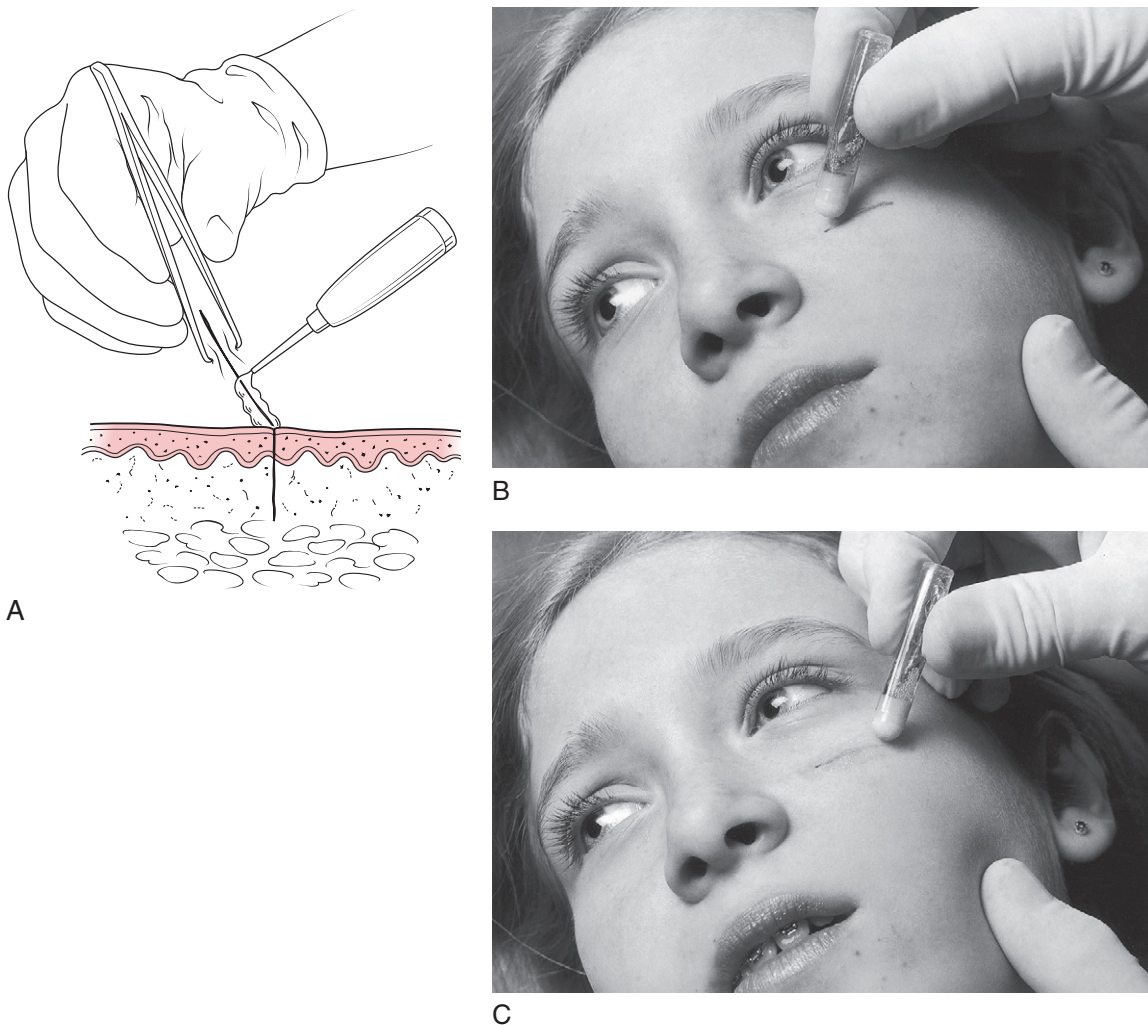




**Figure 14-1** Dermabond wound adhesive applicators: *Left*, Chisel tip. *Center*, ProPen. *Right*, Precision tip. *Foreground*, Original dome tip.

- The patient is placed in a position so that the wound is facing directly up, and adhesive runoff is prevented. It is advisable to have nearby or to hold a gauze sponge to mop excessive adhesive quickly. A rim of petrolatum ointment placed around the wound helps block runoff.
- When the patient is properly prepared and placed, the plastic Dermabond applicator is crushed and squeezed until adhesive covers the applicator tip.
- The wound is approximated gently with fingers or forceps. In some wounds, a second person can assist with wound edge approximation and excess adhesive removal.
- Adhesive is layered over the wound with a margin of 5 to 10 mm. Several strokes are applied until a discrete layer is formed. Finger or forceps approximation is maintained for 30 to 60 seconds to allow for polymerization. After 15 to 20 seconds, more adhesive can be applied. Two or three separate layers are recommended to complete the closure.

Histo-Acryl Blue is a combination of adhesive and blue dye. It is not as versatile as Dermabond and is recommended for short, straight lacerations. It comes in a container with



**Figure 14-2** Wound adhesive application technique. **A**, Wound edges are apposed with fingertips or forceps followed by application of adhesive. **B**, The applicator tip is drawn gently over the length of the wound. **C**, Three to four layers are applied to complete the closure.

an applicator tip but is applied more easily by cutting off the tip and replacing it with a 25G needle. Because of its consistency, Histo-Acryl Blue requires a different technique for application than does Dermabond. After the wound edges are approximated, small drops, "spot welds," are placed along the wound until it is closed. The wound has to be supported for 30 to 60 seconds to ensure proper polymerization.

### Adhesive Closure Aftercare

The patient is instructed to keep the wound clean and dry for 24 hours. After this period, gentle cleansing can be done with great care and caution so as not to disrupt the closure. If a wound dehisces, the patient is instructed to return so that delayed primary closure with wound tapes or sutures can be carried out. No follow-up is necessary for glue removal

because it peels off on its own or comes off with the natural sloughing of keratinized epidermis.

### Adhesive Runoff and Removal

Because adhesives are liquid, they can run off the wound area by accident or drip onto unwounded surfaces. Vulnerable areas include the eyes, nose, mouth, ears, and fingers. If possible, the runoff should be wiped up before drying. If polymerization occurs, petroleum ointment can be applied to accelerate breakdown and peeling. Antibiotic ointments can be used for this task. The most effective removal substance is acetone. Because it is toxic to delicate tissues, great care has to be taken around the eyes. Forceps also can be used when the adhesive is completely dry to flake it away gently.

---

## WOUND TAPING

There are several advantages to wound taping compared with suturing. Advantages include a reduced need for anesthesia, ease of application, even distribution of tension across the wound, no residual suture marks, application by nonphysician personnel, and the elimination of need for suture removal.<sup>13</sup> Tapes also have advantages in closing flap lacerations and have a greater resistance to wound infection than sutures.<sup>14,15</sup> Tapes do not work well on surfaces that are oily or hair bearing, joint surfaces, lax skin, gaping wounds under tension, or very young or uncooperative children.

A bewildering variety of wound tapes are currently on the market. Steri-Strips (3M, St. Paul, Minn.) are the best known; other brands include Shur-Strip, Cover-Strips, Suture-Strip, Clearon, Nichi-Strip, and Curi-Strip. The various brands have differing porosity, adhesion, flexibility, breaking strength, and elongation capability. An early study that compared Clearon and Steri-Strips showed a better overall performance by Steri-Strips.<sup>16</sup> In another comparison study of six tapes (Curi-Strip, Steri-Strips, Nichi-Strip, Cicagraf, Suture-Strip, and Suture-Strip Plus), an overall scoring method was devised to rank their performance under laboratory conditions.<sup>17</sup> The three highest ranking tapes were Nichi-Strip, Curi-Strip, and Steri-Strips. Under experimental conditions, tape closures resisted wound infection better than nylon sutures. Tapes also are well suited for supporting grafts and flaps.

### Indications for Taping

Wound taping can be considered under the following conditions:

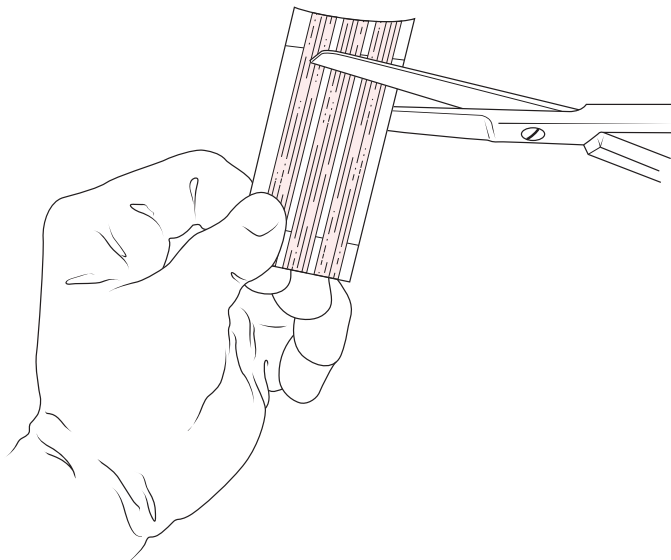
- Superficial, straight lacerations under little tension. Areas suitable for taping include the forehead, chin, malar eminence, thorax, and nonjoint areas of the extremities.
- Flaps in which sutures might compromise vascular perfusion at the wound edges.
- Lacerations with a greater-than-usual potential for infection.
- Lacerations in an elderly or steroid-dependent patient who has thin, fragile skin.
- Support for lacerations after suture removal.

Tapes do not work well on irregular wounds, wounds that cannot be made free of blood or secretions, intertriginous areas, scalp, and joint surfaces.

### Taping Technique

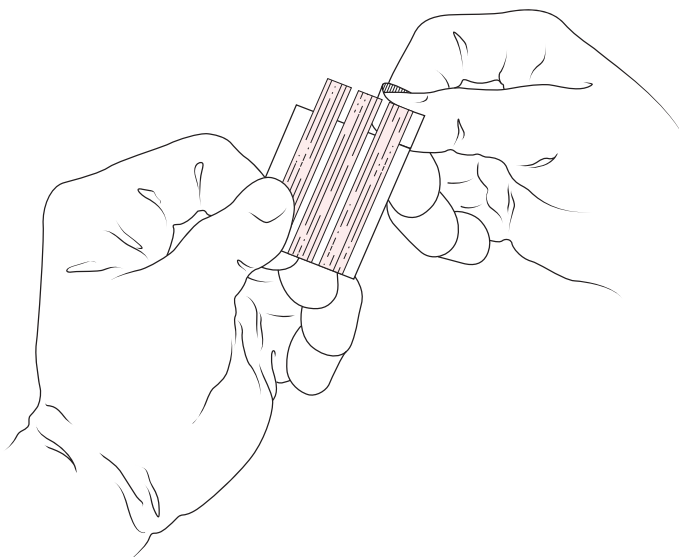
Most taping of emergency wounds can be done with 1/4-inch-wide tape of varying lengths. For wounds that are greater than 4 to 5 cm in length, 1/2-inch width is preferable. The following steps are carried out:

- The wound is cleansed, irrigated, and débrided if necessary. Hemostasis has to be complete and the skin surface completely dried.
- Benzoin is applied to the surrounding skin to increase adhesion. Care is taken not to spill this agent into the wound. It is left to dry until it becomes tacky.

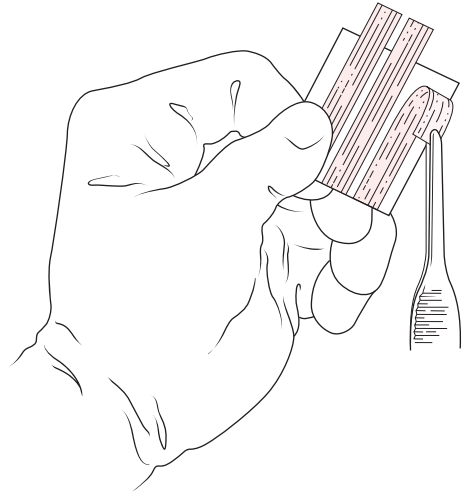


**Figure 14-3** The tapes are cut to the desired length.

- Tapes are cut to the length desired while they are still on the backing sheet. Usually 2 to 3 cm of overlap is allowed for each side of the wound (Fig. 14-3).
- One of the perforated end tabs is gently removed to prevent deforming of the tape ends (Fig. 14-4).
- Individual tapes are removed from the backing with forceps by pulling directly away from the backing (Fig. 14-5).

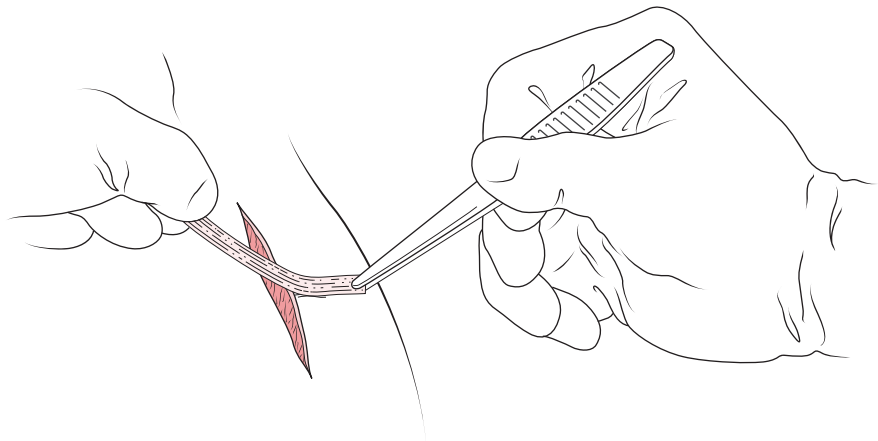


**Figure 14-4** The perforated end tab is gently removed to prevent deforming of the tape ends.

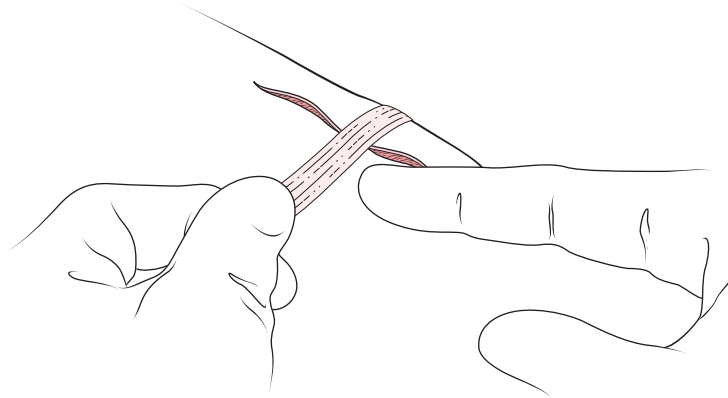


**Figure 14-5** Individual tapes are removed with forceps.

- One half of the tape is securely placed on one side of the midportion of the wound and held securely. The opposite wound edge is apposed with a finger of the opposite hand (Fig. 14-6). After edge apposition, the tape is completely secured (Fig. 14-7).
- Further tapes are placed evenly adjacent to the original midwound tape (Fig. 14-8). This process is repeated with further tapes until the wound edges are completely apposed (Fig. 14-9). Wound tapes should have a gap between them that is at least 2 to 3 mm wide. Complete occlusion of the wound by tapes can cause normal wound seepage to dissect under the tapes and lead to premature removal.
- The final step is to place cross stays to prevent elevation of the tape ends and minor skin blistering caused by tension of the tape ends (Fig. 14-10).



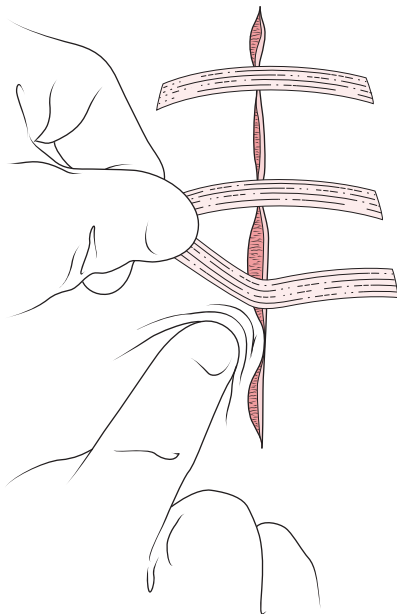
**Figure 14-6** The tape is firmly secured on one side of the wound.



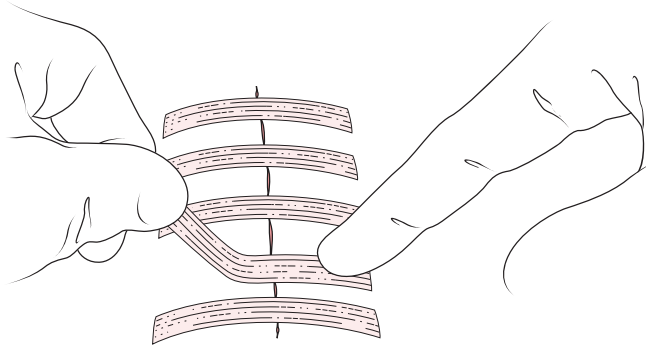
**Figure 14-7** The tape is brought over the wound after the wound is apposed with the finger of the opposite hand.

### Tape Aftercare

Tapes are maintained in place for at least as long as sutures would be for the anatomic area in question. In contrast to a sutured wound, a taped wound cannot be washed or moistened because premature tape removal can lead to wound dehiscence. Tapes should never be wrapped around a digit in a circumferential manner because they are not expandable and can act as a constricting band.



**Figure 14-8** Further tapes are placed in a similar manner.

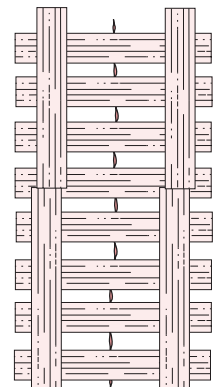


**Figure 14-9** Enough tapes are placed so that wound gaping does not occur. Usually there is 2 to 3 mm between tapes.

## WOUND STAPLING

Since the introduction of automatic skin-stapling devices, there has been a reluctance to use them beyond their intended purpose of closing surgically made incisions. Despite the remarkable amount of time saved by placing staples instead of sutures, early animal and clinical investigations questioned whether staples could appose wound edges accurately or promote wound tensile strength as effectively as sutures.<sup>18</sup> Studies in animals have suggested, however, that wound tensile strength is actually greater for staples compared with sutures.<sup>19,20</sup> In addition, less wound inflammatory response has been noted with staples, and they resist infection more effectively than sutures.

Clinical studies of staple use in traumatic lacerations showed that compared with standard suturing methods, the ultimate cosmetic result as judged by blinded observers is no different.<sup>21,22</sup> In these studies, body regions that were chosen for the comparisons included the scalp, neck, arm/forearm, trunk, buttocks, and legs. Adult and pediatric age groups were studied. The time required for staple closure was approximately four to five times less than that required for suture placement. Cost has been cited as a drawback to the use of staples; however, the time saved by a busy physician and the reduced need for wound closure instruments balances that factor.<sup>23</sup> Patients seem to tolerate staples well while they are in place; however, there does seem to be increased discomfort on removal compared with sutures.<sup>19</sup>



**Figure 14-10** Cross stays are placed over the tape ends to prevent skin blistering and premature removal.

### Indications for Stapling

Wound stapling can be recommended under the following circumstances:


- Linear, sharp (shearing mechanism) lacerations of the scalp, trunk, and extremities. Although they have been used in hand lacerations, experience is not extensive enough to recommend staples confidently for that area. Stapling similarly is avoided for facial wounds.
- Temporary, rapid closure of extensive superficial lacerations in patients requiring immediate surgery for life-threatening trauma.

Staples are avoided in anatomic areas to be studied by computed tomography or magnetic resonance imaging. Staples can produce streak artifact on a computed tomography scan, but in critical circumstances, clinically useful scans can be obtained despite their presence. Staples can move with magnetic resonance imaging and should not be placed if a study is anticipated.

### Stapling Technique

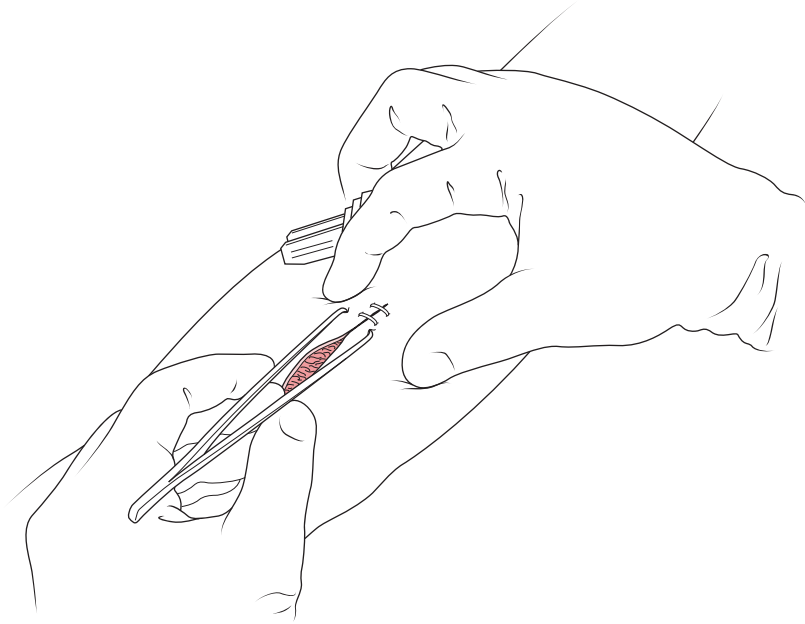
Stapling devices have evolved significantly, and many products are available. The Reflex One is representative of a multiple-staple device (35 staples per cartridge) with a wide staple that closes into a rectangular configuration (Fig. 14-11). This stapler commonly is used for surgical incisions or long lacerations of the trunk or extremity. The Precise Ten Shot stapler holds 10 staples that close into a smaller arcuate configuration. This device is useful for shorter, traumatically induced lacerations that might require greater precision and control. In addition to the stapler, the equipment required includes basic wound care instruments and standard anesthetic agents. The following steps are followed to insert staples:

- Forceps are used to evert the wound edges before placement of each staple (Fig. 14-12). When possible, a second operator can be helpful in everting the edges while the primary operator uses the stapler.
- Before triggering, the stapler should be placed gently on the skin over the wound without indenting the skin (Fig. 14-13).

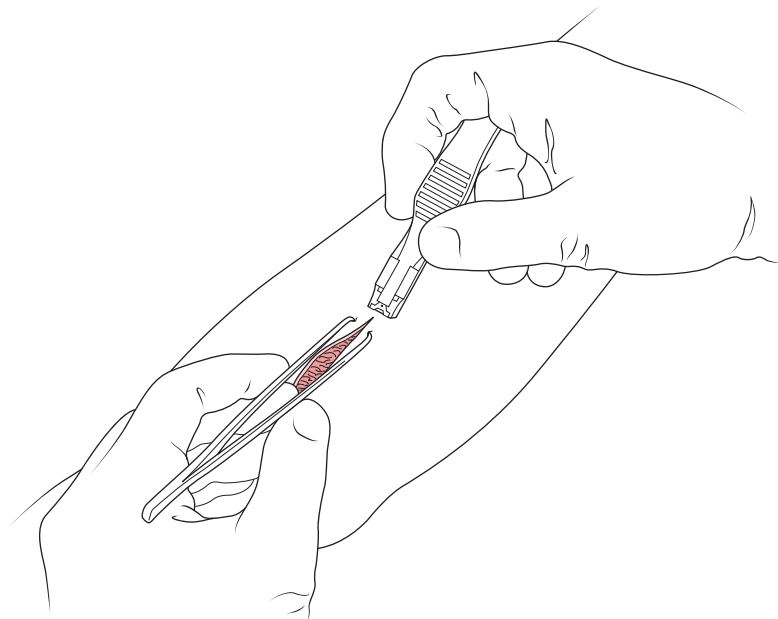


**Figure 14-11** Examples of wound stapling devices.

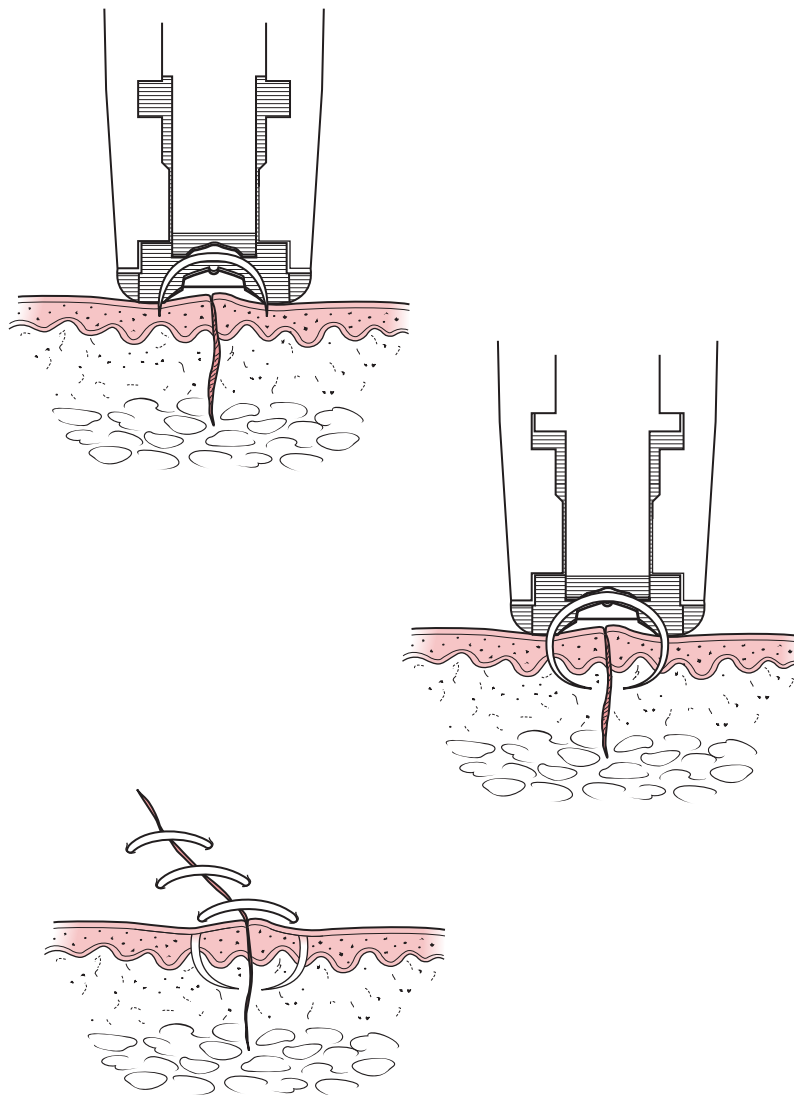




**Figure 14-12** Forceps are used to approximate and evert wound edges during stapling.

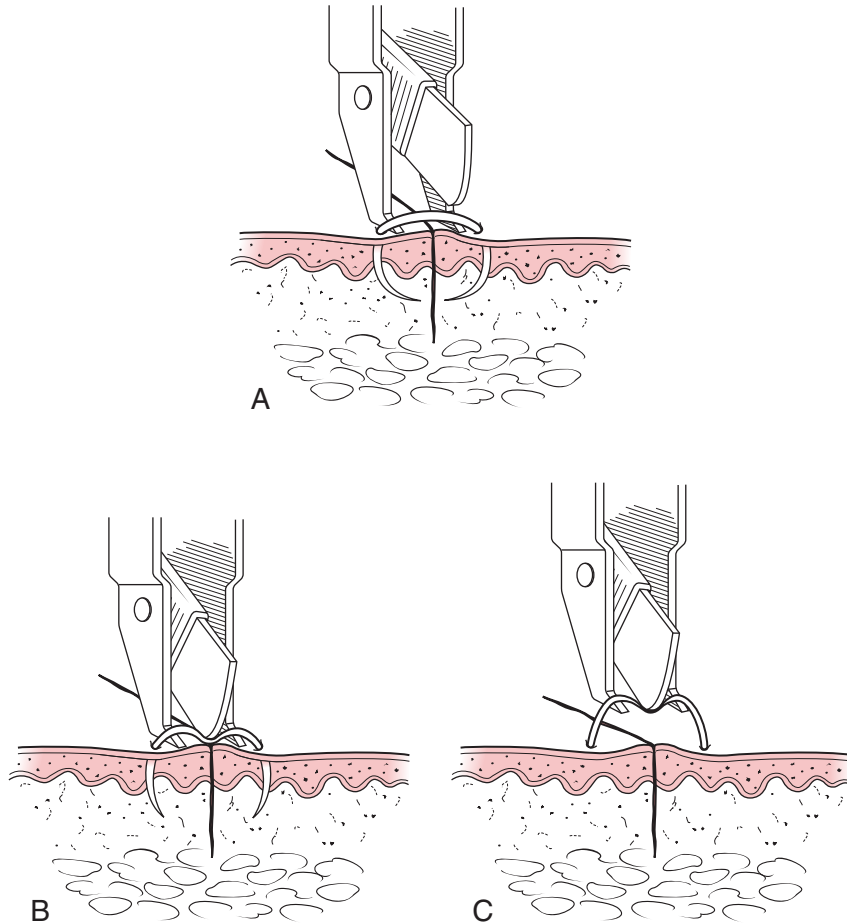


**Figure 14-13** During stapling, the stapler is placed gently on the skin before triggering. Indenting the skin with too much pressure causes staples to be placed too deep.



**Figure 14-14** During triggering, the staple is reconfigured to approximate wound edges.

- The trigger, or handle, is squeezed gently and evenly to advance the staple into the tissue (Fig. 14-14).
- When the staple is placed, a space should be visible between it and skin. A common mistake in placing staples is to apply excessive downward pressure, causing the staples to seat deep in the wound.
- Because of the configuration of the bending mechanism of the stapler, when the staple is seated, the stapler has to be “backed out” of the staple loop to disengage it.



**Figure 14-15** The following procedure is used to remove staples. **A**, The lower jaws of the staple-removing device are positioned under the staple crossbar. **B**, The upper jaw is used to compress the staple gently. **C**, When complete compression has taken place, the staple has been reconfigured for easy, gentle withdrawal.

### Staple Aftercare

Staples are kept in place for the same length of time as are sutures in similar anatomic sites. Staple removal requires a special device that is provided by each manufacturer. The lower jaw is placed under the crossbar of the staple, and the upper jaw is closed to open the loop of the staple (Fig. 14-15).

### REFERENCES

1. Farion KJ, Osmond MH, Harting L, et al: Tissue adhesives for traumatic lacerations: a systematic review of randomized controlled trials, *Acad Emerg Med* 10:110-118, 2003.
2. Noordzij JP, Foresman PA, Rodeheaver GT, et al: Tissue adhesive wound repair revisited, *J Emerg Med* 12: 645-649, 1994.

3. Switzer EF, Dinsmore RC, North JH Jr: Subcuticular closure versus Dermabond: a prospective randomized trial, *Am Surg* 69:434-436, 2003.
4. Saxena AK, Willital GH: Octylcyanoacrylate tissue adhesive in the repair of pediatric extremity lacerations, *Am Surg* 65:470-472, 1999.
5. Quinn JV, Drzewiecki A, Li MM, et al: A randomized, controlled trial comparing a tissue adhesive with suturing in the repair of pediatric facial lacerations, *Ann Emerg Med* 22:1130-1135, 1993.
6. Yaron M, Halperin M, Huffer W, Cairns C: Efficacy of tissue glue for laceration repair in an animal model, *Acad Emerg Med* 2:259-263, 1995.
7. Bruns TB, McLario DJ, Simon HK, et al: Laceration repair using a tissue adhesive in a children's emergency department (Abstract), *Acad Emerg Med* 2:427, 1995.
8. Watson DP: Use of cyanoacrylate tissue adhesive for closing facial lacerations in children, *BMJ* 299:1014, 1989.
9. Toriumi DM, Raslan WF, Friedman M, Tardy ME: Histotoxicity of cyanoacrylate tissue adhesives, *Arch Otolaryngol Head Neck Surg* 116:546-550, 1990.
10. Ellis DAF, Shaikh A: The ideal tissue adhesive in facial plastic and reconstructive surgery, *J Otolaryngol* 19:68-72, 1990.
11. Toriumi DM, O'Grady K: Surgical tissue adhesives in otolaryngology—head and neck surgery, *Otolaryngol Clin North Am* 27:203-209, 1994.
12. Singer AJ, Giordano P, Fitch JL, et al: Evaluation of a new high-viscosity octylcyanoacrylate tissue adhesive for laceration repair: a randomized, clinical trial, *Acad Emerg Med* 10:1134-1137, 2003.
13. Trott AT: Alternative methods of wound closure: wound staples. In Roberts JR, Hedges JR, editors: *Clinical procedures in emergency medicine*, Philadelphia, 1985, WB Saunders.
14. Conolly WB, Hunt TK, Zederfeldt B, et al: Clinical comparison of surgical wounds closed by suture and adhesive tapes, *Am J Surg* 117:318-322, 1969.
15. Efron G, Ger R: Use of surgical adhesive tape (Steri-Strip) to secure skin graft on digits, *Am J Surg* 116:474, 1968.
16. Koehn GG: A comparison of the duration of adhesion of Steri-Strips and Clearon, *Cutis* 26:620-621, 1980.
17. Rodeheaver GT, Spengler MD, Edlich RF: Performance of new wound closure tapes, *J Emerg Med* 5:451-462, 1987.
18. Harrison ID, Williams DF, Cuschieri A: The effect of metal clips on the tensile properties of healing skin wounds, *Br J Surg* 62:945-949, 1975.
19. Roth JH, Windle BH: Staple versus suture closure of skin incisions in a pig model, *Can J Surg* 31:19, 1988.
20. Windle BH, Roth JH: Comparison of staple-closed and sutured skin incisions in a pig model, *Surg Forum* 35:546-550, 1984.
21. Dunmire SM, Yealy DM, Karasic R: Staples versus sutures for wound closure in the pediatric population (Abstract), *Ann Emerg Med* 18:448, 1989.
22. George TK, Simpson DC: Skin wound closure with staples in the accident and emergency department, *J R Coll Surg Edinb* 30:54-56, 1985.
23. Harvey CF, Hume Logan CJ: A prospective trial of skin staples and sutures in skin closure, *Ir J Med Surg* 155:194-196, 1986.

# Bite Wounds

## ANIMAL BITE EPIDEMIOLOGY

## MICROBIOLOGY OF BITE WOUNDS

## BITE RISK FACTORS

Location

Type of Wound

Patient Risk Factors

Biting Species

## GENERAL BITE WOUND MANAGEMENT

## SPECIFIC INJURIES

Dog Bites

Cat Bites

Human Bites

Rat Bites

Fish Bites

## WOUND AFTERCARE AND FOLLOW-UP

## RABIES EXPOSURE AND PROPHYLAXIS

Animal Identification

Type of Exposure

Timing of Postexposure Prophylaxis

Immunosuppression and Pregnancy

## POSTEXPOSURE PROPHYLAXIS

Postexposure Therapy of Previously

Vaccinated Bite Victims

**A**nimal and human bites are common wounds managed by emergency caregivers. Bites can be from a multitude of sources, but most are caused by dogs, cats, and humans.<sup>1,2</sup> Despite apparently similar mechanisms of injury, each type of bite has different clinical, microbiologic, and treatment considerations that affect the management of bite wound patients. With animal bites, there is also the possibility of secondary systemic infectious complications, the most important of which is rabies. It is the responsibility of any person caring for an animal bite victim to investigate thoroughly the biting circumstances and make an appropriate decision about whether to administer rabies prophylaxis.

## ANIMAL BITE EPIDEMIOLOGY

It is estimated that 500,000 to 2 million animal bites occur in the United States each year, most of which are unreported.<sup>1,2</sup> Dog bites predominate, accounting for approximately 80% of all animal bites.<sup>3</sup> Of reported bites, 5% to 15% are caused by cats.<sup>4</sup> The occurrence of human bites varies according to the reporting institution with a range of 3.6% to 23%.<sup>1,5,6</sup> Urban emergency departments treat a greater proportion of human bite victims than community emergency departments.<sup>1</sup> Other animals, such as rodents, monkeys, large mammals, and marine animals, account for a small number of bite wounds.

Bite injuries are more likely to occur in children, with a peak incidence between ages 5 and 14 years.<sup>7</sup> Dog bites are more common in boys; cat bites and scratches are seen more often in girls.<sup>2,7</sup> Most of the attacking animals are known to the victim and can be easily traced. Wild or possibly untraceable animals are involved in about 3% to 15% of bite incidents.<sup>2,8</sup>

The ability to find, investigate, and quarantine the animal makes the decision to administer rabies prophylaxis to a patient much easier.

---

## MICROBIOLOGY OF BITE WOUNDS

The microbiology of bite wounds can be bewildering. Microorganisms belonging to 30 different genera have been cultured from a dog's mouth.<sup>9</sup> A large variety of microorganisms can be cultured from a normal cat mouth as well.<sup>10</sup> Clinical studies have shown, however, that there is little correlation between these potentially contaminating organisms and the ones that actually cause a wound infection.<sup>11-13</sup>

Identification of organisms cultured from actual bite wound infections provides more useful information and predictive value with regard to prophylactic antibiotic choices than cultures of noninfected wounds. The number of species of bacteria that is implicated in true infections, although extensive, is much smaller than the total number of species that can be identified in an animal's mouth.<sup>14</sup>

For dogs and cats, the most infecting bacteria are from the *Pasteurella* species. In dogs, 50% of infected wounds grow *Pasteurella canis*.<sup>4</sup> *Pasteurella multocida* and *Pasteurella septica* can be found in 75% of cat bites. The most common aerobic isolates include *Staphylococcus*, *Streptococcus*, *Moraxella*, and *Neisseria*. *Fusobacterium*, *Bacteroides*, and *Prevotella* are the most frequent anaerobes. At least 50% of these infections are mixed aerobic and anaerobic.

A rare but potentially fatal dog bite infection is caused by *Capnocytophaga canimorsus* (Centers for Disease Control and Prevention group DF-2).<sup>14</sup> It is a gram-negative rod that has been isolated from dogs and cats, although infection from cats is rare. Patients susceptible to this infection often have predisposing factors, such as asplenia, immunosuppression, or chronic disabling diseases.

The microbiology of human bites differs from that of cat and dog bites and is more complex. Aerobic organisms recovered from human bite infections include *Streptococcus* ( $\alpha$ ,  $\beta$ , hemolytic), *Staphylococcus* (*S. aureus*, *S. epidermidis*), and *Corynebacterium*. *Eikenella corrodens* has been recovered from 29% of human bites, including 25% of all clenched-fist injuries.<sup>15-17</sup> *E. corrodens* is a particularly virulent organism that can result in serious, chronic, and indolent infections. Human bite infections in hospitalized or institutionalized patients often are caused by gram-negative organisms, such as *Escherichia coli*, *Proteus*, and *Pseudomonas*.

Infectious complications of human bites also can derive from viruses and other organisms.<sup>1</sup> Viruses transmitted through human bites include hepatitis B and C and herpesvirus types 1 and 2. *Mycobacterium tuberculosis* and *Treponema pallidum* have been reported to be transmitted through human bites. To date, although it is biologically possible, no case of human immunodeficiency virus infection has been reported from transmittal through a human bite.<sup>1</sup>

---

## BITE RISK FACTORS

In an excellent review, Callaham<sup>12</sup> listed the important risk factors that are predictive of bite wound complications. These factors can influence the choice of wound management strategies, such as the decision to close the wound with sutures or to use prophylactic antibiotics.<sup>12,18</sup> Recommendations for specific biting species are made in subsequent sections; however, all bites should be considered in the context of the risk factors listed by Callaham (Box 15-1).<sup>12</sup>

### Location

Approximately 75% of animal bites occur on the extremities.<sup>2,11</sup> In children, however, especially children younger than 9 years old, the predominant injury area is the face and head.<sup>11</sup>

## BOX 15-1

**Animal Bite Risk Factors****High Risk**

## Location

Hand, wrist, or foot

Scalp or face in infants (high risk of cranial perforation; skull x-ray examination mandatory)

Over a major joint (possibility of perforation)

Through-and-through bite of cheek

## Type of wound

Punctures (impossible to irrigate)

Tissue crushing that cannot be débrided (typical of herbivores, such as cows and horses)

Carnivore bite over vital structure (artery, nerve, joint)

## Patient

Older than 50 years

Asplenic

Chronic alcoholic

Altered immune status (chemotherapy, acquired immunodeficiency syndrome, immune defect)

Diabetic

Peripheral vascular insufficiency

Chronic corticosteroid therapy

Prosthetic or diseased cardiac valve (consider systemic prophylaxis)

Prosthetic or seriously diseased joint (consider systemic prophylaxis)

## Species

Domestic cat

Large cat (canine teeth produce deep punctures that can penetrate joints, cranium)

Human (hand wounds only, particularly with delayed medical care)

Primates (anecdotal evidence only)

Pigs (anecdotal evidence only)

**Low Risk**

## Location

Face, scalp, ears, and mouth (all facial wounds should be sutured)

Self-bite of buccal mucosa that does not go through to skin

## Type of wound

Large clean lacerations that can be thoroughly cleansed (the larger the laceration, the lower the infection rate)

Partial-thickness lacerations and abrasions

## Species

Rodents

From Callahan ML, French SP: Bites and injuries inflicted by mammals. In Auerbach P, editor: Wilderness medicine: management of wilderness and environmental emergencies, 3rd edition, St. Louis, 1995, Mosby.

When children are examined, the risk of skull penetration has to be considered. The location of the bite is important because there is a significant difference in the rate of infection per site. The hand seems to be at highest risk, with an incidence of infection in dog bites reported in one study to be 30%.<sup>12</sup> The most resistant anatomic location is the face, which has an infection rate of 1.4% to 5.8%.<sup>11,19</sup>

All human bites to the hand are considered serious injuries. Approximately 3.6% of all bite injuries are caused by humans, with 61.2% of the bites being inflicted on the hand and upper extremity.<sup>20</sup> The hand is a complex anatomic structure with a high density of movable structures enclosed in limited tunnels and spaces. The hand does not tolerate infection well and can be devastated easily by trivial injuries that introduce small inocula of bacteria.<sup>21,22</sup> When the hand comes into contact with the human mouth in a violent manner, it is exposed to a tremendous variety of pathogenic bacteria in high concentrations.<sup>23</sup>

### Type of Wound

The mechanism of injury from an animal bite or attack plays an important role in predicting the chance of infection and the choice of management technique. All animal bites are to be considered contaminated with potentially pathogenic bacteria. These injuries frequently are associated with crushing, tearing, and avulsion forces and devitalized tissue. The combination of bacterial contamination with accompanying devitalized skin and fascia creates a setting ripe for the establishment of infection.

At high risk for becoming infected is the puncture wound caused by fangs.<sup>8,11,24</sup> Slender cat fangs are particularly treacherous because they can be driven deep into tissue and deliver an infectious inoculum of bacteria through the small entry site. These wounds are difficult to cleanse, irrigate, and débride adequately and are considered at greater risk for infection. Large open wounds are less likely to develop this complication. Superficial, laceration-like wounds, without devitalized tissue, carry a low rate of infection regardless of the species.

Most bites are occlusional. The hand is subject to another type of bite wound, however: the clenched-fist injury. A fist struck against the mouth can drive teeth into the lightly padded knuckles. Tendons and their sheaths and underlying joints are particularly vulnerable. Suppurative complications are common, and violation to tendon, bone, or joint has been reported in 75% of cases.<sup>23</sup> These injuries require aggressive intervention with exploration, irrigation, débridement, and early parenteral antibiotic administration. Care is best carried out in consultation with a specialist.

### Patient Risk Factors

Any of the patient conditions listed in Box 15-1 require serious consideration for antibiotic prophylaxis despite little investigational support for their use.<sup>18</sup>

### Biting Species

The overall infection rate of dog and cat bites varies considerably. Of dog bites, 4% to 10% become infected.<sup>2,7,25</sup> Sutured dog bites of the face have been reported to become infected in only 1.4% of cases.<sup>19</sup> Of cat bites, 17% to 50% become infected.<sup>2,7,26</sup> Cat scratches also have been thought to carry an increased rate of infection, but an investigation of 14 claw injuries reported no infections.<sup>26</sup>

Because of the preantibiotic era necessity of performing frequent amputations or resultant severe disability, human bites retain a bad reputation among clinicians.<sup>21</sup> Simple occlusional human bites, not on the hand, have an infection rate not much higher than common lacerations and dog bites.<sup>14,27</sup> The overall incidence of infection has been reported to be approximately 17% (range 10% to 50%).<sup>8,12,27,28</sup> One investigator reported the incidence of infection after human bites to the face to be 2.5%.<sup>29</sup> Original investigations appeared to have been biased by how much time had elapsed before treatment was administered.<sup>5,23</sup> This factor would skew the findings toward a higher infection rate. The face and ear, probably because they have a rich vascularity, have a higher innate resistance to infection and tend to become infected less often.<sup>30,31</sup>



## GENERAL BITE WOUND MANAGEMENT

Wound management depends on the type of wound, its severity, and its anatomic location. Simple contusions and superficial bite abrasions, in which no obvious skin puncture, laceration, or avulsion is present, can be treated by thorough cleansing alone. Despite the relatively minor appearance of many of these wounds, the patient still is at risk for developing rabies, and this possibility has to be addressed. For larger wounds that violate the epidermis and dermis, standard wound care techniques are carried out, as follows:

- Povidone-iodine is the wound cleansing solution recommended for periphery cleansing. The standard 10% solution is diluted 10:1 to 20:1 with saline and can serve as the cleansing agent and the irrigant.
- After thorough scrubbing of the wound periphery, copious high-pressure irrigation is the next step, using a 19G needle, catheter, or splash shield attached to a 20-mL or 35-mL syringe. Delivering diluted povidone-iodine solution directly into the wound enhances its microbicidal action.
- Débridement of all devitalized tissue and wound edges is essential for reducing the possibility of wound infection. Irrigation after débridement is recommended because it provides greater exposure of the wound. Retrospective and prospective studies have shown that wound infection is reduced significantly after débridement.<sup>11,12,32</sup>
- For fang wounds, particularly slender cat teeth wounds, there is often minimal devitalization of the skin. Edge débridement might not be necessary. The problem of adequate wound cleansing remains, however. To facilitate effective irrigation, after local infiltration of anesthesia, the entry site can be widened with a simple 1- to 1.5-cm incision across the puncture with a no. 15 knife blade (Fig. 15-1). The new wound is retracted open with a hemostat or forceps to permit irrigation. These incisions are left to close without sutures. If the edges are devitalized, they should be trimmed back to viable skin.
- Purulence or suspected infection is cultured.
- Radiographs are obtained when fracture or joint penetration is suspected.
- Proper tetanus immunization is ensured.
- Assessment and treatment for rabies exposure are carried out if necessary.

## SPECIFIC INJURIES

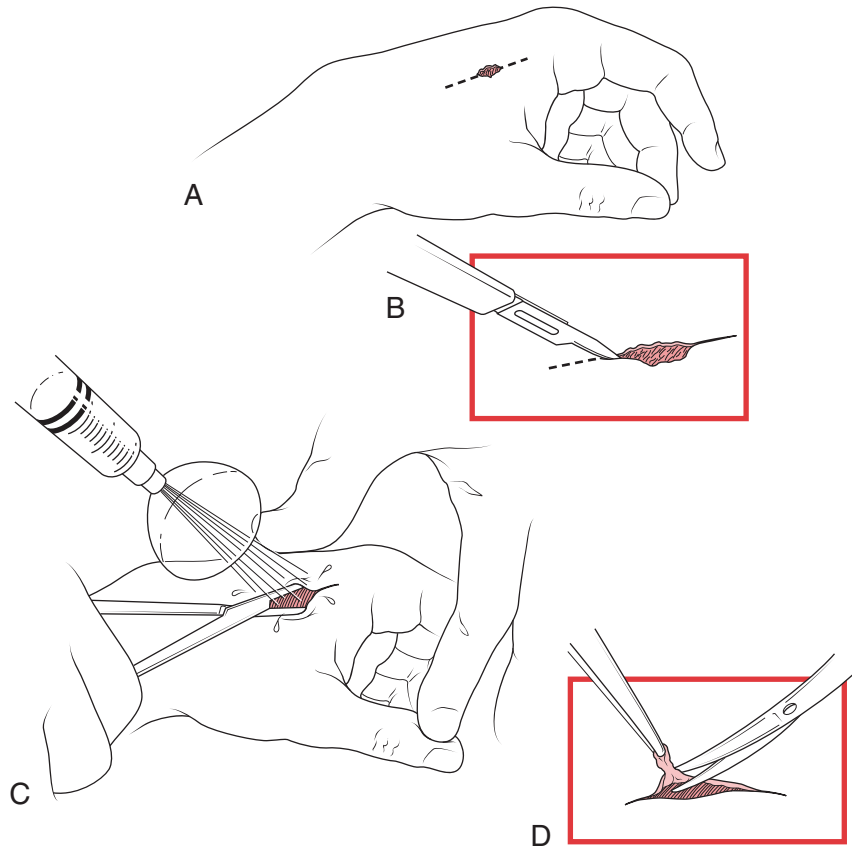
### Dog Bites

#### Suturing

The issue of whether to suture dog bite wounds is controversial. Investigational data and the author's personal experience support the practice of primary suture closure of low-risk dog bite wounds.<sup>11,12,19,33,34</sup> Suturing is not recommended, however, for wounds more than 8 to 12 hours old, fang (puncture) wounds, hand lacerations, or wounds that are high risk (see Box 15-1).<sup>13</sup> When contraindications to closure exist, delayed primary closure (tertiary union) or open closure (secondary union) can be considered. Because of the cosmetic concerns associated with facial bites and a low potential for infection, suturing, even after 8 to 12 hours, can be considered.<sup>19</sup> Consultation with a specialist is recommended to assist in the decision. Whenever primary closure of any dog bite is carried out, deep closures are avoided to minimize the potential for infection.<sup>13</sup>

#### Antibiotics

The use of antibiotics for dog bite wounds is one of the most controversial topics in emergency medicine.<sup>35</sup> This controversy is fueled by the lack of large, definitive, controlled



**Figure 15-1** Fang wound management. **A**, A fang wound with a suggested line of incision to open the wound for effective irrigation and débridement. **B**, A small 1- to 1.5-cm incision can be made with a scalpel and no. 15 blade. **C**, When incised, the wound can be exposed with forceps and copiously irrigated. **D**, The incision also facilitates wound edge débridement if devitalization or excessive contamination is present.

clinical trials without methodologic errors. In a review of the available trials of prophylactic antibiotics for mammalian bites, there was no evidence that antibiotics were effective for dog or cat bites.<sup>36</sup>

One fact is clear: Antibiotics are still no substitute for careful and thorough wound cleansing, irrigation, and débridement. The choice of agents also is complicated by the myriad potentially infecting organisms, conflicting results from *in vivo* clinical studies versus *in vitro* sensitivity studies, and the difference between serum antibiotic levels versus tissue levels. The following recommendations are based on current knowledge and the author's experience. Table 15-1 summarizes these recommendations.

**Established dog bite infection.** For wounds with signs of infection (i.e., purulence, redness, heat, tenderness, and lymphangitis), the initial empirical dose of intravenous antibiotics should be broad spectrum.<sup>14</sup> Ampicillin/sulbactam (Unasyn) provides coverage for the most likely infecting organisms. If a patient requires admission to the hospital, this agent can be

TABLE 15–1 Bite Wound Antibiotic Recommendations for Dog, Cat, and Human Bites

Established Infections—Intravenous	Prophylaxis—Oral
Ampicillin/sulbactam	Ampicillin/clavulanate
Cefoxitin	Penicillin plus cephalexin
Ceftriaxone	Cefuroxime
Trovafloxacin	Trovafloxacin
Clindamycin plus fluoroquinolone	Clindamycin plus fluoroquinolone

## Notes:

1. *Pasteurella multocida* is resistant to single antibiotics dicloxacillin, cephalexin, clindamycin, and erythromycin.
2. *Eikenella* is resistant to single antibiotics dicloxacillin, first-generation cephalosporins, clindamycin, and erythromycin.
3. In  $\beta$ -lactam-allergic children, clindamycin plus trimethoprim/sulfamethoxazole can be used.

continued until wound culture results are available to determine further therapy. If the patient can be treated as an outpatient, oral ampicillin/clavulanate (Augmentin) can be used after the initial parenteral ampicillin/sulbactam. Culture results can guide outpatient therapy as well. Total treatment time is approximately 10 to 14 days; however, the patient is recommended to return in 48 to 72 hours for assessment of treatment effectiveness.

Alternative intravenous antibiotics include cefoxitin (Mefoxin), cefuroxime (Zinacef), and ceftriaxone (Rocephin). All have varying but adequate empirical coverage for *P. multocida*, *S. aureus*, *Streptococcus*, and anaerobes. For patients with major allergic responses to penicillin or allergies to cephalosporins, no single intravenous agent adequately covers all pathogens. Under these constraints, therapy for adults can be initiated with a combination of clindamycin (Cleocin) and ciprofloxacin (Cipro) until culture results are available. Because ciprofloxacin is not recommended for children, clindamycin plus trimethoprim/sulfamethoxazole (Bactrim, Septra) can be used.

**Dog bite prophylaxis.** The most controversial area of dog bite management is the use of prophylactic antibiotics for noninfected-appearing wounds.<sup>30</sup> The preponderance of evidence is that antibiotics do not reduce the infection rate in low-risk dog bite wounds.<sup>11,37-39</sup> Meta-analyses and systematic reviews of available controlled trials found, however, that prophylactic antibiotics were beneficial in high-risk settings.<sup>36,40</sup> The high-risk setting for which there is the best evidence for prophylactic effect of antibiotics is for noninfected-appearing hand wounds.<sup>11,33,36</sup>

Based on the potentially infecting organisms, ampicillin/clavulanate provides good coverage in this setting. Alternatives include penicillin plus cephalexin, levofloxacin, or clindamycin plus a fluoroquinolone. For children, trimethoprim/sulfamethoxazole alone or in combination with clindamycin is a reasonable alternative.

## Cat Bites

### Suturing

Unless tissue coverage and cosmesis are important considerations, cat bite and scratch wounds are probably best left open and not sutured. Cat fangs can penetrate deeply into the soft tissues, and because the infection potential of these wounds is great, the most judicious course of action is to cleanse, irrigate, and débride the wound and leave it open.<sup>41</sup> Another option is to open the wound with a simple incision as described previously in the section on bite wound management. Exceptions to this recommendation include large, easily cleansed

lacerations that are not on the hand or foot. Most lacerations of the face are protected by the good vascular supply of the face. Whenever suturing is chosen, only percutaneous non-absorbable sutures are used. Deep closures are avoided because of the increased risk of infection.

### Antibiotics

Although cat bites are less common than dog bites, the rate of infection is significantly higher than for dog bites.<sup>8,42</sup> Because the hand is a frequent site of injury, and cats have sharp, slender teeth, the risk for infection is greater. *P. multocida* is found more commonly in a higher proportion of cat bite wounds than in dog bite wounds.<sup>1</sup>

**Established cat bite infections.** For initial empirical therapy, as with dog bites, an intravenous dose of ampicillin/sulbactam can be delivered in the emergency department. This agent can be continued during inpatient admission until culture results are known. For outpatient treatment, ampicillin/clavulanate can be prescribed for a full course of 10 to 14 days. This course can be modified with culture results and reviewed at the recommended 48- to 72-hour return visit.

Infection with *P. multocida* is often characteristic with onset of symptoms within 24 hours of the bite, prominent pain and swelling, and a serosanguine and grayish exudate.<sup>43</sup> Because of this organism's exquisite sensitivity to penicillin, penicillin can be initiated parenterally in the emergency department and continued during admission. Alternative intravenous antibiotics include cefoxitin and ceftriaxone. For adult patients with major allergies to penicillin or cephalosporins, clindamycin plus a fluoroquinolone can be given. For children, trimethoprim/sulfamethoxazole with or without clindamycin can be used.

**Cat bite prophylaxis.** Prophylaxis for uninfected-appearing cat bites is less controversial than prophylaxis for dog bites.<sup>8,33,42</sup> Most cat bites, unless they are minor scratches or limited to the superficial dermis, are candidates for oral prophylactic antibiotics.<sup>26</sup> For prophylaxis to be effective, the first dose should be delivered in the emergency department and, preferably, in intravenous form. Either ampicillin/sulbactam or penicillin can be that agent. Amoxicillin/clavulanate also can be used. Alternatives include cefoxitin, levofloxacin, or clindamycin plus a fluoroquinolone. For children allergic to penicillin or cephalosporins, trimethoprim/sulfamethoxazole or clindamycin is recommended as the prophylactic agent.

## Human Bites

### Suturing

As a general rule, closure of human bite wounds traditionally has been avoided.<sup>1</sup> A study has cast doubt, however, on the practice of not closing human bite wounds.<sup>44</sup> Sutured versus nonsutured hand lacerations from human bites had the same outcome. Further studies are needed to confirm these results. Large, easily cleansed and irrigated proximal extremity or truncal wounds can be closed with a single layer of nonabsorbable material. Facial human bites can be disfiguring. A fresh facial bite (<12 hours old) that does not show signs of infection can be closed safely with sutures.<sup>31</sup> Consultation is recommended when there is doubt about what management steps should be carried out for human bites. All clenched-fist bite injuries, with penetration of the dermis, should be managed in consultation with a specialist.

### Antibiotics

Most authorities and clinicians recommend antibiotic prophylaxis for all but the most superficial human bite wounds.<sup>5,45-47</sup> Until reliable clinical studies are carried out to clarify the true risk of human bites and the value of prophylaxis, it is best to err on the side of treatment.

**Established hand infections.** For established infections, in addition to extensive wound cleansing, irrigation, and necessary débridement, ampicillin/sulbactam can be initiated intravenously in the emergency department. It provides excellent coverage against *S. aureus*, *E. corrodens*, and the relevant anaerobic species. Most patients with established hand infections are admitted to the hospital for continued intravenous antibiotics, and ampicillin/sulbactam can be continued until culture results are known. An alternative with similar good coverage against the relevant pathogens is cefoxitin and clindamycin plus a fluoroquinolone. Children can be treated with trimethoprim/sulfamethoxazole in addition to clindamycin. In human bites inflicted by institutionalized patients, coverage for gram-negative organisms should be considered and the addition of an aminoglycoside to one of the above-mentioned regimens might be indicated.

**Hand bite prophylaxis.** Uninfected nonhand bite wounds can be treated on an outpatient basis. Simple abrasions or superficial occlusional bites can be cleansed and observed. Antibiotics are given at the discretion of the caregiver. Wounds penetrating into the dermis or subcutaneous tissue are best treated with antibiotics. Any bite of the hand needs careful follow-up in addition to antibiotics. Because of the potential seriousness of these bites, consultative support is recommended. To ensure early and appropriate antibiotic levels, an initial parenteral dose of ampicillin/sulbactam should initiate prophylaxis.

### Rat Bites

Most reported rat bites occur in a domestic setting. In a study of 50 cases, *Staphylococcus epidermidis* was the most common organism cultured from the open, fresh wound.<sup>48</sup> Other organisms included *Bacillus subtilis*, diphtheroids, and  $\alpha$ -hemolytic streptococci. Although 30% of wounds had positive cultures, only one case became infected. No patient was treated with prophylactic antibiotics. Antibiotics are recommended only if wound infection is evident. Ampicillin/clavulanate and doxycycline are recommended. Rats do not carry rabies, and patients do not need postexposure prophylaxis.

### Fish Bites

People who work with or own fish are susceptible to infection by the small gram-positive rod *Erysipelothrix*. This organism causes a slowly spreading cellulitis of the affected area, usually the hand. The organism responds to penicillin.

---

## WOUND AFTERCARE AND FOLLOW-UP

All animal bite victims or members of their families have to be instructed about the signs of infection: pain, redness, swelling, and purulent drainage. Dressings have to be removed approximately 24 hours after the initial visit so that the wound can be inspected. A wound infection with *P. multocida* usually is apparent by that time.<sup>43</sup> If signs of infection are present, the patient should return to a medical care facility for treatment. A routine follow-up visit for deep, extensive face or hand wounds 24 (particularly for cat bites) to 72 hours after care is a prudent recommendation. Tetanus prophylaxis is administered according to the guidelines outlined in Chapter 21.

---

## RABIES EXPOSURE AND PROPHYLAXIS

Because they treat many animal bites, emergency departments frequently are the facilities that administer rabies postexposure prophylaxis. The most common exposure is from dog bites (Table 15-2).<sup>20</sup> Approximately 6% of dog bites require prophylaxis. Of raccoon and bat

TABLE 15–2 *Emergency Department Rabies Postexposure Prophylaxis Use After Animal Exposures*

Animal Type	No. Exposures	No. (%) Patients Given RPEP
Dog	1635	95 (5.9)
Cat	268	21 (7.8)
Rat/mouse	48	1 (2.1)
Squirrel	20	0 (0)
Gerbil	12	0 (0)
Raccoon	10	8 (80)
Monkey	9	2 (22)
Livestock	8	1 (13)
Bat	5	4 (80)
Gopher	5	0 (0)
Bear	2	1 (50)
Rabbit	2	0 (0)
Skunk	1	0 (0)
Fox	1	1 (100)
Bobcat	1	1 (100)
Coyote	1	1 (100)
Shrew	1	0 (0)
Opossum	1	0 (0)
<b>Total</b>	<b>2030</b>	<b>136 (6.7)</b>

RPEP, rabies postexposure prophylaxis.

From Moran CJ, Talan DA, Mower W: Appropriateness of rabies postexposure prophylaxis treatment for animal exposure, *JAMA* 284:1004, 2000.

bites, 80% receive prophylaxis. Of patients with animal bites that qualify for prophylaxis, 6% do not receive it. The most common reason is the failure to find or account for the status of the biting animal.

Until effective rabies control programs covered the United States by the 1950s, 50 cases of human infection a year were reported, most from dog bites.<sup>49,50</sup> Between 1980 and 1993, only 18 cases were reported to U.S. public health authorities, and only 8 were acquired within the United States. Because of the control programs, almost all (85%) of wildlife rabies occurs in skunks, raccoons, and bats.<sup>51</sup> Although canine rabies has been reduced dramatically, it has not been completely eradicated, particularly along the United States–Mexico border. In the rest of the world, including Asia, Africa, and Latin America, dogs remain the most significant threat to humans for rabies transmittal.

Rabies is a neurotropic virus that, on entering the peripheral nervous system, becomes protected from immune response.<sup>52</sup> For this reason, immediate wound care and postexposure prophylaxis should be initiated to prevent that crucial access. The size of the rabies inoculum, the richness of nerve innervation at the bite site, and the proximity to nerve terminals are crucial risk factors for active disease susceptibility. Animal wounding studies have shown that thorough wound cleansing using soap and water can reduce significantly a bite victim's risk of contracting rabies.<sup>51</sup>

When confronted with a bite victim, the emergency physician has to consider several factors before initiating postexposure prophylaxis,<sup>7</sup> including the animal species involved,

TABLE 15-3 *Rabies Postexposure Prophylaxis Guide—United States, 1999*

Animal Type	Evaluation and Disposition of Animal	Postexposure Prophylaxis Recommendations
Dogs, cats, and ferrets	Healthy and available for 10 days observation Rabid or suspected rabid Unknown (e.g., escaped)	Persons should not begin prophylaxis unless animal develops clinical signs of rabies.* Immediately vaccinate. Consult public health officials.
Skunks, raccoons, foxes, and most other carnivores; bats	Regarded as rabid unless animal proven negative by laboratory tests <sup>†</sup>	Consider immediate vaccination.
Livestock, small rodents, lagomorphs (rabbits and hares), large rodents (woodchucks and beavers), and other mammals	Consider individually	Consult public health officials. Bites of squirrels, hamsters, guinea pigs, gerbils, chipmunks, rats, mice, other small rodents, rabbits, and hares almost never require antirabies postexposure prophylaxis.

\*During the 10-day observation period, begin postexposure prophylaxis at the first sign of rabies in a dog, cat, or ferret that has bitten someone. If the animal exhibits clinical signs of rabies, it should be euthanized immediately and tested.

<sup>†</sup>The animal should be euthanized and tested as soon as possible. Holding for observation is not recommended. Discontinue vaccine if immunofluorescence test results of the animal are negative.

geographic location, type and severity of exposure, status of the animal (captured or not), and underlying disease status of the patient. Tables 15-3 and 15-4 summarize the current postexposure guidelines and treatment schedule.

## Animal Identification

### Wild Carnivores and Bats

Approximately 3% to 20% of all bats submitted for rabies testing are positive for the virus.<sup>51</sup> Bats are responsible for most cases of human rabies in the United States and its territories. Skunks, raccoons, foxes, woodchucks, and wild carnivores should be considered rabid, unless they are in a geographic area known to be free of wildlife rabies. Postexposure prophylaxis should be initiated when patients are exposed to wild carnivores and bats unless (1) the exposure occurred in an area of the continental United States known to be free of terrestrial rabies and the results of immunofluorescence antibody testing is available within 48 hours, or (2) the animal already has been tested and shown not to be rabid. If the animal cannot be captured or tested, prophylaxis is begun immediately. Because the issue of geographic location and the incidence of wildlife rabies can be complicated, consultation with local public health officials is recommended. If there is any delay in obtaining that consultation or the caregiver has any doubt whatsoever about the nature of the biting species, postexposure prophylaxis should be initiated until clinical clarity is obtained. Treatment can be discontinued if it is determined that the risk does not warrant prophylaxis.

### Dogs and Cats

The likelihood of a dog carrying rabies varies with geographic area. The area of highest risk in the United States is along the Mexican border; 80% of all dogs submitted for testing in

TABLE 15-4 *Rabies Postexposure Prophylaxis Schedule—United States, 1999*

Vaccination Status	Treatment	Regimen*
Not previously vaccinated	Wound cleansing	All postexposure treatment should begin with immediate thorough cleansing of all wounds with soap and water. If available, a virucidal agent such as a povidone-iodine solution should be used to irrigate the wounds.
	RIG	Administer 20 IU/kg body weight. If anatomically feasible, the full dose should be infiltrated around the wounds, and any remaining volume should be administered IM at an anatomic site distant from vaccine administration. Also, RIG should not be administered in the same syringe as vaccine. Because RIG might partially suppress active production of antibody, no more than the recommended dose should be given.
	Vaccine	HDCV, RVA, or PCEC 1 mL IM (deltoid area <sup>†</sup> ), one each on days 0 <sup>‡</sup> , 3, 7, 14, and 28.
Previously vaccinated <sup>§</sup>	Wound cleansing	All postexposure treatment should begin with immediate thorough cleansing of all wounds with soap and water. If available, a virucidal agent such as a povidone-iodine solution should be used to irrigate the wounds.
	RIG	RIG should not be administered.
	Vaccine	HDCV, RVA, or PCEC 1 mL IM (deltoid area <sup>†</sup> ), one each on days 0 <sup>‡</sup> and 3.

HDCV, human diploid cell vaccine; IM, intramuscular; PCEC, purified chick embryo cell vaccine; RIG, rabies immune globulin; RVA, rabies vaccine adsorbed.

\*These regimens are applicable for all age groups, including children.

<sup>†</sup>The deltoid area is the only acceptable site of vaccination for adults and older children. For younger children, the outer aspect of the thigh may be used. Vaccine should never be administered in the gluteal area.

<sup>‡</sup>Day 0 is the day the first dose of vaccine is administered.

<sup>§</sup>Any person with a history of preexposure vaccination with HDCV, RVA, or PCEC; prior postexposure prophylaxis with HDCV, RVA, or PCEC; or previous vaccination with any other type of rabies vaccine and a documented history of antibody response to the prior vaccination.

that region have been positive for the rabies virus.<sup>50</sup> Away from the border region, in areas where rabies exists in terrestrial wildlife, only 0.1% to 1% of dogs test positive. That fact underlies the 10-day observation period when a dog is available for observation.

Cats have been reported to have a higher rate of rabies infection than dogs. The region for greatest cat rabies risk is the Mid-Atlantic. Transmittal to cats is probably through raccoons.

No case of animal rabies has been reported from dogs that have been fully vaccinated (two shots).<sup>51</sup> Only three cases of rabies have been reported in dogs and cats that have been reported vaccinated. In all of these cases, it was discovered that the animals had been incompletely vaccinated and had received only one of the two recommended immunization shots.

Treatment guidelines are as follows: When the animal is known to be rabid or is suspected to be, prophylaxis is initiated without delay. For bites from healthy captured but unvaccinated animals, quarantine for 10 days is recommended. Any illness that develops in that period is followed immediately by initiation of prophylaxis. Treatment is not delayed for animal sacrifice and rabies immunofluorescence testing of the brain. For truly wild, unwanted animals that have been captured, immediate sacrifice and testing can be carried out. If the



animal cannot be captured and tested, postexposure prophylaxis is guided by the risk of endemic, wildlife rabies in that area. In these circumstances, consultation with public health officials is recommended. In cases in which consultation cannot be obtained within 48 hours of the biting incident, initiation of prophylaxis is recommended if there is any uncertainty regarding the status of the biting animal. When the circumstances are later clarified, termination of the prophylaxis regimen is carried out if the exposure carried negligible risk.

### **Rodents and Lagomorphs**

Rodents include mice, rats, squirrels, hamsters, guinea pigs, gerbils, and chipmunks. Lagomorphs are rabbits and hares. The overall rate of rabies infection in this group is 0.01%. No cases of human rabies have ever been documented after a rodent or lagomorph bite. Woodchucks and groundhogs are an exception because of reported rabies carriage in some regions. In the event of a rodent or groundhog/woodchuck bite, guidance from the local public health officials is recommended.

### **Exotic Pets**

Included among exotic pets are ferrets, exotic wild animals, and domestic animals crossbred with wild ones. The true risk of rabies in these animals is unknown, and it is recommended by authorities that they be sacrificed and tested rather than observed. Rabies prophylaxis can be initiated and terminated if immunofluorescence is negative. Occasionally the animal is of such rarity or value that immunoprophylaxis might be chosen over animal sacrifice. Consultation with public health officials or zoologic experts can assist in these rare cases.

### **Livestock**

Livestock, particularly cattle, are susceptible to rabies infection from skunks. Horses, mules, sheep, goats, and swine also are susceptible but at a lower rate than cattle. Because of the logistical problems created by large animal exposure, consultation with a veterinarian or public health official is recommended in these cases.

### **Type of Exposure**

Rabies almost always is transmitted by the saliva of an infected animal through a bite. Bites that cause any interruption of the skin—epidermis or dermis—constitute a significant exposure. Significant nonbite exposures include skin scratches, abrasions, open wounds, or mucous membranes that become exposed to and contaminated by the saliva or tissue from a potentially rabid animal. Saliva or tissue that is dry is considered noninfectious. The risk of contracting rabies through a bite from a known rabid animal ranges between 5% and 80%.<sup>53</sup> The risk of exposure of rabies to a skin scratch is 0.1% to 1%.

Aerosolized rabies, such as what might be found in laboratories or caves with resident bats, has been implicated in rare nonbite cases of human rabies. Animal sources responsible for six other cases occurred through corneal transplantation. Since these cases have come to light, guidelines for corneal harvesting have been modified to reduce that risk significantly. Preexposure rabies prophylaxis is recommended for rabies laboratory workers and spelunkers.

Concern often is raised about incidental contact (lack of skin or mucous membrane exposure) with a potentially rabid animal. These exposures do not constitute a rabies risk. In addition, contact with body fluids, such as blood, feces (bat guano), or urine, is considered nonsignificant.

### **Timing of Postexposure Prophylaxis**

In optimal circumstances, and because the stakes can be high, every attempt is made to administer postexposure prophylaxis, if indicated, within 48 hours of contact. This timing is

based on the fact that the incubation period of rabies can be only 5 days, and a margin of safety is desirable.<sup>50</sup> The incubation period can be 2 years, with an average of 30 to 90 days.<sup>51</sup> For this reason, prophylaxis is administered to any patient found to have a rabies-risk bite or exposure regardless of the interval from contact to treatment. The average interval between exposure and care is 5 days, and that delay has not been found to increase the risk of contracting the disease.<sup>25</sup> Because the risk of canine rabies is low in the United States, other than along the Mexican border, a delay of 10 days is considered acceptable if the animal can be confined for observation. Dogs infected with the rabies virus almost always become clinically rabid well before the 10-day period has elapsed.<sup>50</sup>

### Immunosuppression and Pregnancy

Corticosteroid administration, immunosuppressive therapy or disease, and antimalarials can impair the protective immune response of rabies prophylaxis vaccination. Under these circumstances, serum testing for rabies antibody response is recommended. Rabies postexposure prophylaxis provides no risk to a fetus; pregnant women are treated the same as other exposed persons.

---

### POSTEXPOSURE PROPHYLAXIS

The currently approved regimen for rabies postexposure prophylaxis includes the administration of human rabies immune globulin and five doses of human diploid cell vaccine. An additional vaccine, rabies vaccine, adsorbed, is available and is equally efficacious to human diploid cell vaccine. Virtually all vaccines undergo an appropriate antibody response, and antibody titer testing is not necessary. Alternative vaccine dose schedules (e.g., intradermal or intramuscular three doses) are not recommended for use in the United States.

The use of rabies vaccine induces local reactions, such as pain, erythema, swelling, or itching, at the injection site in 30% to 74% of recipients.<sup>51</sup> Approximately 5% to 40% of vaccinees report systemic reactions, such as headache, nausea, abdominal pain, muscle aches, and dizziness. Extremely rare, with only three cases reported, are neurologic illnesses resembling Guillain-Barré syndrome. All three cases resolved without sequelae by 3 months. Another reaction, occurring in 6% of recipients, is an immune complex–like illness characterized by urticaria, arthralgia, arthritis, angioedema, nausea, vomiting, and fever. Local pain and low-grade fever have been reported with human rabies immune globulin.

Because of the seriousness of rabies, if possible, rabies prophylaxis should not be interrupted or discontinued. Attempts are made to manage local or mild systemic reactions with antiinflammatories and antipyretics. Ultimately, in serious reactions, the risk of acquiring rabies must be weighed against the nature of the reaction. In cases such as these, advice and assistance should be sought from public health officials or the Centers for Disease Control and Prevention in Atlanta, Georgia.

### Postexposure Therapy of Previously Vaccinated Bite Victims

Patients who previously have undergone preexposure or postexposure rabies prophylaxis are treated with two doses of the vaccine alone, one immediately and the other 3 days later. Human rabies immune globulin is unnecessary because the vaccination booster provides an effective amnestic antibody response.

### REFERENCES

1. Griego RD, Rosen T, Orengo IF, et al: Dog, cat, and human bites: a review, *J Am Acad Dermatol* 33:1019-1029, 1995.
2. Kizer K: Epidemiologic and clinical aspects of animal bite injuries, *J Am Coll Emerg Physicians* 8:134-141, 1979.

3. Strassburg M, Greenland S, Marron JA, Mationey LE: Animal bites: patterns of treatment, *Ann Emerg Med* 10:193-197, 1981.
4. Talan DA, Citron DM, Abrahamian FM: Bacteriologic analysis of infected dog and cat bites. Emergency Medicine Animal Bite Infection Study Group. *N Engl J Med* 340:138-140, 1999.
5. Farmer C, Mann R: Human bite infections of the hand, *South Med J* 59:515-518, 1966.
6. Marr J, Beck A, Lugo J: An epidemiologic study of the human bite, *Public Health Rep* 94:514-521, 1979.
7. Marcy S: Infections due to dog and cat bites, *Pediatr Infect Dis* 1:351-356, 1982.
8. Aghababian R, Conte J: Mammalian bite wounds, *Ann Emerg Med* 9:79-83, 1980.
9. Bailie W, Stove E, Schmitt A: Aerobic bacterial flora of oral and nasal fluids of canines with reference to bacteria associated with bites, *J Clin Microbiol* 7:223-231, 1978.
10. Goldstein EJC, Citron DM, Wield B: Bacteriology of human and animal bite wounds, *J Clin Microbiol* 8: 667-672, 1978.
11. Callaham ML: Prophylactic antibiotics in common dog bite wounds: a controlled study, *Ann Emerg Med* 9: 410-414, 1980.
12. Callaham ML: Treatment of common dog bites: infection risk factors, *J Am Coll Emerg Physicians* 7:83-87, 1978.
13. Goldstein EJC, Citron D, Finegold SM: Dog bite wounds and infection: a prospective clinical study, *Ann Emerg Med* 9:508-512, 1980.
14. Goldstein EJC: Bite wounds and infection, *Clin Infect Dis* 14:633-640, 1992.
15. Basadre JO, Parry SW: Indications for surgical debridement in 125 human bites of the hand, *Arch Surg* 126: 65-67, 1991.
16. Goldstein EJC, Barones MF, Miller TA: *Eikenella corrodens* in hand infections, *J Hand Surg* 8:563-566, 1983.
17. Patzakis MJ, Wilkins J, Bassett RL: Surgical findings in clenched-fist injuries, *Clin Orthop* 220:237-240, 1987.
18. Mann R, Peacock J: Hand infections in patients with diabetes mellitus, *J Trauma* 17:376-380, 1977.
19. Guy RJ, Zook EG: Successful treatment of acute head and neck dog bite wounds without antibiotics, *Ann Plast Surg* 17:45-48, 1986.
20. Moran GJ, Talan DA, Mower W: Appropriateness of rabies postexposure prophylaxis treatment for animal exposure, *JAMA* 284:1001-1007, 2000.
21. Koch S: Acute rapidly spreading infections following trivial injuries to the hand, *Surg Gynecol Obstet* 59: 277-308, 1934.
22. Peeples E, Boswick J, Scott F: Wounds of the hand contaminated by human or animal saliva, *J Trauma* 19: 655-658, 1979.
23. Malinowski R, Strate RG, Perry JF Jr, Fischer RP: The management of human bite injuries to the hand, *J Trauma* 19:655-658, 1979.
24. Thomson H, Svitek V: Small animal bites: the role of primary closure, *J Trauma* 13:20-23, 1973.
25. Beck AM, Felser SR, Glickman LT: An epizootic of rabies in Maryland, 1982-84, *Am J Public Health* 77:42-44, 1987.
26. Dire DJ: Cat bite wounds: risk factors for infection (Abstract), *Ann Emerg Med* 18:471, 1989.
27. Lindsey D, Christopher M, Hollenbach I, et al: Natural course of the human bite wound: incidence of infection and complications in 434 bites and 803 lacerations in the same group of patients, *J Trauma* 27:45-48, 1987.
28. Rest J, Goldstein ECJ: Management of human and animal bites, *Emerg Clin North Am* 3:117-126, 1985.
29. Earley MJ, Bardsley AF: Human bites: a review, *Br J Plast Surg* 37:458-462, 1984.
30. Brandt F: Human bites of the ear, *Plast Reconstr Surg* 43:130-134, 1969.
31. Thomasetti B, Walker L, Bormby M: Human bites of the face, *J Oral Surg* 37:565-568, 1979.
32. Zook EG, Miller M, Van Beek AL, et al: Successful treatment protocol for canine fang injuries, *J Trauma* 20:243-246, 1980.
33. Dire DJ: Emergency management of dog and cat bite wounds, *Emerg Med Clin North Am* 10:719-736, 1992.
34. Thomas PR, Buntine JA: Man's best friend? A review of the Austin hospital's experience with dog bites, *Med J Aust* 147:536-540, 1987.
35. Callaham ML: Controversies in antibiotic choices for bite wounds, *Ann Emerg Med* 17:1321-1330, 1988.
36. Medeiros I, Sacanoto H: Antibiotic prophylaxis for mammalian bites, *Cochrane Database Syst Rev* 2:CD001738, 2001.
37. Abrahamian FM: Dog bites: bacteriology, management, and prevention, *Curr Infect Dis Rep* 2:446-453, 2000.
38. Douglas LG: Bite wounds, *Am Fam Physician* 11:93-99, 1990.
39. Rosen RA: The use of antibiotics in the initial management of recent dog-bite wounds, *Am J Emerg Med* 3: 19-23, 1985.
40. Cummings P: Antibiotics to prevent infection in patients with dog bite wounds: a meta-analysis of randomized trials, *Ann Emerg Med* 23:535-540, 1994.
41. Vietch J, Omer G: Case report: treatment of cat bite injuries of the hand, *J Trauma* 19:201-202, 1979.
42. Elenbaas RM, McNabney WK, Robinson WA: Evaluation of prophylactic oxacillin in cat bite wounds, *Ann Emerg Med* 13:155-157, 1984.

43. Tindall J, Harrison C: *Pasteurella multocida* infections following animal injuries, especially cat bites, Arch Dermatol 105:412-416, 1972.
44. Bite U: Human bites of the hand, Can J Surg 27:616-618, 1984.
45. Chuinard R, D'Ambrosia R: Human bite infections of the hand, J Bone Joint Surg Am 59A:416-418, 1977.
46. Guba A, Mulliken J, Hoopes J: The selection of antibiotics for human bites of the hand, Plast Reconstr Surg 56:538-541, 1975.
47. Shields C, Patzakis MJ, Meyers MH, Harvey JP Jr: Hand infections secondary to human bites, J Trauma 15:235-236, 1975.
48. Ordog GJ, Balasubramaniam S, Wasserberger J: Rat bites: fifty cases, Ann Emerg Med 14:126-130, 1985.
49. Fishbein DB, Arcangeli LS: Rabies prevention in primary care, Postgrad Med 82:83-95, 1987.
50. Fishbein DB, Robinson LE: Rabies, N Engl J Med 329:1632-1638, 1993.
51. Human Rabies Prevention—United States, 1999: recommendations and practices, MMWR Morb Mortal Wkly Rep 48(RR 1):1-21, 1999.
52. Mann J: Systemic decision-making in rabies prophylaxis, Pediatr Infect Dis 2:162-167, 1983.
53. Hatwick MAW: Human rabies, Public Health Rev 3:229-274, 1974.

# Common Wound Care Problems

## FOREIGN BODIES

Inert (Nonreactive) Objects  
Organic (Reactive) Objects  
Clinical Evaluation  
Imaging  
Techniques for Removal

## PLANTAR PUNCTURE WOUNDS

Treatment of Puncture Wounds  
Antibiotics

## FISHHOOKS

Retrograde Removal  
String Traction  
Barb Cover Technique  
Hook Push-Through

## ABRASIONS AND TATTOOING

**C**ommon nonlaceration problems lend themselves to emergency wound care techniques. These problems include retained foreign bodies and fishhooks, plantar puncture wounds, and abrasions. Although they can appear trivial, each of these problems presents special challenges and occasionally requires sophisticated diagnostic and management procedures. In addition, certain anatomic areas of the body, particularly the structures of the face, hand, and foot, can be fraught with unique difficulties, which are best managed by a thorough understanding of the issues and application of proper technique.

## FOREIGN BODIES

Any object becomes a foreign body when it penetrates the skin and lodges in the soft tissue. In a clinical study of foreign bodies retained in the hand, the most common objects were, in order of frequency, wood splinters, glass fragments, various metallic objects, and needles.<sup>1</sup> Also included in the list were pencil leads, thorns, nails, and plastic objects. Generally, foreign bodies are classified by material—inert (nonreactive) and organic (reactive).

### Inert (Nonreactive) Objects

Inert objects include bullets, needles, and other metallic items. Although they do not provoke inflammation, these objects can cause chronic pain and discomfort, especially in weight-bearing areas or near joints. Metals that oxidize (i.e., rust) can cause a mild-to-moderate tissue reaction. The clinical decision to remove an inert object has to be weighed against the potential damage that could be created during a search for the object. Inert objects can be left in place if they are inaccessible and will not cause tissue damage or a functional deficit. If left alone, noncritical inert foreign bodies encapsulate within soft tissue and cause no further problem.

A question sometimes arises concerning lead foreign bodies, usually bullets, and the risk of lead absorption and toxicity. In a study of patients with retained bullets, lead levels

averaged 17  $\mu\text{g}/\text{dL}$  compared with 7  $\mu\text{g}/\text{dL}$  in the control patients ( $P < 0.002$ ).<sup>2</sup> Levels greater than 10  $\mu\text{g}/\text{dL}$  are considered toxic. Clinical signs of toxicity are uncommon, however. Symptoms, such as fatigue, headache, and nausea, can be low grade and vague. If toxicity is suspected, patients are referred for lead levels and evaluation.

Although glass is considered inert, glass foreign bodies are often symptomatic. Removal is recommended if accessible except for small, insignificant fragments. Pencil “lead” (i.e., graphite) is inert but can cause tattooing. It also can be accompanied by wood fragments during injury. For these reasons, even though it is inert, graphite should be removed from the injury site.

### Organic (Reactive) Objects

Objects that are not inert—wood, bone, soil, stones, rubber, and other organic materials such as thorns—must be removed in their entirety. These materials can cause a variety of bacterial and fungal infections.<sup>3,4</sup> Synovitis from joint penetration, periosteal reactions, foreign-body granulomas, draining fistulas, and pseudotumors of the soft tissue all have been reported with noninert foreign objects.<sup>1,5,6</sup> Retained wood objects have been reported to cause chronic inflammation, drainage, and pain for 7 years after penetration.<sup>5</sup> A missed diagnosis or failure to remove all fragments of a noninert object can lead to prolonged disability and patient discomfort.

### Clinical Evaluation

When a foreign object penetrates the skin, patients cannot reliably report its presence. In glass wounds, reliance on the patient’s history alone would lead to 50% missed fragments.<sup>7</sup> In cases in which no foreign body is reported, certain clinical settings carry a higher risk for one being present. Any injury with glass should raise the suspicion of a retained fragment. In glass injuries, the head and foot are more likely to have retained fragments.<sup>8</sup> In lip or perioral injuries in which there is traumatic loss of dentition, a tooth fragment might be embedded in the soft tissue. Injuries to the feet or hands with needles, nails, or splinters should be suspected of retention if the patient cannot account for the entirety of the injuring object. If the suspicion is strong, the caregiver is obligated to carry out a diagnostic evaluation and local exploration to rule in or rule out the possibility of a retained foreign object.

Before anesthetic is administered, gently running a gloved finger over the suspected foreign-body site can elicit in a patient the characteristic sensation. In the anesthetized wound, gently probing and drawing a closed hemostat in and through the wound can alert the operator to the presence of a wood, glass, or metallic foreign body. The hemostat transmits a distinct “grating” sensation. Probing can reveal the presence of an inert object or a wood splinter before it has been softened by the absorption of tissue fluids.

### Imaging

#### Plain Radiography

For the most part, radiographs are ordered when there is patient belief or clinical suspicion of a foreign object. Most objects (80%) can be visualized directly or indirectly with the use of radiographs.<sup>1</sup> Radiodense objects, even the size of a pinpoint, are easily seen. Metallic objects, with the exception of aluminum, can be visualized in almost all cases. A common misconception is that glass is not visible by radiograph.<sup>9</sup> Virtually all types of glass (95%) 2 mm in size can be seen by x-ray.<sup>10</sup> Fragments 0.5 mm or larger can be visualized in 50% to 60% of cases. Other radiodense objects include pencil graphite, some plastics, and gravel.

Nonradiodense objects include wood, thorns, chicken bones, and some plastics. Radiodensity of wood and organic objects depends to some degree on the time in tissue and absorption of body fluids. Wood has been reported to be visible by radiography in 15% of cases; however, after 48 hours, fluid absorption renders it invisible.<sup>1</sup> Nonradiodense objects

(e.g., splinters or plastic fragments) can be revealed as a filling defect or outlined by air drawn into the wound during the injury.

### Ultrasonography, Computed Tomography, and Magnetic Resonance Imaging

Ultrasonography has become an increasingly important bedside diagnostic aid in emergency departments. Compact portable equipment with versatile transducer probes allows for diagnosis of nonradiodense objects and assisted removal.<sup>11,12</sup> Ultrasonography can detect nonradiodense foreign bodies 1 × 2 mm or larger.<sup>13</sup> In experimental studies, in which various foreign bodies are introduced to chicken or cadaver flesh, the sensitivity of ultrasound detection varied from 43% to 83%.<sup>14-16</sup> The specificity ranged from 59% to 86%. In a small clinical study of patients with actual nonradiodense foreign bodies, ultrasound detected 21 of 22 foreign bodies found at operation.<sup>17</sup>

Tendons, deep scar tissue, fresh hematoma, and tissue calcifications can produce false-positive ultrasound readings. Similar to any technical procedure, experience increases the accuracy and effectiveness of the operator.

Computed tomography (CT) scans offer an alternative to ultrasound.<sup>18</sup> Not only can a CT scan identify vegetative objects, such as splinters and thorns, but also it can localize objects in relationship to the surrounding anatomic structures. Magnetic resonance imaging has similar capabilities to CT but should never be used to locate objects that contain metal.<sup>19</sup> CT and magnetic resonance imaging are expensive imaging alternatives and require a high degree of patient cooperation, which often is not possible for a pediatric patient.

### Techniques for Removal

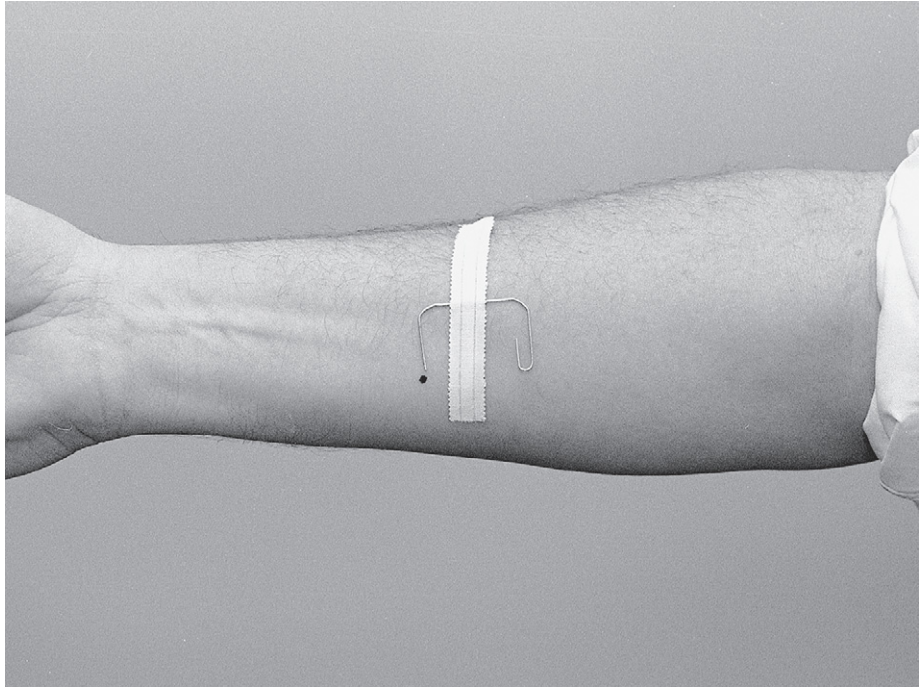
When the diagnosis is made, localization and retrieval of the foreign body are carried out. These steps are often frustrating and attended by unanticipated difficulties. It seems a simple matter to make a small incision and retrieve an object that appears to be close to the surface of the skin. Simple retrieval is not always possible, however. As a rule, if attempts at retrieval exceed 30 minutes, serious consideration should be given to terminating the procedure and obtaining consultation.

### Radiodense Objects

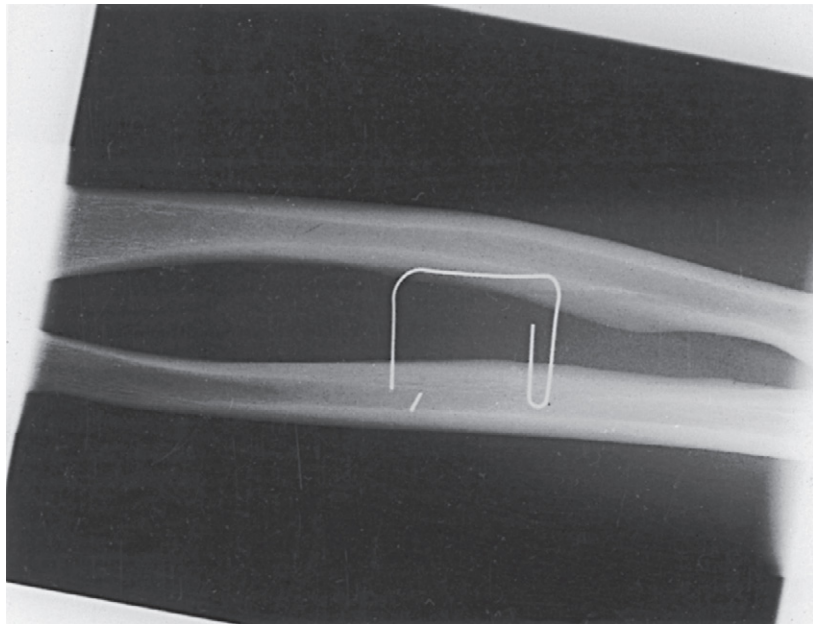
For objects that are located below the surface and out of direct sight, careful localization is necessary before proceeding with exploration. Radiodense objects can be localized by a variety of techniques using markers and radiographs. A simple technique recommended by the author is to bend a paper clip to form a flat plane with an extended arm. The extended arm is placed directly over the skin entry wound created by the foreign object, and the paper clip is secured with a small piece of tape (Fig. 16-1). Two radiographs are taken *exactly* at an angle of 90 degrees to each other (anteroposterior and lateral views) using the plane of the clip as a geometric point of reference (Figs. 16-2 and 16-3). In this manner, the location and the depth of the object relative to the extended arm of the paper clip can be determined. Magnification by this technique occurs, and the distance between the object and the clip on the radiograph is greater than the actual distance. After appropriate cleansing and the administering of an anesthetic, a small incision is made, and exploration is carried out until the object can be removed. The radiographs are needed in the care area for reference during the removal.

### Nonradiodense Objects

If ultrasonography is not available to assist in removal, nonradiodense objects are best approached through a more generous incision and thorough exploration by direct visualization. Incisions permit débridement and removal of tissue that is embedded with foreign material. When the foreign body is located in the hand or foot, the exsanguination tourniquet




**Figure 16-1** Technique for placing a reconfigured paper clip with the extended arm directly over the entry point of a foreign-body penetration.



**Figure 16-2** Direct anteroposterior view of the paper clip and foreign body.





**Figure 16-3** Direct lateral view of the paper clip and foreign body. This type of radiograph and that in Figure 16-2 can be used to locate accurately the position of the foreign body relative to the extended arm by the anteroposterior view and the depth of the foreign body by the lateral view.

technique (see Chapter 9) is recommended. Even a small amount of bleeding can make visualization impossible.

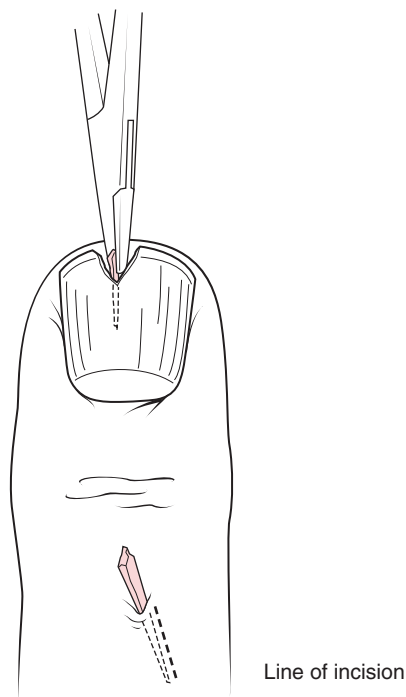
### *Protruding Objects*

For objects that are partially protruding from the skin, the temptation to “grab and yank” must be resisted. If a wood splinter is pulled out injudiciously through a small, tight entry wound, small fragments can be stripped off the splinter and left behind to cause future difficulty.<sup>13</sup> The technique illustrated in the finger in Figure 16-4 shows how a small incision is made parallel to the course and angle of the object. By creating an incision, the splinter can be removed without leaving behind smaller splinters. In addition, the wound can be copiously irrigated to decrease the level of bacterial contamination. These small incisions must not be closed with sutures. They should be left open to drain the site, if necessary, and prevent the accumulation of purulence that might lead to the formation of an abscess.

### *Objects under Nail Plates*

A common problem is a splinter or other object that is lodged under a nail plate. If the object can be grasped by a hemostat, it can be pulled out carefully from under the nail. Care has to be taken not to strip fragments off a wooden object. For a splinter that cannot be grasped, removal of a small part of the nail plate in a wedge-shaped fashion can be carried out to expose the splinter, as shown in the top half of Figure 16-4.

A simple technique for removing small splinters lodged under the nail plate is to bend the tip of a 25G or 27G needle so that a small barb equal in size to the diameter of the needle is created.<sup>20</sup> The shaft of the needle is introduced adjacent and parallel to the splinter and carried back to the most proximal portion of the object. Then the barb is raked along the



**Figure 16-4** *Top*, Technique for removing a small splinter from between the nail plate and the nail bed. A small wedge of nail has been removed to gain exposure of the protruding splinter. A small hemostat is used to extract the splinter gently. *Bottom*, Technique for removing a penetrating foreign body, a splinter, which is protruding from the skin. A small incision is made directly away from the entry point, parallel to the shaft of the foreign body. The splinter can be removed in its entirety without leaving smaller splinters.

splinter, and the needle and the foreign object are pulled out from under the nail. Removing objects from under nails is best carried out when the patient is anesthetized. The anesthetic usually is delivered via a digital block (see Chapter 6).

### Thorns and Cactus Spines

Particularly troublesome are small thorns and cactus spines that can become embedded accidentally in the skin in large numbers, usually in children. In a controlled rabbit experiment, Elmer's Glue-All was applied under a single layer of gauze and allowed to dry. Gentle peeling successfully removed 95% of all spines.<sup>21</sup> The next most effective method was manual removal with tweezers, with a 76% rate of spine removal. The combination of tweezer removal of large spines followed by glue application is effective.

### When to Consult

Occasionally a foreign body cannot be retrieved successfully by attempts at localization and exploration in an emergency wound care setting. The most common situation in which this eventuality arises is deep foreign objects of the foot. These foreign bodies are best removed in radiology department suites where ultrasound, image intensifiers, and stereotaxic localization can be applied while a consultant explores the affected area.<sup>22,23</sup>

## PLANTAR PUNCTURE WOUNDS

Plantar puncture wounds are a common presenting complaint. Most wounds ( $\geq 90\%$ ) are caused by stepping on nails.<sup>24</sup> In many cases, the patient seeks only a tetanus shot and not care for the wound itself. Because many patients do not seek care at all for punctures, the true complication rate is unknown. The complication rate for patients who do seek care

ranges from 2% to 8%.<sup>24,25</sup> The time from injury to presentation is significant because patients who present after 48 hours are more likely to have complications.<sup>26</sup> In actuality, these patients are brought to care because of persistent or worsening symptoms.

In addition to delay of presentation, other circumstances increase the risk for infection and other complications. Punctures suffered outdoors are more likely to be contaminated or caused by rust-covered nails. Remnants of socks or shoes can be carried into wounds with tennis shoes creating an increased risk for osteomyelitis secondary to *Pseudomonas aeruginosa*.<sup>27,28</sup> The forefoot, including the metatarsal heads and toes, is far more vulnerable to complications, particularly pyarthrosis and osteomyelitis, than are the midfoot and heel. In one study, 34 of 35 serious plantar puncture injuries occurred in the forefoot.<sup>29</sup> Deep punctures can penetrate bone, tendon, or joints. Finally, patients with diabetes, peripheral vascular disease, or immunosuppression carry a greater risk for complications.

### Treatment of Puncture Wounds

The management of puncture wounds is controversial and ranges from minimal skin cleansing to complete coring of the puncture wound site. The following are guidelines based on different clinical presentations.

#### Simple Punctures

Most patients present with benign-appearing puncture wounds caused by clean objects, such as tacks; needles; or small unrudded, exposed, nails. These patients often present less than 24 hours from the injury.<sup>30</sup> Realistically, cleaning and irrigating the length and depth of the actual wound might cause more complications than it would prevent. If there are no indications of retained foreign material, the wound edges are clean and not devitalized, and the puncture site is not indurated or excessively tender to palpitation, skin cleansing and a small application of antibiotic ointment, followed by an adhesive bandage (Band-Aid), should suffice.

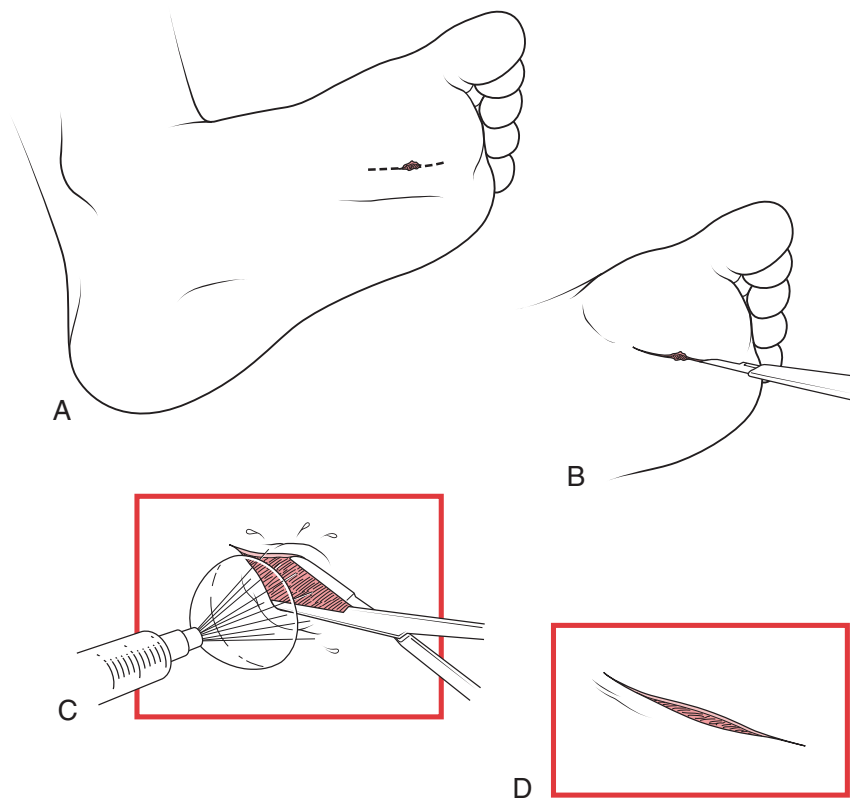
#### Puncture with Suspected Retained Material

In these wounds with suspected retained material, the puncture is often larger than the small sites noted previously. The wound edges are contaminated, stellate, or shredded appearing. Old nails, exposed bolts, and miscellaneous sharp objects are causes of these punctures. By history, the puncturing object is not clean, has broken during the puncture, or possibly has forced sock or shoe fragments into the wound. These patients are more likely to complain of significant pain or a foreign-body sensation on palpation of the puncture site. They often present more than 48 hours after the injury after having tried to treat themselves or having ignored the symptoms, without success.<sup>30</sup>

After anesthesia is provided, either through a foot block or by local infiltration, a transverse incision (parallel to the wrinkle line of a curled foot) is made through the puncture site, long enough to provide good exposure of the puncture site and proximal wound track (Fig. 16-5). Any foreign material or devitalized tissue can be débrided. With the wound edges retracted, thorough irrigation is carried out. No attempt is made to suture this wound. The wound edges close without difficulty after application of a small amount of an antibiotic ointment and a Band-Aid. For comfort and protection, it is recommended that the patient use crutches for 2 to 3 days.

#### Complicated Punctures

In cases in which the puncture site is obviously infected, inflamed, or devitalized, more extensive débridement is carried out. Foreign material is suspected until proved otherwise through exploration. In these cases, opening the wound site as shown in Figure 16-5 can be carried out to expose the wound track and provide for the necessary irrigation, exploration, and débridement. Suturing is not recommended, and crutches, as noted earlier, can be used. Antibiotics, as discussed in the following section, might be indicated.



**Figure 16-5** Plantar puncture wound management. **A**, A suggested incision line, parallel to the wrinkle lines, through the puncture wound. **B**, The incision can be made with a scalpel and no. 15 blade through the thick dermis. **C**, A hemostat is used to expose the wound for exploration and irrigation. **D**, The wound edges can be débrided if necessary and left unsutured to heal by secondary intention.

### Complicated Puncture with Deep Foot Symptoms

In cases in which infection has been established, foreign material has had a chance to create significant tissue reaction, or the bone/joint has been violated, the patient complains of deep foot pain. The foot might appear swollen well beyond the puncture site itself, or lymphangitic streaks could be evident, or both. In these cases, a radiograph is recommended to screen for foreign objects, bone injury, or gas pockets. In addition, consultation with a surgical specialist is recommended. Established infection or significant tissue inflammation well beyond the actual puncture site is often a result of a retained foreign body. These patients usually present several days after the original puncture. Every effort has to be made to discover or rule out retained foreign material.

### Antibiotics

In patients with established infection secondary to puncture wounds, the most common organisms involved are *Staphylococcus aureus*, *Staphylococcus epidermitis*, and *Streptococcus* species.<sup>31</sup> *P. aeruginosa* is the most common cause of postpuncture osteomyelitis and is associated with punctures through tennis shoes. In one series of 15 cases of *Pseudomonas* osteochondritis in children, however, half of the children were not wearing shoes at the time of injury.<sup>32</sup>

It is common for these patients to have initial improvement after the injury followed by a return of pain and disability. Unless *Pseudomonas* is suspected, established infections should be treated with a broad-spectrum antibiotic with coverage of common gram-positive organisms. The first-generation cephalosporin cefazolin (Ancef), ampicillin/sulbactam (Unasyn), or clindamycin (Cleocin) in allergic patients can be initiated until culture results are known. If *Pseudomonas* is suspected, the addition of an aminoglycoside to any of the previously mentioned antibiotics provides appropriate coverage.

The use of prophylactic antibiotics in uninfected puncture wounds is not supported by clinical studies.<sup>26,31-33</sup> Because *P. aeruginosa* is sensitive to ciprofloxacin in vitro, it has been used as a prophylactic agent. This agent is not a first-line agent for the treatment of *Pseudomonas*; it is contraindicated in children, the group most at risk for this type of infection.<sup>17</sup> Reliance on prophylactic antibiotics is undercut by a study in which cellulitis was shown to occur in nine patients despite receiving appropriate antibiotic coverage.<sup>24</sup> The most important finding of this study was that five of the nine patients had a retained foreign object. In uninfected puncture wounds of the foot, the recommended course of action includes careful instructions to the patient regarding the signs of infection and the arrangement of appropriate follow-up. If an infection occurs, a well-informed patient returns for appropriate treatment. It cannot be overemphasized that, if an infection develops, retained foreign material is the cause until proved otherwise.

---

## FISHHOOKS

Many techniques have been described to remove fishhooks. As a rule, hooks with small barbs can be removed with retrograde techniques, and hooks with large barbs often are best managed by the push-through and cut method. In a 1991 study of 97 patients with fishhook injuries, the most common and successful removal technique was the push-through and cut method.<sup>33</sup> Several methods for fishhook removal are described here, and their success rates accompany the descriptions.

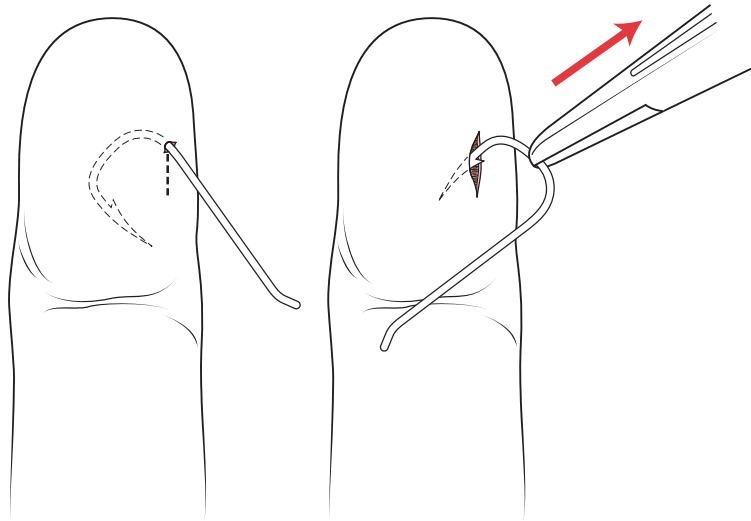
### Retrograde Removal

Hooks with small barbs or hooks that are only superficially embedded often can be backed out through the original site of penetration. Gentle pressure is applied to the eye and shank to push the barb away from tissue. Simultaneously a hemostat is applied to the curved portion of the shaft. Traction with the hemostat “backs” the hook out.

Experienced fishermen sometimes make a small incision in the dermis at the entry site and pull the hook out retrograde with needle-nose pliers. Dermis is the most likely layer to resist removal of the hook and barb because of its naturally tough consistency. This extraction procedure can be duplicated easily in an emergency wound care facility. After basic cleansing with an appropriate solution (e.g., povidone-iodine), a small amount of anesthetic is injected adjacent to the penetrating shaft. With a no. 11 or no. 15 blade, a small incision is made in line with the barb, inside the concave portion of the hook (Fig. 16-6). The portion of the shaft at skin level is grasped with a hemostat, and the hook is removed with a sharp, rapid pulling motion. The pulling motion is in direct line with the length of the shaft closest to the barb of the hook.

### String Traction

Another method for removing a hook with small barbs requires the use of some string with good tensile strength, such as umbilical tape or 0 silk suture (Fig. 16-7). The string is looped around the curved portion of the shaft of the hook and is gently drawn parallel to and in the opposite direction of the straight portion of the shaft. The straight shaft and eyelet portions are depressed against the skin to rotate the barb slightly from its point of attachment in the skin. The string is given a sharp pull to release the hook. Caution is suggested because

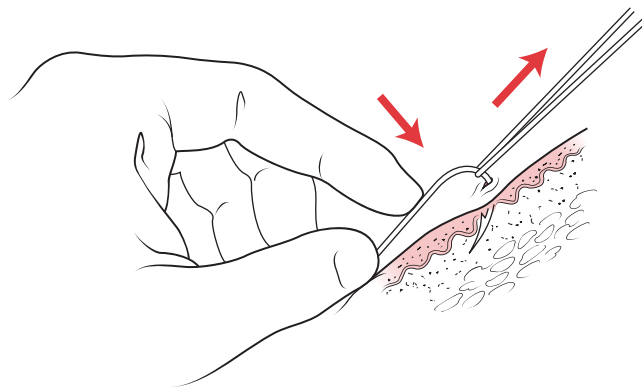


**Figure 16-6** Technique for removing a fishhook with a small barb. A small incision is made in line with the concavity of the curve of the hook. The needle is backed out gently through this incision.

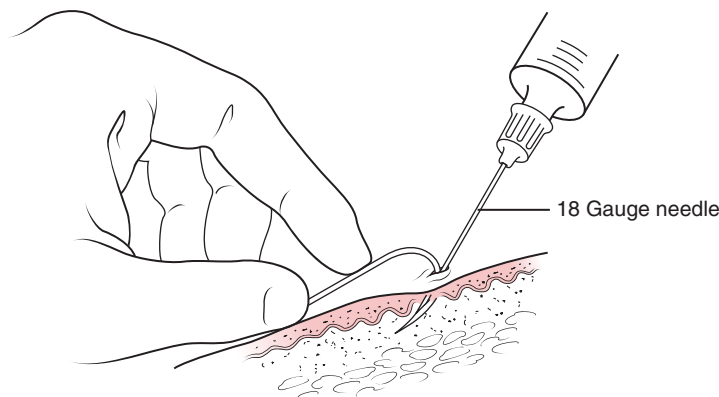
bystanders might be in the pathway of the hook. This method of hook removal does not require the administration of an anesthetic.

### Barb Cover Technique

Another removal method uses an 18G or 16G needle. As illustrated in Figure 16-8, the needle is introduced into the skin through the original wound entry site. It is passed adjacent to the shaft until the hollow portion of the needle point can be placed over, or “cover,” the barb. While both are held firmly together, the needle and hook are brought back out through the wound site. The needle effectively sheaths the barb and prevents it from snagging on tissue during removal.



**Figure 16-7** Technique for removing a fishhook with a small barb by using traction with 0 silk or umbilical tape. Pressure is applied to the shaft of the hook toward the skin as a swift “yank” of the cord is applied in the direction opposite the barb. Bystanders need to be warned that the fishhook could fly across the room. Placing a small piece of adhesive tape around the hook and string might help avoid this hazard.



**Figure 16-8** Technique for removing a fishhook by placing an 18G needle on the barb of the hook and backing it out through the puncture wound.

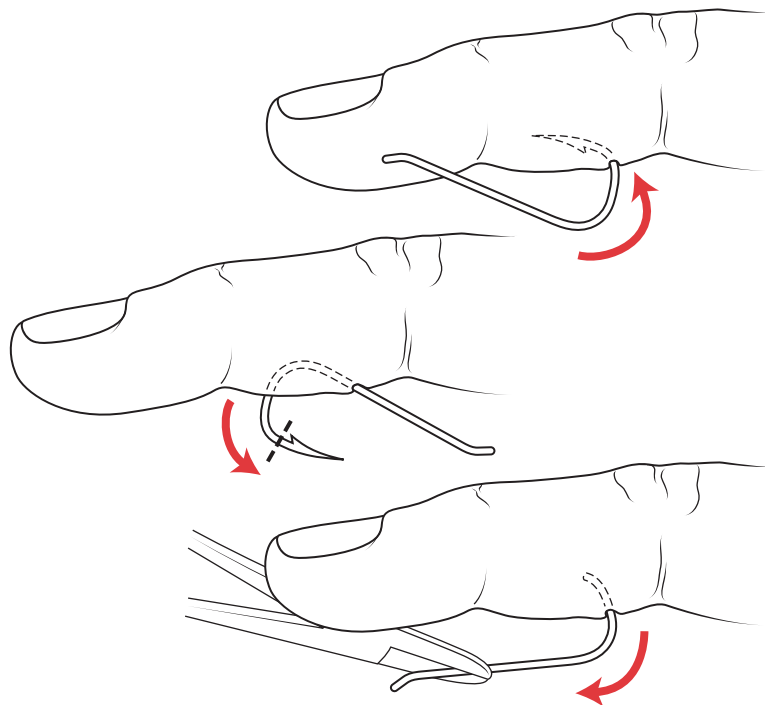
### Hook Push-Through

For deeply embedded hooks or hooks with large barbs, the push-through method is recommended. Trying to back out a deeply penetrated or large barbed hook can cause excessive tissue damage. Basic skin preparation is carried out, and a small amount of local anesthetic is injected at the site through which the hook point is to be extruded. Using a hemostat as a grasping instrument, the hook shaft is manipulated in such a manner so as to push the hook point out through the dermis (Fig. 16-9). The hook is clipped off with wire cutters, and the shaft is backed out of the wound.

Certain anatomic sites merit separate mention. Hooks embedded in cartilage, most commonly the ear or nose, cannot be backed out successfully. The push-through method is recommended for these sites. Hooks that penetrate into joint capsules also are best removed by the push-through method because barbs can break off in the joint space when backed out. Violation of a joint space can lead to serious complications; consultation is encouraged. Occasionally, fishhooks penetrate the cornea or other part of the globe. This complication constitutes an emergency. No attempt is made to remove the hook in an emergency wound care area. Ophthalmologic consultation is mandatory. If the patient has to be transferred to another facility for hook removal, he or she should be placed in a semirecumbent position to decrease eye pressure. A metal eye shield is taped gently over the eye, avoiding any direct contact or pressure on the eye. Pressure patching with gauze sponges is absolutely contraindicated to avoid extrusion of intraocular contents through the eye wound.

### ABRASIONS AND TATTOOING

Abrasions are skin wounds caused by tangential trauma to the epidermis and dermis (i.e., the "skinned knee"). The skin is forced against a resistant surface in a rubbing or scraping fashion. The resultant injury is analogous to a burn. Varying thicknesses of epidermis and dermis can be lost, including tissue as deep as the superficial fascia and even bone. Abrasions can be small or can cover large body surface areas. Frequently these injuries are impregnated with dirt, debris, and road tar. The principles for management include prevention of infection, promotion of rapid healing, and prevention of "tattooing" from the retained foreign material. The last-mentioned problem is of special cosmetic importance because when the healing



**Figure 16-9** The push-through technique for removing hooks with large barbs or hooks that are lodged in cartilage or joint spaces. The anesthetic is infiltrated in the area of the hook and the projected exit site. When the exit has been accomplished, the barb is removed, and the shaft is backed out through the original puncture site.

process traps unsightly debris in the epidermis and dermis, it cannot be removed easily by later surgical intervention.

Most abrasions are small and relatively uncomplicated. Similar to burns, however, they are extremely sensitive and painful to the touch. Cleansing has to be gentle, yet thorough. An appropriate wound cleansing solution suffices to remove surface contaminants and to prepare the wound for dressing. Povidone-iodine solution, without detergent, and chlorhexidine (see Chapter 7) are effective in cleaning abrasions. Abrasions, similar to lacerations, are contaminated with bacteria that can lead to infection and cellulitis. Under experimental conditions, cleansing with povidone-iodine within 6 hours of injury can reduce bacterial counts effectively.<sup>34</sup> After 6 hours, the counts remain the same despite cleansing, increasing the risk of local infection.

Cleansing of contaminated and debris-laden abrasions can be tedious and difficult. If the abrasion is small, a local anesthetic can be injected around the area in a “field” or circumferential pattern. When the pain is eliminated, scrubbing with a sponge or soft surgical brush can be done, using an appropriate cleansing solution. If necessary, meticulous removal of all particulate debris can be aided by using a needle, a no. 11 surgical blade, or a small-jaw tissue forceps. If all ground-in particulate matter cannot be removed in the emergency department with these steps, consultation is recommended to manage this potential cosmetic problem.



Large abrasions (i.e., “road rash”) that are heavily contaminated are difficult to manage in an emergency wound care area because the volume of local anesthetic necessary to achieve anesthesia would exceed toxic limits. In these cases, parenteral sedation is recommended, and in extreme cases, the patient might be better served in the operating room.

One of the most common foreign contaminants of abrasions is road tar or asphalt. If permanently impregnated in skin, tar is a cosmetic disaster because of its dark color. All tar or asphalt particles must be removed during initial wound cleansing and débridement. A cleansing adjunct that is useful for tar removal is polyoxyethylene sorbitan, a nonionic surface-active agent with hydrophilic and lyophilic properties.<sup>35</sup> It is an emulsifying agent that is virtually nontoxic to tissue. This substance is most commonly available as a component of Neosporin antibacterial ointment. Polysporin ointment, with a petrolatum base, is helpful in dissolving tar.<sup>36</sup> The ointment is not as effective, however, and is not water soluble like the cream. The water solubility of the cream makes it easy to wash off after it has been applied to the tar-laden abrasion. Other effective commercial tar removal agents are citrus-based agents derived from orange peels. They are both effective and nontoxic to skin.

When an abrasion is initially cleansed and débrided, follow-up management is usually the patient’s responsibility. The abrasion must be kept clean to prevent secondary infection. Nature’s dry “dressing,” the scab, ultimately does the job, and most abrasions heal without event (neither infectious nor cosmetic). Wound desiccation has been shown experimentally in humans to slow wound healing, however, and impede epithelial cell covering of the injured surface.<sup>37</sup> Dressings provide a moist environment that promotes rapid and effective healing.

For wounds that can be covered easily with a dressing, any nonadherent dressing can be applied over a thin coating of an ointment, such as Neosporin or Polysporin. A variety of dressing materials are available. Adaptic, Telfa, and Vaseline gauze are the least expensive. Other options include products such as membrane (Tegaderm), foam (Epilock), and hydrocolloid (Duoderm) dressings. The dressing can be removed every 2 or 3 days for gentle cleansing and redressing.

Experimentally, topical antibiotic ointments alone have been shown to increase the rate of wound reepithelialization.<sup>38</sup> It is recommended that wounds that cannot be dressed easily should be kept moist with a thin coating of an antibiotic ointment (e.g., Neosporin or Polysporin).<sup>24</sup> The ointment usually is applied two or three times a day to maintain the moist wound environment.

A new and different approach to managing superficial skin wounds and abrasions is octylcyanoacrylate liquid tissue adhesive (Dermabond). Dermabond currently is used to close lacerations and surgical incisions. This liquid adhesive bandage can be applied directly to fresh abrasions with an applicator brush after cleansing and drying.<sup>39</sup> Compared with standard Band-Aid application, liquid adhesive bandage reduces pain and bleeding. It also stays on the wound for 5 days, more than 3 days longer than Band-Aids. The patient is allowed to bathe and can reapply the liquid adhesive bandage as needed. On average, healing is complete in 12 days, which is similar to Band-Aid–treated wounds. Liquid adhesive bandage also has been formulated as a spray that can be applied directly to abrasions.<sup>40</sup>

## REFERENCES

1. Anderson M, Newmeyer W, Kilgore E: Diagnosis and treatment of retained foreign bodies in the hand, *Am J Surg* 144:563-565, 1982.
2. Farrell SE, Vandevander P, Shoffstall JM, et al: Blood lead levels in emergency department patients with retained bullets and shrapnel, *Acad Emerg Med* 6:208-212, 1999.
3. Byron T: Foreign bodies found in the foot, *J Am Podiatr Assoc* 71:30-35, 1981.
4. Rudner E, Mehregan A: Implantation dermatosis, *J Cutan Pathol* 7:330-331, 1980.
5. Cracchiolo A: Wooden foreign bodies in the foot, *Am J Surg* 140:585-587, 1980.

6. Kahn B: Foreign body (palm thorn) in knee joint, *Clin Orthop* 135:104-106, 1978.
7. Steele MT, Tran LV, Watson WA, et al: Retained glass foreign bodies in wounds: predictive value of wound characteristics, patient perception, and wound exploration, *Am J Emerg Med* 16:627-630, 1998.
8. Montano JB, Steele MT, Watson WR: Foreign body retention in glass-caused wounds, *Ann Emerg Med* 21:1365-1368, 1992.
9. Feldman AH, Fisher MS: The radiographic detection of glass in soft tissue, *Radiology* 92:1529-1531, 1969.
10. Tanberg D: Glass in the hand and foot, *JAMA* 248:1872-1874, 1982.
11. Dean AJ, Gronczewski CA, Costantino TG: Technique for emergency medicine bedside ultrasound identification of a radiolucent foreign body, *J Emerg Med* 24:303-308, 2003.
12. Graham DD: Ultrasound in the emergency department: detection of wooden foreign bodies in the soft tissues, *J Emerg Med* 22:75-79, 2002.
13. Lammers RL: Soft tissue foreign bodies, *Ann Emerg Med* 17:1336-1347, 1988.
14. Hill R, Conron R, Greissinger P, et al: Ultrasound for the detection of foreign bodies in human tissue, *Ann Emerg Med* 29:353-356, 1997.
15. Manthey DE, Storrow AB, Milbourn JM, et al: Ultrasound versus radiology in the detection of soft-tissue foreign bodies, *Ann Emerg Med* 28:7-9, 1996.
16. Orlinsky M, Knittel P, Feit P, et al: The comparative accuracy of radiolucent foreign body detection using ultrasonography, *Am J Emerg Med* 18:401-403, 2000.
17. Gilbert FJ, Campbell RS, Bayliss AP: The role of ultrasound in the detection of non-radiopaque foreign bodies, *Clin Radiol* 41:109-112, 1990.
18. Rhoades C, Saye I, Levine E, et al: Detection of a wooden foreign body in the hand using computed tomography: case report, *J Hand Surg* 7:306-307, 1982.
19. Bodne D, Quinn SF, Cochran CF: Imaging foreign glass and wooden bodies of the extremities with CT and MRI, *J Comput Assist Tomogr* 12:608-611, 1988.
20. Davis L: Removal of subungual foreign bodies (Letter), *J Fam Pract* 11:714, 1980.
21. Martinez TT, Jerome M, Barry RC, et al: Removal of cactus spines from the skin: a comparative evaluation of several methods, *Am J Dis Child* 141:1291-1292, 1987.
22. McFadden J: Stereotaxic pinpointing of foreign bodies in the limbs, *Ann Surg* 175:81-85, 1972.
23. Wayne R, Carnazzo A: Needle in the foot, *Am J Surg* 129:599, 1975.
24. Fitzgerald R, Cowan J: Puncture wounds of the foot, *Orthop Clin North Am* 6:965-972, 1975.
25. Houston A, Roy WA, Faust RA, et al: Tetanus prophylaxis in the treatment of puncture wounds of patients in the deep South, *J Trauma* 2:439-450, 1962.
26. Chisholm CD: Plantar puncture wounds: controversies and treatment recommendations, *Ann Emerg Med* 18:1352-1357, 1989.
27. Fischer MC, Goldsmith JF, Gilligan PH: Sneakers as a source of *Pseudomonas aeruginosa* in children with osteomyelitis following puncture wounds, *J Pediatr* 106:607-614, 1985.
28. Jacobs RF, Adelman L, Sack CM: Management of *Pseudomonas* osteochondritis complicating puncture wounds of the foot, *Pediatrics* 69:432-435, 1982.
29. Patzakis MJ, Wilkins J, Brien WW, et al: Wound site as predictor of complications following deep nail punctures of the foot, *West J Med* 150:545-547, 1989.
30. Schwab RA, Powers RD: Conservative therapy of plantar puncture wounds, *J Emerg Med* 13:291-295, 1995.
31. Joseph WF, LeFrock JL: Infections complicating puncture wounds of the foot, *J Foot Surg* 26:S30-S33, 1987.
32. Jarvis JG, Skipper J: *Pseudomonas* osteochondritis complicating puncture wounds in children, *J Pediatr Orthop* 14:755-759, 1994.
33. Doser C, Cooper WL, Ediger WM, et al: Fishhook injuries: a prospective evaluation, *Am J Emerg Med* 9:413-415, 1991.
34. Jeray KJ, Banks DM, Phieffer LS, et al: Evaluation of standard surgical preparations performed on superficial dermal abrasions, *J Orthop Trauma* 14:206-211, 2000.
35. Bose B, Tredget T: Treatment of hot tar burns, *Can Med Assoc J* 127:21-22, 1982.
36. Demling R, Buerstatte W, Perea A: Management of hot tar burns, *J Trauma* 20:242, 1980.
37. Hinman C, Maibach H: Effect of air exposure and occlusion on experimental human skin wounds, *Nature* 200:377-378, 1963.
38. Geronemus R, Mertz P, Eaglstein W: Wound healing: the effects of topical antimicrobial agents, *Arch Dermatol* 115:1311-1314, 1979.
39. Eaglstein WH, Sullivan TP, Giordano PA, et al: A liquid bandage for the treatment of minor cuts and abrasions, *Dermatol Surg* 28:262-267, 2002.
40. Quinn J, Lowe L, Mertz M: The effect of new tissue-adhesive wound dressing on the healing of traumatic abrasions, *Dermatology* 201:343-346, 2000.

# Minor Burns

## INITIAL MANAGEMENT AND PATIENT ASSESSMENT

### BURN ASSESSMENT

- Cause of the Burn
- Body Location
- Depth of the Burn
- Extent of the Burn

## GUIDELINES FOR HOSPITALIZATION

### TREATMENT OF MINOR BURNS

- Epidermal Burns
- Partial-Thickness Burns
- Full-Thickness Burns
- Tetanus and Antibiotic Prophylaxis

The treatment of burns is a common activity for facilities and personnel who care for emergency wounds and injuries. A thorough understanding of the treatment requirements of burns is necessary to properly select patients who can be managed appropriately on an outpatient basis and patients who need referral for specialized care. The depth, type, and extent of the burn; anatomic location; and underlying patient condition all are important factors in making that decision. Although individual treatment aspects of minor burns remain controversial, basic management principles do not vary greatly. The three main principles for treating burn patients are (1) relief of pain, (2) prevention of infection and additional trauma, and (3) minimization of scarring and contracture.<sup>1</sup>

## INITIAL MANAGEMENT AND PATIENT ASSESSMENT

No matter how small or trivial a burn appears, the patient must be assessed for more severe associated problems and injuries. If the patient sustained the burn at the scene of a fire or explosion, immediate evaluation for inhalational injury, carbon monoxide exposure, and other trauma is mandatory. Inhalational injury is the most common cause of mortality in fire victims.<sup>2</sup> Clinical signs of inhalational injury include burned nasal hairs, soot on the face, hoarseness, coughing, shortness of breath, and wheezing. Even if these signs are not present at the outset, an inhalational injury must be suspected in patients who were trapped in an enclosed, smoke-filled space. Respiratory tract injury often is delayed, and observation of the patient for 24 hours may be indicated.<sup>3</sup> Carbon monoxide exposure is suspected in any patient who is alert and has a headache or in a patient with confusion or other alteration of mental status.

When the patient has been initially stabilized, vital signs have been taken, and unnecessary articles of clothing have been removed from the burned area, attention can be turned to the burn itself. The most salient clinical symptom of minor burns is pain. Epidermal (first-degree) and superficial partial-thickness (superficial second-degree) burns can be extremely painful and require immediate pain relief. The simplest and most rapid manner in which to abolish burn pain is to place moist, cool towels over the burned area.<sup>4</sup> Clinical and experimental

evidence shows that the cooling of burned surfaces can decrease the eventual damage to burned tissues.<sup>5-8</sup> The water should not be very cold because excessive cold can compound the burn injury. A water temperature of 8°C (45°F) to 23°C (75°F) seems to be optimal to obtain pain relief and some measure of protection for burned tissue.<sup>6</sup>

Cooling can be effective for 3 hours postburn.<sup>6,9</sup> In a study of children with burns, it was found that only 22% received adequate first aid, including cooling.<sup>10</sup> Immediately on arrival at the care facility, cooling should be initiated to abort the continuing tissue injury. Care must be taken to ensure that large burn areas are not covered with cool, moist towels for excessive periods because hypothermia can set in. In addition to cool towels and sponges, parenteral pain medicine, such as morphine sulfate or meperidine, can be used, especially for patients who have a significant component of anxiety associated with their burns.

While the patient is being stabilized and pain relief is being administered, a thorough history is taken. Important items in the history include the age of the patient, any associated conditions and illnesses, psychosocial considerations, and drug allergies. Patients younger than 2 years old have thin dermis and immature immune systems.<sup>11,12</sup> These children rarely are treated on an outpatient basis. Likewise, patients older than 65 years old tolerate burns poorly and often need inpatient care. Patients with underlying diseases, such as diabetes, pulmonary disease, severe cardiac problems, and disorders requiring long-term immunosuppressive therapy, are at higher risk with burns and require special consideration for hospital management.

Frequently, burn victims have significant psychosocial problems. Similar to automobile trauma victims, burn victims often have alcohol-related or drug-related disorders. Although these impairments may have nothing to do with the treatment of the burn itself, severe alcohol or drug dependency may preclude outpatient management, even for minor burns. The worst psychosocial problem associated with burns is child abuse. Experienced burn care personnel see this catastrophe frequently and tend to think of all children with burns as potential victims of child abuse until proved otherwise. Finally, during the history, a thorough detailing of allergies is necessary because many drugs may be administered or applied to a burn victim during the course of his or her management.

---

## **BURN ASSESSMENT**

### **Cause of the Burn**

Knowing the cause of a burn can make a difference in predicting its depth and extent. Brief scalding burns, which occur with the spilling or splashing of hot water, usually result in epidermal or superficial partial-thickness burns. Burns caused by immersion in a hot liquid or flame contact more frequently cause deep partial-thickness or full-thickness burns. These burns can be complicated and serious, especially when important anatomic parts, such as the hands or face, are involved. Electrical burns almost always cause full-thickness injuries at the burn site. In addition, electrical injuries can be associated with muscle necrosis, fractures, and cardiac arrhythmias.<sup>13</sup>

### **Body Location**

The anatomic location of a burn is an important factor in determining management. Because of the complexity and crucial function of the hands, extensive partial-thickness or full-thickness burns on the hands are best managed, at least at the outset, in a controlled setting. Not only do hand burns require careful cleansing, débridement, and dressing, but also there is a danger of joint stiffening secondary to the immobility caused by pain and edema. Patients must observe strict elevation of the burned extremity in addition to early motion exercises to prevent “freezing” of the hand. This complication occurs more frequently in patients older

than age 50. Partial-thickness burns of the face not only raise the possibility of airway obstruction and inhalational injury, but also they can be difficult to manage surgically.

Burns of the perineum are technically difficult to manage and are extremely uncomfortable for the patient. It is beyond the capabilities of most patients or families to care for these problems at home. Among the most frustrating burns to manage on an outpatient basis are burns of the foot. The dependent nature of this anatomic part and its weight-bearing function cause frequent failure of outpatient management. It is difficult for patients to maintain voluntarily the necessary strict elevation of the legs, failure of which can lead to edema, pain, and tissue breakdown at the burn site.

### Depth of the Burn

Burns traditionally are divided into three depths of tissue injury: epidermal (first-degree burns), partial-thickness (second-degree burns), and full-thickness (third-degree burns). Partial-thickness, or second-degree, burns are subdivided further into superficial and deep partial-thickness burns.

Epidermal, or first-degree, burns are the most common type of burns. Heat induces dermal vasodilation, giving the epidermis its characteristic red color. Blistering does not occur, and these burns heal without treatment. The superficial epidermis sloughs or peels about 5 to 7 days after the burn is sustained, and the vasodilation gradually disappears. Sunburn is the most common example of an epidermal burn. Occasionally, if the heat exposure was especially intense or prolonged, what appears to be an epidermal burn blisters and becomes a superficial partial-thickness burn after 12 to 24 hours.

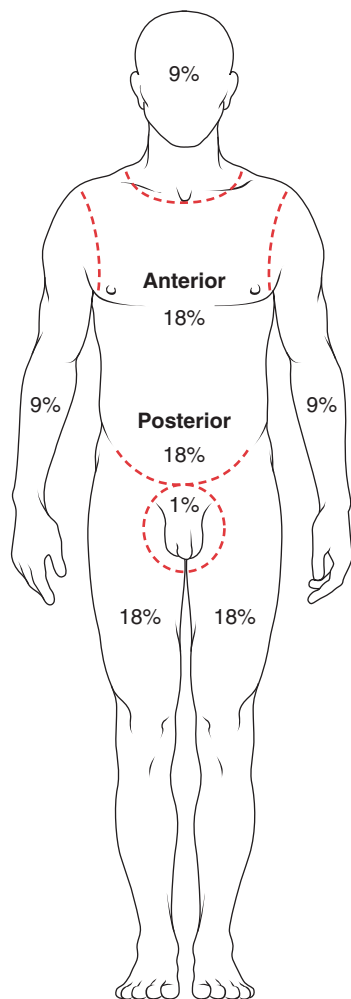
Partial-thickness, or second-degree, burns are so designated because the epidermis and part of the dermis are destroyed. Dermal appendages, such as pilosebaceous units and eccrine sweat glands, survive, however, giving the skin a chance to regenerate epidermis from these preserved dermal foci. These remaining appendages are crucial to eventual healing and recovery.

Clinically, it is important to distinguish between superficial and deep partial-thickness burns. There are important differences in the time they require to heal and in eventual cosmetic appearance. Superficial partial-thickness burns classically blister and are extremely painful. When the necrotic epidermis is removed, the injured dermis is homogeneously pink and moist in appearance. It is extremely sensitive to touch but heals without scarring over 2 to 3 weeks. Deep partial-thickness burns are not as painful to touch, and they appear drier and whiter when débrided. Sometimes the surface of these burns is interspersed with reddish spots, indicating underlying dermal plexus. There still is some awareness of pinprick, however, and some of the dermal appendages are preserved. These burns take longer than 3 weeks to heal.

With full-thickness, or third-degree, burns, the dermis and the dermal appendages are totally destroyed. A dry, taut, leather-like surface that is insensitive to examination or pinprick characterizes the appearance of these burn injuries. The color of these burned areas can vary from white to brown to black. There is frequent difficulty in distinguishing between deep partial-thickness and full-thickness burns on initial presentation of a patient to a wound care facility. Often these two types of burns are treated in the same manner and require grafting for final coverage of the damaged area.

### Extent of the Burn

Proper estimation of the extent of body surface area affected is crucial to burn management. Only partial-thickness (second-degree) and full-thickness (third-degree) injuries are considered in the calculation. The "rule of nines" is adequate for initially estimating burn size in adults (Fig. 17-1). Surface anatomy can be divided into areas that represent 9% or multiples



**Figure 17-1** Rapid estimation of burn extent can be determined by the rule of nines. Only partial-thickness (second-degree) and full-thickness (third-degree) burns are considered for percentage area determination.

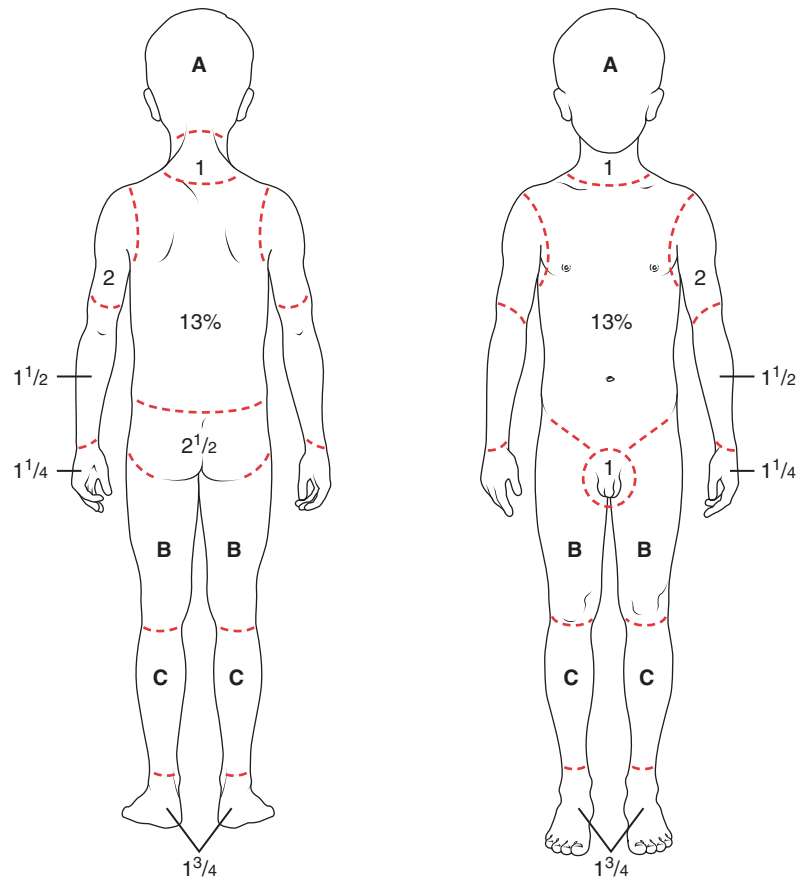
of 9% of the body surface. The head and each arm constitute a 9% surface area apiece, whereas one leg is 18%. The entire surface area of the thorax and abdomen combined, anterior and posterior, is 36%.

Greater precision in estimating burn size can be obtained by using standard, more detailed charts that subdivide the anatomic parts. These diagrams also take into account the variations in surface area that occur with age (Fig. 17-2). In young children, the surface area of the head constitutes a much greater area relative to the rest of the body than in adults. As an individual grows, the lower extremities get proportionately larger, whereas the trunk and arm proportions stay relatively the same throughout life. Final surface area proportions are not reached until after age 15.

---

### **GUIDELINES FOR HOSPITALIZATION**

Box 17-1 lists suggested criteria for hospital management of burns. Patients not meeting these criteria can be considered victims of minor, partial-thickness burns and can be treated



Area	Age 0	1 yr	5 yr	10 yr	15 yr
A = 1/2 of head	9 1/2%	8 1/2%	6 1/2%	5 1/2%	4 1/2%
B = 1/2 of one thigh	2 3/4	3 1/4	4	4 1/4	4 1/2
C = 1/2 of one leg	2 1/2	2 1/2	2 3/4	3	3 1/4

**Figure 17-2** Estimation of burn size in children. The relative area sizes change significantly with age.

as outpatients. Different authorities vary on what constitutes an appropriate burn size that can be treated without having to admit the patient to a hospital. The total extent of burn limit for outpatient management varies from 10% to 15% of the area that has sustained a superficial burn.<sup>5,12</sup> The author, who advocates 10% burn surface area as the cutoff point, believes that pain relief, initial cleansing, débridement, and patient education are best accomplished in a controlled patient setting. Highly motivated, responsible adults with good family support systems are likely to do well on an outpatient basis with burns approaching the 15% range.

## BOX 17-1

**Guidelines for Hospital Admission of Burn Victims**

1. Partial-thickness burns >15% surface area (>10% surface area of child)
2. Full-thickness burns >3% surface area
3. Suspected inhalational injury
4. Age <2 or >65 years
5. Partial-thickness or full-thickness burns of hands, face, perineum, or feet
6. Electrical burns
7. Severe underlying systemic disease
8. Acute alcohol or drug abuse
9. Suspected child abuse

Children are managed best on an inpatient basis with any partial-thickness burn that is greater than 10%. Pain relief, wound cleansing, débridement, and dressings are easier to manage in the hands of experienced personnel. After the parents recover from the trauma, they can be educated properly in the care of the burn before the child is discharged. Except for the most trivial burn, children younger than 2 years old should be managed in the hospital. On the other end of the age scale, it is recommended that patients older than age 65 be considered for similar treatment.

As previously discussed, burns in crucial anatomic locations, such as the hands, feet, face, and perineum, are managed best in an inpatient setting. Full-thickness burns of greater than 3% of the body surface area require surgical management and grafting. Even smaller full-thickness burns, if initially treated outside the hospital, need to be referred to a specialist for continued management and possible later skin grafting.

If there is any suspicion of inhalational or airway injury, no matter how small or superficial the burn, the patient must be admitted for observation. Inhalational injury can be insidious, and overt signs and symptoms often do not appear for several hours postexposure.<sup>3</sup> Finally, the decision to treat patients in the hospital often is determined by the extent of underlying disease, alcohol or drug abuse, and suspicion of potential child abuse.

## TREATMENT OF MINOR BURNS

Most burns that are treated on an outpatient basis are epidermal or superficial partial-thickness burns. Because these burns tend to have an overwhelmingly favorable outcome regardless of treatment, some of the controversies over management are not crucial. For the sake of completeness, however, these controversies are mentioned in context with each management step.

### Epidermal Burns

Epidermal, or first-degree, burns usually are called to the attention of medical care personnel only if the burns are extensive or extremely painful. A gentle cleansing with a nonirritating soap, such as Ivory Flakes or Dreft, mixed in a solution of cool saline is recommended. Diluted (with 2 to 4 parts cool saline) chlorhexidine (Hibiclens) also can be used.<sup>1</sup> For home symptom relief, the patient can apply many commercial preparations containing at least 60% aloe vera. Not only does aloe vera have some antimicrobial activity, but also it provides local pain relief.<sup>11,12</sup> Analgesia can be supplemented with aspirin, ibuprofen, acetaminophen, or codeine for 48 to 72 hours, after which the acute pain eventually subsides.



These burns usually heal within 5 to 7 days after going through epidermal desquamation. Occasionally, epidermal burns convert to superficial-thickness injuries, with blistering 12 to 24 hours after heat exposure. If this conversion occurs, the patient should return to a medical care facility or contact the primary care physician.

## **Partial-Thickness Burns**

### *Cleansing*

Partial-thickness burns also are managed best by an initial cleansing with a nonirritating soap (e.g., Dreft) or with chlorhexidine (Hibiclens) diluted in 2 to 4 parts of cool saline. Ice chips can be mixed into the solution to provide a cooling effect. Hair can be clipped but should not be shaved with a razor in the burn site to prevent any further damage to the remaining dermal appendages from which new epidermis arises.<sup>14</sup> To effectively clean and débride a partial-thickness burn, which is extremely sensitive to touch or manipulation, a parenteral narcotic often is recommended for the patient.

### *Blisters and Débridement*

When cleansing has taken place, the next step is débridement. Obviously necrotic and partially sloughed epidermis and dermis are removed by using forceps and tissue scissors. This skin is dead and insensitive; therefore local anesthetics are not required. A controversy in burn management is whether to remove intact blisters. Proponents for blister removal point to the ideal culture media that blister fluid represents with a concomitant risk of burn infection.<sup>12</sup> There is clinical and experimental evidence, however, that leaving blisters intact has several beneficial effects on burn wounds.<sup>15-17</sup> Intact blisters tend to prevent capillary stasis and retard necrosis within burn injury sites and decrease desiccation of the burn wound. It also is believed that retention of blisters aids in the control of pain, a benefit that is especially important over joint surfaces, where pain can limit active movement, leading to potential joint stiffness.<sup>18</sup> As a general rule, large confluent blisters are likely to break easily and should be removed. Small intact blisters on the hands, feet, and over joints should be left intact. It can be argued that blisters on noncompliant patients should be removed to prevent infection from neglect or improper home care.

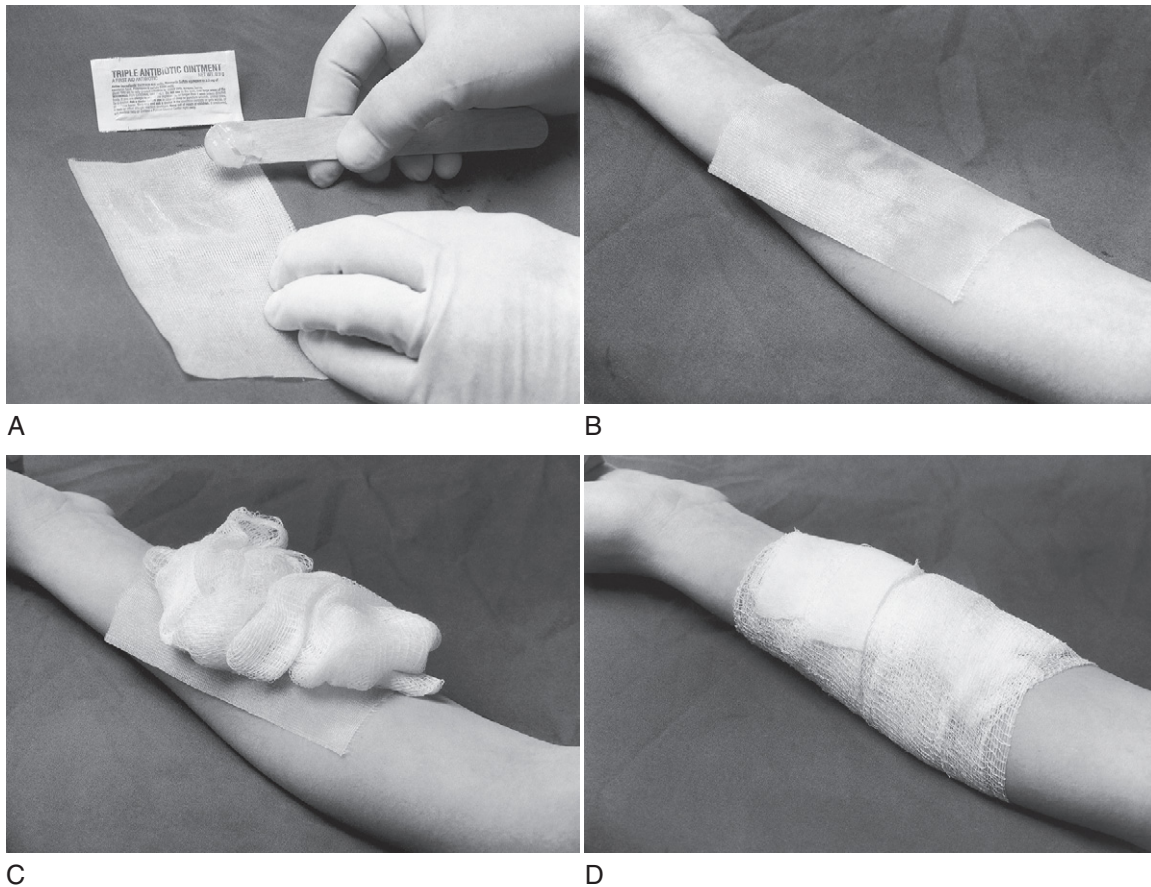
### *Burn Dressing*

Preferences for burn dressing vary widely among practitioners. Topical treatments range from no agent at all to a variety of topical antibiotics and several newer synthetic wound coverings. Because the eventual outcome of limited superficial partial-thickness burns is uniformly good, there is no clear preference for one agent or dressing over another. Small partial-thickness burns, if kept clean and protected, heal without ointments or specialized dressings.

Uncomplicated partial-thickness burns of the head and neck, for practical reasons, are best left open during treatment. Gentle cleansing one to two times a day followed by application of antibacterial ointment leads to complete healing in 2 to 3 weeks.

The open method is an alternative for small burns of the hand. The advantages are maintenance of mobility and flexibility of the hand, freedom from dressing changes, and continued partial use. Because of continued wound exudate and the need to maintain antibacterial ointment on the burn, the open method can be problematic.

Most other partial-thickness and full-thickness burns are treated with burn dressings (Fig. 17-3). After cleansing and débridement, the burned area is covered with an antibacterial ointment or cream with a gloved finger or sterile applicator. Petroleum-based ointments, such as bacitracin or polymyxin B sulfate/bacitracin (Polysporin), are preferred for ease of application, enhanced wound healing, and good suppression of bacterial colonization.<sup>11</sup>



**Figure 17-3** Burn dressing application. **A**, Petroleum-based antibiotic ointment is applied to fine mesh gauze. **B**, The impregnated gauze is placed over burn area. **C**, Gauze “fluffs” made from sponges are added to the base to absorb burn wound exudate. **D**, The dressing is completed with a gauze bandage wrap and strips of adhesive tape.

Ointment is followed by a single layer of fine-mesh gauze or a nonadherent material, such as Adaptic. Gauze “fluffs,” created by unfolding gauze 4 × 4 sponges, are packed over the fine-mesh gauze layer. The fluffs absorb copious drainage created by the fresh wound. The dressing is anchored with gauze bandage roll and tape strips.

Silver sulfadiazine (Silvadene) is an effective antibacterial but is impractical for open treatment and can form a pseudomembrane over partial-thickness burns that is difficult and painful to remove. It cannot be used in patients with sensitivity to other sulfa drugs, and transient leukopenia has been reported with this agent.<sup>19</sup> Silver sulfadiazine has a long record of effectiveness in large burns but has been challenged as the agent of choice for minor burns.<sup>20</sup> At the burn center at the University of Cincinnati, petrolatum-based antibacterial agents are preferred over silver sulfadiazine for the treatment of minor burns.

The interval between dressing changes varies among practitioners. Many burn authorities recommend twice-daily changes to maintain the effectiveness of the antibacterial

ointment or cream. In practicality, once-daily changes are probably sufficient for limited partial-thickness burns. Patients are sent home with specific instructions and burn supplies as listed. The follow-up interval varies based on the compliance and motivation of the patient and the extent and location of the burn. Burns of the hand need close follow-up with a visit to a caregiver within 48 to 72 hours of the injury. Further visits are individualized.

Honey, an age-old treatment for wounds, has been shown more recently to be an effective agent for minor burns.<sup>19</sup> It is simple, natural occurring, and inexpensive and has excellent antibacterial properties.<sup>19</sup> Compared with patients treated with silver sulfadiazine for partial-thickness burns, honey-treated patients had comparable outcomes. Although honey is not likely to replace current agents for burn management, it is a valid alternative in care settings that have limited resources.

Synthetic dressings offer another alternative for patients with limited partial-thickness burns. Many products are on the market, including DuoDerm, Opsite, Vigilon, and Biobrane. These dressings can be applied to fresh burns that have been cleaned and débrided of dead skin and any debris.<sup>21</sup> The dressing is cut in a customized manner to correspond to the burn site with approximately a 1- to 2-cm marginal overlap. An outer gauze wrap is applied to maintain dressing adherence and absorb excessive exudate. These dressings afford good pain relief and can be left on for the duration of the healing. They are time-consuming, however, and difficult to apply. They can dry, crack, and peel at the edges.<sup>22</sup> These dressings are not suitable for covering joints or large areas. Use of these dressings should be in consultation and agreement with the caregiver responsible for follow-up and ongoing care when the patient leaves the emergency department.

### **Home Management and Follow-Up**

Burn supplies, including gauze sponges, gauze wrap, antibacterial soap, and a sterile tongue depressor, are dispensed or prescribed along with written and verbal instructions on how to use them. A small jar or tube of topical antimicrobial agent also is dispensed or prescribed. The patient is instructed to remove the first dressing the morning after his or her first wound care visit. The burned area is washed gently with the soap and two or three of the sterile sponges provided. A topical agent is spread over the wound, and gauze wrapping is applied. Some authorities believe that the first dressing can remain in place for 2 or 3 days. At the University of Cincinnati burn center, it is believed that once- or twice-a-day changes prevent the exudate buildup and crusting that can disrupt epithelialization when infrequent dressing changes are made. There is no clear evidence to support any specific dressing change interval for minor burns.

All minor burn victims are seen in follow-up 48 hours after initial treatment. From that time on, individualized treatment regimens are prescribed. Strict elevation of the burned part is essential to proper healing. The use of slings for upper extremity and hand burns can accomplish this goal while the patient is in an upright position. Gentle but frequent motion of joints within the burn-injured anatomic parts also is mandatory. Pain often deters a patient from this activity, so appropriate oral medication, such as aspirin, ibuprofen, acetaminophen, or codeine, may be required early during convalescence. Usually, however, if the patient thoroughly understands the need for joint motion, cooperation with burn care personnel quickly follows despite some wound discomfort.

### **Full-Thickness Burns**

Full-thickness burns that cover less than 3% of the body surface area and that are in a noncritical site (hand or face) can be treated in the manner described previously for partial-thickness burns. Before proceeding, however, it is best to discuss the case with a consultant. These patients require close follow-up care, and initial treatment decisions are best made in concert with a consultant.

## Tetanus and Antibiotic Prophylaxis

Finally, tetanus prophylaxis and the possibility of wound infection need to be considered. Tetanus toxoid and tetanus immune globulin should be given to all burn patients in accordance with the recommendations in Chapter 21. Currently, no studies support the use of prophylactic oral or parenteral antibiotics in minor superficial burns.<sup>16,23,24</sup> Control and antibiotic-treated groups consistently yield the same infection rate of approximately 3% to 4%. Should a burn wound infection develop, it is best managed with local wound care and appropriate antibiotics at that time.<sup>25</sup>

## REFERENCES

1. Baxter CR, Waacklerle JF: Emergency treatment of burn injury, *Ann Emerg Med* 17:1305-1315, 1988.
2. Trunkey D: Inhalation injury, *Surg Clin North Am* 58:1133-1140, 1978.
3. Achauer B, Allyn PA, Furnas DW, Bartlett RH: Pulmonary complications of burns, *Ann Surg* 177:311-319, 1973.
4. Gruber RP, Laub DR, Vistness LM: The effect of hydrotherapy on the clinical course and pH of experimental cutaneous chemical burns, *Plast Reconstr Surg* 55:200-203, 1975.
5. Cone JB: Minor burns: standards for outpatient treatment, *Consultant* 27:37-42, 1987.
6. Davies J: Prompt cooling of burned areas: a review of benefits and the effector mechanisms, *Burns* 9:1-6, 1983.
7. Pushkar N, Sandorminsky B: Cold treatment of burns, *Burns* 9:101-110, 1983.
8. Saranto J, Rubayi S, Zawacki B: Blisters, cooling, antithromboxanes, and healing in experimental zone-of-stasis burns, *J Trauma* 23:927-933, 1983.
9. Raine TJ, Hegggers JR, Robson M, et al: Cooling the burned wound to maintain microcirculation, *J Trauma* 21:394-397, 1981.
10. McCormack RA, La Hei ER, Martin HCO: First-aid management of minor burns in children: a prospective study of children presenting to the Children's Hospital at Westmead, Sydney, *Med J Aust* 178:31-33, 2003.
11. Griglak MJ: Thermal injury, *Emerg Clin North Am* 10:369-383, 1992.
12. Heimbach D, Engrav L, Marvin J: Minor burns, *Postgrad Med* 69:22-32, 1981.
13. Sances A Jr, Larson SJ, Myklebust J, Cusick JF: Electrical injuries, *Surg Gynecol Obstet* 149:97-108, 1979.
14. Shuck J: Outpatient management of the burned patient, *Surg Clin North Am* 58:108-117, 1978.
15. Moserova J, Runtova M, Broz L: The possible role of blisters in dermal burns, *Acta Chir Plast* 25:51-53, 1983.
16. Moylan J: Outpatient treatment of burns, *Postgrad Med* 73:235-242, 1983.
17. Zawacki B: Reversal of capillary stasis and prevention of necrosis in burns, *Ann Surg* 180:98-102, 1974.
18. Swain AH, Azadian BS, Wakeley C, Shakespeare PG: Management of blisters in burns, *BMJ* 295:181, 1987.
19. Subrahmanyam M: A prospective randomized clinical and histological study of superficial burn wound healing with honey and silver sulfadiazene, *Burns* 24:157-161, 1998.
20. Chung YJ, Herbert ME: Myth: silver sulfadiazine is the best treatment for minor burns, *West J Med* 175:205-206, 2001.
21. Curreri PW, Desai MH, Bartlett RH, et al: Safety and efficacy of a new synthetic burn dressing, *Arch Surg* 115:925-927, 1980.
22. Warren R, Snelling C: Clinical evaluation of the Hydron gel burn dressing, *Plast Reconstr Surg* 66:361-368, 1980.
23. Boss WK, Brand DA, Acampora D, Barese S, Frazier WH, et al: Effectiveness of prophylactic antibiotics in the outpatient treatment of burns, *J Trauma* 25:224-227, 1985.
24. Timmons M: Are systemic prophylactic antibiotics necessary for burns? *Ann R Coll Surg Engl* 65:80-81, 1983.
25. Richards R, Mahlangu G: Therapy for burn wound infection, *J Clin Hosp Pharm* 6:223-243, 1981.

# Cutaneous and Superficial Abscesses

**CLINICAL PRESENTATIONS****MICROBIOLOGY OF ABSCESSES****MANAGEMENT OF ABSCESSES**

Technique for Incision and Drainage  
Special Treatment Settings

**FOLLOW-UP CARE****ANTIBIOTIC USE IN ABSCESS CARE**

Cutaneous and other superficial abscesses commonly are diagnosed and treated in emergency departments. The procedural nature of abscess care makes it a problem with technical requirements similar to those for wound and laceration treatment. Although drainage is the key therapeutic intervention for all abscesses, significant differences between types and locations exist and necessitate individualized treatment. Most cases can be managed in the emergency department with routine outpatient follow-up care. A few cases require specialist consultation, however, for possible operative intervention or inpatient management.

## CLINICAL PRESENTATIONS

A cutaneous abscess is defined as a “localized collection of pus causing a fluctuant soft tissue swelling surrounded by firm granulation tissue and erythema.”<sup>1</sup> Abscesses can begin as furuncles, which are firm, red, tender nodules that become fluctuant and, if left untreated, drain spontaneously. Cutaneous abscesses can occur on any body surface but tend to be more common in certain areas.<sup>1</sup> The most common sites are head, neck, axillae, and buttock and perineal areas. Carbuncles are deep abscesses, with multiple loculations, that occur at the nape of the neck, back, and thighs. Any interruption of the protective layers of the skin, even trivial, with subsequent invasion of exogenous or endogenous microflora, can lead to abscess formation. Abscesses are commonly a result of an obstruction of the apocrine and sebaceous glands. Sebaceous glands are widely distributed over the body, and apocrine glands are found most commonly in axillae and anogenital regions. These glands frequently form cysts that are prone to abscess formation.

Of special note are abscesses that arise on the upper lip and nose. Infections in these sites drain through the facial and angular emissary veins to the cavernous sinus. As discussed in the following section, antibiotics are indicated in the treatment of these lesions.

A common and difficult condition to manage that predisposes to abscess formation is hidradenitis suppurativa,<sup>2</sup> which is a chronic, relapsing, inflammatory involvement of apocrine glands of the axillae and pubic regions. Abscess formation is followed by extensive, excessive scarring. Recurrent abscess formation also predisposes to fistula tracks, skin and subcutaneous induration, and inflammation in various stages of progression. Emergency management is limited to incision and drainage of the discrete abscesses. These patients require long-term

care and a program of management best coordinated and carried out by specialists (e.g., dermatologists or surgeons).

Although breast abscesses commonly are associated with the postpartum period, more than 90% occur outside of that period.<sup>3</sup> Postpartum mastitis, which can occur in nursing mothers 2 to 6 weeks after delivery, predisposes to abscess formation. It is caused by an invasion of *Staphylococcus aureus* through sore, abraded nipples. These patients are often quite sick from extensive local involvement, pain, and chills and fever. Nonpuerperal abscesses can occur in superficial and deep tissues of the breast. Superficial abscesses can be cutaneous or periareolar. Periareolar abscesses arise from occluded ducts and are associated with multiple organisms, including anaerobes. These abscesses involve mammary and ductal tissue. Superficial abscesses, most often resulting from *S. aureus*, are less complicated.

Deep breast abscesses are either intramammary or retromammary. As is the case for periareolar abscesses, fluctuance can be difficult to detect. Fluctuance also is difficult to diagnose when overlying cellulitis is deep and extensive. In these cases, needle aspiration may be required to ensure the proper treatment (i.e., incision and drainage).

Bartholin's glands, located in the vestibule of the vagina, can form cysts from ductal occlusion. These cysts can go on to abscess formation secondary to infection from *Neisseria gonorrhoeae*, enteric organisms, and anaerobic bacteria. In addition to the abscess, the labium usually is inflamed and tender. These abscesses can be confused with periovarular cutaneous abscesses arising from an infected pubic hair. In addition to drainage and catheter placement as described subsequently, it is recommended that sexually active patients be considered for treatment with antigonorrheal and antichlamydial antibiotics.

Pilonidal abscesses arise from cysts that form within embryologic remnant sinuses in the sacrococcygeal area. Patients often present with painful induration of the buttock crease. Fluctuance may not be appreciated; needle aspiration is sometimes necessary to diagnose purulence. Cultures reveal gram-negative enteric organisms and anaerobes. These abscesses often recur unless the sinuses are excised after initial drainage.

Buttock abscesses are common but must be clinically distinguished from perianal and perirectal infections. Buttock abscesses occur cutaneously and do not involve the anus. Perianal abscesses arise from anal crypts and impinge on the anal sphincter. In contrast to patients with buttock abscesses, rectal examination is painful for patients with perianal abscesses. Perianal abscesses often are associated with fistula in ano. The presence of a perianal abscess also might point to other serious, related abscesses and infections of the ischioanal, intersphincteric, and pelvirectal areas. Patients with these abscesses complain of deep rectal or pelvic pain. They often have fever and appear toxic, as manifested by diaphoresis and tachycardia. A rectal examination reveals marked tenderness of the anal sphincter and rectum. Masses can be palpated with the examining finger. This condition requires urgent intervention by a consultant in an operative setting.

A common problem seen by emergency physicians is abscess formation in parenteral drug users. Not only are the patients at risk for bacterial tissue invasion, but also chemical irritants can provoke intense and extensive involvement. These abscesses are often extensive and involve the thighs, buttocks, or forearms. Parenteral drug users have a high incidence of other infectious complications, such as hepatitis, endocarditis, and human immunodeficiency virus-related disorders. Caregivers are urged to observe strict blood and body fluid precautions when draining the patient's abscesses.

---

## MICROBIOLOGY OF ABSCESSES

A large variety of bacteria can be cultured from abscesses. Most lesions are polymicrobial with an average of one aerobic and two anaerobic species per abscess.<sup>4</sup> *S. aureus* is the most

common aerobe.<sup>1,4,5</sup> It can be found in most sites with the axilla and upper extremity predominating. Anaerobes, including *Bacteroides* species, are more likely to be recovered from the groin, vulvovaginal, buttock, and perirectal areas. For reasons that are not clear, *Proteus mirabilis* commonly is associated with abscesses in the head and neck regions, trunk, and axilla.<sup>1</sup> Although 43% of abscesses have no growth, many patients are placed on antibiotics or self-medicate in the early stages of inflammation and swelling.<sup>6</sup>

Because incision and drainage alone are effective for treating abscesses, Gram stains and cultures are not routinely necessary.<sup>1</sup> These diagnostic procedures are recommended for patients with systemic symptoms (indicating extensive involvement), diabetics, parenteral drug users, and patients with conditions causing immunosuppression. In parenteral drug users with fever, blood cultures are recommended before the drainage procedure.

The treatment manipulation of incision and drainage of an abscess carries a risk of transient bacteremia in 30% of cases. Studies have been inconsistent, however, in documenting the risk.<sup>7-9</sup> The bacteremia is brief and is likely of no clinical consequence in otherwise healthy patients. Nevertheless, prophylaxis (see later section) is prudent in certain patients.

---

## MANAGEMENT OF ABSCESES

When confronted with a suspected abscess, palpation does not always reveal fluctuance. Abscesses on the back of the neck, sacrococcygeal area, buttocks, and thighs can be deep or accompanied by significant overlying tissue induration. Whenever an abscess is suspected but clinically not evident, needle aspiration can be carried out with an 18G needle attached to a 5- or 10-mL syringe. The presence of aspirated pus provides the evidence needed to carry out a full incision and drainage.

With the emergence of ultrasound as a diagnostic tool in the emergency department, this technique can be used to diagnose pus accumulation in cases in which aspiration has failed, but the clinical setting is consistent with abscess formation.<sup>10</sup> Ultrasound can guide needle aspiration to confirm the presence and location of the abscess cavity. Drainage is facilitated, and ultrasound can be used in follow-up to confirm resolution.

When pus is not aspirated, the inflammatory mass, or furuncle, has not suppurated. Attempts at incision and drainage are not indicated. In this setting, the patient is placed on antibiotics and twice-daily warm compresses or soaks. The furuncle either heals or goes on to form pus and require drainage. The patient is advised of either possibility and given appropriate follow-up. Usually, within 48 to 72 hours, the furuncle "declares" itself (i.e., begins resolution or suppurates). For choice of antibiotics, see the section on antibiotic use.

In patients with cardiac valvular disease, prophylactic antibiotics as recommended by the American Heart Association should be administered before incision and drainage.<sup>11</sup> Antibiotic prophylaxis also should be considered in patients with implanted orthopedic or other medical devices. Cefazolin, 2 g intravenously, before the procedure is recommended. In  $\beta$ -lactam-allergic patients, 900 mg of clindamycin intravenously or 1 g of azithromycin intravenously is an appropriate choice.

### Technique for Incision and Drainage

When the presence of pus has been established, either by palpation of fluctuance or by aspiration, the abscess site is briefly cleaned with a wound cleansing solution. Wound cleansing of these obviously contaminated sites is carried out to render the field clear of gross contaminants and to prevent extraneous microflora from contaminating any wound cultures should they be indicated.

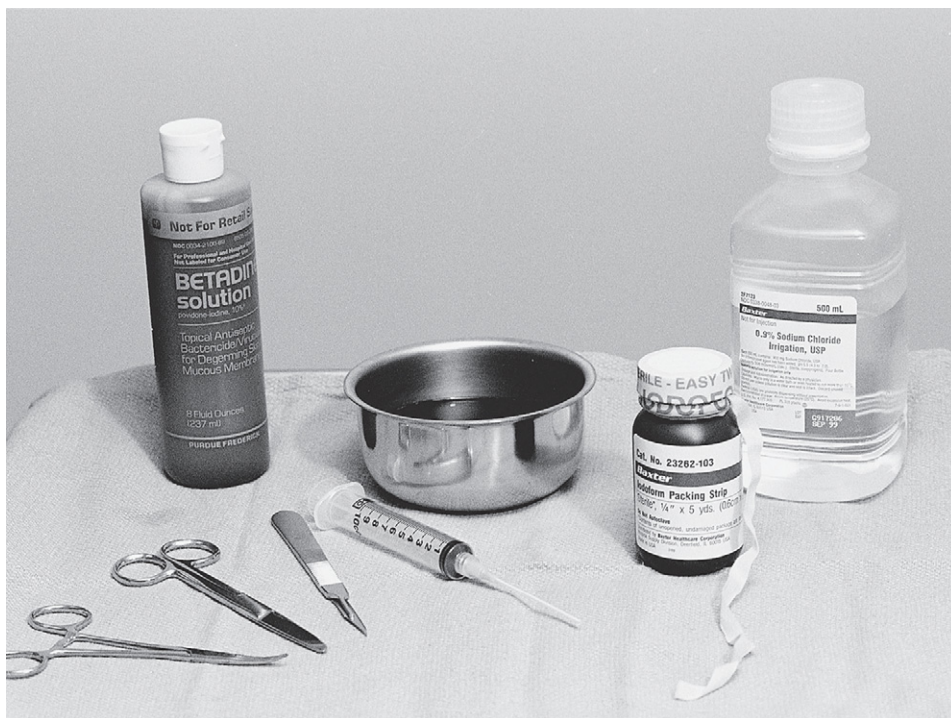Incision and drainage manipulations are painful. For small abscesses (<5 cm in diameter), a field block followed by injection of the abscess roof often suffices for pain control.

Parenteral narcotics and intravenous sedation techniques, as described in Chapter 6, can bring considerable relief to the patient. Even with parenteral pain relief or sedation, the incision site is always anesthetized with a local anesthetic.

The instruments and items needed to drain an abscess include a knife handle and no. 11 blade, a hemostat, gauze packing, and an irrigation syringe mated to a 16G or 14G plastic intravenous catheter (Fig. 18-1). When the field of local anesthesia is created, an incision that is the full length of the fluctuance or, at minimum, two thirds of the diameter of the abscess cavity itself (Fig. 18-2) is made. A common mistake is to make a small, stab-like incision. Wide incisions are necessary to provide for adequate cavity probing and loculation disruption, irrigation, and packing placement.

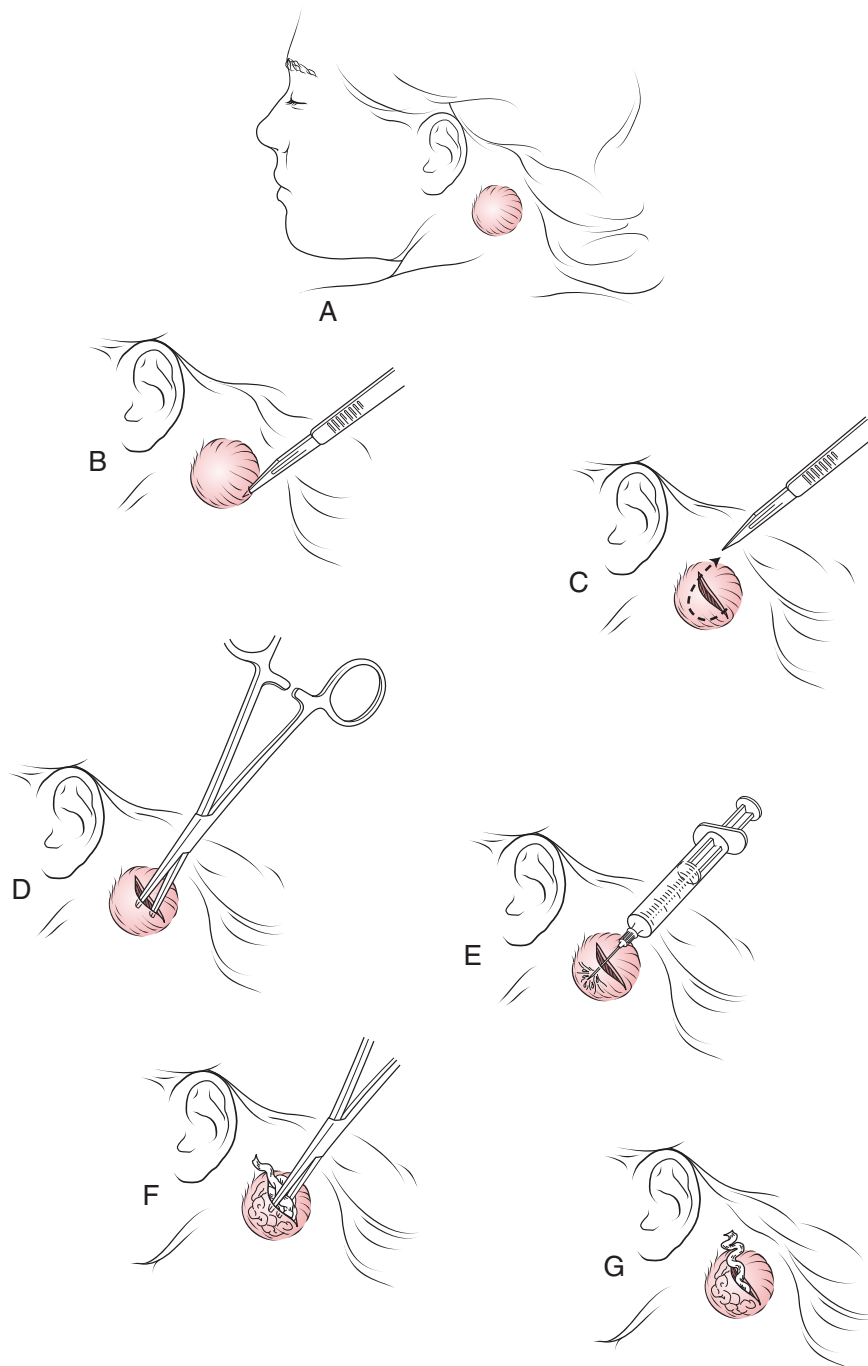
After the incision, the operator gently probes the abscess cavity with either a hemostat or a finger. When all of the abscess cavity surfaces have been explored and loculations broken up, irrigation with saline is carried out through the catheter until all purulence is evacuated. Drainage is considered adequate when the saline effluent is free from pus and appears blood tinged.

The final step in the procedure is to pack the abscess cavity gently and loosely with plain or medicated gauze. For small abscesses drained in the emergency department,  $\frac{1}{4}$ - or  $\frac{1}{2}$ -inch-wide gauze strips are adequate. The purpose of the gauze packing is to promote continued drainage from the abscess cavity. Excessive packing of the cavity can create the direct opposite of the intended outcome. Packing at the incision opening can become encrusted with dried purulence, causing an iatrogenic obstruction to further drainage.



**Figure 18-1** Instruments and materials commonly used to lance, drain, and pack a cutaneous abscess.





**Figure 18-2** Procedure for abscess drainage. **A**, Typical cutaneous abscess. **B**, A scalpel with no. 11 blade is used to “lance” fluctuant mass. **C**, The incision should be generous and at least two thirds of the diameter of the cavity. **D**, A hemostat is used to probe the cavity and gently break up loculations. **E**, The cavity is irrigated until the effluent is clear of purulence. **F**, Gauze tape is used to pack the cavity. Caution is taken not to overpack and obstruct subsequent flow and drainage of remaining purulence. **G**, A 2- to 3-inch tail is left to prevent incision site closure and to aid in packing removal at a later time (2 to 3 days postprocedure).

A bulky dressing, with many gauze sponges or layers, is placed over the site to absorb the inevitable continued purulent drainage. This dressing remains in place for 48 to 72 hours, at which time it is removed and the abscess is inspected.

### Special Treatment Settings

Cutaneous abscesses caused by sebaceous cysts are drained in the manner described previously. These abscesses recur, however, as long as the cyst remains. After drainage, the abscess cavity should be allowed to heal completely. The cyst can be removed easily in its entirety when it is not inflamed. Attempts to remove it at the time of abscess intervention are met only with failure. The cyst wall, at that time, is friable and easily tears. Even if a small fragment of the wall is left behind, a new cyst forms with the resultant return in risk for new abscess formation. After incision and drainage, patients should be referred for later cyst removal after all inflammation has subsided.

Because of the cosmetic concerns involved in the treatment of facial abscesses, consultation might be required. When draining a facial abscess, any incision has to conform to the tension lines as discussed in Chapter 3.

Uncomplicated superficial breast abscesses can be incised and drained as described previously. It is important, however, to make the skin incision in a radial orientation using the nipple as the "hub." Periareolar, intramammary, and deep breast abscesses can be difficult to drain and often are best drained under general anesthesia in an operative setting by a consultant.

The drainage of Bartholin's abscesses is carried out using a specially designed Word catheter.<sup>12</sup> To avoid excessive bleeding during the procedure, the drainage incision is made on the medial wall of the abscess closest to the introitus. Incisions carried out laterally on the labial surface tend to bleed secondary to the vasodilation in that area caused by the inflammatory response to the infection. When the incision is made and irrigation completed, the catheter is inserted and inflated. In contrast to other abscesses, the incision for Bartholin's abscesses is smaller so that the catheter, which has a narrow diameter, remains secure and does not fall out prematurely. Sitz baths can begin immediately for comfort and encouragement of drainage. The catheter is left in for 4 to 6 weeks to allow epithelialization of the drainage track and to lessen the risk of recurrence.

Pilonidal abscesses are drained through generous incisions and packed in the standard manner. These patients are referred for definitive treatment by a consultant, particularly if recurrence has become a problem. Buttock abscesses also are treated as described earlier. Caution is urged in attempting to drain a perianal abscess. These abscesses are exceedingly painful to manipulate and can indicate deeper involvement within the pelvirectal spaces. Consultation should be considered for these abscesses.

---

### FOLLOW-UP CARE

Most small cutaneous abscesses treated in the emergency department require a single packing that stays in place 2 to 3 days. On the first return follow-up visit, the dressing and packing are removed. With successful drainage, the patient reports significant pain relief, and there is minimal continued drainage. For these patients, a regimen of daily wound soakings for 20 to 30 minutes for approximately 1 week suffices to maintain any further drainage until the abscess heals. Abscess cavities heal within 1 to 2 weeks. If the abscess is large and there is continued drainage, repacking can be carried out at 2- to 3-day intervals as necessary. If the patient complains of unremitting pain and discomfort at the drainage site on the first return visit, an undrained cavity or loculation should be considered.

---

## ANTIBIOTIC USE IN ABSCESS CARE

For common, uncomplicated cutaneous abscesses, incision and drainage is curative. Antibiotics offer no advantage.<sup>13-15</sup> Under certain conditions, however, antibiotics are recommended. When the abscess is surrounded by cellulitis that extends well beyond the margins that might be accounted for by the abscess alone, antibiotics are prescribed as an adjunct. Other indications include systemic toxicity as indicated by fever and chills, underlying comorbid condition (diabetes, disease-induced or drug-induced immunosuppression), face location, and cardiac valve disorder. A first-generation cephalosporin (Keflex, Velosef), clindamycin (Cleocin), ciprofloxacin, or a macrolide provides coverage for the common organisms. Cardiac prophylaxis is administered as noted under management of abscesses.

## REFERENCES

1. Meislin HW, Lerner SA, Graves MH, et al: Cutaneous abscesses: anaerobic and aerobic bacteriology and outpatient management, *Ann Intern Med* 87:145-149, 1977.
2. Paletta C, Jurkiewicz MJ: Hidradenitis suppurativa, *Clin Plast Surg* 14:383, 1987.
3. Scholefield JH, Duncan JL, Rogers K: Review of a hospital experience of breast abscesses, *Br J Surg* 74:469, 1987.
4. Meislin HW, McGehee MD, Rosen P: Management and microbiology of cutaneous abscesses, *J Am Coll Emerg Physicians* 7:186-191, 1978.
5. Ghoneim ATM, McGoldrick J, Blick PWH, et al: Aerobic and anaerobic bacteriology of subcutaneous abscesses, *Br J Surg* 68:498-500, 1981.
6. Garcea G, Lloyd T, Jacobs M, et al: Role of microbiological investigations in the management of non-perineal cutaneous abscesses, *Postgrad Med J* 79:519-521, 2003.
7. Bobrow BJ, Pollack CV, Gamble S, et al: Incision and drainage of cutaneous abscesses is not associated with bacteremia in afebrile adults, *Ann Emerg Med* 29:404-409, 1997.
8. Fine BC, Sheckman PR, Bartlett JC: Incision and drainage of soft-tissue abscesses and bacteremia (Letter), *Ann Intern Med* 103:645, 1985.
9. Le Frock IL, Molavi A: Transient bacteremia associated with diagnostic and therapeutic procedures, *Comp Ther* 8:65-71, 1982.
10. Blaivas M: Ultrasound-guided breast abscess aspiration in a difficult case, *Acad Emerg Med* 8:398-401, 2001.
11. Sanford JP, Gilbert DN, Sande MA: Guide to antimicrobial therapy, Dallas, 2003, Antimicrobial Therapy.
12. Word B: Office treatment of cysts and abscess of Bartholin's gland duct, *South Med J* 61:514, 1968.
13. Blick PWH, Flowers MW, Marsden AK, et al: Antibiotics in surgical treatment of acute abscesses, *BMJ* 281:111, 1980.
14. Llera JL, Levy RC: Treatment of cutaneous abscess: a double-blind clinical study, *Ann Emerg Med* 14:15, 1985.
15. Macfie J, Harvey J: The treatment of acute superficial abscesses: a prospective clinical trial, *Br J Surg* 64:264, 1977.

# Complicated and Chronic Wounds

DEEP CUTANEOUS AND NECROTIZING  
INFECTIONS

Evaluation and Treatment

INFECTIONS OF LACERATION REPAIR

Management

CHRONIC SKIN ULCERATIONS

Evaluation

Management

Although acute wounds and lacerations compose the bulk of wound care problems that present to emergency and urgent care facilities, patients with complicated and chronic wounds can present a variety of challenges. Rarely, a small, even trivial wound can become infected with bacteria that cause deep, cutaneous, and necrotizing infections. These wounds require rapid, aggressive diagnosis and intervention.

Despite the best efforts to cleanse and repair lacerations, a few patients return with symptoms and signs of infection. The diagnosis of infection has to be confirmed and followed by the steps needed to treat the infection and promote healing.

Finally, patients with chronic skin ulceration, a condition that affects more than 2 million people in the United States, can require emergency care.<sup>1</sup> The goals of that care are limited but important. Professionals best carry out the ongoing care, with eventual healing, in a setting designed for and with expertise in chronic wound care.

---

## DEEP CUTANEOUS AND NECROTIZING INFECTIONS

The most feared complication of a laceration, puncture, or other traumatic wound is a deep cutaneous and necrotizing soft tissue infection. This complication is rare. These infections are more likely to occur in older patients with diabetes, vascular compromise, and other chronic, debilitating illnesses.<sup>2</sup> In these patients, deep infections are caused by a variety of gram-positive, gram-negative, and anaerobic organisms. The lower extremity is the most commonly affected site. The perineum and surgical incisions also are vulnerable to these infections.<sup>3</sup> The overlying skin becomes discolored and swollen and can evolve into blebs and exudative lesions. These patients require extensive evaluation, including radiographs of the involved site. Broad-spectrum antibiotics, such as ampicillin/sulbactam or clindamycin/gentamicin, are administered. A surgical consultation is obtained as soon as possible if the infected area is life-threatening or limb-threatening.

In a young, healthy patient with a minor wound, the most important feature of a developing deep necrotizing and fascial infection is pain out of proportion to clinical findings.<sup>4</sup> Patients may or may not present to a care facility at the time of the wounding. Within hours, however, they begin to complain of severe pain at the wound site. The surrounding skin and

soft tissue are minimally involved. The most likely organisms to be present in this setting are beta-hemolytic streptococci or the clostridia. These infected wounds can progress to full toxic streptococcal syndrome or gas gangrene.

Because these infections are rare, they often are not recognized until skin changes occur and the patient exhibits systemic symptoms, including tachycardia, tachypnea, acidosis, and eventually hemodynamic instability. A high index of suspicion and a willingness to act early in the course may lessen the severity and improve the outcome.

### Evaluation and Treatment

Whenever a deep, necrotizing infection is suspected after a laceration or other wound, the following diagnostic and treatment steps are carried out:

- Complete hematologic tests, including clotting studies, and biochemical profiles are obtained.
- Oxygen saturation is determined and oxygen supplementation is begun if indicated.
- Intravenous fluids are begun with normal saline or lactated Ringer's solution.
- Radiographs of the involved area are taken to assess for foreign body or gas formation.
- A Gram stain is performed on any exudates or bleb fluid to determine the presence of organisms. Gram-positive rods can be present in clostridial infections, and gram-positive cocci are indicative of beta-hemolytic streptococci.
- Broad-spectrum antibiotics, such as ampicillin/sulbactam, ticarcillin/clavulanate, or clindamycin/gentamicin, are administered. In cases in which the diagnosis of clostridia is confirmed, high-dose penicillin is given.
- A surgical consultation is obtained. Immediate surgical intervention may be necessary as a limb-saving or lifesaving measure.
- In cases of suspected or confirmed clostridial myonecrosis or gas gangrene, hyperbaric oxygen has been shown to be an effective adjunct. If available, consultation with an hyperbaric oxygen specialist is recommended.<sup>2</sup>

---

### INFECTIONS OF LACERATION REPAIR

Approximately 3% to 6% of wounds and lacerations treated in an emergency department become infected.<sup>5</sup> Signs of infection include increasing pain and tenderness of the wounded area, redness spreading away from the wound edges, and discharge or pus formation. Most patients return to the original facility or caregiver for treatment.

Before any action is taken, the diagnosis of infection needs to be confirmed. Patients react differently to healing wounds. Normal discomfort for most is very painful to others. All wounds exude a small amount of thin, bloody material for 1 or 2 days. A narrow margin of erythema is normal. When to declare these findings abnormal and consistent with infection can be a judgment call. Sometimes when the diagnosis is unclear, the patient can be reexamined in 24 hours. If a true infection is present, it becomes apparent in the next 24 to 48 hours. Some clinicians place the patient on antibiotics during that period in an attempt to stop an early infection. If an infection has become established, however, antibiotics are unlikely to suppress it while the sutures are still in place.

### Management

When an infection has been diagnosed, the following guidelines are suggested:

- *Removal of sutures:* Sutures act as foreign bodies. In the face of infection, all sutures, including deep and skin closures, must be removed. Attempts to remove only some of the sutures or every other one only prolong the infection.

- *Cleaning and irrigation:* When sutures are removed, the wound is drained and irrigated to remove any collection of pus or infected exudates.
- *Wound exploration:* The wound is explored for retained foreign material or debris.
- *Antibiotic therapy:* Because most infections are caused by *Staphylococcus aureus* or streptococci, a first-generation cephalosporin, cephalexin, can be given for 7 to 10 days. If there is significant cellulitis, therapy can be started with a dose of intravenous cefazolin. In the event of allergy to  $\beta$ -lactam antibiotics, clindamycin or a macrolide can be substituted.
- *Home care:* The wound is cleansed daily with soap and water. Hydrogen peroxide can be added or used alone. Cotton swabs or small sterile sponges can be used to remove debris and exudates until the infection is brought under control. The wound is covered with a gauze pad and tape between cleanings.
- *Consultation:* Wounds in cosmetically unimportant locations can be left to heal by secondary intention. If cosmesis is a concern, the patient can be referred to a plastic surgeon for further care.

---

## CHRONIC SKIN ULCERATIONS

Although no statistics define the numbers of patients presenting to the emergency department with skin ulcers, it is a frequent occurrence, particularly in emergency departments serving socially and economically disadvantaged groups. Skin ulcers stem from specific systemic or regional disorders. The most common are vascular diseases, diabetes, and neurologic disorders.<sup>6</sup> Cofactors include chronic systemic disease, prolonged bed rest, malnutrition, body size, suboptimal care, weight-bearing surfaces, and patient neglect. The net result of the combined pathophysiologic process is localized loss of integrity of the epidermis, dermis, and subcutaneous tissue secondary to ischemia. If unchecked, the ulcerative process can involve deep fascia, muscle, and bone. Skin ulcers most likely to be encountered by the emergency department physician include ulcers due to pressure, venous stasis, arterial insufficiency, and diabetes.<sup>2</sup>

The ischium, sacrum, and trochanter of the hip account for 60% of pressure ulcers; 17% occur in the foot area.<sup>7</sup> These ulcers almost always occur in chronically debilitated, bedridden patients and neurologically impaired patients, such as quadriplegics and paraplegics.

Chronic venous insufficiency is the setting for venous ulceration. Venous ulcers are most common over the inner aspect of the distal leg and ankle. Most ulcers lie along the saphenous vein system. Edema of the lower extremity and stasis dermatitis precede ulcer formation. Venous ulcers are shallow and tender and have variably shaped borders.

The hallmark of arterial ulcers is resting pain.<sup>2</sup> These ulcers are most common over the lateral ankle, toes, and base of the fifth metatarsal head and heel and ball of the foot. The other signs of arterial insufficiency are usually present, including pale atrophic skin, hair loss, and nail dystrophy. A history of claudication is common, and peripheral pulses are either weak or absent.

Most diabetic ulcers occur in the forefoot and toes.<sup>8</sup> The ulcerated foot is classified as ischemic or neurotrophic. Clinically, if the ankle pulses are present and there are good signs of arterial perfusion, the ulcer is neurotrophic in origin. By comparison, ischemic ulcers present with diminished pulses in pale and atrophic tissue.

### Evaluation

The first duty of the emergency department physician in evaluating a patient with a chronic skin ulcer is to assess for a life-threatening or limb-threatening condition. Patients presenting to the emergency department with skin ulcerations often do so because of changes in their

general medical condition, rather than for the ulcer itself.<sup>2</sup> The four major threats to life and limb that should be considered are venous thrombosis, acute arterial occlusion, severe (systemic or regional) infection, and metabolic abnormalities. For patients with systemic symptoms or potential life threats, the initial stabilization steps consist of providing oxygen supplementation, establishing intravenous access, and placing the patient on a cardiac monitor. Evaluation includes obtaining hematologic and metabolic profiles, an electrocardiogram, and radiographs as needed. Specifically the ulcer site is radiographed to look for tissue gas or osteomyelitis.

When life-threatening and limb-threatening conditions have been considered, a more focused evaluation can be performed. An attempt should be made to define the cause of the ulcer and to determine its extent. Because ulcers occur most commonly in the lower extremities, the focus of the examination is mostly on the buttocks, legs, and feet.

The vascular and neurologic examination of the lower limbs necessitates the most attention. When arterial disease is suspected, femoral, popliteal, dorsalis pedis, and posterior tibial pulses should be examined. Further evidence of arterial disease includes bruits in the midabdominal, femoral, or popliteal regions. Capillary refill (<4 to 8 seconds in normal individuals) can be tested. An ankle systolic pressure of less than 60 mm Hg or an ankle-brachial index (the ratio of lower leg to arm blood pressure) less than 0.4 is highly indicative of severe arterial disease. Assessment of the venous system is more difficult and often requires specialized testing, such as Doppler ultrasound of the lower extremity venous system.

## Management

When the general health of the patient has been addressed and the cause of the ulcer has been determined, specific ulcer therapy can be initiated. The goals of care of patients with ulcers are as follows<sup>6</sup>:

- To decrease the necrotic tissue load and maintain wound cleanliness
- To disinfect the wound site
- To initiate stimulation of granulation tissue

The specific management recommendations for the infected, necrotic ulcer are as follows:

- *Cleansing*: All ulcers should be cleaned. At the initial emergency department visit, standard wound cleansing solutions, such as povidone-iodine and chlorhexidine, can be used. They should be diluted with saline before use.
- *Irrigation*: Probably more important than wound cleansing is saline irrigation under pressure. This technique has been shown to be effective in removing bacteria, loose debris, and exudates from ulcers. In the emergency department, a 20- or 50-mL syringe with an 18G needle is an appropriate choice for irrigation.
- *Wet-to-dry dressings*: For all but the cleanest wounds with viable granulation tissue, the initial choice of dressing is the traditional wet-to-dry saline dressing.<sup>2</sup>
  - The ulcer cavity is packed with moistened saline gauze. This technique permits tissue and debris to embed in the gauze matrix as it dries. Removal of dried gauze effectively débrides the wound. The gauze is kept in place by a gauze bandage wrap (Kling).
  - This process is repeated at least two or three times daily. Patients and families are instructed in this technique if they have the initiative and resources.
  - It is important to let the dressing dry completely and be removed without moistening. The gauze attaches to and lifts up the necrotic tissue debris only if dry.
  - Wet-to-dry dressings are continued for several days until the exudate and debris are significantly reduced, and granulation tissue appears.
- *Discharge*: The patient is given specific instructions on discharge.
  - In addition to the frequent dressing changes, the patient should elevate the affected extremity as much as possible. Continued dependency of the extremity encourages unnecessary edema and retards healing.

- As previously mentioned, antibiotics can be prescribed for the patient. Amoxicillin/clavulanate, ciprofloxacin, cephalexin, and clindamycin have shown efficacy in treating chronic wounds and ulcers.<sup>8</sup>
- The patient should be returned to the care of a physician with chronic wound care support and ability. Only after the wound has been débrided and rendered infection-free can other interventions be applied to continue ulcer healing.

Ultimately, chronic ulcers can benefit from a variety of newer synthetic dressings, Unna boots, skin grafting, wound growth factors, and hyperbaric medicine.<sup>9</sup> These options can be tailored to the individual case. Ideally, patients should be referred to specialized wound care centers, which often are associated with hyperbaric medicine facilities.

## REFERENCES

1. Fletcher J: Measuring the prevalence and incidence of chronic wounds, *Prof Nurse*, 18:384-388, 2003.
2. Trott AT: Chronic skin ulcers, *Emerg Clin North Am* 10:823-845, 1992.
3. Stone DR, Gorbach SL: Necrotizing fasciitis: the changing spectrum, *Infect Dis Dermatol* 15:213-216, 1997.
4. Kaul R, McGeer A, Low DE, et al: Population-based surveillance for group A streptococcal necrotizing fasciitis; clinical features, prognostic indicators, and microbiologic analysis of seventy-seven cases, *Am J Med* 103:18-24, 1997.
5. Cummings P, Del Beccaro MA: Antibiotics to prevent infection of simple wounds: a meta-analysis of randomized studies, *Am J Emerg Med* 13:396-400, 1995.
6. O'Meara SM, Cullum NA, Majid M, et al: Systematic review of antimicrobial agents used for chronic wounds, *Br J Surg* 88:4-21, 2001.
7. Phillips TJ: Chronic cutaneous ulcers: etiology and epidemiology, *J Invest Dermatol* 102:38S-41S, 1994.
8. Ramasastry SS: Chronic problem wounds, *Clin Plast Surg* 25:367-396, 1998.
9. Dieter S: Debridement for chronic wounds, *Adv Nurse Pract* 9:65-66, 2001.



# Wound Dressing and Bandaging Techniques

## WOUND DRESSING PRINCIPLES

Tidiness  
 Nonadherent, Porous Base  
 Moist Environment  
 Protection  
 Partial Immobilization

## BASIC WOUND DRESSING

Dressing Application

## HOME CARE AND DRESSING CHANGE INTERVALS

## BODY AREA DRESSINGS

Scalp  
 Face  
 Ear and Mastoid  
 Neck  
 Shoulder  
 Trunk  
 Groin, Hip, and Thigh  
 Hand and Finger  
 Elbow and Knee  
 Ankle, Heel, and Foot

The choice of a dressing for an emergency wound is subject to the preference of the caregiver who is applying it. There are no hard and fast rules that can be followed when selecting a dressing. This chapter discusses the general principles of wound dressing and some recommendations for dressing and bandaging depending on the type of wound, body location, and other factors. Specialized dressings for burns are discussed in Chapter 17.

## WOUND DRESSING PRINCIPLES

The first decision to be made after repairing a wound is whether to apply a dressing at all. Uncomplicated lacerations of the face and scalp are often left open. The head and face are extremely vascular, and wounds in these areas are resistant to infection. If the patient is careful and keeps the wound clean, a sutured laceration heals without event. These wounds need the regular application of a petrolatum-based antibacterial ointment to maintain a moist environment and to help prevent crusting that can interfere with suture removal.<sup>1</sup> Petrolatum-based antibacterial ointments (e.g., polymyxin B sulfate/neomycin [Neosporin] and silver sulfadiazine [Silvadene]) have been shown experimentally to encourage epithelialization effectively compared with other ointments (e.g., nitrofurazone [Furacin] and Pharmadine, which contains povidone-iodine).<sup>2</sup> Neosporin is easier to apply to the face than silver sulfadiazine, which needs to be applied in a thick layer. Other agents that can be used for this purpose are polymyxin B sulfate/bacitracin (Polysporin) and bacitracin.

The generally accepted practice for wounds and lacerations that are not on the head and face is to apply a wound covering, although there is little evidence that a dressing improves the eventual outcome of sutured lacerations. One study of uncovered surgical incisions that were sutured postoperatively could not document an increase in the rate of infection compared with

dressed incisions.<sup>3</sup> When the decision is made to apply a dressing, the following principles should be observed.

### Tidiness

A dressing must be neat and uncomplicated. Sloppy or poorly applied dressings and bandages do not convince a patient that good wound care has been delivered. Many small wounds are served best by one or two simple adhesive bandages (Band-Aid). This dressing remains one of the most versatile and appropriate wound coverings yet devised.

### Nonadherent, Porous Base

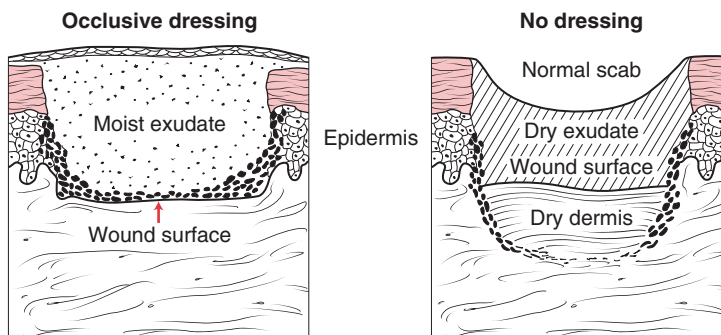
The base of a dressing, the portion in direct contact with the wound surface, should not be adherent.<sup>4</sup> Plain, fine-mesh gauze is an example of a dressing that sticks to wounds by becoming incorporated in the coagulum. When it is removed, it can disrupt healing by disturbing the delicate epithelial covering. A good wound covering also has to allow for the passage of exudate so that excessive accumulation does not occur.

### Moist Environment

The wound has to remain moist. Experimental studies convincingly show that desiccation by exposure can delay epithelial layer formation significantly.<sup>4,5</sup> Figure 20-1 illustrates the pathways for epidermal healing in moist and dry environments. In a nonoccluded wound, epithelial cells are forced to find a pathway beneath dry coagulum/exudate and dermal remnants. In practice, synthetic dressings (e.g., Adaptic, Xeroform, and Telfa) are traditional nonadherent, porous coverings that allow for the drainage of exudate but do not permit excessive desiccation.

A point of controversy that has yet to be resolved is whether the application of antibacterial creams or ointments under dressings has any value.<sup>6</sup> Claims against the use of these agents include excessive maceration of tissue and the emergence of resistant bacteria.<sup>7,8</sup> Suppression of infection and improved wound edge healing, particularly for flaps, are reasons given in support of the use of topical agents.<sup>2,9,10</sup> In an evidence-based review of the application of ointment to lacerations and other small wounds, all of the studies cited had significant weaknesses.<sup>11</sup> The question of whether ointment reduces wound infection remains unanswered.

Currently, topical ointments are recommended for facial wounds (e.g., lacerations, abrasions, burns) or any other wound that is treated without dressing and bandaging. For dressed wounds, any antibacterial effect is lost unless dressings are changed at frequent



**Figure 20-1** The different pathways necessary for epithelial cells to migrate to provide an epithelial cell covering of an open wound. The moist environment experimentally appears to provide for more rapid healing than a dry environment as seen in open, uncovered wounds.

intervals—at least two or three times a day.<sup>9</sup> Application of these ointments becomes impractical for wound protection against infection.

### Protection

Protection from contamination is best accomplished by ensuring that in addition to the non-adherent base, the wound is well covered with gauze sponge material and an appropriate gauze wrap. Gauze sponges help meet this requirement of wound dressing. Most minor wounds and lacerations produce little exudate; a simple 2 × 2 or 4 × 4 gauze sponge or even a Band-Aid suffices for this purpose. Complicated or contaminated wounds with a potential for infection are likely to exude freely and copiously. In addition to several layers of gauze sponges, frequent dressing changes often are necessary.

### Partial Immobilization

Finally, dressings should protect the healing wound and provide partial immobilization of the injured part. Many forces can disrupt a suture line, ranging from clothing contact to accidental minor trauma to the wound. Gauze sponges in combination with gauze wrapping suffice for the purpose of protection. Occasionally, rigid splinting, particularly for lacerations over joints, is necessary. In general, excessive wrapping should be avoided, however, to prevent complete immobilization of a moving anatomic part, particularly the hand. Although rest for the injury is necessary, some movement is encouraged within the bandage. The goal is to prevent the stiffening of joints that can occur, especially in elderly patients.

Young children present a particularly difficult challenge in wound dressing. Their wounds heal rapidly and, in practice, seem to be resistant to infection. The principle of simplicity is important. A Band-Aid, when it can be used appropriately, is the dressing of choice for small wounds. If the Band-Aid is removed by the child, it can be replaced easily by the parent. Children are more likely to leave Band-Aids in place because this dressing is recognized as a “badge” for other children to appreciate. When more complicated dressings have to be used on the hand, a “mitten-like” bandage that encompasses the entire hand is often recommended. If the laceration or wound is serious, older children generally seem to have an instinctive understanding that prevents them from removing dressings.

---

## BASIC WOUND DRESSING

The basic wound covering consists of four materials:

- Nonadherent base
- Absorbent gauze sponges
- Gauze wrapping if needed
- Tape to secure the dressing

Standard nonadherent bases include Adaptic (a porous synthetic mesh), Telfa, and Xeroform (a treated fine-mesh gauze). In recent years, there has been a proliferation of several semi-permeable, occlusive, nonadherent wound dressings that can be applied to lacerations, burns, and abrasions.<sup>12</sup> In a study of a modified polyurethane foam on those three types of wounds, it was found that wounds tended to heal faster, were less painful, and were easier to care for compared with standard dressing controls.<sup>13</sup> Although this study was encouraging, the investigators terminated their comparison after only 20 days of observation. Final healing outcome, after scar maturation, may have been no different.

Other parameters that remain to be fully explored before these new dressings can be recommended routinely for general use include bacterial growth potential at the wound site and effect on wound tensile strength.<sup>4,14</sup> Conflicting data concerning possible adverse effects in these two areas exist. Some of these dressing materials also are considerably more expensive than older, standard materials.<sup>13</sup>

## Dressing Application

After repair, an antibacterial ointment can be thinly and gently spread over the wound. Based on the preceding discussion, application of a topical agent for sutured lacerations can be considered optional. If one is chosen, Neosporin is commonly used. For patients sensitive to the neomycin in Neosporin, bacitracin or Polysporin can be substituted. Although sensitivity to neomycin is a concern, an actual allergic response to patch testing is low. Of 3333 patients reported in a review of topical agents, only 14 (0.3%) were found to be sensitive to neomycin.<sup>10</sup>

In a sterile fashion, the nonadherent base is cut to conform with the general wound area (Fig. 20-2). Depending on the potential for wound drainage and exudation, gauze sponges are placed over the base. On an extremity, a gauze wrap is applied, followed by tape. On flat surfaces where gauze wrapping is not appropriate, the tape is placed directly over the gauze sponges.

A common tape adhesive adjunct is tincture of benzoin. This substance is effective in keeping tape adherent to the skin for the duration of the dressing. Precautions have to be taken, however, not to spill benzoin directly into the wound. Under experimental conditions, this compound has been shown to increase the potential for wound infection when it comes into direct contact with the raw wound surface.<sup>15</sup>

One of the most important precautions in dressing and bandaging is never to wrap tape circumferentially around an extremity or digit (Fig. 20-3). If brought around the finger or wrist to adhere to itself, tape becomes a nonexpanding band that causes a tourniquet effect on the vascular blood supply to the distal regions of a hand or finger. Pressure builds up as congestion and edema develop. This pressure can cause complete cessation of blood flow with attendant ischemic necrosis of the anatomic part. This tourniquet effect is one of the worst potential complications of wound care.

---

## HOME CARE AND DRESSING CHANGE INTERVALS

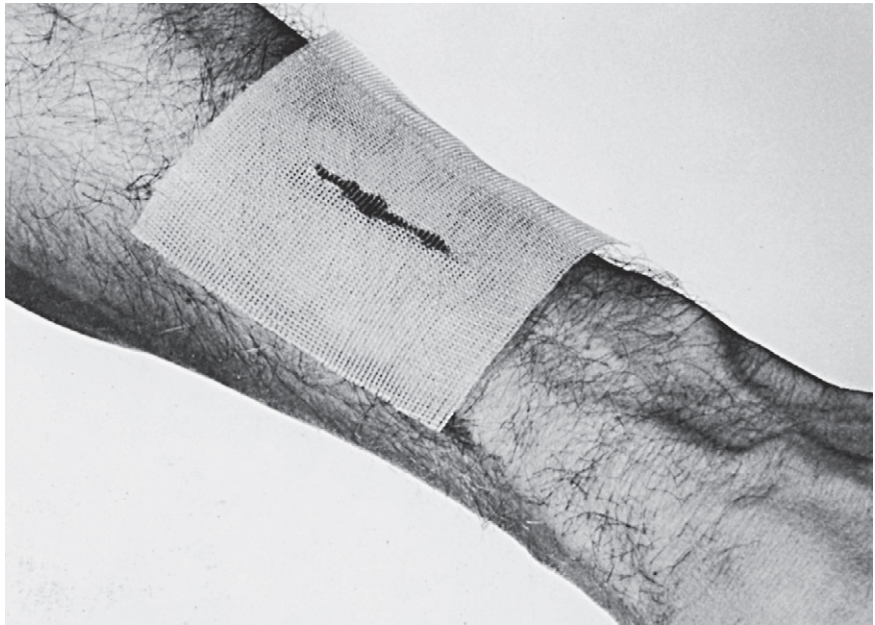
Dressing change intervals vary considerably and depend on the patient, wound characteristics, and home care plan. In general, dressings should be kept clean and dry. Because the initial dressing is placed while the wound might be oozing blood or exudate and may be bulky, it is often useful to instruct the patient to change the dressing 24 to 48 hours after the repair. This change serves several purposes: The wound can be inspected for early signs of infection, the new dressing is free of exudate and blood, and it is less bulky than the original one. Dressing changes thereafter can be individualized based on the patient's ability to maintain the integrity and protective function of the dressing. See Chapter 22 for further home care information and instructions.

---

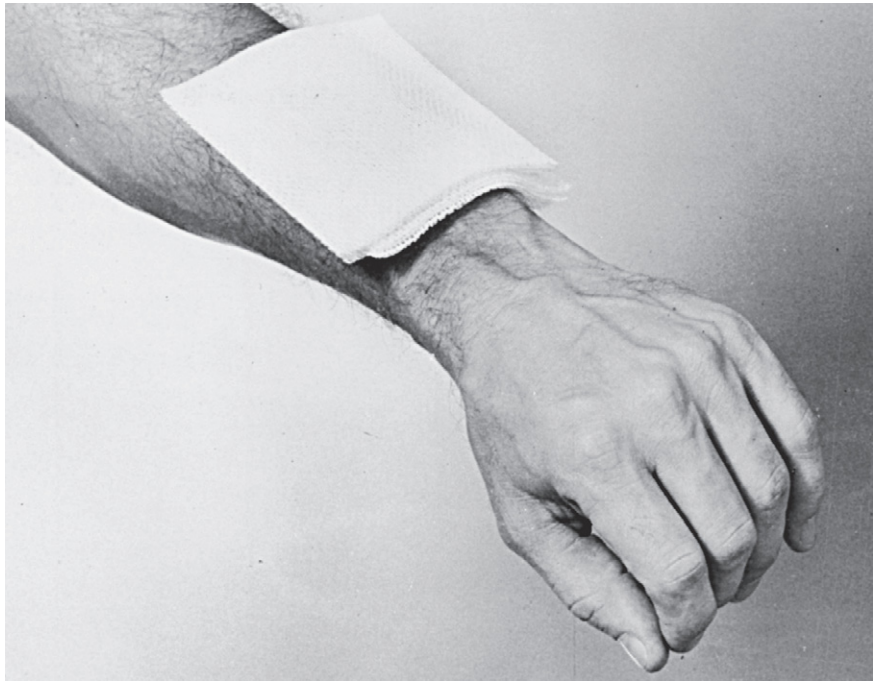## BODY AREA DRESSINGS

### Scalp

Most simple sutured lacerations of the scalp can be left open to the air. A small amount of blood coagulum develops quickly along the suture line and acts as a wound covering. Because the scalp is extremely vascular and tends to bleed profusely when injured, however, occasionally a dressing needs to be applied to the area after repair. Figure 20-4 shows the basic bandage and the method to continue that wrapping as a recurrent dressing for wounds closer to the crown. The initial gauze wrap should include the greatest diameter of the skull to prevent inadvertent slippage. The forehead just above the brow and the external occipital protuberance are the landmarks that are the center points for the wrap. Otherwise the dressing slips over the crown and falls off.

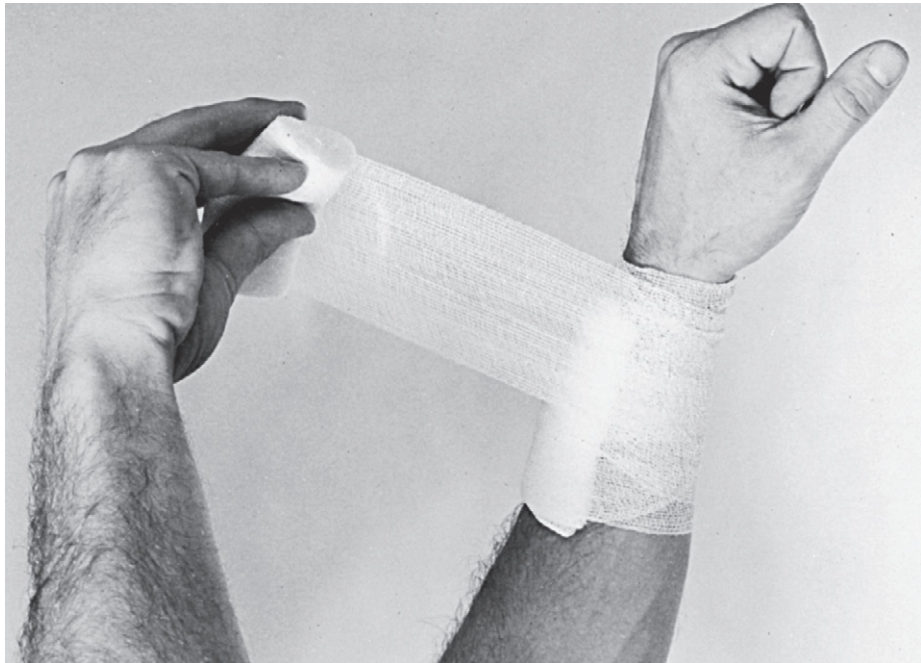

A

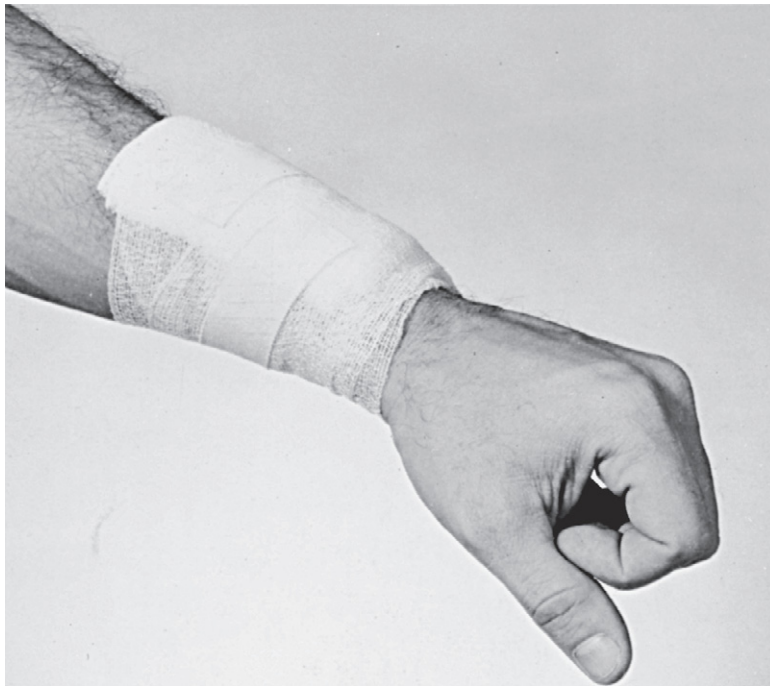

B

**Figure 20-2** Basic components of a wound dressing. **A**, A nonadherent base. **B**, Gauze sponge covering. (Continued)

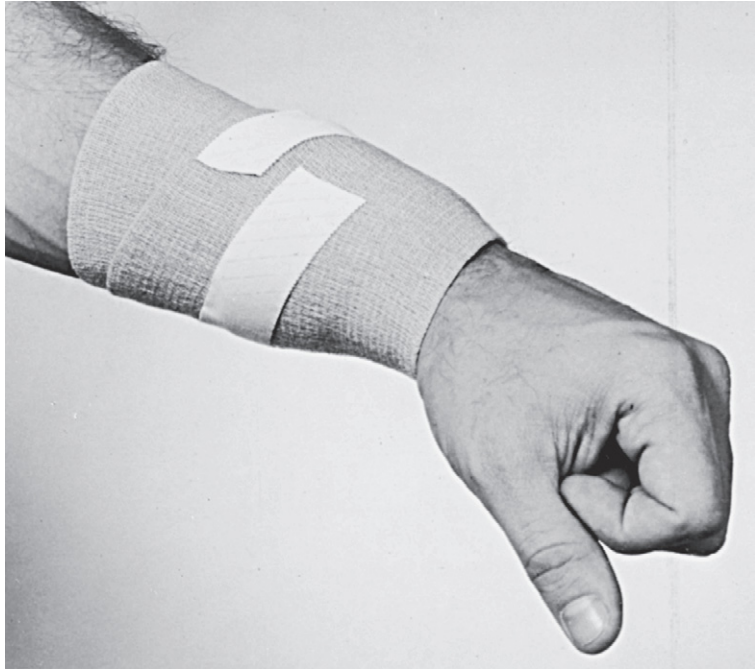

C

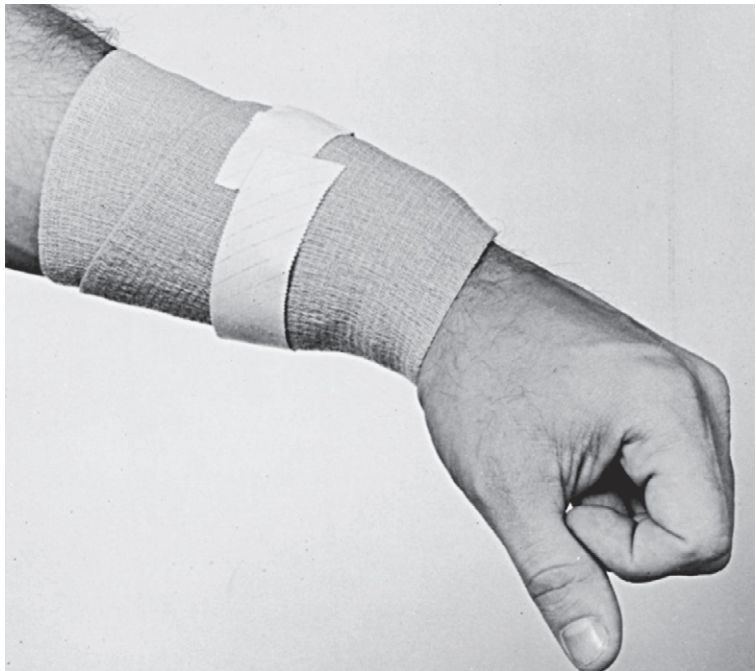

D

**Figure 20-2** Cont'd. C, Gauze wrap. D, Tape application to secure dressing.

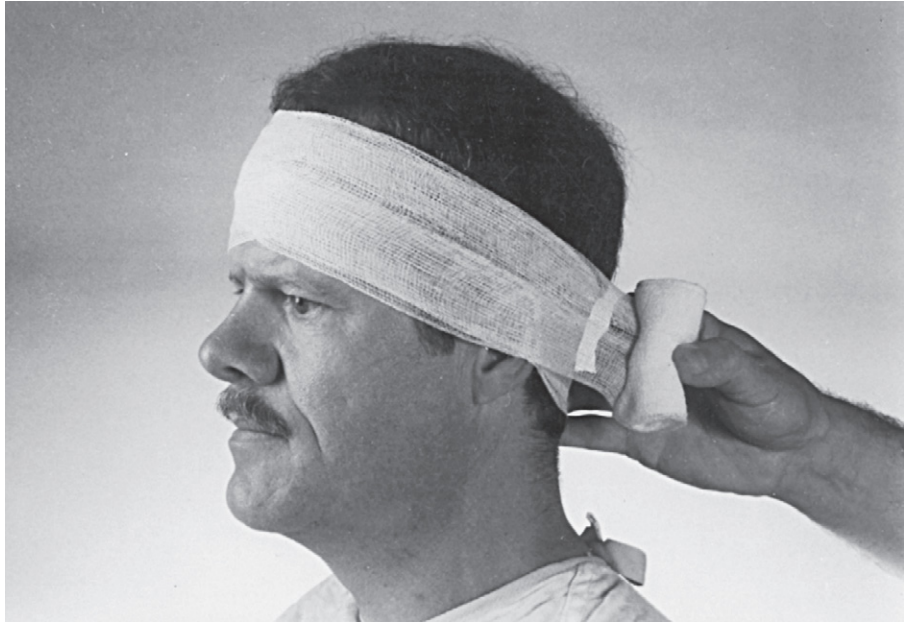

A

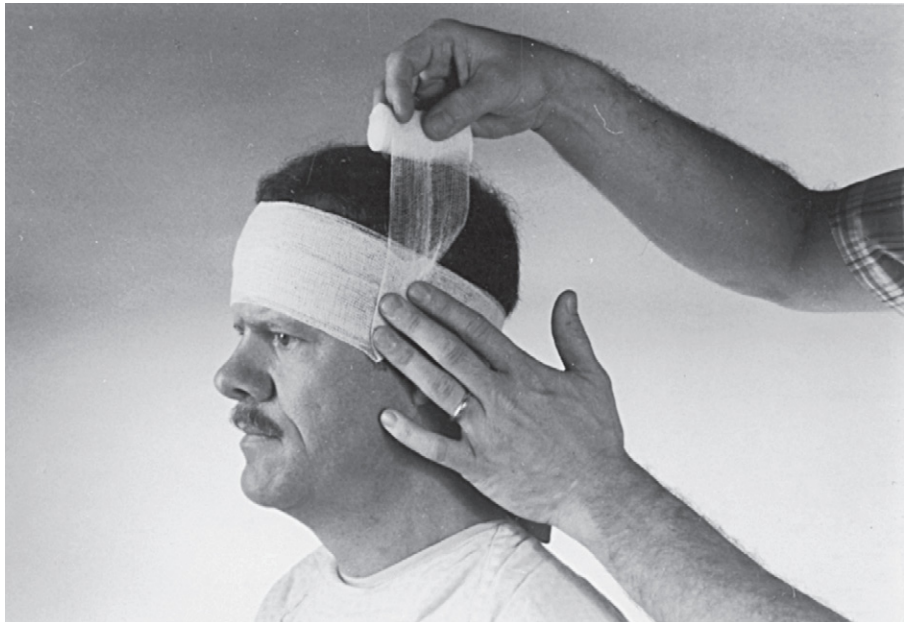

B

**Figure 20-3** Technique for correct taping of a bandage. **A**, Correct: Tape does not overlap if it surrounds an extremity. **B**, Incorrect: Overlapping tape can cause unwanted constriction and distal edema.



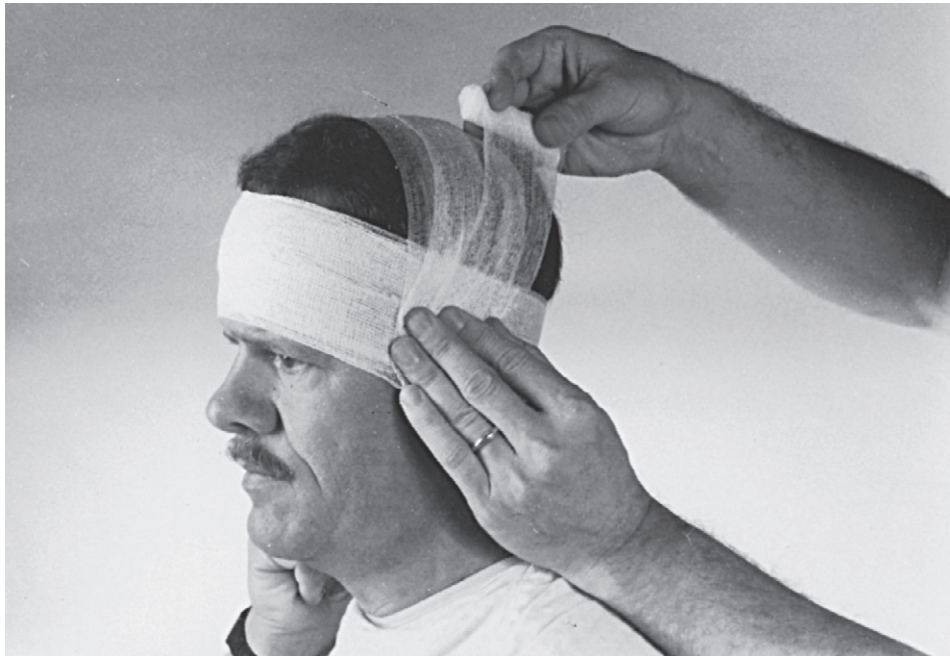A



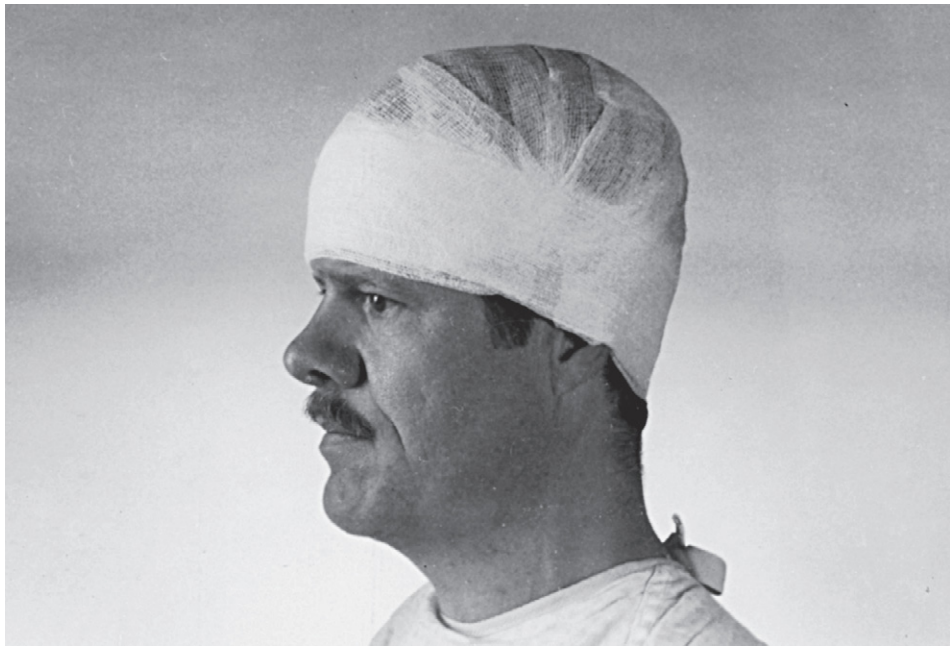
B

**Figure 20-4** Technique for application of a scalp dressing. **A**, Dressing is begun by wrapping gauze around the midforehead and directly over the occipital protuberance. This beginning allows for stabilization of the scalp dressing. Attempts to wrap the dressing higher on the scalp lead to inevitable loosening of the dressing. **B**, If a recurrent portion of the dressing is necessary to cover lacerations or wounds on the top of the head, or vertex, the recurrent portion is begun as illustrated.



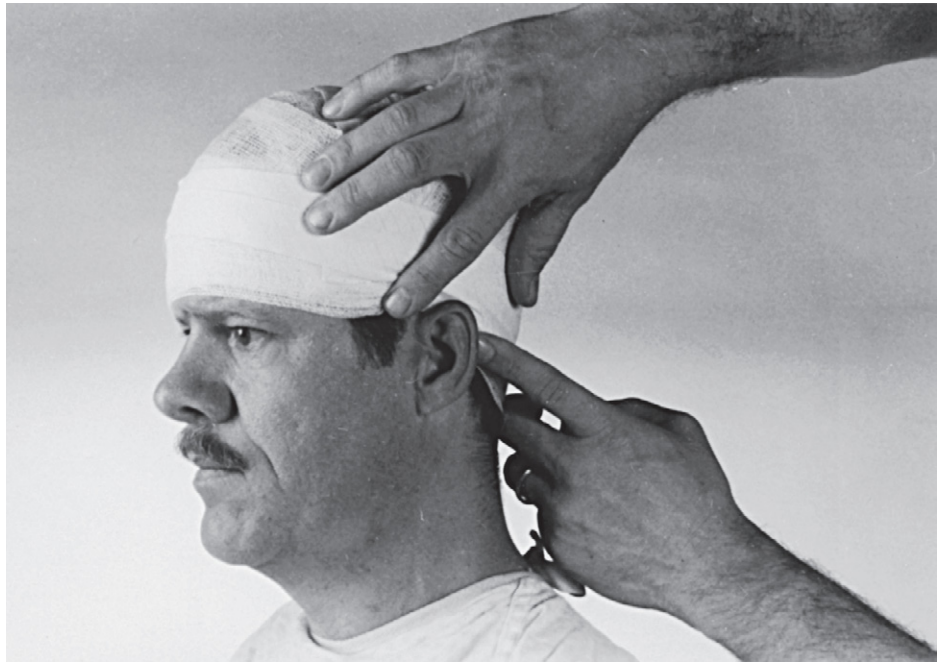


C

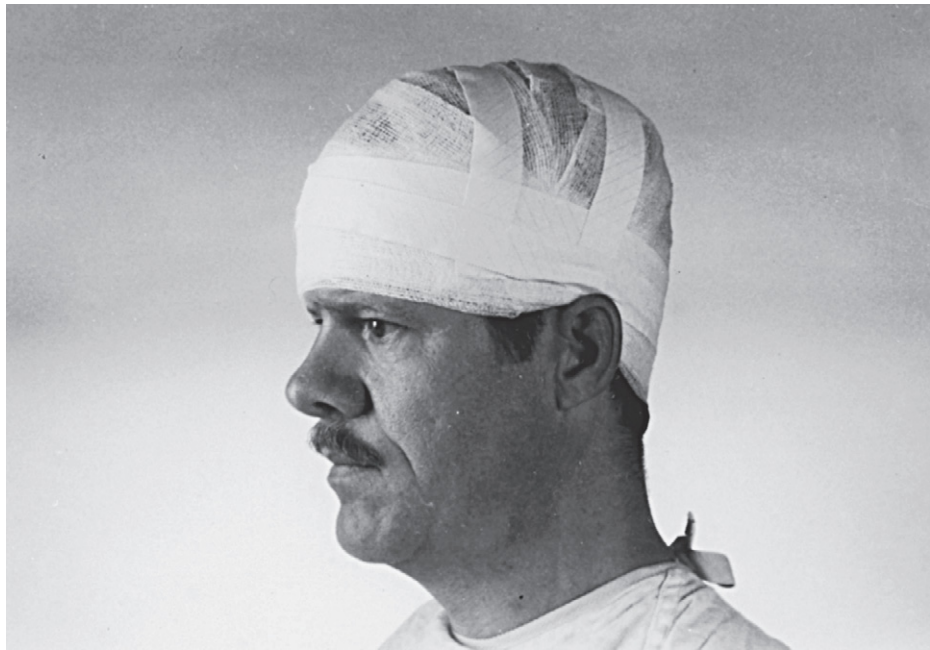

D

**Figure 20-4** Cont'd. **C**, The recurrent portion is brought back and forth over the area of concern. **D**, The recurrent portion is anchored by continued circumferential wrapping of the gauze around the forehead and external occipital protuberance. *(Continued)*



E



F

**Figure 20-4** Cont'd. **E**, Tape is applied to secure the scalp dressing. It is important to remove the ears from underneath the circumferential portion of the dressing to avoid ischemia of the ear skeleton. **F**, View of a completed recurrent scalp dressing.

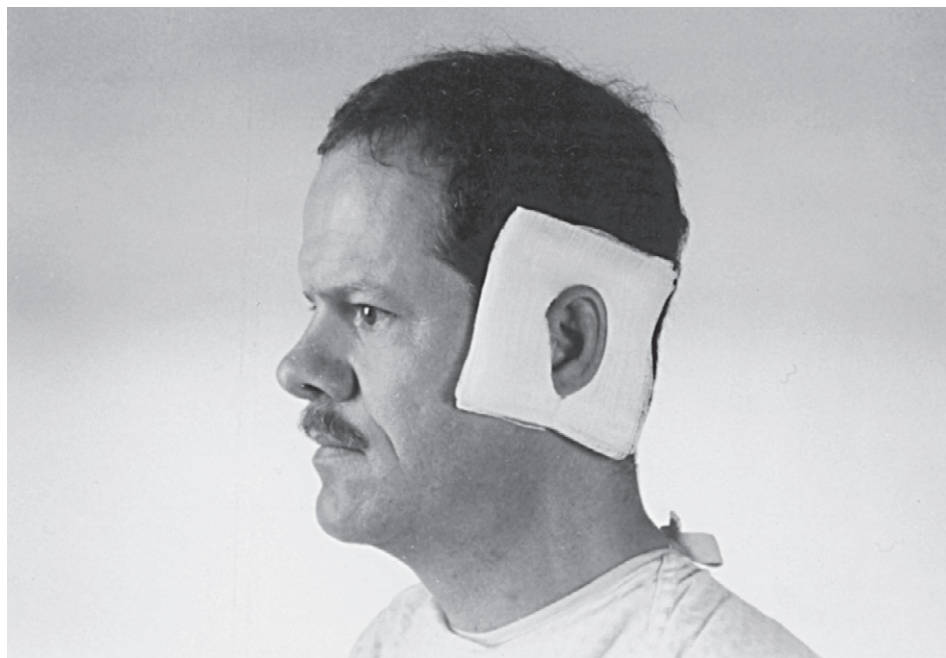This dressing often can be supplemented by gently applied elastic wrap for 24 hours. The elastic wrap is removed after 24 hours, leaving the basic bandage intact. Great care must be taken when applying a scalp dressing, particularly with an elastic support, not to cause excessive pressure on the ears. Whenever possible, the ears should be brought out from underneath the bandage to prevent the complication of an ischemic necrosis of the skin of the ear or of the cartilage skeleton.

## Face

As mentioned previously, facial lacerations can be left uncovered after repair. Small, uncomplicated lacerations of the ear, eyelid, nose, and lip are included in this recommendation. The patient can apply a thin film of an antibacterial ointment (e.g., Neosporin) daily. The antibiotic nature of this ointment is of questionable value at best, but the ointment base is useful in preventing the crusting of coagulum around the wound. When crusting is prevented, sutures are removed much more easily with minimal wound disruption. When a facial wound needs covering to protect it from the environment, Band-Aids are recommended. Bulky bandages of the face are poorly tolerated by patients and tend to come off quickly.

## Ear and Mastoid

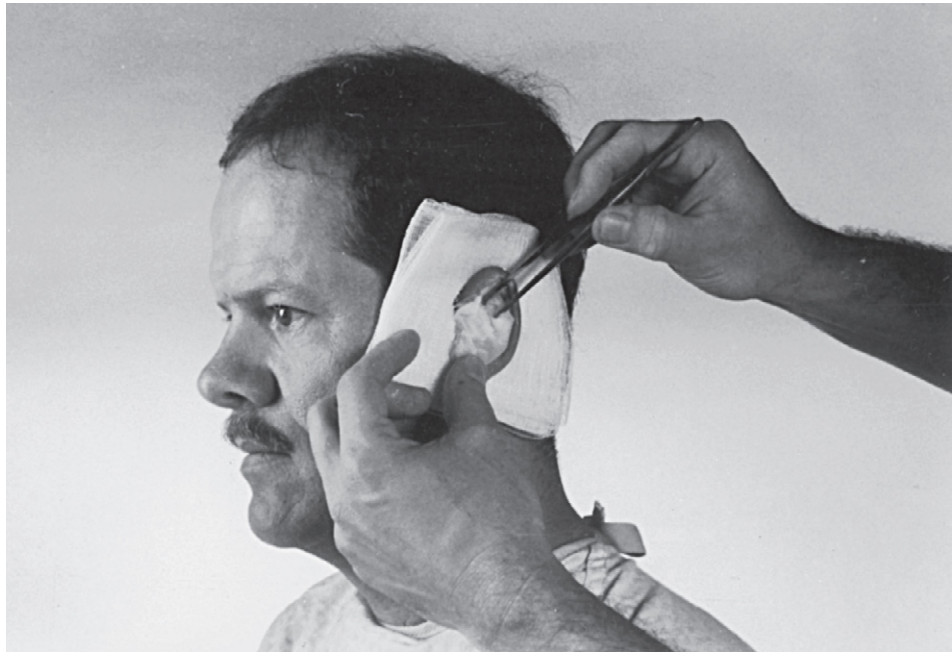
Complicated ear injuries that are at risk for forming perichondral hematomas require a more involved dressing that applies pressure evenly over all of the contours of the ear. One or two  $4 \times 4$  gauze sponges are cut in the contoured fashion shown in Figure 20-5. The sponges are



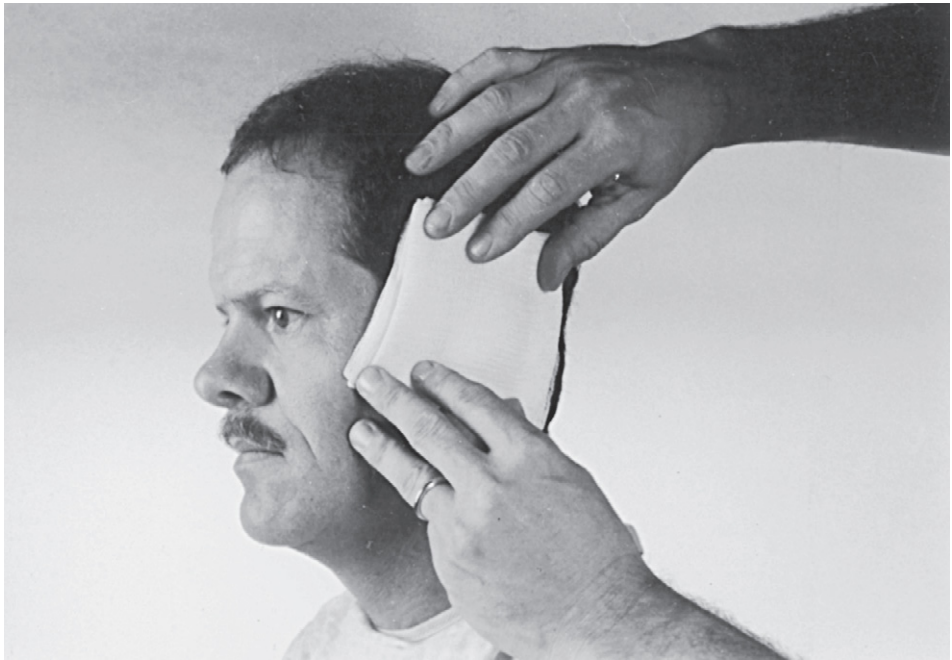A

**Figure 20-5** Technique for application of a mastoid dressing. **A**, With bandage scissors, cut a center portion out of two or three  $4 \times 4$  gauze sponges so that they fit behind the cartilaginous skeleton of the ear. It is important that the cartilaginous skeleton is well supported and not “crushed” against the scalp.

(Continued)

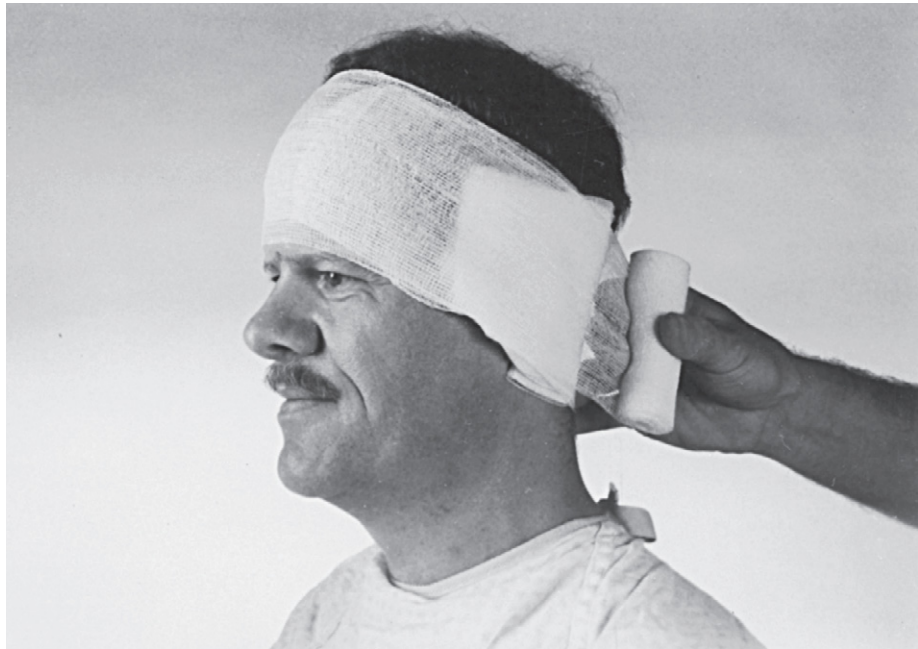

B

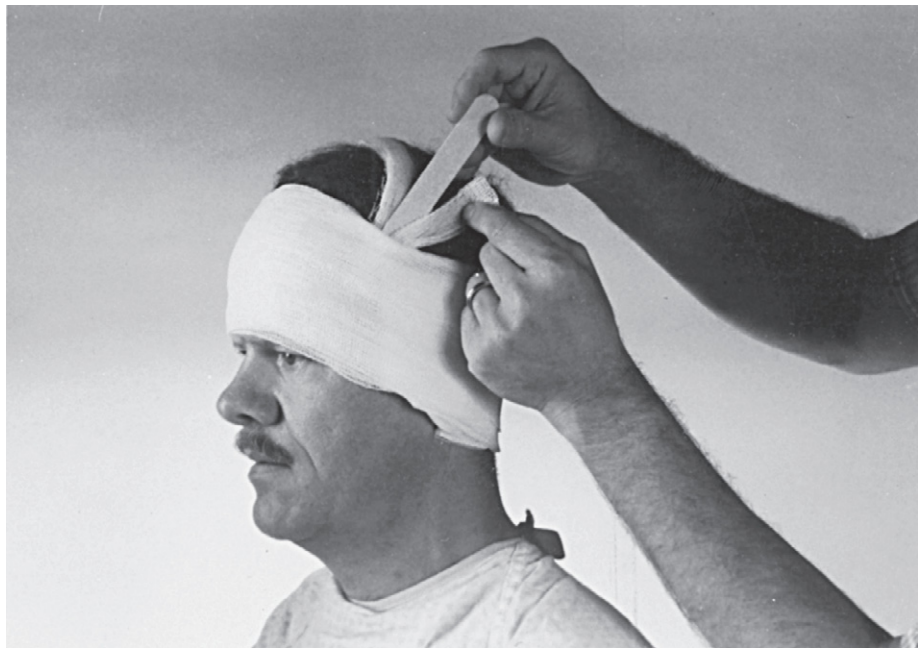

C

**Figure 20-5** Cont'd. **B**, Petrolatum gauze packing is placed and molded within the cartilaginous skeleton. **C**, Fresh sponges are placed over the molded petrolatum gauze.

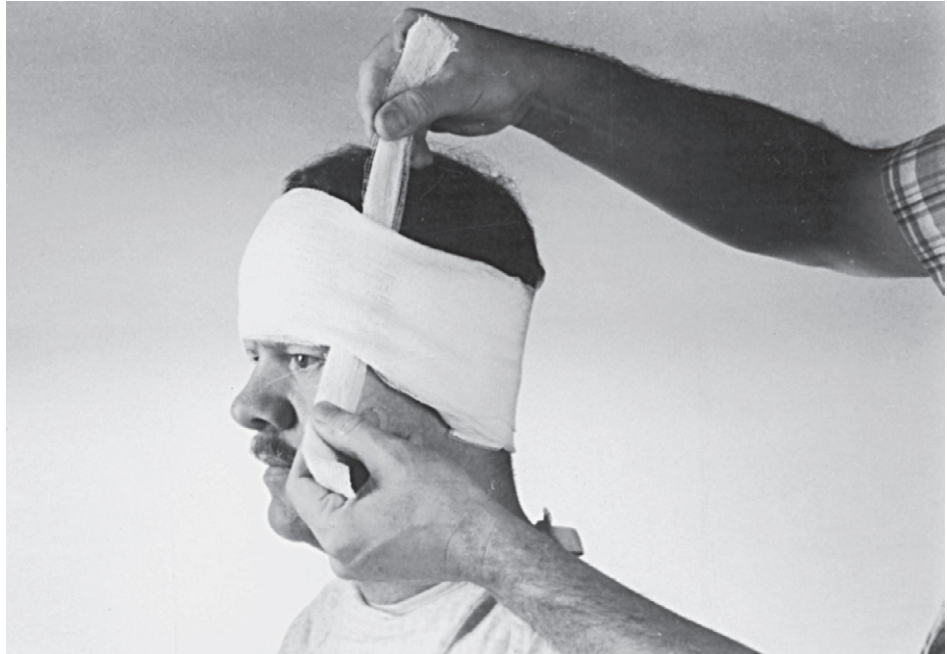

D

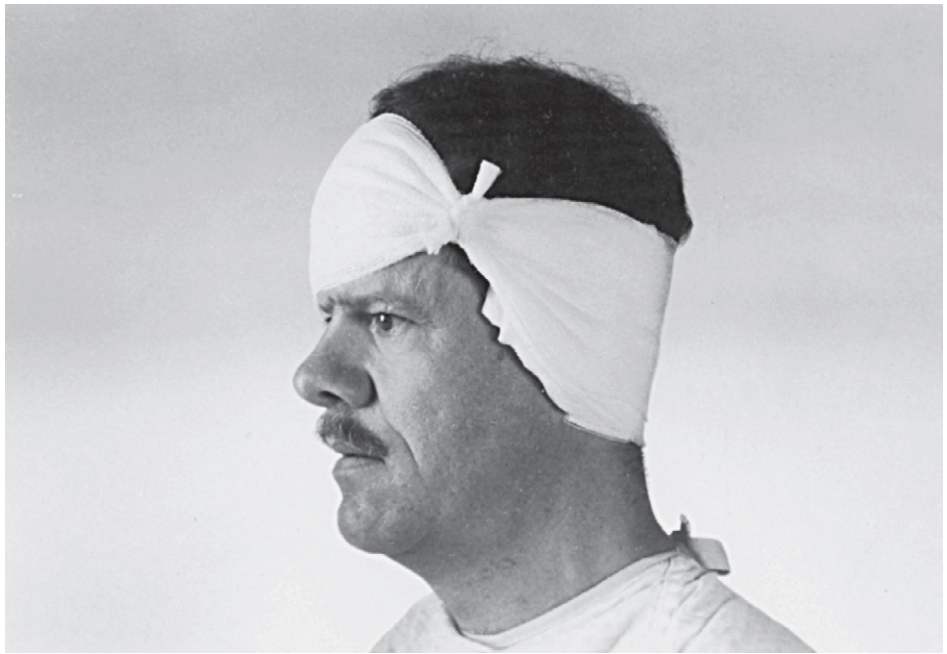

E

**Figure 20-5** Cont'd. **D**, Circumferential gauze wrapping is placed from the midforehead directly over the external occipital protuberance. This portion is secured with tape. **E**, A gauze tie is inserted anterior to the affected ear using a tongue blade. *(Continued)*



F



G

**Figure 20-5** Cont'd. **F**, This gauze is tied firmly in a square knot to provide even pressure over the ear. **G**, The final appearance of a mastoid dressing.

placed around and behind the ear to provide support and a "bed" for the cartilaginous skeleton. The area within the helix is filled with petrolatum gauze and "molded" over the antihelix, antitragus, and external canal. Two intact sponges are placed over the entire ear, and a 3- or 4-inch gauze bandage is brought around the head and over the ear several times. After the bandage is taped, it is tightened by placing a gauze tie just anterior to the ear. The net effect is to provide even pressure over the ear without compromising the blood supply.

### Neck

The neck is an uncommon site for lacerations and other wounds. Dressings need to be secured effectively without compromising the airway or venous return through the jugular system. Simple wrapping with a gauze bandage over the dressing base suffices in most cases. For wounds of the posterior neck in the region of the occiput, the gauze bandage can be wrapped around the head and the neck to provide for adequate coverage and security (Fig. 20-6).

### Shoulder

The shoulder can be a difficult area to dress, especially if the wound is large, in the axilla, or directly over the articular surfaces. The dressing illustrated in Figure 20-7 takes advantage of the trunk to anchor the shoulder portion. The wrap is brought alternately around the trunk and shoulder/upper arm until it is complete. This dressing configuration also is useful for the upper arm, an area in which bandages tend to slip down with arm motion and gravity. A schematic of the shoulder dressing is illustrated in Figure 20-8.

### Trunk

Most wounds on the trunk can be covered with the standard base described previously and taped over benzoin. Larger wounds, such as burns, need larger bandages. The dressing described earlier to cover the shoulder can be extended downward over the trunk and does not slip toward the abdomen. Another method to dress the trunk is illustrated in Figure 20-9.

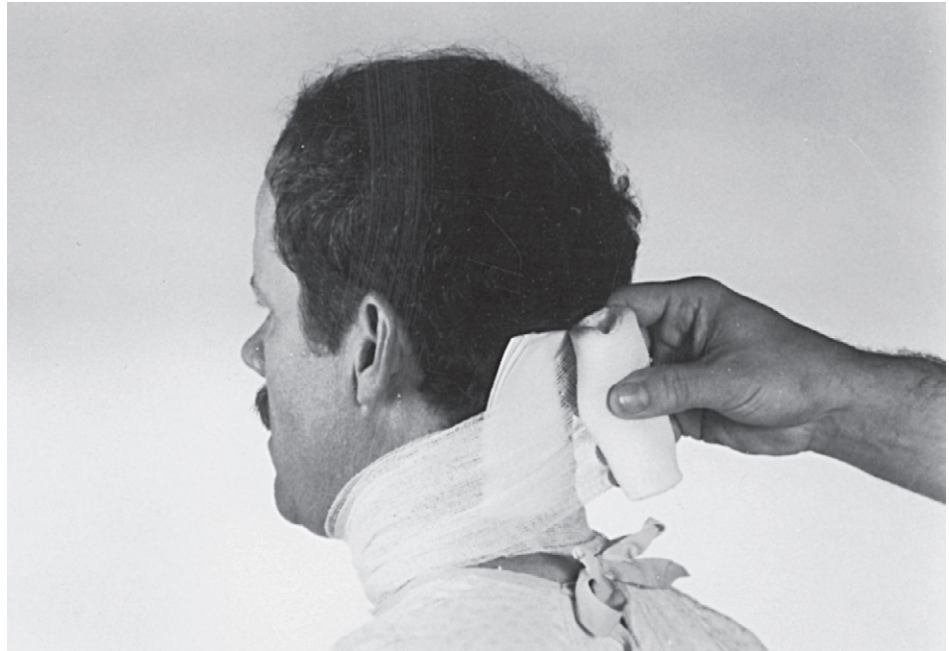### Groin, Hip, and Thigh

The groin, hip, and thigh also are difficult regions to cover properly. The technique illustrated in Figure 20-10 is all-purpose and protects most large wounds in those areas. Similar to the method for covering the shoulder, the gauze wrap is brought alternately around the trunk and thigh until it is complete.

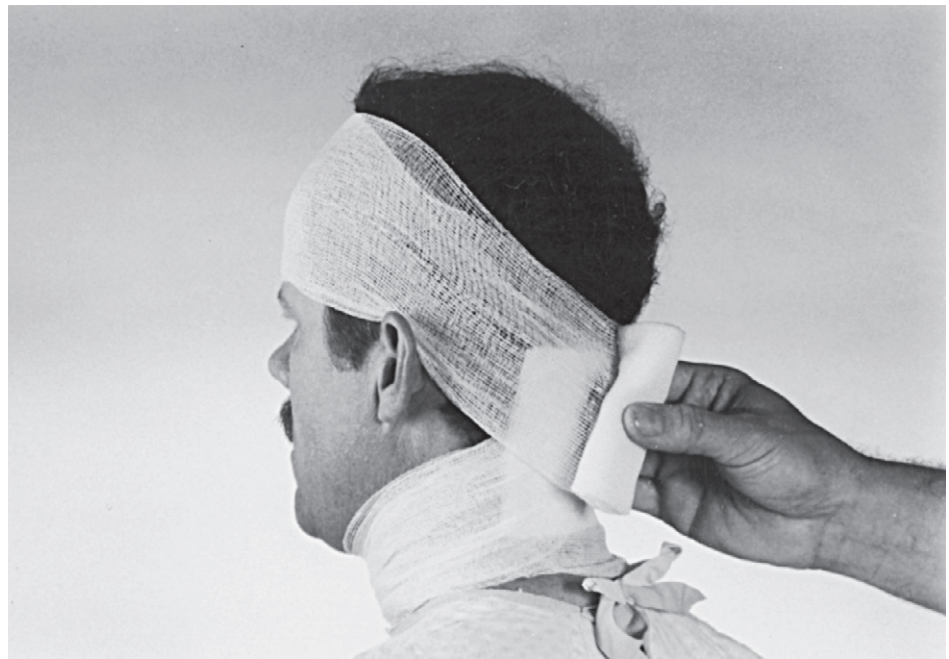### Hand and Finger

Fingers can be bandaged in one of two ways: gauze wrapping or tube gauze application. After applying ointment and a nonadherent base, 2 × 2 sponges are placed over the actual wound. One or two layers of 2-inch gauze bandage are placed over the finger (Fig. 20-11). The bandage then is turned to wrap the entire finger circumferentially from the finger base to tip and back to the base again. To complete the bandaging, the gauze is carried in a figure-eight pattern down around the palm and finally is anchored at the wrist. Gauze bandaging of the finger alone tends to be inadequate, and the dressing can come off prematurely. The basic technique of tube gauze bandages is illustrated in Figure 20-12.

Injuries of the hand itself are bandaged as shown in Figure 20-13. Depending on the size of the hand, 2- or 3-inch gauze wrapping is placed over the nonadherent base and sponge covering. The gauze wrap includes the wrist to ensure proper anchoring. When two or more fingers are incorporated in a hand dressing, they have to be separated by gauze or sponge strips to prevent skin-to-skin contact and subsequent maceration (Fig. 20-14).



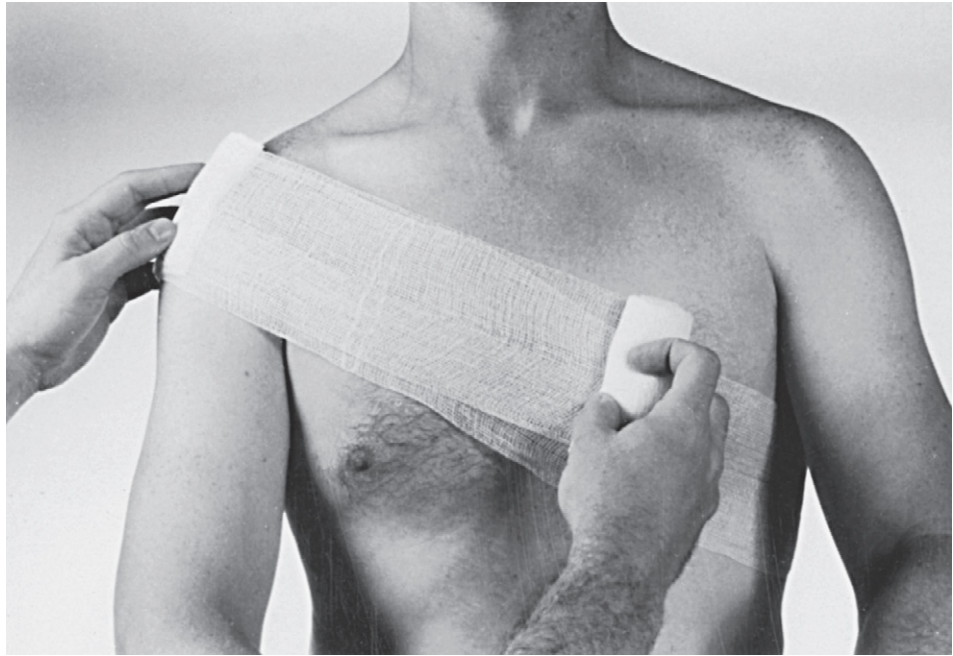A



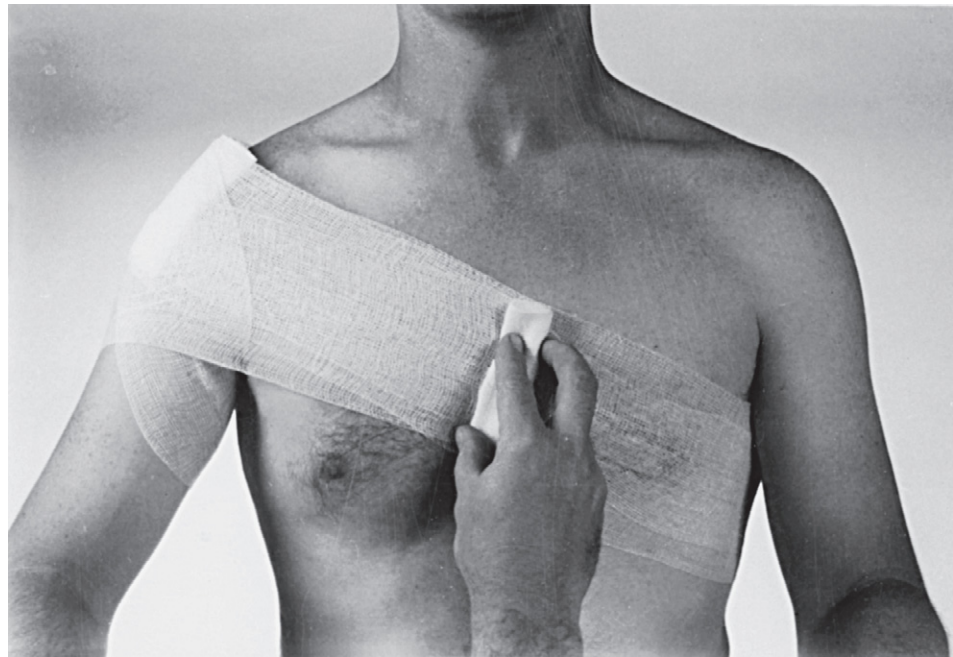B

**Figure 20-6** Technique for application of dressing of the posterior neck area. **A**, After placement of 4 × 4 sponges, gauze wrapping is brought gently around the neck to secure the gauze. In a recurrent manner, the dressing is continued around the frontal area and neck in a figure-eight fashion to secure the dressing completely. The ear is clear of the dressing.



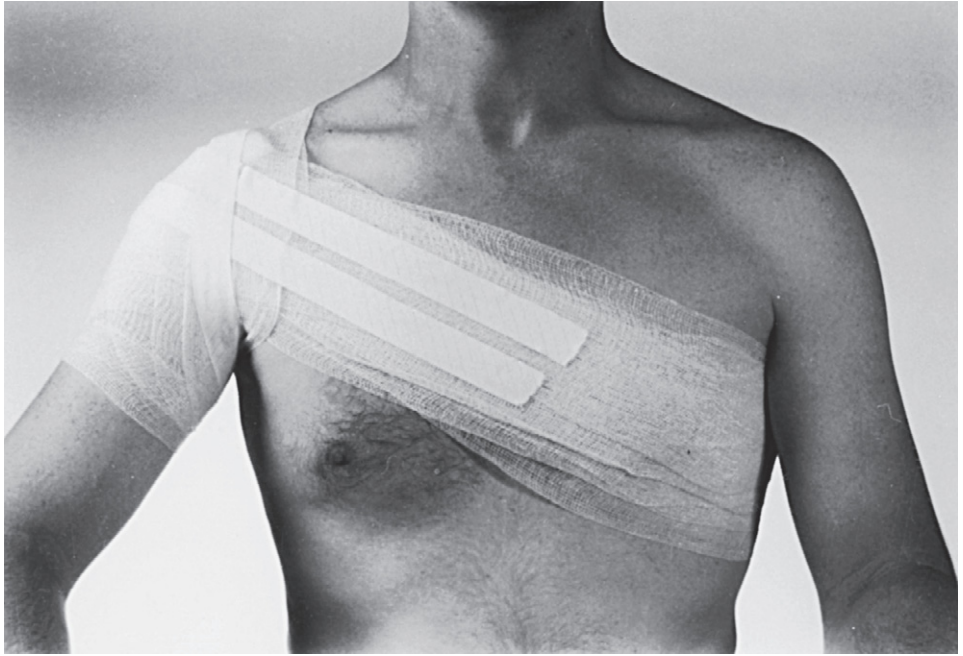

A

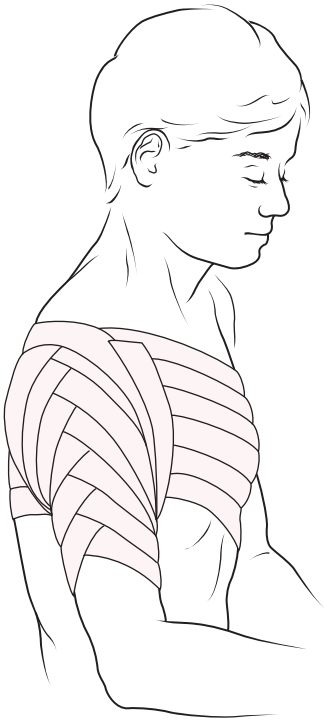


B

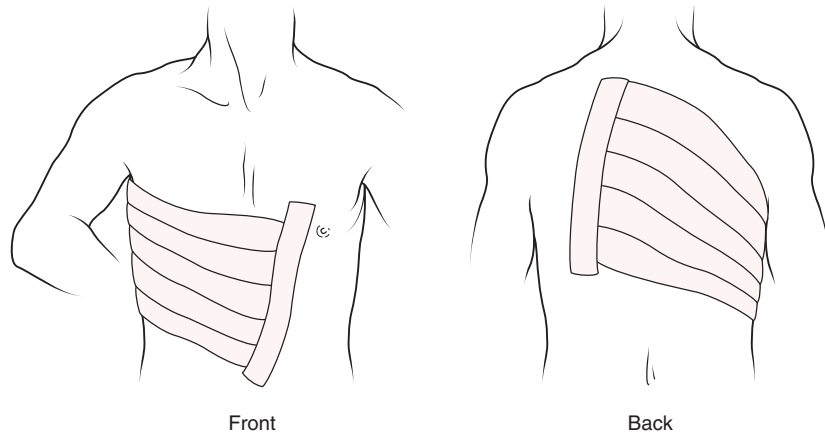
**Figure 20-7** Technique for application of shoulder and upper arm dressing. **A**, The gauze base is placed in the area of injury, and the gauze wrapping is begun by circumferentially placing it around the trunk and shoulder area. **B**, The gauze is continued around the upper arm and the chest in an alternating manner. *(Continued)*

**C**

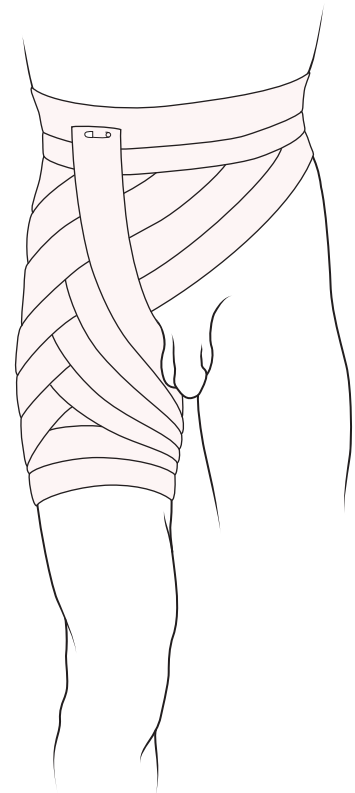
**Figure 20-7** Cont'd. C, Final appearance of a shoulder dressing.



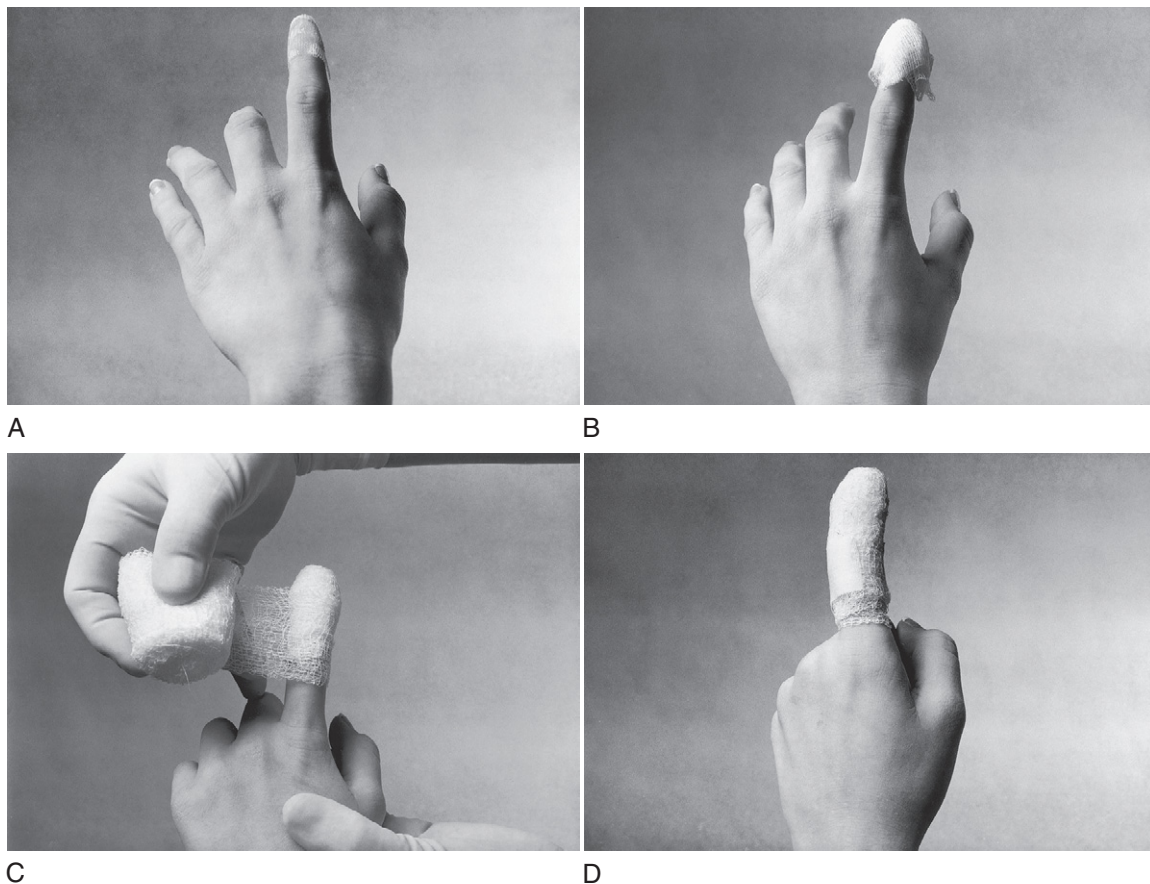
**Figure 20-8** A schematic of the shoulder dressing is presented for clarification.



**Figure 20-9** Technique for application of a truncal dressing. Gauze wrapping is brought around the hemithorax and secured with benzoin and tape.



**Figure 20-10** Technique for dressing the groin and upper thigh area. Similar to the shoulder dressing, the gauze is brought in an alternating manner first around the trunk and then the thigh.



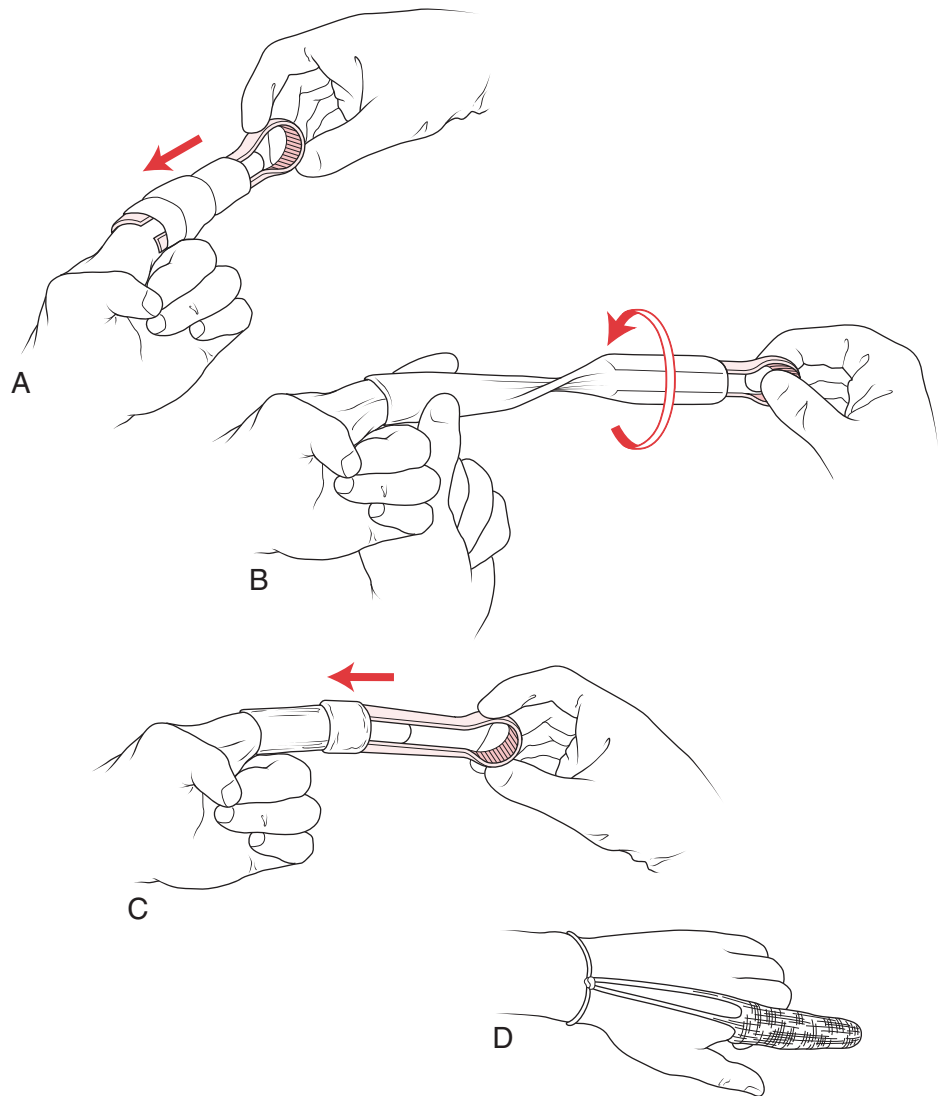
**Figure 20-11** Technique for dressing a finger and fingertip. **A**, The dressing begins with a nonadherent base to cover the wound. **B**, A small 2 × 2 gauze sponge is molded over the tip. **C**, A 2-inch gauze bandage is wrapped around the finger, from tip to base. **D**, The dressing is secured with adhesive tape. Do not apply tape circumferentially to avoid digital edema and vascular compromise.

### Elbow and Knee

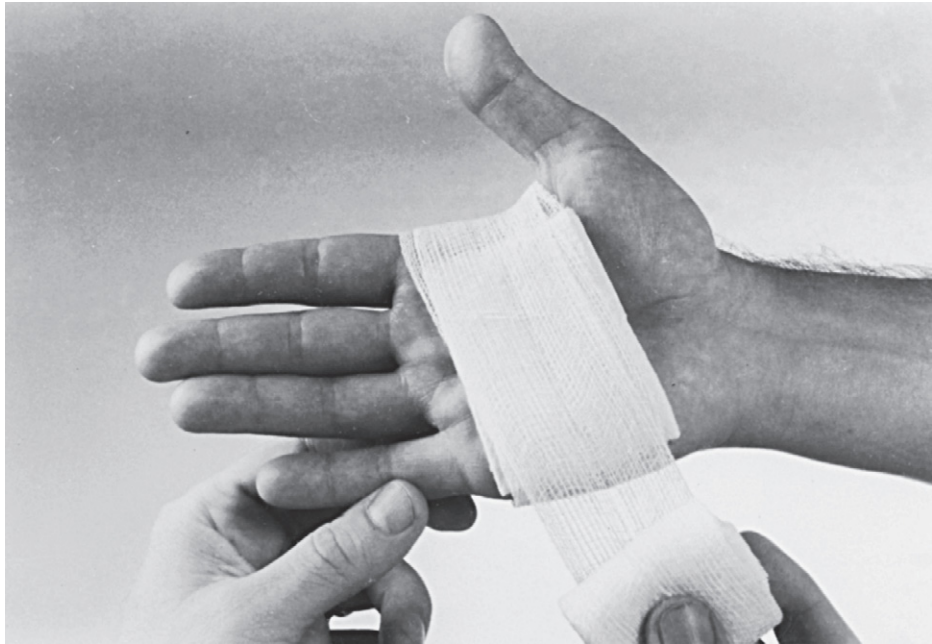The elbow and knee can be wrapped circumferentially with 4-inch gauze. Although the dressing is adequate, it limits motion of the joint. When placed with the joint in some flexion, the figure-eight technique allows for more freedom of movement (Fig. 20-15). Incorporated into the bandaging are 4 × 8 gauze sponges that are placed over the extensor surfaces. These large sponges allow for “travel” as the joint is flexed and extended.

### Ankle, Heel, and Foot

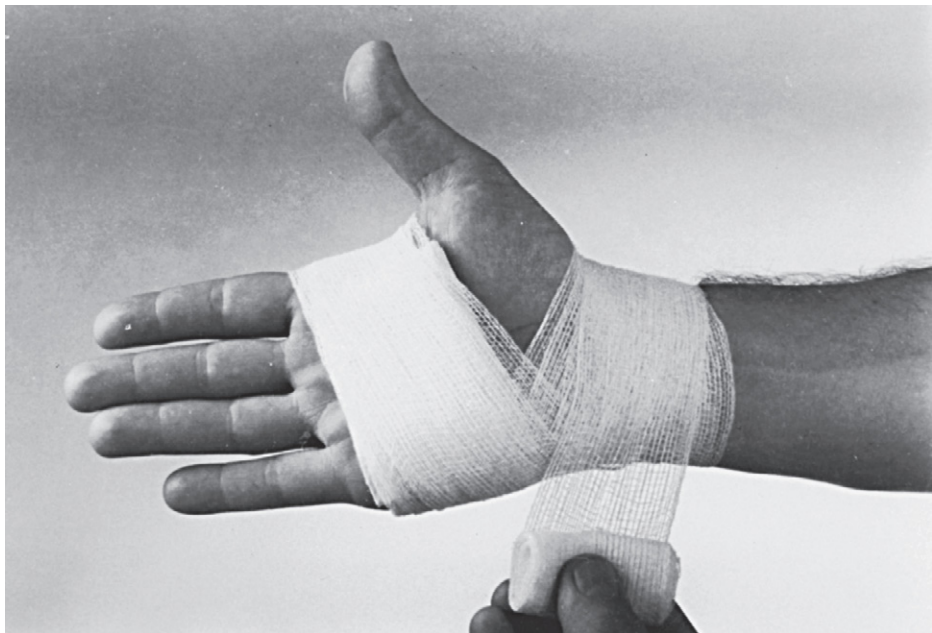Ankle and foot dressings are straightforward. The gauze bandage wrapping is in the same figure-eight style used for the knee and elbow. When the foot is bandaged, the ankle always is included as the anchoring point. The difficult area to cover is the heel. The wrapping starts around the heel and anterior portion of the ankle (Fig. 20-16). After three or four wraps, the bandage is brought around the heel alone, then around the foot. This process is continued until the foot, heel, and ankle all are part of the dressing.



**Figure 20-12** Technique for placement of a tube gauze finger bandage. **A**, Sufficient tube gauze is slid onto the applicator, then brought over the finger. **B**, The first layer of tube gauze is secured as the applicator is brought distally from the finger and rotated 180 degrees. **C**, The next layer of tube gauze is placed by the applicator over the digit. **D**, This process is repeated until an adequate number of layers of tube gauze have been applied.

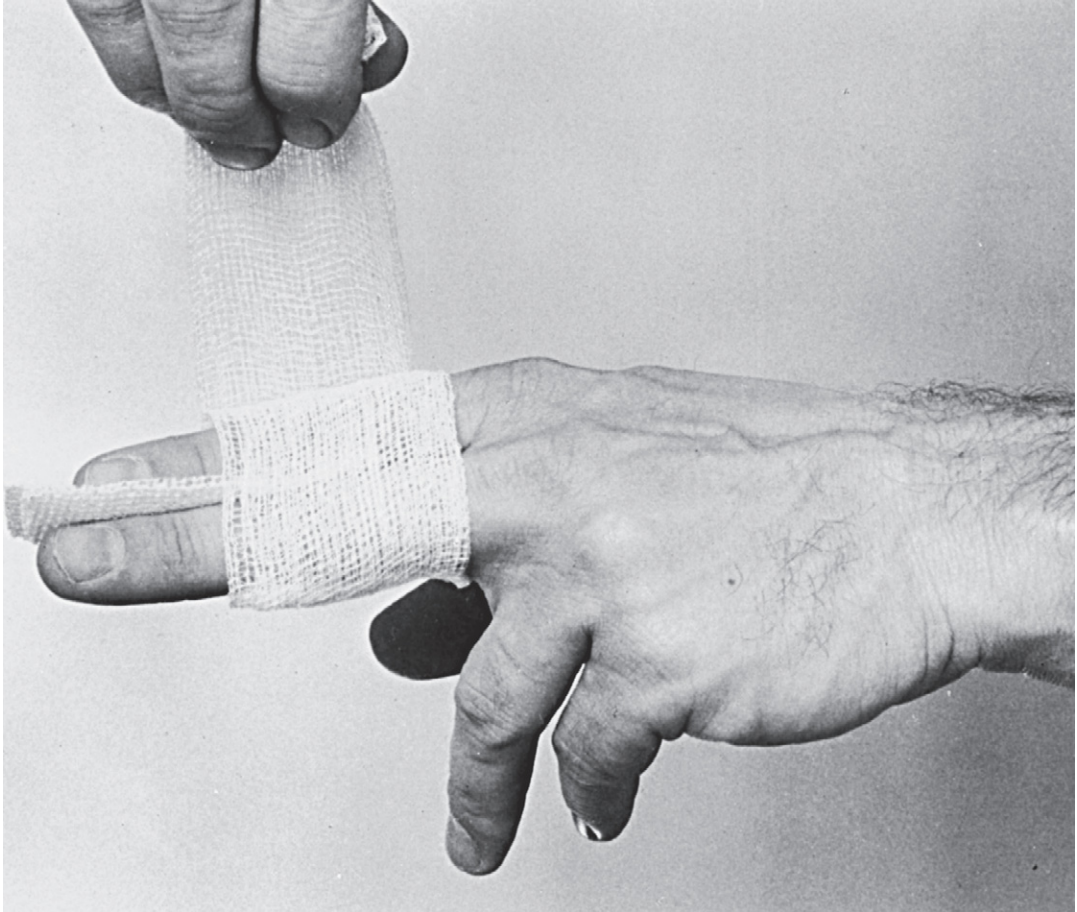

A

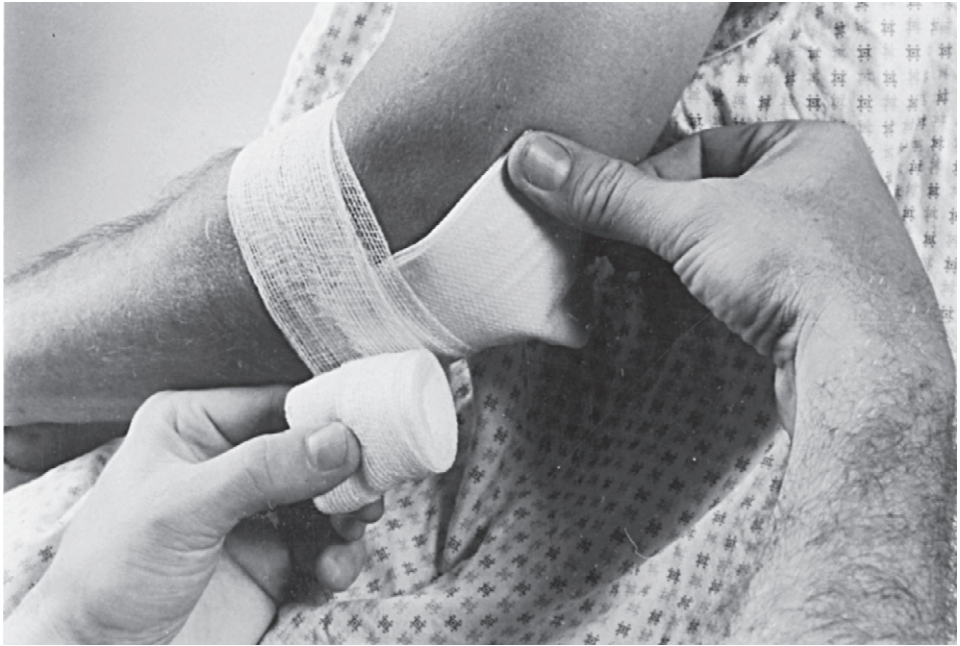

B

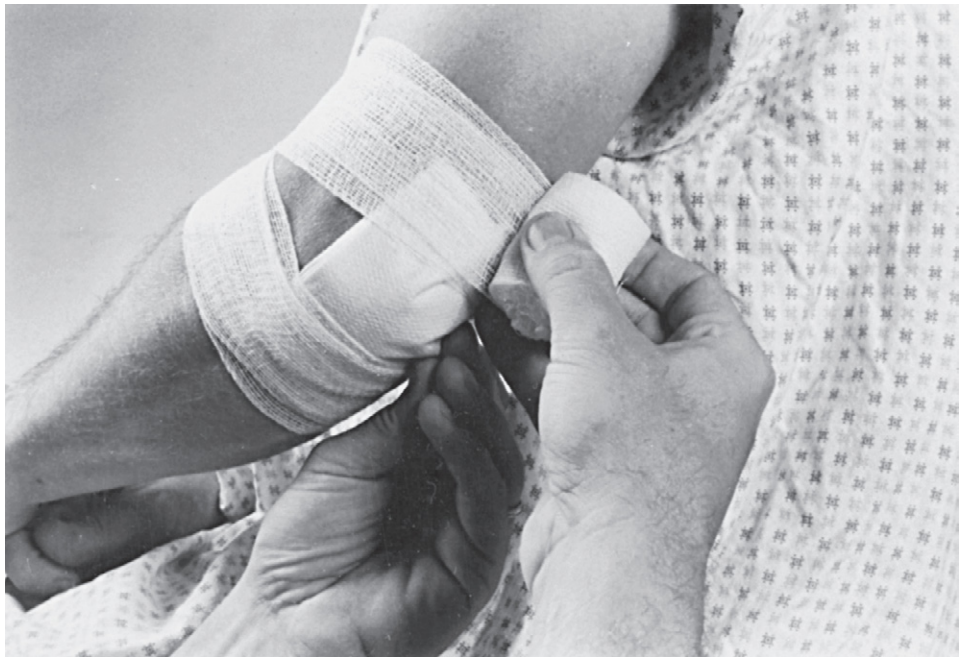**Figure 20-13** Technique for placing a dressing on the palmar or dorsal surface of the hand. **A**, The nonadherent base and 4 × 4 gauze sponges are placed on the palm or dorsum of the hand. The gauze wrapping is begun by securing this dressing base. **B**, The dressing is completed by alternate wrapping of the palm and the wrist with the gauze wrap. Tape is applied in a noncircumferential manner to complete the dressing.



**Figure 20-14** Always place gauze between skin-to-skin contact areas to prevent maceration.



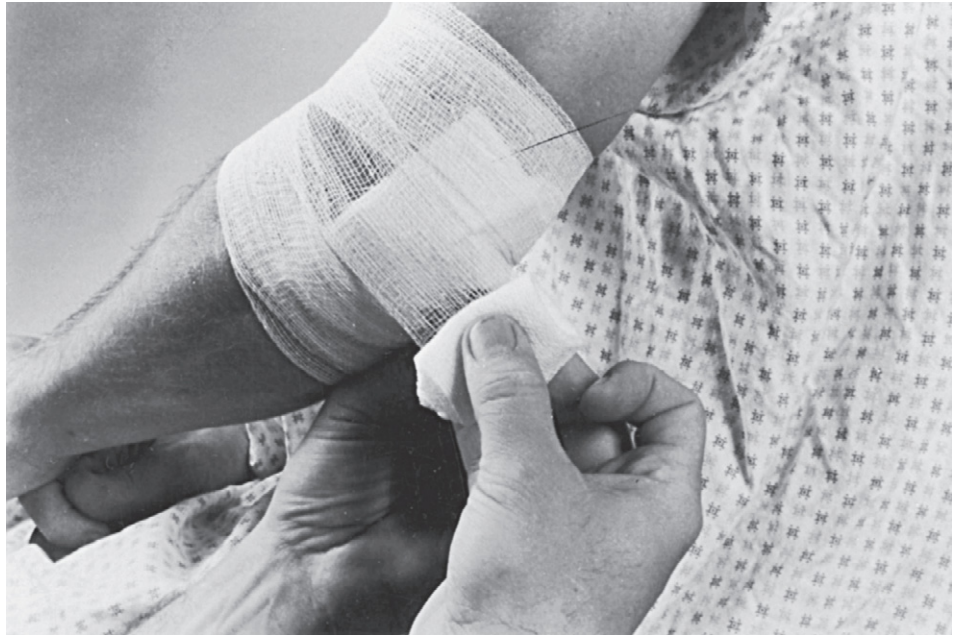A



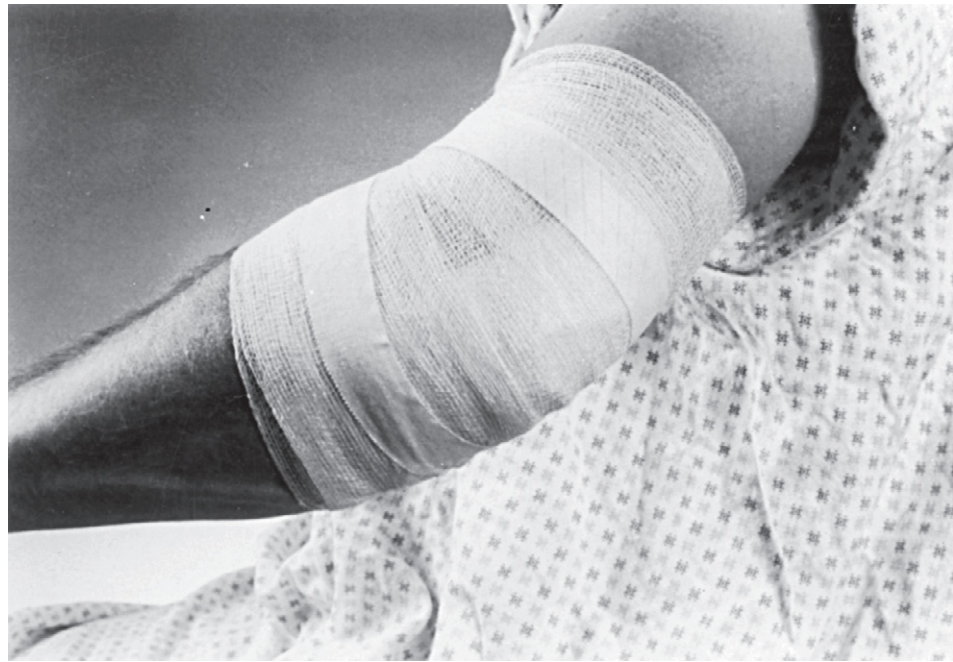B

**Figure 20-15** Technique for elbow or knee dressing. **A**, The gauze sponge is placed over the extensor surface of the knee or elbow and secured with the beginnings of a gauze wrap. **B**, The gauze wrap is brought over to the opposite side of the gauze dressing base.



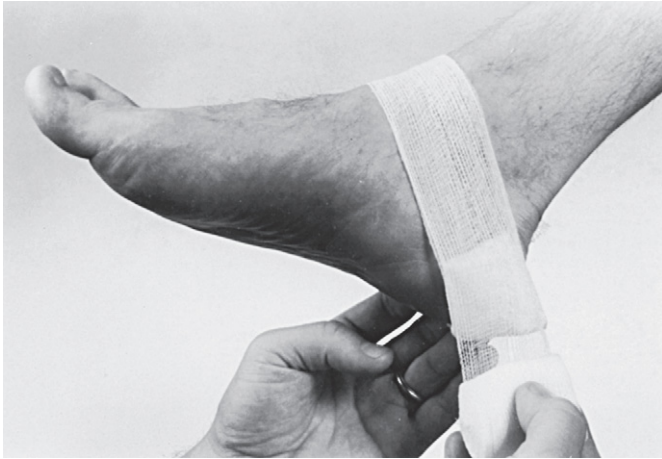


C

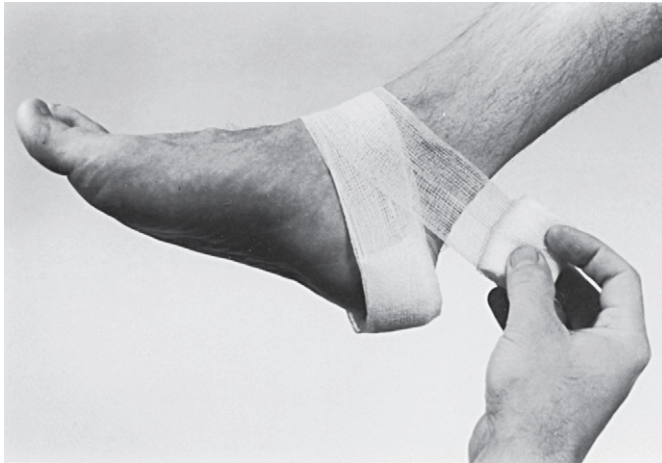

D

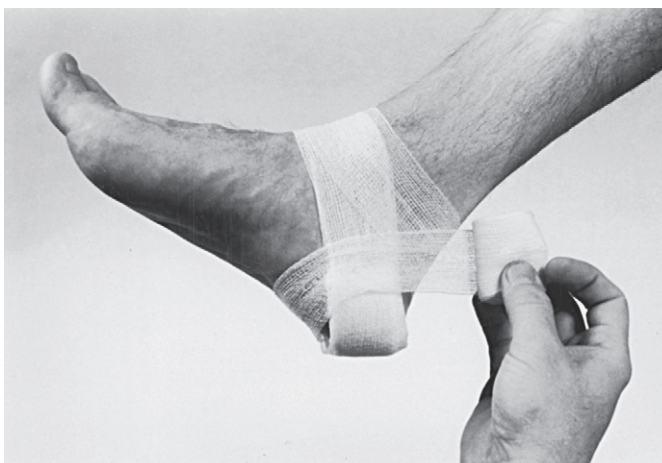**Figure 20-15** Cont'd. C, The gauze wrapping is continued over the center portion of the dressing base. D, An example of a completed dressing. Most elbow and knee dressings are fashioned with the knee or elbow in a slightly flexed position to provide for better patient mobility.



A

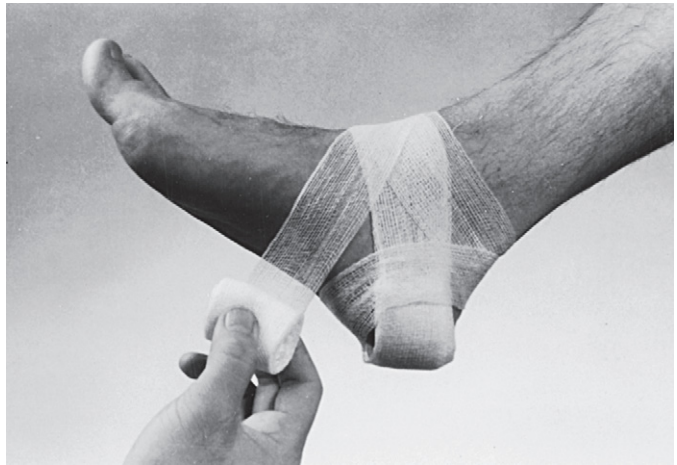

B

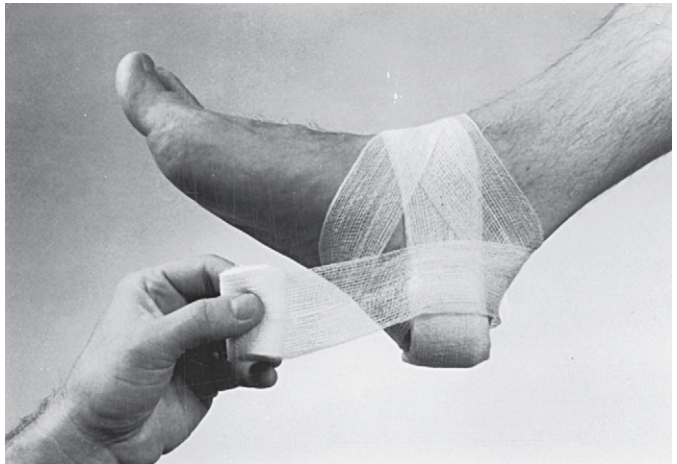


C

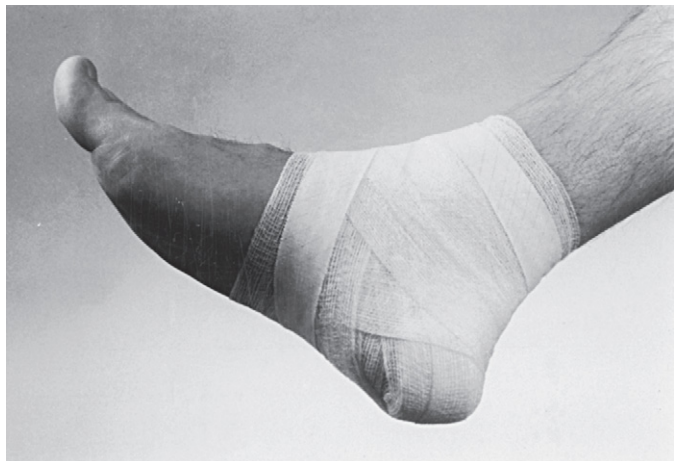**Figure 20-16** Technique for heel dressing. **A**, The dressing base is placed over the area of concern that base. The gauze wrap is continued around the ankle. **C**, The gauze wrap is brought directly across and around the heel.



D



E



F

**Figure 20-16** Cont'd. **D**, When it has crossed the heel, it is brought over the ankle and then around the foot. **E**, After being brought around the ankle and then around the foot, it is brought back in the reverse manner over the heel. **F**, Completed example of heel dressing.

**REFERENCES**

1. Stuzin J, Engrav LH, Buehler PK: Emergency treatment of facial lacerations, *Postgrad Med* 71:81-83, 1982.
2. Eaglestein WH, Mertz PM: Effect of topical medicaments on the rate of repair of superficial wounds. In Dineen P, editor: *The surgical wound*, Philadelphia, 1981, Lea & Febiger.
3. Howells C, Young H: A study of completely undressed surgical wounds, *Br J Surg* 53:436-439, 1966.
4. Lawrence J: What materials for dressings? *Injury* 13:500-512, 1981-1982.
5. Hinman C, Maibach H: Effect of air exposure and occlusion on experimental human skin wounds, *Nature* 200:377-378, 1963.
6. Lammers RL: Principles of wound management. In Roberts JR, Hedges JR, editors: *Clinical procedures in emergency medicine*, Philadelphia, 1991, WB Saunders.
7. Ayliffe GA, Green W, Livingston R, et al: Antibiotic-resistant *Staphylococcus aureus* in dermatology and burn wounds, *J Clin Pathol* 30:40-44, 1977.
8. Norton LW: Trauma. In Hill CJ, editor: *Outpatient surgery*, Philadelphia, 1980, WB Saunders.
9. Dire DJ, Coppola M, Dwyer DA, et al: Prospective evaluation of topical antibiotics for preventing infections of soft-tissue wounds repaired in the ED, *Acad Emerg Med* 2:4-10, 1995.
10. Leyden JJ, Sulzberger MB: Topical antibiotics and minor skin trauma, *Am Fam Physician* 23:121-125, 1981.
11. Van Zyl, Abbott D, Andrews D, et al: Routine use of antibiotic ointment and wound healing, *Emerg Med J* 19:556, 2002.
12. Millikan LE: Wound healing and dermatologic dressings, *Clin Dermatol* 5:31-36, 1987.
13. Wayne MA: Clinical evaluation of Epi-Lock: a semiocclusive dressing, *Ann Emerg Med* 14:20-24, 1985.
14. Bothwell JW, Rovee DT: The effects of dressings on the repair of cutaneous wounds in humans. In Harkiss KJ, editor: *Surgical dressings and wound healing*, London, 1971, Bradford University Press.
15. Panek P, Prusak MP, Bolt D, et al: Potentiation of wound infection by adhesive adjuncts, *Am Surg* 38:343-345, 1972.

# Tetanus Immunity and Antibiotic Wound Prophylaxis

TETANUS PROPHYLAXIS  
Immunization Schedules  
Complications of Tetanus Toxoid

PROPHYLACTIC ANTIBIOTICS  
FOR EMERGENCY WOUNDS

Two issues of prophylaxis arise for virtually all patients with wounds and lacerations. A careful history is taken to establish the tetanus immune status of every patient. Although nurses in most emergency departments are required to document that status in their notes, the ultimate responsibility lies with the physician to ensure that the patient's tetanus prophylaxis is up to date.

Far more controversial and problematic is the issue of antibiotic prophylaxis. Despite the fact that 90% to 95% of all patients with uncomplicated lacerations do not acquire an infection, there remains an excessive use of prophylactic antibiotics.<sup>1-5</sup> As discussed subsequently, multiple large studies have failed to support the use of prophylactic antibiotics, and they may increase the risk for infection.

## TETANUS PROPHYLAXIS

For all patients with an emergency wound or laceration, a decision has to be made about whether to administer tetanus prophylaxis. Although contaminated wounds with extensive devitalized tissue are considered more tetanus-prone than are clean minor wounds, one third of documented cases of tetanus have originated from seemingly trivial injuries.<sup>6,7</sup> A common portal of entry for tetanus is a puncture wound to the foot.<sup>7</sup> The importance of tetanus prophylaxis was underscored during a shortage of immunization doses in 2001.<sup>8</sup> During this period, the number of cases of tetanus increased.<sup>9</sup>

Despite widespread immunization programs, 40 to 50 cases of tetanus are reported each year. Tetanus occurs almost exclusively in patients who have never been immunized or who never completed a proper immunization program.<sup>10</sup> Probably for this reason, most cases are reported in patients who are older than age 50.<sup>10</sup> A high proportion of older adults, when tested for serum tetanus antibody, have been shown to have inadequate levels of protection.<sup>11,12</sup> Young adults and children are more likely to have appropriate levels of protection because of widespread immunization programs that have been put into place in recent years. Regardless of the circumstances, a careful immunization history is taken for every patient with a minor wound. This history should establish whether initial immunization has been properly completed and the date of the last tetanus toxoid dose.

## Immunization Schedules

The guidelines for the administration of tetanus prophylaxis in Table 21-1 are those recommended by the Immunization Practice Advisory Committee of the Centers for Disease

TABLE 21-1 Summary Guide to Tetanus Prophylaxis in Routine Wound Management

History of Adsorbed Tetanus Toxoid (Doses)	Clean, Minor Wounds		All Other Wounds*	
	Td <sup>†</sup>	TIG (250 U)	Td <sup>†</sup>	TIG (250 U)
Unknown or < 3	Yes	No	Yes	No
≥3 <sup>‡</sup>	No <sup>§</sup>	No	No <sup>  </sup>	No

\*Such as, but not limited to, wounds contaminated with dirt, feces, soil, and saliva; puncture wounds; avulsions; and wounds resulting from missiles, crushing, burns, and frostbite.

<sup>†</sup>For children <7 years old, diphtheria-tetanus-pertussis (diphtheria-tetanus, if pertussis vaccine is contraindicated) is preferred to tetanus toxoid alone. For persons ≥7 years of age, Td is preferred to tetanus toxoid alone.

<sup>‡</sup>If only three doses of fluid toxoid have been received, a fourth dose of toxoid, preferably an adsorbed toxoid, should be given.

<sup>§</sup>Yes, if > 10 years since last dose.

<sup>||</sup>Yes, if > 5 years since last dose. (More frequent boosters are not needed and can accentuate side effects.)

Td, tetanus-diphtheria toxoid; TIG, tetanus immunoglobulin.

From ACIP: Diphtheria, tetanus, and pertussis: recommendations for vaccine use and other preventive measures. MMWR Morb Mortal Wkly Rep 40 (RR-10):1-50, 1991.

Control and Prevention.<sup>13</sup> The currently recommended preparation of tetanus toxoid includes the diphtheria toxoid and is designated *Td*. The risk of contracting diphtheria in adulthood is of sufficient magnitude that, as a public measure, prophylaxis against this disease is recommended.<sup>7</sup> The trivalent diphtheria, tetanus, and pertussis (DTaP) preparation is administered to children younger than 7 years old who have not been fully immunized (Table 21-2).<sup>14</sup> DTaP, which has been formulated with acellular pertussis, has fewer local and systemic side effects than the DTP, the older, whole-cell pertussis formulation.<sup>15</sup>

For patients age 7 or older who have never been immunized and who received their first dose of Td at the time of wound repair, follow-up care should include subsequent visits to a medical care facility to complete immunization.<sup>13</sup> Table 21-3 summarizes the time guidelines for administration of the second, third, and booster doses of Td.

### Complications of Tetanus Toxoid

Occasionally a patient reports an allergic reaction to a prior tetanus shot. In a study of 740 patients who claimed to be allergic to tetanus shots, the true incidence of allergy on skin challenge testing was low.<sup>16</sup> Of the 740 patients, 7 developed local reactions that were self-limited. One patient became syncopal, and one developed a fever that lasted for 4 days. Only 1 of 740 patients had a true urticarial response but still tolerated a full immunizing dose. Despite these reassuring figures, the possibility of a serious reaction still must be considered.<sup>16</sup> For patients considered at high risk for a reaction, tetanus immune globulin (250 to 500 U) is given in the emergency department. Tetanus immune globulin confers immunity for that injury but not for future exposures. This preparation consists only of antitetanus antibody and does not cross-react with the toxoid. Referral to an allergist for skin testing and subsequent immunization with toxoid is recommended as prudent follow-up.

Local and systemic reactions to Td are uncommon but occur in 7% to 9% of pediatric patients.<sup>17</sup> Pain, swelling, and erythema can occur at the injection site but usually are self-limited. Preparations containing the pertussis vaccine (DTaP) are associated with a higher rate of adverse reactions. Fever can occur in 5% of infants receiving DTaP.<sup>15</sup> Local reactions, including pain, erythema, and swelling, occur in 10% to 33% of patients.

TABLE 21–2 Routine Diphtheria, Tetanus, and Pertussis Vaccination Schedule for Children Age <7 Years

Dose	Age	Customary Age/Interval	Product <sup>*,†,‡</sup>
Primary 1	2 mo	Age ≥6 wk	DTaP
Primary 2	4 mo	4-8 wk after first dose <sup>  </sup>	DTaP
Primary 3	6 mo	4-8 wk after second dose <sup>  </sup>	DTaP
First booster	15-18 mo <sup>§</sup>	6-12 mo after third dose <sup>  </sup>	DTaP <sup>¶</sup>
Second booster	Before entering kindergarten or elementary school (not necessary if fourth dose [first booster] is administered after fourth birthday)		DTaP
Additional booster	Every 10 yr after last dose		Td <sup>**</sup>

\*Diphtheria and tetanus toxoids and acellular pertussis vaccine (DTaP); diphtheria and tetanus toxoids and whole-cell pertussis vaccine (DTP) are an acceptable alternative to DTaP for any of the five doses.

†Use diphtheria and tetanus toxoids, adsorbed (DT), if encephalopathy has occurred after administration of a previous dose of pertussis-containing vaccine. If the child is age 1 year at the time the first dose of DT is administered, a third dose administered 6-12 months after the second dose completes primary vaccination with DT.

‡Whenever possible, the same DTaP product should be used for all doses. If the same product is not available, Tripedia, ACEL-IMUNE, and Infanrix can be use interchangeably.

<sup>||</sup>Prolonging the interval does not require restarting the series.

<sup>§</sup>If the interval between the third and fourth doses is 36 months and the child is not likely to return for a visit at the recommended age, the fourth dose of either DTaP or DTP may be administered at age 12 months.

<sup>¶</sup>TriHIBit can be administered as the fourth dose after a primary series with either DTaP or whole-cell DTP and a primary series with any *Haemophilus influenzae* type b conjugate vaccine.

\*\*Tetanus-diphtheria toxoids absorbed (Td) (for adult use).

From ACIP: Pertussis vaccination: use of acellular pertussis vaccine among infants and young children. Recommendations of the Immunization Practices Advisory Committee (ACIP), MMWR Morb Mortal Wkly Rep 46 (RR-7):1-25, 1997.

TABLE 21–3 Routine Diphtheria, Tetanus, and Pertussis Vaccination Schedule Summary for Persons ≥ 7 Years

Dose	Age/Interval	Product
Primary 1	First dose	Td
Primary 2	4-8 wk after first dose <sup>*</sup>	Td
Primary 3	6-12 mo after second dose <sup>*</sup>	Td
Booster	Every 10 yr after last dose	Td

\*Prolonging the interval does not require restarting series.

Td, tetanus-diphtheria toxoid.

From ACIP: Diphtheria, tetanus, and pertussis: recommendations for vaccine use and other preventative measures, Recommendations of the Immunization Practices Advisory Committee (ACIP), MMWR Morb Mortal Wkly Rep 40(RR-10):1-50, 1991.

## PROPHYLACTIC ANTIBIOTICS FOR EMERGENCY WOUNDS

For small, uncomplicated, minor, nonbite wounds and lacerations, there is no convincing clinical evidence that systemic antibiotics provide protection against the development of wound infection.<sup>5,18-20</sup> A randomized, controlled study using oral cephalexin for prophylaxis showed no efficacy of the antibiotic for minor lacerations.<sup>5</sup> In two randomized, controlled studies using oral or parenteral cephalosporins for minor hand lacerations, there was no increase in the infection rate of non-antibiotic-treated patients compared with patients treated with antibiotics.<sup>1,18,19</sup>

In a study of 2834 pediatric patients, not only was there no protective effect, but also there was a significant increase in the infection rate in the antibiotic-treated patients.<sup>21</sup> Other studies also support this contradiction.<sup>3,5,19,22</sup> It is thought that selection for resistant organisms, rebound bacterial proliferation after the initial effect, or impairment of host defenses by the drugs might account for this paradox.

Although not all authorities agree, and there is no strong scientific evidence underlying any specific set of recommendations for wound antibiotic prophylaxis, clinical and empirical experience suggests that there are wound characteristics and circumstances that warrant antibiotic intervention.<sup>23-25</sup> If antibiotics are indicated, there is some evidence that the initial dose has to be administered as soon as possible to obtain an effect.<sup>23,25,26</sup> Delays in treatment beyond 3 to 5 hours from injury have been shown in some studies to lead to an increase in the infection rate.<sup>23</sup> Other investigators have found little correlation between the interval from injury to antibiotic delivery and the ultimate risk of wound infection.

The following are guidelines for when antibiotics should be considered:

- *Wound age:* Relative indications include hand and foot wounds more than 8 hours old, facial wounds more than 24 hours old, and other site wounds more than 12 hours old.
- *Wound condition:* Crushing mechanism wounds for which extensive débridement and tissue revision are needed.
- *Contamination:* Wounds initially contaminated with soil, vegetative matter, and other particulates that require extensive cleaning and irrigation.
- *Mammalian bites:* See Chapter 15 for indications for wound prophylaxis in dog, cat, and human bites.
- *Vulnerable anatomic sites:* Wounds of cartilage (ear, nose), tendon, bone, and joint.
- *Circulatory impairment:* Wounds in impaired areas of drainage, such as lymphedema secondary to venous disease or surgical procedure (radical mastectomy).
- *Impaired host defenses:* Diabetes, immunosuppressive agents (corticosteroids, anti-cancer agents), and diseases with altered immune status.
- *Cardiac valvular disease:* Guidelines published by the American Heart Association should be followed relative to wounds in patients with cardiac valvular disease. Prophylaxis is not indicated in patients who have clean, uncomplicated lacerations.
- *Orthopedic implants:* Prophylaxis should be considered in patients with orthopedic implants who have contaminated wounds. Prophylaxis is not indicated for clean, uncomplicated wounds.

The choice of antibiotics for non-bite wound prophylaxis is based on the likely infecting organisms. Multiple studies have shown that for common, uncomplicated wounds and lacerations, *Staphylococcus aureus* and *Streptococcus* species are the infecting agents in more than 90% of cases.<sup>19,20,22,27</sup> More extensive wounds, involving contamination with soil, increase the spectrum to include gram-negative organisms and *Clostridium* species.<sup>28</sup> Wounds involving fresh water, including lakes, streams, and swimming pools, may be contaminated with *Aeromonas hydrophila*.<sup>29,30</sup> Injuries occurring in salt water can be infected with *Vibrio vulnificus*.<sup>31</sup>



For prophylaxis to be effective, the initial dose should be delivered as soon after the injury as possible, preferably in parenteral form, to ensure an adequate level of antibiotic activity.<sup>24-26</sup> For a common, uncomplicated, nonbite wound requiring prophylaxis, the first-generation cephalosporin cefazolin (Ancef) can be administered parenterally, followed by a 3- to 5-day course of cephalexin (Keflex), cephadrine (Velosef), cefadroxil (Duricef), or dicloxacillin. Cefadroxil has the advantage of once-a-day or twice-a-day dosing, which may encourage greater compliance.

For patients allergic to penicillin and cephalosporins, an intravenous dose of clindamycin (Cleocin) followed with oral clindamycin provides coverage of common infecting organisms. Because of the short course, the risk of diarrheal complications from clindamycin is negligible. The macrolides, including erythromycin and azithromycin, are another alternative. If *A. hydrophila* is suspected, ciprofloxacin (Cipro), trimethoprim/sulfamethoxazole (Bactrim, Septra), or an aminoglycoside provides adequate coverage. *V. vulnificus* is more difficult to treat but is sensitive to doxycycline (Vibramycin), chloramphenicol, and ceftazidime (Fortaz).

## REFERENCES

1. Cummings P, Del Beccaro MA: Antibiotics to prevent infection of simple wounds: a meta-analysis of randomized studies, *Am J Emerg Med* 13:396-400, 1995.
2. Gosnold JK: Infection rate of sutured wounds, *Practitioner* 218:584-585, 1977.
3. Hutton PA, Jones BM, Law DJ: Depot penicillin as prophylaxis in accidental wounds, *Br J Surg* 65:549-550, 1978.
4. Rutherford WH, Spence R: Infection in wounds sutured in the accident and emergency department, *Ann Emerg Med* 9:350-352, 1980.
5. Thirlby RC, Blair AJ, Thal ER: The value of prophylactic antibiotics for simple lacerations, *Surg Gynecol Obstet* 156:212-216, 1983.
6. Brand DA, Acampora D, Gottlieb LD, et al: Adequacy of anti-tetanus prophylaxis in six hospital emergency departments, *N Engl J Med* 309:636-640, 1983.
7. Furste W: Fifth international conference on tetanus, Ronneby, Sweden, 1978, *J Trauma* 20:101-105, 1980.
8. Zun LS, Downey L: Tetanus immunization shortage in the US, *Am J Emerg Med* 21:298-301, 2003.
9. Tetanus surveillance—United States 1998-2000, *MMWR Morb Mortal Wkly Rep* 52(SS03):1-8, 2003.
10. Richardson JP, Knight AL: The management and prevention of tetanus, *J Emerg Med* 11:737-742, 1993.
11. Alagappan K, Rennie WP, McPherson P, et al: Seroprevalence of antibody levels to tetanus in adults over 65 years of age (Abstract), *Acad Emerg Med* 2:373, 1995.
12. Crossley K, Irvine P, Warren JB, et al: Tetanus and diphtheria immunity in urban Minnesota adults, *JAMA* 242:2298-2300, 1983.
13. ACIP: Diphtheria, tetanus, and pertussis: recommendations for vaccine use and other preventative measures. Recommendations of the Immunization Practices Advisory Committee (ACIP), *MMWR Morb Mortal Wkly Rep* 40(RR-10):1-50, 1991.
14. ACIP: Pertussis vaccination: use of acellular pertussis vaccine among infants and young children. Recommendations of the Immunization Practices Advisory Committee (ACIP), *MMWR Morb Mortal Wkly Rep* 46(RR-7):1-25, 1997.
15. Conrad DA, Jenson HB: Using acellular pertussis vaccines for childhood immunization, *Postgrad Med J* 105:165-183, 1999.
16. Jacobs RL, Lowe RS, Lanier BQ: Adverse reactions to tetanus toxoid, *JAMA* 247:40-42, 1982.
17. Cody CL, Baraff LJ, Cherry JD, et al: Nature of adverse reactions associated with DTP and DT immunizations in infants and children, *Pediatrics* 68:650-660, 1981.
18. Grossman JA, Adams JP, Kunec J: Prophylactic antibiotics in simple hand lacerations, *JAMA* 245:1055-1056, 1981.
19. Haughey RE, Lammers RL, Wagner DK: Use of antibiotics in the initial management of soft tissue wounds, *Ann Emerg Med* 10:187-190, 1981.
20. Samson RH, Altman SF: Antibiotic prophylaxis for minor lacerations, *N Y State J Med* 77:1728-1730, 1977.
21. Baker MD, Lanuti M: The management and outcome of lacerations in urban children, *Ann Emerg Med* 19:1001-1005, 1990.
22. Worlock P, Boland P, Darrell J, et al: The role of prophylactic antibiotics following hand surgery, *Br J Clin Pract* 34:290-292, 1980.
23. Burke JF: The effective period of preventive antibiotic action in experimental incisions and dermal lesions, *Surgery* 50:161-168, 1961.

24. Cardany CR, Rodeheaver G, Thacker J, et al: The crush injury: the high risk wound, *J Am Coll Emerg Physicians* 5:965-970, 1976.
25. Edlich RF, Kenny JG, Morgan RF, et al: Antimicrobial treatment of minor soft tissue lacerations: a critical review, *Emerg Clin North Am* 4:561-580, 1986.
26. Morgan WJ, Hutchinson D, Johnson HM: The delayed treatment of wounds of the hand and forearm under antibiotic cover, *Br J Surg* 67:140-141, 1976.
27. Day TK: Controlled trial of antibiotics in minor wounds requiring suture, *Lancet* 2:1174-1176, 1975.
28. Fitzgerald RH, Cooney WP, Washington JA, et al: Bacterial colonization of mutilating hand injuries and its treatment, *J Hand Surg* 2:85-89, 1977.
29. Gold WL, Salit IE: *Aeromonas hydrophila* infections of the skin and soft tissue: report of 11 cases, *Clin Infect Dis* 16:69-74, 1993.
30. Skiendzielewski WH, O'Keefe KP: Wound infection due to fresh water contamination of *Aeromonas hydrophila*, *J Emerg Med* 8:701-703, 1990.
31. Chuang YC, Young C, Chen CW: *Vibrio vulnificus* infections, *Scand J Infect Dis* 21:721, 1989.

# Suture Removal and Wound Aftercare

## SUTURE REMOVAL

Timing of Removal  
Technique for Removal

## ANALGESIA

## INSTRUCTIONS TO THE PATIENT

Wound Protection  
Dressing Change and Follow-Up Intervals

Wound Cleansing and Bathing  
Signs of Wound Infection  
Written Instructions

## UNDERSTANDING WOUND HEALING

Wound aftercare includes return scheduling for suture removal, aftercare instructions to the patient, and information on what to expect as the wound heals. When carefully and fully informed, most patients take good care of their wounds and dressings. Written instructions are followed best when reinforced with unhurried verbal explanations. Because each wound and patient differs, information about dressing care, limitations of activity, bathing, and suture removal has to be individualized. Patients often expect that healing is complete when the sutures are removed. If educated about the changes that a wound undergoes over months, patients are more likely to understand and accept the wound's appearance.

## SUTURE REMOVAL

### Timing of Removal

The recommended intervals between wound repair and suture removal are listed in Table 22-1. In the face, where cosmetic appearance is paramount, sutures are removed as early as possible; this is done with the knowledge that a facial wound has barely begun to gain tensile strength. Minimal accidental force can cause disruption and dehisce the laceration. The application of wound tapes for continued support over healing lacerations is recommended. A return visit for tape removal and wound adhesive closure is not necessary. If wound tapes are the primary method of wound closure, they can be left in place for 10 days without causing complications. Adhesives flake off with time. At minimum, these alternative closures should support the wound for the time recommended for sutures.

Suture punctures are small wounds. Epithelial cells invade these small wounds, leaving keratinized epithelial "plugs" caught in the healing suture wound. This phenomenon produces unsightly "railroad tracks" that can be avoided if sutures are removed in less than 7 days.<sup>1</sup> Skin tapes and wound adhesives as wound closure methods are alternative techniques to avoid suture tracking. The subcuticular and pull-out dermal closures described in Chapter 11 are other closure options.

In other areas of the body, where cosmetics is not as important and wound healing is not as rapid as in the highly vascular face, sutures are left in for longer periods. Extensor surfaces of joints require longer times before removal because of the mechanical forces brought

TABLE 22-1 Recommended Intervals for Removal of Percutaneous (Skin) Sutures

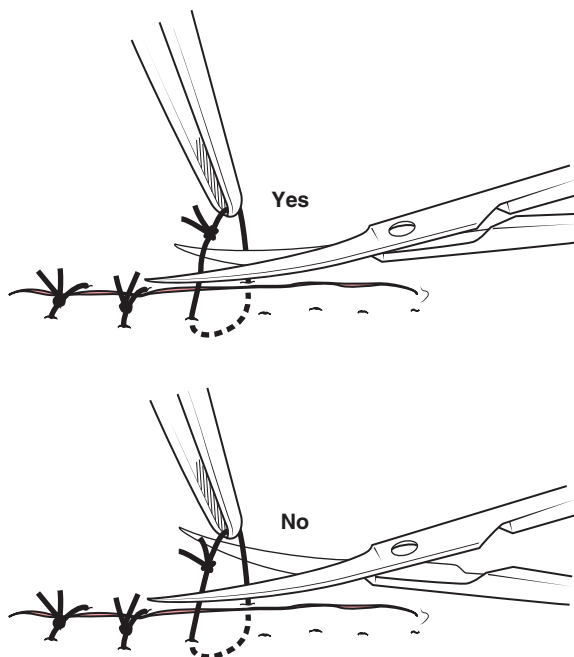
Location	Days to Removal
Scalp	6-8
Face	4-5
Ear	4-5
Chest/abdomen	8-10
Back	12-14
Arm/leg*	8-10
Hand*	8-10
Fingertip	10-12
Foot	12-14

\*Add 2 to 3 days for joint extensor surfaces.

to bear on the healing wound. Because of the dependency of the lower extremities and their relatively slower rate of healing, sutures are left in place longer in those sites as well.

### Technique for Removal

The technique for suture removal is illustrated in Figure 22-1. The suture is cut under the knot, close to the skin surface, so that when it is pulled from the wound, the previously exposed and contaminated portion of the suture does not travel back through the wound.



**Figure 22-1** Technique for correct removal of a suture. The scissors cut between the knot and the skin. The lower figure shows the incorrect technique to remove sutures. (Modified from Zukin D, Simon R: Emergency wound care: principles and practice, Rockville, Md, 1987, Aspen Publishers.)

Although standard scissors can be used for most suture removal tasks, iris scissors or a no. 11 scalpel blade is recommended to cut the fine sutures used on the face. Bandage or commercial suture removal scissors have tips that often are too blunt to cut small, closely spaced sutures easily. Before removal, all dried coagulum is removed gently from the suture line with cotton swabs and hydrogen peroxide. Cleaning away the coagulum makes locating small sutures and knots much easier. In addition, it prevents the unnecessary tugging and pulling that often accompany suture removal when sutures are excessively crusted.

---

## ANALGESIA

Pain after wounding can range from trivial to severe. Simple lacerations are well tolerated by the patient after repair and dressing. Abrasions and partial-thickness (second-degree) burns can be unbearable. For most patients with uncomplicated lacerations, aspirin, acetaminophen, or other nonsteroidal antiinflammatory drugs relieve residual discomfort after repair. Occasionally, codeine or hydrocodone is necessary. Burn victims require more powerful analgesics, such as oxycodone. In addition to drugs, elevation of the injured part, proper immobilization, and cool compresses to the affected area can greatly enhance pain relief.

The pain of lacerations and burns tends to subside significantly within 24 to 48 hours. A key follow-up instruction to the patient is to be concerned when pain increases or recurs. The most likely cause of this change in the pain pattern is wound infection. If pain increases, the physician must be notified immediately.

---

## INSTRUCTIONS TO THE PATIENT

### Wound Protection

Patients need to be instructed carefully in nonmedical terms about how to care for their wound at home. The key principles of home care are protection, elevation, and cleanliness. Most patients instinctively protect wounds from further trauma, but the caregiver should give a reminder that although sutures are in place, undue pressure or other mechanical forces on the wound can cause disruption and possible infection. Counseling and admonition against premature use of a repaired hand or foot are especially necessary for patients who are anxious to return to work or sporting activities.

Elevation is particularly important in extremity wounds. The tendency of lower extremities and hands to develop edema from lymphatic stasis is well recognized. Elevation helps prevent these complications, lessens pain, and improves wound healing. Lower extremity wounds have a higher rate of wound infection, a complication that can be abetted by edema and stasis. Crutches and slings for extremity wounds are useful adjuncts for home wound care.

Fresh healing wounds and repaired lacerations are vulnerable to direct sunlight. Excessive exposure can result in irreversible darkening or hyperpigmentation of the healing epidermis.<sup>2</sup> The wound is at risk for 1 year or until the scar fully matures. Sunblock agents are recommended when prolonged exposure to the sun or ultraviolet light, such as in a tanning facility, is anticipated.

### Dressing Change and Follow-Up Intervals

Dressing management and change intervals are discussed in Chapter 20.

### Wound Cleansing and Bathing

Cleanliness is an important issue in wound aftercare. Sutured wounds of the scalp and face can be left open, provided that they are kept clean. In a controlled study of 200 head and neck incisions and traumatic lacerations, the investigators concluded that early washing

(8 to 24 hours) after wound repair did not significantly alter wound healing or increase the potential for infection.<sup>3</sup> Wounds on other body sites can be cleansed gently 12 to 24 hours after suture repair without ill effect.<sup>4</sup>

Patients can begin to bathe 12 to 24 hours after wound repair. They can be allowed to bathe once a day, provided that the wound is not immersed and soaked in water. Dressings, unless instructed by the caregiver to be left intact, can be removed for cleansing. Showers are preferable to tub baths. Gentle soaping and rinsing are followed immediately by patting the wound dry with a soft towel. Application of an antibiotic ointment or reapplication of a dressing is recommended after each washing.

### Signs of Wound Infection

Most wounds heal without problems or complications. A few wounds become infected, however, despite compliance with accepted wound care procedures. In an analysis of more than 5000 patients, characteristics of wounds that became infected were identified.<sup>5</sup> The overall infection rate was 3.5%. Patients with wound infection were likely to be older or to have diabetes. Large wounds and wounds with visible contamination or foreign bodies also were at risk. Recommendations for prophylactic antibiotics are discussed in Chapter 21.

Every patient has to be instructed in the signs of wound infection. If any of these signs develop, the patient needs to return immediately for examination. Signs of infection include the following:

- *Excessive discomfort*: Most minor wounds are only mildly uncomfortable.
- *Discharge*: Bloody discharge can stain the dressing. Continued drainage, particularly if it is purulent appearing, is a sign of infection.
- *Redness*: Erythema from neovascularization and capillary dilation accompanies most wounds. Redness that extends well beyond the wound margins (>5 mm) with accompanying swelling, induration, or tenderness does not occur in normal healing wounds.
- *Lymphangitic streaks, local nodal enlargement, and fever* all are signs of advanced infection.

If a wound becomes infected, sutures or staples act as foreign bodies and have to be removed. Attempts to remove alternate sutures and start the patient on antibiotics are likely to fail. Chapter 21 discusses the care of infected wounds in greater detail.

### Written Instructions

Patients should be given specific written instructions reinforcing and detailing general principles and any other specifics for the given wound problem. Follow-up visits, dates, and times have to be written clearly and understood by the patient and, whenever possible, by accompanying family members. Figure 22-2 is an example of simple, yet effective, written wound care instructions.

---

## UNDERSTANDING WOUND HEALING

Patients are most concerned about the size and appearance of the scar that will result from their laceration or wound. Because traumatic injuries occur randomly on the body surface, the final outcome, to a certain extent, is predetermined. It is the duty of the caregiver to advise the patient about the kind of scar he or she can expect. Candidly discussing various aspects of wound healing, such as the effects of wound mechanism, associated diseases, body region, and skin tension, allows the patient to accept and cope with the healing process better (see Chapter 4).

**Wound Care**

---

*You have been treated for a laceration. A laceration is a break in the skin that usually needs stitches or staples to close.*

---

**Treatment**

On the first day, keep the wound clean and dry.

After the first day, you should look at the wound and clean it at least once a day. You can clean the wound with soap and water, and an ointment may be applied as directed by your doctor. The wound should be covered with a clean, dry bandage. Face wounds can be left uncovered.

If you are given antibiotic medication, take the medication as prescribed, and take the medication until it is all gone.

Work limitations:

- Do not work until stitches or staples removed
- Light duty to protect the wound
- Full duty
- Other

Return for stitches/staples removal on:

---

**Notify Your Doctor or Return to the Emergency Department If You Experience**

Any signs of infection such as swelling, redness, drainage, increased pain, red streaks, or fever.

---

**Figure 22-2** Sample discharge instructions for patients with lacerations.

The appearance of a wound changes during the healing process, which often gives rise to patient concerns. It is important for patients to understand that although stitches are removed within days of the injury and the wound appears to be sealed, tensile strength is low. Reopening, or dehiscence, can occur if the wound is exposed to undue trauma. Wounds often are temperature and touch sensitive for weeks. Early scars appear red and raised, but eventual blanching and contraction eliminate those characteristics. People with dark skin have to be informed that scars may not regain lost pigmentation and might be lighter than the surrounding skin.

Finally, patients have to be counseled that scars mature and change in configuration for several months until they take on their final appearance. More often than not, an initially unsightly scar becomes acceptable to the patient. A plastic surgeon can be consulted to assess for possible scar revision if concerns remain about the appearance of the scar.

**REFERENCES**

1. Crikelair CT: Skin suture marks, *Am J Surg* 96:631-632, 1958.
2. Ship AG, Weiss PR: Pigmentation after dermabrasion: an avoidable complication, *Plast Reconstr Surg* 75:528-532, 1985.
3. Goldberg HM, Rosenthal SAE, Nemetz JC: Effect of washing closed head and neck wounds on wound healing and infection, *Am J Surg* 141:358-359, 1981.
4. Noe JM, Keller M: Can stitches get wet? *Plast Reconstr Surg* 81:82-84, 1988.
5. Hollander JE, Singer AJ, Valentine SM, et al: Risk factors for infection in patients with traumatic lacerations, *Acad Emerg Med* 8:716-720, 2001.



# Index

Note: Page numbers followed by f indicate figures, t tables, and b boxes.

## A

Abdominal injury, suture removal from, 312t

Abrasions, 249–251  
forehead, 159, 159f  
laceration within, 148, 150f

Abscess, 263–269

axillary, 263  
Bartholin's gland, 264, 268  
breast, 264, 268  
buttock, 263, 264, 265, 268  
causes of, 263  
clinical presentation of, 263–264  
definition of, 263  
facial, 268  
head, 263  
hidradenitis suppurativa, 263–264  
in drug abuse, 264  
intramammary, 268  
knife for, 98  
lip, 263  
microbiology of, 264–265  
neck, 264, 265, 267f  
nonpuerperal, 264  
nose, 263  
pelvic, 264  
perianal, 264  
periareolar, 264, 268  
perineal, 263  
pilonidal, 264, 268  
recurrent, 263–264  
sacrococcygeal, 265  
sebaceous cyst, 263, 268  
sedation for, 55b  
stitch, 30  
thigh, 263, 265

Abscess (*Continued*)

treatment of, 265–268  
antibiotics for, 268–269  
drainage in, 265–266, 266f, 267f, 268  
follow-up care in, 268

Absorbable suture materials, 102–103, 102t, 268  
vs. body region, 154t

Abuse, child, 36, 254

Acetaminophen, for burns, 258, 261

Adaptic, 279

for abrasions, 251  
for burns, 260  
for hand injury, 207  
moist environment with, 278

Additional sutures, 132, 132f

Adhesives, tissue. *See* Tissue adhesives.

Adrenaline. *See* Epinephrine.

Adson forceps, 94, 96f, 192

Advanced repair, 135–151

corner stitch, 139, 141, 141f, 142f  
of aged skin wounds, 149, 151  
of beveled wounds, 136, 138f  
of complete avulsion, 144, 146, 146f, 147f  
of dog-ear deformities, 146–147, 148f  
of geographic lacerations, 143–144, 145f  
of laceration in abrasion, 148–149, 150f  
of parallel lacerations, 147, 149f  
of partial avulsion, 141–143, 143f, 144f  
of thin-edge, thick-edge wound, 148, 150f  
pull-out subcuticular closure, 136, 138, 139f  
running suture closure, 136, 137f  
subcuticular running closure, 138–139, 140f

*Aeromonas hydrophila* infections, antibiotic  
prophylaxis for, 308–309

Aftercare

bathing in, 313–314

Aftercare (*Continued*)

- cleansing in, 313–314
- elevation in, 313
- for abscess, 268
- for animal bites, 231
- for burns, 261
- for cheek injury, 164
- for ear injury, 168–169
- for eyelid and eyebrow injury, 162
- for foot injury, 175
- for forehead injury, 160
- for hand injury, 207
- for human bites, 231
- for knee injury, 173–174
- for lip injury, 170–171
- for lower leg injury, 174
- for nasal injury, 165
- for oral injury, 171
- for pediatric patients, 45
- for perineal injury, 173
- for scalp injury, 158
- for stapling, 220–221
- for taping, 214
- for tissue adhesive application, 212–213
- for ulcer, 274–275
- healing process understanding in, 314–315
- infection monitoring in, 314
- instructions for, 313–314, 315f
- protection in, 313
- suture removal in, 45, 311–312, 312f, 312t
- written instructions for, 314, 315f

## Aging skin

- avulsion injury of, 149, 151
- changes of, 18
- Dermabond use in, 210
- healing of, 29–30
- lower leg injury in, 174

## Alcohol use, burns with, 254

## Allergy

- to anesthetics, 52
- to tetanus toxoid, 306

## Aloe vera, for burn cleansing, 258

## Alternative wound closure

- stapling. *See* Stapling.
- taping. *See* Taping.
- tissue adhesives, 209–213, 211f, 212f

## Amoxicillin, for septal hematoma, 165

## Amoxicillin/clavulanate, for ulcer, 275

## Ampicillin/clavulanate

- for cat bites, 230
- for dog bites, 229
- for rat bites, 231

## Ampicillin/sulbactam

- for cat bites, 230
- for deep infections, 271, 272
- for dog bites, 228–229
- for human bites, 231

## Amputation

- antibiotics for, 116
- finger, 203
- fingertip, 44

Amputation (*Continued*)

- for pressure injection injury, 206
- scalp, 157

## Anaerobic infections

- abscess, 265
- of Bartholin's gland, 264
- of dog bites, 229

## Analgesia, 258, 313

Anatomy. *See* specific sites.Anesthesia and anesthetics. *See also* specific anesthetics.

- allergy to, 52
- auricular block, 64, 66, 68f
- buffering of, 56–57
- differential blockade with, 50–51
- digital nerve blocks, 50, 68–69, 69f–75f, 72
- direct wound infiltration in, 58–59, 60f
- duration of, 50
- epinephrine with, 51
- finger blocks, 68–69, 69f–74f, 72
- for abrasion cleansing, 250–251
- for abscess drainage, 265–266
- for cleansing, 86–87, 89
- for ear injury, 166
- for eyebrow and eyelid injury, 161
- for fishhook removal, 247–249, 250f
- for forehead injury, 158
- for foreign body removal, 240
- for hand injury, 192
- for lip injury, 169
- for nail plate object removal, 243
- for nasal injury, 165
- for paronychia drainage, 203
- for pediatric patients, 42–43
- for plantar puncture wound, 245
- for scalp injury, 156
- for severe soft tissue injury, 9
- for tongue injury, 171
- forehead block, 60–61, 62f, 63f
- healing complications from, 29
- infraorbital nerve block, 61–62, 62f, 64f–65f
- mechanism of blockade of, 50
- median nerve block, 72, 76f
- mental nerve block, 62, 62f, 64, 67f–68f
- onset of action of, 50
- pain reduction for, 56–57
- parallel margin infiltration in, 59, 61f
- pharmacology of, 49–51
- radial nerve block, 77, 78f, 79
- sedation with, 42, 52–54, 53t, 55b
- sole of foot block, 79–80, 79f–81f
- solutions of, 54–56, 56t
- supraorbital nerve block, 60–61, 62f, 63f
- supratrochlear nerve block, 60–61, 62f, 63f
- sural nerve block, 79–80, 79f, 80f
- thumb block, 72, 73f–74f
- tibial nerve block, 79–80, 79f, 81f
- toe block, 68–69, 72, 75f
- topical, 57–58
- toxicity of, 51
- ulnar nerve block, 76–77, 77f
- warming of, 57

- Animal bites, 223–238  
 aftercare for, 231  
 bat, 231–233, 232t, 233t  
 body locations of, 224–226, 225b  
 cat. *See* Cat bites and scratches.  
 dog. *See* Dog bites.  
 epidemiology of, 223–224  
 exotic pets, 235  
 ferret, 233t  
 fish, 231  
 fox, 233t  
 human. *See* Human bites.  
 infection of, 226  
 lagomorph, 233t, 235  
 livestock, 233t, 235  
 management of, 227, 228f  
 marine animals, 223  
 microbiology of, 224  
 monkey, 223  
 rabies exposure and prophylaxis in, 231–236, 232t–234t  
 raccoon, 231–233, 232t, 233t  
 rat, 231  
 risk factors for, 224–226, 225b  
 rodent, 223, 233, 233t, 235  
 skunk, 232, 233, 233t  
 wound types in, 226
- Ankle injury  
 dressings for, 296, 302f–303f  
 ulcer, 273
- Ankle-brachial index, in arterial insufficiency, 274
- Antibiotics. *See also specific antibiotics.*  
 for abrasions, 251  
 for abscess, 268–269  
 for cat bites, 230  
 for deep infections, 271  
 for delayed closure, 108  
 for dog bites, 227–229, 229t  
 for early infections, 272, 273  
 for hand injury, 206–207  
 for human bites, 230–231  
 for necrotizing infections, 272  
 for plantar puncture wound, 45, 246–247  
 for septal hematoma, 165  
 for ulcer, 275  
 prophylactic, 3, 10, 117, 308–309  
   for abscess, 265  
   for burns, 262  
   for cat bites, 230  
   for dog bites, 229  
   for human bites, 213  
 under dressings, 277–279, 280
- Antihelix, 167f
- Antitragus, 167f
- Apocrine glands, abscess of, 263
- Arm injury  
 dressings for, 291, 292f–294f  
 suture removal from, 312t
- Arterial insufficiency, ulcers in, 273–274
- Arthrocentesis, in knee injury evaluation, 173
- Articaine, 56
- Asphalt, in abrasions, 251
- Aspiration, of abscess, 265
- Aspirin, for burns, 258, 261
- Assessment. *See* Evaluation.
- Auricular block, 64, 66, 68f
- Auricular injury. *See* Ear injury.
- Avulsion injury, 21, 21f  
 complete, 145–146, 146f, 147f  
 dental, 172  
 fingertip, 44  
 forehead, 159  
 lower leg, 174  
 nail, 198–200, 200f  
 partial, 141–144, 143f–147f, 146  
 scalp, 157
- Axilla, abscess of, 263
- Azithromycin  
 for abscess, 265  
 for hand injury, 207  
 prophylactic, 309
- B**
- Bacillus subtilis* infections, in rat bites, 231
- Bacitracin ointment, for burns, 259
- Back injury, suture removal from, 312t
- Bacteremia, in abscess drainage, 265
- Bacteria, contaminating, 28–29
- Bacteroides* infections  
 abscess, 265  
 of animal bites, 224
- Bandage. *See also* Dressings.  
 elastic, for hemostasis, 111
- Band-Aids, 278, 279
- Barb cover technique, for fishhook removal, 248, 249f
- Barbed hooks, removal of, 247–250, 248f, 249f
- Bard/Parker–style knife handle, 98, 101f
- Bartholin’s gland abscess, 264, 268
- Basal layer (stratum germinativum), 13–14, 14f
- Basic repair, 119–134  
 closure sequence and style in, 133–134, 133f  
 dead space elimination in, 133, 133f  
 knot-tying in, 120, 121f–124f  
 layer matching in, 120, 125f  
 terminology of, 119–120  
 wound edge eversion in, 120, 125–126, 126f–129f  
 wound tension reduction in, 126–127, 129–132, 130f–132f
- Bat bites, 231–233, 232t, 233t
- Bathing, in aftercare, 313–314
- Battle’s sign, 166
- Benzoin, for taping, 213, 280
- Beveled wounds, 136, 138f
- Bicarbonate, for anesthetic buffering, 57
- Biobrane, for burns, 261
- Bites (from teeth). *See* Animal bites; Human bites.
- Bites (of skin), in suturing, 119
- Blades, knife, 100, 101f, 266, 266f, 267f
- Bleeding  
 control of, 9, 110–111, 112f  
   hemostats for, 99, 101f  
   in hand injury, 178  
   in scalp, 155

Bleeding (*Continued*)  
 initial, 5, 7  
 from scalp injury, 154  
 Blisters, in burns, 255, 259  
 Blunt injury, fingertip, 193–195  
 Body surface, skin tension lines of, 16, 17f  
 Bone(s)  
 as foreign object, 240  
 fractures of. *See* Fractures.  
 infections of (osteomyelitis)  
 in plantar puncture wound, 45, 246–247  
 in ulcer, 274  
 of hand, 179f  
 Braided sutures, 102, 102t, 104, 104t  
 Breast, abscess of, 264, 268  
 Buccal mucosal injury, 171, 172f  
 Buccal nerve injury, 163, 163f  
 Buffering, anesthetic, 56–57  
 Bullets, 239–240  
 Bupivacaine, 55–56, 56t  
 allergy to, 52  
 buffering of, 57  
 duration of, 50  
 onset of action of, 50  
 shelf life of, 57  
 Burns, 253–262  
 age considerations in, 254  
 assessment of, 254–256  
 blisters in, 255, 259  
 carbon monoxide exposure in, 253  
 causes of, 254  
 depth of, 255  
 electrical, 254  
 epidermal, 255–256, 256f, 258–259  
 extent of, 255–256, 256f, 257f  
 facial, 254–255  
 foot, 255  
 full-thickness, 255, 256f, 258, 261  
 hand, 254–255, 259  
 healing of, 255  
 in pediatric patients, 254, 256, 257f, 258  
 inhalation injury with, 253  
 location of, 254–255  
 partial-thickness, 255–256, 256f,  
 259–261, 260f  
 patient assessment in, 253–254  
 perineal, 255  
 psychosocial problems with, 254  
 rule of nines for, 255–256, 256f  
 scalding, 254  
 treatment of  
 antibiotics for, 262  
 cleansing in, 259  
 débridement in, 259  
 dressings for, 259–261, 260f  
 epidermal, 258–259  
 follow-up in, 261  
 full-thickness, 261  
 home, 261  
 hospitalization guidelines for, 256–258, 258b  
 initial, 253–254  
 pain relief in, 253–254, 258–259, 313

Burns (*Continued*)  
 partial-thickness, 259–261, 260f  
 principles of, 253  
 tetanus prophylaxis in, 262  
 Buttock abscess, 263, 264, 265, 268  
 n-Butylcyanoacrylate, 209, 212

## C

Cactus spines, removal of, 244  
 Capillary refill, in arterial insufficiency, 274  
 Capitate, anatomy of, 179f  
*Capnocytophaga canimorsus* infections, 224  
 Carbocaine. *See* Mepivacaine.  
 Carbon monoxide exposure, with burns, 253  
 Carbuncles, 263  
 Cardiovascular reactions, to anesthetics, 51  
 Carpometacarpal joint, 179f, 186t  
 Cartilage injury  
 ear, 168, 168f  
 fishhook, 249  
 nasal, 165  
 Cat bites and scratches  
 animal identification after, 234–235  
 antibiotics for, 230  
 epidemiology of, 223–224  
 infection of, 226, 230  
 microbiology of, 224  
 rabies rate in, 234–235  
 suturing of, 229–230  
 wound types in, 226  
 Catheter, for abscess drainage, 266, 266f,  
 267f, 268  
 Cattle bites, 235  
 Cauliflower ear, 166, 168  
 Cautery, electric, for nail trephination, 194, 195f  
 Cefadroxil  
 for hand injury, 207  
 prophylactic, 309  
 Cefazolin  
 for abscess, 265  
 for plantar puncture wound, 247  
 for *Staphylococcus aureus* infections, 273  
 prophylactic, 117, 309  
 Cefoxitin  
 for cat bites, 230  
 for dog bites, 229  
 for human bites, 213  
 Ceftazidime, prophylactic, 309  
 Ceftriaxone  
 for cat bites, 230  
 for dog bites, 229  
 Cefuroxime, for dog bites, 229  
 Cephadrine  
 for hand injury, 207  
 prophylactic, 309  
 Cephalixin  
 for hand injury, 207  
 for *Staphylococcus aureus* infections, 273  
 for ulcer, 275  
 prophylactic, 309

- Cephalosporins  
 for abscess, 269  
 for delayed closure, 108  
 for hand injury, 201, 203, 207  
 for paronychia, 204  
 prophylactic, 117
- Cervical nerve injury, 163, 163f
- Cheek injury, 162–164  
 aftercare for, 164  
 anatomic considerations in, 162–163, 163f  
 deep or through-and-through, 164  
 preparation for closure, 163  
 uncomplicated, 163–164
- Chest injury  
 dressings for, 294, 294f  
 suture removal from, 312t
- Child abuse, 36, 254
- Child life specialists, 36
- Children. *See* Pediatric patients.
- Chipmunk bites, 235
- Chloral hydrate, for pediatric patients, 41, 41t
- Chloramphenicol, prophylactic, 309
- Chlorhexidine, 84, 84t  
 for abrasions, 250  
 for burns, 258, 259
- Chlorpromazine, 42, 53, 53t
- Chromic gut sutures, 43, 102t, 103
- Cicagraf (tape), 212
- Ciprofloxacin  
 for abscess, 269  
 for dog bites, 229  
 for plantar puncture wound, 247  
 for ulcer, 275  
 prophylactic, 117, 309
- Circular defects, 146, 146f, 147f
- Circulation  
 impairment of, antibiotic prophylaxis in, 308  
 of hand, 190, 191f
- Claudication, in arterial insufficiency, 273
- Cleansing, wound, 83–91  
 abrasions, 250–251  
 abscess, 265  
 after suture removal, 313  
 anesthesia for, 86–87, 89  
 bite, 227, 228f  
 burn, 258, 259  
 débridement in. *See* Débridement.  
 ear, 166  
 eyebrow and eyelid, 161  
 forehead, 158  
 foreign material removal in, 87  
 hair removal for, 86, 87f  
 hand, 178, 203  
 hand washing before, 85–86  
 in aftercare, 313–314  
 infected, 273  
 irrigation in, 88, 90, 90f  
 knee, 173  
 lip, 169  
 nasal, 164  
 perineal, 173  
 periphery, 88
- Cleansing, wound (*Continued*)  
 personnel precautions in, 86  
 plantar puncture, 245, 246f  
 preparation for, 85–88, 87f  
 procedure for, 88–90, 89f, 90f  
 scalp, 155–156  
 setup for, 88–90, 89f, 90f  
 soaking in, 87  
 solutions for, 83–85, 84t  
 supplies for, 89  
 technique for, 89–90, 89f, 90f  
 ulcer, 274
- Clearon (tape), 212
- Clenched-fist injury, 226
- Clindamycin  
 for abscess, 265, 269  
 for cat bites, 230  
 for deep infections, 271, 272  
 for dog bites, 229  
 for hand injury, 201, 207  
 for human bites, 213  
 for lip injury, 171  
 for paronychia, 204  
 for plantar puncture wound, 247  
 for *Staphylococcus aureus* infections, 273  
 for ulcer, 275  
 prophylactic, 117, 309
- Clostridium* infections, antibiotics for, 10, 272, 308
- Cocaine, in TAC (tetracaine-adrenaline-cocaine), 58
- Codeine, 258, 261, 313
- Collagen  
 corticosteroid effects on, 18  
 in healing, 24
- Comfort, 5, 6f
- Complete avulsions, 145–146, 146f, 147f, 157
- Complex and complicated wounds. *See also* Advanced repair;  
 Infections.  
 antibiotics for, 117  
 cheek, 164  
 deep cutaneous, 271–272  
 flap, 142, 143f  
 forehead, 159, 159f  
 lip, 170, 170f  
 necrotizing, 271–272  
 punctures as, 245–246
- Compression injuries, 21–22, 22f  
 hand, 179  
 scalp, 156f, 157
- Compression wrap, for scalp injury, 158
- Computed tomography  
 in foreign body detection, 241  
 staple problems in, 218
- Consultation, 117–118  
 for abrasions, 250  
 for animal bites, 227, 235  
 for burns, 261  
 for cheek injury, 164  
 for facial abscess, 268  
 for fishhook removal, 250  
 for foot injury, 175  
 for forehead windshield injury, 159  
 for foreign body removal, 244

- Consultation (*Continued*)  
   for hand injury, 179, 192  
     amputation, 203  
     bite, 226  
     pressure injection, 206  
     tendon, 200–201, 201f, 202f, 203  
     with nerve injury, 184, 203  
   for hidradenitis suppurativa, 264  
   for infections, 272, 273  
   for intramarginal eyelid lacerations, 161, 162f  
   for lip injury, 170  
   for nasal injury, 164–165  
   for pelvic abscess, 264  
   for plantar puncture wound, 246  
   for severe injury, 10
- Contamination  
   antibiotic prophylaxis for, 308  
   bacterial, 28–29  
   protection against, dressing for, 279
- Continuity of care, 118
- Continuous closure/sutures, 120, 136, 137f
- Contraction, in healing, 24–25
- Cooling, for burns, 253–254, 259
- Corner stitch, 139, 141f, 142, 142f
- Corpora cavernosa injury, 172–173
- Corticosteroids  
   healing affected by, 30  
   skin alterations due to, 18
- Corynebacterium* infections, of human bites, 224
- Cosmetic outcome  
   of abrasions, 249–250  
   of burns, 255  
   of cheek injury, 163–164  
   of dog bites, 227  
   of ear injury, 166–168  
   of eyebrow and eyelid injuries, 160–162  
   of facial abscess, 268  
   of forehead injury, 158–160  
   of lip injury, 169–170  
   of scalp injury, 157  
   of stapling, 216  
   of suture removal, 311  
   of tissue adhesives, 210  
   patient expectations of, 118
- Cotton sutures, 104
- Cover-Strips, 212
- Crushing injuries, 21–22, 22f, 196
- Crutches, 313
- Curi-Strip, 212
- Cutaneous layer (epidermis), structure of, 13–15, 14f
- Cuticle (eponychium), 193, 193f  
   infection of, 203–205, 204f
- Cuticular needles, 105
- Cutting needles, 104–105, 105f
- Cyanoacrylate adhesives. *See* Tissue adhesives.
- Cyst, sebaceous, abscess of, 263, 268
- D**
- Dacron sutures, 104, 104t
- Dead space, 133, 133f
- Débridement  
   of bite wounds, 227, 228f  
   of burns, 259  
   of dermis, 14  
   of ear injury, 168  
   of fascia, 15  
   of hand injury, 192  
   of knee injury, 173  
   of plantar puncture wound, 245, 246f  
   of pressure injection, 206  
   skin tension lines and, 16–17, 16f, 17f  
   technique for, 90, 111, 113–115, 114f–116f  
   to prevent tattooing, 88
- Deep (dermal) closure, 119, 127, 129, 130f, 131  
   for dead space elimination, 133, 133f  
   for eyebrow injury, 162  
   of forehead injury, 158  
   of lip injury, 170, 170f  
   vs. suture materials, 154t
- Deep fascia, 15, 15f
- Deep foot syndrome, 246
- Deep lacerations, of cheek, 164
- Deep partial-thickness burns, 255
- Dental trauma, 172
- Depth, of burns, 255
- Dermabond (octylcyanoacrylate), 209–213  
   aftercare for, 213  
   closure technique for, 210–212, 211f, 212f  
   for abrasions, 251  
   uses of, 209–210
- Dermal closure. *See* Deep (dermal) closure.
- Dermalon (nylon) sutures, 103–104, 104t
- Dermis  
   burns of. *See* Partial-thickness (second-degree) burns.  
   closure of. *See* Deep (dermal) closure.  
   débridement of, 113, 114f  
   incision in, for fishhook removal, 247, 248f  
   parallel margin infiltration under, 59, 61f  
   scoring of, 113, 115, 115f, 116f  
   structure of, 13–15, 14f, 15f
- Developmental abilities, of pediatric patients, 36t
- Devitalized tissue  
   in flap, 142–143, 144f, 145f  
   in lip, 170  
   recognition of, 111  
   removal of. *See* Débridement.
- Dexon and Dexon Plus sutures, 102, 102t
- Diabetes mellitus  
   healing in, 30  
   infections in, 271  
   ulcers in, 273
- Diazepam, 41t, 52, 53t
- Dicloxacillin  
   for delayed closure, 108  
   for hand injury, 201  
   prophylactic, 309
- Differential blockade, 50–51
- Digital injury. *See also* Finger injury; Fingertip injury; Toe injury.  
   nerve blocks for, 50, 68–69, 69f–75f, 72  
   nerve testing in, 183–184, 185f  
   tourniquet for, 111, 112f

- Digital nerve injury, 190, 191f, 203  
 DIP (distal interphalangeal joint), 179f, 186t  
 Diphenhydramine, as anesthetic, 52  
 Diphtheria, tetanus, and pertussis vaccine, 306, 307t  
 Direct wound infiltration, 58–59, 60f  
 Discharge, from infections, 314  
 Discomfort, in infections, 314  
 Dissection scissors, 96–97, 100f  
 Distal interphalangeal joint, 179f, 186t  
 Distal phalanges, 179f, 180f  
 Documentation, of care, 11t, 12  
 Dog bites  
   animal identification after, 233–235  
   antibiotics for, 227–229, 229t  
   body location of, 225  
   epidemiology of, 223–224  
   infection of, 226, 228–229  
   microbiology of, 224  
   rabies exposure and prophylaxis for, 231–232, 232t  
   rabies rate in, 233–235  
   suturing of, 227  
 Dog-ear deformities, 146, 148f  
 Dorsal digital nerve block, 68–69, 69f–71f, 72  
 Dorsal surface, of hand, 178  
 Doxycycline  
   for rat bites, 231  
   prophylactic, 309  
 DPT, as sedative, 53, 53t  
 Drainage  
   of abscess, 265–266, 266f, 267f, 268  
   of felon, 206, 206f  
   of infections, 314  
   of paronychia, 203–205, 204f, 205f  
 Drains, surgical, 115–116  
 Dreft, for burn cleansing, 258, 259  
 Dressings, 277–304  
   abrasions, 251  
   abscess, 266, 268  
   ankle, 296, 302f–303f  
   antibacterial ointments for, 277–279  
   application of, 280, 281f–283f  
   burn, 259–261, 260f  
   changes of, 280  
   ear, 287, 287f–290f, 291  
   elbow, 296, 299f–301f  
   face, 287  
   finger, 291, 296f–299f  
   foot, 296, 302f–304f  
   for children, 279  
   for delayed wound care, 9  
   for partial immobilization, 279  
   for pediatric patients, 45  
   groin, 291, 295f  
   hand, 207, 291, 296f–299f  
   heel, 296, 302f–304f  
   hip, 291, 295f  
   home care of, 280  
   knee, 296, 299f–301f  
   mastoid, 287, 287f–290f, 291  
   materials for, 279–280, 281f–283f  
   moist environment for, 278–279, 278f  
   Dressings (*Continued*)  
   nail bed, 195, 197  
   neck, 291, 292f  
   nonadherent, porous base for, 278  
   paronychia, 204  
   principles of, 277–279, 278f  
   protective function of, 279  
   scalp, 280, 284f–286f, 287  
   shoulder, 291, 293f–294f  
   taping of, 280, 281f–283f  
   thigh, 291, 295f  
   tidiness of, 278  
   trunk, 291, 295f  
   ulcer, 274–275  
   upper arm, 291, 293f–294f  
   wet-to-dry, 274  
 Drugs. *See also* Anesthesia and anesthetics;  
   Antibiotics.  
   abuse of  
     abscess in, 264  
     burns with, 254  
     healing affected by, 30  
 Duoderm  
   for abrasions, 251  
   for burns, 261  
 Dynamic skin tension lines, 16–17
- E**
- Ear injury, 165–169, 166, 167f  
 aftercare for, 168–169  
 anatomic considerations in, 165–166, 165f  
 antibiotics for, 116  
 cartilage involvement in, 168, 168f  
 dressings for, 287, 287f–290f, 291  
 ear block for, 64, 66, 68f  
 perichondral hematoma, 168  
 preparation for repair, 166  
 suture materials for, 154t  
 suture removal from, 312t  
 uncomplicated, 166, 167f  
 Edge of wound  
   beveled, 136, 138f  
   eversion of, 120, 125–126, 126f–129f  
   revision of, 113, 114f, 115f  
*Eikenella corrodens* infections, of human bites, 224, 231  
 Elastic bandage, for hemostasis, 111  
 Elbow, dressings for, 296, 299f–301f  
 Elderly persons, burns in, 254  
 Electric cautery, for nail trephination, 194, 195f  
 Electrical burns, 254  
 Elevation, of extremities, 313  
 Ellipsing, 145–146, 146f  
   of nonviable flap, 144, 144f  
 Elmer's Glue-All, for thorn and spine removal, 244  
 Emissary vein, 155, 155f  
 Epidermis  
   burns of (first-degree), 255–256, 256f, 258–259  
   scoring of, 113, 115, 115f, 116f  
   structure of, 13–15, 14f, 15f  
 Epilock, for abrasions, 251

- Epinephrine, 50, 51  
 contraindicated in digital blocks, 68  
 for hemostasis, 110  
 in LET (lidocaine-epinephrine-tetracaine), 42  
 in TAC (tetracaine-adrenaline-cocaine), 58  
 lidocaine with, 54, 56t, 58
- Epithelialization, 24, 278–279, 278f
- Eponychium, 193, 193f  
 infection of, 203–205, 204f
- Equipment. *See* Instruments and materials.
- Erysipelothrix* infections, in fish bites, 231
- Erythromycin  
 for delayed closure, 108  
 for hand injury, 207  
 for lip injury, 171  
 prophylactic, 309
- Escherichia coli* infections, of human bites, 224
- Esmarch technique, 111
- Ethilon (nylon) sutures, 103–104, 104t
- Evaluation. *See also specific injuries.*  
 patient, 5–10, 6f–8f, 35–37  
 in burns, 253–254  
 wound, 10–12, 11t, 37  
 for foreign body, 240
- Excision, wound, 113–115, 114f–116f
- Exotic pets, bites by, 235
- Expectations, for wound care outcome, 2, 118
- Exploration, wound, 109–110, 110f  
 hand, 192  
 in infections, 273  
 puncture, 245, 246f  
 tendon, 187, 188f
- Extensor tendon injury  
 functional evaluation of, 185, 186t, 187, 187f, 188f  
 suture materials for, 154t  
 treatment of, 201, 202f, 203
- Extramarginal eyelid laceration, 161, 161f
- Extremity injuries, 174, 174f. *See also* Arm injury;  
 Leg injury.  
 elevation of, 313  
 suture materials for, 154t  
 ulcers, 273–275
- Eye, fishhook removal from, 249
- Eyebrow and eyelid injuries, 160–162, 161f, 162f  
 aftercare of, 162  
 anatomic considerations in, 160, 160f  
 cleansing of, 86, 87f  
 dressings for, 287  
 evaluation of, 160–161, 160f  
 extramarginal lid, 161, 161f  
 infraorbital nerve block for, 61–62, 62f, 64f–65f  
 intramarginal lid, 161, 162f  
 preparation for closure, 161  
 suture materials for, 154t
- F**
- Face injury. *See also* Forehead injury.  
 abscess, 268  
 animal bites, 224–225, 227  
 burns, 254–255  
 dressings for, 287
- Face injury (*Continued*)  
 human bites, 230  
 immobilization of, 38, 39f, 43–44  
 in pediatric patients, 43–44  
 skin tension lines and, 16, 16f, 158  
 suture materials for, 154t  
 suture removal from, 312t
- Facial nerve injury, 162–164, 163f
- Fainting  
 from anesthetics, 51  
 from wound cleansing, 88–89  
 in hand injury, 177
- Fang injury, 226, 227, 228f, 229–230
- Fascia, anatomy of, 14f, 15, 15f
- Fasciotomy, for pressure injection injury, 206
- Fat  
 in superficial fascia, 15, 15f  
 periorbital, extrusion of, 160–161  
 removal of, 142, 143f, 192
- Fear, in pediatric patients, 36t
- Feet. *See* Foot injury.
- Felon, 205–206, 205f, 206f
- Fentanyl, 40, 41t, 52, 53, 53t, 55b
- Ferret bites, 233t, 235
- Fibroblasts, 15, 25
- Field block (parallel margin infiltration), 59, 61f
- Figure-eight technique, for tendon repair, 201, 202f, 203
- Finger injury. *See also* Fingertip injury.  
 amputation, 203  
 antibiotics for, 206–207  
 circulation in, 190, 191f  
 digital nerve blocks for, 50, 68–69, 69f–74f, 72  
 dressings for, 291, 296f–299f  
 examination of. *See* Hand injury, examination of.  
 exploration of, 192  
 felon, 205–206, 205f, 206f  
 history of, 179–180  
 jewelry removal and, 7, 7f, 8f, 177, 178f  
 nerve, 203  
 paronychia, 203–205, 204f  
 pressure injection, 206  
 radial nerve block for, 77, 78f, 79  
 radiography in, 190, 192  
 tendon, 200–201, 201f, 202f  
 terminology of, 178–179, 179f, 180f  
 tourniquet for, 111, 112f  
 treatment of, initial, 177–178, 178f  
 ulnar nerve block for, 76–77, 77f  
 uncomplicated, 192
- Fingertip injury, 193–200  
 amputation, 44  
 anatomic considerations in, 193, 193f, 194f, 205f  
 avulsion, 44, 198, 200, 200f  
 blunt (subungual hematoma), 193–195  
 dressings for, 291, 296f–299f  
 felon, 205–206, 205f, 206f  
 in pediatric patients, 196  
 nail bed lacerations, 195–197, 196f–199f  
 nail removal for, 197–198, 199f, 200f  
 digital nerve blocks for, 50, 68–69, 69f–75f, 72, 74  
 paronychia, 204–205, 204f, 205f  
 suture removal from, 312t



- Fingertip injury (*Continued*)  
 treatment principles of, 193, 193f, 194f  
 types of, 193
- First-degree (epidermal) burns, 255–256, 256f, 258–259
- Fish bites, 231
- Fishhook removal, 247–249  
 barb cover technique for, 248, 249f  
 push-through technique for, 249, 250f  
 retrograde, 247, 248f  
 string traction method for, 247–248, 248f
- Fistulas, from foreign objects, 240
- Flap injury, 139, 142–144, 142f–144f  
 fingertip, 44  
 forehead, 159, 159f  
 gingival, 171, 172f  
 lower leg, 174  
 tongue, 171
- Flap stitch, 139, 141f, 142
- Flexor carpi radialis tendon, 72, 76f
- Flexor carpi ulnaris muscle, 181
- Flexor carpi ulnaris tendon, 75f, 77, 77f, 189f
- Flexor digitorum profundus muscle, 181
- Flexor digitorum profundus tendon, 75f, 188–189, 189f–190f
- Flexor digitorum sublimis tendon, 75f, 189–190, 189f
- Flexor digitorum superficialis muscle, 182
- Flexor digitorum superficialis tendon, 189f
- Flexor retinaculum, 72, 76f, 189f
- Flexor tendon injury  
 functional evaluation of, 186f, 188–190, 189f–191f  
 treatment of, 200–201, 201f, 203
- Fluid therapy, for necrotizing infections, 272
- Flumazenil, for pediatric patients, 41t
- Fluoroquinolones, for cat bites, 230
- Follow-up care, 12  
 for pediatric patients, 38
- Foot injury, 175. *See also* Plantar puncture wounds.  
 burn, 255  
 dressings for, 296, 302f–303f  
 in pediatric patients, 44–45  
 sural nerve block for, 79–81, 79f, 80f  
 suture materials for, 154t  
 suture removal from, 312t  
 tibial nerve block for, 79–81, 79f, 81f  
 ulcer, 273
- Forceps, 94–97, 97f–99f  
 in hand injury exploration, 192  
 in stapling, 218, 219f  
 in tape handling, 214, 215f, 216f
- Forehead injury, 158–160  
 aftercare for, 160  
 anesthesia for, 60–61, 62f, 63f, 158  
 cleansing of, 158  
 complex, 159, 159f  
 preparation for closure, 158  
 principles of, 158  
 skin tension lines and, 158  
 suture materials for, 154t  
 uncomplicated, 158  
 windshield, 159, 159f
- Foreign bodies, 239–244  
 antibiotics for, 117
- Foreign bodies (*Continued*)  
 clinical evaluation of, 240  
 consultation in, 244  
 exploration for, 109–110, 110f  
 failure to remove, 3  
 imaging of, 240–241  
 in eye, 161  
 in forehead, 158  
 in hand, 180, 192  
 in plantar puncture wound, 45, 245, 246, 246f  
 inert (nonreactive) objects, 239–240  
 knife for, 98  
 nonradiodense, 241, 243  
 organic (reactive), 240  
 protruding, 243, 244f  
 radiodense, 241, 242f, 243f  
 removal of, 87, 241, 242f–244f, 243–244  
 sutures as, 272  
 teeth and teeth fragments as, 109, 169  
 thorns and spines, 244  
 types of, 239  
 under nail plates, 243–244, 244f
- Fox bites, 233t
- Fractures  
 antibiotics for, 116  
 fingertip, 194, 195  
 hand, 190, 192  
 nasal, 164–165  
 skull, 166
- Full wound excision, 113–115, 115f, 116f
- Full-thickness (third-degree) burns, 255, 256f, 258, 261
- Furuncles, 264, 265
- Fusobacterium* infections, of animal bites, 224
- G**
- Galea aponeurotica, 154–155, 155f  
 injury of, 157
- Gas gangrene, 272
- Gauze  
 adherence of, 278  
 protective function of, 279
- Gelfoam, for hemostasis, 110
- Genital injury. *See* Perineal injury.
- Gentamicin, for deep infections, 271, 272
- Geographic lacerations, 144, 145f
- Gerbil bites, 235
- Germinal matrix, nail, 193, 193f
- Gingival lacerations, 171, 172f
- Glass  
 as foreign object, 240  
 failure to remove, 3
- Globe, fishhook removal from, 250
- Glue, for thorn and spine removal, 244
- Goat bites, 235
- Golden period, for wound closure, 107–108
- Grafting, for complete avulsions, 144, 146
- Gram stain, in necrotizing infections, 272
- Granulation, in healing, 24
- Granulocytes, in healing, 23
- Granulomas, from foreign bodies, 240

Grease gun, pressure injection injury from, 206  
 Groin, dressings for, 291, 295f  
 Groundhog bites, 235  
 Guided imagery techniques, for pediatric patients, 38–39  
 Guinea pig bites, 235  
 Gut sutures, 102t, 103

## H

### Hair

anatomy of, 154, 155f  
 removal of, 86, 87f, 156, 259  
 Hair-tie/hair-braiding technique, for scalp laceration, 43, 157  
 Hamate, anatomy of, 179f  
 Hamster bites, 235  
 Hand injury, 177–208. *See also* Finger injury; Fingertip injury.  
 aftercare for, 207  
 amputation, 203  
 anatomic considerations in, 178–179, 178f–180f,  
 200, 201f  
 antibiotics for, 206–207  
 bite, 226, 230–231  
 burn, 254–255, 259  
 circulation assessment in, 190, 191f  
 clenched-fist, 226  
 digital nerve blocks for, 50, 68–69, 69f–75f, 72  
 dominance considerations in, 280  
 dressings for, 207, 291, 296f–299f  
 elevation of, 313  
 examination of, 180–190  
   nerve testing in, 181–184, 181f–185f  
   tendon function in, 184–185, 186t, 187–190, 187f–191f  
 exploration of, 192  
 felon, 205–206, 206f  
 fingertip. *See* Fingertip injury.  
 history of, 179–180  
 human bite, 226, 230–231  
 in pediatric patients, 44  
 median nerve block for, 72–75, 76f  
 nerve, 203  
 paronychia, 203–205, 204f  
 pressure injection, 206  
 radial nerve block for, 77, 78f, 79  
 radiography in, 190, 192  
 suture removal from, 312t  
 tendon, 3, 200–201, 201f, 202f  
 terminology of, 178–179, 178f, 179f  
 treatment of, 177–178, 178f  
 ulnar nerve block for, 75, 77, 77f  
 uncomplicated, 192  
 Hand tie, 120, 123f–124f  
 Hand washing, 85–86  
 Hare bites, 233t, 235  
 Head injury. *See also* Face injury; Forehead injury;  
   Scalp injury.  
   abscess, 263  
   dressings for, 280, 284f–286f, 287  
 Healing, 314–315. *See also* Scar(s).  
 categories of, 25–27  
 dressings and, 278–279, 278f  
 factors complicating, 27–30

### Healing (*Continued*)

normal, 22–25, 23f, 25f  
 of burns, 255  
 of suture wounds, 311  
 suture marks in, 30–31  
 Heart disease, antibiotics for, 116  
 Heel, dressings for, 296, 302f–303f  
 Helix, 167f, 168  
 Hematoma  
   in dead space, 133, 133f  
   in nose injury, 164–165, 164f, 166f  
   perichondral, 166, 167f  
   subungual, 193–195  
 Hemorrhage. *See* Bleeding.  
 Hemostasis, 1, 110–111, 112f–114f  
   hand tie for, 120, 123f–124f  
   in hand injury, 178  
   in healing, 22–23  
   in scalp injury, 155–156  
   initial, 5, 7  
 Hemostat, 99, 101f  
   for abscess drainage, 266, 266f, 267f  
   for exploration, 109–110, 109f  
   for fishhook removal, 249, 249f  
   for hemostasis, 110  
   for nail removal, 198, 199f  
   hand tie at, 120, 123f–124f  
 Hepatitis B transmission  
   in bites, 224  
   precautions for, 86  
 Hepatitis C transmission  
   in bites, 224  
   precautions for, 86  
 Herpesvirus infections, of human bites, 224  
 Hexachlorophene, 84t, 85  
 Hibiclens. *See* Chlorhexidine.  
 Hidradenitis suppurativa, 263–264  
 Hip injury  
   dressings for, 291, 295f  
   pressure ulcer, 273  
 Histo-Acryl Blue (nbutylcyanoacrylate), 209, 211  
 History, medical, 10, 11t  
   in burns, 254  
   in hand injury, 179–180  
   of pediatric patients, 35  
 Home care. *See also* Aftercare.  
   of dressings, 280  
   of infections, 273  
 Honey, for burns, 261  
 Hooks  
   fish, 247–250, 248f, 249f  
   skin, 95–96, 97f–99f  
 Horizontal mattress suture, 125–126, 129f  
   for aged skin, 151  
   for parallel lacerations, 147, 149f  
   for scalp injury, 156, 156f  
   for thin-edge, thick-edge wound closure, 148, 150f  
   half-buried, for corner closure, 139, 141f, 142f  
 Horse bites, 235  
 Horseshoe paronychia, 204, 205f  
 Hospitalization, for burns, 256–258, 258b

- Human bites  
 antibiotics for, 230–231  
 body locations of, 226  
 epidemiology of, 223  
 infection of, 226, 231  
 management of, 227  
 microbiology of, 224  
 suturing of, 230  
 wound types in, 226
- Human immunodeficiency virus infection, transmission of, precautions for, 86
- Human rabies immune globulin, 236
- Hydrocodone, 313
- Hydrocolloid, for abrasions, 251
- Hydrogen peroxide, 84t, 85, 273
- Hyperbaric oxygen therapy, for deep infections, 272
- Hypertrophic scars, 31
- Hyphema, 160f, 161
- Hyponychium, 193f
- Hypothenar eminence, 180f
- I**
- Ibuprofen, for burns, 258, 261
- Imagery techniques, for pediatric patients, 38–39
- Immersion burns, 254
- Immobilization  
 dressings for, 279  
 for pain relief, 313  
 for pediatric patients, 38–39, 39f
- Immune globulin, tetanus, 306
- Immunization status  
 of pediatric patients, 37  
 tetanus prophylaxis and, 305–306
- Immunosuppression  
 antibiotics for, 116  
 rabies prophylaxis in, 236
- Implants, orthopedic, antibiotic prophylaxis in, 265, 308
- Inert (nonreactive) objects, 239–240
- Infections, 1. *See also specific organisms.*  
 deep cutaneous, 271–272  
 diagnosis of, 272  
 foreign bodies in, 240  
 healing and, 28–29  
 in dead space, 133, 133f  
 in delayed closure, 108, 109f  
 liability for, 3  
 management of, 272–273  
 necrotizing, 271–272  
 of abrasions, 250–251  
 of bite wounds, 224, 226, 228–231, 229t  
 of burns, 262  
 of hand, 207  
   felon, 205–206, 205f, 206f  
   paronychia, 203–205, 204f  
 of plantar puncture wound, 45, 245–247  
 of scalp injury, 155  
 of ulcers, 273–274  
 pain in, 313  
 signs of, 314
- Infiltration anesthesia  
 direct wound, 58–59, 60f  
 parallel margin, 59, 61f
- Inflammatory phase, of healing, 23–24
- Infraorbital nerve block, 61–62, 62f, 64f–65f
- Inhalation injury, with burns, 253
- Injuries  
 etiology of, 20t  
 mechanism of, 19–22, 20f–22f, 20t  
 severe, 9–10
- Instructions, for wound aftercare, 314, 315f
- Instruments and materials  
 forceps. *See* Forceps.  
 hemostats. *See* Hemostat.  
 knife handles and blades, 98, 101f, 266, 266f, 267f  
 needle holders, 93–94, 94f–96f  
 needles. *See* Needle(s).  
 pediatric, 43  
 scissors. *See* Scissors.  
 skin hooks, 94–96, 97f–99f  
 suture materials. *See* Suture materials.
- Interphalangeal joints, 179f, 186t
- Interrupted closure, 119, 157
- Intramammary abscess, 264
- Intramarginal eyelid laceration, 161, 162f
- Iris scissors, 99, 99f, 100f, 198, 199f
- Irregular defects, 146, 146f, 147f
- Irrigation, 88, 90, 90f  
 of abscess, 266, 266f, 267f  
 of bite wound, 227, 228f  
 of infections, 273  
 of plantar puncture wound, 245, 246f  
 of ulcer, 274
- Ischemia  
 epinephrine-induced, 51  
 healing complications from, 29  
 in tension injury, 21  
 ulcer in, 273
- Ischium, pressure ulcers of, 273
- Ivory Flakes, for burn cleansing, 258
- J**
- Jewelry removal, 7, 7f, 8f, 177, 178f
- Joints  
 burns near, 261  
 dressings for, 296, 299f–301f  
 fishhook removal from, 249  
 hand, 179f  
 sutures near, 311, 312t
- K**
- Kelly clamp, for jewelry removal, 177
- Keloids, 31
- Ketamine, 42, 54
- Kling bandage wrap, 274
- Knee injury, 173–174  
 dressings for, 296, 299f–301f  
 skinned, 250–251
- Knife handles and blades, 100, 101f, 266, 266f, 267f

Knot(s), hair, 43, 157  
 Knot-tying, 120, 121f–124f  
 Kraissl's lines, 16f, 17, 17f

## L

Labia majora and minora, injury of, 172–173  
 Lagomorph bites, 233t, 235  
 Lancing, of abscess, 265–266, 266f, 267f  
 Langer's lines (skin tension lines), 16–18, 16f, 17f  
 Lavage, 88  
 Layer matching, 120, 125f  
 Leg injury  
   lower, 174, 174f, 295, 295f  
   suture removal from, 312t  
   ulcer, 273–275  
 LET (lidocaine-epinephrine-tetracaine), for pediatric patients, 42  
 Levator palpebrae muscle, injury of, 160–161, 160f  
 Liability, for wound care dissatisfaction, 2–3  
 Lidocaine, 54, 56t  
   allergy to, 52  
   buffering of, 57  
   duration of, 50  
   epinephrine with, 54, 56t, 58  
   for differential blockade, 51  
   for digital nerve blocks, 69, 72  
   for scalp injury, 156  
   in LET (lidocaine-epinephrine-tetracaine), 42  
   onset of action of, 50  
   shelf life of, 57  
   topical, 58  
   viscous, 62, 64  
 Lip injury, 169–171  
   abscess, 263  
   aftercare for, 170–171  
   complicated, 170, 170f  
   dressings for, 287  
   exploration of, 109  
   infraorbital nerve block for, 61–62, 62f, 64f–65f  
   mental nerve block for, 62, 62f, 64, 67f–68f  
   preparation for closure, 169  
   suture materials for, 154t  
   through-and-through, 170, 170f  
   types of, 169  
   uncomplicated, 169–170, 169f  
 Livestock bites, 233t, 235  
 Local anesthetics. *See* Anesthesia and anesthetics.  
 Logistics of care, 118  
 Lunate, anatomy of, 179f  
 Lunula, 193f  
 Lymphangitis, in infections, 314  
 Lymphocytes, in healing, 23

## M

Macrophages, in healing, 24  
 Magnetic resonance imaging  
   in foreign body detection, 241  
   staple problems in, 218  
 Malpractice, 2–3  
 Mandibular nerve injury, 163, 163f  
 Marcaine. *See* Bupivacaine.

Marine animal bites, 223  
 Mastitis, postpartum, 264  
 Mastoid injury, dressings for, 287, 287f–290f, 291  
 Materials. *See* Instruments and materials.  
 Matrix, nail, 193, 193f  
 Maxon (polyglyconate sutures), 102t, 103  
 Mechanism of injury, 19–22, 20f–22f, 20t  
   compression, 21–22, 22f. *See also* Compression injuries.  
   shearing, 19, 20f, 21, 179  
   tension, 21, 21f  
 Medial palpebral ligament injury, 160–161, 160f  
 Median nerve  
   injury of, 188, 189f  
   innervation by, 186t  
   testing of, 182, 183, 183f, 185f  
 Median nerve block, 72, 76f  
 Medi-Sol, for abrasion cleaning, 251  
 Mental imagery techniques, for pediatric patients, 38–39  
 Mental nerve block, 62, 62f, 64, 67f–68f  
 Meperidine, 9, 52  
   for burns, 254  
   for pediatric patients, 42  
 Mepivacaine, 55, 56t  
   allergy to, 52  
   buffering of, 57  
   for differential blockade, 51  
   for digital nerve blocks, 69, 72  
   onset of action of, 50  
   shelf life of, 57  
 Mersilene (Dacron) sutures, 104, 104t  
 Metacarpal bones, anatomy of, 179f  
 Metacarpophalangeal joint, 179f, 186t  
 Metallic foreign objects, 239–241  
 Methylparaben, in anesthetics, allergy to, 52  
 Metzenbaum dissection scissors, 99, 99f  
 Midazolam, 40–41, 41t, 52, 53, 53t, 55b  
 Middle phalanges, anatomy of, 179f, 180f  
 Moist environment, for dressing, 278–279, 278f  
 Monitoring, in sedation, 40, 55b  
 Monkey bites, 223  
 Monocryl (poliglecaprone) sutures, 103  
 Monofilament sutures, 103–104, 104t  
*Moraxella* infections, of animal bites, 224  
 Morphine, 9  
   for burns, 254  
   for pediatric patients, 40, 41t  
 Mosquito hemostat, 97, 101f  
 Motor function, testing of, in hand injury, 181–182, 181f–183f  
 Mouse bites, 235  
 Mule bites, 235  
 Multiflap lacerations, 139, 141f  
*Mycobacterium tuberculosis* infections, of human bites, 224  
 Myofibroblasts, in remodeling, 25  
 Myonecrosis, 272

## N

Nail(s) (metal), stepping on. *See* Plantar puncture wounds.  
 Nail bed  
   anatomy of, 193, 193f  
   lacerations of, 194–198, 196f–198f  
 Nail fold, lateral, 193f

- Nail injury. *See also* Fingertip injury.  
 anatomic considerations in, 193, 193f, 194f  
 digital nerve blocks for, 50, 68–69, 69f–75f, 72, 74  
 foreign bodies under nail plate, 243–244, 244f  
 nail bed lacerations, 194–197, 196f–199f  
 nail removal for, 197–198, 199f, 200f, 204–205, 204f, 205f  
 subungual hematoma, 193–195
- Nail plate  
 anatomy of, 193, 193f  
 paronychia under, 204–205, 204f, 205f
- Nail root, 193, 193f
- Naloxone, for pediatric patients, 41t
- Neck injury  
 abscess, 264, 265, 267f  
 dressings, 291, 292f
- Necrotizing infections, 271–272
- Needle(s)  
 as foreign objects, 239  
 for abscess drainage, 265  
 for anesthetics  
 selection of, 57  
 technique for. *See also specific nerve blocks.*  
 for fishhook removal, 248, 249f  
 for suturing, 104–105, 105f  
 grasping in needle holder, 93, 94f–96f, 95
- Needle holders, 93–94, 94f–96f
- Neisseria* infections  
 of animal bites, 224  
 of Bartholin's gland, 264
- Neosporin  
 for abrasions, 251  
 for dressings, 277, 279
- Neovascularization, in healing, 24
- Nerve blocks  
 anesthetics for. *See Anesthesia and anesthetics.*  
 auricular, 64, 66, 68f  
 digital, 50, 68–69, 69f–75f, 72  
 finger, 68–69, 69f–74f, 72, 74, 76  
 forehead, 60–61, 62f, 63f  
 infraorbital, 61–62, 62f, 64f–65f  
 median, 72, 76f  
 mental, 62, 62f, 64, 67f–68f  
 radial, 77, 78f, 79  
 sole of foot, 79–80, 79f–81f  
 supraorbital, 60–61, 62f, 63f  
 supratrochlear, 60–61, 62f, 63f  
 sural, 79–80, 79f, 80f  
 thumb, 72, 73f–74f  
 tibial, 79–80, 79f, 81f  
 toe, 68–69, 72, 75f  
 ulnar lock, 77, 77f
- Nerve injury, in hand, 203
- Nerve testing, in hand injury, 181–184  
 motor, 181–182, 181f–183f  
 sensory, 182–184, 184f, 185f
- Neurologic disorders, ulcers in, 273
- Nichi-Strip, 212
- Nitrous oxide, 41, 52–54
- No man's land, in tendon repair, 200, 201f
- Nonabsorbable suture materials, 103–104, 104t  
 vs. body region, 154t
- Nonionic surfactants, for cleansing, 85
- Nonpuerperal abscess, 264
- Nonradiodense foreign bodies, 241, 243
- Nonvital tissue. *See* Devitalized tissue.
- Nose injury, 164–165, 164f, 166f  
 abscess, 263  
 aftercare for, 165  
 anatomic considerations in, 164, 164f  
 bone involvement in, 165  
 cartilage, 165  
 dressings for, 287  
 infraorbital nerve block for, 61–62, 62f, 64f–65f  
 nostril, 165  
 preparation for closure, 164–165  
 septal hematoma in, 165, 166f  
 skin, 165  
 suture materials for, 154t
- Nostrils, injury of, 165
- Novafil (polybutester) sutures, 103–104, 138
- Nylon sutures, 103–104, 104t
- O**
- Octylcyanoacrylate, 209–213  
 aftercare for, 213  
 closure technique for, 210–212, 211f, 212f  
 for abrasions, 251  
 uses of, 209–210
- Ointments, antibiotic, under dressings, 277–279
- Opsite, for burns, 261
- Oral cavity injury, 171–172  
 aftercare for, 171  
 buccal mucosal, 171, 172f  
 dental, 172  
 gingival, 171, 172f  
 preparation for repair, 171  
 structures in, 171  
 suture materials for, 154t  
 tongue, 171
- Orbicularis oris muscle injury, 169–170, 169f, 170f
- Organic (reactive) objects, 240
- Orthopedic implants, antibiotic prophylaxis in, 265, 308
- Osteochondritis, in plantar puncture wound, 246–247
- Osteomyelitis  
 in plantar puncture wound, 45, 246–247  
 in ulcer, 274
- Over-and-under suture. *See* Running suture.
- Oxycodone, 313
- Oxygen therapy  
 for necrotizing infections, 272  
 for ulcer, 274
- P**
- Pain  
 in hand injury, 177  
 in infections, 271, 272, 313  
 in plantar puncture wound, 245, 246  
 in ulcer, 273
- Pain relief. *See also* Anesthesia and anesthetics; Sedation.  
 for abrasions, 313  
 for anesthetic administration, 56–57

- Pain relief (*Continued*)  
 for burns, 253–254, 258–259, 313  
 for severe soft tissue injury, 9–10  
 initial, 7
- Paint sprayer, pressure injection injury from, 206
- Palm, anatomy of, 179
- Palmar digital nerve block, 68–69, 69f–71f, 72
- Palmar surface, of hand, 178
- Palmaris longus tendon, 72, 75, 75f, 189f
- Paper clip  
 for foreign body localization, 241, 242f, 243f  
 for nail trephination, 194  
 for two-point discrimination test, 182–183, 184f
- Papillary dermis, 15
- Papoose boards, 38
- Parallel lacerations, 147, 149f
- Parallel margin infiltration, 59, 61f
- Paronychia, 203–205, 204f
- Parotid gland injury, 162–164, 163f
- Partial-thickness (second-degree) burns  
 description of, 255  
 in extent assessment, 255–256, 256f  
 treatment of, 259–261, 260f
- Pasteurella* infections, of animal bites, 224, 229, 230
- Patient instructions, 274, 313–315, 315f
- Pediatric patients, 35–47  
 abuse of, 36, 254  
 aftercare for, 45  
 anesthetic techniques for, 42–43  
 assessment of, 35–37  
 burns in, 254, 256, 257f, 258  
 calming techniques for, 35–37  
 closure materials for, 43  
 developmental abilities of, 36t  
 distraction of, 36  
 dressings for, 279  
 facial injury in, 43–44  
 fingertip crushing injury in, 196  
 foot injury in, 44–45  
 hand injury in, 44  
 parent interactions and, 9, 37–38  
 perineal injury in, 45  
 restraints for, 38–39, 39f  
 scalp injury in, 43  
 sedation for, 39–42, 41t  
 straddle injury in, 45  
 tetanus prophylaxis for, 305–306, 306t, 307t
- Pelvic abscess, 264
- Pencil grasp technique, 97, 98f
- Penicillin(s)  
 for cat bites, 230  
 for deep infections, 272  
 for lip injury, 171
- Penile injury, 154t, 172–173
- Penrose drain  
 for digital hemostasis, 111, 112f  
 for felon, 206
- Percutaneous (skin) closure, 119, 121f–122f  
 for cheek injury, 163–164  
 for ear injury, 167f  
 for eyelid injury, 161, 161f
- Percutaneous (skin) closure (*Continued*)  
 for forehead injury, 158  
 suture materials for, 154t
- Perianal abscess, 264
- Periareolar abscess, 264, 268
- Perichondral hematoma, 166, 167f
- Perineal injury, 172–173  
 abscess, 263  
 burn, 255  
 in pediatric patients, 45  
 suture materials for, 154t
- Periorbital tissue injury. *See* Eyebrow and eyelid injuries.
- Periosteal injury  
 from foreign objects, 240  
 of skull, 156
- Periphery wound cleansing, 88, 89f
- pH, of anesthetic solutions, buffering of, 56–57
- Phalanges, anatomy of, 179f, 180f
- pHisoHex. *See* Hexachlorophene.
- Physical restraints, for pediatric patients, 38, 39f
- Pilonidal abscess, 264, 268
- Pinprick stimulus testing, in hand injury, 182
- PIP (proximal interphalangeal joint), 179f, 186t
- Pisiform, anatomy of, 179f
- Plantar puncture wounds, 244–247  
 antibiotics for, 246–247  
 complicated, 245–246  
 complications of, 244–245  
 in pediatric patients, 45  
 simple, 245  
 tetanus prophylaxis for, 305  
 treatment of, 245–246, 246f  
 with deep foot syndrome, 246  
 with retained material, 245, 246, 246f
- Plastic needles, 105
- Plastic surgery, 118
- Pledglet technique, lower leg injury, 174, 174f
- Pliers, for fishhook removal, 247
- Poliglecaprone sutures, 103
- Poloxamer 188, 84t, 85
- Polybutester sutures, 103–104, 138
- Polydioxanone sutures, 102t, 103
- Polyglactin 910 sutures, 102t, 103  
 for eyebrow and eyelid injury, 161  
 for lip injury, 170  
 for scalp injury, 157
- Polyglycolic acid sutures, 102, 102t
- Polyglyconate sutures, 102t, 103
- Polymyxin B ointment, for burns, 259
- Polyoxyethylene sorbitan, for cleansing, 251
- Polypropylene sutures, 103, 136, 138
- Polysporin  
 for abrasions, 251  
 for burns, 259  
 for dressings, 277, 279
- Polyurethane foam, for dressing, 279
- Position  
 for evaluation and treatment, 5, 6f  
 for hand injury treatment, 177  
 for tissue adhesive application, 211  
 for wound cleansing, 88–89

- Povidone-iodine, 83–84, 84t  
 for abrasions, 250  
 for bite wounds, 227  
 for eyebrow and eyelid injury, 161
- Precautions, for blood-borne diseases, 86
- Precise Ten Shot stapler, 218
- Pregnancy, rabies prophylaxis in, 236
- Pressure injection injury, of hand, 206
- Pressure ulcers, 273–275
- Prevotella* infections, of animal bites, 224
- Primary closure (primary intention), 26f, 27, 108
- Procedures and techniques  
 abrasion cleansing, 250–251  
 abscess incision and drainage, 265–266, 266f, 267f, 268  
 aged skin wound closure, 151  
 beveled edge closure, 136, 138f  
 calming children, 35–38, 36t  
 complete avulsion closure, 146, 146f, 147f  
 corner stitch, 139, 141, 141f, 142f  
 delayed primary closure, 108  
 dog-ear closure, 147, 148f  
 dressing application, 280, 281f–283f. *See also specific body areas.*  
 excision, 113–115, 114f–116f  
 extensor tendon repair, 201, 202f, 203  
 felon drainage, 206, 206f  
 fishhook removal, 247–249, 248f, 249f  
 forceps handling, 96, 98f, 99f  
 foreign body removal, 241, 242f–244f, 243–244  
 geographic laceration closure, 143–144, 145f  
 infiltration anesthesia, 58–59, 60f, 61f  
 jewelry removal, 7, 7f, 8f, 177, 178f  
 knot-tying, 120, 121f–124f  
 laceration in abrasion closure, 149, 150f  
 nail removal, 198, 199f, 200f  
 nail trephination, 194–195, 195f  
 needle holder handling, 93, 94f–96f, 95  
 nerve blocks. *See* Nerve blocks.  
 of parallel lacerations, 147, 149f  
 paronychia drainage, 204–205, 204f, 205f  
 partial avulsion repair, 142–143, 143f, 144f  
 plantar puncture wound, 245–246, 246f  
 pull-out subcuticular closure, 138, 139f  
 running suture closure, 136, 137f  
 scissors tip control, 97, 100f  
 stapling, 217–218, 218f–221f, 220  
 subcuticular running closure, 139, 140f  
 suture removal, 311–312, 312f, 313t  
 taping, 212–215, 214f–217f  
 thin-edge, thick-edge wound closure, 148, 150f  
 tissue adhesive application, 210–212, 211f, 212f  
 tourniquet hemostasis, 111, 112f  
 wound cleansing, 88–90, 89f, 90f  
 wound edge eversion, 120, 125–126, 126f–129f  
 wound exploration, 109–110, 110f  
 wound tension reduction, 127, 129–132, 130f–132f
- Prolene (polypropylene) sutures, 103
- Promethazine, 9, 42, 53, 53t
- Prophylaxis  
 antibiotic. *See* Antibiotics, prophylactic.  
 tetanus, 262, 305–306, 306t, 307t
- Propofol, for pediatric patients, 42
- Prosthesis, prophylactic antibiotics for, 265
- Protective equipment, for blood-borne disease prevention, 86
- Proteus* infections  
 abscess, 265  
 of human bites, 224
- Protruding foreign bodies, 243, 244f
- Proximal interphalangeal joint, 179f, 186t
- Proximal phalanges, anatomy of, 179f, 180f
- Pseudomonas* infections  
 of human bites, 224  
 of plantar puncture wound, 45, 246–247
- Psychosocial problems, in burn patients, 254
- Pull-out subcuticular closure, 136, 138–139, 138f
- Pulsatile lavage, 88
- Pulse, examination of, in arterial insufficiency, 274
- Puncture wounds  
 hand, 180  
 in pressure injection, 206  
 plantar. *See* Plantar puncture wounds.  
 tetanus prophylaxis for, 305
- Pus  
 in abscess, 263, 265–266, 266f, 267f  
 in felon, 205–206, 205f, 206f  
 in infections, 272  
 in paronychia, 203–205, 204f
- Push-through technique, for fishhook removal, 249, 250f
- ## Q
- Quaternary ammonium compounds, for cleansing, 85
- ## R
- Rabbit bites, 233t, 235
- Rabies, 231–236  
 aerosolized, 235  
 animals carrying, 231–232, 232t  
 disease characteristics of, 232  
 in humans, statistics on, 232  
 incubation period of, 236  
 postexposure prophylaxis for, 232–233, 232t–233t  
 adverse reactions of, 236  
 animal identification and, 233–235  
 in immunosuppression, 236  
 in pregnancy, 236  
 in previously vaccinated victims, 234t, 236  
 recommendations for, 236  
 timing of, 235–236  
 type of exposure and, 235  
 transmission of, 235
- Raccoon bites, 231–233, 232t, 233t
- Radial artery, 190, 191f
- Radial border, of hand, 180f
- Radial nerve  
 innervation by, 186t  
 testing of, 181, 181f, 183, 185f
- Radial nerve block, 77, 78f, 79
- Radial side, of hand, 179, 180f
- Radiodense foreign bodies, 241, 242f, 243f

- Radiography  
 in foreign body detection, 240–241  
 in hand injury, 190, 192  
 in necrotizing infections, 272
- Ragged-edge lacerations, forehead, 159
- “Railroad tracks,” with sutures, 311
- Rat bites, 231
- Rectal injury, 45, 172–173
- Redness, in infections, 272, 314
- Redundant tissue flap (dog ear), 146–147, 148f
- Reflex One staple device, 218
- Remodeling, in healing, 24–25
- Removal  
 cactus spines, 244  
 devitalized tissue. *See* Débridement.  
 fat, 142, 143f, 192  
 fishhook, 247–250, 248f, 249f  
 foreign bodies, 87, 241, 242f–244f, 243–244  
 glass, 3  
 hair, 86, 87f, 156, 259  
 jewelry, 7, 7f, 8f, 177, 178f  
 nail, 198, 199f, 200f  
 sutures, 45, 272, 311–312, 312f, 313t  
 thorns, 244  
 tissue adhesives, 213
- Respiratory tract injury, with burns, 253
- Restraints, for pediatric patients, 38–39, 39f
- Resuscitation, 9, 55b
- Reticular dermis, 15
- Retractors, for exploration, 109–110, 109f
- Retrograde fishhook removal, 247, 248f
- Retromammary abscess, 264
- Reverse cutting needles, 105, 105f
- Revision, edge, 113, 114f, 115f
- Ring removal, 7, 7f, 8f, 177, 178f
- Road rash, 251
- Rodent bites, 223, 233, 233t, 235
- Rubber, as foreign object, 240
- Rule of nines, for burn extent, 255–256, 256f
- Running suture, 120, 136, 137f, 138–139, 140f  
 subcuticular, 139, 140f
- S**
- Sacrococcygeal abscess, 264, 268
- Sacrum, pressure ulcers of, 273
- Saddle joint (carpometacarpal joint), 179f
- Saline solution  
 for cleansing, 88, 89  
 for irrigation, 88
- Saliva  
 leakage of, in parotid gland injury, 162–163  
 rabies virus transmission in, 235
- Scab, on abrasions, 251
- Scalding burns, 254
- Scalp injury, 11, 154–158  
 aftercare for, 158  
 anatomic considerations in, 154–155, 155f  
 anesthesia for, 156  
 avulsion, 157  
 bleeding control in, 155–156  
 cleansing of, 155–156
- Scalp injury (*Continued*)  
 compression, with irregular margins, 156f, 157  
 dressings for, 280, 284f–286f, 287  
 exploration of, 109  
 forehead block for, 60–61, 62f, 63f  
 galeal, 157  
 hair removal from, 86, 156  
 in pediatric patients, 43  
 preparation for closure, 155–156  
 suture materials for, 154t  
 suture removal from, 312t  
 uncomplicated, 156–157
- Scaphoid, anatomy of, 179f
- Scar(s)  
 formation of, 2, 17–18, 314–315  
 hypertrophic, 31  
 keloid, 31  
 management of, 25  
 maturation of, 315  
 remodeling of, 24–25  
 revision of, 25, 315  
 skin tension lines and, 16–18, 16f, 17f  
 wound characteristics and, 28  
 wound edge eversion and, 120, 126f–127f
- Scissors, 99, 99f, 100f  
 for excision, 113, 114f  
 for nail removal, 198, 199f  
 for suture removal, 312–313, 312f
- Scratches, cat. *See* Cat bites and scratches.
- Screening examination, 10–11
- Scrotal injury, 154t, 172–173
- Scrubbing, 88–90, 89f  
 of abrasions, 250
- Sebaceous glands, abscess of, 263, 268
- Secondary closure (secondary intention), 26f, 27, 108
- Second-degree burns. *See* Partial-thickness (second-degree) burns.
- Sedation, 42, 52–54, 53t, 55b  
 for pediatric patients, 39–42, 41t  
 reversal of, 41t
- Seizures, from anesthetics, 51
- Sensorcaine. *See* Bupivacaine.
- Sensory function, testing of, in hand injury, 44, 182–184, 184f, 185f
- Septa, of fingernail, 193, 194f
- Septal hematoma, 164–165, 164f, 166f
- Severe injury, 9–10
- Shaving hair, 86, 87f, 156
- Shearing injuries, 179  
 fingertip, 197–198, 198f  
 hand, 19, 20f, 21
- Sheep bites, 235
- Shin injury, 174, 174f
- Shock, healing in, 30
- Shorthand technique, for vertical mattress suture, 125
- Shoulder, dressings for, 291, 293f–294f
- Shur-Clens, 85, 161
- Shur-Strip, 212
- Silk sutures, 104, 104t
- Silver sulfadiazine  
 for burns, 260  
 for dressings, 277



- Simple excision, 113, 114f, 115f
- Simple punctures, 245
- Skin
- abscess of. *See* Abscess.
  - aging. *See* Aging skin.
  - alterations in, 18
  - anatomy of, 13–15, 14f, 15f
  - avulsion of, 21, 21f
  - characteristics of, healing and, 29
  - cleansing of. *See* Cleansing, wound.
  - closure methods for. *See* Percutaneous (skin) closure.
  - stapling of. *See* Stapling.
  - tension lines in, 16–18, 16f, 17f
  - ulcers of, 273–275
- Skin hooks, 94–97, 96f, 97f
- Skin tapes. *See* Taping.
- Skived (beveled) wounds, 136, 138f
- Skull
- animal bites of, 225
  - fractures of, in ear injury, 166
  - periosteal injury of, 156
- Skunk bites, 232, 233, 233t
- Slings, 313
- Smoke injury, 253
- Soaking, 87
- for felon, 206
  - for hand injury, 178
  - for paronychia, 204
- Sodium influx, anesthetic effects on, 50
- Soil
- as foreign object, 240
  - healing complications from, 29
- Spines, removal of, 244
- Splash shield, 89, 90f
- Splint
- dressing as, 279
  - for tendon injury, 203
- Splinters, 240–241, 243, 244f
- Sponge
- for hemostasis, 110
  - scrubbing with, 88–90, 89f
- Squirrel bites, 235
- Standard of care, 117
- Staphylococcus aureus* infections
- abscess, 264–265
  - antibiotics for, 10, 308
  - of breast, 264
  - of dog bites, 229
  - of eponychium (paronychia), 204
  - of fingertip (felon), 205
  - of human bites, 231
  - of plantar puncture wound, 246
  - treatment of, 273
- Staphylococcus epidermidis* infections
- of plantar puncture wound, 246
  - of rat bites, 231
- Staphylococcus* infections
- of animal bites, 224
  - of plantar puncture wound, 45
- Stapling
- advantages of, 217
  - aftercare for, 220–221, 221f
- Stapling (*Continued*)
- for pediatric patients, 43
  - for scalp injury, 157
  - indications for, 218
  - staple removal after, 221, 221f
  - technique for, 218, 219f–221f, 220
- Static skin tension lines, 16–17, 111
- Stellate lacerations, 139, 141f
- Stent, for nail bed injury, 196f
- Sterile matrix, nail, 193, 193f
- Steri-Strips, 212
- Stitches. *See* Suture(s).
- Stones, as foreign objects, 240
- Straddle injuries, in pediatric patients, 45
- Stratum corneum, 14, 14f
- Stratum germinativum, 13–14, 14f, 24
- Streptococcal infections
- alpha-hemolytic, in rat bites, 231
  - antibiotic prophylaxis for, 308
  - beta-hemolytic, antibiotics for, 10
  - necrotizing, 272
  - of animal bites, 224, 229, 231
  - of dog bites, 229
  - of plantar puncture wound, 45, 246
- Streptococcus pyogenes* infections
- of eponychium (paronychia), 204
  - of fingertip (felon), 205
- String traction, for fishhook removal, 247–248, 248f
- Strips, for wound closure. *See* Taping.
- Subcutaneous layer (superficial fascia), 14f, 15, 15f, 113, 114f
- Subcuticular closure
- pull-out, 136, 138–139, 138f
  - running, 139, 140f
- Submersion test, in hand injury, 44
- Sunburn, 255
- Sunlight exposure, avoidance of, 313
- Super glues. *See* Tissue adhesives.
- Superficial abscess. *See* Abscess.
- Superficial fascia, 14f, 15, 15f
- débridement of, 113, 114f
  - exposure of, in complete avulsions, 144, 146, 146f, 147f
  - parallel margin infiltration over, 59, 61f
- Superficial partial-thickness burns, 255
- Supraorbital nerve block, 60–61, 62f, 63f
- Supratrochlear nerve block, 60–61, 62f, 63f
- Sural nerve block, 79–81, 79f, 80f
- Surgeon's knot, 120, 121f–122f
- Surgical drains, 115–116
- Suture(s)
- abscess from, 30
  - additional, 132, 132f
  - continuous, 136, 137f
  - corner (flap), 139, 141, 141f, 142f
  - deep. *See* Deep (dermal) closure.
  - duration in place, 31
  - flap, 139, 141, 141f, 142f
  - for animal bites, 227, 229–230
  - for edge eversion, 120, 125–126, 126f–129f
  - for human bites, 230
  - for pediatric patients, 43
  - for tension reduction, 126–127, 129, 130f–132f, 131–132

Suture(s) (*Continued*)

- healing complications from, 29
- horizontal mattress. *See* Horizontal mattress suture.
- marks from, 30–31
- materials for. *See* Suture materials.
- needle holders for, 93, 94f–96f, 95
- removal of, 311–312, 312f, 312t
  - in infections, 272
  - in pediatric patients, 45
- running. *See* Running suture.
- scissors for, 96–97, 100f
- tying of, 120, 121f–124f
- vertical mattress, 120, 125, 128f
- vs. staples, 215–216
- vs. tapes, 213
- vs. tissue adhesives, 210
- V-Y, 142–143, 144f

## Suture materials, 100–104

- absorbable, 102–103, 102t, 154t
- for cheek injury, 163–164
- for ear injury, 166, 167f, 168
- for eyebrow and eyelid injury, 161–162
- for foot injury, 175
- for hand injury, 192
- for knee injury, 173
- for lip injury, 169–170, 169f, 170f
- for lower leg injury, 174, 174f
- for nail bed laceration, 195, 196f, 198
- for nasal injury, 165
- for oral injury, 171
- for perineal injury, 173
- for ring removal from finger, 177, 178f
- for scalp injury, 156–157
- for tendon repair, 201, 202f, 203
- nonabsorbable, 103–104, 104t, 154t
- vs. body region, 153, 154t

## Suture-Strip, 212

## Swine bites, 235

## Syncope

- from anesthetics, 51
- in hand injury, 177
- in wound cleansing, 88–89

## Synovitis, from foreign bodies, 240

## Syringe, for irrigation, 88, 89

**T**

## TAC (tetracaine-adrenaline-cocaine), 58

## Tapered needles, 104–105, 105f

## Taping, 212–215, 214f–217f

- aftercare, 216
- after tissue adhesive failure, 213
- for aged skin, 151
- for lower leg injury, 174
- for parallel lacerations, 147, 149f
- for pediatric patients, 43
- of dressing, 280, 282f, 283f
- removal of, 311

## Tar, in abrasions, 250

## Tattooing, 88, 240, 249–251

## Tear duct apparatus, injury of, 160, 160f

Techniques. *See* Procedures and techniques.

## Teeth

- bite wounds from. *See* Animal bites; Human bites.
- broken or missing, 109, 169, 171–172, 172f, 240
- trauma to, 171–172, 172f

## Tegaderm, for abrasions, 251

## Telfa, 279

- for abrasions, 251
- moist environment with, 278

## Temporal nerve injury, 163, 163f

## Tendon injury, 3

- anatomic considerations in, 200, 201f
- exploration of, 109–110, 110f
- functional evaluation of, 184–190, 186t, 187f–191f
- skin wound-tendon wound mismatch in, 187, 188f
- treatment of, 200–201, 201f, 202f, 203

## Tensile strength, during healing, 315

## Tension

- healing complications from, 29
- in wound closure, 2, 126–127, 129, 130f–132f, 131–132

## Tension injuries, 21, 21f

## Tension lines, skin, 16–18, 16f, 17f

## Tertiary (delayed primary) closure, 26f, 27, 108, 109f

## Testicular injury, 172–173

## Tetanus prophylaxis, 305–306

- complications of, 306
- for burns, 262
- schedules for, 305–306, 306t, 307t

## Tetracaine

- allergy to, 52
- in LET (lidocaine-epinephrine-tetracaine), 42
- in TAC (tetracaine-adrenaline-cocaine), 58

## Thenar eminence, 180f

## Thigh injury

- abscess, 263
- dressings for, 291, 295f
- Third-degree (full-thickness) burns, 255, 256f, 258, 261

## Thorns, removal of, 240, 244

## Thrombosis, venous, ulcer in, 274

## Through-and-through lacerations

- cheek, 164
- lip, 170, 170f

## Throw, in knot-tying, 119

## Thumb

- anatomy of, 179f, 180f
- digital nerve block for, 72, 73f–74f
- functional components of, 186t
- innervation of, 182, 183, 183f, 185f
- median nerve block for, 74–75, 76f
- radial nerve block for, 77, 78f, 79

## Tibial nerve block, 79–81, 79f, 81f

## Ticarcillin/clavulanate, for deep infections, 271, 272

## Timing, of wound closure, 25, 26f, 27, 101–108, 109f

## Tissue adhesives, 209–213

- advantages of, 210
- aftercare for, 212–213
- complications of, 210
- for abrasions, 251
- indications for, 210
- materials for, 209–210
- removal of, 213

Tissue adhesives (*Continued*)  
 runoff from, 213  
 technique for, 210–212, 211f, 212f

Tissue defects, forehead, 159

Tissue preservation, 2, 159

TLE (topical lidocaine-epinephrine), 58

Toe injury  
 toe blocks for, 68–69, 72, 75f  
 web space, 175

Tongue injury, 171

Tooth. *See* Teeth.

Topical anesthesia, 57–58

Touch testing, in hand injury, 182

Tourni-Cot, 111, 112f

Tourniquet, 9–10  
 dressing as, 280, 283f  
 for hemostasis, 110–111, 112f–113f

Toxic streptococcal syndrome, 272

Toxicity, of anesthetics, 51

Tragus, 167f

Trapdoor phenomenon, in forehead injury, 159

Trapezium, anatomy of, 179f

Trapezoid, anatomy of, 179f

Trauma. *See* Injuries.

Trephination, nail, 194–195, 195f

*Treponema pallidum* infections, of human bites, 224

Triangle flap, conversion to ellipse, 145

Trimethoprim-sulfamethoxazole  
 for cat bites, 230  
 for dog bites, 229  
 for human bites, 213  
 for septal hematoma, 165  
 prophylactic, 309

Triquetrum, anatomy of, 179f

Trunk injury  
 dressings for, 291, 295f  
 suture materials for, 154t

Tube gauze finger bandage, 291, 291f

Tunica albuginea, injury of, 172–173

Tweezers, for thorn and spine removal, 244

Two-point discrimination test, in hand injury,  
 182–184, 184f

Tympanic membrane, injury of, 166

**U**

Ulcer, skin, chronic, 273–275

Ulnar artery, 190, 191f

Ulnar border, of hand, 180f

Ulnar nerve  
 innervation by, 186t  
 testing of, 181–182, 182f, 183, 185f

Ulnar nerve block, 76–77, 77f

Ulnar side, of hand, 179, 180f

Ultrasonography  
 in abscess location, 265  
 in foreign body detection, 241

Umbilical tape, for ring removal from finger, 177, 178f

Uncomplicated lacerations  
 ear, 166, 167f  
 forehead, 158

Uncomplicated lacerations (*Continued*)  
 hand, 192  
 lip, 169–170, 169f  
 scalp, 156–157

Undermining, wound, 131–132, 131f

Uremia, healing in, 29–30

Urethral injury, 172–173

**V**

Vaccine, rabies. *See* Rabies, postexposure prophylaxis for.

Vaginal injury, 172–173  
 Bartholin's gland abscess, 264, 268  
 in pediatric patients, 45  
 suture materials for, 154t

Vascular disease, ulcer in, 273

Vaseline gauze, for abrasions, 251

Vasovagal syncope  
 from anesthetics, 51  
 from wound cleansing, 88–89  
 in hand injury, 177

Venous stasis ulcers, 273

Venous thrombosis, ulcer in, 274

Vermilion border, alignment of, 169–170, 169f, 170f

Vertical mattress suture, 120, 125, 128f

*Vibrio vulnificus* infections, antibiotic prophylaxis for, 308–309

Vicryl (Polyglactin) 910 sutures. *See* Polyglactin 910 sutures.

Vigilon, for burns, 261

Viral infections, of human bites, 224

Vitamin(s), healing affected by, 30

Volar digital nerve block, 69, 70f–71f, 72

Volar surface, of hand, 178, 180f

V-Y closure, 143, 143f, 147f

**W**

Warming, of anesthetics, 57

Web space injury, toe, 175

Webster needle holder, 93, 94f–96f, 95

Wet-to-dry dressings, for ulcer, 274

Windshield injury, forehead, 159, 159f

Wood fragments, 240–241, 243, 244f

Woodchuck bites, 235

Wound cleansing. *See* Cleansing, wound.

Wound closure  
 alternative methods for. *See* Alternative wound closure.  
 consultation on, 117–118  
 continuous, 120  
 débridement before. *See* Débridement.  
 deep. *See* Deep (dermal) closure.  
 delayed, 9, 108, 109f  
 excision before, 113–115, 114f–116f  
 exploration before, 109–110, 110f  
 goals of, 1–2  
 hemostasis before, 5, 7, 110–111, 112f  
 initial steps in, 5–10, 6f–8f  
 interrupted, 119, 157  
 layer matching in, 120, 125f  
 percutaneous. *See* Percutaneous (skin) closure.  
 sequence and style of, 133–134, 133f  
 stapling in. *See* Stapling.

Wound closure (*Continued*)

- steps of, 1–2
- taping in. *See* Taping.
- tension in, 2
- timing of, 25, 26f, 27, 101–108, 109f
- tissue adhesives for, 209–213, 211f, 212f

Wound edge. *See* Edge of wound.

Wrist

- cross section of, 75f, 189f
- flexor muscles of, 182
- flexor tendons of, 188–189, 189f
- functional components of, 186t, 187, 188f
- injury of, volar surface, 188–189, 189f
- tendon repair zones of, 201f

X

- Xeroform, 279
  - for hand injury, 207
  - moist environment with, 278
- Xylocaine. *See* Lidocaine.

Z

- Zephiran, 85
- Zeroset splash shield, 89, 90f
- Zinc deficiency, healing in, 30
- Zygomatic area injury. *See* Cheek injury.
- Zygomatic nerve injury, 163, 163f