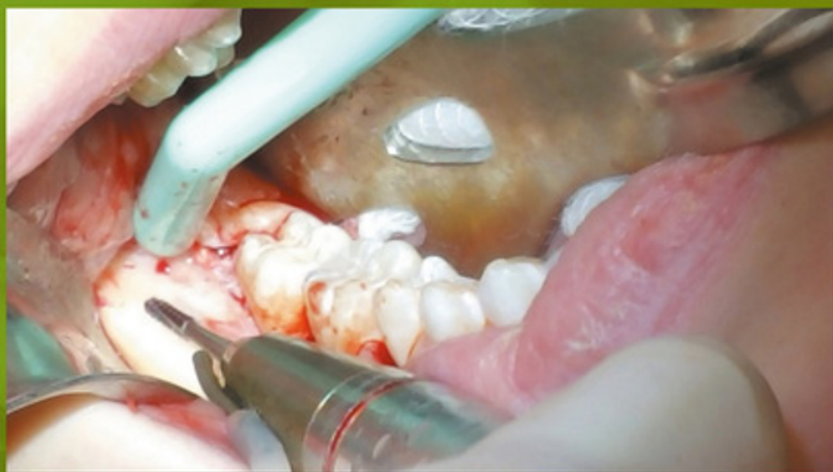

# Impacted Third Molars

John Wayland



WILEY Blackwell



## Impacted Third Molars



# Impacted Third Molars

*John Wayland*

*DDS, FAGD, MaCSD  
Wailuku*

**WILEY** Blackwell

This edition first published 2018  
© 2018 John Wiley & Sons, Inc.

All rights reserved. No part of this publication may be reproduced, stored in a retrieval system, or transmitted, in any form or by any means, electronic, mechanical, photocopying, recording or otherwise, except as permitted by law. Advice on how to obtain permission to reuse material from this title is available at <http://www.wiley.com/go/permissions>.

The right of John Wayland to be identified as the author of this work has been asserted in accordance with law.

*Registered Office*

John Wiley & Sons, Inc., 111 River Street, Hoboken, NJ 07030, USA

*Editorial Office*

111 River Street, Hoboken, NJ 07030, USA

For details of our global editorial offices, customer services, and more information about Wiley products visit us at [www.wiley.com](http://www.wiley.com).

Wiley also publishes its books in a variety of electronic formats and by print-on-demand. Some content that appears in standard print versions of this book may not be available in other formats.

*Limit of Liability/Disclaimer of Warranty*

The contents of this work are intended to further general scientific research, understanding, and discussion only and are not intended and should not be relied upon as recommending or promoting scientific method, diagnosis, or treatment by physicians for any particular patient. In view of ongoing research, equipment modifications, changes in governmental regulations, and the constant flow of information relating to the use of medicines, equipment, and devices, the reader is urged to review and evaluate the information provided in the package insert or instructions for each medicine, equipment, or device for, among other things, any changes in the instructions or indication of usage and for added warnings and precautions. While the publisher and authors have used their best efforts in preparing this work, they make no representations or warranties with respect to the accuracy or completeness of the contents of this work and specifically disclaim all warranties, including without limitation any implied warranties of merchantability or fitness for a particular purpose. No warranty may be created or extended by sales representatives, written sales materials or promotional statements for this work. The fact that an organization, website, or product is referred to in this work as a citation and/or potential source of further information does not mean that the publisher and authors endorse the information or services the organization, website, or product may provide or recommendations it may make. This work is sold with the understanding that the publisher is not engaged in rendering professional services. The advice and strategies contained herein may not be suitable for your situation. You should consult with a specialist where appropriate. Further, readers should be aware that websites listed in this work may have changed or disappeared between when this work was written and when it is read. Neither the publisher nor authors shall be liable for any loss of profit or any other commercial damages, including but not limited to special, incidental, consequential, or other damages.

*Library of Congress Cataloging-in-Publication Data*

Names: Wayland, John, author.

Title: Impacted third molars / by John Wayland.

Description: Hoboken, NJ: John Wiley & Sons, Inc., 2018. | Includes bibliographical references and index. |

Identifiers: LCCN 2017040593 (print) | LCCN 2017041147 (ebook) | ISBN 9781119118343 (pdf) | ISBN 9781119118350 (epub) | ISBN 9781119118336 (cloth)

Subjects: | MESH: Molar, Third—abnormalities | Tooth, Impacted

Classification: LCC RK521 (ebook) | LCC RK521 (print) | NLM WU 101.5 | DDC 617.6/43—dc23

LC record available at <https://lcn.loc.gov/2017040593>

Cover design: Wiley

Cover image: Courtesy of John Wayland

Set in 10/12pt Warnock by SPi Global, Pondicherry, India

*To my wife and best friend, Betty Yee.*





## Contents

**Preface** *xi*

**About the Companion Website** *xiii*

### **1 Anatomy** *1*

Nerves *1*

Blood Vessels *4*

Buccal Fat Pad *6*

Submandibular Fossa *7*

Maxillary Sinus *8*

Infratemporal Fossa *8*

References *10*

### **2 Case Selection** *13*

Medical Evaluation *13*

Radiographic Assessment *20*

Early Third Molar Removal *27*

Prophylactic Removal of Third Molars *29*

Summary *30*

References *31*

### **3 Complications** *33*

Paresthesia *33*

Alveolar Osteitis *40*

Infection *46*

Bleeding and Hemorrhage *52*

Jaw Fracture *54*

Osteomyelitis *56*

Damage to Proximal Teeth *57*

Buccal Fat Pad Exposure *57*

Oral-Antral Communication *57*

Displacement of Third Molars *58*

Aspiration and Ingestion *61*

Temporomandibular Joint Injury *62*

Complications Summary *62*

References *62*

- 4 Work Space: Equipment, Instruments, and Materials 67**
  - Equipment 68
  - Instruments 74
  - Materials 83
  - Bloodborne Pathogens Standard 93
  - References 94
  
- 5 Surgical Principles and Techniques 97**
  - Surgical Principles 97
  - Surgical Technique 108
  - Germectomy 125
  - References 126
  
- 6 Pharmacology 131**
  - Pharmacokinetics and Pharmacodynamics 131
  - Pharmacology for Third Molar Removal 134
  - Sedation 134
  - Pain Management 140
  - Inflammation 150
  - Infection 153
  - Author's Medication Regimen 156
  - References 157
  
- 7 Sedation Techniques 163**
  - Sedation as a Continuum 165
  - ADA Definitions (Verbatim) 166
  - ADA Clinical Guidelines (Verbatim) 167
  - Medical Evaluation 173
  - Routes of Administration 174
  - Inhalation (N<sub>2</sub>O) 176
  - Oral Sedation 183
  - Sublingual Administration 184
  - Intravenous Sedation 185
  - Venipuncture 188
  - References 194
  
- 8 Sedation Emergencies and Monitoring 197**
  - Patient Safety and Sedation Law 197
  - Sedation Emergencies 200
  - Monitors 207
  - References 212
  
- 9 Documentation 213**
  - Informed Consent 213
  - Progress Notes 217
  - Malpractice Cases 218
  - Summary 223
  - References 224

<b>10 The Mobile Third Molar Practice</b>	<b>225</b>
Mobile Practice Benefits	227
General Dentist or Specialist	228
Mobile Practice Promotion	229
Third Molar Procedure Manual	234
Third Molar Removal With IV Sedation	235
Introduction	235
Guidelines for Third Molar Surgery	236
Instruments/Operatory Setup	237
Instruments/Sterilization	238
Emergency Procedures	238
Medical History	241
Presurgical Instructions	242
Postsurgical Instructions	243
Progress Notes	244
Progress Notes Key	245
Sedation Record	246
Third Molar Impaction Consent	247
IV Sedation and Wisdom Teeth Briefing	248
Third Molar Research	249
Contractual Agreement for Dental Services	250
Documents	253
Scheduling Letter	253
Scheduling Protocol	254
Scheduling Tips	254
Insurance/Fees	255
Summary	257
References	257
<b>Index</b>	<b>259</b>



## Preface

Most dentists receive minimal exodontia training in dental school. All difficult extractions and surgical procedures are referred to specialty programs: OMFS, AEGD, and GPR. Exodontia courses are hard to find after dental school, especially courses for the removal of impacted third molars. Most oral surgeons are reluctant to share their third molar knowledge. Very few general dentists have the third molar experience or training to pass on to their colleagues.

The removal of third molars is one of the most common procedures in dentistry. The majority of impacted third molars are removed by oral surgeons who also do hospital procedures including orthognathic, cleft palate, TMJ, reconstructive, and other complex surgical procedures. Compared to complex oral surgery, the removal of third molars is a relatively simple procedure that can be done safely by most general practitioners.

## Why Should YOU Remove Third Molars?

The removal of impacted third molars is a predictable and profitable procedure that benefits your practice and patients. Proper case selection and surgical procedure will minimize complications and can be learned by any dentist. The author has removed more than 25,000 wisdom teeth with no significant complications (i.e., no permanent paresthesia).

Fear of the unknown is a common barrier preventing dentists from removing third molars. They often ask themselves, “Is this third molar too close to the inferior alveolar nerve? How much bleeding is normal? What should I do if there’s infection?” You probably asked similar questions with your first injection, filling, root canal, or crown. Now those procedures are routine. The removal of third molars, including impactions, will also become routine.

It’s estimated that 10 million wisdom teeth are removed in the United States every year. Imagine a dentist who refers only one third molar patient per month for the removal of four third molars. If the cost per patient averaged \$1500, including sedation, this dentist would refer \$360,000 in 20 years! Conversely, the dentist could have treated his own patients and used the \$360,000 to fund a retirement plan, pay off a mortgage, or send his or her children to college.

Your patients don’t want to be referred out of your office. They prefer to stay with a doctor and staff that they know and trust.

## Prophylactic Removal of Third Molars Controversy

There is no debate about the removal of third molars when pain or pathology is present. However, the prophylactic removal of third molars is controversial. There are many studies published to support either side of this controversy. However, the author believes common sense would support prophylactic removal.

Most patients with retained third molars will develop pathology. Third molars are difficult to keep clean. Every hygienist routinely records deep pockets near retained third molars. Caries are commonly found on third molars or the distal of second molars.

It is well documented that early removal of wisdom teeth results in fewer surgical complications. The incidence of postoperative infections and dry socket is also reduced.

## Intended Audience

This book is intended for general dentists who would like to predictably, safely, and efficiently remove impacted third molars. It can be read cover to cover or by selected areas of interest. Emphasis has been placed on practical and useful information that can be readily applied in the general dentistry office.

## About the Companion Website

Don't forget to visit the companion website for this book:

[www.wiley.com/go/wayland/molars](http://www.wiley.com/go/wayland/molars)



There you will find valuable material designed to enhance your learning, including:

- Videos clips explaining the procedures
- Figures

Scan this QR code to visit the companion website







## 1

## Anatomy

Third molar surgical complications can be minimized or eliminated with proper case selection, surgical protocol, and a thorough knowledge of oral anatomy. Removal of third molars, including impactions, can become routine. A brief review of oral anatomy related to third molars is the first step in your journey to become proficient in the safe removal of impacted third molars. The structures relevant in the safe removal of third molars are the following:

- 1) Nerves
- 2) Blood vessels
- 3) Buccal fat pad
- 4) Submandibular fossa
- 5) Maxillary sinus
- 6) Infratemporal fossa

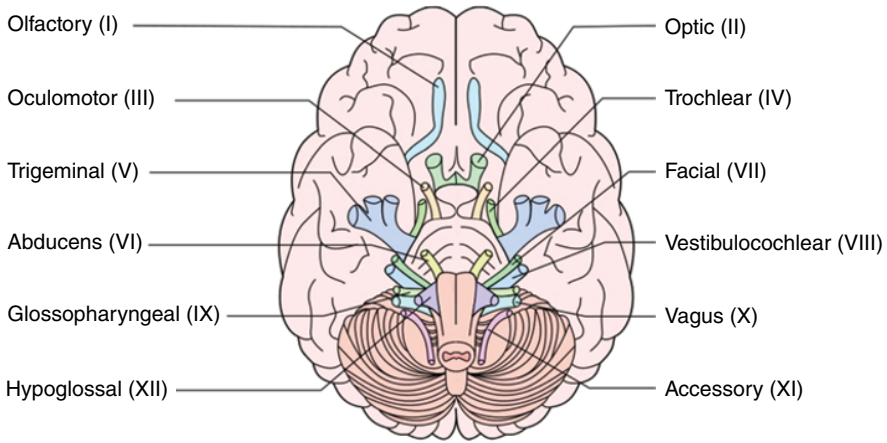
## Nerves

In classical anatomy there are 12 paired cranial nerves (I–XII) providing sensory and motor innervation to the head and neck (see Figure 1.1).

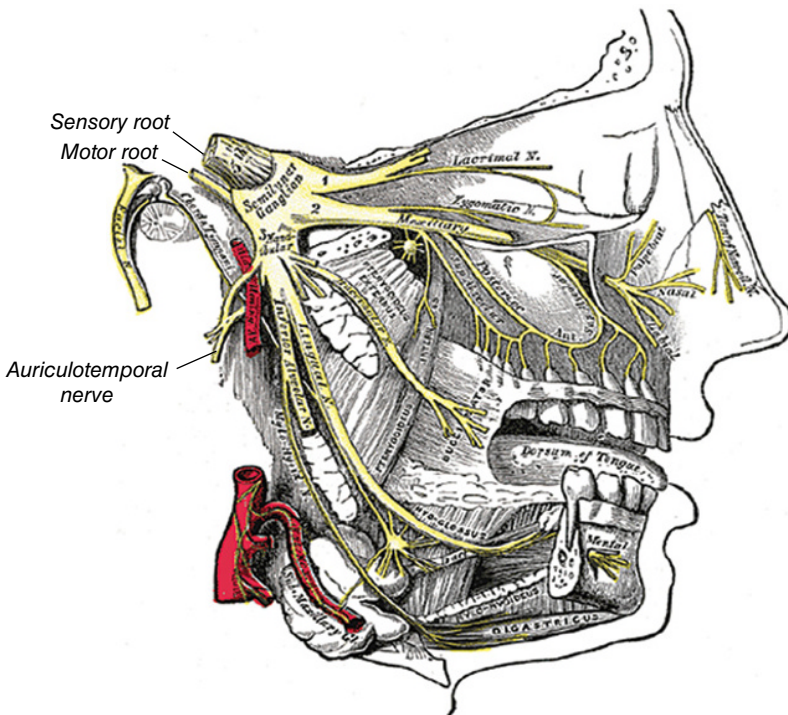
The trigeminal nerve (V), the fifth cranial nerve, is responsible for sensations of the face and motor functions of the muscles of mastication. This cranial nerve derives its name from the fact that each trigeminal nerve (one on each side of the pons) has three major branches: the ophthalmic nerve (V<sub>1</sub>), the maxillary nerve (V<sub>2</sub>), and the mandibular nerve (V<sub>3</sub>) (see Figure 1.2). The ophthalmic and maxillary nerves are purely sensory, while the mandibular nerve has sensory and motor functions (see Figure 1.3).

The mandibular nerve (V<sub>3</sub>) is the largest of the three branches or divisions of the trigeminal nerve, the fifth (V) cranial nerve. It is made up of a large sensory root and a small motor root. The mandibular nerve exits the cranium through the foramen ovale and divides into an anterior and posterior trunk in the infratemporal fossa. The mandibular nerve divides further into nine main branches, five sensory and four motor (see Figure 1.4).

The five sensory branches of the mandibular nerve control sensation to teeth, tongue, mucosa, skin, and dura.



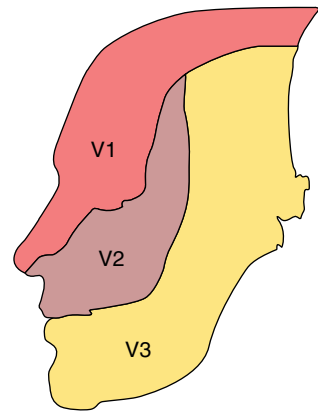
**Figure 1.1** The 12 cranial nerves emerge from the ventral side of the brain. *Source:* Courtesy of Michael Brooks.



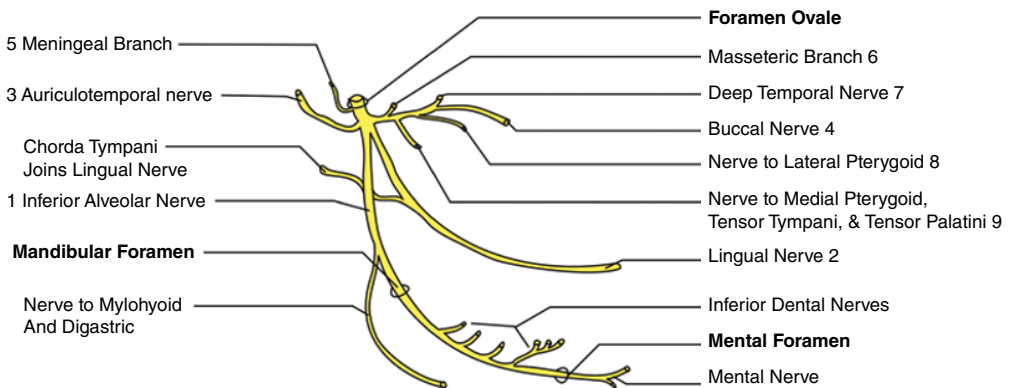
**Figure 1.2** The 5th cranial nerve and three branches of the trigeminal nerve: (1) the ophthalmic nerve, (2) the maxillary nerve, and (3) the mandibular nerve. (By Henry Vandyke Carter, via Wikimedia Common.)

- 1) Inferior alveolar—exits the mental foramen as the mental nerve and continues as the incisive nerve
  - The nerve to the mylohyoid is a motor and sensory branch of the inferior alveolar nerve.
  - Mean inferior alveolar nerve diameter is 4.7 mm.<sup>1</sup>
- 2) Lingual—lies under the lateral pterygoid muscle, medial to and in front of the inferior alveolar nerve
  - Carries the chorda tympani nerve, affecting taste and salivary flow.
  - May be round, oval, or flat and varies in size from 1.53 mm to 4.5 mm.<sup>2</sup>
  - Average diameter of the main trunk of the lingual nerve is 3.5 mm.<sup>3</sup>
- 3) Auriculotemporal—innervation to the skin on the side of the head
- 4) Buccal or long buccal—innervation to the cheek and second and third molar mucosa
- 5) Meningeal—innervation to dura mater.

The four motor branches of the mandibular nerve control the movement of eight muscles, including the four muscles of mastication: masseter, temporal, medial pterygoid, and lateral pterygoid. The other four muscles are the tensor veli palatini, tensor tympani, mylohyoid, and anterior belly of the digastric. Nerves to the tensor veli tympani and tensor veli palatini are branches of the medial pterygoid nerve. Nerves to the mylohyoid (motor and sensory) muscle and anterior belly of the digastric (motor only) muscle are branches of the inferior alveolar nerve. The nerve to the anterior belly of the digastric muscle is a motor branch of the inferior alveolar nerve.



**Figure 1.3** Sensory innervation of the three branches of the trigeminal nerve. *Source:* Madhero88, [https://commons.wikimedia.org/wiki/File:Trig\\_innervation.svg](https://commons.wikimedia.org/wiki/File:Trig_innervation.svg). CC BY 3.0.



**Figure 1.4** Mandibular nerve branches from the main trunk; anterior and posterior divisions. *Source:* Courtesy of Michael Brooks.

## **Nerve Complications Following the Removal of Impacted Third Molars**

Injury to the inferior alveolar, lingual, mylohyoid, and buccal nerves may cause altered or complete loss of sensation of the lower third of the face on the affected side.

The majority of serious nerve complications result from inferior alveolar or lingual nerve injuries. Most surgical injuries to the inferior alveolar nerve and lingual nerve cause temporary sensory change, but in some cases they can be permanent. Injury to these nerves can cause anesthesia (loss of sensation), paresthesia (abnormal sensation), hypoesthesia (reduced sensation), or dysesthesia (unpleasant abnormal sensation). Injury to the lingual nerve and associated chorda tympani nerve can also cause loss of taste of the anterior two-thirds of the tongue.

Damage to the mylohyoid nerve has been reported to be as high as 1.5% following lower third molar removal, but this is probably due to the use of lingual retraction.<sup>4</sup> Most third molars can be removed by utilizing a purely buccal technique. Utilizing this technique, it is not necessary to encroach on the lingual tissues or to remove distal or lingual bone.<sup>5</sup>

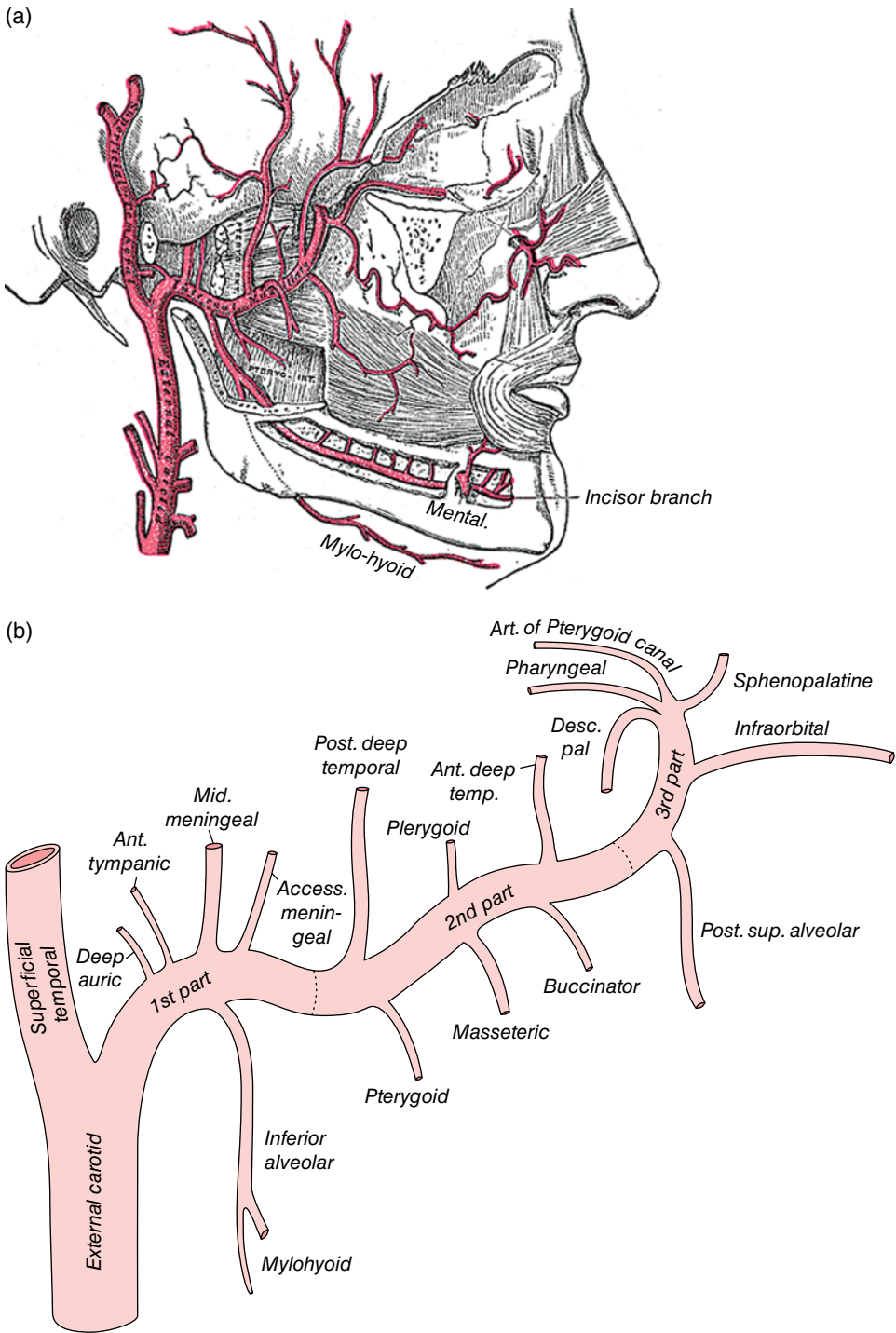
A search of the literature found no specific reports of long buccal nerve involvement (AAOMS white paper, March 2007), although one article did note long buccal involvement when the anatomical position was aberrant. In this case, the long buccal nerve was coming off the inferior alveolar nerve once it was already in the canal and coming out through a separate foramen on the buccal side of the mandible.<sup>6</sup> Long buccal nerve branches are probably frequently cut during the incision process, but the effects are generally not noted.<sup>7</sup>

## **Blood Vessels**

Life-threatening hemorrhage resulting from the surgical removal of third molars is rare. However, copious bleeding from soft tissue is relatively common. One source of bleeding during the surgical removal of third molars is the inferior alveolar artery or vein. These central vessels can be cut during sectioning of third molars, leading to profuse bleeding. The path of vessels leading to the inferior alveolar neurovascular bundle begins with the common carotid arteries and the heart.

The common carotid arteries originate close to the heart and divide to form the internal and external carotid arteries. The left and right external carotid arteries provide oxygenated blood to the areas of the head and neck outside the cranium. These arteries divide within the parotid gland into the superficial temporal artery and the maxillary artery. The maxillary artery has three portions: maxillary, pterygoid, and pterygomaxillary (see Figures 1.5a and 1.5b).

The first portion of the maxillary artery divides into five branches. The inferior alveolar artery is one of the five branches of the first part of the maxillary artery. The inferior alveolar artery joins the inferior alveolar nerve and vein to form the inferior alveolar neurovascular bundle within the mandible. Three studies confirm that the inferior alveolar vein lies superior to the nerve and that there are often multiple veins. The artery appears to be solitary and lies on the lingual side of the nerve, slightly above the horizontal position.<sup>8</sup>



**Figure 1.5** (a) The maxillary artery. (by Henry Gray, 1918, via Wikimedia Commons.) (b) Branches of the maxillary artery depicting maxillary, pterygoid, and pterygomaxillary portions. (By Henry Vandyke Carter, via Wikimedia Commons.)

Bleeding during and after third molar impaction surgery is expected. Local factors resulting from soft-tissue and vessel injury represent the most common cause of postoperative bleeding.<sup>9</sup> Systemic causes of bleeding are not common, and routine preoperative blood testing of patients, without a relevant medical history, is not recommended.<sup>10</sup>

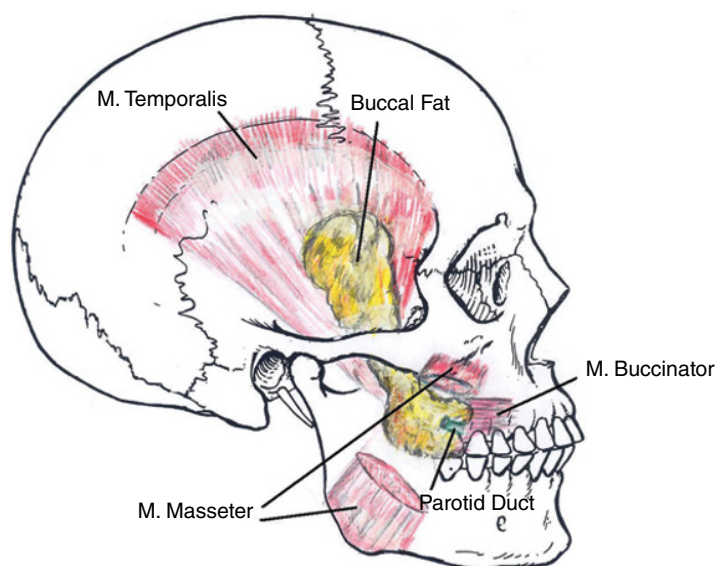
Hemorrhage from mandibular molars is more common than bleeding from maxillary molars (80% and 20%, respectively), because the floor of the mouth is highly vascular.<sup>11</sup> The distal lingual aspect of mandibular third molars is especially vascular and an accessory artery in this area can be cut leading to profuse bleeding.<sup>12,13</sup> The most immediate danger for a healthy patient with severe postextraction hemorrhage is airway compromise.<sup>14</sup>

Most bleeding following third molar impaction surgery can be controlled with pressure. Methods for hemostasis will be discussed further in Chapter 3.

## Buccal Fat Pad

The buccal fat pad is a structure that may be encountered when removing impacted third molars. It is most often seen when flap incisions are made too far distal to maxillary second molars. It is a deep fat pad located on either side of the face and is surrounded by the following structures (see Figure 1.6):

- Anterior—angle of the mouth
- Posterior—masseter muscle
- Medial—buccinator muscle
- Lateral—platysma muscle, subcutaneous tissue, and skin



**Figure 1.6** Buccal fat pad. Source: Otto Placik, <https://clinanat.com/mtd/833-buccal-fat-pad-of-bichat>. CC BY-SA 3.0.

- Superior—zygomaticus muscles
- Inferior—depressor anguli oris muscle and the attachment of the deep fascia to the mandible

Zhang, Yan, Wi, Wang, and Liu reviewed the anatomical structures of the buccal fat pad in 11 head specimens (i.e., 22 sides of the face). They found the following:

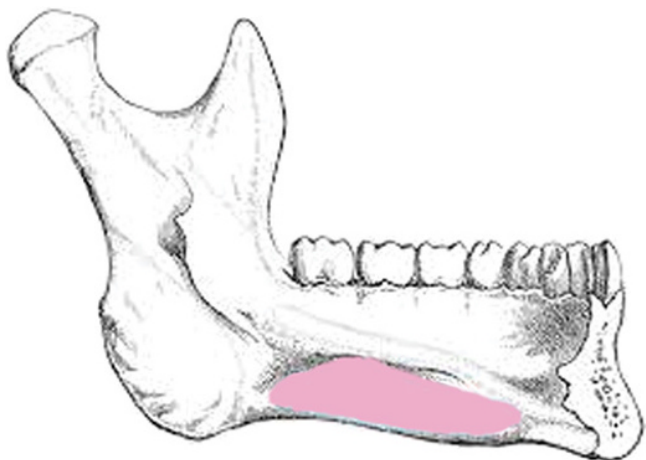
The enveloping, fixed tissues and the source of the nutritional vessels to the buccal fat pad and its relationship with surrounding structures were observed in detail. Dissections showed that the buccal fat pad can be divided into three lobes—anterior, intermediate, and posterior, according to the structure of the lobar envelopes, the formation of the ligaments, and the source of the nutritional vessels. Buccal, pterygoid, pterygopalatine, and temporal extensions are derived from the posterior lobe. The buccal fat pad is fixed by six ligaments to the maxilla, posterior zygoma, and inner and outer rim of the infraorbital fissure, temporalis tendon, or buccinator membrane. Several nutritional vessels exist in each lobe and in the subcapsular vascular plexus. The buccal fat pads function to fill the deep tissue spaces, to act as gliding pads when masticatory and mimetic muscles contract, and to cushion important structures from the extrusion of muscle contraction or outer force impulsion. The volume of the buccal fat pad may change throughout a person's life.<sup>15</sup>

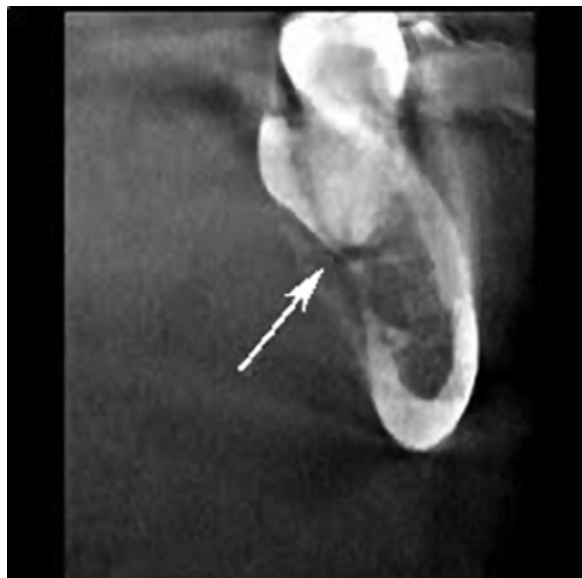
## Submandibular Fossa

The submandibular fossa is a bilateral space located medial to the body of the mandible and below the mylohyoid line (see Figure 1.7). It contains the submandibular salivary gland, which produces 65% to 70% of our saliva.

Third molar roots are often located in close proximity to the submandibular space (see Figure 1.8). The lingual cortex in this area may be thin or missing entirely. Therefore, excessive or misplaced force can dislodge root fragments or even an entire tooth into the adjacent submandibular space.<sup>16</sup>

**Figure 1.7** Submandibular fossa. *Source:* Adapted from Henry Vandyke Carter, via Wikimedia Commons.





**Figure 1.8** Third molar roots near submandibular fossa. *Source:* Reproduced by permission of Dr. Jason J. Hales, DDS.

Patients presenting with partially impacted third molars can develop pericoronitis. This localized infection can spread to the submandibular, sublingual, and submental spaces. Bilateral infection of these spaces is known as Ludwig's Angina.<sup>17</sup> Prior to the advent of antibiotics, this infection was often fatal due to concomitant swelling and compromised airway.

## Maxillary Sinus

The maxillary sinus is a bilateral empty space located within the maxilla, above the maxillary posterior teeth. It is pyramidal in shape and consists of an apex, base, and four walls (see Figure 1.9 and Box 1.1).

The size and shape of the maxillary sinus vary widely among individuals and within the same individual. The average volume of a sinus is about 15 ml (range between 4.5 and 35.2 ml).<sup>18</sup>

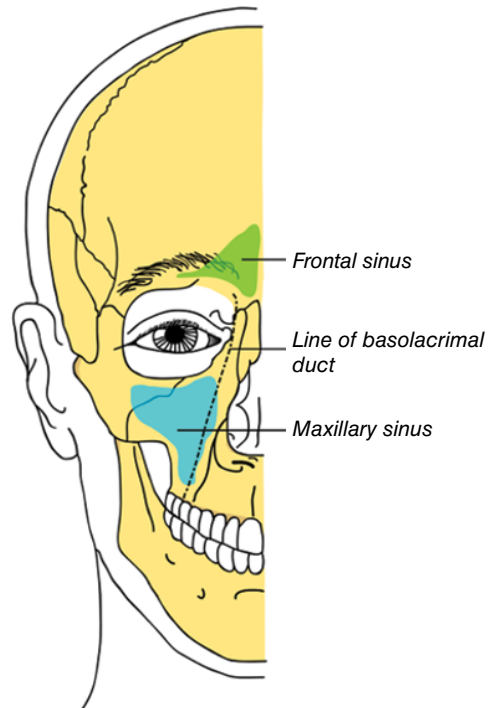
Maxillary third molar teeth and roots are often in close proximity to the maxillary sinus. The distance between the root apices of the maxillary posterior teeth and the sinus is sometimes less than 1 mm.<sup>19</sup> Complications related to the removal of maxillary third molars include sinus openings, displacement of roots or teeth into the sinus, and postoperative sinus infections.

## Infratemporal Fossa

The infratemporal fossa is an irregularly shaped space located inferior to the zygomatic arch and posterior to the maxilla. Six structures form its boundaries (see Figure 1.10 and Box 1.2).



**Figure 1.9** Maxillary sinus coronal view. (By Henry Vandyke Carter, via Wikimedia Commons)



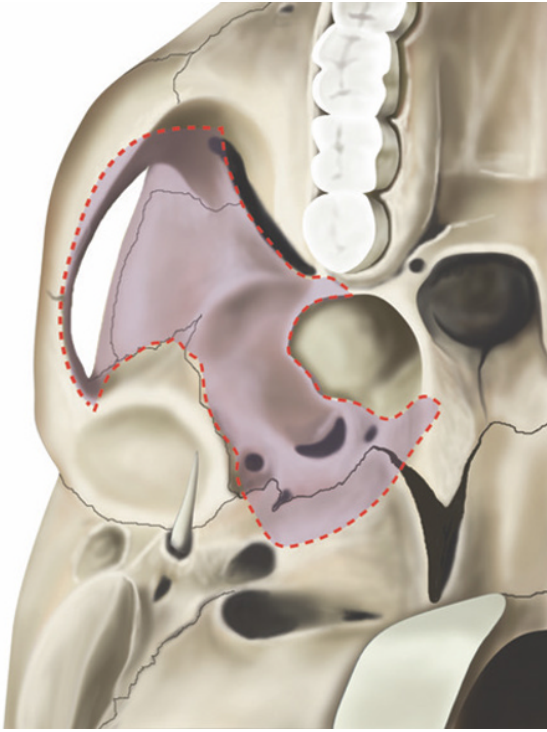
**Box 1.1 Boundaries of the maxillary sinus.**

Apex – pointing towards the zygomatic process  
 Anterior wall – facial surface of the maxilla  
 Posterior wall – infratemporal surface of the maxilla  
 Superior – floor of the orbit  
 Inferior – alveolar process of the maxilla  
 Base – cartilagenous lateral wall of the nasal cavity

Although rare, there are documented cases of maxillary third molars displaced into the infratemporal fossa. This complication is most likely to occur during the early removal of deeply impacted third molars positioned near the palate.

Unlike the maxillary sinus, the infratemporal fossa is not an empty space. It contains many vital structures, including nerves, arteries, and veins. A third molar displaced into the infratemporal fossa is considered a major complication. Dentists removing impacted maxillary third molars should understand the anatomy of the infratemporal fossa.

This chapter is not intended to be a comprehensive review of oral anatomy but instead a review of structures relevant to third molars. This knowledge is essential to avoid surgical complications. Although no surgical procedure is without risk, most impacted third molars can be removed safely and predictably.



**Figure 1.10** Boundaries of the infratemporal fossa. *Source:* Reproduced by permission of Joanna Culley BA(hons) IMI, MMAA, RMIP.

**Box 1.2** Boundaries of the infratemporal fossa. *Source:* Reproduced by permission of Joanna Culley.

Anterior: posterior maxilla  
 Posterior: tympanic plate and temporal bone  
 Medial: lateral pterygoid plate  
 Lateral: ramus of the mandible  
 Superior: greater wing of the sphenoid bone  
 Inferior: medial pterygoid muscle

An important key to avoid complications is deciding when to refer to an oral surgeon. This will be different for each dentist depending on experience and training. When to refer may be the most important factor to consider prior to treating your patients. Case selection, including surgical risk and difficulty, is discussed in the next chapter.

## References

- 1 Svane TJ, Wolford LM, Milam SB, et al. Fascicular characteristics of the human inferior alveolar nerve. *J Oral Maxillofac Surg.* 1986;44:431.
- 2 Graff-Radford SB, Evans RW. Disclosures. *Headache.* 2003;43(9).

- 3 Zur KB, Mu L, Sanders I. Distribution pattern of the human lingual nerve. *Clin Anat.* 2004 Mar;17(2):88–92.
- 4 Carmichael FA, McGowan DA. Incidence of nerve damage following third molar removal: West of Scotland Surgery Research Group study. *Brit J Oral Maxillofac Surg.* 1992;30:78.
- 5 Gargallo-Albiol J, Buenechea-Imaz R, Gay-Escoda C. Lingual nerve protection during surgical removal of lower third molars. *Int J Oral Maxillofac Surg.* 2000;29:268–71.
- 6 Singh S. Aberrant buccal nerve encountered at third molar surgery. *Oral Surg Oral Med Oral Pathol.* 1981;52:142.
- 7 Merrill RG. Prevention, treatment, and prognosis for nerve injury related to the difficult impaction. *Dent Clin North Am.* 1979;23:471.
- 8 Pogrel MA, Dorfman D, Fallah H. The anatomic structure of the inferior alveolar neurovascular bundle in the third molar region. *J Oral Maxillofac Surg.* 2009;67(11):2452–54.
- 9 Allen FJ. Postextraction hemorrhage: a study of 50 consecutive cases, *Br Dent J.* 1967;122(4):139–43.
- 10 Suchman AL, Mushlin AI. How well does activated partial thromboplastin time predict postoperative hemorrhage? *JAMA.* 1986;256(6):750–53.
- 11 Jensen S. Hemorrhage after oral surgery. An analysis of 103 cases. *Oral Surg Oral Med Oral Pathol.* 1974;37(1):2–16.
- 12 Funayama M, Kumagai T, Saito K, Watanabe T. Asphyxial death caused by post extraction hematoma. *Am J Forensic Med Pathol.* 1994;15(1):87–90.
- 13 Goldstein BH. Acute dissecting hematoma: a complication of an oral and maxillofacial surgery. *J Oral Surg.* 1981;39(1):40–43.
- 14 Moghadam HG, Caminiti MF. Life-threatening hemorrhage after extraction of third molars: case report and management protocol. *J Can Dent Assoc.* 2002;68(11):670–75.
- 15 Zhang HM, Yan YP, Qi KM, Wang JQ, Liu ZF. Anatomical structure of the buccal fat pad and its clinical adaptations. *Plastic and Reconstructive Surgery.* 2002;109(7):2509–18; discussion 2519–20.
- 16 Aznar-Arasa L, Figueiredo R, Gay-Escoda C. Iatrogenic displacement of lower third molar roots into the sublingual space: report of 6 cases. *Int J Oral Maxillofac Surg.* 2012;70:e107–e115.
- 17 Vijayan A et al. Ludwigs angina: report of a case with extensive discussion on its management. *URJD.* 2015;5(2):82–6.
- 18 Kim JH. A review of the maxillary sinus. *Perio Implant Advisory.* 2012 Sep.
- 19 Hargreaves KM, Cohen S, Berman LH. Cohen's pathways of the pulp, 10th ed. St. Louis: Mosby Elsevier. 2010:590, 592.



## 2

### Case Selection

The best way to avoid complications when removing impacted third molars is to select patients and surgeries that are commensurate with your level of training and experience. Will you treat medically compromised patients? Or will you only remove impacted third molars from healthy teens? Have you removed thousands of impactions? Or are you about to remove your first maxillary soft tissue impaction? This chapter will help you decide which third molar surgery patients should be referred to a maxillofacial surgeon or kept in your office. It will also help you know when you are ready to move to the next level of difficulty.

### Medical Evaluation

The medical evaluation includes a complete health history/patient interview, physical assessment, clinical exam, and psychological evaluation of the patient. The removal of impacted third molars is an invasive surgical procedure with risk of complications higher than most dental procedures. Furthermore, patients are often apprehensive and have anxiety about the procedure.

#### Health History and Patient Interview

A thorough health history and patient interview should be completed prior to treatment. The primary purpose of a patient's health history is to attempt to find out as much about each patient as possible, so that the patient can be treated safely and knowledgeably. A health history form, completed by the patient, should be reviewed before interviewing the patient. The American Dental Association's 2014 Health History form is provided as an example (see Figure 2.1).

The patient's health history can be subpoenaed in court cases, such as a malpractice suit or when disciplinary action is taken against a dental professional by a regulatory board. Medical evaluation documents can be used as legal evidence and must be thorough and comprehensive.

The patient interview is an essential part of a medical evaluation. It's not uncommon to have an unremarkable health history, only to learn during the interview that the patient has a history of health issues and medication. Good interview technique requires open-ended questions and active listening. Open-ended questions always begin with

What, How, When, or Where. These questions cannot be answered with a simple yes or no answer. Yes or no questions should be limited to the health history form.

**CAMP** is a useful mnemonic to remember key interview questions.

**Chief complaint** – What brings you to the office?

**Allergies** – What are you allergic to? What else?

**Medications** – What medications do you take? What medications have you taken previously?

**Past Medical History** – What medical problems have you had in the past and when did you have them?

### Confidential Health History

Patient Name: \_\_\_\_\_ Date of Birth: \_\_\_\_\_

**I. CIRCLE APPROPRIATE ANSWER** (Leave blank if you do not understand the question)

1. Yes / No Is your general health good?  
If NO, explain: \_\_\_\_\_
2. Yes / No Has there been a change in your health within the last year?  
If YES, explain: \_\_\_\_\_
3. Yes / No Have you gone to the hospital or emergency room or had a serious illness in the last three years?  
If YES, explain: \_\_\_\_\_
4. Yes / No Are you being treated by a physician now? If YES, explain: \_\_\_\_\_  
Date of last medical exam? \_\_\_\_\_ Reason for exam: \_\_\_\_\_
5. Yes / No Have you had problems with prior dental treatment?  
If YES, explain: \_\_\_\_\_  
Date of last dental exam: \_\_\_\_\_ Name of last treating dentist: \_\_\_\_\_
6. Yes / No Are you in pain now?  
If YES, explain: \_\_\_\_\_

**II. HAVE YOU EVER EXPERIENCED ANY OF THE FOLLOWING?** (Please circle Yes or No for each)

- |   |                                   |                                  |
|---|-----------------------------------|----------------------------------|
| Yes / No Chest pain (angina)            | Yes / No Blood in stools          | Yes / No Frequent vomiting       |
| Yes / No Fainting spells                | Yes / No Diarrhea or constipation | Yes / No Jaundice                |
| Yes / No Recent significant weight loss | Yes / No Frequent urination       | Yes / No Dry mouth               |
| Yes / No Fever                          | Yes / No Difficulty urinating     | Yes / No Excessive thirst        |
| Yes / No Night sweats                   | Yes / No Ringing in ears          | Yes / No Difficulty swallowing   |
| Yes / No Persistent cough               | Yes / No Headaches                | Yes / No Swollen ankles          |
| Yes / No Coughing up blood              | Yes / No Dizziness                | Yes / No Joint pain or stiffness |
| Yes / No Bleeding problems              | Yes / No Blurred vision           | Yes / No Shortness of breath     |
| Yes / No Blood in urine                 | Yes / No Bruise easily            | Yes / No Sinus problems          |
| Other: _____                            |                                   |                                  |

**III. HAVE YOU EVER HAD OR DO YOU HAVE ANY OF THE FOLLOWING?** (Please circle Yes or No for each)

- |  |  |                                     |
|--|--|-------------------------------------|
| Yes / No Heart disease                   | Yes / No AIDS/HIV                        | Yes / No Psychiatric care           |
| Yes / No Family history of heart disease | Yes / No Surgeries                       | Yes / No Osteoporosis               |
| Yes / No Heart attack                    | Yes / No Hospitalization                 | Yes / No Thyroid disease            |
| Yes / No Artificial joint                | Yes / No Diabetes                        | Yes / No Asthma                     |
| Yes / No Stomach problems or ulcers      | Yes / No Family history of diabetes      | Yes / No Hepatitis                  |
| Yes / No Heart defects                   | Yes / No Tumors or cancer                | Yes / No Sexual transmitted disease |
| Yes / No Heart murmurs                   | Yes / No Chemotherapy                    | Yes / No Herpes                     |
| Yes / No Rheumatic fever                 | Yes / No Radiation                       | Yes / No Canker or cold sores       |
| Yes / No Skin disease                    | Yes / No Arthritis, rheumatism           | Yes / No Anemia                     |
| Yes / No Hardening of arteries           | Yes / No Emphysema or other lung disease | Yes / No Liver disease              |
| Yes / No High blood pressure             | Yes / No Kidney or bladder disease       | Yes / No Eye disease                |
| Yes / No Seizures                        | Yes / No Stroke                          | Yes / No Transplants                |
| Yes / No Cosmetic surgery                | Yes / No Eating disorders                | Yes / No Tuberculosis               |
| Other: _____                             |  |                                     |

Figure 2.1 American Dental Association Health History. Source: Reproduced by permission of the ADA.

**IV. ARE YOU ALLERGIC TO OR HAVE YOU HAD A REACTION TO ANY OF THE FOLLOWING?**

(Please circle Yes or No for each)

Yes / No Aspirin	Yes / No Valium or other sedatives	Yes / No Codeine or other narcotics
Yes / No Penicillin or other antibiotics	Yes / No Latex	Yes / No Food
Yes / No Nitrous oxide	Yes / No Local anesthetic	Yes / No Metal

Others: \_\_\_\_\_

**V. ARE YOU TAKING OR HAVE YOU TAKEN ANY OF THE FOLLOWING IN THE LAST THREE MONTHS?**

(Please circle Yes or No for each)

Yes / No Recreational drugs	Yes / No Tobacco in any form	Yes / No Antibiotics
Yes / No Over-the-counter medicines	Yes / No Alcohol	Yes / No Supplements
Yes / No Weight loss medications	Yes / No Bisphosphonate (Fosamax)	Yes / No Aspirin
Yes / No Anti-Depressants	Yes / No Herbal Supplements	

Please list all prescription medications: \_\_\_\_\_

**VI. WOMEN ONLY** (Please circle Yes or No for each)

Yes / No Are you or could you be pregnant? If YES, what month? \_\_\_\_\_

Yes / No Are you nursing? \_\_\_\_\_

Yes / No Are you taking birth control pills? \_\_\_\_\_

**VII. ALL PATIENTS** (Please circle Yes or No for each)

Yes / No Do you have or have you had any other diseases or medical problems NOT listed on this form?  
If YES, please explain: \_\_\_\_\_

Yes / No Have you ever been pre-medicated for dental treatment? If YES, why: \_\_\_\_\_

Yes / No Have you ever taken Fen-Phen? If YES, when: \_\_\_\_\_

Yes / No **Is there any issue or condition that you would like to discuss with the dentist in private?**

*The practice of dentistry involves treating the whole person. If the dentist determines that there may be a potentially medically compromised situation, medical consultation may be needed prior to commencement of dental treatment.*

*I authorize the dentist to contact my physician.*

Patient's Signature: \_\_\_\_\_ Date: \_\_\_\_\_

Physician's Name: \_\_\_\_\_ Phone Number: \_\_\_\_\_

**Whom would you like us to contact in case of an emergency?**

**Name:** \_\_\_\_\_ **Relationship:** \_\_\_\_\_ **Phone Number:** \_\_\_\_\_

**I certify that I have read and understand this form. To the best of my knowledge, I have answered every question completely and accurately. I will inform my dentist of any change in my health and/or medication. Further, I will not hold my dentist, or any other member of his/her staff, responsible for any errors or omissions that I may have made in the completion of this form.**

\_\_\_\_\_  
Signature of Patient (Parent or Guardian)

\_\_\_\_\_  
Date

\_\_\_\_\_  
Signature of Dentist

\_\_\_\_\_  
Date

Figure 2.1 (Cont'd)

**MEDICAL UPDATES**

I have reviewed my Health History and confirm that it accurately states past and present conditions.

DATE	PATIENT SIGNATURE	CHANGES TO HEALTH HISTORY	DENTIST INITIALS
_____	_____	_____	_____
_____	_____	_____	_____
_____	_____	_____	_____
_____	_____	_____	_____
_____	_____	_____	_____
_____	_____	_____	_____

(AS 10/2014)

Figure 2.1 (Cont'd)

**Physical Assessment**

The American Society of Anesthesiologist's (ASA) physical classification system is a useful guide when deciding to refer third molar surgical patients<sup>1</sup> (see Table 2.1).

A study published in the *Journal of Public Health Dentistry* in 1993 evaluated the general health of dental patients on the basis of the physical status classification system of the American Society of Anesthesiologists. A total of 4,087 patients completed a



**Table 2.1** ASA physical status classification system.

Classification	Description
ASA 1	Normal healthy
ASA 2	Mild systemic disease
ASA 3	Severe systemic disease
ASA 4	Disease is a constant threat to life
ASA 5	Not expected to survive without operation
ASA 6	Declared brain dead patient donating organs

risk-related, patient-administered questionnaire. On the basis of their medical data, a computerized ASA classification was determined for each patient: 63.3% were in ASA Class I, 25.7% in Class II, 8.9% in Class III, and 2.1% in Class IV. Eighty-nine percent of patients in this study were ASA Class I or II.<sup>2</sup>

Another study measured the medical problems of 29,424 dental patients (aged 18 and older) from 50 dental practices in the Netherlands. This study found that the number of patients seen with hypertension, cardiovascular, neurological, endocrinological, infectious, and blood disease increased with age.<sup>3</sup>

Kaminishi states that the number of patients over age 40 requiring third molar removal is increasing. Over a five-year period, 1997–2002, the incidence almost doubled to 17.9%. This age category is known to be high risk for third molar surgery. At equal or higher risk is the rapidly growing number of patients seeking third molar surgery that are moderately or severely medically compromised.<sup>4</sup>

There are no absolute case selection recommendations based on these studies. However, most experts agree that ASA I and II patients can be treated safely in a dental office setting. Medically compromised ASA III patients are taking medications that do not adequately control their disease. The author recommends referral of medically compromised ASA III patients and the elderly. Alternatively, an anesthesiologist can sedate these patients. Fortunately, the majority of patients seen for third molar impaction surgery are relatively young, healthy ASA I and II patients.

The physical assessment begins at first contact with the patient.

- Overall appearance – What is their overall appearance? Is the patient obese, elderly, frail?
- Lifestyle – Do they use drugs or alcohol in excess? Do they have an active lifestyle?
- Vital signs – Multiple blood pressure readings are recommended.

Every patient considering the removal of impacted third molars should have their vital signs checked at the surgery consultation and on the day of surgery. Patients with hypertension are more prone to cardiovascular complications. Hypertension can be diagnosed with simple blood pressure readings. This is especially important if the patient will be sedated because a baseline recording is needed to compare with readings during the procedure. According to the U.S. Department of Health and Human Services, desired systolic pressure ranges from 90 to 119. The desired diastolic range is 60–79.<sup>5</sup> (see Table 2.2)

As of 2000, nearly one billion people, approximately 26% of the adult population of the world, had hypertension.<sup>6</sup> Forty-four percent of African American adults have hypertension.<sup>7</sup>

**Table 2.2** Classification of blood pressure for adults.

Blood Pressure Category	Systolic, mm Hg (upper number)		Diastolic, mm Hg (lower number)
Normal	Less than 120	and	Less than 80
Elevated	120–129	and	Less than 80
High blood pressure (Hypertension) stage 1	130–139	or	80–89
High blood pressure (Hypertension) stage 2	140 or higher	or	90 or higher
Hypertensive crisis (consult your doctor immediately)	Higher than 180	and/or	Higher than 120

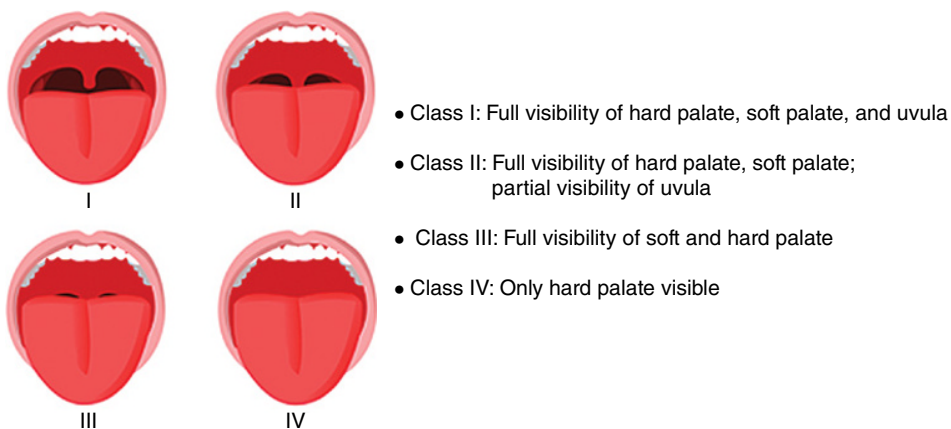
### Clinical Exam

Access is particularly important during the removal of impacted third molars. Poor access can make the procedure much more difficult. Patients with orthodontics in progress, small mouths, short anterior posterior distance, large tongues, and limited opening can make the removal of impacted third molars nearly impossible. A useful guide to evaluate access is the Mallampati airway classification (see Figure 2.2).

Class IV patients are typically patients with square faces, short necks, and large tongues. The coronoid process will move close to maxillary third molars during translation, severely limiting access. In addition, these patients may have small arch size and limited soft tissue opening. A prudent dentist would consider referring these patients to a maxillofacial surgeon.

### Psychological Evaluation

The psychological and emotional status of impacted third molar patients is an important factor in their successful treatment. Dr. Milus House has been credited with developing a system to classify the psychology of denture patients. Although this system



**Figure 2.2** Mallampati classification can be used to predict airway management and oral access. Source: Jmarchn [https://en.wikipedia.org/wiki/Mallampati\\_score#/media/File:Mallampati.svg](https://en.wikipedia.org/wiki/Mallampati_score#/media/File:Mallampati.svg). CC BY-SA 3.0.

was devised in 1937 to evaluate denture patients, it is still applicable today for third molar patients. Class I and II patients are most likely to have a positive treatment result (see Box 2.1).

In a study conducted in 2007, National Institute of Mental Health researchers examined data to determine how common personality disorders are in the United States. A total of 5,692 adults, aged 18 and older, answered screening questions from the International Personality Disorder Examination. The researchers found that the prevalence for personality disorders in the United States is 9.1%.<sup>8</sup> Nearly 10% of dental patients aged 18 and older may have some form of personality disorder!

Patients who have psychological and emotional challenges may be less compliant and unable to cope with the stress of surgical procedures (see Figure 2.3). The author recommends referral of these patients to a maxillofacial surgeon for treatment with general anesthesia.

**Box 2.1 House's emotional and psychological patient classification.**

- Class 1: Philosophical – Accepts dentist's judgment and instructions, best prognosis
- Class 2: Exacting – Methodical and demanding, asks a lot of questions, good prognosis
- Class 3: Indifferent – Doesn't care about dental treatment and gives up easily, fair prognosis
- Class 4: Critical – Emotionally unfit, never happy, worst prognosis



**Figure 2.3** Patients with severe anxiety should be treated with GA. Source: Edvard Munch, <http://www.ibiblio.org/wm/about/license.html>. CC BY-SA 3.0.

## Radiographic Assessment

A thorough evaluation of radiographs is essential to avoid surgical complications. Resolution, contrast, and clarity should not be compromised. Panoramic radiographs are ideal for viewing structural relationships. They allow for visualization of the third molar's relationship to the following structures: inferior alveolar nerve canal, maxillary sinus, ramus, and second molar. Intraoral films further delineate the third molar periodontal ligament, root structure, and position. Most third molar surgeries can be completed safely with high-quality panoramic and intraoral films.

At the time of this writing, cone beam computed tomography (CT) scans have yet to become the standard of care in outpatient oral surgery. However, a CT scan may be appropriate for patients with fully developed roots near vital structures. For example, CT imaging may be appropriate when intimate contact with the inferior alveolar nerve is suspected after reviewing panoramic films or when a third molar is located near the palate.

The following factors are important when assessing radiographs.

- 1) Position
- 2) Depth
- 3) Angulation
- 4) Combined root width
- 5) Root length, size, and shape
- 6) Periodontal ligament and follicle
- 7) Bone elasticity and density
- 8) Position relative to the inferior alveolar canal

### Position

The anterior posterior position of impacted third molars is always a significant factor. Third molars positioned in or near the ramus will have limited access. The position of mandibular third molars can be classified in relation to the second molar and ascending ramus (see Figure 2.4). Mandibular third molars are classified as Class I position when there is sufficient room for eruption between the second molar and ascending ramus. The tooth should have no tissue covering the distal aspect. Class II mandibular third molars do not have sufficient room for normal eruption. Some of the third molar is in the ramus. Mandibular third molars are Class III when the majority of the third molar is in the ramus. A Class III position, short anterior posterior distance, will severely limit access to maxillary impactions.

### Depth

The depth of mandibular third molars can be classified relative to the occlusal surface and cemento-enamel junction (CEJ) of the adjacent second molar. A mandibular third molar is Depth A when it is even with or above the occlusal surface of the second molar. It is Depth B when it is located between the occlusal surface and CEJ of the second molar. It is Depth C when it is located below the second molar CEJ. Surgical difficulty increases in direct proportion to depth for both mandibular and maxillary third molars (see Figure 2.5).

This classification system produces nine possible outcomes when position and depth are combined. IA would be considered the easiest position and depth, while IIIC would

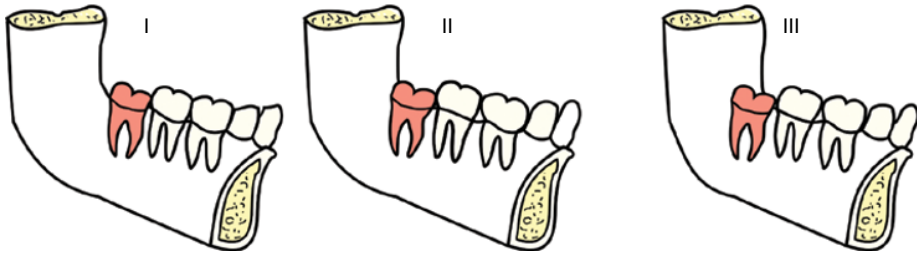### Position - 2nd Molar to Ramus

Class I - EASY - Sufficient room for third molar eruption

Class II - MODERATE - Some of the third molar is in the ramus

Class III - DIFFICULT - Most or all of the third molar is in the ramus

\* This assessment is related to AP distance.  
Class III maxillary impactions are usually more difficult due to poor access.



**Figure 2.4** Surgical difficulty based on AP distance, second molar, and ramus. *Source:* Reproduced by permission of Robert J. Whitacre.

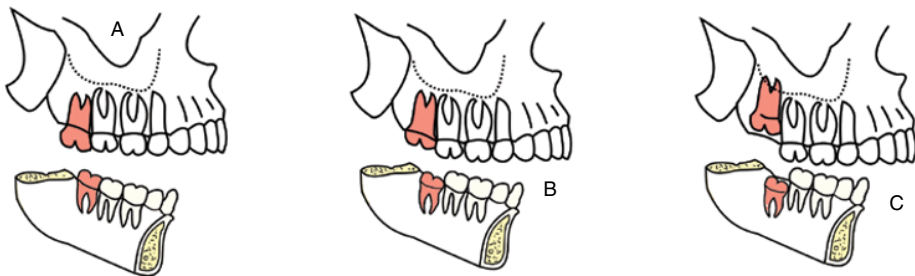
### Depth - 2nd Molar Occlusal Surface & CEJ

Class A - Easy - Third Molar is even with second molar occlusal surface

Class B - Moderate - Third molar is between second molar occlusal surface and CEJ

Class C - Difficult - Third molar is between second molar apex and CEJ

\* A deep maxillary third molar will be very difficult due to access

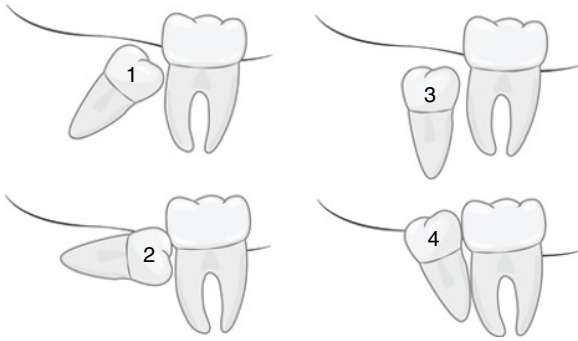


**Figure 2.5** Surgical difficulty based on depth relative to second molar. *Source:* Reproduced by permission of Robert J. Whitacre.

be the most difficult position and depth. This system is often attributed to Gregory and Pell. It is a modification of the classification developed by George B. Winter.

### Angulation

Angulation refers to the mandibular third molar longitudinal axis relative to its adjacent second molar longitudinal axis. Mandibular impaction angulations can be mesioangular (43%), horizontal (3%), vertical (38%), or distoangular (6%).<sup>9</sup>



**Figure 2.6** Surgical difficulty by angulation—4 is most difficult.

The long axis of mesioangular impactions is tilted toward the second molar. The mesioangular impacted third molar is notorious for third molar pain. Its crown is often partially erupted, leading to localized infection and pericoronitis. They represent 43% of all impactions and are usually the easiest to remove with a straight surgical handpiece. The long axis of horizontal impactions is perpendicular or nearly perpendicular to the second molar long axis. Horizontal impactions are the second easiest surgical angulation after the mesioangular. Inexperienced surgeons often mistake this angulation for the most difficult surgical angulation. Horizontal impactions represent 3% of all impactions. The vertical impaction long axis parallels the long axis of the second molar. Vertical impactions are considered to be more difficult than horizontal impactions due to access. This is especially true for deep vertical impactions. The vertical impaction represents 38% of impacted third molars. Finally, the distoangular mandibular impaction is tilted toward the ramus. The path of removal is toward the ramus (see Figure 2.6). This is the reason this angulation is considered the most difficult of all mandibular third molar impactions. Fortunately, they only account for 6% of mandibular third molar impactions. All of these impactions can be in buccal version or lingual version. The remaining 10% of mandibular impactions are transverse or inverted. A transverse impaction is growing toward the cheek or tongue. Inverted impactions are “upside down.”

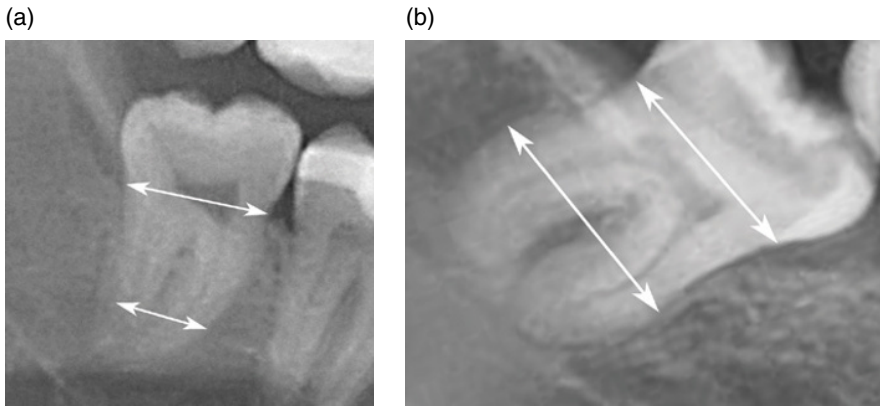
The radiographic assessment discussed here does not apply to maxillary third molars. Maxillary mesioangular impactions are usually more difficult than maxillary distoangular impactions.

### Combined Root Width

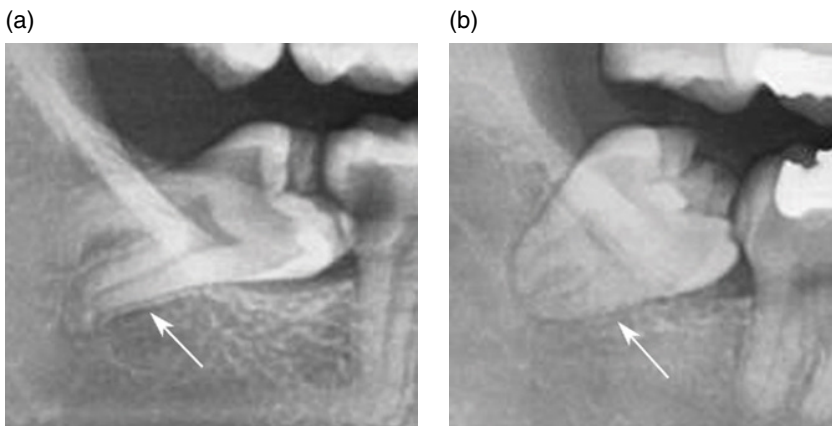
Combined root width is always a significant factor. A tooth with a conical root will be easier to remove than one with divergent roots. The roots of teeth with multiple roots are often divergent. The removal of these teeth will be more difficult when the combined root width is greater than the tooth width at the CEJ. Third molars with divergent roots may require sectioning (see Figures 2.7a and 2.7b).

### Root Length, Size, and Shape

Root length, size, and shape are always significant factors, but they are often overlooked. Third molar roots that are long, thin, or curved may fracture, leaving root fragments that are difficult to remove. The root fragments may be near vital structures such as the



**Figure 2.7** Different root widths: (a) Conical. (b) Divergent.



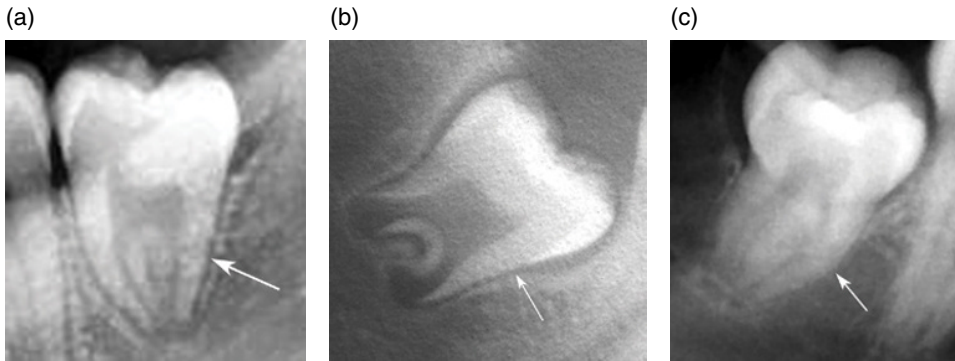
**Figure 2.8** Different root lengths, sizes, and shapes: (a) Long, thin, and curved. (b) Short, thick, and straight.

inferior alveolar nerve, maxillary sinus, infratemporal fossa, or submandibular fossa. It is always prudent to carefully assess quality radiographs to avoid root fracture. Sectioning may be required (see Figure 2.8a and 2.8b).

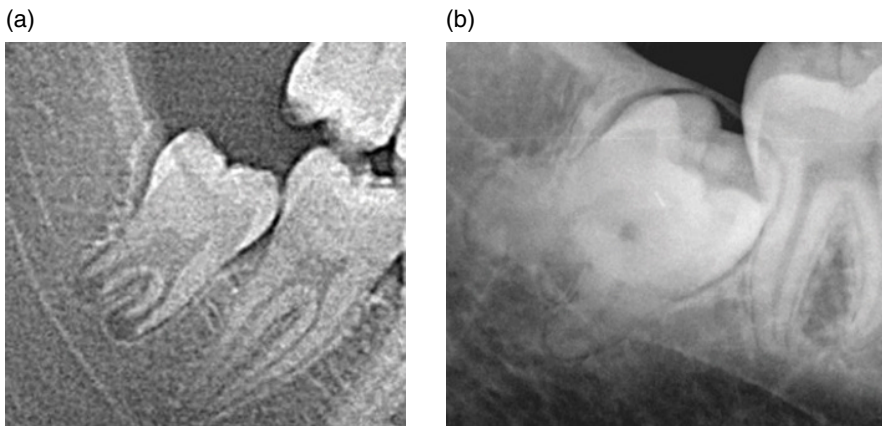
### Periodontal Ligament and Follicle

The periodontal ligament and follicle are always significant factors. A periodontal ligament space or follicle visible on a radiograph is a positive sign. These spaces allow for movement of the tooth with elevators and forceps. Periotomes, luxators, and proximators can be wedged into these spaces to luxate a tooth or root (see Figure 2.9a).

A dental follicle is always present with developing third molars. This structure differentiates into the periodontal ligament as the tooth develops.<sup>10</sup> The dental follicle provides a space larger than the periodontal ligament space (see Figure 2.9b). The follicular space is one reason oral surgeons recommend removing third molars early, usually in the teenage years.



**Figure 2.9** Periodontal ligament and follicle. (a) Wide periodontal ligament. (b) Third molar follicle. (c) Narrow periodontal ligament.



**Figure 2.10** Bone density and elasticity. (a) Dense bone. (b) Elastic bone.

Tooth ankylosis can be defined as the fusion of bone to cementum resulting in partial or total elimination of the periodontal ligament. An ankylosed tooth, or one with a narrow periodontal ligament, has no space for the insertion of instruments. This condition is in dramatic contrast to a developing third molar with follicular space (see Figure 2.9c).

### Bone Density and Elasticity

Density is defined as the degree of compactness of a substance. Elasticity is the ability of an object or material to resume its normal shape after being stretched or compressed. Both of these characteristics play a profound role in the removal of impacted third molars. Compact bone is very dense, strong, and stiff bone. Cancellous bone is softer, weaker, and more elastic than compact bone. Radiographs can provide indications of bone density (see Figures 2.10a and 2.10b). Age-related weakening of bony elasticity makes extractions more difficult and mandibular fracture more likely.<sup>11</sup>



## Position Relative to the Inferior Alveolar Canal

### Superimposition

Proper interpretation of a quality panoramic radiograph can significantly reduce inferior alveolar nerve (IAN) injuries. Many, if not most, general dentists assume that any third molar with roots extending to or beyond the radiographic inferior alveolar canal is at high risk of paresthesia. However, most third molar roots that appear to be near or beyond the canal are actually buccal or lingual to the nerve. This condition, known as superimposition, is indicated on a panoramic radiograph by continuous white lines created by the inferior alveolar canal bone. Superimposed tooth roots are buccal or lingual to the canal and IAN injury is unlikely (see Figure 2.11).

### Grooving

The inferior alveolar canal develops before third molar roots. Grooving of the third molar root is caused by a third molar root developing in close proximity to the IAN. Thinning of the developing root is caused by contact with the inferior alveolar canal. This condition, known as grooving, is indicated on radiographs by a radiolucent band where the canal crosses over the third molar root. The canal's radiographic white lines are not visible on the radiograph at this point. Grooving increases the possibility of IAN paresthesia (see Figure 2.12).


### Notching

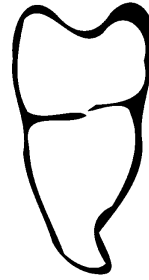
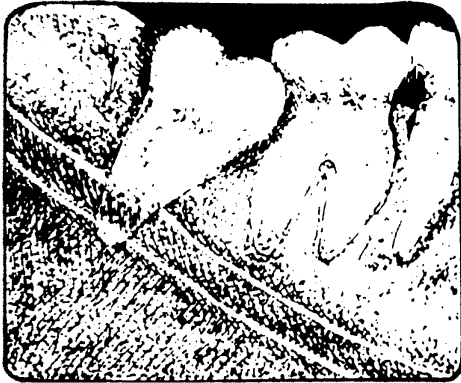
Notching, like grooving, is caused by the developing tooth contacting the inferior alveolar canal. In this case, the tooth root develops directly above the canal. This is seen on a radiograph as a radiolucent third molar apex and loss of the top white line as the canal passes over the root. The dark apex may also indicate an open apex for young patients whose third molar roots are still developing. Notching increases the possibility of IAN paresthesia (see Figure 2.13).

### Perforation

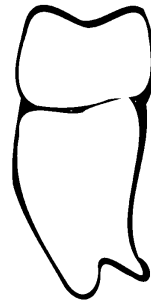

In rare cases, the developing third molar root completely encircles the inferior alveolar canal. This is seen on the radiograph as a narrowing, radiolucent band where the canal crosses through the third molar root. White lines are not visible on the radiograph at

**Figure 2.11** Continuous white lines indicate superimposition. *Source:* Courtesy of Michael Brooks.

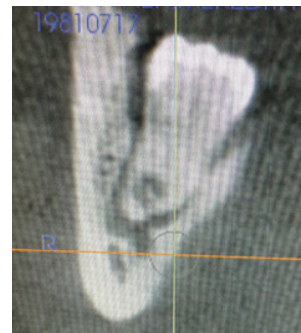
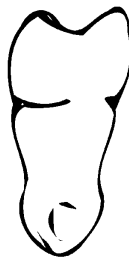


**Figure 2.12** A radiolucent band and loss of white lines indicates grooving. *Source:* Courtesy of Michael Brooks.



**Figure 2.13** A radiolucent apex and loss of the top white line indicates notching. *Source:* Courtesy of Michael Brooks.



**Figure 2.14** Narrowing of the IAN canal and loss of white lines indicates perforation. *Source:* Courtesy of Michael Brooks; Dr. Ryan Max Johnson, DDS. Abilene Wisdom Teeth.

this point (see Figure 2.14). Other radiographic signs of intimate root contact with the inferior alveolar canal include canal deflection, root deflection, bifid roots, and root narrowing. A detailed discussion of these radiographic signs, including several studies, can be found in Chapter 3.

## Early Third Molar Removal

Age may be the most significant factor in case selection. Several studies have shown that teenage patients have fewer surgical and postoperative complications.

A prospective study evaluated the surgical and postsurgical complications of 9,574 patients who had 16,127 third molars removed. It was concluded that removal of mandibular third molar teeth during the teenage years resulted in decreased operative and postoperative morbidity. The study showed that increased numbers of complications (alveolar osteitis, infection, and dysesthesias) occur in the removal of impacted third molars of older patients. This study suggests that, when indicated, third molars should be removed during the teenage years, thereby decreasing the incidence of postoperative morbidity.<sup>12</sup>

Another study estimated the frequency of complications after mandibular third molar surgery as related to patient age. An overall 4,004 subjects had a total of 8,748 mandibular third molars removed. The mean age was  $39.8 \pm 13.6$  years, with 245 subjects (6.1%) aged 25 and younger. The study concluded that increased age (>25 years) appears to be associated with a higher complication rate for mandibular third molar extractions.<sup>13</sup>

The American Association of Oral and Maxillofacial Surgeons published a white paper in 2007. They reviewed 205 publications related to various aspects of third molars. The effects of age on various parameters relating to third molars are so important that the AAMOS findings related to age are included verbatim in this chapter by permission of AAMOS.

## The Effects of Age on Various Parameters Relating to Third Molars<sup>14</sup>

**Symptomatology and Age:** A study of 1,151 patients from 13–69 years of age with third molars showed that of those who had symptoms, pain was the most common symptom (35.3%), followed by swelling (21.7%), discomfort from food impaction (3.6%), and purulent discharge (3%) (Punwutikorn 1999). The frequency of each increased generally with age. Slade also noted that 37% of patients presenting with wisdom tooth problems reported pain and swelling as the indication for seeking treatment (2004). Additionally, this study noted that Health Related Quality of Life indicators were reported more frequently as patients got older.

**Periodontal Pathology and Age:** Asymptomatic periodontal defects associated with third molars are more common in patients older than 25 (33%) than those under 25 (17%) (Blakey 2002). Inflammatory mediators and periodontal pathogens were similarly correlated with the periodontal defects (White 2002). On two year follow-up, 24% of the periodontal defects deteriorated by a further 2 mm (White 2006). A study of 6,793 persons 52 to 74 years old found that they had 1.5 times the odds of having a periodontal defect >5mm on the adjacent

second molar if the third molar was visible (Elter 2005). A comparison of 5,831 patients aged 25 to 34 with a group aged 18 to 24 showed a 30% greater chance of having a periodontal defect on the adjacent second molar when a third molar was present in the older age group versus the younger age group (Elter 2004). In a study of 342 subjects with a mean age of 73 who had at least one third molar present at three year follow-up, attachment losses  $\geq 2$  mm were detected on the third molars in 45% of subjects (Moss 2007).

**Caries and Age:** Caries prevalence in 342 subjects with a mean age of 73 years with at least one third molar present showed an increased caries prevalence in the third molars over time (Moss 2007). Another study of 22- to 32-year-old cohorts followed for three years, showed that caries prevalence in the third molars also increased with time in this younger age group (Shugars 2005). Caries were also correlated in third molars with the experience in non-third molars (Moss 2007, Shugars 2005). Shugars suggested that a 40% risk of caries in erupted third molars exists before the end of the third decade. Patients over 25 years of age have a greater caries experience compared to patients under 25 years of age (Shugars 2004).

**Postoperative Risks and Age:** A critical review showed lower postoperative morbidity in a younger age group of patients (Mercier 1991). All risks associated with third molar removal increased from age under 25, to 25 to 35, to over 35 (Bruce 1980). Health Related Quality of Life indicators similarly deteriorated for recovery as correlated with age following third molar removal (Phillips 2003). A study of 4,004 patients showed a 1.5 times likelihood of a complication if the patient having third molars removed at over 25 years of age with generalized increasing risks with age through age 65 (Srizingas and Dodson In Press). Similarly, in a study of 583 patients, age was correlated with risk (Bui 2003). Other studies also show that postoperative risks increase with increasing age (Valmaseda-Castellon 2001, Bataineh 2001). A consensus of the literature supports the concept that postoperative risks from third molar removal increase with age.

The risk of postoperative fracture following third molar removal may be age related, and one study shows a mean age at fracture to be 45 years (Krimmel 2000). The incidence of oroantral perforation from upper third molar removal may also increase with age past 21 years (Rothamel 2006). Postoperative periodontal defects occur twice as commonly (51%) in patients over 26 years of age, than those under 25 following third molar removal (Kugelberg 1990). Significant postoperative defects in 215 second molars were three times more common when removing impacted third molars over the age of 25 than under the age of 25 (Kugelberg 1991). Pockets on the second molars in 215 cases were studied two years postoperatively. Persistence of postoperative periodontal defects compared to preoperative defects in these patients were shown to be age related (Kugelberg 1985). Postoperative periodontal defects after third molar extraction are two to three times more common over the age of 25, and persistence of defects was age related.

**Germectomy or Lateral Trepanation:** For the purposes of this document, germectomy is defined as the removal of a tooth that has one third or less of root formation and also has a radiographically discernible periodontal ligament. A study of 15 cases of early third molar removal in patients aged between 13 and 16 years

of age showed no postoperative periodontal pocketing and no pocketing developing one year later (Ash 1962). In a study of 500 lower wisdom teeth removed in patients aged 9 to 16, there were no cases of alveolar osteitis, nerve involvement, or second molar damage, and a 2% infection rate was reported (Chiapasco 1995). In a study where germectomy was performed in 300 teeth in patients aged 12 to 19 years of age, there were no lingual nerve injuries (Chossegrs 2002). A study of 149 germectomies reported a 2% infection rate and no case of nerve involvement (Avendano 2005). A study of 86 patients aged 8 to 17 years, having 172 germectomies, reported that three patients developed infection, and no cases of nerve involvement or alveolitis were encountered (Bjornlang 1987). It does appear that early third molar removal may be associated with a lower incidence of morbidity and also less economic hardship from time off work for the patient.

**The Presence of Third Molars and Age:** One study noted that between 1997 and 2002 there was an increase in patients over the age of 40 requiring third molar removal (Kaminishi 2006). The number increased from 10.5% to 17.3% of all third molars removed. This was felt to be due to changing demographics in the geographical areas served by this study. It does appear that the eruption of third molars in older patients is more frequent than may be thought, but in some cases, rather than the third molar erupting, it may become visible due to periodontal bone loss and subsequent gingival recession and exposure (Garcia 1989). Many of these late erupting teeth have pathology, including caries and periodontal disease (Garcia 1989). A study of 14- to 45-year-olds found that 51% of 312 late erupting third molars had periodontal disease in a 2.2 year follow-up (Nance 2006).

### Conclusions

*Periodontal defects, as assessed by pocket depths, deteriorate with increasing age in the presence of retained third molars. Caries in erupted third molars increases in prevalence with increasing age.*

*The incidence of postoperative morbidity following third molar removal is higher in patients > 25 years.*

The selection of patients is critical to success when removing impacted third molars. Most teenage patients can be treated with confidence when proper surgical protocol is followed. Caution is advised when treating patients aged 20–25 with fully developed roots. Patients over age 25 will have more surgical and postoperative complications. All factors including age must be considered before selecting patients for impacted third molar surgery. Referral to a maxillofacial surgeon may be prudent for many patients older than age 25.

## Prophylactic Removal of Third Molars

Studies presented in this chapter support the early removal of third molars. Surgical and postoperative complications are minimized when third molars are removed in the teenage years. Early removal of third molars includes germectomy, the removal of a third

molar with one-third or less root development. Germectomy is always prophylactic because the teeth are full bony impactions with little or no root development. Advocates of early removal of third molars believe that it is better to intercept and prevent potential issues than to simply react and deal with the consequences. Opponents believe that there is no reliable evidence to support the prophylactic removal of disease-free impacted third molars.

The prophylactic removal of asymptomatic third molars is controversial. Many studies have been published supporting both sides of the argument. The United Kingdom-based National Health Service and the National Institute for Clinical Excellence (NICE) published guidelines in 2000 citing a “lack of evidence for prophylactic removal of asymptomatic wisdom teeth.”<sup>15</sup> The American Association of Maxillofacial Surgeons’ 2007 white paper concluded that early third molar removal may be associated with lower incidence of morbidity and less economic hardship from time off work for the patient.<sup>16</sup> Each side has been criticized for bias.

Cochran Reviews are systematic reviews of research in health care and health policy. Cochrane Reviews authors apply methods that reduce the impact of bias. Cochrane is an independent network of researchers, professionals, patients, caregivers, and people interested in health. Their work is recognized as representing an international gold standard for high-quality, trusted information.

A 2016 Cochrane review looked at prophylactic removal of asymptomatic impacted third molars versus retention in adolescents and adults. The electronic database search found insufficient evidence to support or refute routine prophylactic removal of asymptomatic disease-free impacted wisdom teeth. Cochrane concluded that patient values and clinical expertise should guide shared decision making with patients who have asymptomatic disease-free impacted wisdom teeth.<sup>17</sup>

Patients are responsible for the final decision regarding the prophylactic removal of asymptomatic disease-free third molars. The dentist and oral surgeon are responsible for informing the patient of the risks and benefits of retention or prophylactic removal.

The author is an advocate for the early prophylactic removal of third molars in most cases. This advocacy stems from evidence-based research and 36 years of experience removing impacted third molars. The author has removed more than 25,000 third molars with no permanent paresthesia or significant complication. Most of these patients were younger than age 25.

In rare cases, when patients have sufficient room for eruption and hygiene, retention is recommended. These patients should be closely monitored since the ability to erupt does not guarantee third molar health. Sufficient access is required to ensure adequate oral hygiene.

## Summary

Case selection is vitally important to ensure a good surgical result for patients. Dentists who are just beginning to remove impacted third molars are advised to carefully select appropriate patients. Special attention should be given to the age of patients undergoing third molar removal. Research shows that teenagers will experience fewer complications and will have better recovery. Third molar removal when roots are undeveloped is

more predictable than when roots are fully formed and may be near vital structures. Difficult cases should be referred to an oral or maxillofacial surgeon. More challenging cases can be done as skills improve.

## References

- 1 American Society of Anesthesiologists. ASA Physical Status Classification System. Retrieved 9 July 2007.
- 2 de Jong KJ, Oosting J, Abraham-Inpijn L. Medical risk classification of dental patients in the Netherlands. *J Public Health Dent.* 1993 Fall;53(4):219–22.
- 3 Smeets EC, de Jong KJ, Abraham-Inpijn L. Detecting the medically compromised patient in dentistry by means of the medical risk-related history. A survey of 29,424 dental patients in the Netherlands. *Prev Med.* 1998;27(4):530–5.
- 4 Kaminishi RM, Kaminishi KS. New considerations in the treatment of compromised third molars. *J Calif Dent Assoc.* 2004 Oct;32(10):823–5.
- 5 US Department of Health and Human Services. National High Blood Pressure Educational Program, NIH publication No. 3-5233, 2003 Dec.
- 6 Awino BO, Ogonda LA, Barno GC, Ng'wena G, Ng'wena MAG. Awareness Status and Associated Risk Factors for Hypertension among Adult Patients Attending Yala Sub-County Hospital, Siaya County, Kenya. *Public Health Research.* 2016;6(4):99–105.
- 7 Lloyd-Jones D, Adams RJ, Brown TM, et al. Heart disease and stroke statistics—2010 update: a report from the American Heart Association. *Circulation.* 2010;121(7):e46–e215.
- 8 Lenzenweger MF, Lane MC, Loranger AW, Kessler RC. DSM-IV personality disorders in the National Comorbidity Survey Replication. *Biol Psychiatry.* 2007;62(6):553–64.
- 9 Peterson LJ. Principles of management of impacted teeth in contemporary oral and maxillofacial surgery, 2nd ed. Missouri: Mosby Publications, 1993:237–9.
- 10 Nanci A. Ten Cate's oral histology, 8th ed. Elsevier, 2013:220.
- 11 Abdulkadir Burak Cankaya, et al. Iatrogenic mandibular fracture associated with third molar removal. *Int J Med Sci.* 2011;8(7):547–53.
- 12 Thomas P. Osborn, DDS, et al. A prospective study of complications related to mandibular third molar surgery. *J Oral Maxillofac Surg.* 1965;43:767–69.
- 13 Chuang SK, Perrott DH, Susarla SM, Dodson TB. Age as a risk factor for third molar surgery complications, *J Oral Maxillofac Surg.* 2007;65(9):1685–92.
- 14 American Association of Maxillofacial Surgeons. White Paper on Third Molar Data, The effects of age on various parameters relating to third molars. 2007.
- 15 Eng R. Third Molar Surgery: A Review of Current Controversies in Prophylactic Removal of Wisdom Teeth. *Oral Health.* 2009 June 1.
- 16 American Association of Maxillofacial Surgeons. White Paper on Third Molar Data, The effects of age on various parameters relating to third molars. 2007.
- 17 Ghaemina H, Perry J, Nienhuijs ME, Toedtling V, Tummers M, Hoppenreijts TJ, Van der Sanden WJ, Mettes TG. Surgical removal versus retention for the management of asymptomatic impacted wisdom teeth. *Cochrane Database Syst Rev.* 2016 Aug 31;8:CD003879.





### 3

## Complications

The expected postoperative healing following the removal of impacted third molars includes pain, swelling, bleeding, and muscle trismus. Complications are uncommon and usually avoidable when proper case selection and surgical protocol are followed. The purpose of this chapter is to discuss potential third molar surgical complications.

A retrospective cohort study by Bui, Seldin, and Dodson found the overall complication rate for the removal of mandibular third molars is 4.6%. The risks of complications are lower for maxillary third molars than for mandibular third molars. Risk increases with age, position of third molars relative to the inferior alveolar nerve, and positive medical histories.<sup>1</sup>

Possible complications include paresthesia, alveolar osteitis, infections, bleeding and hemorrhage, jaw fracture, osteomyelitis, damage to proximal teeth, buccal fat pad exposure, oral-antral communication, displacement of third molars, aspiration, periodontal defects, and temporomandibular joint injury. The four most common postoperative complications of third molar extraction reported in the literature are paresthesia, alveolar osteitis, infection, and bleeding/hemorrhage.<sup>2</sup>

## Paresthesia

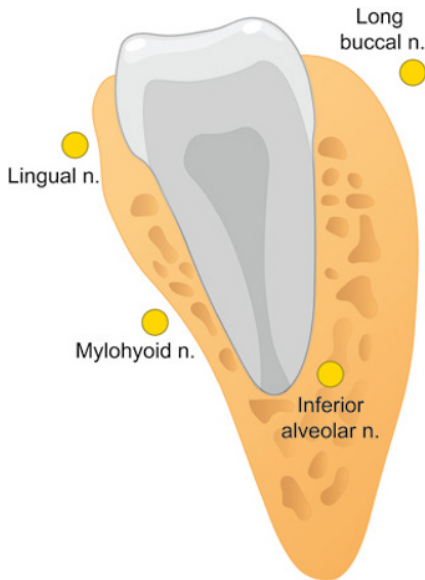
Impacted mandibular third molar teeth are in close proximity to the lingual, inferior alveolar, mylohyoid, and buccal nerves<sup>3</sup> (see Figure 3.1).

The possibility of paresthesia is a common reason for referral to maxillofacial surgeons by general dentists. The referral is usually made after viewing a panoramic radiograph showing a third molar root near the inferior alveolar canal. However, as we learned in Chapter 2, mandibular third molar roots seen on radiographs are often superimposed on the inferior alveolar canal. Radiographic superimposition indicates that the roots are either buccal or lingual to the canal.

Many studies have been published on the risk of nerve injury following the removal of third molars. A sample of those studies is presented here.

## Buccal and Mylohyoid Nerve Studies

Although the buccal and mylohyoid nerves may be near third molars, they are rarely affected. Alves studied 10 cadaver heads and found that the buccal nerve crossed the



**Figure 3.1** Nerves in close proximity to mandibular third molars.

anterior border of the ramus at a point far above the retromolar region. He concluded that the risk of injury to the buccal nerve was low.<sup>4</sup>

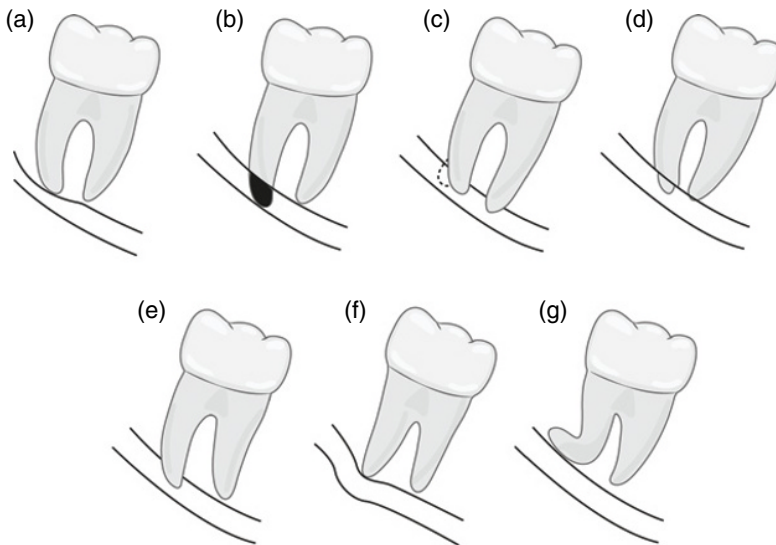
Merril and MacGregor postulated that the buccal nerve was frequently cut during incisions for the removal of mandibular third molars, but sensory changes go unnoticed.<sup>5,6</sup> The author found one study of mylohyoid injuries. The study, published in 1992 by Carmichael, found injury to the mylohyoid nerve to be as high as 1.5%, probably due to lingual retraction.<sup>7</sup>

There is very little evidence in the literature demonstrating injury to the buccal and mylohyoid nerves following the removal of impacted mandibular third molars. The nerves most commonly affected are the inferior alveolar and lingual nerves. Many studies have been conducted in an attempt to estimate the possibility of inferior alveolar and lingual nerve injury when removing third molars. A summary of selected studies follows.

### IAN Studies

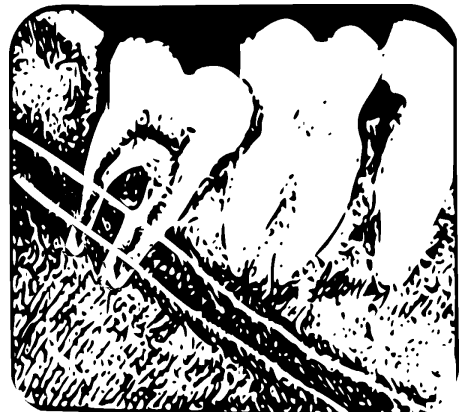
Sarikov and Juodzbals conducted a systematic review of 14 studies.<sup>8</sup> They found IAN injury ranged from 0.35% to 8.4%. Ninety-six percent of IAN injuries recovered within 8 weeks. They concluded that injury of the IAN can be predicted by various panoramic radiological signs. These signs included narrowing of the canal, dark root apices, bifid root apices, narrowing of the root, loss of the canal “white line” on radiographs, deflection of the canal, and deflection of the root. When panoramic radiological signs indicate intimate contact between a third molar and the inferior alveolar canal, 3D imaging with computed tomography is recommended (see Figure 3.2).

Darkening of third molar roots near the IAN is less significant for young patients with developing root apices. The IAN is normally buccal or lingual to third molar roots. The radiographic roots are superimposed on the canal. Superimposition is indicated on radiographs when there is no interruption of radiographic white lines (see Figure 3.3).



**Figure 3.2** Radiographic indications of root contact with IAN. (a) Narrowing of canal, (b) Dark root apex, (c) Bifid root apex, (d) Narrowing of root, (e) Loss of “white line,” (f) Deflection of canal, (g) Deflection of root.

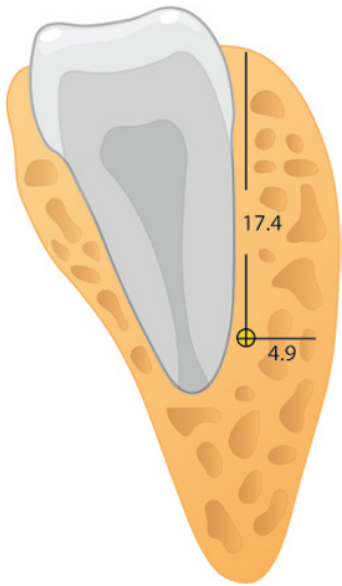
**Figure 3.3** Superimposition of roots on IAN canal; the white line is continuous and uninterrupted.  
Source: Courtesy of Michael Brooks.



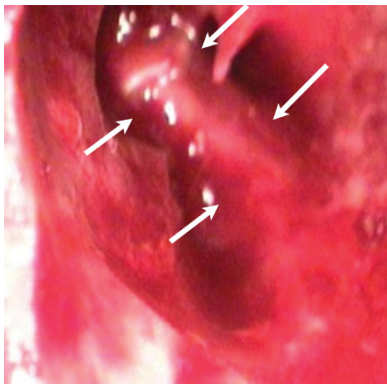
Superimposition indicates no intimate contact with the IAN canal and a low probability of nerve injury, especially for patients under age 25.

Levine et al. studied the IAN canal position within the body of the mandible.<sup>9</sup> The average IAN canal position was 4.9mm from the lateral surface of the mandible and 17.4mm apical from the alveolar crest (see Figure 3.4). It's important to note that the IAN may be lingual to third molar roots for two reasons:

- 1) Third molars are often in a linguoversion position with roots near or touching buccal bone.
- 2) The 17.4mm and 4.9mm distance are average distances. Variable positions are very common.



**Figure 3.4** One study's average IAN position—IAN position is highly variable.



**Figure 3.5** IAN “true relationship” following third molar removal.

The bucco-lingual IAN canal position was associated with age and race. Older patients and white patients had less distance between the buccal aspect of the canal and the buccal surface of the mandible. To minimize the risk of IAN injury, these variables should be considered when removing impacted mandibular third molars.

In a landmark inferior alveolar nerve article by Howe and Poyton in 1960 it was determined after evaluating 1,355 impacted mandibular molars clinically and radiographically at the time of extraction that a true relationship existed in only 7.5% of cases.<sup>10</sup> A “true relationship” was defined as the visualization of the neurovascular bundle at the time of tooth removal (see Figure 3.5). An “apparent” relationship was defined by radiographs when the roots of the teeth appeared to be in an intimate relationship to the IAN. This occurred in 61.7% of the third molars.

Of the 70 cases that developed nerve impairment, more than 50% of them had a true relationship with the IAN. This was a 13 times greater incidence than that occurring with those teeth exhibiting an apparent one. The study found that permanent nerve injury is much more likely to occur if there is a true relationship between the IAN and the roots of mandibular third molar teeth. Permanent IAN injury occurred in less than 1% of all patients, even though an apparent relationship existed in 61.7% of all radiographs. The results of this study seem to indicate that the radiographic appearance of third molar roots close to the IAN is not a good predictor of IAN injury.

The Howe and Poyton study further noted an increased incidence in older patients, in teeth that were deeply impacted, and in those that exhibited grooving, notching, or perforation, as well as a three- and fourfold increase in mesial and horizontally impacted teeth with linguoversion.

Valmeseda-Castellon et al. had similar findings in their study published in 2000.<sup>11</sup> They found the location of impacted teeth and a person's age contributed to the incidence of injury. There is a greater incidence of injury as persons become older. Wisdom teeth that are lingually oriented, or those where there is direct contact with the inferior alveolar canal, are more likely to be associated with injury. Injury seems to adversely affect females more often than males. Surgical duration is another variable that may contribute to nerve injury.

## Lingual Nerve Studies

The incidence of lingual nerve injury following mandibular third molar removal may depend on the surgical technique. Raising and retracting a lingual mucoperiosteal flap with a Howarth periosteal elevator may result in more frequent injury, but this is usually temporary.<sup>12</sup>

In a study of 1117 consecutive surgical procedures to remove a lower third molar by a variety of operators, the incidence of lingual nerve damage was determined to be 11%. Lingual flaps were implicated in this study. The percentage of nerve injury varied among surgeons. Permanent damage arose when distal bone was removed with a bur.<sup>13</sup>

Karakas et al. studied the relationship of the lingual nerve to third molars using radiographic images. A literature search found that the incidence of lingual nerve damage during mandibular region surgery varies between 0.6% and 2.0%.<sup>14</sup>

## Combined Inferior Alveolar and Lingual Nerve Studies

The incidence of reported postoperative dysesthesia of the inferior alveolar and the lingual nerve (LN) varies widely in published studies. Bui and colleagues studied 583 patients who had third molars removed by an experienced oral surgeon between 1996 and 2001. The majority of subjects in this study were healthy college students. Approximately 75% of the mandibular third molars were in close proximity to the inferior alveolar canal. IAN and lingual nerve injuries were 0.4% and 0%, respectively.<sup>15</sup>

In a study published in 2000 by Gargallo-Albiol et al., the incidence of temporary disturbances affecting the IAN or the LN was found to range from 0.278% to 13%.<sup>16</sup> Zuniga found the incidence of injury to the IAN to range from 0.4% to 25%. Lingual nerve injury ranged from 0.04% to 0.6%. The incidence of permanent nerve damage varied between 0.5% and 2%.<sup>17</sup>

Cheung et al. carried out a study in which lower third molar extractions were performed by surgeons with different levels of skill. In this study, 0.35% developed IAN deficit and 0.69% developed LN deficit. Inexperienced surgeons caused more lingual nerve injuries. He concluded that distoangular impactions increased the risk of LN deficit significantly. Deep impactions increased the risk of IAN sensory deficit.<sup>18</sup>

Anwar Bataineh found LN paresthesia in 2.6% of patients. There was a highly significant increase in the incidence associated with the use of lingual flaps. The incidence of IAN paresthesia was 3.9%. The study concluded that the elevation of lingual flaps and the experience of the operator are significant factors contributing to lingual and inferior alveolar nerve paresthesia, respectively.<sup>19</sup>

Meshram et al. studied 147 patients, three of whom reported paresthesia.<sup>20</sup> Two patients reported LN paresthesia (1.36%) and one patient reported IAN paresthesia (0.68%). One of the lingual paresthesia third molars was a horizontal Gregory-Pell class IIC, a deep impaction partially in the ramus. The second lingual paresthesia was a distoangular Gregory-Pell class IIA, a minimally deep impaction partially in the ramus. The third molar with IAN paresthesia was a Gregory-Pell class IIA mesioangular impaction (a minimally deep impaction partially in the ramus). In this study, incidence of injury to IAN and LN was comparatively very low, and all cases were of transient paresthesia.

Various factors are responsible for the injury to the inferior alveolar nerve and lingual nerve in third molar surgery. Most studies have shown that when paresthesia follows

extraction, it is likely to be temporary and to resolve within the first 6 months. The combined findings of IAN and LN studies are presented in Table 3.1.

These studies found IAN and LN paresthesia ranging from 0.28% to 13.0% and 0% to 13%, respectively. Some studies found a very low percentage of nerve injury while others found a relatively high incidence. These inconsistencies are probably due to variability in study design. For example, studies completed with an expert surgeon, patients under age 25, or without lingual flap found a lower incidence of nerve injury than studies with less experienced surgeons, older patients, or with lingual flap technique. Factors affecting the risk of nerve damage are shown in Box 3.1.

IAN and LN paresthesia can profoundly affect patients both psychologically and physically. Speech and chewing can be impaired following nerve injury and lead to litigation. Therefore, it's important to thoroughly document nerve injury in the patient's chart.

**Table 3.1** Combined findings of IAN and LN studies.

Study	IAN %	Risk Factors	LN %	Risk Factors
Bui et al. [15]	0.4		0	
Gargallo-Albiol et al. [16]	0.278–13		0.278–13	
Zuniga [17]	0.4–25		0.04–0.6	
	0.5–2		0.5–2	
	permanent		permanent	
Cheung et al. [18]	0.35	Depth	0.69	Distoangular position Lingual flap Lingual version Vertical sectioning Surgeon experience
Bataineh [19]	3.9	Surgeon experience	2.6	Lingual flap
Meshram et al. [20]	0.68		1.36	
Sarikov and Juodzbaly [8]	0.35–8.4	Root deflection Root narrowing Root dark/bifid Canal narrowing Canal diversion		
Blackburn and Bramley [13]			11.0	Lingual flap Surgeon experience Distal bone removed
Karakas et al. [14]			0.6–2.0	
Howe and Poynton [10]	<1.0	Age Depth Grooving Notching Perforation Linguoversion		

**Box 3.1 Factors affecting nerve injury.**

Expertise of surgeon	Formed roots vs. incomplete root formation
Age of patient	Roots close to IAN as defined on X-ray
Depth of impaction	Time taken to perform procedure
Mesial/horizontal impactions in linguoversion	Surgical technique
Sectioning multiple times	Distal bone removal

An evaluation of the extent of IAN injury should be conducted as soon as an altered sensation is reported by the patient. The patient's subjective assessment of change is important. The surgeon should ask the patient if there is any change in sensation since the teeth were removed. Any change in sensation is a positive sign and indicates probable recovery of normal sensation. The patient should be informed that recovery is likely, but full recovery may take a few weeks or more than a year. Mapping is used to record the areas affected when no change is reported.

Mapping is accomplished using sophisticated tests such as Semmes Weinstein monofilament or simple cotton fibers. A sharp instrument such as an explorer is commonly used for mapping. Light touch fibers or explorer are applied to the affected area and slowly moved until the patient reports sensation. The point where the patient is aware of stimulus is recorded in the patient's chart. Photographic documentation can be recorded by marking points of sensation on the patient's face with an erasable marker. Recovery of normal sensation is often slow and patients may not be aware of progress. Mapping provides a semiobjective measurement of change. If no change is found after three months, the patient should be referred to an appropriate maxillofacial surgeon for evaluation and possible nerve repair. The extent of nerve injury can be documented using systems for classification. Seddon described three classes of peripheral nerve injury.<sup>21</sup>

**Class I—Neurapraxia**

Class I nerve injury is the mildest form of nerve injury and full recovery is expected. There is a temporary loss of conduction without loss of axonal continuity. In neurapraxia, there is a physiologic block of nerve conduction in the affected axons. Full recovery takes days to weeks. The axon portion distal to the injury does not degenerate.

**Class II—Axonotmesis**

Class II injuries involve the loss of the relative continuity of the axon and its covering of myelin, but preservation of the connective tissue framework of the nerve (the encapsulating tissue, the epineurium and perineurium) are preserved. Axon degeneration occurs distal to the site of injury. Axonal regeneration occurs and recovery is possible without surgical treatment.

**Class III—Neurotmesis**

Class III injuries are the most severe and involve total severance or disruption of the entire nerve fiber. Degeneration occurs distal to the site of injury and sensory problems are severe. There is no nerve conduction distal to the site of injury. Surgical intervention

is necessary. Seddon's peripheral nerve classification was expanded by Sunderland to include five degrees of nerve injury.<sup>22</sup>

For purposes of documentation following nerve injury, it is recommended to document Class I–II (recovering) injury versus Class III (requires surgical repair) injury.

### Paresthesia Conclusions

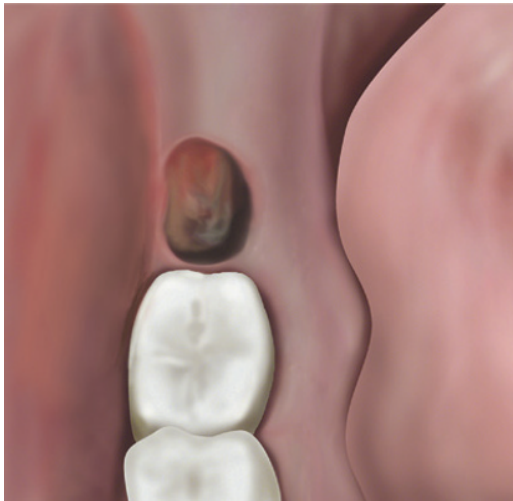The risk of paresthesia following the removal of third molars is low when certain guidelines are followed. Risk factors to avoid have been identified in many studies. Most of these factors can be eliminated with proper case selection and good surgical protocol.

The author has removed more than 25,000 third molars with no permanent nerve injury. Thirteen patients had temporary paresthesia. Most of the treated patients were teenagers with one-third to two-thirds root development. Early third molar removal appears to be a vital key to avoid paresthesia. In the opinion of the author, virtually all risk factors can be eliminated when third molars are removed prior to full root development using a buccal approach. Dentists with minimal experience should begin by removing soft tissue impactions for teenagers with partial root development.

Radiographic superimposition of third molar roots on the inferior alveolar canal is not an absolute contraindication for treatment. A cone beam CT scan can confirm the relationship between third molar and inferior alveolar canal when intimate contact is suspected. Patients should be referred to a maxillofacial surgeon when significant risk of paresthesia exists.

### Alveolar Osteitis

Alveolar osteitis (AO) is the most common complication following the removal of third molars (see Figure 3.6). Alveolar osteitis is commonly called “dry socket.” It's also known as alveolitis, localized osteitis, fibrinolytic alveolitis, septic socket, necrotic socket,



**Figure 3.6** Postextraction socket with exposed bone. *Source:* Reproduced by permission of Joanna Culley BA(hons) IMI, MMAA, RMIP.



alveolgia, and fibrinolytic alveolitis. Symptoms typically develop 4 to 5 days following surgery. AO is self-limiting and will resolve spontaneously if left untreated. Treatment is palliative.

AO is characterized by extreme pain radiating to the ear or temporal region, empty socket, and foul odor/taste. The condition is significant because it causes extreme pain and usually requires several visits to treat. The exact cause of AO is not well known and many concepts about the condition are controversial.

### Possible Causes

Kolokythas et al. completed a comprehensive review of AO literature and published an article in 2010. Sixteen possible causes were found in their literature search.<sup>23</sup>

#### 1. Surgical Trauma and Difficulty of Surgery

Most authors agree that surgical trauma and difficulty of surgery play a significant role in the development of AO. This could be due to more liberation of direct tissue activators secondary to bone marrow inflammation following the more difficult, hence, more traumatic extractions. Surgical extractions, in comparison to nonsurgical extractions, result in a 10-fold increased incidence of AO. Lilly et al. found that surgical extractions involving reflection of a flap and removal of bone are more likely to cause AO.

#### 2. Lack of Operator Experience

Many studies claim that operator's experience is a risk factor for the development of AO. Larsen concluded that surgeon's inexperience could be related to a bigger trauma during the extraction, especially surgical extraction of mandibular third molars. Alexander and Oginni et al. both reported a higher incidence of AO following extractions performed by the less experienced operators. Therefore, the skill and experience of the operator should be taken into consideration.

#### 3. Mandibular Third Molars

It has been shown that alveolar osteitis is more common following the extraction of mandibular third molars. Some authors believe that increased bone density, decreased vascularity, and a reduced capacity of producing granulation tissue are responsible for the site specificity. However, there is no evidence suggesting a link between AO and insufficient blood supply. The area specificity is probably due to the large percentage of surgically extracted mandibular third molars and may reflect the effect of surgical trauma rather than the anatomical site.

#### 4. Systemic Disease

Some researchers have suggested that systemic disease could be associated with alveolar osteitis. One article proposed immunocompromised or diabetic patients being prone to development of alveolar osteitis due to altered healing. But no scientific evidence exists to prove a relationship between systemic diseases and AO.

### **5. Oral Contraceptives**

Oral contraceptive is the only medication associated with developing AO. Oral contraceptives became popular in 1960s and studies conducted after 1970s (as opposed to studies prior to 1960s) show a significant higher incidence of AO in females. Sweet and Butler found that this increase in the use of oral contraceptives positively correlates with the incidence of AO. Estrogen has been proposed to play a significant role in the fibrinolytic process. It is believed to indirectly activate the fibrinolytic system (increasing factors II, VII, VIII, X, and plasminogen) and therefore increase lysis of the blood clot. Catellani et al. further concluded that the probability of developing AO increases with increased estrogen dose in the oral contraceptives. One author even suggested that in order to reduce the risk of AO, hormonal cycles should be considered when scheduling elective exodontia.

### **6. Patient's Gender**

Many authors claim that female gender, regardless of oral contraceptive use, is a predisposition for development of AO. MacGregor reported a 50% greater incidence of AO in women than that in men in a series of 4000 extractions, while Colby reported no difference in the incidence of AO associated with gender.

### **7. Smoking**

Multiple studies demonstrated a link between smoking and AO. A dose dependent relationship between smoking and the occurrence of alveolar osteitis has been reported. Among a total of 4000 surgically removed mandibular third molars, patients who smoked a half-pack of cigarettes a day had a four- to five-fold increase in AO (12% versus 2.6%) when compared to nonsmokers. The incidence of AO increased to more than 20% among patients who smoked a pack per day and 40% among patients who smoked on the day of surgery. Whether a systemic mechanism or a direct local affect (heat or suction) at the extraction site is responsible for this increase is unclear. Blum speculated that this phenomenon could be due to the introduction of foreign substance that could act as a contaminant in the surgical site.

### **8. Physical Dislodgement of the Clot**

Although a very commonly discussed theory, no evidence exists in the literature verifying that physical dislodgement of the blood clot caused by manipulation or negative pressure created via sucking on a straw would be a major contributor to AO.

### **9. Bacterial Infection**

Most studies support the claim that bacterial infections are a major risk for the development of AO. It has been shown that the frequency of AO increases in patients with poor OH, preexisting local infection such as pericoronitis and advanced periodontal disease. Attempts have been made to isolate specific causative organisms. A possible association of *Actinomyces viscosus* and *Streptococcus mutans* in AO was studied by Rozantis et al., where they demonstrated delayed healing of extraction sites after inoculation of these microorganisms in animal models. Nitzan et al. observed high plasmin-like fibrinolytic activities from

cultures of *Treponema denticola*, a microorganism present in periodontal disease. Catenalli studied bacterial pyrogens in vivo and postulated that they are indirect activators of fibrinolysis.

#### **10. Excessive Irrigation or Curettage of Alveolus**

It has been postulated that excessive repeated irrigation of alveolus might interfere with clot formation and that violent curettage might injure the alveolar bone. However, the literature lacks evidence to confirm these allegations in the development of AO.

#### **11. Age of the Patient**

Little agreement can be found as to whether age is associated with peak incidence of AO. The literature supports the general axiom that the older the patient, the greater the risk. Blondeau et al. concluded that surgical removal of impacted mandibular third molars should be carried out well before age of 24 years, especially for female patients since older patients are at greater risk of postoperative complications in general.

#### **12. Single Extraction versus Multiple Extractions**

Limited evidence exists indicating higher prevalence of AO after single extractions versus multiple extractions. In one study, AO prevalence was 7.3% following single extractions and 3.4% following multiple extractions. This difference could possibly be due to less pain tolerance in patients with single extractions compared to patients with multiple extractions whose teeth have deteriorated to such an extent that multiple extractions are needed. Moreover, multiple extractions involving periodontally diseased teeth may be less traumatic.

#### **13. Local Anesthetic with Vasoconstrictor**

It has been suggested that the use of local anesthesia with vasoconstrictors increases the incidence of AO. Lehner found that AO frequency increases with infiltration anesthesia because the temporary ischemia leads to poor blood supply. However, the studies that followed indicated that ischemia lasts for one to two hours and is followed by reactive hyperemia, which makes it irrelevant in the disintegration of the blood clot. One study reported no significant difference in AO prevalence following extraction of teeth requiring infiltration anesthesia versus regional block anesthesia with vasoconstrictor. It is currently accepted that local ischemia due to vasoconstrictor in local anesthesia has no role in the development of AO.

#### **14. Saliva**

A few authors have argued that saliva is a risk factor in the development of AO. However, no firm scientific evidence exists to support this claim. Birn found no evidence that saliva plays a role in AO.

#### **15. Bone/Root Fragments Remaining in the Wound**

Some authors have suggested that bone/root fragments and debris remnants could lead to disturbed healing and contribute to development of AO. Simpson,

in his study, showed that small bone/root fragments are commonly present after extractions and these fragments do not necessarily cause complications as they are often externalized by the oral epithelium.

#### 16. Flap Design/Use of Sutures

Some previous literature claims that flap design and the use of sutures affect the development of AO. However, more recent studies found little evidence to prove such relationship. In the absence of any significant evidence, it is reasonable to assume that these are not major contributing factors.

A summary of possible causes of AO, and their significance, is presented in Table 3.2. Mandibular third molars have the highest incidence of AO following removal. One possible explanation for this is the difficulty and trauma related to the removal of mandibular impacted third molars. It has been reported that the incidence of AO is 10 times greater following surgical extractions (impacted third molar) than nonsurgical extractions.<sup>24</sup>

### Prevention

Many studies have been conducted regarding the prevention of AO. The results of these studies are often controversial and inconsistent. However, the literature provides some insight into the clinical management of AO. There is evidence to support the use of a 0.12%

**Table 3.2** Contributing factors in the development of alveolar osteitis.

Proposed AO Causes	Major	Minor or Unproven
Smoking	X	
Age	X	
Surgeon experience	X	
Surgical difficulty/trauma	X	
Oral contraceptives	X	
Female gender	X	
Bacterial infection		X
Systemic disease		X
Physical dislodgement of clot		X
Excessive irrigation/curettage		X
Multiple vs. single extraction		X
Anesthetic and vasoconstrictor		X
Saliva		X
Bone/root fragments in wound		X
Flap design and sutures		X
Systemic disease		X
Compromised blood supply		X
Radiotherapy		X
Mandibular third molars		X

and 0.2% chlorhexidine rinse prior to surgery and one week postextraction to prevent the occurrence of dry socket following tooth extraction (see Figure 3.7).

In a prospective, randomized, double-blind placebo-controlled study, this regime was associated with a 50% reduction in alveolar osteitis compared to the control group.<sup>25</sup> In 2007 Shepard analyzed five randomized controlled trials studying prevention of alveolar osteitis (dry socket). The analysis indicated that 0.12% chlorhexidine gluconate rinsing preoperatively and 7 days postoperatively reduces the frequency of alveolar osteitis following surgical removal of lower third molars.<sup>26</sup>

Renton et al. reviewed the literature and concluded that prophylactic antibiotics reduce the risk of AO following the removal of mandibular third molars.<sup>27</sup> However, the potential for anaphylaxis, the development of resistant bacterial strains, and other adverse side effects preclude the routine use of antibiotics. Patients with a known risk for AO such as smokers and females on birth control may benefit from prophylactic antibiotics. Among the many antibiotics studied, topical tetracycline has shown promising results. The reported method of delivery includes powder, aqueous suspension, gauze drain, and Gelfoam sponges (preferred). However, side effects including foreign body reactions have been reported with the application of topical tetracycline.<sup>28</sup> There is also evidence that antifibrinolytic agents applied to the socket after the extraction may reduce the risk of dry socket.<sup>29</sup>

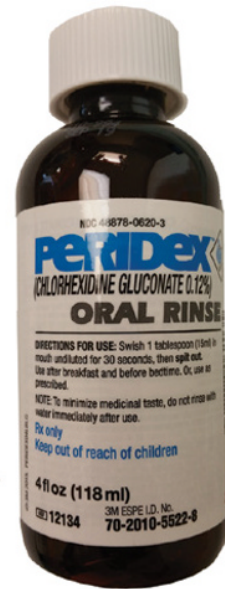

Figure 3.7 Chlorhexidine rinse.

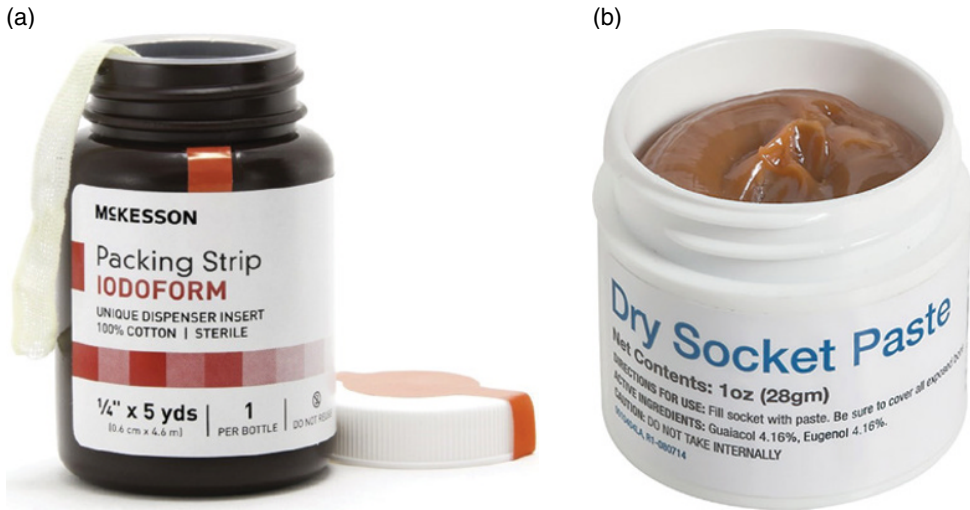## Treatment

Treatment of AO is focused on medications to alleviate pain since the condition is self-limiting. Systemic pain medications may be used but are rarely sufficient without topical dressings. The most common treatment involves irrigation of the extraction site with chlorhexidine and the placement of medicated dressings in the socket (see Figures 3.8a and 3.8b and Box 3.2). Many different medicaments and carrier systems are commercially available.

The author has had success using iodoform gauze strips coated with dry socket paste. Dry socket paste containing gualacol, balsam peru, eugenol, and 1.6% chlorobutanol (Sultan Healthcare, York, PA) can be placed with iodoform gauze. Another common medicament used in the management of AO is Alvogyl containing butamben (anesthetic), eugenol (analgesic), and iodoform (antimicrobial). All AO topical dressings contain varying amounts of similar ingredients designed to control pain and bacterial growth.

## Alveolar Osteitis Conclusions

Alveolar osteitis is the most common complication following the removal of impacted third molars. AO etiology is unknown, but many contributing factors have been suggested. Major factors include smoking, surgeon's experience, difficult extractions, female gender,



**Figure 3.8** (a) Iodoform gauze. (Courtesy of Christopher Rogers) (b) Dry socket paste.

### Box 3.2 A typical regimen used in the treatment of alveolar osteitis.

- 1) Remove debris from socket and irrigate with chlorhexidine.
- 2) Fill socket with dressing—dry socket paste/eugenol with iodoform gauze.
- 3) Replacement of gauze and/or dressing at 48 hours is recommended.

oral contraceptives, bacterial infection, and age. Presurgical and postoperative rinsing with chlorhexidine has been shown to reduce AO by 50%. Treatment of AO is focused on the management of pain. Irrigation and dressing of the socket will usually eliminate pain within minutes.

## Infection

Most third molar infections occur in the mandible. The most common third molar infection is pericoronitis. A study in the United Kingdom assessed 25,001 third molars. Pericoronitis was the most common indication for extraction and was found in 39.5% of all extractions.<sup>30</sup> Third molar related infections can present prior to surgery or at varying times following surgery. Postoperative infections have been reported to range from 0.8% to 4.2%.<sup>31</sup> Peterson stated that almost all postoperative infections are minor. About 50% of all postoperative infections are localized subperiosteal abscess infections related to the surgical flap. The remaining 50% of postoperative infections rarely require hospitalization.<sup>32</sup> Although hospitalization is rare, serious life-threatening space infections are possible.

### Pericoronitis

Pericoronitis is a localized infection around the crown of an erupting or partially impacted third molar. The infection can be chronic or acute. Chronic pericoronitis may

**Table 3.3** Symptoms and signs consistent with a diagnosis of pericoronitis.

Symptoms	Signs
Increasing pain for 3–4 days	Red, inflamed tissue overlying third molar
Bad odor or taste	Tissue tender to palpation with or without pus
Difficulty chewing, opening, closing, swallowing	Limited opening
Sore throat	Lymph nodes tender to palpation
General feeling of ill health	Increased temperature
Recent or concurrent respiratory infection	Partial eruption—usually vertical or distoangular
Pain when biting teeth together	Super erupted opposing maxillary third molar

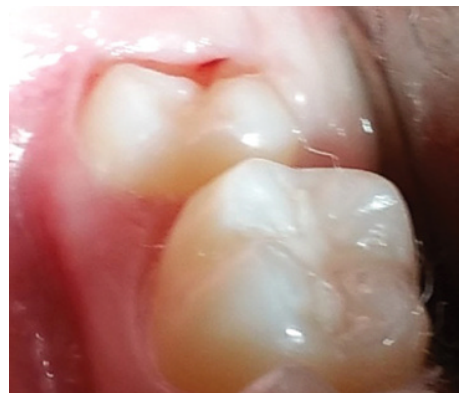exist with mild or no symptoms. Acute pericoronitis is always associated with pain and red, inflamed tissue surrounding the third molar. Both chronic and acute pericoronitis can present with exudate. Patients present with some or all of the following symptoms and signs (see Table 3.3).

The fundamental cause of pericoronitis is bacteria. Oral hygiene access is limited near third molars. Food accumulates under tissue overlying a partially erupted third molar and provides a substrate for bacterial growth (see Figure 3.9).

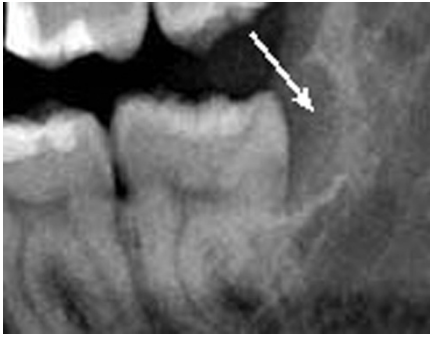
Localized infection can be exacerbated by a super erupted opposing maxillary third molar irritating the area when chewing. Chronic pericoronitis can lead to bone loss (see Figure 3.10). The arrow indicates the position of the tissue covering the distal half of tooth #17.

Acute pericoronitis usually develops endogenous microorganisms during a period of poor oral hygiene or when the immune system is challenged by diabetes, HIV, stress, or infections such as colds, flu, and respiratory tract infections. Meurman et al. collected data from 14,500 male patients to determine if a relationship exists between pericoronitis and respiratory tract infection.<sup>33</sup> The incidence of respiratory tract infection was significantly higher during the two weeks before acute pericoronitis was diagnosed compared with that in controls. The study concluded that a cause and effect relationship exists between pericoronitis and respiratory tract infections. Respiratory tract infection may precipitate acute pericoronitis. Conversely, third molar removal for pericoronitis can trigger respiratory tract infection.<sup>34</sup>

Pericoronitis is usually found in patients under the age of 25 with erupting mandibular third molars. Patients with good oral hygiene and adequate room for eruption can be treated conservatively by irrigation, ultrasonic debridement, and removal of overlying tissue (operculum). Antibiotics are usually not indicated for healthy patients when swelling is absent.



**Figure 3.9** Pericoronitis—food accumulates under tissue overlying the third molar.



**Figure 3.10** Pericoronitis bone loss.

Removal of infected third molars is recommended when patients have poor oral hygiene and inadequate room for eruption. Antibiotics are indicated prior to surgical intervention when patients exhibit significant swelling, lymphadenopathy, fever, or complain of malaise. These signs and symptoms may indicate cellulitis.

It is important to distinguish between cellulitis and abscess. Cellulitis is a diffuse infection spreading through soft tissue fascia. It is a firm, nonfluctuant, painful, indurated area (i.e., warm, red, swollen) of the face or neck. Antibiotics are indicated

for cellulitis to reduce infection prior to surgery. Streptococcus is the most common cause of early stage cellulitis. As the infection progresses, a mixed streptococcal/anaerobic infection develops. As the local tissue condition changes to a more hypoxic state, the predominant bacteria become anaerobic species, such as bacteroides or fusobacterium.<sup>35</sup> An abscess is a localized area of pus that is fluctuant. Incision and drainage is indicated for an abscess.

### Surgical Site Infections (SSIs)

Third molar SSIs are usually caused by normal endogenous microorganisms. Risk factors for SSIs are similar to those for pericoronitis and include the following:

- Medical problems or diseases
- Elderly adults
- Overweight adults
- Smoking
- Cancer
- Weakened immune system
- Diabetes
- Surgery that lasts more than two hours
- Pre-existing infection

The most common third molar SSI is a localized subperiosteal abscess-type infection that occurs 2–4 weeks after a previously uneventful postoperative course. These are usually attributed to debris or food left under the mucoperiosteal flap. The definitive treatment is surgical debridement and drainage.<sup>36</sup> Odontogenic infections are typically polymicrobial; however, anaerobes generally outnumber aerobes by at least fourfold. Metronidazole is a bactericidal agent that is highly active against most anaerobes. In serious infections, metronidazole works well with penicillin or amoxicillin.<sup>37</sup>

The author has treated four patients for subperiosteal infection over 36 years of clinical practice. Each of these patients called the office about one month after an uneventful recovery and complained of unilateral swelling of the lower face. Clinically, intraoral healing appeared normal with no evidence of surgery. However, significant unilateral swelling was noted. One patient was treated by reopening of the mucoperiosteal flap,



debridement, and irrigation followed by antibiotics. The remaining three patients were successfully treated with a combination of amoxicillin 500 mg and metronidazole 500 mg, tid, for 10 days. Although most postoperative infections are minor, a small percentage can be life threatening. Early intervention and treatment is very important to prevent the spread of infection to deep spaces.

### Space Infections

SSIs that progress to deep space infections are rare. However, general knowledge of space infections is needed for accurate diagnosis. SSI infections can spread via blood vessels, lymphatics, or fascial planes. Head and neck spaces can be classified as primary, secondary, and deep neck. Infections involving spaces of the head and neck may give varying signs and symptoms depending upon the space(s) involved. Trismus (difficulty opening the mouth) is a sign that the muscles of mastication are involved. Dysphagia (difficulty swallowing) and dyspnea (difficulty breathing) may be signs that the airway is being compressed by the swelling.

Pus and cellulitis from odontogenic infections move by hydrostatic pressure and will follow the path of least resistance. Most untreated intraoral infections drain through sinus tracts and fistulas. Some infections spread to fascial spaces. Fascial spaces are either pathological spaces (clefts), potential spaces between facial layers, or normal spaces (compartments) containing salivary glands, lymph nodes, blood vessels, nerves, or muscles. The fascia surrounding these spaces is strong and inflexible. Fascial planes offer anatomic highways for infection to spread from superficial to deep planes.<sup>38</sup> Clefts between fascia and structures of the head and neck are created by the pathological spread of infection and do not exist in health. Spaces and planes are defined by bone, fascia, and muscle attachments, especially the mylohyoid, buccinator, masseter, medial pterygoid, superior constrictor, and orbicularis oris muscles.

Spaces of the head and neck can be divided into primary and secondary spaces. Primary spaces are located close to the source of infection. Odontogenic infections spread directly from teeth and bone to primary spaces. The primary spaces are the canine, buccal, vestibular, submandibular, sublingual, and submental. Secondary spaces are located away from the source of infection. Secondary space infections are created by the spread of infection from primary spaces. The secondary spaces are the masticator, pterygomandibular, masseteric, temporal (superficial and deep), infratemporal, prevertebral, lateral pharyngeal, and retropharyngeal. Space infections are summarized in Table 3.4.

Canine space infections originate almost exclusively from a maxillary canine tooth. Canine space infections result in significant swelling lateral to the nose and upper lip that may cause eye closure and drooling. Infections of the canine space can spread hematogenously into the cavernous sinus. This can result in a life-threatening condition known as cavernous sinus thrombosis. Although rare, death from cavernous sinus thrombosis has been reported as a result of third molar removal.<sup>39</sup>

Infections spread to the buccal or vestibular spaces directly from maxillary or mandibular molars. The initial spread of infection is dependent on the attachment of the buccinator muscle in relation to the roots of the molars. Infections from roots inside the buccinator attachment will spread to the vestibular space. Infections outside the buccinator attachment will spread to the buccal space. Infections can spread from these

**Table 3.4** Summary of space infection: origin, signs, and symptoms.

	Origin of Infection	Signs/Symptoms
<b>Primary Spaces</b>		
Canine	Maxillary canine or first premolar	Painful swelling lateral to the nose including loss of the nasolabial fold
Buccal	Maxillary or mandibular 1st, 2nd, and 3rd molars, roots outside buccinator muscle attachment	Painful swelling is ovoid, below the zygomatic arch and above the inferior border of the mandible
Vestibular	Maxillary or mandibular 1st, 2nd, and 3rd molars, roots inside buccinator muscle attachment	Painful swelling of vestibular tissue overlying affected tooth
Submandibular	Mandibular 2nd/3rd molars below mylohyoid muscle	Painful swelling under posterior mandible
Sublingual	Mandibular 1st/2nd molars, premolars above mylohyoid	Painful, firm swelling of the anterior floor of the mouth, difficult to swallow
Submental	Mandibular incisors	Painful swelling under anterior mandible or chin
<b>Secondary Spaces</b>		
Masticator		
● Pterygomandibular	Mandibular 2nd/3rd molars	Significant trismus, pain with no visible swelling
● Masseteric	Mandibular 3rd molars via buccal space	Mild to moderate trismus, swelling of the posterior inferior portion of the mandible
● Temporal (deep and superficial)	Mandibular 3rd molars	Rare infection, trismus, pain, swelling, possible deviation of mandible on opening
<b>Deep Neck Spaces</b>		
Parapharyngeal (lateral pharyngeal)	Mandibular 3rd molars	Trismus, fever, sore throat, dysphagia, swollen neck, mediastinitis, airway obstruction
Retropharyngeal	Mandibular 3rd molars	Trismus, fever, sore throat, dysphagia, swollen neck, mediastinitis, airway obstruction
Prevertebral ("danger space")	Mandibular 3rd molars	Trismus, fever, sore throat, dysphagia, swollen neck, mediastinitis, airway obstruction

spaces to the pterygomandibular space, submasseteric space, deep and superficial temporal spaces, and the lateral pharyngeal space.

Submandibular space infections originate directly from mandibular third molars and second molars that have roots located below the mylohyoid line. Sublingual space infections originate from mandibular first molars, second molars, and premolars that have roots located above the mylohyoid line. Submental space infections arise from

mandibular incisors. The three spaces collectively (submandibular, sublingual, and submental) are sometimes called the submandibular spaces. The submandibular spaces communicate with each other, the masticator space, and deep neck secondary spaces.

Ludwig's angina is a rapidly spreading cellulitis of the submandibular, sublingual, and submental spaces. It produces pronounced swelling, displacement of the tongue, and induration of the submandibular region. Signs and symptoms include trismus, drooling, and dyspnea. Upper airway obstruction can lead to death. The usual cause of Ludwig's angina is an odontogenic infection from a mandibular second or third molar.<sup>40</sup>

There are three secondary spaces of the mandible located near the ramus and angle of the mandible: the masseteric, pterygomandibular, and temporalis secondary spaces. These three spaces are collectively known as the masticator space, because they are bounded by the muscles of mastication: masseter, medial pterygoid, and temporalis. Infections can spread to the masticator spaces from infected mandibular third molars via the buccal, submandibular, and sublingual primary spaces. The masticator spaces communicate with one another and the parapharyngeal, sublingual, and submandibular spaces.<sup>41</sup>

Masseteric space infections are relatively rare. Infection may spread to this space from the buccal space or an infected mandibular third molar (pericoronitis).<sup>42</sup> Infection is characterized by significant trismus and swelling at the inferior posterior portion of the mandible.

The pterygomandibular space may become infected when infection spreads from the submandibular and sublingual spaces or from an infected mandibular third molar (pericoronitis). A key diagnostic feature of pterygomandibular space infections is significant trismus and pain with no swelling.

The third compartment found in the masticator space is the temporal space. The temporal space is posterior and superior to the masseteric and pterygomandibular spaces. It is divided into a superficial and deep portion by the temporalis muscle. The inferior portion of the deep temporal space is the infratemporal space. Infection can spread to the temporal space from adjacent masticator spaces or the infratemporal space. The signs and symptoms of temporal space infections are swelling and trismus.

## Deep Neck Spaces

Authors disagree regarding the number and nomenclature of deep neck spaces. As many as eleven deep neck spaces have been reported in the literature.<sup>43</sup> Three major deep neck spaces are discussed in this section: the parapharyngeal, retropharyngeal, and vertebral. These three deep neck spaces communicate with each other, allowing infection to spread. The parapharyngeal and vertebral spaces are sometimes known as the lateral pharyngeal and "danger space," respectively. Spread within the danger space tends to occur rapidly (hence the name *danger space*) because of the loose areolar tissue that occupies this region.

### 1. Parapharyngeal (Lateral Pharyngeal)

The parapharyngeal space connects with the masticator, retropharyngeal, submandibular spaces and all other deep neck spaces. Parapharyngeal space infections may occlude the airway due to swelling of the posterior pharyngeal wall. Medial displacement of the

lateral pharyngeal wall and tonsil is a hallmark of parapharyngeal space infections. Trismus, drooling, and difficulty swallowing are commonly observed.

## 2. Retropharyngeal

Retropharyngeal infections can extend down to the superior mediastinum, resulting in infections of the pleural cavity and heart. If the infection perforates the posterior border of the retropharyngeal space, it enters the danger space.<sup>44</sup>

## 3. Vertebral (Danger Space)

The vertebral space lies posterior to the retropharyngeal space. The danger space is so called because its loose areolar tissue offers a potential route for the downward spread of infection. The vertebral space extends down the entire mediastinum to the level of the diaphragm. Infections of the danger space most commonly occur when an abscess in the retropharyngeal space ruptures through the retropharyngeal fascia.

Odontogenic origin is the most common etiology of deep space infections in adults.<sup>45</sup> Dentists removing third molars should be aware that deep space infections can be caused by oral surgical procedures. Once diagnosed, deep space and resistant infections should be referred to a maxillofacial surgeon for treatment.

## Bleeding and Hemorrhage

Bleeding is normal following the removal of impacted third molars. Oozing of blood may continue throughout the first day following surgery. It is vital that patients are informed that bleeding should be expected. Patients may have experienced the removal of a single permanent or deciduous tooth and will be unprepared for the amount of blood seen after the removal of four impacted third molars.

Normal postoperative bleeding can be controlled by biting on gauze. The author prefers 4x4 filled gauze. Filled gauze is very absorbent and easier to manage than multiple, unfilled 2x2 gauze. The patient is instructed to avoid talking or moving their mouth for one hour. Patients should remain inactive for the entire day following the procedure. This protocol is sufficient to control bleeding for most patients.

Significant bleeding is most often found in the mandible (80%). Risk factors include older patients, distoangular impactions, and deep impactions near the inferior alveolar neurovascular canal.<sup>46</sup>

Persistent intraoperative bleeding can often be controlled with a vasoconstrictor such as epinephrine 1:100,000. Other alternatives include additional sutures, Gelfoam, Surgicel, ActCel, BloodSTOP, Collaplug, tranexamic acid, and bone wax (see Box 3.3). Arterial, nutrient canal bleeding may require electrocautery or ligation.

Bleeding beyond that expected for the procedure or bleeding that persists beyond the normal time for clot formation, 6–12 hours, is considered excessive.<sup>47</sup> The author has experienced one case of excessive bleeding. A 16-year-old male patient presented for the removal of impacted third molars. His medical and dental history was unremarkable and the procedure was uneventful. The patient's father was given postoperative instructions, verbal and written, and the patient was dismissed. The patient's father called that evening and stated that his son was still bleeding. Postoperative instructions were reviewed and biting on a tea bag was recommended. The patient's father was

**Box 3.3 Hemostatic agents.**

Positive pressure on gauze—4×4 filled	BloodSTOP (LifeScience PLUS)
Vasoconstrictor—epinephrine 1:100,000	ActCel (Coreva Health Sciences)
Tranexamic acid (Pharmacia & Upjohn Company)	Additional sutures
Gelfoam (Pfizer)	CollaPlug (Integra Life Sciences)
Surgicel (Johnson & Johnson)	Bone Wax (Ethicon)

instructed to call again if there was no improvement within two hours. A phone call was received at 11:30 pm stating that there was no improvement and the patient was still bleeding. The patient was instructed to drink lots of water, continue to bite on gauze or tea bag, and come to the office in the morning at 8:00 a.m.

The patient was still bleeding when he arrived at the office. Gauze (4x4) was changed every half hour for two hours with no improvement. The patient was referred to the local emergency room and was later admitted to the hospital to conduct bleeding tests. The patient was diagnosed with von Willebrand disease, an abnormality of the coagulation cascade. Von Willebrand factor (vWF) promotes normal platelet function and stabilizes factor VIII.

It was later discovered that the patient had a history of hematoma in his thigh sustained while playing soccer. This was unreported on his medical history and preoperative assessment. This case clearly illustrates the importance of a thorough preoperative medical history, interview, and assessment to rule out bleeding disorders. Patients with coagulation disorders may be identified by questions regarding personal or familial history of bleeding and bruising. Preoperative assessment of intrinsic coagulation disorders and the use of anticoagulant and antiplatelet medications (Coumadin, Plavix) is essential.<sup>48</sup>

Tranexamic acid is an antifibrinolytic chemical that has been used successfully to treat and prevent excessive bleeding following surgical procedures for patients on anticoagulants. Ramstrom et al. studied the hemostatic effect of tranexamic acid solution (4.8%) used as a mouthwash compared with a placebo solution in 93 patients on continuous, unchanged, oral anticoagulant treatment undergoing oral surgery. In the placebo group, 10 patients developed bleeding requiring treatment, while none of the patients treated with tranexamic acid solution had bleeding. It was concluded that most patients on oral anticoagulants can undergo oral surgery within the therapeutic range (INR 2.10–4.00) without reducing the dosage of anticoagulants, provided that local antifibrinolytic treatment with tranexamic acid solution is instituted.<sup>49</sup> Patients should be instructed to rinse with 10 ml four times daily for seven days following surgery.<sup>50</sup>

The level of the impaction and its proximity to the neurovascular bundle are the most important risk factors for excessive bleeding. Excessive bleeding has been reported to occur more frequently with the extraction of mandibular third molars versus their maxillary counterparts. Excessive bleeding is more frequent, regardless of the type of impaction, for inexperienced surgeons. It is also more commonly reported in older patients, probably because of vascular fragility and less effective coagulation mechanisms. It is reported that men are as much as 60% more likely to suffer from excessive bleeding than women.<sup>51</sup> Hypovolemia and deep space hematomas are potentially fatal. Symptoms of hypovolemic/hemorrhagic shock may appear with blood loss near 1000 ml (see Box 3.4).

**Box 3.4 Symptoms of hemorrhagic shock.**

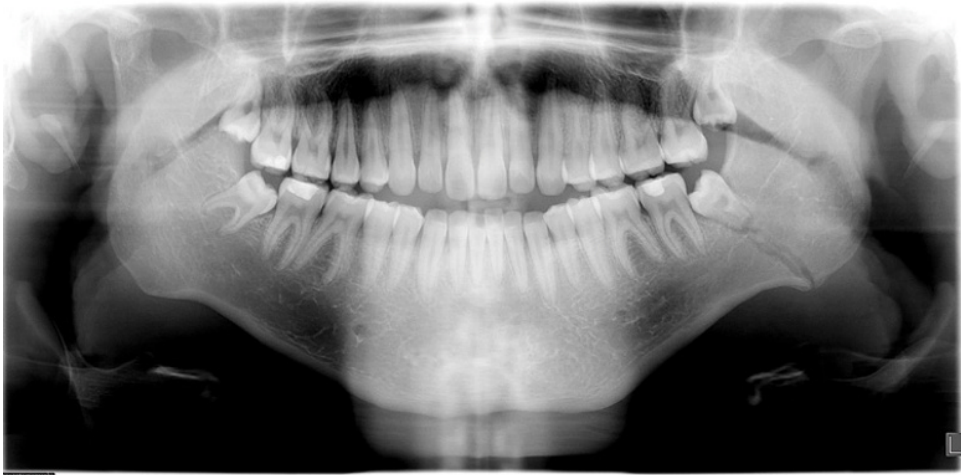Anxiety or agitation	Cool, clammy skin
Confusion	Decreased or no urine output
General weakness	Unconsciousness
Pale skin color (pallor)	Sweating, moist skin
Rapid breathing	

Most studies have found that blood loss from dental surgeries is less than 200 ml. To put this in perspective, a blood donation of one pint is 473 ml.<sup>52</sup> Dentists removing impacted third molars should keep in mind that long procedures increase the possibility of excessive blood loss. Uncontrollable intraoral hemorrhage can quickly lead to airway compromise either because of an expanding hematoma in the neck or from blood pooling in the airway.<sup>53</sup> The possibility of uncontrolled hemorrhage when treating healthy patients is remote. However, dentists removing impacted third molars should be aware that excessive bleeding can be fatal.

## Jaw Fracture

One of the most severe complications from third molar surgery is mandibular fracture (see Figure 3.11).

Mandibular fractures resulting from third molar removal are extremely rare. Fractures can occur at the time of surgery or can be delayed. Libersa et al. found mandibular fractures during or after the removal of third molar to occur in 0.00049% of cases.<sup>54</sup> This complication is very serious, especially when it includes nerve injury. Uncontrolled force and deep impactions are the common denominators in surgically related jaw



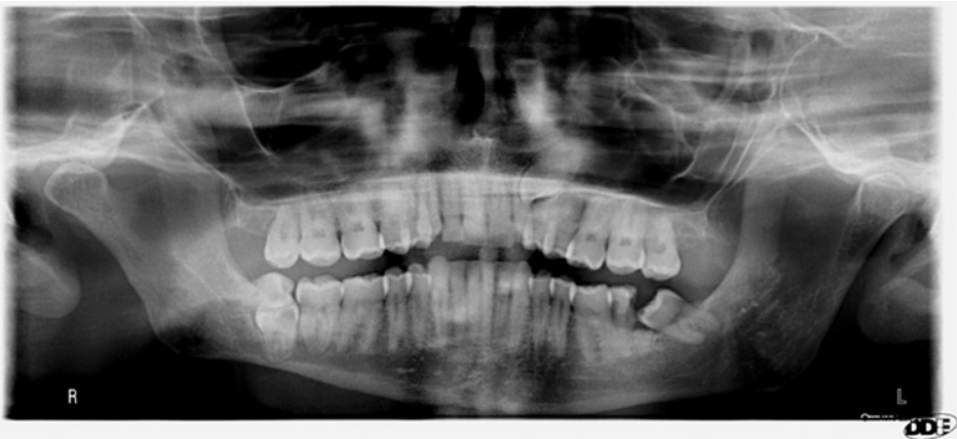**Figure 3.11** Fracture of the mandible near a third molar. *Source:* Courtesy of Dr. Joanne Toy.

fractures. Experienced surgeons can usually remove deeply impacted third molars without fracture (see Figure 3.12a and 3.12b), but even the most experienced oral surgeons may experience this complication when removing deep impactions. Mandibular fracture is a serious complication that can lead to litigation. It should be included in consent forms and discussed with all patients presenting with deep third molar impactions near the inferior border of the mandible.

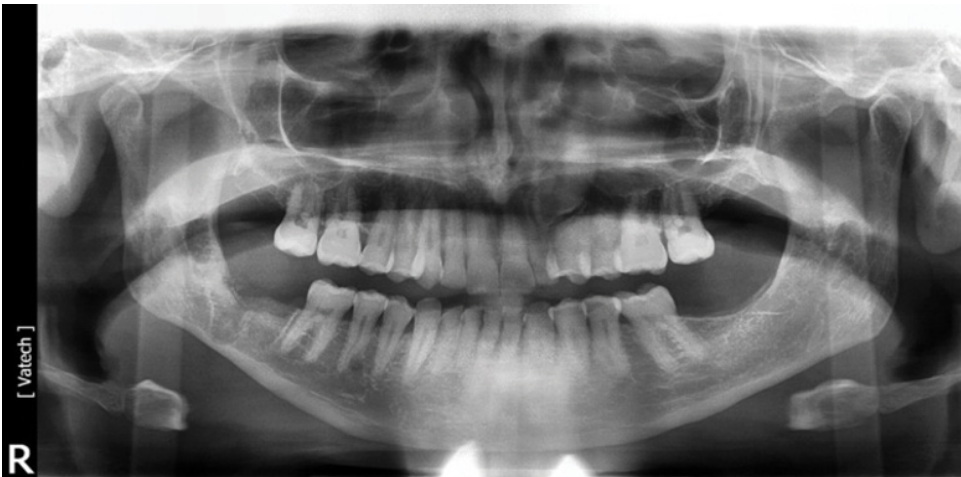Some studies have shown older patients as a risk factor for jaw fracture.<sup>55</sup> Mandibular fractures may be stabilized with open reduction, closed reduction, or soft diet depending on the severity of the fracture and the direction of muscle pull.

The most common jaw fracture is maxillary tuberosity fracture. The distal aspect of maxillary third molars has no support and the bone is soft osteoporotic bone. The maxillary sinus may compromise bone support. These factors combined with excessive force

(a)



(b)



**Figure 3.12** (a) #32 Deep impaction preoperative panograph. (b) #32 Deep impaction postoperative panograph. *Source:* Courtesy of Dr. Vincent Vella.

**Box 3.5 Options to prevent tuberosity fracture.**

Preoperative radiographs	Periosteal elevator dissection
Pinch grip feedback	Tooth sectioning
Bone removal	Elevator and forceps combination

make this area subject to fracture. A fractured tuberosity with good blood supply, attached to periosteum, can be repositioned and monitored. Tuberosity fracture may be accompanied by mucosal tears. In this case, sutures are required to hold the fractured bone in place.

Several options are available to prevent tuberosity fracture (see Box 3.5). Preoperative radiographs can be used to evaluate bone thickness, periodontal ligament space, and proximity of the maxillary sinus. A periosteal elevator can be placed distal to the third molar to separate it from the periodontal ligament and tuberosity. A “pinch grip,” grasping the alveolus between thumb and index finger of the nondominant hand, can be used while applying force. This technique provides tactile feedback to the operator regarding tooth movement and bone fracture. Finally, the tooth can be sectioned and bone judiciously removed to prevent fracture.

Tuberosity fracture may be unavoidable when removing impacted maxillary third molars. However, in most cases, the mobile fractured bone has a good blood supply and remains attached to periosteum.

## Osteomyelitis

Osteomyelitis (OM) is an inflammatory condition of bone marrow that may be classified as acute, chronic, or suppurative. Acute osteomyelitis is OM that has been present for less than one month. The infection is considered chronic when the condition lasts for more than a month.<sup>56</sup> Osteomyelitis infections with the formation of pus may be classified as suppurative.

Suppurative osteomyelitis of the jaws is uncommon in developed countries. There have been many reported cases occurring in Africa that are coexistent with acute necrotizing ulcerative gingivitis. In the preantibiotic era, acute OM of the jaws was more extensive. Massive, diffuse infections commonly involved the whole side of the mandible. Before antibiotics, OM was a common complication of odontogenic infections, frequently ending in death.

Osteomyelitis of the jaws occurs in the bones of the maxilla and mandible but is most common in the mandible due to limited blood supply from the inferior alveolar neurovascular bundle. In Europe and the United States, most cases follow dental infections, extractions, or mandibular fractures in patients with compromised host defenses. OM may occur as result of contamination of a surgical site.

Diabetes, alcoholism, autoimmune disease, radiation therapy, chemotherapy, steroid use, osteoporosis, myeloproliferative diseases, and malnutrition can contribute to the development of osteomyelitis. Patients with acute osteomyelitis often present with dull deep pain, fever, malaise, swelling, fistula, and trismus. In contrast, patients with chronic



osteomyelitis often present without the symptoms of acute osteomyelitis. Radiographs may have a “moth eaten” pattern of bony sequestrum.<sup>57</sup>

## Damage to Proximal Teeth

Clinical and radiographic evaluation of the patient is essential to avoid damage to proximal teeth when removing third molars. Patients should be informed prior to the procedure of possible injury to adjacent teeth. Second molar teeth with large restorations, crowns, or caries may be damaged during the removal of third molars. Complications include displacement of restorations and crowns, fractured restorations and crowns, and fracture of adjacent teeth weakened by large restorations or caries. Judicious bone removal and meticulous technique that avoids contact with these structures is necessary. Fortunately, displaced or fractured restorations and crowns can normally be replaced.

Second molar teeth with short, conical roots may be accidentally loosened or avulsed. Teeth that are minimally loosened can often be repositioned and left alone. Seriously loosened or avulsed teeth should be repositioned and stabilized for 10–14 days with the least rigid fixation possible to prevent ankylosis and root resorption.<sup>58</sup>

## Buccal Fat Pad Exposure

The buccal fat pad is located bilaterally between the buccinator muscle, masseter muscle, and ramus. It consists of a central body and four extensions; buccal, pterygoid, superficial, and deep temporal. The buccal extension is located superficially within the cheek. Deep incisions distal to the maxillary tuberosity may cause herniation of the buccal extension (see Figure 3.13).

The unexpected herniation of the buccal fat pad is alarming. However, this complication is typically innocuous. The buccal fat pad is frequently used to repair small and medium intraoral defects such as oral antral fistulas. Exposed buccal fat is epithelialized within 2–3 weeks.<sup>59</sup>

The exposed fat should be repositioned if possible, although this is analogous to replacing toothpaste back into the toothpaste tube. The procedure should be terminated and the patient rescheduled for removal of the third molar. Experienced surgeons may be able to work around the defect and complete the procedure.

## Oral-Antral Communication

The most common molar involved with a sinus communication is the first molar, followed by the second molar

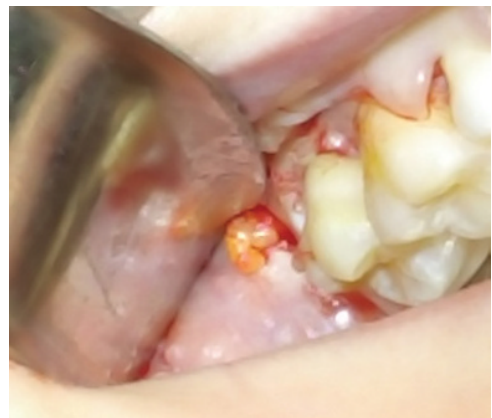

Figure 3.13 Buccal fat pad herniation.

and third molar. Removal of maxillary third molars with roots near the maxillary sinus can result in an oral-antral communication (OAC) between the oral cavity and sinus. An opening into the maxillary sinus that does not epithelialize may become a permanent communication known as an oral-antral fistula.

OAC is diagnosed by applying the Valsalva maneuver used by divers to “clear their ears.” The patient’s nose is pinched shut and the patient is instructed to gently blow their nose. Air passing through an opening can be heard and seen as bubbles of blood and fluid are expressed. This is diagnostic for an OAC. Alternatively, a mouth mirror can be held next to the extraction site and the Valsalva maneuver performed. The mirror will fog if an opening is present.

Openings less than 2 mm in diameter usually close spontaneously.<sup>60</sup> Furthermore, impacted maxillary third molar flaps usually cover the extraction site and aid in closure. Intermediate size openings of 2–7 mm may be treated with a collagen plug or Gelfoam placed in the socket. A figure 8 suture will help to stabilize socket dressings and the clot. Openings greater than 7 mm and oral-antral fistulas generally require surgical repair by an oral and maxillofacial surgeon.

Postoperative instructions, written and oral, should be given to any patient diagnosed with OAC. The condition should be explained to patients in terms that are easy to understand. Patients are instructed to not blow their nose and to sneeze with their mouths open for two weeks. Medications include antibiotics, nasal decongestants, and an antihistamine. Amoxicillin is recommended for five days to prevent the development of sinusitis. Sudafed, a nasal decongestant, is used for two weeks to open nasal passages. An antihistamine nasal spray such as Neo-Synephrine or Afrin should be used for two weeks to reduce sneezing and nose blowing (see Box 3.6).

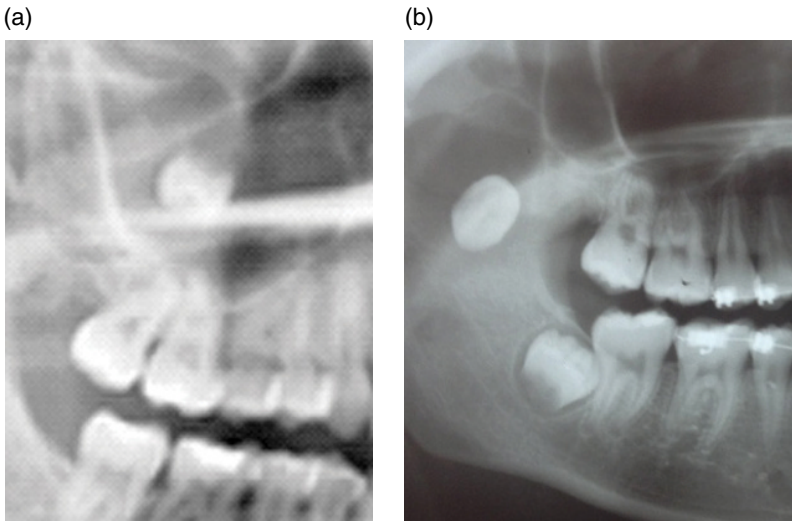
Careful assessment of radiographs can reduce the incidence of OAC when removing impacted third molars. Older patients with dense bone, divergent roots, and sinus pneumatization around roots are red flags. These teeth should be carefully luxated and sectioned to minimize the chance of an OAC.

## Displacement of Third Molars

Third molars and their roots can be displaced into adjacent spaces during removal. This is a rare complication associated with deep impactions, poor access and visualization, and uncontrolled forces. Maxillary third molars or their roots can be displaced into the maxillary sinus or infratemporal fossa (see Figures 3.14a and 3.14b). These teeth may develop palatal to the maxillary arch. This position predisposes displacement into the

### Box 3.6 Oral-antral communication postoperative instructions.

Amoxicillin 500 mg, tid, until gone, #30  
Decongestant (Sudafed)—for two weeks  
Antihistamine (Neo-Synephrine or Afrin)  
Do not blow your nose for two weeks  
Sneeze with your mouth open for two weeks  
Avoid smoking and straws



**Figure 3.14** (a) Third molar in maxillary sinus. (b) Third molar in infratemporal fossa. *Source:* Cassio, 2005. [http://www.scielo.br/scielo.php?pid=0103-644020050002&script=sci\\_issuetoc](http://www.scielo.br/scielo.php?pid=0103-644020050002&script=sci_issuetoc). CC BY-NC 4.0.

maxillary sinus and infratemporal fossa. Access and visualization of third molars in this position are often restricted. Poor access, excessive apical force, and poor technique increase the chance of displacement into the maxillary sinus or infratemporal fossa.

The maxillary sinus is an empty space that contains no vital structures. Pogrel has recommended suction through the oral-antral communication to retrieve teeth displaced into the maxillary sinus. A second attempt can be made with irrigation of the sinus followed by suction. Pogrel states that a third attempt should not be made and the patient should be placed on antibiotics and nasal decongestant.<sup>61</sup> The patient should be referred to a maxillofacial surgeon and the tooth retrieved via the Caldwell-Luc approach. The oral-antral communication can be closed at the same appointment.

The infratemporal fossa is located posterior to the maxilla, lateral to the lateral pterygoid plate, and inferior to the lateral pterygoid muscle. Displacement of maxillary third molars into the infratemporal fossa is a rarely reported complication with an unknown incidence. This complication is far more serious than displacement into the maxillary sinus. In contrast to the maxillary sinus, the infratemporal fossa is not an empty space. It contains vital structures including the pterygoid plexus, maxillary artery, and mandibular nerve (the third branch of the trigeminal nerve). Treatment of this complication is varied and depends on the position of the tooth, experience of the surgeon, and patient's wishes. Treatment choices include intraoral retrieval, extraoral retrieval, and observation. A CT scan is ordered to localize the exact position of the tooth. Retrieval is hindered by poor visualization and bleeding from the pterygoid plexus.<sup>62</sup> Treatment may be immediate to avoid infection or delayed to allow for development of fibrous tissue around the tooth. Fibrous tissue may aid in retrieval of the tooth.

The author has had one displacement of a right maxillary third molar into the infratemporal fossa. The patient, a 15-year-old male with orthodontic arch wires in place, was referred by his orthodontist for removal of developing (germectomy) third molars. In addition to the orthodontic appliances, the patient had a small mouth with

limited opening. The right maxillary third molar was located and visualized near the apices of the second molar and in a palatal position. Gentle force was applied to the tooth when it suddenly disappeared.

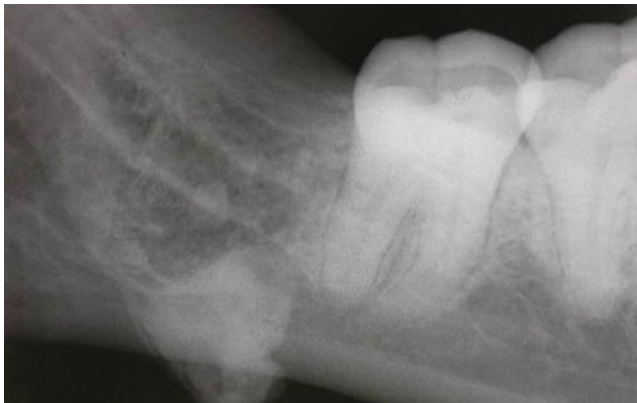A panoramic X-ray was taken that confirmed location of the third molar in the infratemporal fossa. The patient was referred to the UCSF Department of Maxillofacial Surgery where he was seen several times over a period of three months. Cone beam CT images were taken and the patient was monitored for symptoms of pain or signs of infection. Fortunately, the patient was asymptomatic and no treatment was recommended.

Factors increasing the potential for maxillary third molar displacement include deep (high) impactions with the crown near the apices of the second molar, palatal location, distoangular position, and poor access and visualization (see Box 3.7). A good axiom to remember when removing maxillary impacted third molars is, “A difficult maxillary third molar will be much more difficult than a difficult mandibular third molar.”

Mandibular third molars or their roots can also be displaced into the submandibular, sublingual, and pterygomandibular spaces (see Figure 3.15). In addition, the roots of mandibular third molars can be displaced into the inferior alveolar canal. The lingual cortical plate is often thin or nonexistent in the posterior region of the mandible. Fenestrations of the lingual plate can be found on the lingual aspect of some impacted mandibular third molars.<sup>63</sup>

**Box 3.7 Factors affecting the potential for maxillary third molar displacement.**

Deep impactions  
Palatal location  
Distoangular position  
Poor access  
Poor visualization



**Figure 3.15** Third molar in submandibular space. Source: Kamburoglu, <https://casesjournal.biomedcentral.com/articles/10.1186/1757-1626-3-8>. CC BY 2.0.

The submandibular space is located below the mylohyoid muscle. The sublingual space is located above the mylohyoid muscle. Displacement of third molar teeth or roots into these spaces can sometimes be prevented by finger pressure on the lingual periosteum, inferior to the third molar roots, prior to applying force. The procedure should be stopped whenever access and direct vision is impaired. Open flaps and bone removal may be needed to improve visibility when third molar teeth are moving in an apical, lingual direction. Care should be taken to not displace the tooth or roots deeper into the space. Displaced roots can sometimes be manipulated back into their socket with lingual finger pressure. Patients should be referred to a maxillofacial surgeon when these attempts are unsuccessful.

A root tip or tooth fragment can be left in the tooth socket if it is less than 5 mm in length and is not infected or palpable. Baseline X-rays should be taken and the patient should be informed of the possibility of infection. The patient should be monitored for deep space infection or foreign body reaction.<sup>64</sup>

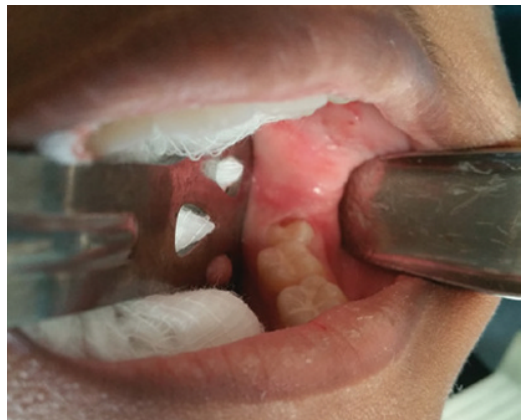## Aspiration and Ingestion

Aspiration and ingestion is probably under reported. Approximately 92.5% of objects are ingested while 7.5% are aspirated.<sup>65</sup> This complication can be prevented by using 4x4 gauze throat packs. A pharyngeal curtain can be created by gently rolling this gauze into a soft ball and placing it above the patient's oropharyngeal airway. A Weider retractor can be used to hold the gauze in position and create a clean surgical field (see Figure 3.16).

The 4x4 gauze will completely block openings to the pharynx and patient's airway. Filled gauze is more absorbent than nonfilled gauze. The assistant should be trained to suction close to the surgical site and to alert you if openings are visible around the gauze. A large-bore surgical suction is recommended to increase suction and rapidly remove fluid, pieces of tooth, or entire teeth after removal.

Cough and gag reflexes of sedated patients are obtunded. These patients are more likely to aspirate or ingest objects. The pharyngeal curtain is especially important for

**Figure 3.16** Weider retractor and 4×4 filled gauze pharyngeal screen.



sedated patients. A decrease in oxygen saturation without coughing or gag reflex may indicate aspiration or ingestion. HVE suction should be used in an attempt to remove the object and ACLS protocol initiated. The Heimlich maneuver should be used to dislodge the object. If this is unsuccessful, EMS should be called. If the patient becomes cyanotic and unconscious, advanced airways or cricothyrotomy should be considered. Patients should be transported to the emergency room to remove objects that have passed through the vocal cords.

## Temporomandibular Joint Injury

Temporomandibular joint (TMJ) injury as a result of third molar surgery is not supported by the literature. Threlfall et al. found that patients diagnosed with anterior disc displacement with reduction were no more likely to have undergone third molar removal than controls. The data did not exclude the possibility that long, traumatic procedures or procedures with general anesthesia could increase the risk of developing TMJ symptoms.<sup>66</sup>

Normal surgical protocol requires the use of a bite block and support of the patient's jaw during the removal of mandibular third molars. Unusual apical force with elevators without supporting the patient's jaw is not recommended.

## Complications Summary

The possibility of surgical complications during and after the removal of impacted third molars can be intimidating for the untrained dentist. However, it should be emphasized that the majority of complications discussed in this chapter are rare. The four most common postoperative complications of third molar extraction reported in the literature are alveolar osteitis, paresthesia, infection, and bleeding/hemorrhage. These four complications can be virtually eliminated with proper case selection and good surgical technique.

The author has removed more than 25,000 impacted third molars, including thousands of germectomies. Approximately 90% of these patients were teenagers. The remaining 10% included a variety of ages and surgical risk. Complications included 13 temporary inferior alveolar nerve injuries, 4 subperiosteal infections, 2 alveolar osteitis infections, and 2 displaced teeth. These complications represent a percentage that is much lower than what is found in the literature. All of the nerve injury patients were more than 20 years old. Age is a major factor in case selection and avoiding surgical complications.

## References

- 1 Bui CH, Seldin EB, Dodson TB. Types, frequencies, and risk factors for complications after third molar removal. *J Oral Maxillofac Surg.* 2003;61(12):1379–89.
- 2 Bouloux GE, Steed MB, Perciaccante VJ. Complications of third molar surgery. *Oral Maxillofac Surg Clin North Am.* 2007 Feb;19(1):117–28.

- 3 Meshram VS, Meshram PV, Lambade P. Assessment of nerve injuries after surgical removal of mandibular third molar: a prospective study, *Asian J Neurosci.* 2013; Article ID 291926.
- 4 Alves N. Study of descendent course of buccal nerve in adult individuals. *Int J Morphol.* 2009;27(2):295–8.
- 5 MacGregor AJ. *The impacted lower wisdom tooth.* New York: Oxford University Press, 1985.
- 6 Merrill RG. Prevention, treatment, and prognosis for nerve injury related to the difficult impaction. *Dent Clin North Am.* 1979;23:471–88.
- 7 Carmichael FA, McGowan DA. Incidence of nerve damage following third molar removal: a West of Scotland Surgery Research Group study. *British J Oral Maxillofac Surg.* 1992;30:78.
- 8 Sarikov R, Juodzbaly G. Inferior alveolar nerve injury after mandibular third molar extraction: a literature review, *J Oral Maxillofac Res* 2014;5(4):e1.
- 9 Levine MH, Goddard AL, Dodson TB. Inferior Alveolar nerve canal position: a clinical and radiographic study. *J Oral Maxillofac Surg.* 2007;65(3):470–4.
- 10 Howe J, Poyton H. Prevention of damage to the inferior alveolar dental nerve during the extraction of mandibular third molars. *Br Dent J.* 1960;109:355.
- 11 Valmeseda-Castellon E, Berini-Aytes L, Gay-Escoda C. Lingual nerve damage after third molar extraction. *Oral Surg Oral Med Oral Pathol Oral Radiol Endod.* 2000;90:567–73.
- 12 Graff-Radford SB, Evans RW. Disclosures. *Headache.* 2003;43(9).
- 13 Blackburn CW, Bramley PA. Lingual nerve damage associated with the removal of lower third molars. *Br Dent J.* 1989;167(3):103–7.
- 14 Karakas P, Üzel M, Koebke J. The relationship of the lingual nerve to the third molar region using radiographic imaging. *Br Dent J.* 2007;203:29–31.
- 15 Bui CH, Seldin EB, Dodson TB. Types, frequencies, and risk factors for complications after third molar removal. *J Oral Maxillofac Surg.* 2003;61(12):1379–89.
- 16 Gargallo-Albiol J, Buenechea-Imaz R, Gay-Escoda C. Lingual nerve protection during surgical removal of lower third molars: a prospective randomised study. *Int J Oral Maxillofac Surg* 2000;29(4):268–71.
- 17 Zuniga JR, Management of third molar-related nerve injuries: observe or treat? *Alpha Omegan.* 2009;102(2):79–84.
- 18 Cheung LK, Leung YY, Chow LK, Wong MCM, Chan EKK, Fok YH. Incidence of neurosensory deficits and recovery after lower third molar surgery: a prospective clinical study of 4338 cases. *Int J Oral Maxillofac Surg.* 2010;39(4):320–6.
- 19 Bataineh AB, Sensory nerve impairment following mandibular third molar surgery. *J Oral Maxillofac Surg.* 2001;59(9):1012–7.
- 20 Meshram VS, Meshram PV, Lambade P. Assessment of nerve injuries after surgical removal of mandibular third molar: a prospective study, *Asian J Neurosci.* 2013; Article ID 291926.
- 21 Seddon HJ. Classification of nerve injuries. *Br Med J.* 1942;2:237.
- 22 Sunderland S. A classification of peripheral nerve injuries producing loss of function. *Brain.* 1951;74(4):491–516.
- 23 Kolokythas A, Eliza Olech E, Michael Miloro M. Alveolar osteitis: a comprehensive review of concepts and controversies. *Int J Dent.* 2010;249073.

- 24 Blum IR. Contemporary views on dry socket (alveolar osteitis): a clinical appraisal of standardization, aetiopathogenesis and management: a critical review. *Int J Oral Maxillofac Surg.* 2002;31(3):309–17.
- 25 Larsen PE. The effect of a chlorhexidine rinse on the incidence of alveolar osteitis following the surgical removal of impacted mandibular third molars. *J Oral Maxillofac Surg.* 1991;49(9):932–37.
- 26 Shepherd J. Pre-operative chlorhexidine mouth rinses reduce the incidence of dry socket. *Evid Based Dent.* 2007;8(2):43.
- 27 Renton T, Al-Haboubi M, Pau A, Shepherd J, Gallagher JE. What has been the United Kingdom's experience with retention of third molars? *J Oral Maxillofac Surg.* 2012;70(Suppl 1):48–57.
- 28 Dodson TB. The management of the asymptomatic, disease-free wisdom tooth: removal versus retention (Review). *Atlas Oral Maxillofac Surg Clin North Am.* 2012;20(2):169–76.
- 29 Rango JR, Szkutnik AJ. Evaluation of 0.12% chlorhexidine rinse on the prevention of alveolar osteitis. *Oral Surg Oral Med Oral Pathol Oral Radiol, Endod.* 1991;72:524–6.
- 30 Worrall SF, Riden K, Haskell R, Corrigan AM. UK National Third Molar Project: the initial report. *Br J Oral Maxillofac Surg.* 1998;36(1):14–8.
- 31 Bouloux GF, Steed MB, Perciaccante VJ. Complications of third molar surgery. *Oral Maxillofac Surg Clin North Am.* 2007;19(1):117–28.
- 32 Miloro M., editor. *Peterson's principles of oral and maxillofacial surgery*, 2nd edition. London: B.C. Decker, Inc. 2004.
- 33 Meurman JH, Rajasuo A, Murtomaa H, Savolainen S. Respiratory tract infections and concomitant pericoronitis of the wisdom teeth. *BMJ.* 1995;310(6983):834–6.
- 34 Miloro M., editor. *Peterson's principles of oral and maxillofacial surgery*, 2nd edition. London: B.C. Decker, Inc., 2004; chap. 69.
- 35 Sandor GKB, Low DE, Judd PL, Davidson RJ. Antimicrobial treatment options in the management of odontogenic infections. *J Can Dent Assoc.* 1998;64(7):508–14.
- 36 Miloro M., editor. *Peterson's principles of oral and maxillofacial surgery*, 2nd edition. London: B.C. Decker, Inc. 2004.
- 37 Odell W. *Clinical problem solving in dentistry*, 3rd edition. Edinburgh: Churchill Livingstone, 2010: 151–3, 229–33.
- 38 Palmersheim LA, Hamilton MK. Fatal cavernous sinus thrombosis secondary to third molar removal. *J Oral Maxillofac Surg.* 1982 Jun;40(6):371–6.
- 39 Miloro M., editor. *Peterson's principles of oral and maxillofacial surgery*, 2nd edition. London: B.C. Decker, Inc., 2004: chap. 69.
- 40 Dhali I. Spread of oral infections. Retrieved online at [www.slideshare.net](http://www.slideshare.net). 2011 Feb 19.
- 41 Hupp JR, Ellis E, Tucker MR. *Contemporary oral and maxillofacial surgery*, 5th ed. St. Louis: Mosby Elsevier, 2008: 317–33.
- 42 Murray AD et al. Deep neck infections. *Medscape.* 2014 March 28.
- 43 Murray AD et al. Deep neck infections. *Medscape.* 2014 March 28.
- 44 Pinto A, Scaglione M, Scuderi MG, Tortora G, Daniele S, Romano L. Infections of the neck leading to descending necrotizing mediastinitis: Role of multi-detector row computed tomography. *Eur J Radiol.* 2008;65:389–94.
- 45 Smith JK, Armao DM, Specter BB, Castillo M. Danger space infection: infection of the neck leading to descending necrotizing mediastinitis. *Emerg Radiol.* 1999;6:129–32.
- 46 Potoski M, Amenabar JM. Dental management of patients receiving anticoagulation or antiplatelet treatment. *J Oral Sci.* 2007;49(4):253–8.



- 47 Srinivas M, Susarla BS, et al. Third molar surgery and associated complications. *Oral Maxillofac Surg Clin N Am.* 2003;15:177–86.
- 48 Ramström G, Sindet-Pedersen S, Hall G, Blombäck M, Alander, Prevention of postsurgical bleeding in oral surgery using tranexamic acid without dose modification of oral anticoagulants, *U J Oral Maxillofac Surg.* 1993 Nov;51(11):1211–6.
- 49 Bandrowsky T, Vorono A, Borris T, Marcantoni H. Amoxicillin-related postextraction bleeding in an anticoagulated patient with tranexamic acid rinses. *Oral Surg Oral Med Oral Pathol Oral Radiol Endod.* 1996;82(6):610–2.
- 50 de Boer MP, Raghoobar GM, Stegenga B, et al. Complications after mandibular third molar extraction. *Quintessence International.* 1995;26:779–84.
- 51 Baab D, Ammons W, Selipsky H. Blood loss during periodontal flap surgery. *J Periodontol.* 1977;48(11):693–8.
- 52 Hassan G, Moghadam, Marco F, Caminiti, Life-threatening hemorrhage after extraction of third molars: case report and management protocol. *J Can Dent Assoc.* 2002;68(11):670–4.
- 53 Libersa P, Roze D, Cachart T, et al. Immediate and late mandibular fractures after third molar removal. *J Oral Maxillofac Surg.* 2002;60:163–5.
- 54 Krimmel M, Reinert S. Mandibular fracture after third molar removal. *J Oral Maxillofac Surg.* 2000;58:1110–2.
- 55 Hudson JW. Osteomyelitis and osteoradionecrosis. In: Fonseca RJ, editor. *Oral and maxillofacial surgery*, Vol 5. Philadelphia: W.B. Saunders; 2000.
- 56 Marx RE. Chronic osteomyelitis of the jaws. *Oral Maxillofac Surg Clin North Am.* 1991;24(2):367–81.
- 57 Schlieve T, Kolokythas A, Miloro M. Third molar surgery. In: Miloro M., Kolokythas A, editors. *Management of complications in oral and maxillofacial surgery*, 1st edition. Hoboken, NJ: Wiley-Blackwell, 2012: 25–40.
- 58 Samman N, Cheung LK, Tideman H. The buccal fat pad in oral reconstruction. *Int J Oral Maxillofac Surg.* 1993;22(1):2–6. doi:10.1016/S0901-5027(05)80346-7.
- 59 Schuchardt K. Treatment of oro-antral perforations and fistulae. *Int Dent J.* 1955;5.
- 60 Sverzut CE, Trivellato AE, Lopes LME, Ferraz EP, Sverzut AT. Accidental displacement of impacted maxillary third molar: a case report. *Braz Dent J.* 2005;16(2).
- 61 Pogrel M. Complications of third molar surgery. *Oral Maxillofac Surg Clin North Am.* 1990;2:441.
- 62 Oberman M, Horowitz I, and Ramon Y., Accidental displacement of impacted maxillary third molars. *Int J Oral Maxillofac Surg.* 1986;15:756–8.
- 63 Tumuluri V, Punnia-Moorthy, A. Displacement of a mandibular third molar root fragment into the pterygomandibular space. *Australian Dent J.* 2002;47:(1):68–71.3.
- 64 Nusrath MA, Banks RJ. Unrecognised displacement of mandibular molar root into the submandibular space. *Brit Dent J* 2010;209(6).
- 65 Peterson LJ. Prevention and management of surgical complications. In: *Contemporary oral and maxillofacial surgery*, 4th edition. St Louis: CV Mosby, 2003.
- 66 Bouloux GF, Steed MB, Perciaccante VJ. Complications of third molar surgery. *Oral Maxillofac Surg Clin North Am.* 2007 Feb;19(1):117–28, vii.



## 4

### Work Space

#### Equipment, Instruments, and Materials

The work space of the general dentist and oral surgeon are similar but with important differences. General dentists often sit in a relatively static position for long periods of time; oral surgeons usually work standing and are frequently moving to improve access, visualization, and the application of force. The oral surgeon's work space is usually larger than the general dentist's. General dentists place instruments on a small, movable instrument tray; oral surgeons place instruments on a large surgical table positioned directly over a fully reclined patient. Visualization is critical for both dentists and surgeons, but good visualization is somewhat more important for the surgeon who frequently works near vital structures. Finally, the equipment, instruments, and materials used by the oral surgeon are often different from those used by the general dentist.

In the ADA's Health Screening Program of 2012, 56.4% of participating dentists had musculoskeletal symptoms. Thirty-seven percent were working 15 to 30 years. Thirty percent had symptoms over 10 years. Seventy-nine percent had symptoms that were worsening or unchanging. Forty-four percent believed that their pain was due to repetitive actions during work. Sixty-one percent of the currently practicing dental professionals reported regularly experiencing pain, tingling, or numbness. The most commonly reported symptoms were located in the back (51.0% reported) and neck (51.1%).<sup>1</sup> A good, ergonomically designed operator with equipment that is supportive to the practitioner, while allowing easy access to the oral cavity, can help to avoid these injuries.<sup>2</sup>

According to the International Standards Organization, the following actions can improve work space ergonomics and reduce musculoskeletal disorders:<sup>3</sup>

Adapt work space and equipment to account for operator and work being performed with preferred body postures.

- 1) Provide sufficient space for body movements.
- 2) Provide variety in tasks and movements to avoid static muscle tension caused by postural constraints.
- 3) Design work to allow machinery to do and assist highly repetitive tasks.
- 4) Avoid extreme posture when exerting high force.

Compliance with these recommendations is possible when a dentist performs exodontia from the standing position. In a seated position the pressure in the lumbar discs increases by 50% as compared to standing.<sup>4</sup>

Work space ergonomics can be significant for the general dentist whose practice has a heavy emphasis on exodontia and the removal of impacted third molars. The ergonomic

demands of exodontia require a large operatory with room to move. Flat surfaces are needed for surgical motors, irrigation pumps, instruments, and materials. Surgical tables and chairs, loupe magnification, and loupe lighting improve efficiency, quality of treatment, and ergonomics.

## Equipment

### Surgical Tables and Chairs, Magnification, and Lighting

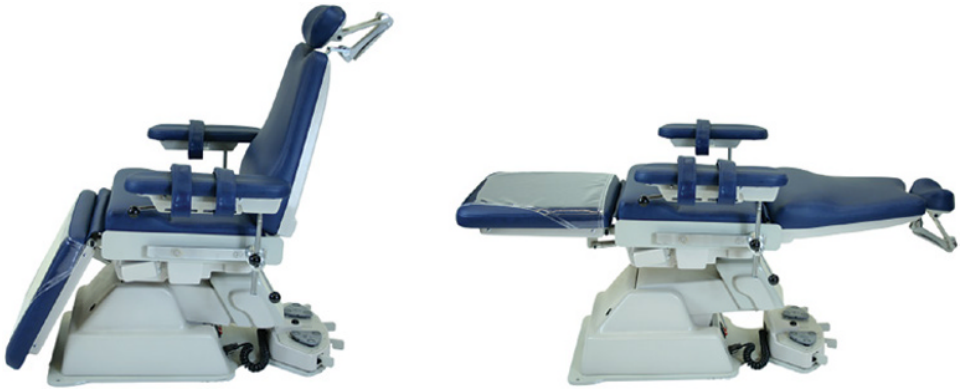Surgical tables can significantly improve work space ergonomics, efficiency, and productivity. Although most routine exodontia can be completed with a handful of instruments, some extractions require the use of specialized instruments. The seasoned surgical assistant can anticipate the surgical instrument and effortlessly pass it to the dentist. There is no need to leave the room in search of a unique instrument. A large surgical table (24" x 39"), positioned above the reclined patient's chest, allows the placement of many instruments within easy reach (see Figure 4.1).

Surgical chairs are used by most oral surgeons for two reasons: patient access and chair height (see Figure 4.2). Both of these considerations are closely related to ergonomics. Oral surgery chairs are designed to allow the best possible access to the patient's oral cavity when seated or standing. Reaching and leaning are reduced compared to a traditional dental chair designed for work from the 11 o'clock or 1 o'clock position. Optimum ergonomic chair height should provide a 90-degree angle between the upper arm and lower arm. This is often difficult or impossible to achieve when working in a standing position with a traditional dental chair.

Busy exodontia practices should consider equipping one large operatory with a surgical table and chair. This investment will result in increased efficiency and production and a reduction in musculoskeletal disorders.



**Figure 4.1** Rolling table adjusts from 31 in. to 46 in. tall. *Source:* Reproduced by permission of Salvin Dental.



**Figure 4.2** Oral surgery chair. *Source:* Reproduced by permission of BOYD Industries, Inc.

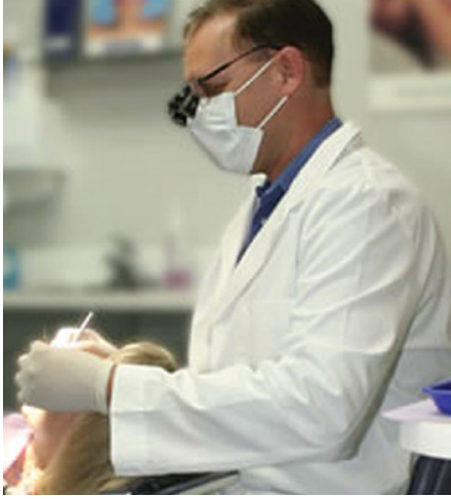The routine use of magnification in dentistry is a relatively new innovation. The author was in dental school from 1977 to 1981. The only dentists using magnification at that time were a handful of instructors. They were thought to be “nerds” or “geeks.” Today most dental schools recommend or require the use of magnification.<sup>5</sup> Loupes make it possible to comfortably reach and see the third molar region. Loupes help to prevent nerve injury and other complications when removing bone and sectioning third molars. Magnification also improves a dentist’s ability to distinguish between tooth structure and alveolar bone.<sup>6</sup>

Schoeffl et al. were able to prove that microsurgical success is directly related to optical magnification. Sixteen participants of microsurgical training courses had to complete artery and nerve surgery. Each surgery had to be performed with an unaided eye, surgical loupes, and a regular operating microscope. This study showed a direct relationship of error frequency and lower optical magnification. The highest number of microsurgical errors occurred with the unaided eye.<sup>7</sup>

There are many variables to consider when choosing loupes. Prices range from a few hundred dollars to thousands of dollars. Optical resolution is very important when considering loupes. The image viewed through the oculars should be crisp and uniformly clear from edge to edge. Quality loupes are made with glass optics. High-quality optics improve the image and lessen the potential for eye fatigue. Plastic optics, found in less expensive loupes, do not offer the highest level of visual acuity.<sup>8</sup> Another decision point is the choice between through-the-lens (TTL) and flip-up (FU) loupes.

The choice of TTL or FU loupes depends on personal preference. TTL loupes never need adjustment because the lens is mounted directly on the loupe glass. They are customized to the exact pupillary distance of each dentist. FU loupes can be adjusted and shared with other users. Working distance and angle of the loupes can affect posture. Properly fitted and adjusted loupes will decrease neck and back stress, an important aspect when considering our field (see Figure 4.3).

Another ergonomic decision involves lighting. Adequate lighting is essential for surgery and other dental procedures. Loupe lights are mounted between the loupe lenses, directly on the loupe frame. This position provides bright, shadow-free light for the dentist/surgeon. Traditional operatory lighting cannot provide the shadow-free, bright light of loupe lights (see Figure 4.4).



**Figure 4.3** Loupe magnification can improve posture.



**Figure 4.4** Loupe lighting can improve posture.

### Surgical Drills and Motors

Surgical drills used for the removal of impacted third molars are powered by compressed gas or electricity. The cost of surgical drill systems ranges from a few hundred dollars to more than \$20,000. Surgical drills can be classified as high-speed compressed air, low-speed pneumatic, or low-speed electric. The most economical surgical drills are high-speed handpieces (similar to operative dental handpieces) that run on compressed air.

#### High-Speed Compressed Air

High-speed operative handpieces should not be used for oral surgery. Compressed air from operative handpieces can enter the surgical site resulting in surgical emphysema, also known as subcutaneous emphysema. Subcutaneous emphysema occurs when air is forced into soft tissue through a reflected flap. The air invades adjacent tissues, leading

to pain, infection, swelling, crepitus on palpation, and occasionally spreading through fascial planes.<sup>9</sup> This can be a life-threatening complication.

Affordable, high-speed surgical drills have been developed to address this problem (see Figures 4.5a and 4.5b). The cost of a high-speed surgical drill is about the same as a standard operative handpiece. They have a 45-degree angled head to improve access and visibility and a rear exhaust to prevent subcutaneous emphysema. Examples are the Impact Air 45 and the Sabra OMS45. These surgical drills run at 400,000 to 500,000 RPM and deliver slightly more torque than a standard dental handpiece. They are capable of removing bone and sectioning teeth but don't have the high torque of traditional, straight surgical drills. The high-speed surgical drill chuck does not hold a surgical bur securely. The bur does not turn concentrically, which leads to chatter and bur breakage.

### Low-Speed Nitrogen

In 1963, Dr. Robert Hall introduced the Surgairtome (also known as the “Hall”) surgical drill. An example of this type of surgical drill is shown in Figure 4.6. This was one of the first high torque pneumatic drills used in oral surgery. The Hall runs on compressed nitrogen at 100 psi and 90,000 rpm. It is available in straight configurations. The torque of this drill is many times greater than that of an air-driven surgical handpiece.



**Figure 4.5a** Impact Air 45. *Source:* Reproduced by permission of Palisades Dental, LLC.



**Figure 4.5b** Sabra OMS45. *Source:* Reproduced by permission of Sabra Dental.



**Figure 4.6** Hall type surgical drill. *Source:* Reproduced by permission of ACE Surgical Supply Co. Inc.


The Hall type surgical drill is ideal for efficiently removing bone and sectioning teeth. It is completely sealed, does not require lubrication, and is extremely durable. Nitrogen is used to power the Hall drill to prevent oxidation of the sealed contents. Additionally, nitrogen does not support combustion.

The nitrogen-driven surgical drill requires a quick disconnect hose, bur guard, compressed nitrogen, and a regulator. The straight drill design, heavy hose, and lever actuator may be challenging for first time users. An optional foot pedal actuator is available. This drill is very loud.

### Low-Speed Electric

Electric surgical drills are not as durable as pneumatic surgical drills, but they have many advantages. These drills are powered by a portable electric motor that is placed on a counter, cart, or Mayo stand near the dentist or surgeon. The Osteomed system features an electric surgical drill (see Figure 4.7a, b, and c).

Electric surgical motors are very versatile and can be used for many dental procedures, including oral surgery and implantology. The typical surgical system includes an electric motor, micromotor, cable, surgical handpiece (attachment), peristaltic pump for irrigation, and foot pedal. The micromotor is considered an “E-type” motor if it has a flat surface for coupling with the handpiece (see Figures 4.8 and 4.9). E-type micromotors are interchangeable with attachments from many manufacturers.



**Figure 4.7** (a) Motor. (b) Foot pedal. (c) Drill. *Source:* Reproduced by permission of Osteomed, Inc.

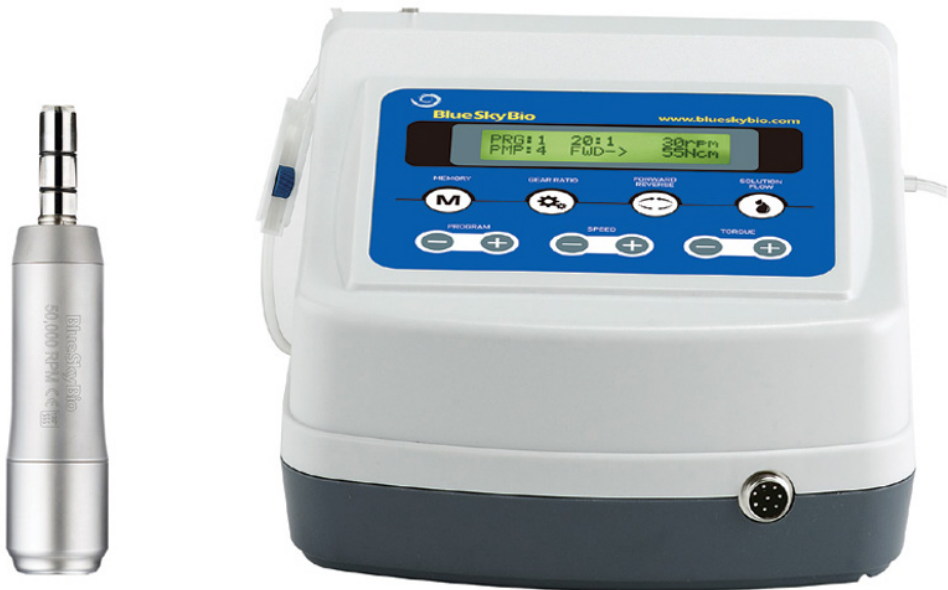

**Figure 4.8** E type micromotor with flat connecting surface.





**Figure 4.9** Author's surgical drill compatible with E type micromotor. *Source:* Reproduced by permission of Bien Air, USA.



**Figure 4.10** X Cube motor and E type micromotor. *Source:* Reproduced by permission of Blue Sky Bio.

Surgical drills used with E-type micromotor connections are available in straight or angled configurations. They are quiet compared to the pneumatic surgical drill. Electric surgical micromotors used for the removal of impacted third molars usually run between 40,000 and 100,000 rpm. The drill speed can be doubled with 1:2 increasing gears in the handpiece. However, the high torque of these systems is more important than rpm when removing bone and sectioning third molars. Electric systems tend to be expensive with frequent maintenance when compared with gas-driven drills. The X Cube is an example of an affordable electric surgical system (see Figure 4.10).

There are advantages and disadvantages to each system (see Table 4.1). The high-speed 45-degree surgical handpiece is affordably priced but does not have the cutting power (torque) of a straight surgical drill. The nitrogen-driven surgical drill system is moderately priced and very durable. It has high torque and cuts smoothly and efficiently. Electricity is not required. The straight drill chuck holds a 44.5 mm bur securely, which eliminates chatter. Unfortunately, it is very loud and requires a tank of nitrogen and a long high-pressure hose to operate. Electric surgical drill systems are relatively quiet. E type micromotors can fit various attachments, including a straight or angled

**Table 4.1** Characteristics of surgical drill systems.

Surgical Drill System	Cost	RPM	Torque	Cutting Efficiency	Durability	Multiple Attachments (E-Type)	Bur Type
High-speed air	Low	400,000–500,000	Low	Low	Moderate	No	High-speed friction grip
Low-speed nitrogen	Moderate	90,000–100,000	High	High	High	No	44.5 mm–70 mm
Low-speed electric	Moderate–High	0–100,000	High	High	Low–Moderate	Yes	44.5 mm–70 mm

(20 degrees) surgical handpiece. Like nitrogen-driven surgical drills, electric surgical drill systems' chuck holds a long bur securely to cut smoothly and eliminate chatter. Most electrical systems have a wide range of torque and rpm. The main disadvantage of these systems is cost.

The choice of systems usually depends on frequency of use. The high-speed surgical handpiece may be the right choice for a dentist removing impactions once a month. An expensive electrical system may be the right choice for someone removing impactions every day.

## Instruments

### Instrument Manufacturing and Care

There are literally thousands of instruments used in oral surgery. Surgical instruments are manufactured by many different companies throughout the world. The quality and characteristics of surgical instruments can vary depending on the manufacturer's design and the quality of steel. High-quality surgical instruments are handmade, which can lead to some minor variations in the dimensions of instruments, particularly between manufacturing sets. A 301 elevator manufactured by Miltex may feel and function differently than the same numbered elevator made by Hu-Friedy. Many surgeons prefer one instrument brand over another and may have an assortment of their favorite instruments from different manufacturers.

Most surgical instruments are stainless steel. Steel is made stainless by adding nickel and chromium in measured quantities. There are over 150 grades of stainless steel. Medical grade stainless steel is an alloy containing nickel and chromium in very specific quantities. Most medical grade stainless steel is Type 304, sometimes called T304. Carbon can be added to the steel to make the metal harder when a sharp instrument edge is desired, but the addition of carbon makes surgical instruments more likely to corrode. This problem can be solved for hinged instruments by the addition of tungsten carbide inserts. Tungsten carbide is among the hardest materials known and is very resistant to wear and corrosion. Tungsten carbide inserts are used in surgical instruments to enhance their performance and longevity. Needle holders and forceps made with tungsten carbide grasp more securely and are more durable than those made with stainless steel. Tungsten

carbide scissors cut better and need much less sharpening than stainless steel. A gold handle on scissors, forceps, or needle holders indicates they have tungsten carbide inserts on the working surfaces. They are approximately twice as expensive as standard instruments but can last five times longer. This can be very cost effective in the long run.

New instruments are more likely to corrode than old instruments because they have a thin layer of chromium oxide on their surface. This layer thickens with age and increases the resistance of the instruments to corrosion. New instruments are particularly vulnerable to detergents, inadequate lubrication, and the corrosive environment of an autoclave. New instruments often show markings while old instruments are unmarked. Maximizing the chromium oxide layer is the basis of sound instrument care.

The chromium oxide layer can be maintained and thickened through proper cleaning and maintenance. Surgical instruments should be scrubbed with a soft brush to remove blood and debris, run in an ultrasonic cleaner for 10–15 minutes, immediately rinsed, and steam autoclaved until the full drying cycle is complete. Any moisture left on instruments or in overlapping joints will result in staining, pitting, and corrosion. The use of a surgical “milk” lubricant for hinged instruments prior to sterilizing will prevent corrosion and spotting from mineral deposits left behind by water. Silicone grease can be used in the joint of hinged instruments to improve performance. Lubrication is the most important action one can take to extend the life of hinged instruments.

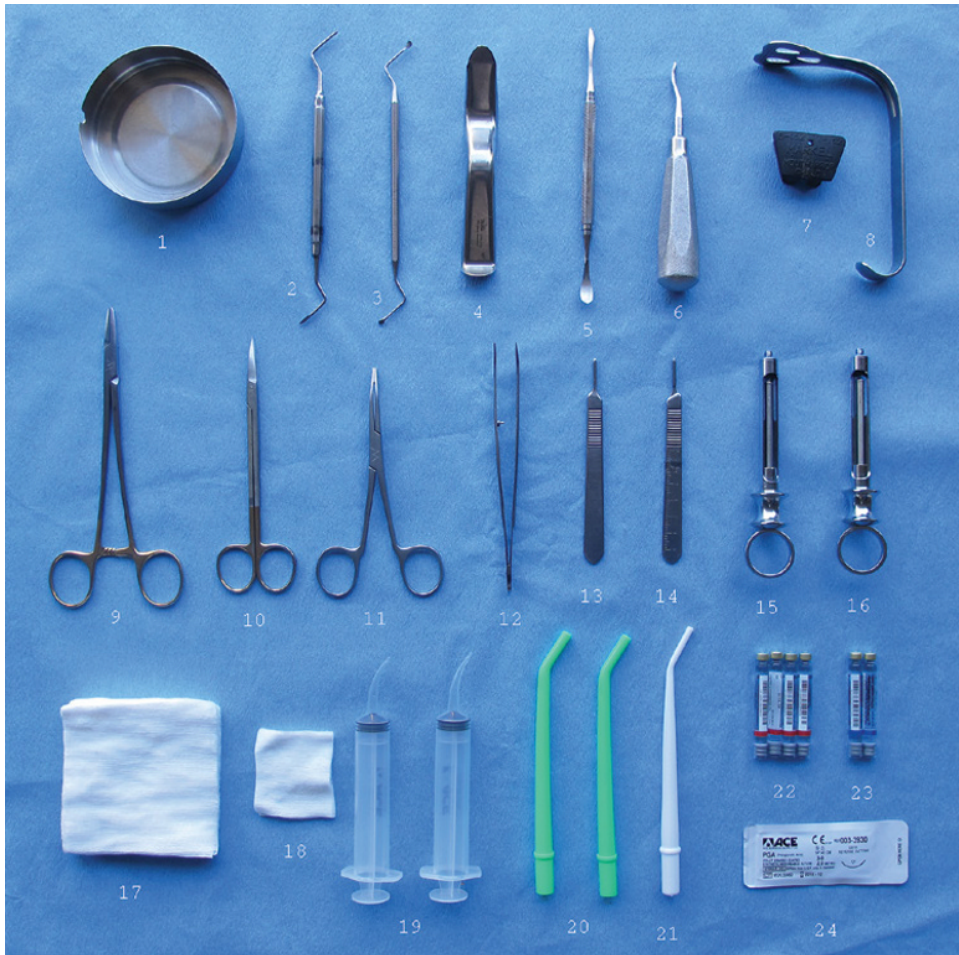### Impacted Third Molar Instruments

A basic setup for the surgical removal of impacted third molars consists of a limited number of instruments. A fundamental goal in any efficient surgical procedure requires that individual instruments are used as seldom as possible. Accomplished surgeons routinely complete difficult procedures with a handful of their favorite instruments. A good analogy would be the beginning golfer, with a bag full of clubs, who cannot

#### Box 4.1 Author’s basic surgical instrument setup.

Straight elevator – serrated 46R	Anesthetic syringe (2)	Surgical drill	Scalpel handle (2)
Periosteal elevator – #9 molt	Bite block – child	1703L surgical bur	#12 scalpel blade
Curette – 2/4 double ended molt	Needle holder – carbide tungsten	Tissue forceps	#15 scalpel blade
Minnesota retractor	Scissors – carbide tungsten	412 Monoject syringe (2)	3.0 PGA suture
Weider retractor – medium	Curved hemostat or KLS Marin “tooth grabber”	4×4 and 2×2 filled 8-ply gauze	Sterile bowl
Root tip pick	Magnification	Loupe light	Mask
Small and large surgical suction (2)	Lidocaine 2% epinephrine 1:100,000	Marcaine 0.5% epinephrine 1:200,000	Gloves

break 100 on the golf course. Any professional golfer could easily break 100 with three clubs. However, there are times when every surgeon needs an instrument that is not in their basic setup. For the purpose of this chapter, these instruments will be termed “specialty instruments.” A specialty instrument for one operator may be a member of the basic setup for another operator. Specialty instruments are used when instruments in the basic setup are inadequate. The author’s basic instruments can be seen in Box 4.1 and Figure 4.11.



**Figure 4.11** Photo of author’s basic third molar instrument setup. Legend: (1) Sterile bowl for irrigant. (2) Root tip pick. (3) Surgical curette. (4) Minnesota retractor. (5) #9 periosteal elevator. (6) 46R elevator. (7) Child mouth prop. (8) Weider retractor. (9) Needle holder with carbide tips. (10) Scissors. (11) Curved hemostat. (12) Cotton plier. (13) #12 bard parker handle. (14) #15 bard parker handle. (15) 30-gauge long anesthetic syringe. (16) 27-gauge long anesthetic syringe. (17) 4×4, 8-ply filled gauze. (18) 2×2, 8-ply filled gauze. (19) Irrigation syringes. (20) Two 1/4 inch large surgical suction. (21) 1/16 inch small surgical suction. (22) Four carpules lidocaine 2% with epinephrine 1:100,000. (23) Two carpules marcaine 0.5% with epinephrine 1:200,000. (24) 3.0 polyglycolic acid absorbable suture (PGA).

Forceps are conspicuously missing from the surgical setup. By definition, impacted third molars cannot be removed with forceps. Universal forceps or a rongeur may be useful to grasp a luxated third molar or root.

The Weider retractor is used in most oral surgery offices (see Figures 4.12a and 4.12b). It is rarely used in general dentistry practices. The instrument isolates the surgical site and protects the patient's tongue. It also prevents aspiration of fluids and solid objects when used with a gauze pharyngeal screen. This combination is especially useful when patients are sedated.

The heart-shaped paddle is inserted between the tongue and lingual surface of the mandible. The L-shaped handle can be used to retract the tongue but usually functions as ballast, allowing the assistant to use both hands for suctioning, irrigation, and other functions. The Weider retractor is available in small, medium, and large sizes.

### **Elevators**

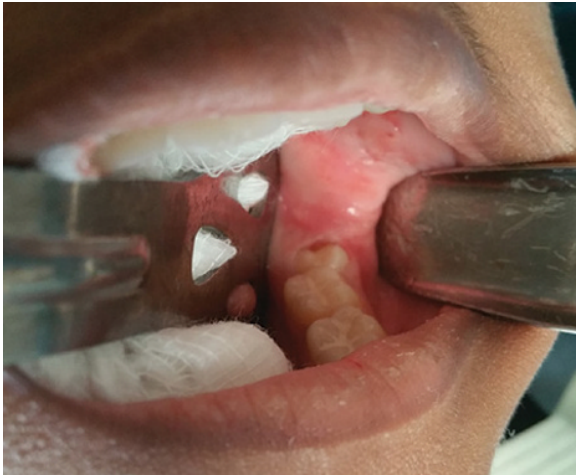Elevators used in oral surgery are examples of two simple machines, the wheel and axle and inclined plane. The wheel and axle and incline plane change the direction or magnitude of force to gain mechanical advantage. Elevators can be found in many shapes and sizes for different situations when removing teeth and fractured roots.

Wheel and axle elevators usually have sharp tips that are offset from the instrument shank (see Figure 4.13). They are always found as a left and right pair. They are often referred to as pennant or flag instruments due to their characteristic triangular tip resembling a flag. These elevators develop significant torque when bone is used as a fulcrum. They are usually used to remove roots when there is an empty adjacent socket. The sharp point is used to engage the remaining fractured root tip. A #30 or #31 Cryer elevator can be used to remove a mesial third molar root after the distal root has been removed (see Figures 4.14a and 4.14b). The sharp instrument tip can push through interseptal bone and engage the mesial root cementum. Cryer elevators and other similar flag instruments come in many sizes and shapes.

Another flag elevator that resembles the Cryer elevator is the Seldin #1L and #1R (see Figures 4.15a and 4.15b). The Cryer and Seldin elevators are mainly used in the mandible. These elevators should be sharpened regularly.

The Crane Pick and Cogswell B elevators are two more examples of wheel and axle elevators (see Figures 4.16 and 4.17). These elevators can be used to remove teeth and roots in the maxilla and mandible. The Crane Pick and Cogswell B are very similar in appearance and are often confused with each other. The handle, shank, and offset tip are nearly identical. However, the Crane Pick has a sharp pointed tip that is triangular in shape. The tip of the Cogswell B is smooth and rounded. Both instruments work well when a purchase point is drilled in a tooth or root. The instrument tip is placed in the purchase point and a bony fulcrum used to remove the tooth or root.

The inclined plane principle is illustrated in Figure 4.18. These elevators work on the principle that two objects cannot occupy the same space at the same time. Straight elevators are wedged into the periodontal ligament (PDL) space between bone and tooth structure to luxate teeth and roots. The shank of a straight elevator should parallel the long axis of the tooth or root when used properly. Once the PDL is severed, the instrument can be rotated clockwise and counter clockwise to further luxate the tooth or root.



**Figure 4.12a** Weider retractor. *Source:* Reproduced by permission of Hu-Friedy Dental.




**Figure 4.12b** Weider retractor in position.



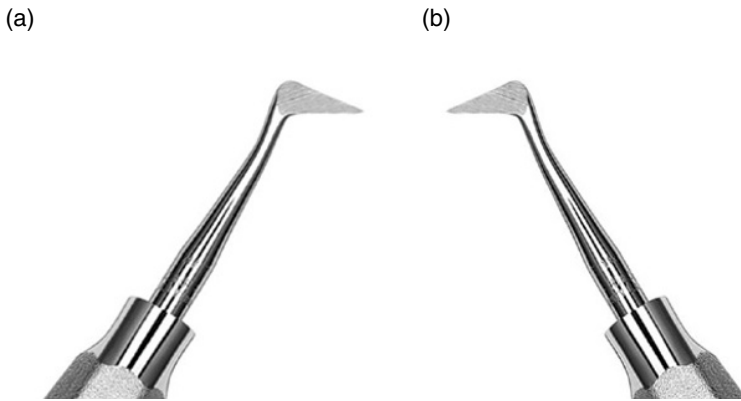
**Figure 4.13** Wheel and axle.

Inclined plane elevators are normally called straight elevators. They have a straight or slightly curved shank and a tapering, concave tip. Common straight elevators are the 301 and 34 (see Figures 4.19 and 4.20). There are many versions of these versatile elevators. Straight elevators can be used to elevate all teeth in addition to third molars. The main difference between the 301 and 34 is the size of the tip and the amount of force that can be applied. The 301 can be used when access is poor, such as when roots are close to one another. The 34 is used in larger spaces and has much more torque when force is applied.

The author's favorite elevator for the removal of third molars is the 46R. This instrument is very similar to the 77R. The main feature of the instrument is a gradual curve in the instrument shaft. This curve provides easier access to third molars. Serrations at the working end of the instrument increase the grip on the tooth (see Figure 4.21).



**Figure 4.14** (a) #30 Cryer elevator. (b) #31 Cryer elevator. *Source:* Reproduced by permission of Hu-Friedy Dental.



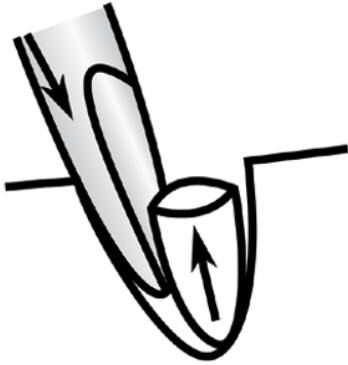
**Figure 4.15** (a) Seldin elevator #1L. (b) Seldin elevator #1R. *Source:* Reproduced by permission of Hu-Friedy Dental.



**Figure 4.16** Crane Pick. *Source:* Reproduced by permission of Hu-Friedy Dental.



**Figure 4.17** Cogswell B. *Source:* Reproduced by permission of Hu-Friedy Dental.



**Figure 4.18** Inclined plane displaces the root or tooth.



**Figure 4.19** 301 elevator. *Source:* Reproduced by permission of Hu-Friedy Dental.



**Figure 4.20** 34 elevator. *Source:* Reproduced by permission of Hu-Friedy Dental.



**Figure 4.21** 46R elevator. *Source:* Reproduced by permission of Hu-Friedy Dental.

Another elevator used by the author to remove impacted third molars is the Hu-Friedy EL3CSM (see Figure 4.22). The number 3 indicates that the working tip is 3 mm wide. The EL CSM elevators are available from Hu-Friedy with tips ranging from 2 mm to 5 mm. This elevator is very similar to the generic 301 elevator with some important differences. The shaft has a gradual curve that improves access when used as an incline plane. The tip is sharp, slightly concave, and is very strong. This elevator is especially useful when removing vertical and distoangular impactions. The tip is placed in the PDL space on the buccal surface with the shaft parallel to the long axis of the tooth. Force is applied and the tooth is elevated in a coronal direction.

The inclined plane straight elevators previously described are among the most popular elevators used in the United States for the removal of impacted third molars. Wheel and axle elevators are especially useful when removing maxillary third molars and space is



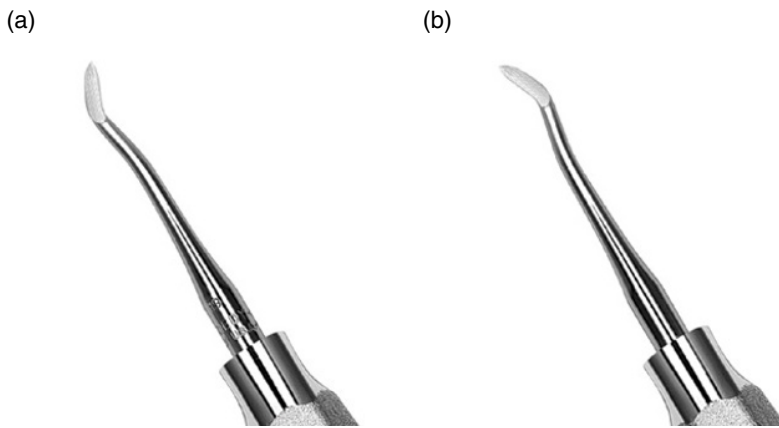
limited. The 19/20, 190/191, and Potts elevators are other examples of wheel and axle elevators (see Figures 4.23a and 4.23b, Figures 4.24a and 4.24b, and Figures 4.25a and 4.25b).

#### Periotomes, Proximators, and Luxators (PPL)

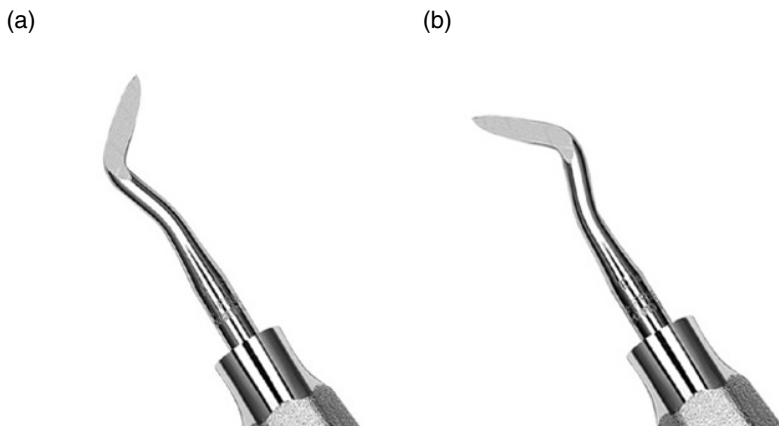
PPL instruments, like straight elevators, are wedged between tooth roots and bone to sever the periodontal ligament and displace a tooth or fractured root. The tip of PPL instruments is very sharp, and relatively flat when compared to the traditional straight elevator. A periotome is smaller than a proximator, a proximator is



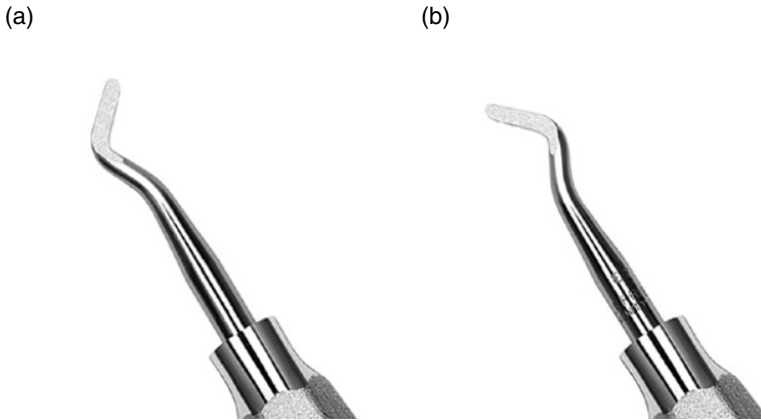
**Figure 4.22** Hu-Friedy EI3CSM. *Source:* Reproduced by permission of Hu-Friedy Dental.



**Figure 4.23** (a) #19 Warwick-James. (b) #20 Warwick-James. *Source:* Reproduced by permission of Hu-Friedy Dental.



**Figure 4.24** (a) #190 Modified Woodward. (b) #191 Modified Woodward. *Source:* Reproduced by permission of Hu-Friedy Dental.



**Figure 4.25** (a) #6 Potts. (b) #7 Potts. *Source:* Reproduced by permission of Hu-Friedy Dental.



**Figure 4.26** Periostome. *Source:* Reproduced by permission of Schumacher Dental.



**Figure 4.27** Proximator. *Source:* Reproduced by permission of Schumacher Dental.

usually smaller than a luxator, and a luxator is usually smaller than a straight elevator (see Figures 4.26, 4.27, and 4.28). The previously mentioned EL3CSM is sometimes called a luxating elevator because it combines the characteristics of a luxator and an elevator. The instrument is unique because it has a thin, strong, and sharp tip that can be rotated clockwise and counterclockwise, or used with a prying motion, without breaking.



**Figure 4.28** Luxator (luxating elevator). *Source:* Reproduced by permission of Schumacher Dental.



**Figure 4.29** Spade proximator. *Source:* Reproduced by permission of Schumacher Dental.

PPLs are used in the periodontal ligament space prior to the application of a straight elevator. The progressive application of larger instruments expands the bony socket. The use of a traditional elevator may not be necessary since the tooth or fractured root is often avulsed without the prying motion of an elevator.

PPL instruments are manufactured in many different sizes. All PPL instruments work on the principle of the inclined plane. They are inserted along the long axis of the tooth into the PDL space to sever the periodontal ligament and expand the socket. Periotomes, proximators, and luxators can be used in succession to enlarge the PDL space and socket. Unlike straight elevators, these instruments are not rotated clockwise and counter clockwise once they are wedged in place. PPL instruments are used with finesse to avoid chipping of the sharp tip. They are wedged in several places around the tooth/root and gradually displace the tooth/root from the socket. PPL instruments are often used when the dentist's goal is an atraumatic extraction.

The spade proximator deserves further discussion (see Figure 4.29). The author has had success using this instrument to remove impacted third molar root tips. The spade-shaped instrument tip can be wedged between the retained root and the wall of the socket.

The number of instruments designed to remove teeth can be overwhelming. One manufacturer's website (Hu-Friedy) displays 123 elevators over 14 pages! Furthermore, there are hundreds of manufacturers worldwide with a wide range of quality and design for the same instrument.

Oral surgeons have favorite instruments for different situations. It is recommended that the reader try different instruments and manufacturers to discover their favorite instruments. It is not possible to know which instrument feels right and works best for you unless you try it. For example, a 190/191 elevator from one manufacturer may feel, and function, very differently from a 190/191 from another manufacturer.

## Materials

Materials used in oral surgery for the removal of impacted third molars are many and varied. For the purpose of this discussion, materials are grouped into two categories.

- 1) Personal protective equipment
- 2) Disposable materials

## Personal Protective Equipment (PPE)

PPE is designed to protect the skin and the mucous membranes of the eyes, nose, and mouth from exposure to blood or other potentially infectious material.<sup>10</sup> Use of rotary surgical instruments and air-water syringes creates a visible spray that contains primarily large-particle droplets of water, saliva, blood, microorganisms, and other debris. This spatter travels only a short distance and settles out quickly, landing on the floor, nearby operatory surfaces, dental health care providers, or the patient. The spray also might contain certain aerosols (i.e., particles smaller than 10  $\mu\text{m}$  that can be inspired). Aerosols can remain airborne for extended periods. However, they should not be confused with the large-particle spatter that makes up the bulk of the spray from handpieces. Appropriate work practices, including the use of a throat pack and high-velocity evacuation, should minimize the spread of droplets, spatter, and aerosols.<sup>11</sup>

The use of PPE and universal precautions in health care is closely related to the AIDS outbreak in the 1980s. Kimberly Bergalis developed AIDS after visiting HIV-positive Dr. David Acer in 1987 for the removal of a molar. This incident is the first known case of clinical transmission of HIV.<sup>12</sup> Initially, the CDC and media believed HIV was transmitted to Ms. Bergalis via unclean dental instruments. It was later learned that Dr. Acer may have intentionally infected the patient. This incident led to the implementation of universal precautions.

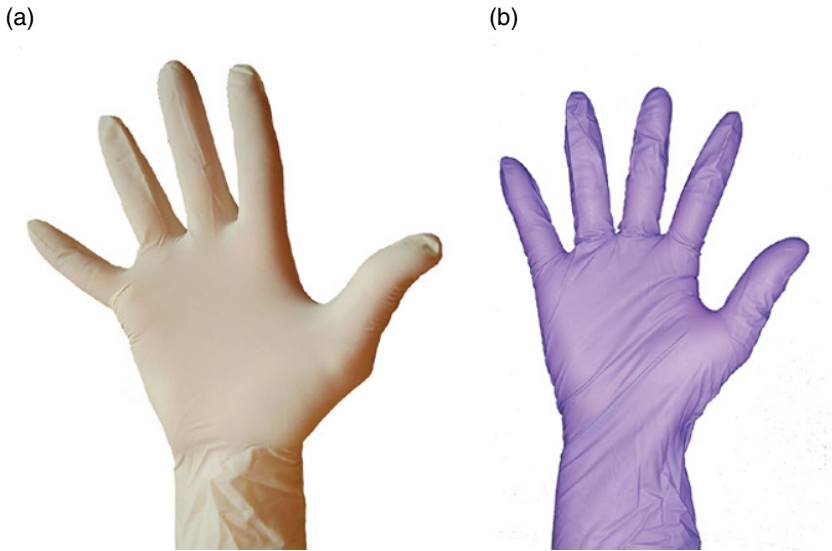
Universal precautions in health care refer to the practice of treating every patient as if they are infected.<sup>13</sup> Universal precautions include good hygiene habits (hand washing), correct handling of needles and scalpels, aseptic techniques, and the use of barriers such as gloves, face masks, eye protection, and barrier gowns or lab coats.

### Gloves

Gloves reduce the spread of germs to patients and protect the hands of the surgeon. Surgical latex gloves come with or without powdered cornstarch to make them easier to put on the hands. In the late 1980s latex glove use in dentistry exploded after the AIDS outbreak and implementation of Universal Precautions. According to projections from a report published by Global Industry Analysts (GIA), the market for disposable medical gloves will be worth \$4 billion in 2017.<sup>14</sup> Gloves used in dentistry are primarily made of natural latex rubber or synthetic nitrile rubber (see Figures 4.30a and 4.30b).

Most surgeons prefer latex gloves due to superior fit and the ability to stretch, which improves tactile feel. However, the incidence of latex allergy has prompted an increase in the use of synthetic gloves such as nitrile gloves. It is estimated that 8%–12% of health care workers are latex sensitive, with reactions ranging from irritant contact dermatitis and allergic contact sensitivity to anaphylaxis.<sup>15</sup> Regarding powdered gloves, one should consider that the cornstarch powder in latex gloves may cause wound healing issues and postoperative complications, and may facilitate latex allergy exposure.<sup>16</sup>

Wearing gloves does not eliminate the need for hand washing. Hand washing should be performed immediately before putting on gloves. Gloves can have small defects or can be torn during use, increasing the risk of wound contamination and exposure to microorganisms from patients. Bacteria can multiply rapidly in the moist environments underneath gloves. Therefore, hands should be completely dry before donning gloves and washed again immediately after glove removal.<sup>17</sup>



**Figure 4.30** (a) Latex glove. (b) Nitrile glove.

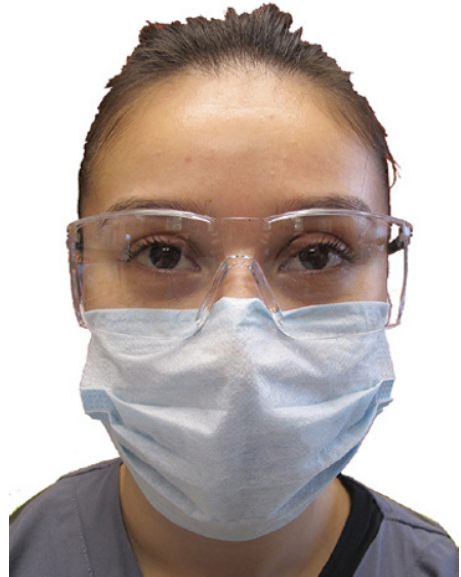### Masks

Surgical masks prevent the transmission of body fluids to patients and protect the surgical team from being splashed in the mouth with body fluids (see Figure 4.31). They can also reduce the spread of infectious liquid droplets that are created when the wearer coughs or sneezes. They are a constant reminder for the surgical team to not touch their mouth or nose, which could transfer viruses and bacteria. Evidence supports the effectiveness of a mask: the bacterial filtration efficiency is  $>95\%$ , reducing the risk of infection.<sup>18</sup>

All procedures performed with the use of surgical handpieces cause the formation of aerosol and splatter, which are commonly contaminated with bacteria, viruses, fungi, and blood.<sup>19</sup>

### Eyewear

Eye protection includes face shields and goggles (see Figure 4.32). Protective eyewear with solid side shields or a face shield should be worn during procedures likely to generate splashes or sprays of blood or body fluids. Goggles and face shields protect mucous membranes in the surgical team eyes from these fluids. Protective



**Figure 4.31** Surgical masks reduce the transmission of infectious disease.

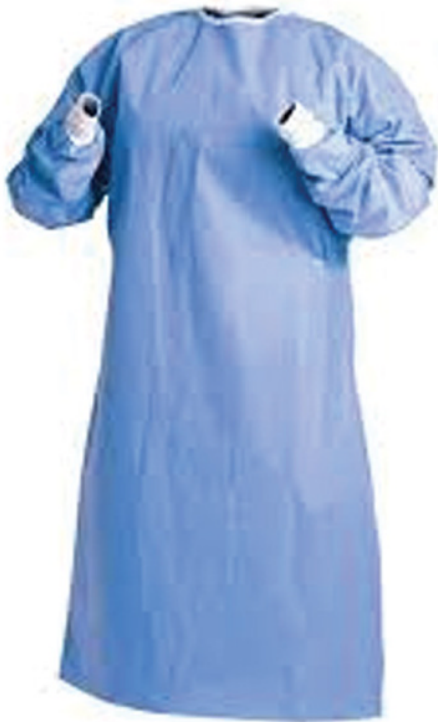

**Figure 4.32** Goggles and face shields protect against transmission of disease.

eyewear for patients shields their eyes from splatter or debris generated during surgical procedures.

#### **Gowns**

The Occupational Safety and Health Administration (OSHA) Bloodborne Pathogens standard requires that personal protective clothing (e.g., gowns, lab coat) have sleeves long enough to protect the forearms, have a high neck, and be knee length (see Figure 4.33). Street clothes or scrubs are usually not intended to be personal protective equipment and are worn under a lab coat or gown.



**Figure 4.33** Surgical gowns and lab coats protect against transmission of disease. *Source:* Reproduced by permission of Dynarex.

#### **Disposable Materials**

The removal of impacted third molars requires the use of many disposable materials. Most of these materials are essential but may vary by manufacturer and the surgeon's preference. A list of disposable materials used by the author when removing impacted third molars is shown in Box 4.2.

The use of some materials shown in Box 4.2 is anecdotal, but they have worked well for the author for more than 36 years. The author's rationale for using these materials is presented in the following section. The scientific basis for the material use is included when available.

**Box 4.2 Disposable materials used by the author when removing impacted third molars.**

Lidocaine 2% epi 1:100,000 Marcaine 0.5% epi 1:200,000	PGA 3.0 suture	4×4 gauze, 2×2 gauze
Surgical suction	12 and 15 scalpel	Irrigation syringes

**Lidocaine and Marcaine**

The author uses lidocaine 2% with epinephrine 1:100,000 in all four quadrants. Bupivacaine (Marcaine) 0.5% with epinephrine 1:200,000 is used in addition to lidocaine in lower quadrants. Marcaine appears to be more effective than lidocaine in reducing postoperative pain following the removal of impacted mandibular third molars.

Brajkovi et al. studied the effects of lidocaine versus bupivacaine in reducing postoperative pain following the surgical removal of mandibular third molars. They concluded that bupivacaine 0.5% (Marcaine) controlled postoperative pain more efficiently after lower third molar surgery than lidocaine 2% with epinephrine 1:80,000.<sup>20</sup>

Another study by Naichuan et al. found bupivacaine to work better than lidocaine in dental operations that take a relatively long time, especially in endodontic treatments or where there is a need for postoperative pain management. Specifically, 0.5% levobupivacaine had higher success rates and was better in postoperative pain control than 2% lidocaine.<sup>21</sup>

**Suction**

Disposable surgical suction is available in three lumen sizes, 1/16 inch, 1/8 inch, and 1/4 inch. The plastic surgical suction is sterilized prior to use. Two disposable surgical suction are part of the author's surgical setup, green 1/4 inch and white 1/8 inch (see Figure 4.34). The green suction is used for most of the surgery. The 1/4-inch large lumen minimizes clogging and the suction power is almost the same as HVE. The strong suction is useful if debris or fluid find its way behind the pharyngeal screen. The small white 1/8-inch suction is used inside flaps or when visualization is paramount, for example, when removing root tips.

**Suture**

The use of needle and thread to close wounds is several thousand years old, dating back to ancient Egypt. Classical period literature (800–200 BC) contains many descriptions



**Figure 4.34** Disposable surgical suction is sterilized prior to use.

of surgery involving sutures. Two physicians from that period, Hippocrates and Galen, described sutures and suturing technique.<sup>22</sup>

Various types of suture materials were used for thousands of years. Needles and thread were made from bone or metal such as gold, silver, copper, and bronze. Suture thread was made of metal wire or plant or animal material. Silk eventually became the number-one nonabsorbable material. Catgut (bovine, sheep, goat intestine) became the standard absorbable suture material near the end of the 19th century.

The first synthetic suture was developed in the 1930s, followed by polyglycolic acid suture (PGA) in the 1960s (see Figure 4.35). Many synthetic sutures are now available with different characteristics. The majority of sutures used today are synthetic. Silk and gut are the only remaining natural sutures from ancient times. Gut sutures have been banned in Europe and Japan owing to concerns regarding bovine spongiform encephalopathy (mad cow disease). Most sutures manufactured today are sterilized by ethylene oxide or gamma irradiation.

Suture material can be classified as absorbable or nonabsorbable, natural or synthetic. Absorbable suture from natural sources, such as catgut, is absorbed enzymatically. Absorbable suture from synthetic polymer sources is hydrolyzed. Sutures are absorbed at different rates. This is important since surgery may require a strong suture of long duration or a weak suture of short duration. Suture half-life is described as the amount of time for the suture to lose half of its original tensile strength. Suture rate of absorbability and half-life can be as short as a few days or more than a month. Suture half-life is influenced by type of material, thread diameter, type of tissue, and general condition of the patient. Nonabsorbable materials used in oral surgery must be removed. This suture type includes natural materials such as silk and cotton, or steel and synthetic materials such as prolene, polypropylene, polyester, and nylon.



**Figure 4.35** Polyglycolic acid absorbable suture handles like silk and absorbs like gut.



Another important characteristic of sutures is thread structure. Sutures can be considered monofilament or multifilament (usually braided). Monofilament sutures are composed of one strand. Catgut is a monofilament suture. Monofilament sutures pass through tissue smoothly and are resistant to infection. However, monofilament sutures bend and crimp easily, which can lead to breakage and loss of tensile strength. Multifilament suture consists of several strands braided or twisted together. This structure increases tensile strength but increases the rate of infection and drag through tissue.

Multifilament sutures can be coated to decrease drag when passing through tissue. Monofilament sutures and coated multifilament sutures are easier to tie in a surgical knot, but the knot is more likely to come untied. Coatings can also increase the half-life of sutures. For example, coated chromic gut will maintain its integrity and strength longer than standard gut suture.

Suture thread is sized by numbers: the smaller the number, the larger the thread. The smallest suture is 10.0, which is the thickness of a human hair. The largest suture is 00, which may be as large as a fishing line. Oral surgery procedures usually require suture between 3.0 and 5.0. The larger of these, 3.0 sutures, are most commonly used for impacted third molar flaps. Smaller 4.0 or 5.0 suture may be used to repair mucosal tears or to close vertical incisions.

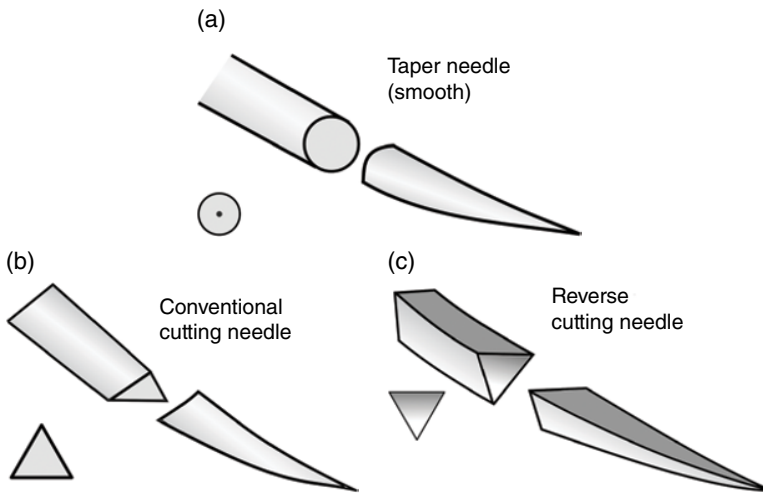
Needles are selected based on size, type, and shape. Needle size can be tiny for ophthalmic procedures or huge for abdominal procedures. Most needles used in oral surgery are moderate in size. There are two fundamental types of suture needles: tapered or cutting. Tapered needles are used where tissue is easy to penetrate such as bowel or blood vessels. These needles are round in cross-section and taper to a point. Cutting needles are triangular in cross-section, which makes it easier to penetrate tough tissue with less trauma. Cutting needles are either conventional cutting or reverse cutting. The apex of conventional cutting needle triangle is on the inside, concave, surface of the needle. Reverse cutting needles are similar to a conventional cutting needle, but the triangle apex is on the outside, convex, surface of the needle. Reverse cutting needles, often used in oral surgery, decrease the chance of sutures tearing tissue and pulling through the incision edge (see Figures 4.36a, 4.36b, and 4.36c).

Suture needles are available in many different shapes, including straight and fish-hook shape. However, most suture needles are partial circles ranging from 1/4 circle to 1/2 circle (see Figure 4.37).

Although there are hundreds of suture and needle configurations, there are only a few possibilities for each surgical application. Flap design, access, and procedure dictate suture and needle choice when removing impacted third molars. Flaps created for the removal of impacted third molars are full thickness mucoperiosteal flaps with or without a releasing incision. Third molar sutures dissolve or are removed within 2 weeks. This timeline limits absorbable sutures to gut, rapid PGA, or other fast-resorbing synthetic sutures. Silk is another option, but not a good choice due to patient noncompliance with appointments. Also, silk is often difficult to remove after third molar procedures due to limited access and patient sensitivity. Absorbable sutures are recommended.

Two surgical situations determine suture selection when removing impacted third molars.

- 1) Releasing incisions and the repair of mucosal tears determine needle and thread size. Size 5.0 suture is typically used to approximate edges of delicate oral mucosa. The thread diameter and friable tissue dictate a small, 1/2 circle, reverse cutting needle.



**Figure 4.36** (a) Tapered needle. (b) Conventional cutting needle. (c) Reverse cutting needle. *Source:* Courtesy of Michael Brooks.

- 2) Full-thickness mucoperiosteal flaps without releasing incisions or mucosal tears are typically closed with 3.0 suture thread and 19 mm, 3/8 circle, reverse cutting needle.

Experienced surgeons choose their favorite sutures based on flap design, procedure, absorbability, and handling characteristics. PGA suture is the author's favorite suture. It handles like silk and absorbs like gut.

### Scalpel Blades

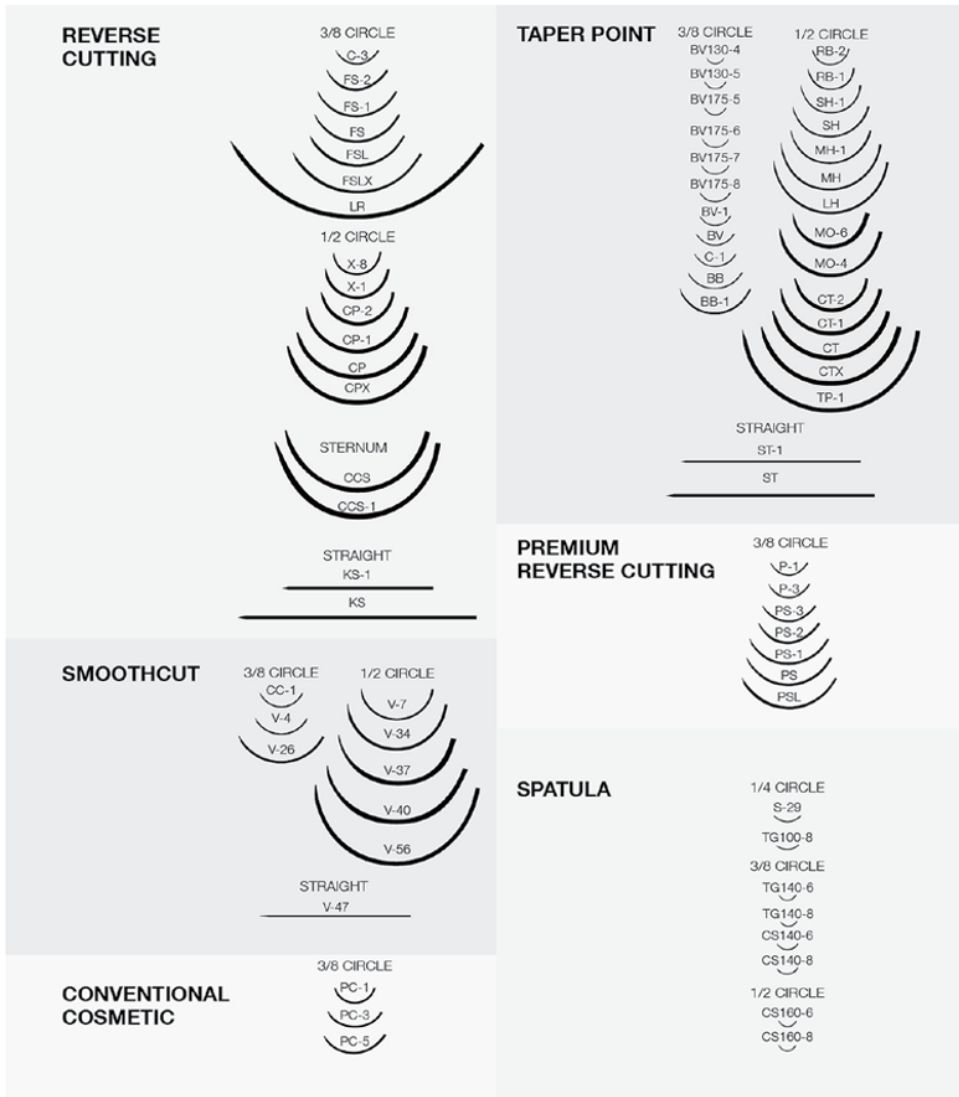
Scalpel blades are made of hardened and tempered steel, stainless steel, or high carbon steel. Titanium blades are available for surgical procedures performed with MRI guidance. Scalpel blades are also made with zirconium nitride-coated edges to improve sharpness and edge retention. Other manufactured blades are polymer coated to enhance lubricity during a cut.

Scalpels consist of reusable handles and disposable blades. Like sutures, scalpel blades come in many sizes and shapes (see Figure 4.38). The choice of scalpel blade is based on the surgical procedure. There are dozens of scalpel blades designed for different surgical procedures. For example, the #10 blade is a relatively large blade with a smooth curve used for skin incisions and abdominal surgery. The most common blades used for the removal of impacted third molars are the #12 and #15 (see Figure 4.39).

The #12 blade is sometimes used for an incision distal to a maxillary second molar and tuberosity. The curved blade allows easy access to this area. The #15 blade is used for small, precise incisions and is ideal for most oral surgery procedures, including third molar removal.

### Gauze

A fundamental premise in oral surgery is to prepare for complications and prevent them. The aspiration of root fragments, debris, or blood during exodontia can be



**Figure 4.37** The 3/8 circle shape is normally used for third molar surgery. *Source:* Reproduced by permission of Riverpoint Medical.

prevented with gauze. Gauze used to prevent accidental aspiration or swallowing is variously known as a pharyngeal drape, screen, or throat pack.

Gauze should be placed in the pharynx, posterior to the tongue, during every exodontia procedure. Used in conjunction with a Weider retractor, 4x4, 8-ply filled gauze protects the airway and throat (see Figures 4.40 and 4.41). Pharyngeal screens keep the surgical field dry and clean and increase visibility. This simple device should be part every dentist’s exodontia algorithm.



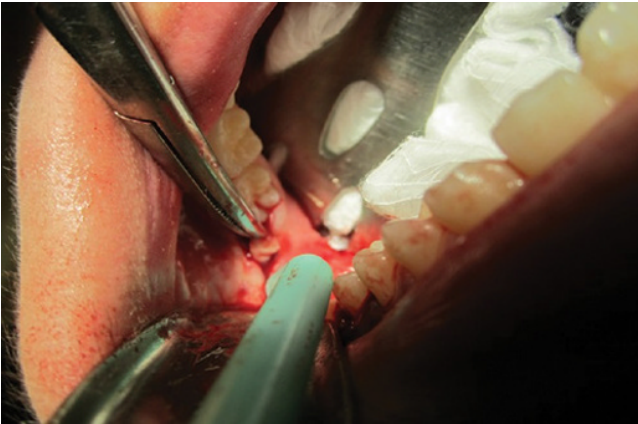
**Figure 4.38** Scalpel blades are available in many sizes and shapes. *Source:* Reproduced by permission of Exel International.



**Figure 4.39** #12 and #15 blades are commonly used when removing impacted third molars. *Source:* Reproduced by permission of Exel International.



**Figure 4.40** Filled 4x4 gauze.



**Figure 4.41** Filled gauze 4x4 pharyngeal screen.



**Figure 4.42** Irrigation syringes are used to irrigate the surgical site and flap.

### **Irrigation Syringe**

Irrigation syringes are an essential part of any exodontia procedure. The flap should be thoroughly irrigated with sterile fluid to flush out debris. The extraction site should be suctioned and inspected following flap irrigation. The Monoject 412 syringe or similar syringe is recommended. These syringes can be sterilized without melting (see Figure 4.42). Irrigation is also needed to reduce heat from rotary instruments when removing bone or sectioning teeth.

## **Bloodborne Pathogens Standard**

OSHA personal protective clothing regulations are specific and can be found in the Bloodborne Pathogens standard, Part 1910.1030 of the OSHA Regulations,<sup>23</sup> reproduced verbatim here:

- 1) Provision. When there is occupational exposure, the employer shall provide, at no cost to the employee, gowns and lab coats. Personal protective equipment will be considered “appropriate” only if it does not permit blood or other potentially infectious materials to pass through to or reach the employee’s work clothes, street clothes, undergarments, skin, eyes, mouth, or other

- mucous membranes under normal conditions of use and for the duration of time which the protective equipment will be used.
- 2) Use. The employer shall ensure that the employee uses appropriate personal protective equipment unless the employer shows that the employee temporarily and briefly declined to use personal protective equipment when, under rare and extraordinary circumstances, it was the employee's professional judgment that in the specific instance its use would have prevented the delivery of health care or public safety services or would have posed an increased hazard to the safety of the worker or co-worker. When the employee makes this judgment, the circumstances shall be investigated and documented in order to determine whether changes can be instituted to prevent such occurrences in the future.
  - 3) Accessibility. The employer shall ensure that appropriate personal protective equipment in the appropriate sizes is readily accessible at the worksite or is issued to employees.
  - 4) Cleaning, laundering, and disposal. The employer shall clean, launder, and dispose of required personal protective equipment at no cost to the employee.
  - 5) Repair and replacement. The employer shall repair or replace personal protective equipment as needed to maintain its effectiveness, at no cost to the employee. The employer must pay for replacement PPE, except when the employee has lost or intentionally damaged the PPE.
  - 6) Removal. If a garment(s) is penetrated by blood or other potentially infectious materials, the garment(s) shall be removed immediately or as soon as feasible. All personal protective equipment shall be removed prior to leaving the work area. When personal protective equipment is removed, it shall be placed in an appropriately designated area or container for storage, washing, decontamination, or disposal.

Personal protective equipment is especially important during surgical procedures. Removal of impacted third molars requires a mucoperiosteal flap, bone removal, and sectioning of teeth. These actions create an open wound that allows access of bacteria into a normally sterile blood stream and surgical site. The use of personal protective equipment minimizes the transfer of bacteria from the surgical team into the surgical site.

The workplace, equipment, instruments, and materials used to remove impacted third molars are an important consideration for every dentist. Workplace conditions affect the health of the patient and surgical team. Equipment, instruments, and materials affect procedure efficiency and surgical success.

## References

- 1 HaEstrich C, Caruso T, Gruninger S, Pleva D. Musculoskeletal complaints among dental practitioners. *Occup Environ Med.* 2014;71(Suppl 1):A50.
- 2 ADA. Ergonomics and dental practice: preventing work-related musculoskeletal problems. *ADA Professional Product Review*, 2014 Nov 1;9(4).

- 3 Silverstein B. When to take action to reduce risk: work-related musculoskeletal disorders (lecture). Dental Ergonomics Summit 2000, ADA, Chicago.
- 4 Fisk JW. *Your painful neck & back*. London: Arrow, 1987.
- 5 Clark DJ. Operating microscopes and zero-defect dentistry. *Micro Restorative Dentistry*. 2008; 37–42.
- 6 Mamoun J. Use of high-magnification loupes or surgical operating microscope when performing dental extractions. *N Y State Dent J*. 2013;79(3):28–33.
- 7 Schoeffl H, Lazzeri D, Schnelzer R, Froschauer SM, Huemer GM. Optical magnification should be mandatory for microsurgery: scientific basis and clinical data contributing to quality assurance. *Arch Plast Surg*. 2013;40(2):104–8.
- 8 Pencek L. Benefits of magnification in dental hygiene practice. *J Prac Hyg* 1997;6(1):13–1.
- 9 Romeo U, Galanakis A, Lerario F, Daniele GM, Tenore G, Palaia G. Subcutaneous emphysema during third molar surgery: a case report. *Braz Dent J*. 2011;22(1):83–6.
- 10 Centers for Disease Control and Prevention. Personal protective equipment. <http://www.cdc.gov/niosh/pppe>. Accessed 20 February 2014.
- 11 Centers for Disease Control and Prevention. Recommended infection-control practices for dentistry. *MMWR*. 1993;42(No.RR-8).
- 12 Johnson B. A life stolen early. *People*. 1990 Oct 22. Retrieved 2008 Dec 24.
- 13 Centers for Disease Control and Prevention. Recommendations for prevention of HIV transmission in health-care settings. *MMWR*. 1987;36(Suppl 2S).
- 14 Global Industry Analysts, Inc. Disposable medical gloves: a global strategic business report. 2014 Apr.
- 15 United States Department of Labor, Occupational Health and Safety Administration, Healthcare wide hazards, latex allergy (website). 2015.
- 16 Hinsch M. Selecting surgical gloves. *Regent Medical Surgical Services Management*. 2000 Apr;6(4):36–42.
- 17 Larson EL. APIC guideline for hand washing and hand antisepsis in health-care settings. *Am J Infect Control*. 1995;23:251–69.
- 18 MacIntyre CR, Chughtai AA. Facemasks for the prevention of infection in healthcare and community settings. *BMJ (Clinical research ed.)*. 2015 Apr 9;350:h694.
- 19 Szymańska JA. Dental bioaerosol as an occupational hazard in a dentist's workplace. *Agric Environ Med*. 2007 Dec;14(2):203–7.
- 20 Brajkovi D et al. Quality of analgesia after lower third molar surgery: a randomised, double-blind study of levobupivacaine, bupivacaine, and lidocaine with epinephrine. *Vojnosanit Pregl*. 2015;72(1):50–56.
- 21 Su N et al. Efficacy and safety of bupivacaine versus lidocaine in dental treatments: a meta-analysis of randomised controlled trials. *International Dental Journal*. 2014;64(1):34–45.
- 22 Nutton V. *Ancient medicine*. Taylor & Francis US. Retrieved 21 Nov 2012.
- 23 United States Department of Labor, Occupational Safety and Health Administration. Bloodborne pathogens standard. In: *Regulations, Part 1910.1030*.





## 5

### Surgical Principles and Techniques

The removal of impacted third molars can be predictable. A thorough knowledge of oral anatomy, proper case selection, and good surgical principles and techniques is necessary to avoid complications. This chapter will discuss surgical principles and techniques for the removal of impacted third molars.

#### Surgical Principles

Successful impacted third molar surgery follows fundamental surgical principles. Following these principles will increase success and decrease complications. The following list is a guide for surgical protocol.

- 1) **Preparation for surgery**
- 2) **Patient management**
- 3) **Speed and efficiency**
- 4) **Surgical access**
- 5) **Osteotomy and sectioning**
- 6) **Surgical site debridement**
- 7) **Soft tissue management**
- 8) **Postoperative care**

#### 1. Preparation for Surgery

Operating room sterility is required for hospital procedures. All surfaces are sterile and the surgical team is “scrubbed in” to the operating room. Even room air is exchanged periodically to reduce airborne microbes. Patients are premedicated and prepared for surgery well before the actual procedure. All instruments are sterile and equipment is ready for use. The anesthesiologist and surgeon have completed informed consent. The surgical team is a cohesive unit that follows established protocol. This presurgical routine is completed for every patient.

Preparation for the removal of impacted third molars is also important. The operating room, instruments, equipment, medication, and documentation should be ready prior to surgery. Preparation will decrease complications and increase surgical speed and efficiency.

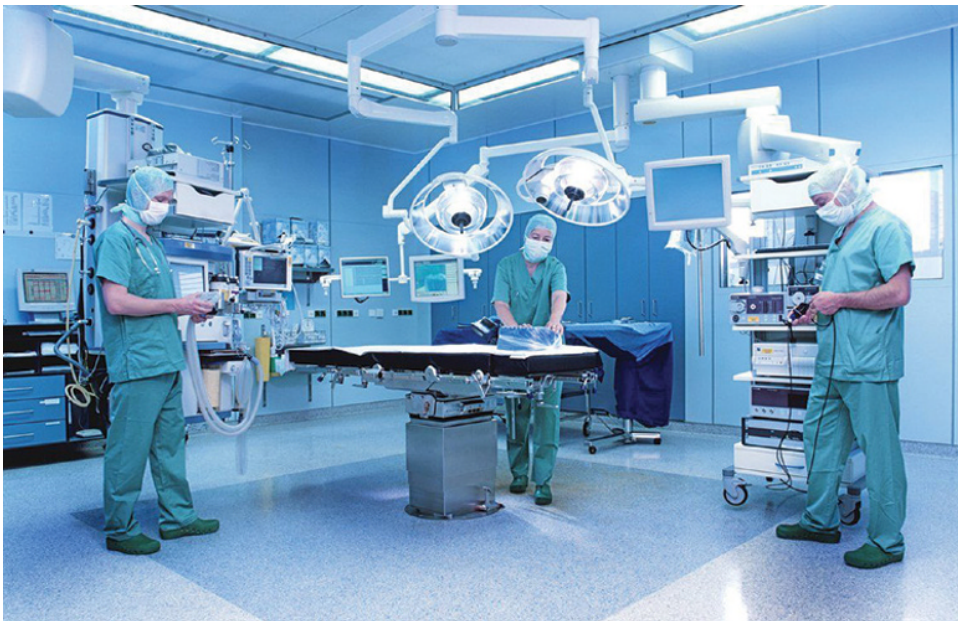### Asepsis

There is debate regarding aseptic technique for in-office oral surgery and exodontia. Several studies have shown that operating room asepsis is not necessary for minor in-office oral surgery.<sup>1</sup> There are more than  $10^{13}$  microbes on all surfaces of the body, yet the underlying tissues and the bloodstream are usually sterile. One study observed bacteremia in 55% of the patients after third-molar surgery.<sup>2</sup>

In spite of these findings, several studies have found no difference between clean and sterile conditions when used for minor in-office surgery (see Figure 5.1).

Chui et al. completed a randomized prospective study to evaluate post-operative complication rates after mandibular third molar surgery performed with either sterile or clean gloves.

The microbiological profiles of the tooth sockets and glove surfaces were also evaluated and compared. A total of 275 ASA I, non-smoking and non-drinking patients consented to be randomly assigned into two groups for lower wisdom tooth surgery, performed by operators wearing either sterile or clean gloves. All the patients returned for a post-operative assessment visit one week later. An additional 40 patients were recruited and randomized into the sterile glove group ( $n=20$ ) or the clean glove group ( $n=20$ ) for the microbiology study. Specimens were taken from the glove surfaces and the post-operative socket wounds during wisdom tooth surgery. This clinical trial showed no significant difference between the sterile and clean glove groups in the incidence of acute inflammation, acute infection, and dry sockets in the wounds. No single



**Figure 5.1** Operating room asepsis is not necessary for minor in-office oral surgery. Source: Bureau of Labor Statistics, U.S. Department of Labor, *Occupational Outlook Handbook, 2016-17 Edition*, Surgical Technologists.

peri-operative factor had a statistically significant effect on post-operative pain intensity. Most of the bacterial isolates from the clean gloves were Gram-positive cocci or spore-forming bacilli. The total number of colony forming units and the variety of bacterial isolates from the socket wounds in the sterile and clean glove groups were similar.<sup>3</sup>

The study concluded that there was no advantage in using sterile surgical gloves rather than clean gloves to minimize postoperative complications in third molar surgery. There was also no apparent relationship between the bacteria contaminating the clean glove surfaces and those isolated from the socket wounds.

Another study looked at success rates of osseointegration for implants. A retrospective analysis was done comparing the success rate of osseointegration at stage 2 of implants placed under sterile versus clean conditions. “Sterile” surgery took place in an operating room setting with strict sterile protocol. “Clean” surgery took place in a clinic setting with the critical factor that nothing touched the surface of the implant until it contacted the prepared bone site. A total of 273 implants in 61 cases were placed under sterile conditions with a fixture success rate of 98.9% and a case success rate of 95.1%; 113 implants were placed under clean conditions in 31 cases with a fixture and case success rate of 98.2% and 93.5%, respectively, as judged clinically at stage 2. The difference in the success rates was not statistically significant. The results of this analysis indicate that implant surgery can be performed under both sterile and clean conditions to achieve the same high rate of clinical osseointegration.<sup>4</sup>

A third prospective study suggested that routine exodontia can be safely performed by a surgeon wearing nonsterile but surgically clean gloves without increasing the risk of postoperative infection. One hundred twenty-four patients who showed no clinical evidence of acute infection, were not taking antibiotics, and were to undergo routine removal of erupted teeth were studied. Patients were alternately assigned to surgeons who were wearing sterile or clean gloves. Surgery was performed in the usual manner and no postoperative antibiotics were prescribed. None of the patients was found to be infected postoperatively.<sup>5</sup>

A fourth study looked at clean versus sterile technique for pediatric dental patients in the operating room. Recommendations on the need for clean or sterile technique were made based on personal experience. This retrospective analysis of 100 children and adolescents who received dental treatment in the operating room showed no statistical difference in morbidity or postoperative complications between patients treated with clean or sterile operating room techniques.<sup>6</sup>

The author recommends a common sense approach to operator asepsis when removing impacted third molars. All surfaces should be disinfected. Sterile gloves are recommended but not required. The use of an over-the-patient surgical table, as mentioned in the previous chapter, is highly recommended. The work surface or table should be covered with a sterile drape. All instruments, equipment, suction, irrigation fluid, and gauze that make direct contact with the surgical site should be sterile.

A busy oral surgeon or general dentist may remove more than 100 impacted third molars per day. It is not practical or necessary to achieve hospital operating room asepsis for these procedures.<sup>7-9</sup> Wearing personal protective equipment, sterilizing all critical instruments, and following CDC disinfection guidelines is an evidence-based and logical approach to asepsis. The operatory should be in full compliance with the Centers for Disease Control (CDC) guidelines for infection control.

According to the Centers for Disease Control, dental instruments are classified into three categories depending on the risk of transmitting infection. The classifications of critical, semicritical, and noncritical are based on the following criteria.

- 1) **Critical** instruments are those used to penetrate soft tissue or bone, or enter into or contact the bloodstream or other normally sterile tissue. They should be sterilized after each use. Sterilization is achieved by steam under pressure (autoclaving), dry heat, or heat/chemical vapor. Critical instruments include forceps, scalpels, bone chisels, scalers, and surgical burs.
- 2) **Semi-critical** instruments are those that do not penetrate soft tissues or bone but contact mucous membranes or nonintact skin, such as mirrors, reusable impression trays, and amalgam condensers. These devices also should be sterilized after each use. In some cases, however, sterilization is not feasible and, therefore, high-level disinfection is appropriate. A high-level disinfectant is registered with the U.S. Environmental Protection Agency (EPA) as a “sterilant/disinfectant” and must be labeled as such.
- 3) **Noncritical** instruments are those that come into contact only with intact skin such as external components of X-ray heads, blood pressure cuffs, and pulse oximeters. Such devices have a relatively low risk of transmitting infection and therefore may be reprocessed between patients by intermediate-level or low-level disinfection. An intermediate-level disinfectant is EPA-registered as a “hospital disinfectant” and will be labeled for “tuberculocidal” activity (e.g., phenolics, iodophors, and chlorine-containing compounds). A low-level disinfectant is EPA-registered as a “hospital disinfectant” but is not labeled for “tuberculocidal” activity (e.g., quaternary ammonium compounds). The tuberculocidal claim is used as a benchmark to measure germicidal potency. Germicides labeled as “hospital disinfectant” without a tuberculocidal claim pass potency tests for activity against three representative microorganisms: *Pseudomonas aeruginosa*, *Staphylococcus aureus*, and *Salmonella choleraesuis*.

All critical instruments used to remove third molars must be sterile. These instruments include plastic irrigation syringes and surgical suction. The dental surgeon and surgical team should wear personal protective equipment including gowns, masks, and eye protection.

### Antibiotics

Surgical preparation includes prescribing necessary antibiotics. Although the routine use of prophylactic antibiotics is controversial, a substantial number of studies have shown that the use of antibiotics decreases the incidence of alveolar osteitis, especially when bone is removed or the procedure is long or complicated.

Martin et al. reviewed the available literature regarding the use of prophylactic antibiotics for the removal of third molars. They found many studies that advocated or disapproved of the use of antibiotics in the removal of third molars. They concluded that there is no advantage in patients where bone removal is not required.<sup>10</sup>

A second study by Arora et al. found no statistically significant difference between the test group and the control group with regard to erythema, dehiscence, swelling, pain, trismus, and infection based on microbial load. The data were statistically significant for alveolar osteitis, with the occurrence of alveolar osteitis (14.58%) in the placebo

group. They concluded that postoperative antibiotics are recommended only for patients undergoing contaminated, long-duration surgery.<sup>11</sup>

A third study found that antibiotics reduced the risk of AO and wound infection only when the first dose was given before surgery. They concluded that systemic antibiotics given before surgery were effective in reducing the frequencies of AO and wound infection after third molar surgery.<sup>12</sup>

The author routinely prescribes prophylactic antibiotics. The number of postoperative complications has been extremely low, far below published percentages. More than 25,000 impacted third molars have been removed, resulting in 4 subperiosteal infections and 8 dry sockets. Most of the patients were under age 25.

### Antiseptic Mouthwash

Preoperative antiseptic mouthwash (e.g., chlorhexidine) has been shown to decrease intraoral bacterial counts and alveolar osteitis. In order to show the effectiveness of preoperative antiseptic mouthwash, Kosutic et al. undertook a prospective study of 120 patients who underwent elective surgery under general or local anesthesia. Patients were allocated to one of four groups, depending on whether the oral cavity was washed preoperatively with 1% cetrimide, chlorhexidine, povidone-iodine, or sterilized normal saline solution (control group). Aerobic and anaerobic bacterial samples were taken from the inferior vestibular mucosa before surgery, 5 min after the start of the operation, and at the end of the procedure. The results show a statistically significant reduction in bacterial counts during procedures in which antiseptics were used to wash the oral cavity preoperatively. Cetrimide solution (1%) was the most successful in reducing intraoral bacterial counts and produced the longest lasting antiseptic effect. Chlorhexidine is a good option for procedures longer than 1 hour, while povidone-iodine is recommended for procedures lasting up to 1 hour. Normal saline rinse reduced bacterial counts in the specimen taken 5 min after washing, but this short-lasting effect was due to mechanical cleansing rather than the antiseptic effect.<sup>13</sup>

Another study published in the *Journal of Maxillofacial Oral Surgery* found the incidence of alveolar osteitis was 8% when patients did not use 0.2% chlorhexidine gluconate rinse perioperatively. The incidence of AO was reduced significantly by using 0.2% chlorhexidine gluconate mouth rinse twice daily, 1 day before and 7 days after the surgical extraction of impacted mandibular third molars.<sup>14</sup>

### Pain Medication

There is evidence that nonsteroidal anti-inflammatory drugs (NSAIDs) combined with acetaminophen are more effective in controlling acute pain than narcotics. Hersh et al. found the combination of ibuprofen and acetaminophen works better than the combination of an opioid drug and acetaminophen. Furthermore, the ibuprofen and acetaminophen combination was safer than combinations that include opioids. The combination may work best when administered prior to the start of surgery.<sup>15</sup>

### Documentation

All documents, including medical history and consent forms, should be completed prior to seating the patient. The patient's vital signs should be recorded and entered in the patient's record. Informed consent should be completed with the patient prior to administering medication.

## 2. Patient Management

A successful surgical procedure requires the cooperation of the patient. Ideally, the patient will not move during the procedure. A cooperative patient improves efficiency, speed, and the quality of surgery. Select patients can have their third molars successfully removed with local anesthesia. Many factors must be considered when determining if local anesthetic without sedation is appropriate:

- Patient anxiety
- Difficult local anesthesia
- Difficult procedure
- Dentist proficiency

A study was completed by Aznar-Arasa et al. to determine if patient anxiety influences the difficulty of impacted lower third molar removal. They assessed 102 extractions done under local anesthesia. The study found that impacted lower third molar extraction is significantly more difficult in anxious patients.<sup>16</sup>

Patients with high anxiety are not good candidates for local anesthetic without sedation. The removal of impacted third molars often requires significant pressure, which will be unacceptable for the anxious patient. Constant management of the patient demands the dentist's attention. Surgical complications are more likely to occur.

Patients who are "difficult to numb" may need sedation or general anesthesia. The difficult to numb patient may have aberrant nerve pathways, low pain thresholds, or psychological issues such as dental phobias.

The difficulty of the procedure and dentist's proficiency are important factors when deciding if sedation is necessary. Difficult surgeries and inexperienced dentists will increase appointment length. Patients may become less cooperative during long procedures. These surgeries may require additional local anesthetic, sedation, or general anesthesia.

Sedation combined with local anesthetic is recommended for most impacted third molar patients. Local anesthetic alone should be reserved for cooperative patients and predictable surgeries.

## 3. Efficiency and Speed

Efficiency and speed can increase office production and improve surgical results. Many studies have shown that long surgical procedures result in increased complications and delayed healing. Bello et al. studied 120 patients with an age range of 19–42 years. Operation time was determined by the time lapse between incision and completion of suturing. The study concluded that increased operating time and advanced age are associated with more postoperative morbidity.<sup>17</sup>

Daley et al. found that the duration of an operation correlates with complications, and time longer than a statewide established standard carries higher risk. For reduced risk of complications, study data support expeditious surgical technique.<sup>18</sup>

The coordinated efforts of the surgical team can make an impressive difference in efficiency and speed. The steps required for the removal of impacted third molars should be completed in sequence for every patient. Instruments should be arranged in the order of use on the surgical table. The orderly sequence of events is a key factor in

efficiency and predictability. Surgical assistants cannot be efficient when procedures are completed in a haphazard manner.

A real-life example will illustrate efficiency. This dental team actually exists. The office is designed for the efficient removal of third molars. Three rooms are equipped with high torque, straight surgical drills, surgical tables, and a very competent surgical assistant.

General practitioner dentist Dr. X has removed thousands of third molars. Dr. X is very proficient at removing impacted third molars. There is no wasted motion. Patients are sedated. Retractors are used to improve access and visibility. A surgical table is placed over the patient. Instruments are inches from the patient's mouth. All instruments are quickly and efficiently passed to Dr. X without discussion.

A nurse anesthetist prepares each patient ahead of Dr. X. The anesthetist has more than 26 years of experience. Patients are sedated in a safe and predictable manner. Local anesthetic is provided in each quadrant. We will begin this example with patients seated in all three rooms.

Dr. X has just completed the removal of four third molars in room 1 with the anesthetist. The surgical assistant provides postoperative instructions, dismisses the patient, prepares the operatory, and seats the next patient. After completing surgery in room 1, Dr. X completes informed consent in room 3 while the patient in room 2 is sedated by the nurse anesthetist.

Dr. X then removes four third molars in room 2 with the anesthetist. The surgical assistant provides postoperative instructions, dismisses the patient, prepares the operatory, and seats the next patient. After completing surgery in room 2, Dr. X completes informed consent in room 1 while the patient in room 3 is sedated by the nurse anesthetist.

Dr. X then removes four third molars in room 3 with the anesthetist. The surgical assistant provides postoperative instructions, dismisses the patient, prepares the operatory, and seats the next patient. After completing surgery in room 3, Dr. X completes informed consent in room 2 while the patient in room 1 is sedated by the nurse anesthetist.

This organized sequence of events continues throughout the day. Dr. X removes about 120 third molars per day, 4 every 15 minutes. He works two days a week. Very few dentists remove 120 third molars in a day. However, the Dr. X example clearly illustrates how organization and teamwork can increase productivity and procedure speed while decreasing complications.

#### 4. Surgical Access

Surgical incisions should be as conservative as possible while providing unobstructed access and vision for the surgeon. This fundamental principle is especially important when removing impacted third molars. Many factors affect surgical access and vision in the oral cavity.

- Surgical site
- Mucosa
- Saliva
- Coronoid process
- Tongue

Third molars are located in the posterior portion of the mouth. Access requires a vertical releasing incision or a large envelope flap to gain access and vision. Mucosa is difficult to handle and usually requires a small needle and suture to close. Alternatively, a large envelope flap can be used to gain access. The large envelope flap is usually closed with 3.0 suture.

Saliva can be viscous or watery. Watery saliva tends to increase the flow of blood, requiring constant suction to maintain good vision. A dry mouth with viscous saliva is preferable to watery saliva.

The coronoid process can be particularly troublesome when removing maxillary third molars. The coronoid process can press against the maxillary alveolus when the mouth is opened wide. This may make surgical access very difficult. In this case a large envelope flap may be needed.

Patients may have a large, active tongue combined with a small alveolus. The tongue may actually cover the mandibular posterior teeth. A Weider retractor is recommended to retract the tongue and isolate the surgical site.

## 5. Osteotomy and Sectioning

The removal of bone and sectioning of third molars allows access for instruments and elevation of the third molar. Oral surgery drills, either compressed gas or electric, should be used to remove impacted third molars. Surgical drills have several advantages over restorative handpieces when used to remove bone and section third molars: (1) efficient cutting, (2) decreased heat, (3) decreased vibration, and (4) rear exhaust. Oral surgery drills are designed to address the limitations of the restorative handpiece (see Table 5.1).

The removal of impacted third molars requires cutting bone and sectioning teeth. Cutting efficiency is a balance between the speed and torque delivered to the bur. Air-driven restorative handpieces run at 400,000 to 500,000 rpm. Pneumatic (gas driven) and electric handpieces operate between 50,000 and 100,000 rpm, but their torque is much higher than restorative handpieces. Torque is more applicable to how efficient a handpiece functions than speed. Drills designed specifically for use in oral surgery offer smooth, constant torque that does not vary as the bur meets resistance. High torque results in more cutting efficiency and less heat at the bone–bur interface.

Several studies have shown that increased heat from drills can cause bone necrosis.<sup>19</sup> One study measured bone temperature rise during drilling of bovine cortical bone specimens. A straight surgical drill (Stryker-100) was fitted with a custom-designed speedometer for monitoring the rotational speed during the drilling, and the drill was

**Table 5.1** Surgical drill advantage compared to restorative handpiece.

Characteristic	Restorative	Pneumatic	Electric
Efficient cutting	No	Yes	Yes
Decreased vibration	No	Yes	Yes
Decreased heat	No	Yes	Yes
Possible air emphysema	Yes	No	No



mounted on a specially constructed drill press. The tests were conducted at variable speeds (20,000–100,000 rpm) and at different constant forces (1.5–9.0 N). The results revealed that the temperature rise and the duration of temperature elevation decreased with speed and force, suggesting that drilling at high speed and with large load is desirable. High torque (larger load) can only be accomplished with a straight surgical handpiece.

In a second study, Augustin et al. found that, during the drilling of bone, temperature could increase above 47°C and cause irreversible osteonecrosis. The aim of the study was to find an optimal condition where the increase in bone temperature during bone drilling process would be minimal. The study concluded that for all combinations of parameters used, external irrigation maintained the bone temperature below 47°C. External irrigation was the most important cooling factor.<sup>20</sup>

Most oral surgeons use straight surgical handpieces, which are either electric or driven by nitrogen gas that exhausts to the rear. Straight surgical handpieces use a long surgical bur, typically 44.5 to 70 mm in length. The added length creates higher torque and a more concentric bur rotation that results in less vibration and heat. The use of electric or pneumatic straight handpieces eliminates the possibility of subcutaneous air emphysema.

Although uncommon, subcutaneous air emphysema has been reported in both the medical and dental literature. This condition can be minor or life threatening. It is often the result of trauma such as stabbings, gunshot wounds, or car accidents. It has been reported in root canal treatment, dental restorations, ultrasonic scalers, standard dental air-water syringes, and extraction of maxillary and mandibular teeth. According to Reznik,<sup>21</sup>

The most common cause of subcutaneous air emphysema involves the surgical extraction of mandibular third molars. It is a result of air under pressure being driven into the subcutaneous tissues in the head and neck. It is generally associated with the use of a high-speed, air-driven, restorative handpiece which allows air to be vented toward the bur. This air under pressure can get into the subcutaneous tissues when either a flap is reflected or the gingival attachment to the alveolus is compromised. Air is forced beneath the soft tissue and subcutaneous air emphysema results.

One alternative to the straight surgical handpiece is the high-speed surgical handpiece. The Impact Air 45 and Sabra OMS45 are similar to a restorative handpiece but have higher torque and rear exhaust. They are available with fiber optics and connect to the standard dental unit. These surgical handpieces are a good choice for the general dentist who seldom removes impacted third molars.

The use of a surgical drill is a fundamental surgical principle when removing impacted third molars. Efficient bone removal with irrigation reduces vibration, heat, and bone necrosis. Surgical drills eliminate the possibility of subcutaneous air emphysema.

## 6. Surgical Site Debridement

Surgical site debridement can prevent infection and improve healing.<sup>22,23</sup> The socket should be gently irrigated with sterile saline following the removal of the impacted third

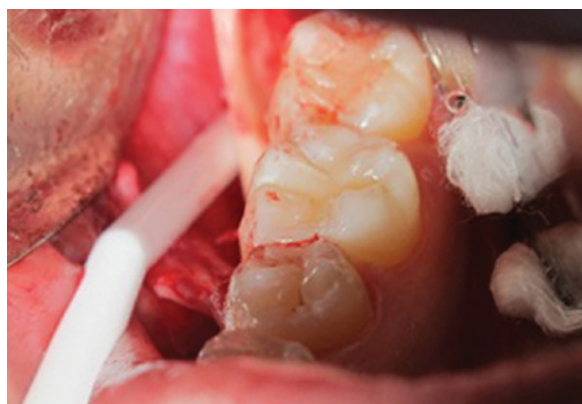molar. A small surgical suction allows for close inspection of the surgical site and removal of small particles of bone and tooth. The socket walls should be gently curetted to remove loose bone, tooth remnants, and soft tissue.

Aggressive use of the surgical curette in a mandibular third molar socket could damage nearby structures such as the fragile lingual plate, inferior alveolar nerve, or lingual nerve. The thin bone of the maxillary sinus floor can be damaged, creating an opening into the sinus. Any sharp bony edges around the socket should be smoothed using a bone file, #9 periosteal elevator, or rongeur. Soft tissue flaps accumulate debris from troughing and sectioning. All debris must be removed from flaps to prevent subperiosteal infections. Forceful irrigation between the flap and lateral border of the mandible is required to flush out debris. Irrigation is followed by close inspection and suctioning of the flap/bone interface to remove all debris (see Figure 5.2).

Contrary to aggressive flap irrigation, studies have shown that aggressive irrigation of the extraction socket can impede healing and cause alveolar osteitis. Tolstunov evaluated the role of socket irrigation with normal saline on the development of alveolar osteitis after the removal of impacted mandibular third molars.<sup>24</sup> The study was conducted as a split-mouth study. One side was irrigated with normal saline, the opposite side received no irrigation. The study found:

“A noticeable difference of dry socket syndromes (77.8% on the irrigated versus 22.2% on non-irrigated side) was demonstrated between the traditional extraction protocol versus modified approach without the end-of-surgery irrigation. The study demonstrated that the post-extraction socket bleeding is very important for proper uncomplicated socket healing. If it’s not washed away with irrigation solution at the end of extraction, the normal blood clot has a higher likelihood to form, and therefore, can potentially lead to an uncomplicated socket healing without development of alveolar osteitis. Socket bleeding at the extraction site creates a favorable environment for the formation of a blood clot—a protective dressing—necessary for a favorable osseous healing of the socket”.

Gentle irrigation of postextraction sockets is recommended.



**Figure 5.2** Inspection of flap following irrigation.

## 7. Soft Tissue Management

Most dentists have experienced frustration while attempting to remove a fractured tooth after breaking off the clinical crown. The constant and prolonged effort to remove the tooth fragment is a nightmare for both the dental surgeon and patient. The use of soft tissue flaps in exodontia can facilitate the removal of teeth and decrease trauma for the patient. Many flap designs have been proposed for the removal of impacted third molars. All of the designs have certain principles in common.

All flaps should have a broad base, which insures a good blood supply to the flap margins. The flap should be tension free and large enough to provide access to the surgical site. A tension-free flap prevents accidental tearing of delicate tissue. A large flap heals as fast as a small flap and prevents surgical errors resulting from poor access and vision. Nontension closure of soft tissue flaps is a universally accepted surgical principle. However, primary versus secondary flap closure is controversial.

Silverstein et al. stated in the *Journal of Oral Implantology*,

“Establishing non-tension primary wound closure of various soft tissue flaps is paramount for optimal postsurgical wound healing. Surgical procedures that require clinical flap manipulation, such as those used with traditional periodontal therapy, periodontal plastic cosmetic surgery, hard and soft tissue regeneration, and the excision of pathologic tissue, also require excellence in execution.”<sup>25</sup>

Primary closure may not be the best choice in every case. Several studies have found that secondary closure improves wound healing following the removal of impacted third molars when compared to primary closure. The findings of one study suggest that the procedure of choice after removal of impacted mandibular third molars is a secondary closure and healing by secondary intention. The research concluded that secondary closure appears to minimize post extraction swelling, pain, and trismus and thus contributes to enhanced patient comfort.<sup>26</sup>

Jay Reznick, DDS, MD, maxillofacial surgeon, advocates one suture between the first and second molar. The incision distal to second molars is left open to drain.<sup>27</sup> The author has used full-thickness envelope flaps with distal wedge for more than 36 years. One suture is placed distal to the second molar. The flaps heal by secondary intention. Swelling, pain, and trismus are usually minimal or gone one week following surgery. These results are consistent with many of those reported in the literature.

## 8. Postoperative Care

A review of surgical principles would not be complete without discussing postoperative care. The importance of comprehensive postoperative instructions cannot be overstated. Instructions must be reviewed orally with the patient, parent, or guardian. The postsurgical review increases compliance and reduces postoperative complications. Translation may be required when English is a second language.

Patients sedated during the removal of third molars require special postoperative attention. Many drugs used in oral and IV sedation have prolonged clearance from the body. For example, diazepam has a half-life of up to 96 hours in elderly patients.<sup>28</sup> Compliance with postoperative instructions may be negatively affected for these patients. Follow-up phone calls are recommended to review instructions and insure compliance.

Surgical sites should remain undisturbed for at least 24 hours. Initial healing begins with coagulation of blood and a blood clot within the socket. Rinsing, spitting, or drinking through a straw should be avoided. Patients should be cautioned to not chew food, brush their teeth, or touch the area of surgery for 24 hours.

Patients should not be discharged until bleeding is controlled. Most patients presenting for the removal of third molars know if they have a bleeding disorder. However, postoperative complaints of excessive bleeding should be taken seriously. The author has had one patient with an undiagnosed bleeding disorder. This case, detailed in Chapter 3, clearly illustrates the need for patient follow-up and monitoring, especially when bleeding is excessive.

A follow-up phone call, the evening of surgery, can reduce the number and severity of complications. Reinforcement of proper home care increases compliance with postoperative instructions. Patients often have questions that they forgot to ask at their appointment. How much bleeding is normal? How long should the numb sensation last? When should the swelling go away? Patients should have a one-week postoperative appointment to check for normal healing.

The surgical principles discussed in this chapter are general guidelines for success. Following these fundamental principles will streamline your procedures and help to avoid complications.

## **Surgical Technique**

There is no universally accepted technique for the removal of impacted third molars. Schools in Great Britain advocate a lingual approach for removal, while United States schools tend to favor a buccal approach. Troughing bone and sectioning teeth can be accomplished with a round bur, fissure bur, or Lindemann bone cutting bur (see Figures 5.3a, 5.3b, and 5.3c).

Third molars are usually sectioned with a surgical drill, but some operators still prefer mallet and chisel. The management of soft tissue is extremely variable. Many flap designs exist that use various incisions. Wound closure can be primary with several sutures or secondary with no sutures.

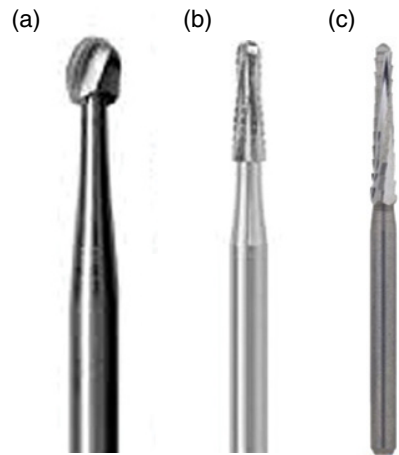The remainder of this chapter reviews various surgical techniques used for the removal of impacted third molars. A technique is recommended based on a review of the literature and the author's 36 years of experience.

### **Mandibular Third Molars**

The removal of mandibular impacted third molars can be separated into seven steps.

- 1) **Flap**
- 2) **Trough**
- 3) **Section**
- 4) **Split**
- 5) **Delivery**
- 6) **Debridement**
- 7) **Closure**

**Figure 5.3** (a) Round bur. (b) Fissure bur. (c) Lindemann bone cutting bur.



### 1. Flap

All third molar flaps are designed to separate periosteum from the underlying bone to gain surgical site access. Many flap designs and incisions have been used to remove mandibular impacted third molars (see Figures 5.4a, 5.4b, 5.4c, and 5.4d). Regardless of design, all third molar flaps should be full thickness with a broad base.

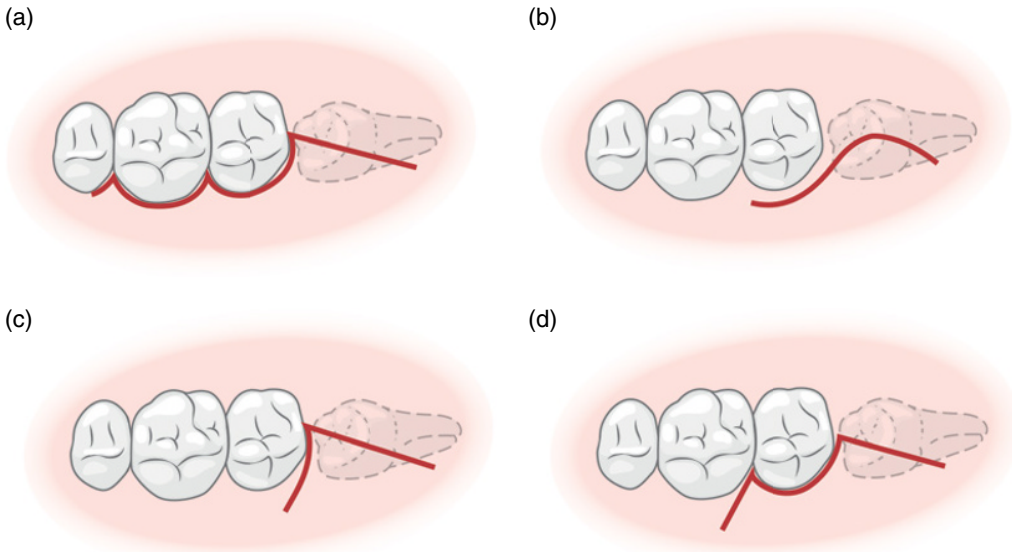
Many studies have been completed to determine the best flap design for the removal of impacted mandibular third molars. The majority of these studies found no difference in postoperative healing between different designs.

Suliaman evaluated four flap designs for postoperative pain, swelling, and trismus. Sixty patients were divided into four groups based on flap design: envelope flap, triangular, modified triangular, and S-flap (see Figures 5.4a, 5.4b, 5.4c, and 5.4d). Pain and swelling were evaluated subjectively while trismus was evaluated by measuring the maximum mouth opening ability (in mm) between the right upper and right lower central incisors. No significant difference was found in the postoperative sequel among the four groups.<sup>29</sup>

A second study compared the two most commonly used flap designs, envelope and triangular, to evaluate periodontal healing and postoperative complications. Twenty-four mandibular third molars were extracted from 12 patients with an average age of 16 years. Patients were included in the study when radiographs at the time of surgery showed that only the crown was formed (germectomy). Each patient underwent two extractions, using a triangular flap on one side and an envelope flap on the other. Periodontal probing was recorded at the preoperative visit and 7 days, 3 months, and 6 months after extraction. Postoperative complications were recorded using a questionnaire completed by the patient for the week after the extraction.

The examination performed 7 days after extractions demonstrated a deeper probing depth in all teeth examined. This increase was statistically greater for the first and second molars when an envelope flap was used. However, after 3 months, the probing depths returned to preoperative values. No significant differences were seen between the two flap designs when postoperative complications were considered.<sup>30</sup>

The author prefers large envelope flaps. Owing to the broad base, blood supply is excellent and the design facilitates easy closure and repositioning. Envelope flaps,



**Figure 5.4** Flap designs: (a) Envelope. (b) S shape. (c) Triangle. (d) Modified triangle.

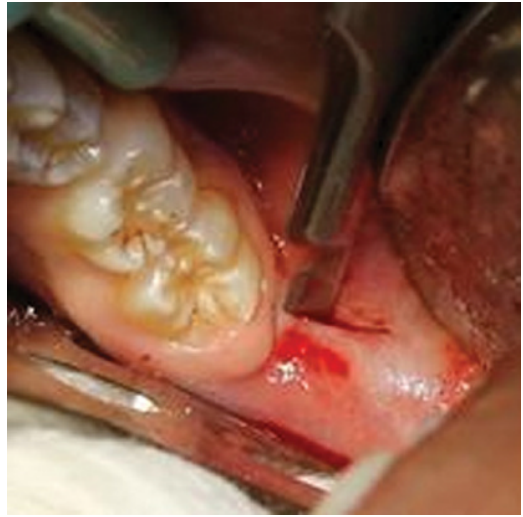completed efficiently with one incision and suture, decrease surgical time and swelling. Large envelope flaps improve access and visibility and heal as fast as small flaps. Small “conservative” flaps that require multiple incisions and/or sutures may actually increase swelling due to increased surgical time.<sup>31,32</sup>

The initial incision for a mandibular envelope starts 1–1.5 cm distal to the second molar and ends near the central groove of the second molar. The incision starts on the buccal near the external oblique ridge and can be extended as needed for access. DO NOT place incisions directly distal to the second molar. Never place incisions or use instruments on the lingual of the surgical site. You may cause lingual nerve paresthesia (see Figure 5.5). Maxillary envelope flap incisions start in the hamular notch distal to the tuberosity and end between the central groove and distal buccal cusp of the second molar. Mandibular and maxillary envelope flaps should end distal to the second premolar. The papilla between first molar and second premolar is included in the flap.

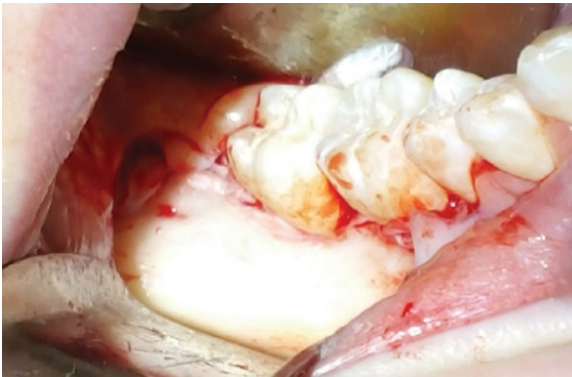The scalpel blade stays on bone throughout the incision. The incision should be completed in one smooth stroke to create a flap with clean edges. A #9 periosteal elevator is used to open the flap beginning at the anterior portion of the flap and moving posterior (see Figure 5.6).

The small end of the elevator is used to elevate the papilla between second premolar and first molar, followed by elevating the papilla between the first molar, second molar, and the tissue distal to the second molar. The flap will open easily once dissected past the mucogingival junction. The flap should be passive, mobile, and allow the placement of a Minnesota retractor in the pocket created between the lateral surface of the mandible and the flap periosteum. One significant advantage of the large envelope flap is the ability to place a Minnesota retractor in this pocket. This technique, when combined with a Weider retractor on the lingual, isolates the surgical site and improves access and

**Figure 5.5** Mandibular third molar envelope flap incision.



**Figure 5.6** #9 periosteal elevator.

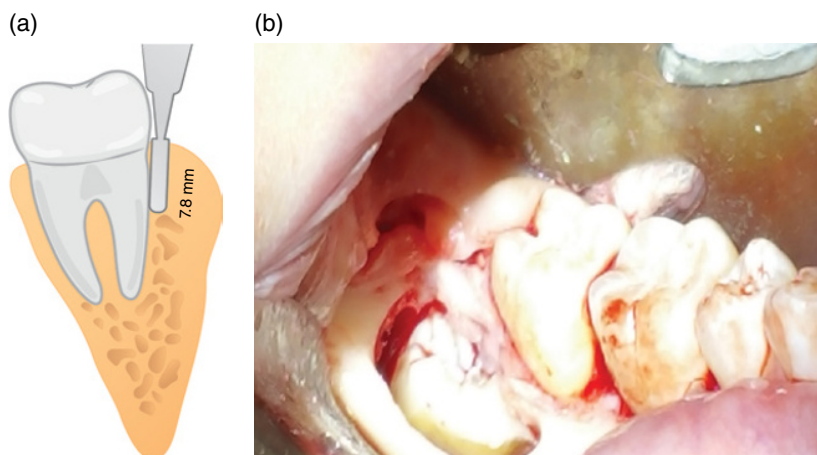


**Figure 5.7** Minnesota retractor in flap "pocket."

visibility (see Figure 5.7). Another unique characteristic of the envelope flap is the ability to extend and enlarge the flap as needed. This is not possible when releasing incisions are used.

## 2. Trough

Full bony impactions and germectomies require removal of bone covering the impaction prior to creating a trough. This can be accomplished using a surgical drill and bur. The tooth location is determined after assessing a panoramic X-ray and patient arch form.



**Figure 5.8** (a) Trough sagittal view. (b) Trough complete.



**Figure 5.9** 1703L surgical bur, working end is 7.8 mm.

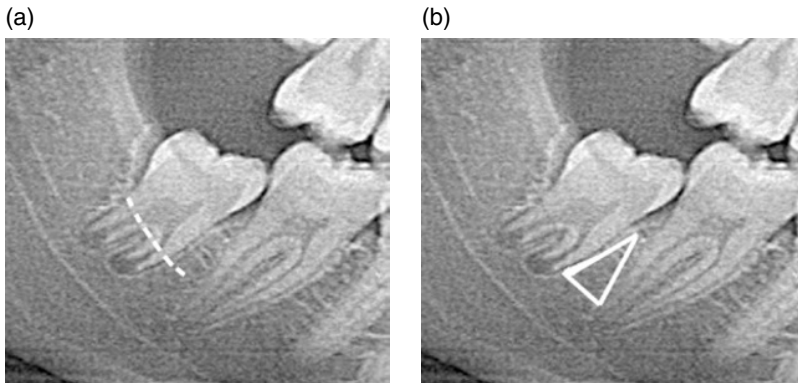
A buccal trough next to the impacted mandibular third molar creates space for elevators (see Figures 5.8a and 5.8b). The trough is completed using a surgical drill and bur. The author recommends a 1703L bur. The working end of the bur is 7.8 mm in length and 2.1 mm in diameter at the tip. The tip is rounded to facilitate smoothing bone (see Figure 5.9).

The depth of the trough can be estimated using the 7.8 mm working end of the 1703L bur. When the junction of bur shank and working end is even with the crown CEJ, the bur tip is approximately 8 mm past the CEJ. The trough should be as deep possible without injuring the IAN. The IAN is almost invariably located laterally with respect to the roots of the third molar.<sup>33</sup> It is important to visualize the local anatomy in three dimensions. The depth and path of the trough will vary based on individual anatomy. This can be assessed with a quality digital panoramic film.

The trough allows for the placement of elevators and mobilization of the tooth. It should continue in a mesial direction to a point adjacent to the distal buccal line angle of the second molar. Bone surrounding the second molar is not removed. The mesial extension of the trough facilitates placement of instruments mesial to the impacted third molar. The ideal trough follows the course of the IAN; it is deeper on the mesial than on the distal (see Figure 5.10a). The triangular area mesial to mandibular third molar roots can be considered an IAN “safe zone” (see Figure 5.10b).

The bur should hug the crown of the impacted third molar to create a narrow trough and preserve bone. The impacted tooth enamel will feel harder than the surrounding bone. This is especially true when using a straight, high-torque, surgical drill. The trough should always extend apically past the impacted third molar height of contour to prevent undercuts. Ideally, the trough should have the characteristics shown in Table 5.2.





**Figure 5.10** (a) Trough deeper on mesial. (b) IAN “safe zone.”

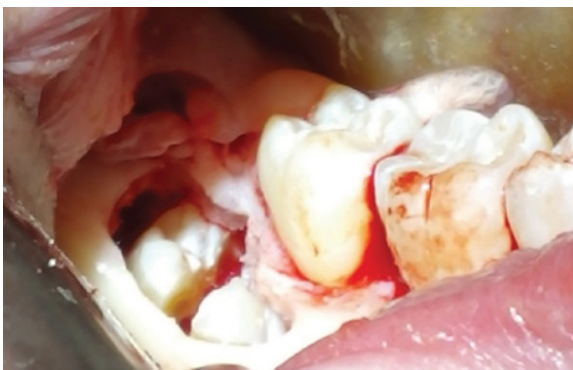
**Table 5.2** Ideal trough characteristics and rationale.

Characteristic	Rationale
Deep as possible without injury to IAN	Access for instruments and tooth mobilization
Extends mesial to second molar	Allow mesial elevator access
Deeper on mesial than on distal	IAN is more apical on mesial
Close to tooth surface	Preserves bone
Extends past height of contour	Removes undercuts

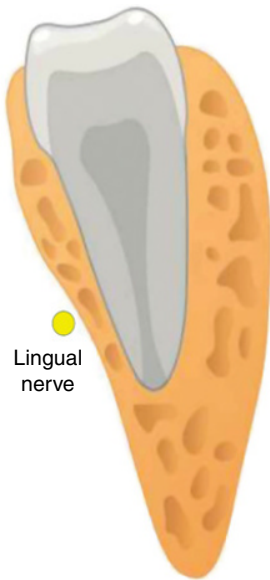
### 3. Section

Sectioning of mandibular third molars, like troughing, creates space and is best accomplished with the 1703 L bur. The section should attempt to divide the tooth into mesial and distal halves (see Figure 5.11).

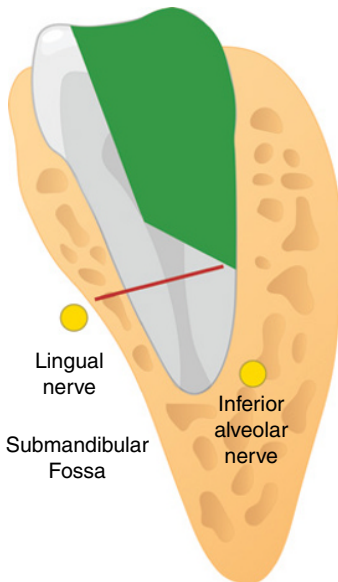
A cross-section of the mandible near the third molar reveals the submandibular fossa, a depression on the medial surface of the mandible, inferior to the mylohyoid muscle



**Figure 5.11** Section complete.



**Figure 5.12** Submandibular fossa and lingual nerve.



**Figure 5.13** Ideal zone for sectioning shown in green; red line indicates possible lingual penetration area.

(see Figure 5.12). This concavity contains the submandibular salivary gland and may contain the lingual nerve. The lingual nerve enters the sublingual space by passing between the superior constrictor and mylohyoid muscles; at this location, the nerve may be near the periosteum and at risk from trauma.

Mandibular third molar sections should cut approximately 3/4 through the tooth, stopping short of the lingual plate, submandibular fossa, and lingual nerve.<sup>34</sup> The green area in Figure 5.13 represents a safe zone for sectioning. The section should be deeper on the buccal than on the lingual. This precaution will minimize injury to the lingual nerve. The red line indicates possible lingual plate penetration when deep sections are aggressive.

The third molar section is analogous to a trough that is deeper on the mesial than on the distal. It is important to visualize local anatomy in three dimensions to avoid nerve injury. Ideally, the section should have the characteristics shown in Table 5.3.

Third molar dimensions vary considerably; however, the buccolingual diameter of third molars is normally 9.5–10.0mm. Crown length is normally 6.5–7.0mm (see Table 5.4). The 7.8mm cutting surface of the 1703L bur can be used as a gauge to avoid vital structures when troughing and sectioning. In all cases of sectioning, the cut should be kept within the tooth structure to prevent damage to the lingual tissues or the inferior alveolar canal.

#### 4. Split

An ideal section stops short of the lingual plate and inferior alveolar canal. The tooth is then “split” into separate segments. The split is usually accomplished with a straight elevator, such as a 301, 34, or 46R. The tip of the elevator is placed deep into the section and rotated along its long axis. An audible “pop” is heard, accompanied by a tactile sensation when the tooth is divided into segments (see Figure 5.14).

#### 5. Delivery

The 301 and 46R elevators are commonly used for delivery (see Figure 5.15). A Hu-Friedy EL3CSM luxating elevator is helpful when used on the straight buccal of vertical and distoangular impactions. The Cogswell B is recommended when purchase points

**Table 5.3** Ideal section characteristics and rationale.

Characteristic	Rationale
Divide tooth into mesial and distal halves	Equal halves are easier to remove
Extend to furcation	Section into individual roots
Lingual as possible without injury to LN	Avoid incomplete split
Deeper on buccal than on lingual	Avoid submandibular fossa and LN
More lingual through the crown (~3/4)	Avoid submandibular fossa and LN
Less lingual past the CEJ (~2/3)	

**Table 5.4** Third molar crown length and diameter relative to 7.8 mm bur working end.

	Crown Length	Root Length	Crown MD	Diameter FL <sup>†</sup>	Curvature	
					M	D
<b>Maxillary teeth</b>						
Central incisor	10.5	13.0	8.5	7.0	3.5	2.5
Lateral incisor	9.0	13.0	6.5	6.0	3.0	2.0
Canine	10.0	17.0	7.5	8.0	2.5	1.5
1 <sup>st</sup> premolar	8.5	14.0	7.0	9.0	1.0	0.0
2 <sup>nd</sup> premolar	8.5	14.0	7.0	9.0	1.0	0.0
First molar	7.5	B 12, L 13	10.0	11.0	1.0	0.0
Second molar	7.0	B 11 L 12	9.0	11.0	1.0	0.0
Third molar	<b>6.5</b>	11	8.5	<b>10.0</b>	1.0	0.0
<b>Mandibular teeth</b>						
Central incisor	9.0	12.5	5.0	6.0	3.0	2.0
Lateral incisor	9.5	14.0	5.5	6.0	3.0	2.0
Canine	11.0	16.0	7.0	7–5	2.5	1.0
1 <sup>st</sup> premolar	8.5	14.0	7.0	7.5	1.0	0.0
2 <sup>nd</sup> premolar	8.0	14.5	7.0	8.0	1.0	0.0
First molar	7.5	14.0	11.0	10.5	1.0	0.0
Second molar	7.0	13.0	10.5	10.0	1.0	0.0
Third molar	<b>7.0</b>	11.0	10.5	<b>9.5</b>	1.0	0.0

\*Average measurements in millimeters.

<sup>†</sup>FL = faciolingual, buccolingual, labiolingual.

Source: Adapted from Ash and Nelson [35].

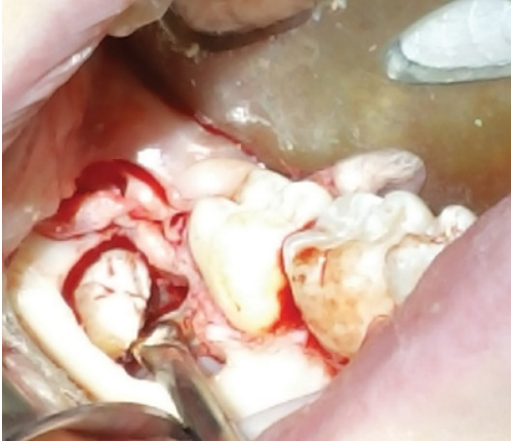

Figure 5.14 Split with 46R elevator.

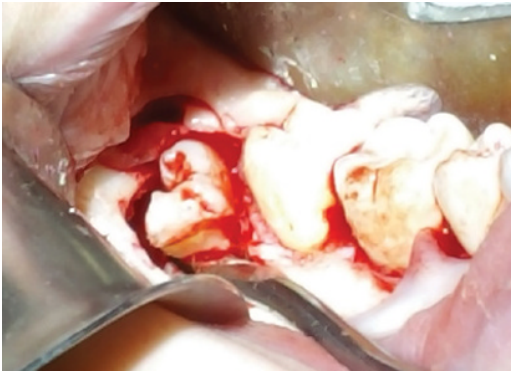


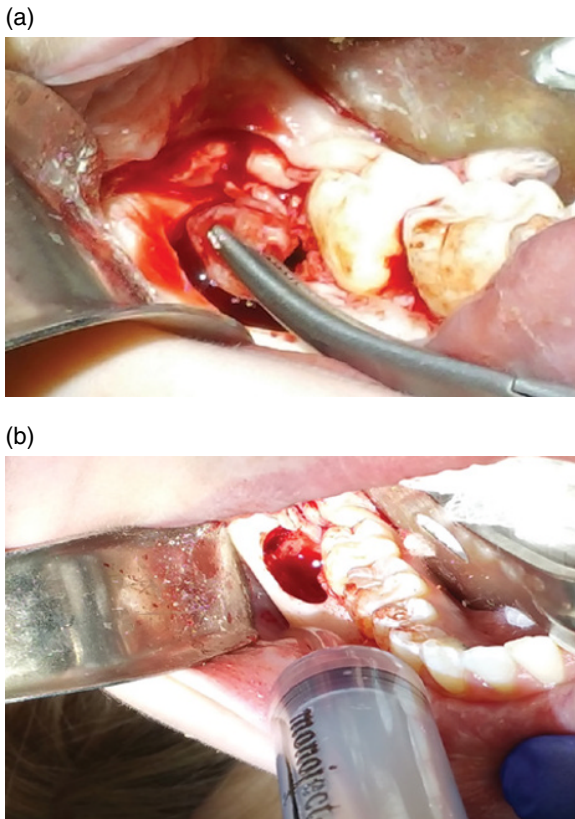
Figure 5.15 Elevator delivery with 46R.

are placed. The Cogswell B has smooth surfaces at the tip and is less likely to cause fracture than a Crane pick. The purchase point should be placed deep into substantial tooth structure to elevate the tooth segment without fracture. Excessive force can result in root fracture, unnecessary bone loss, or even fracture of the mandible. An adequate trough and section provide an unobstructed pathway for delivery. Multiple sections may be required.

## 6. Debridement

The surgical site must be thoroughly cleansed following the removal of third molars. This includes debridement of all particulate bone, tooth fragments, soft tissue, and follicle. Sharp or rough edges around the socket should be removed. This is accomplished with double-ended surgical curettes, 2/4 molt curettes, bone files, burs, rongeurs, and Kelly hemostats. The socket is gently irrigated, suctioned, and inspected with magnification (see Figure 5.16a and 5.16b).

Debridement includes irrigation of the full thickness flap. Irrigation is completed with a Monoject 412 syringe and sterile saline. The passive flap is retracted and saline is injected with pressure between the lateral surface of the mandible and flap. The flap is



**Figure 5.16** (a) Debridement of socket. (b) Thorough irrigation of flap.

suctioned and inspected with magnification and loupe light to be certain that all debris has been removed. A small suction tip is necessary to reach the apical portion of the flap.

Meticulous debridement of the flap is necessary to avoid subperiosteal infections. Fifty percent of third molar postoperative infections are localized subperiosteal abscess-type infections occurring approximately 2–4 weeks after surgery.<sup>36</sup> This infection results from debris left in the flap following surgery. Healing is normal at one week, followed by acute swelling 2–4 weeks after the procedure. Definitive treatment involves reopening the flap, debridement, irrigation, and antibiotics.

## 7. Closure

Primary closure of lower third molar surgical sites is controversial. Some surgeons are proponents of tight suturing to assist in hemostasis, whereas other surgeons believe that loose suturing leads to less edema and allows for drainage of the wound.<sup>37</sup>

A study conducted in 2005 by Pasqualini et al. compared postoperative pain and swelling following removal of impacted mandibular third molars. Two hundred patients with impacted third molars were randomly divided into two groups of 100. Panoramic radiographs were taken to assess degree of eruption and angulation of third molars. Teeth were extracted, and in Group 1 the surgical site was closed by primary intention. In Group 2 a distal wedge of tissue was removed adjacent to the second molar to obtain

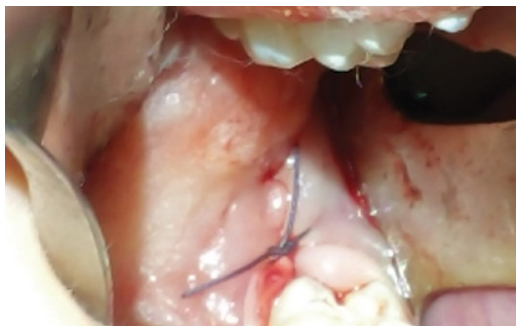

Figure 5.17 Single suture closure.

secondary healing. Swelling and pain were evaluated for 7 days after surgery. Pain and swelling were less severe with secondary closure than with primary closure.<sup>38</sup>

A second study in 2012 found similar results. Chaudhary et al. studied the effects of primary versus secondary closure on pain and swelling following the removal of impacted mandibular third molars.<sup>39</sup> Twelve patients under 30 years of age were divided into two groups. In Group A, closure was done by primary intention and in Group B by secondary closure. A comparison between both groups was done with regard to post-operative pain and swelling. The study found that secondary closure is better than primary closure for removal of impacted mandibular third molar with regard to postoperative pain and swelling.

The author prefers an envelope flap with distal wedge and secondary closure using PGA suture. A simple interrupted suture can be placed just distal to the second molar or more distally over the incision (see Figure 5.17). Care must be taken to keep the suture needle from penetrating tissue below the level of the lingual alveolar bone. Penetrating the tissue below this level increases the risk of injury to the lingual nerve.<sup>40</sup>

Mandibular third molar flaps can be closed with 3.0 silk, gut, or polyglycolic acid suture (PGA). Non-absorbable silk sutures should not remain in place for more than a week due to increased risk of infection. Gut sutures normally resorb in 3 to 5 days, chromic gut in 10 days. A third possibility is PGA, which handles like silk and resorbs in two to three weeks. In delicate nonkeratinized mucosa, 5.0 suture with a small needle is preferred. This size suture is recommended to close vertical releasing incisions or tears in the flap. Proper flap closure requires that the suture needle be held approximately 2/3 of the way from the tip of the needle. Holding a 3.0 suture needle in this position allows the needle and suture to easily penetrate the flap's mobile buccal tissue and fixed lingual tissue in one pass. The tying technique is a double throw, followed by a locking throw in the opposite direction. Although nonabsorbable silk sutures encourage patients to return for suture removal, some surgeons prefer sutures that will resorb if patients do not return. Pressure should be held on the repositioned flap for 10–15 seconds to adapt the soft tissue and papilla.

### Maxillary Third Molars

The removal of maxillary impacted third molars can be separated into four steps:

- 1) **Flap**
- 2) **Delivery**

- 3) Debridement
- 4) Closure

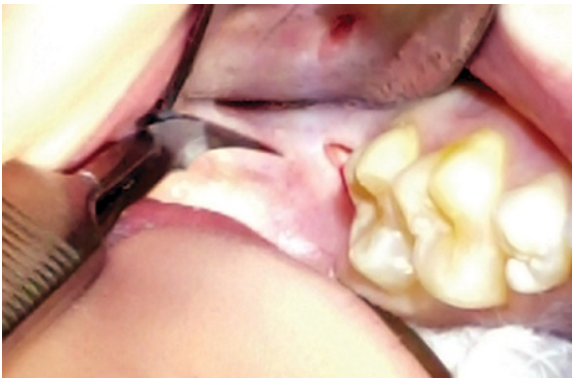
### 1. Flap

The maxillary third molar flap is similar to the mandibular third molar flap. A large envelope flap is recommended. The initial incision begins distal to the tuberosity near the hamular notch. A #12 scalpel blade improves access distal to the tuberosity. The incision ends between the second molar central groove and distobuccal cusp. The tip of the #12 scalpel blade should remain on bone during the incision. The papilla distal to the second premolar is included in the flap (see Figures 5.18a and 5.18b).

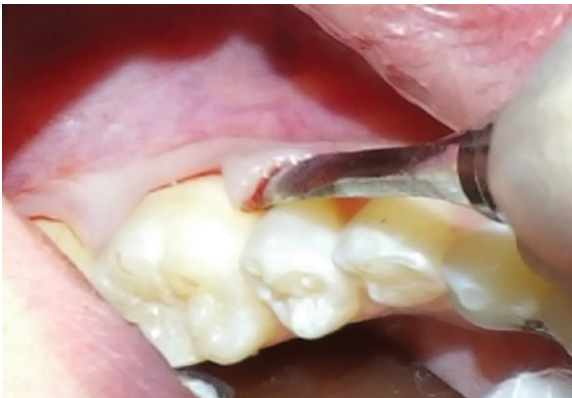The flap is reflected with a #9 periosteal elevator beyond the mucogingival junction. A Minnesota retractor is used to retract the flap. The flap will be easier to retract when incisions are made ending at the distobuccal cusp of the second molar. This is important when removing deep impactions.

Maxillary flap incisions distal to the second molar should be completed with caution. Incisions that are too far distal and buccal can expose the buccal fat pad. Exposure of the buccal fat pad results in fat extruding from the incision site and restricting vision.

(a)



(b)



**Figure 5.18** (a) #12 blade improves access. (b) Flap includes premolar papilla.

High-volume suction should be avoided to prevent further extrusion of the fat pad. Experienced surgeons may be able to work around the fat and complete the procedure.

Surgeons with limited experience should attempt to reposition the extruded fat as much as possible and abort the procedure. The surgical site usually heals without complications and the procedure can be attempted again when healing is complete. Sutures are usually not needed.

## 2. Delivery

Most impacted maxillary third molars can be easily removed with 301 or 46R elevators (see Figure 5.19).

Flag elevators are especially useful when access is limited. Examples include the 190/191, Woodson, Potts, or other paired elevators. A Minnesota retractor, periosteal elevator, or Laster retractor should be placed distal to the tuberosity to prevent displacement into the infratemporal fossa (see Figures 5.20a and 5.20b). The risk of this complication increases when the third molar is deep and palatal, which is often the case with germectomies. Although rare, this is a serious complication due to the contents of the infratemporal fossa. The infratemporal fossa contains many vital structures including the pterygoid plexus, maxillary artery, and the mandibular nerve. Damage to these structures can affect function and may be fatal.

The overlying bone in the maxilla is typically thin and can be removed with hand instruments such as a #9 periosteal elevator. The pointed end of the elevator is used to pry away buccal bone covering the tooth (see Figures 5.21a and 5.21b).

In some cases, a surgical drill may be required when maxillary third molars are in a palatal position or buccal bone is thick. The drill is used to create a shallow vertical groove in the buccal bone distal to the second molar. The #9 periosteal elevator can be placed in the groove to remove buccal bone and gain access to the third molar. Once access is gained, a 301 straight elevator, EL3CSM, 46R elevator, 190/191, or similar instrument is used to deliver the tooth.

Delivery is usually easier in the maxilla than in the mandible for two reasons. First, the maxillary impaction is usually covered with thin compact bone when compared to the mandibular impaction. Second, the periodontal ligament space is wide because the impacted tooth has not experienced occlusal loading.<sup>41</sup> Due to these factors, sectioning

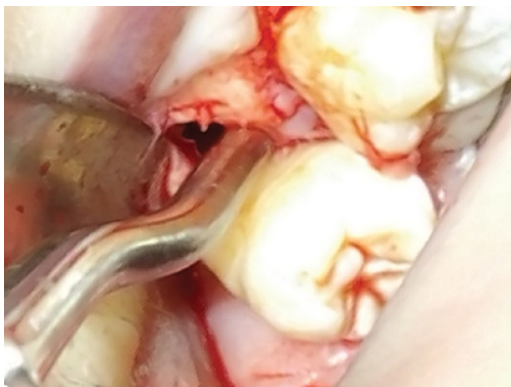
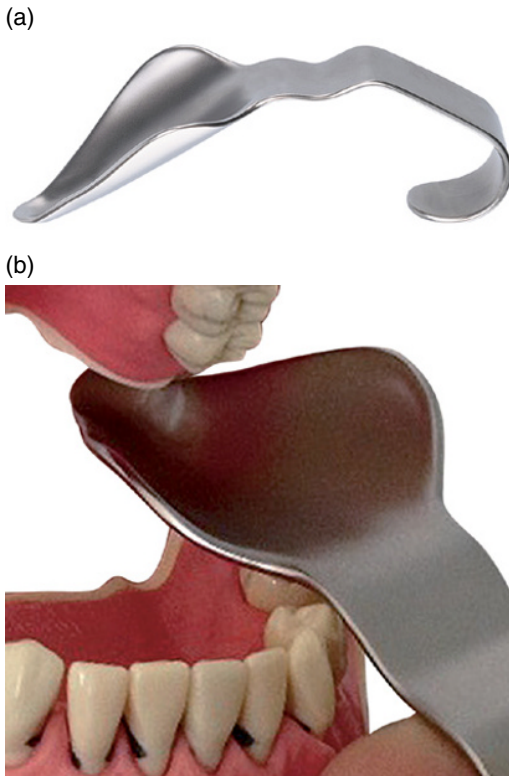
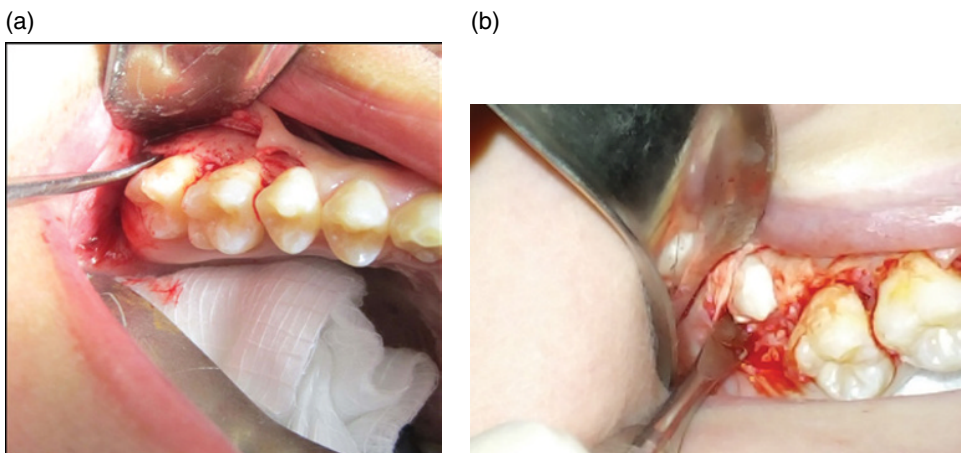


Figure 5.19 Delivery with 46R elevator.

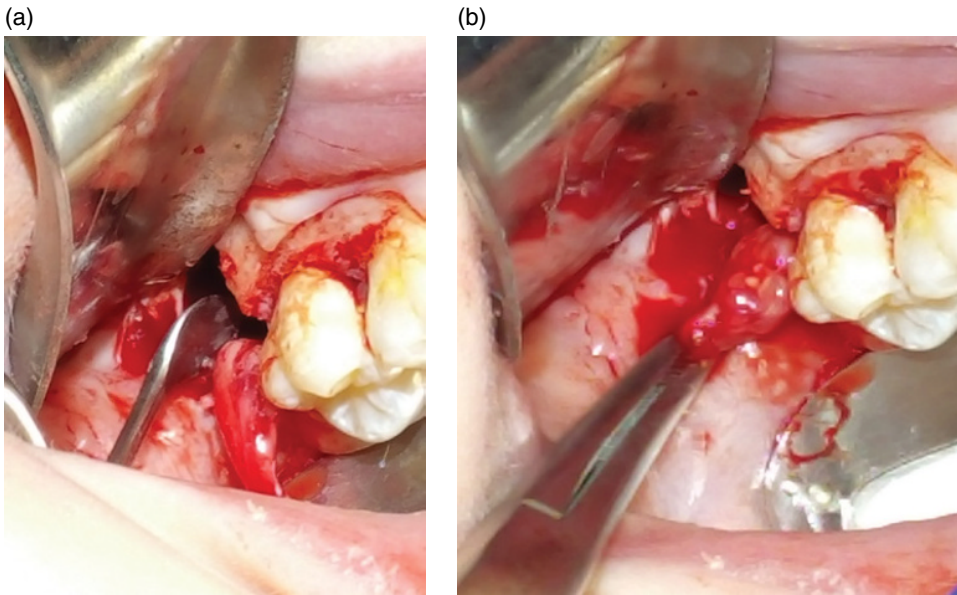




**Figure 5.20** (a) Laster retractor. (b) Laster retractor in position. *Source:* Reproduced by permission of Salvin Dental.



**Figure 5.21** (a and b) Removal of buccal bone with #9 periosteal elevator.



**Figure 5.22** (a) Removal of tissue with curette. (b) Removal of tissue with hemostat.

is normally not required to remove a maxillary impaction. However, it should be noted that a difficult maxillary impaction is much more difficult than a difficult mandibular impaction due to limited access and vision.

Maxillary third molars with divergent roots or thick cortical bone may require sectioning. This should be considered only as a last resort because small segments can be displaced into the sinus or infratemporal fossa.

### 3. Debridement

The surgical site should be thoroughly debrided with a surgical curette. All bone fragments and tissue should be removed from the socket. Sharp edges should be smoothed. The surgical site should be suctioned and palpated to confirm that all sharp edges have been removed. Irrigation is not required unless a surgical drill was used (see Figures 5.22a and 5.22b).

### 4. Closure

Maxillary third molar envelope flaps usually do not require suturing because they are held in place by gravity, the coronoid process, and the surrounding soft tissues. Pressure should be held on the repositioned flap for 10–15 seconds to adapt the soft tissue and papilla (see Figure 5.23).

## Angulations

The recommended surgical steps used for the removal of impacted mandibular third molars are universal. However, individual angulations require minor modifications when sectioning and elevating.

### Mesioangular

Mesioangular impactions usually offer good access for sectioning. A straight surgical handpiece is used to section the long axis of the tooth. The most common problem, when sectioning along the tooth's axis, is not dividing the tooth into equal halves. This is caused by the second molar obstructing access and results in a section that is too far distal. The solution to this problem involves making the section 1–2 mm more mesial than originally planned. Sectioning more mesial is especially important when sectioning vertical and distoangular impactions.

When roots are divergent, the section should end near the furcation. The distal root is removed first after splitting the tooth through the furcation. The mesial root can be elevated distally into the available space (see Figure 5.24).

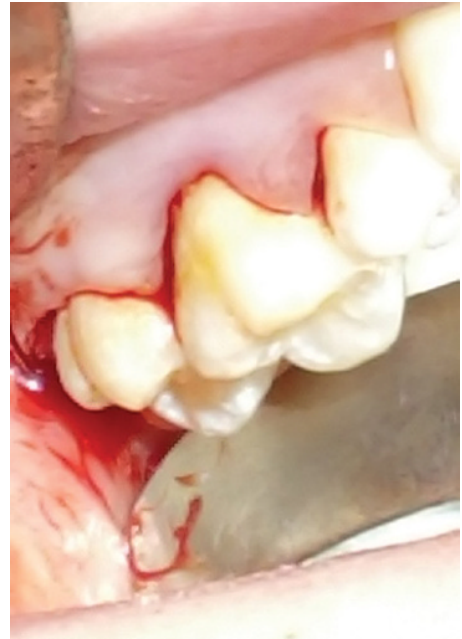

Figure 5.23 Passive closure without suture.

### Horizontal

The crown of horizontal impactions is often “trapped” under the height of contour of the second molar. A straight surgical handpiece is used to section the crown. The objective is to remove the crown and create space for the subsequent removal of the roots. The sectioned crown must be narrower on the bottom than on the top to facilitate removal (see Figure 5.25). Multiple crown sections are often required.

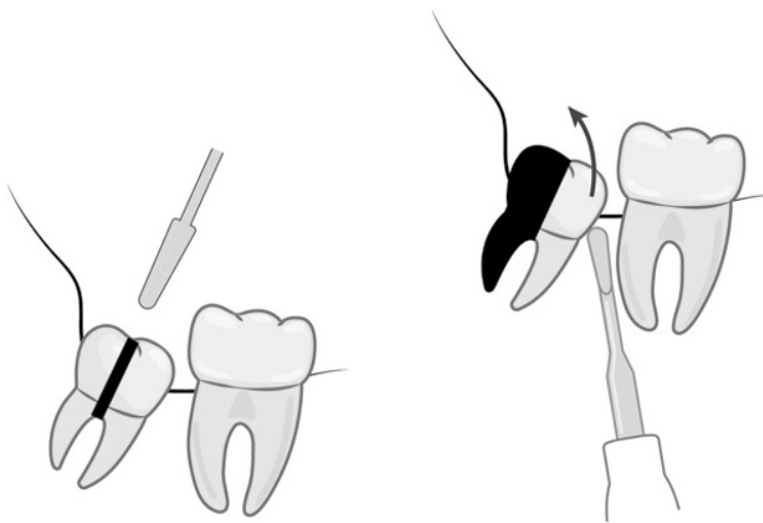
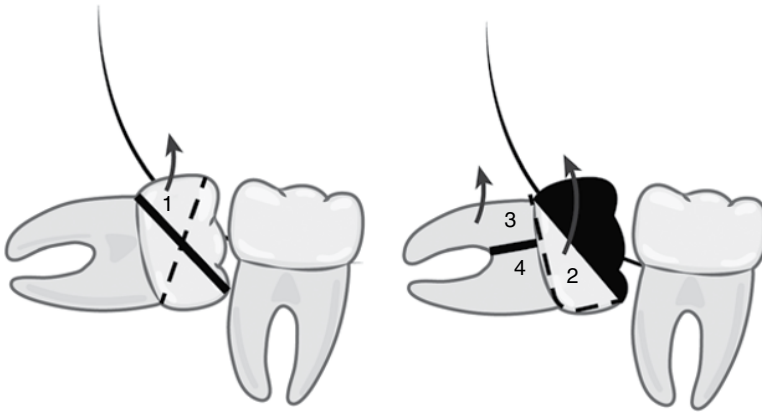


Figure 5.24 Technique for removal of mesioangular impaction. Left: section. Right: elevation.

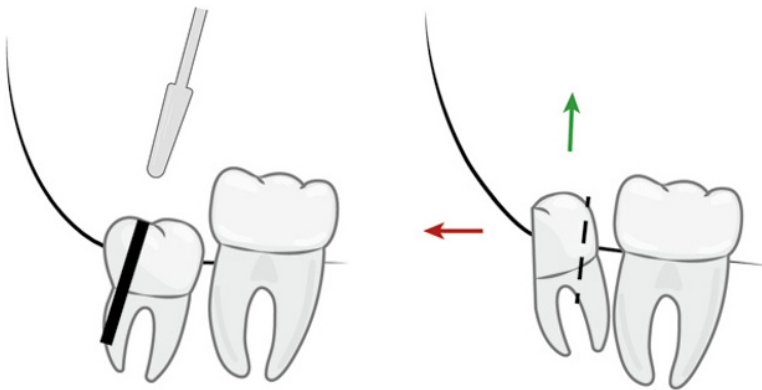


**Figure 5.25** Horizontal section should be narrow apically and wide coronally (solid line).

Following crown removal, remaining roots are moved mesial into the vacated space, where they are easily removed. This is usually accomplished with a Cryer elevator or similar flag elevator. A purchase point can be helpful. Divergent or hooked roots may require sectioning through the furcation. The distal root is removed followed by the mesial root.

### Vertical

Deep vertical impactions always require sectioning. A 50% section on the long axis of the tooth is usually not possible due to limited access. However, sectioning as close as possible to the long axis is the goal. This usually results in sectioning a distal portion of the tooth. A purchase point and Cogswell B or luxating elevator can be used to move the tooth in a straight vertical direction (green arrow, Figure 5.26) until obstructions block further elevation. Repeated sections may be required as the tooth is slowly elevated from its socket. Avoid forces that move the tooth in a distal direction (red arrow, Figure 5.26).



**Figure 5.26** Vertical impactions usually require slow elevation and multiple sections.

### Distoangular

Most distoangular impactions will be more difficult than expected. Sectioning always results in a less than ideal section. The steps required for removal of a distoangular impaction are very similar to the vertical impaction (Figure 5.26). Removal of distal bone may be required while keeping in mind the possibility of lingual nerve injury.

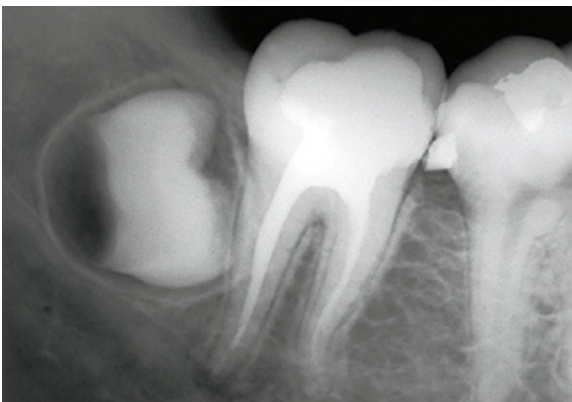Following the initial section, the tooth should be slowly elevated and sectioned repeatedly as needed. A purchase point and Cogswell B, or luxating elevator, can be used to move the tooth in a straight vertical direction (green arrow, Figure 5.26). Removal of the crown followed by the roots may be necessary. Never remove the crown until the tooth is luxated and elevated.

### Germectomy

There is little debate regarding the benefits of early third molar removal (Chapter 2). The removal of third molars prior to full root development, during the teenage years, is predictable and decreases surgical complications. Most surgeons agree that the ideal time to remove third molars is when the roots are 1/2–3/4 developed, usually in the later teenage years. Eruption follows the development of roots and can be seen as early as 13–14 years of age or as late as the third decade of life. The third molar crown is typically visible on radiographs by 14–15 years of age (see Figure 5.27).

Germectomy is defined as the removal of teeth with one-third or less root development. The removal of third molars with little or no root development is controversial. Detractors argue against removal prior to root development for two reasons; (1) the tooth has not erupted and is covered with bone and (2) the tooth can “spin” or move in the bone crypt.

Advocates argue that removal of third molars as germectomies is predictable with fewer complications because roots have not developed (see Box 5.1). Dilacerated, divergent, or thin roots are no longer subject to fracture with displacement of fragments into the maxillary sinus, infratemporal fossa, or submandibular space. Modified technique for different tooth angulations is not necessary. The surgical technique is the same for all germectomies. Sinus openings are reduced and nerve injuries from third molar roots



**Figure 5.27** Third molar crown at 14–15 years of age.

**Box 5.1 Removal of third molars at the germectomy stage of development has many advantages.**

Germectomy advantages		
Eliminates fractured roots	Eliminates displaced roots	Eliminates hooked roots
Eliminates divergent roots	Eliminates tooth angulation	Decreases nerve injury
Decreases sinus openings	Increases follicular space	Increases predictability

virtually eliminated. The developing tooth has a large follicular space that allows for easy placement of elevators and reduced force when elevating. The removal of third molars becomes routine and predictable.

Chiapasco et al. found no difference in the incidence of complications when removing third molars from two different age groups, 9–16 and 17–24.<sup>42</sup> The study included 1500 mandibular impactions for 868 patients aged 9 to 67 years. The patients were divided into three groups:

Group A, patients aged 9 to 16, including germectomies

Group B, patients aged 17 to 24

Group C, patients older than 24

The incidence of complications was 2.6% in group A, 2.8% in group B, and 7.4% in group C. All complications were temporary except in one instance of inferior alveolar nerve paresthesia that occurred in a group C patient. This study showed no significant difference in the complication rate between group A (including germectomies) and group B, but complications significantly increased in group C.

The germectomy procedure always requires a full-thickness mucoperiosteal flap and bone removal. The mandibular tooth germ is always sectioned and may require a second section in a mesial–distal direction. The section creates a flat surface that prevents “spinning.” Elevators are often unnecessary. The tooth fragments can be removed with cotton pliers or similar instruments. Maxillary germectomies can be problematic when they are in a deep Gregory Pell class C position. Maxillary germectomies in Gregory Pell A and B positions are easily removed with minimal force due to the large follicular space. One exception is the maxillary germectomy positioned near the palate. **Extreme caution** must be used when removing these teeth due to their proximity to the infratemporal fossa.

It is not always possible to remove impacted third molars at the ideal time when roots are 1/2–3/4 developed. Dentists proficient in the removal of impacted third molars should consider removal as germectomies when access and position is favorable.

## References

- 1 Li X, Kolltveit KM, Tronstad L, Olsen I. Systemic diseases caused by oral infection. Clin Microbiol Rev. 2000 Oct;13(4):547–58.
- 2 Heimdahl A, Hall G, Hedberg M, Sandberg H, Söder PO, Tunér K, Nord CE. Detection and quantitation by lysis-filtration of bacteremia after different oral surgical procedures. J Clin Microbiol. 1990;28(10):2205–9.

- 3 Chiu WK et al. A comparison of post-operative complications following wisdom tooth surgery performed with sterile or clean gloves. *International J Oral Maxillofacial Surgery*. 2006;35(2):174–9.
- 4 Scharf DR, Tarnow DP. Success rates of osseointegration for implants placed under sterile versus clean conditions. *J Periodontol*. 1993 Oct;64(10):954–6.
- 5 Giglio JA, Rowland RW, Laskin DM, Grenevicki L, Roland RW. The use of sterile versus nonsterile gloves during out-patient exodontia. *Quintessence Int*. 1993;24(8):543–5.
- 6 Helpin ML, Duncan WK. Clean vs sterile technique for pediatric dental patients in the operating room, *ASDC J Dent Child*. 1988;55(6):449–51.
- 7 Heimdahl A, Hall G, Hedberg M, Sandberg H, Söder PO, Tunér K, Nord CE. Detection and quantitation by lysis-filtration of bacteremia after different oral surgical procedures. *J Clin Microbiol*. 1990;28(10):2205–9.
- 8 Chiu WK et al. A comparison of post-operative complications following wisdom tooth surgery performed with sterile or clean gloves. *International J Oral Maxillofacial Surgery*. 2006;35(2):174–9.
- 9 Giglio JA, Rowland RW, Laskin DM, Grenevicki L, Roland RW. The use of sterile versus nonsterile gloves during out-patient exodontia. *Quintessence Int*. 1993;24(8):543–5.
- 10 Martin MV, Kanatas AN, Hardy P. Antibiotic prophylaxis and third molar surgery. *Brit Dent J*. 2005;198:327–30.
- 11 Arora A, Roychoudhury A, Bhutia O, Pandey S, Singh S, Das BK. Antibiotics in third molar extraction: are they really necessary? A non-inferiority randomized controlled trial. *Natl J Maxillofac Surg*. 2014 Jul-Dec;5(2):166–71.
- 12 Ren Y-F, Malmstrom HS. Effectiveness of antibiotic prophylaxis in third molar surgery: a meta-analysis of randomized controlled clinical trials. *Oral Maxillofac Surg*. 2007;65(10):1909–21.
- 13 Kosutic D, Uglesic V, Perkovic D, Persic Z, Solman L, Lupi-Ferandin S, Knezevic P, Sokler K, Knezevic G. Preoperative antiseptics in clean/contaminated maxillofacial and oral surgery: prospective randomized study. *Int J Oral Maxillofac Surg*. 2009;38(2):160–5.
- 14 Sridhar V, Wali GG, Shyla HN. Evaluation of the perioperative use of 0.2% chlorhexidine gluconate for the prevention of alveolar osteitis after the extraction of impacted mandibular third molars: a clinical study. *J Maxillofac Oral Surg*. 2011 Jun;10(2):101–11.
- 15 Hersh EV, Moore PA. Combining ibuprofen and acetaminophen for acute pain management after third-molar extractions. *J Am Dent Assoc*. 2013 Aug 1;144:898–908.
- 16 Aznar-Arasa L, Figueiredo RL, Valmaseda-Castellón, Gay-Escoda, Patient anxiety and surgical difficulty in impacted lower third molar extractions: a prospective cohort study. *Int J Oral Maxillofac Surg*. 2014 Sep;43(9):113–6.
- 17 Bello SA, Adeyemo WL, Bamgbose BO, Obi EV, Adeyinka AA, Effect of age, impaction types and operative time on inflammatory tissue reactions following lower third molar surgery. *Head Face Med*. 2011;7:8.
- 18 Daley BJ, Cecil, Clarke P, Cofer JB, Guillamondegui OD. How slow is too slow? Correlation of operative time to complications: an analysis from the Tennessee Surgical Quality Collaborative. *J Am Coll Surg*. 2015 Apr;220(4):550–8.

- 19 Symington JM. Effect of drill speed on bone temperature. *Int J Oral Maxillofac Surg*. October 1996;25(5):394–9.
- 20 Augustin G et al. Thermal osteonecrosis and bone drilling parameters revisited. *Arch Orthop Trauma Surg*. 2008 Jan;128(1):71–7.
21. Reznick JB. Avoiding a very preventable surgical complication. *Dentaltown Magazine*. 2010 August.
- 22 Robinson PD. *Tooth extraction, a practical guide*. Wright Elsevier, 2010: 77.
- 23 Hooley JR, Whitacre RJ. *Assessment of and surgery for impacted third molars*, 3rd edition. Stoma Press, Inc., 1983: 62.
- 24 Tolstunov L. Influence of immediate post-extraction socket irrigation on development of alveolar osteitis after mandibular third molar removal: a prospective split-mouth study, *Brit Dent J*. 2012;213:597–601.
- 25 Silverstein LH, Kurtzman GM, Shatz PC. Suturing for optimal soft-tissue management. *J Oral Implantol*. 2009;35(2):82–90.
- 26 Maria A, Malik M, Virang P, Comparison of primary and secondary closure of the surgical wound after removal of impacted mandibular third molars. *J Maxillofac Oral Surg*. 2012 Sep;11(3):276–28.
- 27 Reznick JB, Principles of flap design and closure, *Dentaltown Magazine*, 2016 April.
- 28 Ruscin M, Linnebur SA, *Pharmacokinetics in the Elderly*. MSD Manual. 2014 June.
- 29 Sulieman MS. Clinical evaluation of the effect of four flap designs on the post-operative sequel (pain, swelling and trismus) following lower third molar surgery. *Al-Rafidain Dent J*. 2005;5(1):24–32.
- 30 Monaco G1, Daprile G, Tavernese L, Corinaldesi G, Marchetti C. Mandibular third molar removal in young patients: an evaluation of 2 different flap designs. *J Oral Maxillofac Surg*. 2009 Jan;67(1):15–21.
- 31 Bello SA, Adeyemo WL, Bamgbose BO, Obi EV, Adeyinka AA, Effect of age, impaction types and operative time on inflammatory tissue reactions following lower third molar surgery. *Head Face Med*. 2011;7:8.
- 32 Daley BJ, Cecil, Clarke P, Cofer JB, Guillamondegui OD. How slow is too slow? Correlation of operative time to complications: an analysis from the Tennessee Surgical Quality Collaborative. *J Am Coll Surg*. 2015 Apr;220(4):550–8.
- 33 Farish SE, Bouloux GF. General technique of third molar removal. *Oral Maxillofacial Surg Clin N Am*. 2007;19:23–43.
- 34 Farish SE, Bouloux GF. General technique of third molar removal. *Oral Maxillofacial Surg Clin N Am*. 2007;19:23–43.
- 35 Ash MM, Nelson SJ. *Wheeler’s dental anatomy, physiology, and occlusion*, 8th edition. Philadelphia: WB Saunders. 2003.
- 36 Figueiredo R, Valmaseda-Castellon E, and Berini-Aytes L. Incidence and clinical features of delayed-onset infections after extraction of lower third molars. *Oral Surg Oral Med Oral Pathol Oral Radiol Endod*. 2005;99:265.
- 37 Chaudhary M, Singh M, Singh S, Singh SP, and Kaur G. Primary and secondary closure technique following removal of impacted mandibular third molars: a comparative study. *Natl J Maxillofac Surg*. 2012 Jan-Jun;3(1):10–4.
- 38 Pasqualini D, Cocero N, Castella A, Mela L, Bracco P. Primary and secondary closure of the surgical wound after removal of impacted mandibular third molars: a comparative study. *Int J Oral Maxillofac Surg*. 2005 Jan;34(1):52–7.



- 39 Chaudhary M, Singh M, Singh S, Singh SP, and Kaur G. Primary and secondary closure technique following removal of impacted mandibular third molars: a comparative study. *Natl J Maxillofac Surg*. 2012 Jan-Jun;3(1):10–4.
- 40 Reznick JB. Principles of flap design and closure. *Dentaltown Magazine*. 2016 April.
- 41 Farish SE, Bouloux GE, General technique of third molar removal, *Oral Maxillofac Surg Clin N Am*. 2007;19:23–43.
- 42 Chiapasco M, Crescentini M, Romanoni G. Germectomy or delayed removal of mandibular impacted third molars: the relationship between age and incidence of complications. *J Oral Maxillofac Surg*. 1995 Apr;53(4):41.



## 6

### Pharmacology

Pharmacology is the science that deals with drugs. A myriad of drugs are available to control anxiety, pain, inflammation, and infection when removing impacted third molars. In many cases the use of particular drugs and regimens may not be appropriate. For example, the use of oral narcotics (Vicodin, Lortab, or Norco) to control pain may cause postoperative nausea and vomiting or lead to addiction. Research has shown that 200 mg ibuprofen combined with 650 mg acetaminophen is as efficacious as 10 mg of oxycodone with minimal adverse effects and no potential for abuse.<sup>1</sup> A fundamental knowledge of pharmacology is necessary to provide optimal care when removing impacted third molars. The subjects of pharmacokinetics and pharmacodynamics are the foundation of pharmacology. The pharmacology of the most common drugs used by general dentists when removing impacted third molars is the focus of this chapter.

### Pharmacokinetics and Pharmacodynamics

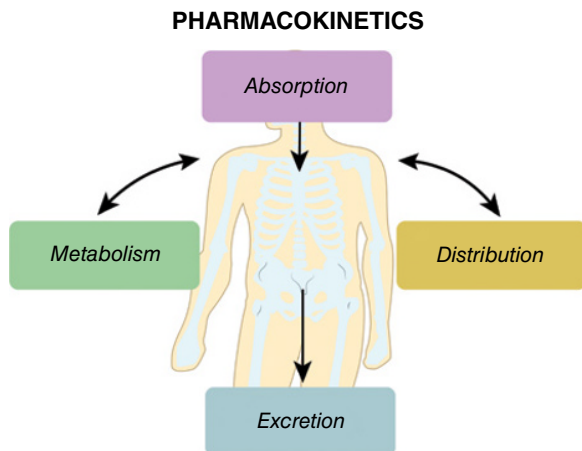
#### Pharmacokinetics

Pharmacokinetics describes how the body affects drugs: how drugs are absorbed, distributed, metabolized, and excreted. It refers to the movement of a drug into, throughout, and out of the body. Drug pharmacokinetics determines the onset, duration, and intensity of a drug's effect (see Figure 6.1).

The pharmacokinetic process of absorption is defined as the diffusion of a drug from the site of administration into the bloodstream. Distribution refers to the diffusion of a drug from the bloodstream into the body tissues. Metabolism refers to the process of biotransformation by which drugs are broken down so that they can be eliminated by the body. Elimination is defined as the removal of an active drug from the bloodstream.

Absorption of a drug into the bloodstream is determined by a drug's properties, formulation, and route of administration. Bioavailability is a subcategory of absorption. It is the percentage of a drug that reaches the systemic circulation. By definition, when a drug is administered intravenously its bioavailability is 100%. The drug is then distributed in its active form to the target organ (brain, heart, kidney, liver, etc.).

The bioavailability of drugs that are administered orally is highly variable and is never 100%. Bioavailability is dependent on absorption and biotransformation. A portion of orally administered drugs is absorbed through the intestinal mucosa and enters the liver



**Figure 6.1** Pharmacokinetics describes how the body affects drugs.

where it may be altered due to first-pass metabolism before entering the blood stream. The bioavailability of drugs administered sublingually is higher than orally administered drugs, but it is unpredictable because some of the drug is swallowed and is absorbed in the intestines. Therefore, the time to reach peak plasma level for sublingual drugs should be viewed as the same as oral drugs.

Absorbed drugs entering the bloodstream are either bound to plasma proteins or unbound and available for distribution. The average circulation time of blood is 1 minute. As the blood circulates, unbound drugs move from the bloodstream into the body's tissues. The amount and rate of drug distribution to body tissues is dependent on many factors, including perfusion (blood flow), tissue binding, regional pH, and permeability of cell membranes.<sup>2</sup> Distribution is greater in highly perfused tissue such as the heart, brain, liver, and kidney. Some drugs accumulate within cells because they bind with proteins, phospholipids, or nucleic acids. Drugs that are lipid soluble are more likely to penetrate cell membranes and distribute to tissues. Tissues with permeable cell membranes receive more drug distribution than tissues with low cell membrane permeability. Drugs with a high pH (such as meperidine) have a relatively high distribution to tissues. Additionally, metabolism and excretion occur simultaneously with distribution, making the process complex.

Most drugs are metabolized and transformed in the liver. Metabolism typically inactivates drugs in preparation for excretion. However, some drug metabolites are pharmacologically active. The liver's primary mechanism for metabolizing drugs is oxidation by a specific group of enzymes known as cytochrome P-450 (CYP450) enzymes. The concentration of cytochrome P-450 enzymes controls the rate at which many drugs are metabolized. Young children and the elderly metabolize drugs more slowly than the young or middle-aged adult due to altered enzymatic activity in the liver. These patients require smaller doses to achieve the same effect as young and middle-aged adults.

Elimination is accomplished through two mechanisms: (1) renal clearance by excretion into urine via the kidneys and (2) hepatic clearance by biotransformation to inactive metabolites via the liver. The term *elimination* refers to the removal of active molecules from the bloodstream, not from the body. Active drugs are transformed into inactive

metabolites in the liver. This is termed hepatic clearance. Drugs that are water soluble are generally excreted in urine. This is termed renal clearance. The plasma half-life of a drug is the time required to eliminate 50% of the active drug from the bloodstream. Drugs are considered to be completely eliminated after four half-lives. The elderly and patients with liver or kidney dysfunction will experience longer drug elimination half-lives. For example, both renal and hepatic clearance are reduced by 50% by age 65.<sup>3</sup>

## Pharmacodynamics

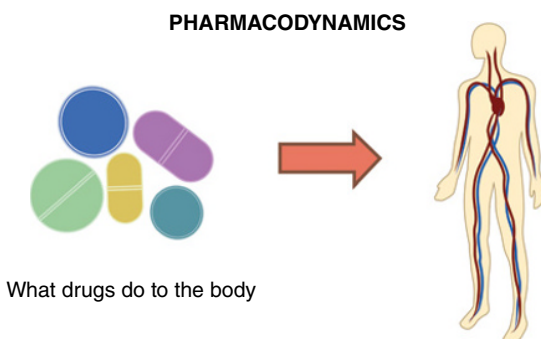
The mechanism by which a drug produces an effect is described as its action. Pharmacodynamics describes a drug's actions and how the actions affect the body. It describes observed therapeutic effects and side effects, which can be positive or negative (see Figure 6.2).

Physiological responses are the result of the interaction of substances with molecular components of cells called receptors. Drugs that bind to receptors and initiate a response are called agonists. Drugs that bind to receptors and block a response are called antagonists. For example, the emergency drug naloxone is an antagonistic drug that blocks the effect of opioids. Naloxone has greater affinity for the central nervous system (CNS) receptor than the opioids.

Drugs can also influence the action of enzymes. Enzyme inducers increase an enzyme's activity, while enzyme inhibitors decrease an enzyme's activity. For example, nonsteroidal anti-inflammatory drugs (NSAIDs) are enzyme inhibitors. NSAIDs inhibit the enzymes responsible for prostaglandin synthesis, resulting in decreased pain, inflammation, and fever.

A drug's effect on the body can be evaluated in terms of potency and efficacy. Potency refers to the amount of a drug needed to produce an effect such as pain reduction or sedation. Efficacy refers to a drug's ability to produce an effect—its effectiveness.

A common misconception in dentistry is the belief that a more potent drug is more effective than a less potent drug. A drug can be less potent but more effective than another drug.<sup>4</sup> Drugs are considered equipotent when they produce the same effect. For example, 50 mcg of fentanyl is 1000 times more potent than 50 mcg of meperidine. However, 50 mcg of fentanyl is no more effective than 50 mg of meperidine. Equipotent doses are equivalent in efficacy. Drugs belonging to the same class generally produce



**Figure 6.2** Pharmacodynamics describes how drugs affect the body.

comparable efficacy, provided one administers appropriate doses. When choosing between drugs of comparable cost and safety, preference should be given to the one demonstrating greatest efficacy.<sup>5</sup>

A drug's therapeutic index is an indication of a drug's safety. It is a ratio of a clinically adequate dose and an average lethal dose. Drugs with a high index are safer than drugs with a low index and are prescribed more frequently. Drugs within the same class tend to have similar safety margins and efficacy.

The ceiling effect of a drug refers to a point where no additional effect is seen with increasing dosage. Increasing the dose further will not produce a greater response. This upper limit of dosage, above which no additional effect is seen, is called the ceiling dose. Ibuprofen has a ceiling dose of 400 mg as an analgesic. Opioids have no ceiling effect as analgesics.

The interaction of two or more drugs can have a positive or negative effect. Pharmacodynamic interactions alter the response of another drug by having an agonistic or antagonistic effect.

## Pharmacology for Third Molar Removal

Countless drugs are available to produce sedation, manage pain, reduce inflammation, and prevent or eliminate infection. Clinicians removing impacted third molars have many choices. The objective of this chapter is to reduce these overwhelming choices to a manageable number. A limited number of drugs are recommended in this book for the removal of impacted third molars.

Every drug mentioned in this chapter should be evaluated prior to use with pregnant patients. The United States Food and Drug Administration (FDA) classifies drugs based on the risk they pose to the fetus (see Box 6.1).

Drugs in categories A and B are considered safe for use during pregnancy. Drugs in Category C can be used when the benefits to mother and fetus outweigh the risks. Drugs in category D should be avoided except in exceptional circumstances. The use of drugs in category X is strictly prohibited during pregnancy.

## Sedation

Sedation is recommended for the removal of impacted third molars. Extractions and the removal of third molars are among the most feared oral surgical procedures. Patient management can be challenging when treating patients with anxiety.

Data collected by Osborne and Sandler suggest that the more anxious a patient in the preoperative period, the more prone he or she is to movement during the surgical procedure.<sup>6</sup> Obviously, surgical complications are more likely when patients are moving. The surgical removal of impacted third molars requires a cooperative patient. Sedation can improve the patient's experience and treatment outcome.

The most common drugs used for sedation by general dentists when removing impacted third molars are triazolam, midazolam, zolpidem, and nitrous oxide. Triazolam and zolpidem are administered orally or sublingually, nitrous oxide by inhalation, and

### Box 6.1 FDA pregnancy risk categories.

#### FDA Pregnancy Category

**A – No risk in controlled human studies:** Adequate and well-controlled human studies have failed to demonstrate a risk to the fetus in the first trimester of pregnancy (and there is no evidence of risk in later trimesters).

**B – No risk in other studies:** Animal reproduction studies have failed to demonstrate a risk to the fetus and there are no adequate and well-controlled studies in pregnant women, OR animal studies have shown an adverse effect, but adequate and well-controlled studies in pregnant women have failed to demonstrate a risk to the fetus in any trimester.

**C – Risk not ruled out:** Animal reproduction studies have shown adverse effect on the fetus and there are no adequate and well-controlled studies in humans, but potential benefits may warrant use of the drug in pregnant women despite potential risks.

**D – Positive evidence of risk:** There is positive evidence of human fetal risk based on adverse reaction data from investigational or marketing experience or studies in humans, but potential benefits may warrant use of the drug in pregnant women despite potential risks.

**X – Contraindicated in pregnancy:** Studies in animals or humans have demonstrated fetal abnormalities and/or there is positive evidence of human fetal risk based on adverse reaction data from investigational or marketing experience, and the risks involved in use of the drug in pregnant women clearly outweigh potential benefits.

midazolam intravenously. Fentanyl, a narcotic, has both analgesic and sedative qualities. It is discussed in this chapter in the pain management section.

### Triazolam (Halcion)

Triazolam belongs to a group of drugs known as benzodiazepines. Benzodiazepines possess amnesic, sedative-hypnotic, anxiolytic, and anticonvulsant qualities. More than 2000 benzodiazepines have been synthesized since 1933.<sup>7</sup> Benzodiazepines affect GABA-mediated systems. The neurotransmitter GABA is an inhibitory neurotransmitter and controls the state of a chloride ion channel. Benzodiazepines increase the inhibitory action at the GABA receptor. Benzodiazepines are the most effective drugs currently available for the management of anxiety.<sup>8</sup> The efficacy of benzodiazepines is equivalent to or greater than any other class of sedatives and their safety profile is enviable. Death following an overdose of benzodiazepines alone is extremely rare.<sup>9</sup> Benzodiazepines are normally administered by the oral, sublingual, intramuscular, or intravenous route. Benzodiazepines are contraindicated in patients with acute narrow-angle glaucoma.

Triazolam is normally used in dentistry for short to moderate length appointments. Its rapid onset, short duration of action, and lack of active metabolites make it a near ideal antianxiety/sedation medication for the removal of impacted third molars. Onset of activity is usually within 30 minutes with peak blood levels occurring after approximately 75 minutes. The oral bioavailability for triazolam is only 44% but can be increased to 53% with sublingual administration.<sup>10</sup>

**Table 6.1** Characteristics of triazolam.

Characteristic	Triazolam
Bioavailability	44%–53%
Peak plasma level	75 min
½ Life	1.5–5.5 hr
Availability	0.125–0.25 mg
Metabolism	Hepatic CYP 450
Active metabolites	None major
Onset of activity	30 min
Amnesia	Yes
Pregnancy category	X + not for use in nursing
DEA schedule	IV
Contraindications	1. Acute narrow-angle glaucoma 2. Ketoconazole, itraconazole, nefazodone, HIV protease inhibitors impair metabolism

The usual adult dose for triazolam sedation ranges from 0.125 mg to 0.5 mg. The maximum recommended dose is 0.5 mg. Toxicity and overdose may develop at four times the maximum recommended dose. Baughman et al. compared triazolam 0.125, 0.25, and 0.5 mg with diazepam 5, 10, and 15 mg. Only the highest triazolam dose was consistently effective.<sup>11</sup> Triazolam has no major active metabolites. It is metabolized by oxidative reduction via the hepatic cytochrome P450 system. It can be influenced by aging, hepatic dysfunction, and drug–drug interactions. A small percentage of patients can have paradoxical reactions such as worsened agitation, aggression, or panic. Triazolam is contraindicated with medications that significantly impair the oxidative metabolism mediated by cytochrome P450, including ketoconazole, itraconazole, nefazodone, and several HIV protease inhibitors (see Table 6.1).

Triazolam is a United States FDA pregnancy category X drug. It is contraindicated in pregnant patients, patients with acute narrow-angle glaucoma, or known hypersensitivity to triazolam.

### Midazolam (Versed)

Midazolam is another benzodiazepine commonly used during the removal of impacted third molars. Many routes of administration are possible, including oral, intramuscular, nasal, and intravenous. The intravenous route is normally used for the removal of impacted third molars. Midazolam is available for parenteral administration in concentrations of 1 mg/ml and 5 mg/ml in 2 ml or 10 ml vials. Midazolam received FDA approval in December of 1985 (see Table 6.2).

Midazolam is soluble in water. Its water solubility is responsible for the absence of phlebitis and a lack of burning sensation on injection. Midazolam is metabolized in the liver by the cytochrome P450 system, resulting in no major active metabolites. Onset is rapid when administered intravenously. Midazolam has been used as an induction



**Table 6.2** Characteristics of intravenous midazolam.

Characteristic	IV Midazolam
Bioavailability	100%
Peak plasma level	<1 min
½ Life	1.5–3.5 hr
Availability	1 and 5 mg/ml
Metabolism	Hepatic CYP 450
Active metabolites	None major
Onset of activity	<1 min
Amnesia	Yes
Pregnancy category	D + caution in nursing
DEA schedule	IV
Contraindications	Acute narrow-angle glaucoma Ketoconazole, intraconazole, HIV protease inhibitors impair metabolism

agent for general anesthesia, with induction times ranging from 55 to 143 seconds.<sup>12</sup> Anterograde amnesia is a characteristic of midazolam.

Midazolam can be used alone or in combination with other drugs. Titration should be slow and dosage should be reduced when used with other CNS depressants such as nitrous oxide or fentanyl. The 1 mg/ml intravenous concentration is recommended to increase the drug's safety margin.

Midazolam is a United States FDA pregnancy category D drug. Midazolam is contraindicated for patients with acute narrow-angle glaucoma or known hypersensitivity to midazolam.

### Zolpidem (Ambien)

Zolpidem tartrate is a nonbenzodiazepine sedative hypnotic drug with pharmacodynamic characteristics (benefits, side effects, and risks) nearly identical to triazolam. However, the chemical structure of zolpidem is unrelated to triazolam. Zolpidem belongs to a class of sedative hypnotics known as imidazopyridines. This class of sedative hypnotics is sometimes referred to as “Z-compounds.”

Zolpidem is a strong sedative with mild anxiolytic, muscle relaxant, and anticonvulsant properties. It has amnesic side effects similar to triazolam. More than 90% of zolpidem exists in its protein-bound form with a bioavailability of approximately 70%.<sup>13</sup> It is rapidly absorbed from the GI tract, having an onset of action of 45 minutes and a peak effect in 1.6 hours.<sup>14</sup> It is metabolized in the liver with an elimination half-life of 2.6 hours. Elimination is primarily renal.

Zolpidem has no major active metabolites. It is metabolized by oxidative reduction via the hepatic cytochrome P450 system. It can be influenced by aging, hepatic dysfunction, and drug–drug interactions. A minority of patients can have paradoxical reactions such as worsened agitation, aggression, or panic (see Table 6.3).

**Table 6.3** Characteristics of oral zolpidem.

Characteristic	Zolpidem
Bioavailability	70%
Peak plasma level	1.5–2.5 hr
1/2 Life	2.5–3.1 hr
Availability	5 mg +10 mg
Metabolism	Hepatic CYP 450
Active metabolites	No
Onset of activity	45 min
Amnesia	Yes
Pregnancy category	C + caution in nursing
DEA schedule	IV
Contraindications	Hypersensitivity

Zolpidem is a United States FDA pregnancy category C drug. Zolpidem is contraindicated in patients with known hypersensitivity to Zolpidem.

### Flumazenil (Romazicon)

Adverse drug reactions can occur after the administration of any drug. A major advantage of benzodiazepines and imidazopyridines is the ability of flumazenil to reverse their sedative effects. Flumazenil is a benzodiazepine and imidazopyridine antagonist that rapidly reverses the sedative effects of triazolam, midazolam, or zolpidem. Patients show an improved ability to comprehend and obey commands when flumazenil is administered intravenously.<sup>15,16</sup> Flumazenil was FDA approved in December 1991 (see Table 6.4).

Flumazenil's onset of action is 1 to 2 minutes following IV administration. Peak concentrations are dose dependent and occur 1 to 3 minutes after administration.<sup>17</sup> Flumazenil's duration of action is short. Additional flumazenil doses may be needed to reverse sedative effects when extremely large doses of sedative have been used. Resedation is highly unlikely following low or conventional doses of benzodiazepines, for example, less than 10 mg midazolam IV.<sup>18</sup>

Flumazenil is a United States FDA pregnancy category C drug. Flumazenil injection is contraindicated in patients with a known hypersensitivity to flumazenil or a history of seizures.

### Nitrous Oxide

Nitrous oxide is an inorganic inhalation agent that is colorless, odorless to sweet-smelling, and non-irritating to tissues. It is non flammable but will support combustion. Given its long history of safety, it could be argued that nitrous oxide is the safest of all the modalities available for sedation in dentistry.<sup>19</sup> It is an ideal drug for patients with mild to moderate anxiety.

**Table 6.4** Characteristics of IV flumazenil.

Characteristic	IV Flumazenil
Bioavailability	100%
Peak plasma level	1–3 min
½ Life	54 min
Availability	0.5 mg/5 ml vials
Metabolism	Hepatic CYP 450
Active metabolites	No
Onset of activity	1–3 min
Amnesia	Reverses
Pregnancy category	C + caution in nursing
DEA schedule	None
Contraindications	History of seizures

The potency of an anesthetic gas is described as its minimum alveolar concentration (MAC). MAC represents the percent concentration required to produce immobility in response to a surgical stimulus for 50% of patients. Nitrous oxide has very low potency with a MAC of 104. The concentration of nitrous oxide indicated on typical dental office equipment is drastically reduced when compared with the concentration that actually reaches the patient. Even though the machine may indicate up to 70% nitrous oxide, the actual concentration delivered to alveoli is unlikely to exceed 30% to 50%.<sup>20</sup> Breathing by mouth, system leaks, poorly fitting masks, and dead space all contribute to this discrepancy. It should be emphasized that nitrous oxide MAC is significantly reduced (more potent) when it is combined with other sedatives or narcotics. General anesthesia with depressed respiratory and cardiovascular function is possible when nitrous oxide is combined with other sedative hypnotic drugs or narcotics.

Nitrous oxide has the fastest onset and elimination of all anesthetic gases due to its low solubility in blood. The absorption, distribution, and elimination of nitrous oxide are the result of pressure gradients in the lungs, blood, and tissue. Nitrous oxide does not undergo biotransformation. The elimination half-life of nitrous oxide is approximately 5 minutes.<sup>21</sup> Nitrous oxide is eliminated unchanged from the body, almost entirely via the lungs (see Table 6.5).

Nitrous oxide produces analgesia in addition to sedation. It is estimated that a 20%:80% mixture of N<sub>2</sub>O:O<sub>2</sub> produces the analgesic effectiveness of 10 to 15 mg of morphine.<sup>22</sup> The exact mechanism for the analgesic property of nitrous oxide is unknown. It is believed that there is an interaction with the endogenous opioid system. The strongest evidence is that nitrous oxide stimulates release of enkephalins, which bind to opioid receptors that trigger descending noradrenergic pathways.<sup>23</sup> The analgesic effect of nitrous oxide can be reversed with the opioid antagonist naloxone.

There are no contraindications to the use of nitrous oxide in combination with an adequate percentage of oxygen.<sup>24</sup> Nitrous oxide is an FDA pregnancy category C drug.

**Table 6.5** Characteristics of nitrous oxide.

Characteristic	Nitrous Oxide
Minimum alveolar concentration (MAC)	104
½ Life	5 min
Availability	Gas cylinders
Metabolism	No
Active metabolites	No
Onset of activity	1–3 min
Amnesia	No
Pregnancy category	C + caution in nursing
DEA schedule	No
Contraindications	History of seizures

## Pain Management

The management of pain is an integral part of the practice of dentistry. This is especially true when impacted third molars are removed. The most common drugs used to manage intraoperative and postoperative third molar pain include local anesthetics, opioids, ibuprofen, and acetaminophen.

### Local Anesthetics: Lidocaine, Articaine, and Bupivacaine

The ancient Incas may have used the leaves of the coca plant as a local anesthetic. Cocaine was isolated from the coca plant in 1860 and first used as a local anesthetic in 1884. Since then, several synthetic local anesthetic drugs have been developed, including lidocaine in 1943, bupivacaine in 1957, and articaine in 1969. These local anesthetics are commonly used for the removal of impacted third molars.

The potency of a local anesthetic is determined by its lipid solubility. Lipid solubility improves diffusion through nerve cell membranes. Bupivacaine is the most lipid soluble and potent local anesthetic. It is four times as potent as lidocaine and three times as potent as articaine.<sup>25</sup>

The majority of lidocaine and bupivacaine is metabolized in the liver by cytochrome P450 enzyme pathways. In contrast, 90%–95% of articaine is hydrolyzed in plasma, rendering the molecule inactive. The result is that articaine is eliminated quickly when compared to lidocaine and bupivacaine. For this reason, articaine presents less risk for systemic toxicity than lidocaine or bupivacaine at equipotent doses.<sup>26</sup>

The time of onset of a local anesthetic is determined by the amount of anesthetic that is non-ionized. Local anesthetics with more molecules that are non-ionized have faster onset times. At the physiological pH of 7.4, lidocaine and articaine have more non-ionized molecules than bupivacaine. Therefore, lidocaine and articaine have faster onset times than bupivacaine in equipotent doses.<sup>27</sup>

Duration of action is determined by plasma protein binding. Bupivacaine is 95% bound to plasma protein and has an affinity for protein at the receptor site within the sodium channel. Protein binding accounts for the long duration of bupivacaine.<sup>28</sup>

**Table 6.6** Characteristics of lidocaine, articaine, and bupivacaine.

Anesthetic	Potency	Metabolism	Onset	Duration Pulp/Soft Tissue (minutes)	Elimination $\frac{1}{2}$ Life (minutes)
Lidocaine 2% 1:100,000	Least	70% Hepatic	Rapid	60/180–360	96
Articaine 4% 1:100,000	Intermediate	95% Plasma	Rapid	60–75/180–360	45
Bupivacaine .5% 1:200,000	Most	94% Hepatic	Slow	90–180/240–540	210

**Table 6.7** Maximum local anesthetic recommendations.

Anesthetic	Absolute Max. (mg)	Max. Carpules
Lidocaine 2% Epinephrine 1:100,000	300	7
Articaine 4% Epinephrine 1:100,000	500	8
Bupivacaine .5% Epinephrine 1:200,000	90	10

The elimination half-life of a drug is largely dependent on metabolism. Drugs metabolized in the blood have a shorter half-life compared with drugs metabolized in the liver. This process is clearly demonstrated when comparing the half-lives of articaine and lidocaine. The elimination half-life for lidocaine is 96 min as compared to 45 min for articaine. Bupivacaine has the longest elimination half-life due to the combination of liver metabolism and protein binding. The elimination half-life of bupivacaine is 210 min (see Table 6.6).

Epinephrine delays absorption of local anesthetic and provides hemostasis. Concentrations of epinephrine greater than 1:200,000 do not provide better onset or duration for inferior alveolar nerve blocks.<sup>29</sup> However, higher concentrations of epinephrine improve hemostasis. Delayed absorption due to the addition of vasoconstrictor decreases the risk of anesthetic toxicity but does not eliminate it.

Maximum recommended doses must be respected. Toxic doses of local anesthetic can induce seizures. Local anesthetic is a CNS depressant when administered in high doses. This factor should be considered when local anesthetic is combined with other CNS depressant drugs. The absolute maximum adult dose of lidocaine is 300 mg, articaine 500 mg, and bupivacaine 90 mg. The absolute maximum recommendations for lidocaine, articaine, and bupivacaine are shown in Table 6.7.

A medical consultation is prudent for medically compromised patients receiving local anesthetics. The planned amount of local anesthetic and vasopressor should be expressed in milligrams and micrograms when consulting with a physician. Physicians are not familiar with dental carpule concentrations.

Daniel E. Becker, DDS, and Ken Reed, DMD, have proposed a simple and effective method to quickly convert anesthetic and epinephrine concentrations.<sup>30</sup> Consider all carpules to be 2.0 ml. This adjustment makes calculations easier and adds a margin of

**Table 6.8** Epinephrine concentration of common local anesthetics.

Vasopressor Concentration	Micrograms per 2 ml Carpule
1:50,000	40
1:100,000	20
1:200,000	10

safety. To convert anesthetic concentration from percent to milligrams, move the decimal point one place to the right. 2% lidocaine is 20 mg/ml, 4% articaine is 40 mg/ml, and 0.5% bupivacaine is 5 mg/ml. One carpule of lidocaine contains 2 ml; therefore, each carpule contains 40 mg of lidocaine. Two and a half carpules of lidocaine contains 100 mg lidocaine.

Vasopressor concentrations can be converted to micrograms by remembering that a vasopressor concentration of 1:100,000 is equivalent to 10 mcg/ml. Again, consider all carpules to be 2 ml. A 2 ml carpule of lidocaine 2% with epinephrine 1:100,000 will contain 20 mcg of epinephrine. A concentration of 1:50,000 will contain 40 mcg of epinephrine, and a concentration of 1:200,000 will contain 10 mcg of epinephrine (see Table 6.8).

The recommended local anesthetic dose is only a guideline. The amount of local anesthetic administered is determined following a thorough patient assessment. Surgical difficulty, patient anxiety, and appointment length are variables that affect local anesthetic decisions. Dose adjustments may be necessary for medically compromised patients. The vital signs of these patients should be assessed at regular intervals following the administration of local anesthetic.

Articaine and bupivacaine are United States FDA pregnancy category C drugs. Contraindications include a known history of hypersensitivity to local anesthetics and sulfites. Lidocaine is a United States FDA pregnancy category B drug. Contraindications include a known history of hypersensitivity to local anesthetics and sulfites.

### Opioids: Hydrocodone, Oxycodone, and Fentanyl

Opioids are among the world's oldest known drugs.<sup>31</sup> Opiates, originally derived from the opium poppy, have been used for thousands of years for both recreational and medicinal purposes. The earliest reference to opium growth and use is in 3400 B.C. when the opium poppy was cultivated in lower Mesopotamia (Southwest Asia).<sup>32</sup> The word *opium* originates from the Greek word *opion*, which meant poppy juice (see Figure 6.3).

The word *opiate* was classically used in pharmacology to mean a drug derived from opium. The modern word *opioid* is now used to designate all substances, both natural and synthetic, that bind to opioid receptors in the central nervous system and other tissues.<sup>33</sup> Opioids bind to specific receptors in these areas. There are three principal classes of opioid receptors,  $\mu$ ,  $\kappa$ ,  $\delta$  (mu, kappa, and delta).

Opioids are strong analgesics with sedative and antianxiety qualities. Oral opioids are often used to control preoperative anxiety and postoperative pain when removing third molars. Intravenous opioids are usually combined with an intravenous sedative hypnotic drug during the procedure to control pain and anxiety. Opioids are CNS depressants



**Figure 6.3** Poppy pod and flower in bloom. (Dinkum, via Wikimedia Commons)

capable of producing respiratory depression, especially when combined with other CNS depressants.

Malamed divides opioids into three categories: (1) opioid agonists, (2) opioid antagonists, and (3) opioid agonist-antagonists.<sup>34</sup> Opioid agonists (fentanyl) produce a physiological change. Opioid antagonists (naloxone) do not produce a physiological change. Opioid agonist-antagonists (nalbuphine) have properties of both agonists and antagonists. Agonist-antagonists are not discussed in this section since they are not commonly used for the removal of impacted third molars.

Opioid agonists produce analgesia, drowsiness, and euphoria. Arms and legs feel heavy, the body becomes warm, the mouth becomes dry, and itching develops around the nose and eyes. Negative side effects include nausea, vomiting, constipation, and dizziness. Opioid agonists increase smooth muscle tone, which can aggravate asthma in ASA III patients. However, this is unlikely to occur at therapeutic doses. Opioids are “cardioprotective” because they depress catecholamine release and obtund sympathetic reflexes to noxious stimuli such as the removal of impacted third molars. This pharmacodynamic property is especially beneficial for patients with hypertension, tachyarrhythmias, and ischemic heart disease.<sup>35</sup>

Common opioids used when removing impacted third molars include hydrocodone (Vicodin), oxycodone (Oxycontin), and fentanyl (Sublimaze). Hydrocodone and oxycodone are administered by the oral route and fentanyl by the IV route when used for the removal of third molars.

### **Hydrocodone (Vicodin)**

Hydrocodone was first synthesized in Germany in 1920 by Carl Mannich and Helene Löwenheim.<sup>36</sup> It was approved by the Food and Drug Administration in 1943 for sale in the United States. Hydrocodone is marketed in the United States under the brand

**Table 6.9** Characteristics of hydrocodone.

Characteristic	Oral Hydrocodone
Bioavailability	70%
Peak plasma level	1 hr
½ Life	3.3–4.4 hr
Availability	10, 15, 20, 30, 40, and 50 mg tablets
Metabolism	Hepatic—complex metabolism
Active metabolites	Yes
Onset of activity	10–30 min
Amnesia	No
Pregnancy category	Category C, not for use in nursing
DEA schedule	II
Contraindications	Opioid intolerance or allergy

names Vicodin, Lortab, and Norco. Hydrocodone is formulated with acetaminophen. It is well absorbed via the gastrointestinal tract. Oral bioavailability is 70%. Following oral administration, onset occurs after 10–30 minutes and peak plasma levels occur after about an hour. The average plasma half-life is 3.8 hours. Hydrocodone “exhibits a complex pattern of hepatic metabolism including O-demethylation, N-demethylation and 6-keto reduction to the corresponding 6-a and 6-b hydroxymetabolites”<sup>37</sup> (see Table 6.9).

Hydrocodone is the most frequently prescribed opioid in the United States, with an estimated 130 million prescriptions in 2006, up from approximately 88 million in 2000 (IMS National Prescription Audit Plus™). Hydrocodone is contraindicated in patients with a known hypersensitivity. Hydrocodone is a United States FDA pregnancy category C drug.

#### **Oxycodone (Oxycontin)**

Freund and Speyer of the University of Frankfurt in Germany first synthesized oxycodone from thebaine in 1916.<sup>38</sup> It was first introduced to the U.S. market in 1939. Oxycodone is available in the United States in immediate release and extended release forms. The most common brand name is Oxycontin. Oxycodone is formulated with and without acetaminophen. It is well-absorbed via the gastrointestinal tract. It has an oral bioavailability of 60%–87%. Following oral administration, onset occurs after 5 to 10 minutes and peak plasma levels occur after 30 to 60 minutes. The average plasma half-life is 3 to 4 hours. Oxycodone is metabolized in the liver by CYP3A4 to the weak analgesic noroxycodone and by CYP2D6 to the potent analgesic oxymorphone (see Table 6.10). It is estimated that 53 million oxycodone prescriptions are dispensed by U.S. pharmacies annually.<sup>39</sup>

Oxycodone is contraindicated in patients with known hypersensitivity. Oxycodone is a United States FDA pregnancy category B drug.



**Table 6.10** Characteristics of oxycodone.

Characteristic	Oxycodone
Bioavailability	60%–87 %
Peak plasma level	30–60 min
1/2 Life	3–4 hr
Availability	10 mg, 20 mg tablets
Metabolism	Hepatic – CYP3A4 and CYP2D6
Active metabolites	Yes
Onset of activity	10–15 min
Amnesia	No
Pregnancy category	Category B, not for use in nursing
DEA schedule	II
Contraindications	Opioid intolerance or allergy

**Fentanyl (Sublimaze)**

Fentanyl was first synthesized by Paul Janssen of Janssen Pharmaceutica in 1959.<sup>40</sup> The FDA approved fentanyl for IV administration in February 1968. Fentanyl is the most used opioid for dental IV moderate sedation.<sup>41</sup> It is approximately 100 times more potent than morphine.

Fentanyl has a rapid onset and short duration of action. Following the IV administration of fentanyl, the onset of analgesia and sedation is less than one minute. Average duration of clinical action is 30 to 60 minutes, which makes fentanyl an almost ideal drug for the removal of third molars. Fentanyl does not promote histamine release. Fentanyl has an elimination half-life of 3.7 hours. Peak plasma concentration is observed after 6 minutes. It is primarily metabolized in the liver by the enzyme CYP3A4. There are no significant active metabolites. Injectable fentanyl is available in ampules, syringes, and, vials (see Table 6.11).

Fentanyl may cause muscular rigidity, especially involving the muscles of respiration, when rapidly injected as a bolus. It should be administered slowly to avoid this potentially disastrous complication. Fentanyl is contraindicated in patients with opioid intolerance or hypersensitivity. Fentanyl is a United States FDA pregnancy category C drug.

**Naloxone (Narcan)**

Naloxone was patented in 1961 by Jack Fishman and Mozes J. Lewenstein. It was approved for the treatment of opioid overdose by the Food and Drug Administration in 1971.<sup>42</sup> Naloxone is an opioid antagonist that rapidly reverses the CNS and respiratory depressant effects of opioids. Naloxone exhibits essentially no pharmacological activity when administered in the absence of opioids.<sup>43</sup>

Onset of action and improvement in respiration is usually seen within 1–2 minutes following IV administration. The effect of naloxone lasts 30 to 60 minutes. In one study, the duration of action was 45 minutes following IV administration.<sup>44</sup> Multiple doses may be required because the duration of action of most opioids is greater than that of

**Table 6.11** Characteristics of fentanyl.

Characteristic	IV Fentanyl
Bioavailability	100%
Peak plasma time	6 min
½ Life	3.7 hr
Availability	50 mcg/ml
Metabolism	Hepatic – CYP3A4
Active metabolites	None significant
Onset of activity	<1 min
Amnesia	No
Pregnancy category	Category C, caution in nursing
DEA schedule	II
Contraindications	Opioid intolerance or allergy

**Table 6.12** Characteristics of IV naloxone.

Characteristic	IV Naloxone
Bioavailability	100%
½ Life	30–81 min
Availability	0.2 and 0.4 mg/ml
Metabolism	Hepatic
Active metabolites	Yes
Onset of activity	2 min
Duration of action	30–60 min
Pregnancy category	Category C, caution in nursing
DEA schedule	Prescription
Contraindications	Hypersensitivity to naloxone

naloxone.<sup>45</sup> An IM dose of naloxone following IV administration increases the duration of clinical action. The mean serum elimination half-life has been shown to range from 30 to 81 minutes. Withdrawal symptoms are triggered when naloxone is administered to patients who are physically dependent on opioids (see Table 6.12).

Naloxone is contraindicated in patients with known hypersensitivity. Naloxone is a United States FDA pregnancy category C drug.

### **Ibuprofen (Advil)**

Ibuprofen was discovered in 1961 by Stewart Adams. It was first marketed in the United States in 1974.<sup>46</sup> Ibuprofen is an NSAID used for the treatment of pain, inflammation,

and fever. Its effects are due to the inhibitory actions on enzymes that synthesize prostaglandins. Prostaglandins play an important role in the production of pain, inflammation, and fever.<sup>47</sup>

Preoperative use of ibuprofen has been demonstrated repeatedly to decrease the intensity of postoperative pain and swelling.<sup>48</sup> The concept of “preloading” is valid if ibuprofen is administered while local anesthetic is effective. In a survey published in 2006, investigators found that ibuprofen was the most frequently recommended non-prescription peripherally acting analgesic among oral and maxillofacial surgeons for the management of postoperative pain after third-molar extractions in the United States.<sup>49</sup> Ibuprofen has an analgesic ceiling effect of 400 mg. Doses beyond 400 mg will not improve analgesia.

There is no ibuprofen ceiling effect for inflammation. Doses of 1600 mg to 2400 mg per day may decrease inflammation following the removal of third molars. As the dose of an NSAID is increased, anti-inflammatory effects improve until maximum safe doses (2400 mg/day) preclude any further increase.<sup>50</sup>

Ibuprofen’s bioavailability is nearly 100%. It is rapidly and widely distributed to human tissues. Onset of action is usually seen within 30 minutes, with effects lasting 4–6 hours. The mean serum elimination half-life has been shown to range from 1.8 to 2.5 hours. Ibuprofen is metabolized in the liver (see Table 6.13).

Ibuprofen should be avoided in patients with bleeding disorders, erosive or ulcerative conditions of the GI mucosa, and those taking anticoagulants such as Coumadin. Patients with compromised renal function can experience renal failure within 24 hours of ibuprofen administration. Ibuprofen should not be prescribed for patients who have known or questionable renal function. This concern has not been found relevant with short-term use of ibuprofen. (e.g., 5–7 days). Ibuprofen is a United States FDA pregnancy category B drug.

**Table 6.13** Characteristics of ibuprofen.

Characteristic	Ibuprofen
Bioavailability	95%–100%
½ Life	1.8–2.0 hr
Peak plasma time	1–2 hr
Availability	200 mg, 400 mg, 600 mg, 800 mg
Metabolism	Hepatic, CYP450
Active metabolites	No
Onset of activity	30 min
Duration of action	4–6 hr
Pregnancy category	Category C, D in third trimester, not for use in nursing
Contraindications	Hypersensitivity, blood thinners, compromised GI or renal function

### Acetaminophen (Tylenol)

Acetaminophen (paracetamol) was synthesized by Harmon Northrop Morse in 1873. This discovery was largely ignored at the time.<sup>51</sup> In 1948, Brodie and Axelrod linked the use of acetanilide with methemoglobinemia and determined that the analgesic effect of acetanilide was due to its active metabolite acetaminophen. They advocated the use of acetaminophen, since it did not have the toxic effects of acetanilide. The product went on sale in the United States in 1955 under the brand name Tylenol.<sup>52</sup> The exact mechanism of action of acetaminophen is still poorly understood.

Oral acetaminophen is rapidly and completely absorbed from the small intestine. Its bioavailability ranges from 70% to 90% depending on dose.<sup>53</sup> Onset of action occurs between 30 and 60 minutes.<sup>54</sup> Peak plasma concentrations occur within 24 to 60 minutes. Acetaminophen has a short plasma half-life that ranges from 2 to 3 hours in healthy adults. Because acetaminophen clears rapidly from the body, it requires dosing every 4 to 6 hours in order to maintain therapeutic levels.<sup>55</sup>

Unlike ibuprofen, acetaminophen has no anti-inflammatory properties; therefore, it is not a nonsteroidal anti-inflammatory drug. NSAIDs have influence on peripheral prostaglandin synthesis. Acetaminophen has no effect on peripheral prostaglandin synthesis. Instead, it is believed to inhibit prostaglandin synthesis within the CNS. This may be the reason that acetaminophen lacks anti-inflammatory qualities.

Acetaminophen has a narrow therapeutic index. This means that the common dose is close to the overdose, making it a relatively dangerous substance.<sup>56</sup> Hepatotoxicity is the most significant adverse effect of acetaminophen. The recommended maximum daily dose for adults is 3000 mg. Without timely treatment, acetaminophen overdoses can lead to liver failure and death within days.<sup>57</sup> Acetaminophen is less likely than ibuprofen to cause gastric irritation or bleeding when used in normal doses. It does not affect blood coagulation or the kidneys. When used responsibly, acetaminophen is one of the safest medications available for analgesia (see Table 6.14).

Acetaminophen is contraindicated in patients with severe hepatic impairment or patients with a known hypersensitivity to acetaminophen. Acetaminophen is a United States FDA pregnancy category B drug.

**Table 6.14** Characteristics of acetaminophen.

Characteristic	Oral Acetaminophen
Bioavailability	70%–90%
½ Life	2–3 hr
Peak plasma time	24–60 min
Availability	325 mg
Metabolism	Hepatic
Active metabolites	Yes
Onset of activity	30–60 min
Duration of action	4–6 hr
Pregnancy category	Category B, nursing safety unknown
Contraindications	Hypersensitivity to acetaminophen, hepatic impairment

### Ibuprofen and Acetaminophen Combination

The removal of impacted third molars is recognized as one of the more painful procedures in dentistry. Pain following the surgical removal of impacted third molars is frequently used as an analgesic model because of the intensity and consistency of postoperative pain.<sup>58</sup> One study found the prescription analgesics most frequently recommended by maxillofacial surgeons for the removal of third molars were acetaminophen-hydrocodone (Vicodin, Lortab, Norco) and acetaminophen-oxycodone (Percocet).<sup>59</sup> Unfortunately, the use of opioids to control postoperative pain following the removal of impacted third molars is associated with adverse events, including nausea, vomiting, dizziness, and drug abuse.

The strategy of combining two analgesic agents with different sites of action has been advocated for many years. A study, published in the *Journal of the American Dental Association* in 2013, compared the efficacy of several drugs used to control postoperative pain following the removal of impacted third molars. The authors used the statistic “number needed to treat” (NNT) to rank the efficacy of individual drugs and drug combinations. NNT has been defined as “the number of patients needed to be treated to obtain one additional patient achieving at least 50 percent maximum pain relief over four to six hours compared with placebo.” The lower the NNT, the more effective the analgesic drug therapy.<sup>60,61</sup> (See Table 6.15).

The most effective drug combination in this study was ibuprofen 200 mg combined with 500 mg acetaminophen (NNT = 1.6). The combination was more effective than either drug used alone (ibuprofen 2.7, acetaminophen 3.2) or acetaminophen combined with the opioid oxycodone (2.3). The data suggest that ibuprofen combined with acetaminophen would also be more effective than hydrocodone combined with acetaminophen (Vicodin, Lortab, or Norco). There was little indication that adverse reactions are more frequent with the administration of the ibuprofen acetaminophen combination than with the administration of the individual components, as long as maximum recommended doses of both components are not exceeded.

**Table 6.15** Efficacy of oral analgesics, NNT study.

Drug (mg)	Number Needed to Treat
Aspirin (600 or 650)	4.5 (4.0–5.2)
Aspirin (1,000)	4.2 (3.2–6.0)
APAP* (1,000)	3.2 (2.9–3.6)
Ibuprofen (200)	2.7 (2.5–3.0)
Celecoxib (400)	2.5 (2.2–2.9)
Ibuprofen (400)	2.3 (2.2–2.4)
Oxycodone (10) with APAP (650)	2.3 (2.0–6.4)
Codeine (60) with APAP (1,000)	2.2(1.8–2.9)
Naproxen (500 or 550)	1.8 (1.6–2.1)
<b>Ibuprofen (200) with APAP (500)*</b>	<b>1.6 (1.4–1.8)</b>

\*acetaminophen is N-acetyl-p-aminophenol (APAP).

The analgesic ceiling effect should be considered when evaluating this study. The analgesic ceilings for ibuprofen and acetaminophen are 400 mg and 1000 mg, respectively.<sup>62</sup> It can be assumed that a combination of 400 mg ibuprofen combined with 1000 mg acetaminophen would have an NNT result lower than 1.6. To avoid adverse events, it is important that daily maximum doses of 2400 mg ibuprofen and 3000 mg acetaminophen are not exceeded.

Several options in addition to oral medication are available to reduce postoperative pain when removing impacted third molars. The long-acting local anesthetic bupivacaine can provide extended soft-tissue and periosteal anesthesia.<sup>63</sup> Ibuprofen taken preemptively before surgery has been shown to decrease the severity and onset of acute postoperative pain.<sup>64</sup> The corticosteroid dexamethasone is effective in limiting trismus, swelling, and pain after third molar surgery.<sup>65</sup>

In summary, many medications and routes of administration are available to manage impacted third molar surgical and postoperative pain. The safest and most efficacious pharmacological choice to manage postoperative pain appears to be ibuprofen combined with acetaminophen.

## Inflammation

Pain, inflammation, and trismus following the removal of impacted third molars are inextricably linked. Ata-Ali et al. studied the effects of corticosteroids on pain, inflammation, and trismus after lower third molar surgery.<sup>66</sup> A total of 14 articles were included in the study. Trismus is a reduction of jaw opening caused by edema and swelling. The study found a mean reduction in opening of 24.1% the day after removal of mandibular third molars when corticosteroids were used. In 5 of the 14 articles analyzed, steroid use resulted in statistically significant reductions in pain. Seven articles found steroids reduced swelling. Eight articles found steroids reduced trismus. Few side effects were observed after short-term use of the corticosteroids.

Postoperative swelling is expected following the removal of impacted third molars. This complication can affect the social, school, and work life of patients. Pharmacological intervention has been shown to reduce postoperative swelling. Common medications used in the management of postoperative swelling include dexamethasone, methylprednisolone, and ibuprofen. Dexamethasone and methylprednisolone are glucocorticoids. Ibuprofen is an NSAID.

## IV Dexamethasone

Dexamethasone was first synthesized in 1957.<sup>67</sup> It is a potent steroid with anti-inflammatory and immunosuppressant activity. Dexamethasone phosphate is absorbed rapidly following intravenous injection. Metabolism occurs primarily in the liver by cytochrome P3A4 enzymes. The biological half-life of dexamethasone is about 190 minutes. Onset of action is within 1 hour. Duration of action is 36 to 54 hours. Dexamethasone phosphate can be administered IV, IM, or intraorally (see Table 6.16).

Many studies have shown that dexamethasone can safely reduce facial swelling using different routes of administration. For example, one study showed that the use of

**Table 6.16** Characteristics of injectable dexamethasone.

Characteristic	IV Dexamethasone
Bioavailability	100%
½ Life	190 min
Peak plasma time	<1 hr
Availability	4.0 and 10.0 mg/ml
Metabolism	Hepatic, CYP3A4
Active metabolites	No
Onset of activity	<1 hr
Duration of action	36–54 hr
Pregnancy category	Category C, not for use in nursing
Contraindications	Hypersensitivity to dexamethasone, systemic fungal infections

injectable dexamethasone phosphate, given as an intraoral injection at the time of the procedure, was effective in the prevention of postoperative swelling. In third molar surgery, pain and trismus are often directly proportional to swelling. Therefore, a patient with minimal swelling should have minimal pain and trismus.<sup>68,69</sup>

Another, more recent, study found that parenteral use of dexamethasone 4 mg, given as an intraoral injection at the time of surgery, is effective in the prevention of postoperative edema. The study also found that increasing the dose to 8 mg provides no further benefit.<sup>70</sup>

Adding dexamethasone by intraoral injection may be an attractive option for dentists not certified in IV sedation. Alternatively, methylprednisolone can be given orally by individual tablet.

### Oral Methylprednisolone

Methylprednisolone is another potent anti-inflammatory steroid. The oral administration of methylprednisolone has been shown to reduce inflammation following the removal of third molars. Acham et al. evaluated the influence of preoperative oral methylprednisolone on postoperative swelling, trismus, and pain. Sixteen healthy patients were included in a prospective, randomized, placebo controlled, double-blind study in a split-mouth design. Patients received oral methylprednisolone (40–80 mg) or a placebo 1 hour prior to surgery. The study found a significant reduction of trismus, swelling, and pain in the methylprednisolone group.<sup>71</sup>

Another study looked at the analgesic and anti-inflammatory efficacy when methylprednisolone is combined with oral ibuprofen. Methylprednisolone (32 mg) was given 12 hours before and 12 hours after removal of mandibular impacted third molars. Ibuprofen (400 mg) was given three times a day on the day of the procedure and on the two days following the procedure. Evaluation showed a 67.7 % reduction in pain and a 56% reduction in swelling compared with the placebo group.<sup>72</sup>

**Table 6.17** Characteristics of oral methylprednisolone.

Characteristic	Methylprednisolone
Bioavailability	82%–89%
½ Life	1.8–5.2 hr
Peak plasma time	1.1–2.2 hr
Availability (Upjohn)	4–100 mg
Metabolism	Hepatic, CYP3A4
Active metabolites	No
Onset of activity	1–2 hr
Duration of action	8–24 hr
Pregnancy category	Category C, not for nursing
Contraindications	Hypersensitivity to methylprednisolone, systemic infections

Methylprednisolone is rapidly absorbed, and the maximum plasma concentration is achieved around 1.1 to 2.2 hours across doses following oral administration in normal healthy adults. The absolute bioavailability of methylprednisolone in normal healthy subjects is generally high (82% to 89%) following oral administration. Methylprednisolone is widely distributed into the tissues, crosses the blood-brain barrier and the placental barrier, and is secreted in breast milk. Methylprednisolone is metabolized in the liver to inactive metabolites. Metabolism in the liver occurs primarily via the CYP3A4 enzyme. The mean elimination half-life for methylprednisolone is in the range of 1.8 to 5.2 hours (see Table 6.17).

## Ibuprofen

Ibuprofen was previously discussed under the pain section of this chapter. Because ibuprofen has analgesic and anti-inflammatory qualities, it will be discussed again here (see Table 6.14).

Ibuprofen has greater potency as an analgesic and antipyretic than as an anti-inflammatory agent. Ibuprofen 400 mg is equivalent to 10 mg of oxycodone as an analgesic (NNT of 2.3) (see table 6.16). However, higher doses are required to achieve anti-inflammatory effects than analgesic effects. As the dose of ibuprofen is increased, anti-inflammatory effects improve until maximum safe doses preclude any further increase.<sup>73</sup> Doses of 1600 mg to 2400 mg per day may decrease inflammation following the removal of third molars. The maximum daily dose of ibuprofen should not exceed 2400 mg.

Inflammation is better controlled with corticosteroids than with NSAIDs.<sup>74,75</sup> The anti-inflammatory and analgesic actions of corticosteroids and NSAIDs, respectively, suggest that combining dexamethasone and ibuprofen may provide beneficial inflammatory and pain relief in the absence of side effects. Jarrah et al. completed a study that confirmed the synergistic effect of corticosteroids (dexamethasone) with ibuprofen in controlling postoperative pain, trismus, and swelling as opposed to corticosteroid alone.<sup>76</sup>



## Infection

Antibiotics play a key role in the treatment and prevention of third molar surgical site infections. The incidence of infection after the removal of third molars is very low, ranging from 1.7% to 2.7%.<sup>77</sup> *Peterson's Principles of Oral and Maxillofacial Surgery* states:

“Infection after the removal of mandibular third molars is almost always a minor complication. In relation to third molar surgery, 50% of infections are localized subperiosteal abscess type infections occurring approximately 2–4 weeks after surgery. This type of infection is attributed to debris left under the surgically created mucoperiosteal flap and would likely not be prevented with the use of antibiotic prophylaxis. The remaining 50% of third molar surgical site infections are rarely severe enough to necessitate further surgery, antibiotics, or hospitalization. Surgical site infections within the first postoperative week after third molar surgery occurs only 0.5–1.0% of the time.”<sup>78</sup>

Common antibiotics used in the United States for the treatment of third molar surgical site infections include amoxicillin, clindamycin, and metronidazole.

### Amoxicillin (Amoxil)

The Nobel Prize in Physiology or Medicine 1945 was awarded jointly to Sir Alexander Fleming, Ernst Boris Chain, and Sir Howard Walter Florey “for the discovery of penicillin and its curative effect in various infectious diseases”<sup>79</sup> (see Figure 6.4).

Amoxicillin first became available in 1972.<sup>80</sup> Amoxicillin is a member of a class of broad-spectrum antibiotics that contain a  $\beta$ -lactam ring in their molecular structure. Amoxicillin is similar to penicillin in its bactericidal action against susceptible bacteria. It acts through the inhibition of cell wall biosynthesis, which leads to the death of the bacteria. Amoxicillin is active against a wide range of Gram-positive and a limited range



**Figure 6.4** Nobel Prize winners in 1945 for the discovery of penicillin. (a) Sir Alexander Fleming. (b) Ernst Boris Chain. (c) Sir Howard Walter Florey. *Source:* Courtesy of IWM. <http://www.iwm.org.uk/collections/item/object/205188777>.

**Table 6.18** Characteristics of amoxicillin.

Characteristic	Amoxicillin
Bioavailability	>80%
½ Life	61.3 min
Peak plasma time	1.0–2.0 hr
Availability	250–500 mg capsules
Metabolism	~30% hepatic, CYP450
Active metabolites	Yes
Onset of activity	0.5 hr
Duration of action	6–8 hr
Pregnancy category	Category B, caution in nursing
Contraindications	Hypersensitivity to $\beta$ -lactam antibiotics

of Gram-negative organisms. Oral amoxicillin is the usual drug of choice within its class because it is better absorbed than other beta-lactam antibiotics.

The bioavailability and half-life of amoxicillin is superior to that of penicillin V. Amoxicillin has bioavailability greater than 80% and a half-life of 61 minutes. Amoxicillin has a peak plasma time of 1 to 2 hours. Onset of action is rapid at 0.5 hours. Duration of action is 6 to 8 hours. Approximately 30% of amoxicillin is metabolized in the liver with no active metabolites. Amoxicillin is available in many forms, including 250 mg and 500 mg capsules (see Table 6.18).

Amoxicillin is contraindicated in patients with known hypersensitivity to amoxicillin and or other  $\beta$ -lactam antibiotics. Amoxicillin is a United States FDA pregnancy category B drug.

### Clindamycin (Cleocin)

Clindamycin was synthesized from lincomycin in 1967.<sup>81</sup> Clindamycin belongs to a class of antibiotics known as lincosamides. Clindamycin is a broad-spectrum antibiotic with activity against aerobic, anaerobic, and beta-lactamase-producing pathogens. Clindamycin has a primarily bacteriostatic effect, inhibiting bacterial protein synthesis by binding to the 50S bacterial ribosome subunit.<sup>82</sup>

A review of the literature relating to maxillofacial infections has shown this antibiotic to be highly effective in the field of dentistry.<sup>83</sup> Clindamycin is considered the alternative of choice in patients allergic to amoxicillin.

Clindamycin has bioavailability of 90% and a half-life of 2.5 to 3 hours. It has a peak plasma time of 45 minutes. Onset of action is variable. Duration of action is 8 to 12 hours. Clindamycin is metabolized in the liver with active metabolites. Clindamycin is available in many forms, including 75 mg, 150 mg, and 300 mg capsules (see Table 6.19).

Clindamycin is contraindicated in patients with known hypersensitivity to clindamycin or lincomycin. Clindamycin is a United States FDA pregnancy category B drug.

### Metronidazole (Flagyl)

Metronidazole was introduced in 1959.<sup>84</sup> It belongs to a class of antibiotics known as nitroimidazoles. Metronidazole is the gold standard antibiotic in the treatment of

**Table 6.19** Characteristics of clindamycin.

Characteristic	Clindamycin
Bioavailability	90%
½ Life	2.4–3.0 hr
Peak plasma time	45 min
Availability	75 mg, 150 mg, 300 mg capsules
Metabolism	Hepatic, CYP450
Active metabolites	Yes
Onset of action	Variable
Duration of action	8–12 hr
Pregnancy category	Category B, not for use in nursing.
Contraindications	Hypersensitivity to clindamycin or lincomycin

**Table 6.20** Characteristics of metronidazole.

Characteristic	Metronidazole
Bioavailability	95%
½ Life	8 hr
Peak plasma time	1–2 hr
Availability	250–500 mg capsules
Metabolism	Hepatic, CYP450
Active metabolites	Yes
Onset of activity	Rapid
Duration of action	6–8 hr
Pregnancy category	Category B, caution in nursing
Contraindications	Hypersensitivity to metronidazole

anaerobic infections because of its pharmacodynamics and pharmacokinetics, minimal adverse effects, and antimicrobial activity. Metronidazole is not recommended as single drug therapy for oral infections because it is inactive against aerobic and facultative streptococci. However, it may be combined with beta lactams (amoxicillin) when managing severe infections.<sup>85</sup>

The bioavailability of metronidazole is 95%. Its elimination half-life is 8 hours. Metronidazole has a peak plasma time of 1 to 2 hours. Onset of action is rapid. Duration of action is 6–8 hours. Metronidazole is metabolized in the liver and excreted primarily by the kidneys. Metronidazole is available in many forms, including 250 mg and 500 mg capsules (see Table 6.20).

Metronidazole is contraindicated in patients with known hypersensitivity to metronidazole. Metronidazole is a United States FDA pregnancy category B drug.

## Prophylactic Antibiotics

The universal use of prophylactic antibiotics to prevent third molar postoperative infection is controversial. Antibiotic resistance is now a serious problem, which was not the case 50 years ago.<sup>86</sup> Peterson's criterion for antibiotic use is that the surgical procedure should have a significant risk of infection.<sup>87</sup> Antibiotic prophylaxis may also be recommended for patients when traumatic surgical procedures have been performed.<sup>88,89</sup>

The risk of developing a surgical site infection, associated with the removal of impacted third molars, increases with degree of impaction; need for bone removal or sectioning; the presence of gingivitis, periodontal disease, and/or pericoronitis; surgeon experience; increasing age; and antibiotic use.<sup>90</sup> The decision to use prophylactic antibiotics should be based on these factors and assessment of each individual patient.

## Treatment of Existing Infection

Signs of surgical site infection include localized swelling, purulence, erythema, fluctuance, trismus, fever, and dehydration. Definitive treatment of surgical site infection involves incision and drainage plus the administration of antibiotics. Amoxicillin, a broad-spectrum antibiotic, is often prescribed since most oral infections are caused by a mixed flora of anaerobic and Gram-positive streptococci microorganisms. Metronidazole is primarily used to treat infections caused by anaerobic microorganisms. Metronidazole can be combined with amoxicillin to treat severe infections. This combination is very effective in the treatment of subperiosteal infections. Most impacted third molar surgical site infections are localized subperiosteal abscesses. Clindamycin is a good choice of antibiotic for patients allergic to amoxicillin. Rarely, cellulitis develops or the infection spreads along fascial planes in the head and neck. In this situation, immediate referral to an oral and maxillofacial surgeon for definitive management is recommended.<sup>91,92</sup>

## Author's Medication Regimen

Most of the author's impacted third molar patients are ASA I or II patients requiring surgical flaps, bone removal, and sectioning. The majority of these patients receive prophylactic antibiotics due to the traumatic nature of the procedure. The following regimen is used for full and partial bony impactions.

Patients arrive at the office one hour prior to the procedure and are given amoxicillin, ibuprofen, and sublingual triazolam (see Box 6.2).

### Box 6.2 Author's medication regimen for the removal of partial and full bony impactions.

**Amoxicillin** 500 mg, Disp: 15

Take one tablet 1 hour before appointment and continue three times a day until gone.

**Ibuprofen** 800 mg, Disp: 15

Take one tablet 1 hour before appointment and continue three times a day until gone.

**Triazolam** 0.25 mg, Disp: 2

Bring to appointment (0.5 mg administered sublingual in office for ASA I and II; 0.25 mg for elderly or medically compromised).

One hour after arrival, the patient is seated in the operatory. The IV is started and fentanyl and midazolam are slowly titrated to the desired effect. Patients who are moderately sedated from the sublingual sedative do not receive IV midazolam. Most patients receive 50 mcg of fentanyl (maximum of 100 mcg) and 3 mg of midazolam. Sedations appear to be more effective when fentanyl is administered before midazolam.

This regimen works well for the vast majority of patients. When necessary, the patient is instructed to take Tylenol 500 mg six times a day in addition to prescribed ibuprofen. Hydrocodone 10 mg without acetaminophen is added in rare cases.

## References

- 1 Harrison L. Painful dental work: Acetaminophen with ibuprofen best. *Medscape*. 2013 Aug 14.
- 2 Le J, Drug distribution to tissues. Merck Manuals. 2016 Apr.
- 3 Montamat SC, Cusack BJ, Vestal RE. Management of drug therapy in the elderly. *N Engl J Med* 1989;321:303–9.
- 4 Oates JA. The science of drug therapy. In: Brunton LL, Lazo JS, Parker KL, editors. Goodman and Gilman's the pharmacological basis of therapeutics, 11th edition. New York: McGraw-Hill; 2006:117–36.
- 5 Becker DE. Drug therapy in dental practice: general principles, part 2. Pharmacodynamic considerations. *Anesth Prog* 2007;54:19–24.
- 6 Osborn TM Sandler NA. The effects of preoperative anxiety on intravenous sedation. *Anesth Prog*. 2004;51(2):46–51.
- 7 Saïas T, Gallarda T. Paradoxical aggressive reactions to benzodiazepine use: a review. *L'Encéphale* (in French). 2008;34(4):330–6.
- 8 Malamed S, Stanley F. Sedation: a guide to patient management, 5th edition. Mosby; 2010: 101.
- 9 Donaldson M, Gizzarelli G, Chanpong B. Oral sedation: a primer on anxiolysis for the adult patient, *Anesth Prog*. 2007;54(3):118–29.
- 10 Dionne RA, Trapp LD. Oral and rectal sedation. In: Dionne RA, Phero JC, Becker DE, editors. Management of pain and anxiety in the dental office. St. Louis: WB Saunders; 2002: 229.
- 11 Baughman VL, Becker GL, Ryan CM, Glaser M, Abenstein JP. Effectiveness of triazolam, diazepam, and placebos as preanesthetic medications. *Anesthesiology*. 1989;71:196–200.
- 12 Ouellette RG. Midazolam: an induction agent for general anesthesia. *Nurse Anest*. 1991;2:131.
- 13 Drover DR. Comparative pharmacokinetics and pharmacodynamics of short-acting hypnotosedatives: zaleplon, zolpidem and zopiclone. *Clin Pharmacokinet*. 2004;43(4):227–38.
- 14 Malamed SF. Sedation: a guide to patient management, 5th edition, Mosby; 2010: 109.
- 15 Patat A, Naef MM, van Gessel E, Forster A, Dubruc C, Rosenzweig P. Flumazenil antagonizes the central effects of zolpidem. *Clin Pharmacol Ther*. 1994;56(4):430–6.
- 16 Rodrigo MR, Rosequist JB. The effect of Anexate on conscious sedation produce with midazolam. *Anaesth Intensive Care*. 1987;15:185.
- 17 Malamed SF. Sedation: a guide to patient management, 5th edition, Mosby; 2010: 347.

- 18 Greenblatt DJ, Ehrenberg BL, Gunderman J, et al. Kinetic and dynamic study of intravenous lorazepam: comparison with intravenous diazepam. *J Pharmacol Exp Ther.* 1989;250:134–40.
- 19 Becker DE, Pharmacodynamic considerations for moderate and deep sedation. *Anesth Prog.* 2012; 59(1):28–42.
- 20 Sher AM, Braude BM, Cleaton-Jones PE, Moyes DG, Mallett J. Nitrous oxide sedation in dentistry: a comparison between Rotameter settings, pharyngeal concentrations and blood levels of nitrous oxide. *Anaesthesia.* 1984;39:236–9.
- 21 Browne DR, Rochford J, O'Connell U, Jones JG. The incidence of postoperative atelectasis in the dependent lung following thoracotomy: the value of added nitrogen. *Br J Anaesth.* 1970 Apr;42(4):340–6.
- 22 Yacoub O, Doell D, Kryger MH et al. Depression of hypoxic ventilator response by nitrous oxide. *Anesthesiology.* 1976;45:385m.
- 23 Zhang C, Davies ME, Guo TZ, Maze M. The analgesic action of nitrous oxide is dependent on the release of norepinephrine in the dorsal horn of the spinal cord. *Anesthesiology.* 1999;91:1401–7.
- 24 Wylie WD, Churchill-Davidson HC. *A practice of anesthesia*, 4th edition. Philadelphia: WB Saunders; 1978.
- 25 Logothetis D. Local anesthetic agents: a review of the current options for dental hygienists, *CDHA J.* 2011 Summer.
- 26 Becker DE, Reed KL. Essentials of local anesthetic pharmacology. *Anesth Prog.* 2006 Fall;53(3):98–109.
- 27 Chong CA. Local anaesthetic and additive drugs. *Anesthesia UK.* 2005 Aug.
- 28 Logothetis D. Local anesthetic agents: a review of the current options for dental hygienists, *CDHA J.* 2011 Summer.
29. Tofoli GR, Ramacciato JC, de Oliveira PC, et al. Comparison of effectiveness of 4% articaine associated with 1:100,000 or 1:200,000 epinephrine in inferior alveolar nerve block. *Anesth Prog.* 2003;50:164–8.
- 30 Becker DE, Reed KL. Essentials of local anesthetic pharmacology. *Anesth Prog.* 2006 Fall;53(3):98–109.
- 31 Kritikos PG, Papadaki SP. The history of the poppy and of opium and their expansion in antiquity in the eastern Mediterranean area. *Bulletin on Narcotics.* United Nations Office on Drug Control (3-003); 1967: 17–38.
- 32 Drug Enforcement Administration. Museum and visitors center, Pentagon City, Arlington, VA.
- 33 Hemmings HC, Egan TD, *Pharmacology and physiology for anesthesia: foundations and clinical application.* Elsevier Health Sciences; 2013: 253.
- 34 Malamed SF. *Sedation: a guide to patient management*, 5th edition, Mosby; 2010: 330.
- 35 Becker DE, Pharmacodynamic considerations for moderate and deep sedation. *Anesth Prog.* 2012; 59(1):28–42.
- 36 Mannich C, Löwenheim H. Ueber zwei neue Reduktionsprodukte des Kodeins. *Archiv der Pharmazie.* 1920;258(2-4):295–316.
- 37 Hydrocodone bitartrate and acetaminophen: clinical pharmacology. RxList. Accessed 2009 February 19.
- 38 Sneader W. *Drug discovery: a history.* Hoboken, NJ: Wiley; 2005: 119.
- 39 IMS Health. National prescription audit, years 1997–2013. Data extracted 2014.

- 40 Lopez-Munoz, et al. The consolidation of neuroleptic therapy: Janssen, the discovery of haloperidol and its introduction into clinical practice. *Brain Res Bull.* 2009;79(2):130–41.
- 41 Malamed SF. *Sedation: a guide to patient management*, 5th edition, Mosby; 2010: 333.
- 42 Yardley W. Jack Fishman dies at 83; saved many from overdose. *New York Times.* 2013 Dec.
- 43 Malamed SF. *Sedation: a guide to patient management*, 5th edition, Mosby; 2010: 346.
- 44 McEvoy GK, editor. *Drug information 2012.* Bethesda, MD: American Society of Health-System Pharmacists; 2012: 2236–39.
- 45 Bosack R. *Anesthesia complications in the dental office.* John Wiley & Sons; 2015: 191.
- 46 Halford GM, Lordkipanidzé M, Watson SP. 50th anniversary of the discovery of ibuprofen: an interview with Dr Stewart Adams. *Platelets.* 2012;23(6):415–22.
- 47 Wahbi AA, Hassan E, Hamdy D, Khamis E, Barary M. Spectrophotometric methods for the determination of ibuprofen in tablets. *Pak J Pharm Sci.* 2005 Oct;18(4):1–6.
- 48 Dionne RA, Campbell RA, Cooper SA, Hall DL, Buckingham B. Suppression of postoperative pain by preoperative administration of ibuprofen in comparison to placebo, acetaminophen, and acetaminophen plus codeine. *J Clin Pharmacol.* 1983;23:37–43.
- 49 Moore PA, Nahouraii HS, Zovko JG, Wisniewski SR. Dental therapeutic practice patterns in the U.S, II: analgesics, corticosteroids, and antibiotics. *Gen Dent.* 2006;54(3):201–7.
- 50 Becker DE. Pain management: part 1. Managing acute and postoperative dental pain. *Anesth Prog.* 2010;57(2):67–79.
- 51 Melgarejo CM, Miller MG. *Pharmacology application in athletic training.* Philadelphia: F.A. Davis; 2005: 39.
- 52 Acetaminophen. *New World Encyclopedia.* 2016 Feb 11, 16:26 UTC; 2016 Sep 12, 03:49.
- 53 Forrest JA, Clements JA, Prescott LF. Clinical pharmacokinetics of paracetamol. *Clin Pharmacokinet.* 1982;7(2):93–107.
- 54 Sattar N, Preiss D, Murray H, et al. Statins and risk of incident diabetes: a collaborative meta-analysis of randomised statin trials. *Lancet.* 2010;375:735–42.
- 55 McNeil. Nonprescription Drugs Advisory Committee meeting, background package on acetaminophen. 2002 Sep 19.
- 56 Piletta P, Porchet HC, Dayer P. Central analgesic effect of acetaminophen but not aspirin. *Clin Pharmacol Ther.* 1991;49:350–4.
- 57 Acetaminophen. *New World Encyclopedia.* 2016 Feb 11, 16:26 UTC; 2016 Sep 12, 03:49.
- 58 Hersh EV, Moore PA, Ross GL. Over the counter analgesics and antipyretics: a critical assessment, *Clin Ther.* 2000;22(5):500–48.
- 59 Moore PA, Nahouraii HS, Zovko JG, Wisniewski SR. Dental therapeutic practice patterns in the U.S, II: analgesics, corticosteroids, and antibiotics. *Gen Dent.* 2006;54(3):201–7.
- 60 Moore RA, Derry S, McQuay HJ, Wiffen PJ. Single dose oral analgesics for acute postoperative pain in adults. *Cochrane Database Syst Rev.* 2011;(9):CD008659.
- 61 Moore PA, Hersh EV. Combining ibuprofen and acetaminophen for acute pain management after third molar extractions: translating clinical research to dental practice. *JADA.* 2013;144(8):898–908.

- 62 Laska EM, Sunshine A, Marrero I, et al. The correlation between blood levels of ibuprofen and clinical analgesic response. *Clin Pharmacol Ther.* 1986;40:1–7.
- 63 Moore PA. Bupivacaine: a long-lasting local anesthetic for dentistry. *Oral Surg Oral Med Oral Pathol* 1984;58(4):369–374.
- 64 Truollos ES, Hargreaves KM, Butler DP, et al. Comparison of nonsteroidal anti-inflammatory drugs, ibuprofen and flurbiprofen, methylprednisolone and placebo for acute pain, swelling, and trismus. *J Oral Maxillofac Surg* 1990;48(9):945–52.
- 65 Moore PA, Brar P, Smiga ER, Costello BJ. Preemptive rofecoxib and dexamethasone for prevention of pain and trismus following third molar surgery. *Oral Surg Oral Med Oral Pathol Oral Radiol Endod* 2005;99(2):E1–E7.
- 66 Ata-Ali J, Ata-Ali F, Peñarrocha-Oltra D, Peñarrocha M. Corticosteroids use in controlling pain, swelling and trismus after lower third molar surgery, *J Clin Exp Dent.* 2011;3(5):e469–75.
- 67 Rankovic Z, Hargreaves R, Bingham M. Drug discovery and medicinal chemistry for psychiatric disorders. Cambridge: Royal Society of Chemistry; 2012: 286.
- 68 Tiwana PS, Foy SP, Shugars DA. The impact of intravenous corticosteroids with third molar surgery in patients at high risk for delayed health-related quality of life and clinical recovery. *J Oral Maxillofac Surg.* 2005 Jan;63:55–62.
- 69 Messer EJ, Keller JJ. The use of intraoral dexamethasone after extraction of mandibular third molars. *Oral Surg Oral Med Oral Pathol.* 1975 Nov;40(5):594–8.
- 70 Grossi GB, Maiorana C, Garramone RA, Borgonovo A, Beretta M, Farronato D, Santoro F. Effect of submucosal injection of dexamethasone on postoperative discomfort after third molar surgery: a prospective study. *J Oral Maxillofac Surg.* 2007 Nov;65(11):2218–26.
- 71 Acham S, Klampfl A, Truschneg A, et al. Beneficial effect of methylprednisolone after mandibular third molar surgery: a randomized, double-blind, placebo-controlled split-mouth trial. *Clin Oral Invest.* 2013;17:1693.
- 72 Schultze-Mosgau, Schmelzeisen R, Frölich JC, Schmele H, Use of ibuprofen and methylprednisolone for the prevention of pain and swelling after removal of impacted third molars. *J Oral Maxillofac Surg.* 1995;53(1):2–7.
- 73 Becker DE. Pain management: part 1. Managing acute and postoperative dental pain. *Anesth Prog.* 2010;57(2):67–79.
- 74 Baxendale BR, Vater M, Lavery KM. Dexamethasone reduces pain and swelling following extraction of third molar teeth. *Anesthesia.* 1993;48:961–4.
- 75 Markiewicz MR, Brady MF, Ding EL, Dodson TB. Corticosteroids reduce postoperative morbidity after third molar surgery: a systematic review and meta-analysis. *J Oral Maxillofac Surg.* 2008;66:1881–94.
- 76 Jarrah MH, Al-Rabadi HF, Imrayan M, Al-share' AA. Single dose of dexamethasone with or without ibuprofen effects on post-operative sequelae of lower third molar surgical extraction. *J R Med Serv.* 2015;22(1):41–5.
- 77 Kipp DP, Goldstein BH, Weiss WW Jr. Dysethesia after mandibular third molar surgery: a retrospective study and analysis of 1377 surgical procedures. *J Am Dent Assoc.* 1980;100:185–92.
- 78 Miloro M, Ghali GH, Larsen P, Waite P. Peterson's principles of oral and maxillofacial surgery, 3rd edition. Shelton, CT: PMPH-USA; 2011: 114.
- 79 The Nobel Prize in Physiology or Medicine 1945. Nobelprize.org. Nobel Media AB 2014 [online]. Accessed: 2016 Sep 19.



- 80 Roy J. An introduction to pharmaceutical sciences production, chemistry, techniques and technology. Cambridge: Woodhead; 2012: 239.
- 81 Ainsworth SB. Neonatal formulary: drug use in pregnancy and the first year of life, 7th edition. Hoboken: John Wiley & Sons; 2014: 162.
- 82 Schlecht H, Bruno C. Lincosamides, oxazolidinones, and streptogramins. Merck Manual of Diagnosis and Therapy. Merck & Co; 2005 Nov.
- 83 Brook I, et al. Clindamycin in dentistry: more than just effective prophylaxis for endocarditis? *Oral Surg Oral Med Oral Pathol Oral Radiol Endod.* 2005;100:550–8.
- 84 Bowman WC, Rand MJ. Treatment of *Trichomonas urogenitalis*. Textbook of pharmacology, 2nd ed. Blackwell Scientific Publications; 1980: 36.16.
- 85 Becker DE, Antimicrobial drugs, *Anesth Prog.* 2013;60(3):111–23.
- 86 Siddiqi A, Morkel JA, Zafar S. Antibiotic prophylaxis in third molar surgery: A randomized double-blind placebo-controlled clinical trial using split-mouth technique. *Int J Oral Maxillofac Surg.* 2010;39:107–4.
- 87 Peterson LJ. Antibiotic prophylaxis against wound infections in oral and maxillofacial surgery. *J Oral Maxillofac Surg.* 1990;48:617–20.
- 88 Salmerón-Escobar JI, Del Amo-Fernández de Velasco A. Antibiotic prophylaxis in oral and maxillofacial surgery. *Med Oral Patol Oral Cir Bucal.* 2006;11:E292–6.
- 89 Lawler B, Sambrook PJ, Goss AN. Antibiotic prophylaxis for dentoalveolar surgery: Is it indicated? *Aust Dent J.* 2005;50:S54–9.
- 90 Miloro M, Kolokythas A, editors. Management of complications in oral and maxillofacial surgery. Hoboken: Wiley-Blackwell; 2012: 27.
- 91 Figueiredo R, Valmaseda-Castellon E, Berini-Aytes L. Incidence and clinical features of delayed-onset infections after extraction of lower third molars. *Oral Surg Oral Med Oral Pathol Oral Radiol Endod.* 2005;99:265.
- 92 Goldberg MH, Nemarich AN, Marco WP. Complications after mandibular third molar surgery: a statistical analysis of 500 consecutive procedures in private practice. *J Am Dent Assoc.* 1985;111:277–9.



## 7

## Sedation Techniques

This chapter is not intended to be a comprehensive review of sedation and anesthesia. Rather, it is a review of the three most common techniques used by general dentists when sedating adults. These three techniques—nitrous oxide, oral sedation, and IV sedation—are invaluable when removing impacted third molars. The reader is referred to Stanley Malamed's excellent book *Sedation: A Guide to Patient Management* for a comprehensive review of sedation.

It is estimated that as many as 75% of U.S. adults experience some degree of dental fear, from mild to severe.<sup>1-3</sup> Approximately 5% to 10% of U.S. adults are considered to experience dental phobia, that is, they are so fearful of receiving dental treatment that they avoid dental care at all costs.<sup>4</sup> People who are very fearful of dental care often experience a “cycle of avoidance,” in which they avoid dental care due to fear until they experience a dental emergency requiring invasive treatment, which can reinforce their fear of dentistry.<sup>5</sup> A survey of 1000 adult Americans found “going to the dentist” to be the second most common fear, only surpassed by public speaking.<sup>6</sup>

Gale ranked 25 dental situations from the most fearful to the least fearful. Removal of a tooth was the most feared situation.<sup>7</sup> Another study conducted in 2012 evaluated the level of fear and anxiety in patients undergoing different minor oral surgery procedures. The removal of a third molar was the most feared surgical procedure in the study.<sup>8</sup> Fortunately, thanks to the discovery of anesthesia, dentistry and the removal of impacted third molars can now be completed with minimal discomfort and with little or no memory of the procedure.


Prior to the discovery of modern anesthesia, patients facing surgery were confronted with impossible choices; namely, suffer a prolonged, painful death from their affliction or experience excruciating surgery without effective pain control. Faced with these options, many people committed suicide.

The discovery of modern anesthesia is often credited to two dentists, Dr. Horace Wells and Dr. William T. G. Morton.<sup>9</sup> Dr. Wells, a New England dentist, used nitrous oxide for the extraction of one of his teeth on 12 December 1844 (see Figure 7.1). Wells had seen nitrous oxide displayed the night before by the traveling chemist and showman Gardner Quincy Colton, a “purveyor of laughing gas.” Wells had noted that those under the influence of nitrous oxide seemed insensible to injury. Dr. Wells used nitrous oxide on a number of his patients with success.

Dr. William T. G. Morton, another New England dentist, was a former student and business partner of Wells (see Figure 7.2). Morton arranged for Wells to demonstrate his technique for dental extraction under nitrous oxide anesthesia at Massachusetts



**Figure 7.1** Dr. Horace Wells (via Wikimedia Commons).




**Figure 7.2** Dr. William T. G. Morton (via Wikimedia Commons). *Source:* Courtesy of National Library of Medicine (NLM).

General Hospital. This demonstration took place on 20 January 1845 and was deemed a failure because the patient moaned during the procedure. Believing that a more potent anesthetic gas was necessary, Dr. Morton began to search for a better agent than nitrous oxide. In October 1846, he demonstrated the use of diethyl ether as a general anesthetic at Massachusetts General Hospital, in what is known today as the Ether Dome. This time, the operation was deemed a success.

Research in the control of pain and anxiety continued following the discoveries of Wells and Morton. One hundred years later, Dr. Niels Bjorn Jorgensen (another dentist), developed the Jorgensen or “Loma Linda” technique for intravenous administration of drugs to induce sedation by titration.<sup>10</sup> Dr. Jorgensen is considered by many to be the father of intravenous sedation in dentistry (see Figure 7.3).

**Figure 7.3** Dr. Niels Jorgensen. *Source:* Reproduced by permission of Department of Archives and Special Collections, University Libraries, Loma Linda University.



Today, virtually all dental procedures can be completed without discomfort when topical and local anesthetics are used properly. However, difficult-to-numb patients, patients with long appointments or invasive procedures, and patients with high anxiety may require sedation. The goal of sedation is the elimination of anxiety and pain. Sedation is commonly used before and during impacted third molar surgery.

## Sedation as a Continuum

The concept of sedation as a continuum is the foundation of patient safety. In 2004, the American Society of Anesthesiologists made the following statement: “Because sedation and general anesthesia are a continuum, it is not always possible to predict how an individual patient will respond. Hence, practitioners intending to produce a given level of sedation should be able to diagnose and manage the physiologic consequences (rescue) for patients whose level of sedation becomes deeper than initially intended.”<sup>11</sup> Dentists providing sedation must have the training, skills, drugs, and equipment necessary to manage patients who are more deeply sedated than intended until EMS arrives or the patient returns to the intended level of sedation. Sedation is a continuum of levels of sedation from fully consciousness to unconsciousness (general anesthesia) (see Figure. 7.4).

The American Dental Association’s Council on Dental Education published “Guidelines for the Use of Sedation and General Anesthesia by Dentists” in 2007. A sedation and general anesthesia policy statement was adopted by the ADA House of Delegates in 2012. This policy statement contains the following definitions and clinical guidelines.<sup>12</sup>

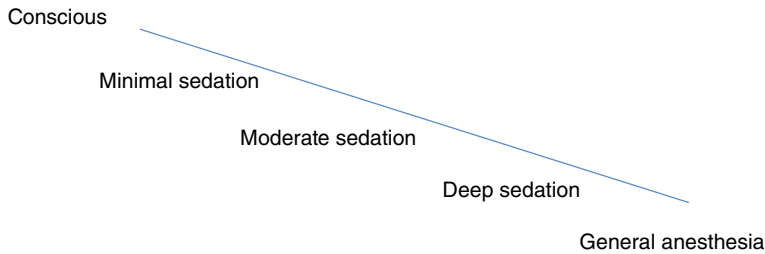


Figure 7.4 Sedation continuum.

## ADA Definitions (Verbatim)

**Minimal sedation** (previously anxiolysis) – a minimally depressed level of consciousness, produced by a pharmacological method, that retains the patient’s ability to independently and continuously maintain an airway and respond normally to tactile stimulation and verbal command. Although cognitive function and coordination may be modestly impaired, ventilatory and cardiovascular functions are unaffected.

Note: In accord with this particular definition, the drug(s) and/or techniques used should carry a margin of safety wide enough never to render unintended loss of consciousness. Further, patients whose only response is reflex withdrawal from repeated painful stimuli would not be considered to be in a state of minimal sedation.

When the intent is minimal sedation for adults, the appropriate initial dosing of a single enteral drug is no more than the maximum recommended dose (MRD) of a drug that can be prescribed for unmonitored home use.

**Moderate sedation** (previously conscious sedation) – a drug-induced depression of consciousness during which patients respond purposefully to verbal commands, either alone or accompanied by light tactile stimulation. No interventions are required to maintain a patent airway, and spontaneous ventilation is adequate. Cardiovascular function is usually maintained.

Note: In accord with this particular definition, the drugs and/or techniques used should carry a margin of safety wide enough to render unintended loss of consciousness unlikely. Repeated dosing of an agent before the effects of previous dosing can be fully appreciated may result in a greater alteration of the state of consciousness than is the intent of the dentist. Further, a patient whose only response is reflex withdrawal from a painful stimulus is not considered to be in a state of moderate sedation.

**Deep sedation** – a drug-induced depression of consciousness during which patients cannot be easily aroused but respond purposefully following repeated or painful stimulation. The ability to independently maintain ventilatory function may be impaired. Patients may require assistance in maintaining a patent airway, and spontaneous ventilation may be inadequate. Cardiovascular function is usually maintained.

**General anesthesia** – a drug-induced loss of consciousness during which patients are not arousable, even by painful stimulation. The ability to independently maintain

ventilator function is often impaired. Patients often require assistance in maintaining a patent airway, and positive pressure ventilation may be required because of depressed spontaneous ventilation or drug-induced depression of neuromuscular function. Cardiovascular function may be impaired.

The following definitions from the ADA guidelines apply to administration of minimal sedation:

**Maximum recommended dose (MRD)** – maximum FDA-recommended dose of a drug, as printed in FDA-approved labeling for unmonitored home use.

**Incremental dosing** – administration of multiple doses of a drug until a desired effect is reached, but not to exceed the maximum recommended dose (MRD).

**Supplemental dosing** – during minimal sedation, supplemental dosing is a single additional dose of the initial dose of the initial drug that may be necessary for prolonged procedures. The supplemental dose should not exceed one-half of the initial dose and should not be administered until the dentist has determined the clinical half-life of the initial dosing has passed. The total aggregate dose must not exceed 1.5x the MRD on the day of treatment.

The following definition from the ADA guidelines applies to moderate or greater sedation:

**Titration** – administration of incremental doses of a drug until a desired effect is reached. Knowledge of each drug's time of onset, peak response and duration of action is essential to avoid over sedation. Although the concept of titration of a drug to effect is critical for patient safety, when the intent is moderate sedation one must know whether the previous dose has taken full effect before administering an additional drug increment.

## ADA Clinical Guidelines (Verbatim)

### Minimal Sedation

#### 1. Patient Evaluation

Patients considered for minimal sedation must be suitably evaluated prior to the start of any sedative procedure. In healthy or medically stable individuals (ASA I, II) this may consist of a review of their current medical history and medication use. However, patients with significant medical considerations (ASA III, IV) may require consultation with their primary care physician or consulting medical specialist.

#### 2. Preparation

The patient, parent, guardian or care giver must be advised regarding the procedure associated with the delivery of any sedative agents and informed consent for the proposed sedation must be obtained. Determination of adequate oxygen supply and equipment necessary to deliver oxygen under positive pressure must be

completed. Baseline vital signs must be obtained unless the patient's behavior prohibits such determination. A focused physical evaluation must be performed as deemed appropriate. Preoperative dietary restrictions must be considered based on the sedative technique prescribed. Pre-operative verbal and written instructions must be given to the patient, parent, escort, guardian, or care giver.

### **3. Personnel and Equipment**

At least one additional person trained in Basic Life Support for Healthcare Providers must be present in addition to the dentist. A positive-pressure oxygen delivery system suitable for the patient being treated must be immediately available. When inhalation equipment is used, it must have a fail-safe system that is appropriately checked and calibrated. The equipment must also have either (1) a functioning device that prohibits the delivery of less than 30% oxygen or (2) an appropriately calibrated and functioning in-line oxygen analyzer with audible alarm. An appropriate scavenging system must be available if gases other than oxygen or air are used.

### **4. Monitoring and Documentation**

A dentist, or at the dentist's direction, an appropriately trained individual, must remain in the operatory during active dental treatment to monitor the patient continuously until the patient meets the criteria for discharge to the recovery area. The appropriately trained individual must be familiar with monitoring techniques and equipment. Monitoring must include oxygenation, ventilation, and circulation.

- **Oxygenation**

The color of mucosa, skin, or blood must be evaluated continually, and oxygen saturation by pulse oximetry should be considered.

- **Ventilation**

The dentist and/or appropriately trained individual must observe chest excursions and verify respirations continually.

- **Circulation**

Blood pressure and heart rate should be evaluated pre-operatively, post-operatively, and intra-operatively as necessary (unless the patient is unable to tolerate such monitoring).

An appropriate sedative record must be maintained, including the names of all drugs administered, including local anesthetics, dosages, and monitored physiological parameters.

### **5. Recovery and Discharge**

Oxygen and suction equipment must be immediately available if a separate recovery area is utilized. The qualified dentist or appropriately trained clinical staff must monitor the patient during recovery until the patient is ready for discharge by the dentist. The qualified dentist must determine and document that the level of consciousness, oxygenation, ventilation, and circulation are satisfactory prior to discharge. Post-operative verbal and written instructions must be given to the patient, parent, escort, guardian, or care giver.



## 6. Emergency Management

If a patient enters a deeper level of sedation than the dentist is qualified to provide, the dentist must stop the dental procedure until the patient returns to the intended level of sedation. The qualified dentist is responsible for the sedative management, adequacy of the facility and staff, diagnosis and treatment of emergencies related to the administration of minimal sedation, and providing the equipment and protocols for patient rescue.

## 7. Management of Children

For children 12 years of age and under, the American Dental Association supports the use of the American Academy of Pediatrics/American Academy of Pediatric Dentists Guidelines for Monitoring and Management of Pediatric Patients During and After Sedation for Diagnostic and Therapeutic Procedures.

## Moderate Sedation

### 1. Patient Evaluation

Patients considered for moderate sedation must be suitably evaluated prior to the start of any sedative procedure. In healthy or medically stable individuals (ASA I, II) this should consist of at least a review of their current medical history and medication use. However, patients with significant medical considerations (e.g., ASA III, IV) may require consultation with their primary care physician or consulting medical specialist.

### 2. Preparation

The patient, parent, guardian, or care giver must be advised regarding the procedure associated with the delivery of any sedative agents and informed consent for the proposed sedation must be obtained. Determination of adequate oxygen supply and equipment necessary to deliver oxygen under positive pressure must be completed. Baseline vital signs must be obtained unless the patient's behavior prohibits such determination. A focused physical evaluation must be performed as deemed appropriate. Pre-operative dietary restrictions must be considered based on the sedative technique prescribed. Pre-operative verbal or written instructions must be given to the patient, parent, escort, guardian, or care giver.

### 3. Personnel and Equipment

At least one additional person trained in Basic Life Support for Healthcare Providers must be present in addition to the dentist. A positive-pressure oxygen delivery system suitable for the patient being treated must be immediately available. When inhalation equipment is used, it must have a fail-safe system that is appropriately checked and calibrated. The equipment must also have either (1) a functioning device that prohibits the delivery of less than 30% oxygen or (2) an appropriately calibrated and functioning in-line oxygen analyzer with audible alarm. An appropriate scavenging system must be available if gases other than oxygen or air are used. The equipment necessary to establish intravenous access must be available.

#### **4. Monitoring and Documentation**

A qualified dentist administering moderate sedation must remain in the operatory room to monitor the patient continuously until the patient meets the criteria for recovery. When active treatment concludes and the patient recovers to a minimally sedated level a qualified auxiliary may be directed by the dentist to remain with the patient and continue to monitor them as explained in the guidelines until they are discharged from the facility. The dentist must not leave the facility until the patient meets the criteria for discharge and is discharged from the facility.

Monitoring must include consciousness, oxygenation, ventilation, and circulation.

- **Consciousness**

The level of consciousness (e.g., responsiveness to verbal command) must be continually assessed.

- **Oxygenation**

The color of mucosa, skin, and blood must be continually evaluated. Oxygen saturation must be evaluated continuously by pulse oximetry.

- **Ventilation**

The dentist must monitor ventilation. This can be accomplished by auscultation of breath sounds, monitoring end-tidal CO<sub>2</sub> or by verbal communication with the patient. The dentist must observe chest excursions continually.

- **Circulation**

The dentist must continually evaluate blood pressure and heart rate (unless the patient is unable to tolerate and this is noted in the time-oriented anesthesia record). Continuous ECG monitoring of patients with significant cardiovascular disease should be considered.

Appropriate time-oriented anesthetic record must be maintained, including the names of all drugs administered, including local anesthetics, dosages and monitored physiological parameters. Pulse oximetry, heart rate, respiratory rate and blood pressure must be recorded continually.

#### **5. Recovery and Discharge**

Oxygen and suction equipment must be immediately available if a separate recovery area is utilized. The qualified dentist or appropriately trained clinical staff must continually monitor the patient's blood pressure, heart rate, oxygenation, and level of consciousness. The qualified dentist must determine and document that level of consciousness; oxygenation, ventilation and circulation are satisfactory for discharge. Post-operative verbal and written instructions must be given to the patient, parent, escort, guardian or care giver. If a reversal agent is administered before discharge criteria have been met, the patient must be monitored until recovery is assured.

#### **6. Emergency Management**

If a patient enters a deeper level of sedation than the dentist is qualified to provide, the dentist must stop the dental procedure until the patient returns to the intended level of sedation. The qualified dentist is responsible for the sedative

management, adequacy of the facility and staff, diagnosis and treatment of emergencies related to the administration of moderate sedation and providing the equipment, drugs and protocol for patient rescue.

### **7. Management of Children**

For children 12 years of age and under, the American Dental Association supports the use of the American Academy of Pediatrics/American Academy of Pediatric Dentists Guidelines for Monitoring and Management of Pediatric Patients During and After Sedation for Diagnostic and Therapeutic Procedures.

## **Deep Sedation or General Anesthesia**

### **1. Patient Evaluation**

Patients considered for deep sedation or general anesthesia must be suitably evaluated prior to the start of any sedative procedure. In healthy or medically stable individuals (ASA I, II) this must consist of at least a review of their current medical history and medication use and NPO status. However, patients with significant medical considerations (e.g., ASA III, IV) may require consultation with their primary care physician or consulting medical specialist.

### **2. Preparation**

The patient, parent, guardian or care giver must be advised regarding the procedure associated with the delivery of any sedative or anesthetic agents and informed consent for the proposed sedation/anesthesia must be obtained. Determination of adequate oxygen supply and equipment necessary to deliver oxygen under positive pressure must be completed. Baseline vital signs must be obtained unless the patient's behavior prohibits such determination. A focused physical evaluation must be performed as deemed appropriate. Preoperative dietary restrictions must be considered based on the sedative/anesthetic technique prescribed. Pre-operative verbal and written instructions must be given to the patient, parent, escort, guardian or care giver. An intravenous line, which is secured throughout the procedure, must be established except in special circumstances (see Pediatric and Special Needs Patients).

### **3. Personnel and Equipment**

A minimum of three (3) individuals must be present. A dentist qualified in accordance with these Guidelines to administer the deep sedation or general anesthesia and two additional individuals who have current certification of successfully completing a Basic Life Support (BLS) Course for the Healthcare Provider are required. When the same individual administering the deep sedation or general anesthesia is performing the dental procedure, one of the additional appropriately trained team members must be designated for patient monitoring.

A positive-pressure oxygen delivery system suitable for the patient being treated must immediately be available. When inhalation equipment is used, it must have a fail-safe system that is appropriately checked and calibrated. The equipment must also have either (1) a functioning device that prohibits the delivery of less

than 30% oxygen or (2) an appropriately calibrated and functioning in-line oxygen analyzer with audible alarm. An appropriate scavenging system must be available if gases other than oxygen or air are used. The equipment necessary to establish intravenous access must be available. Equipment and drugs necessary to provide advanced airway management, and advanced cardiac life support must be immediately available. If volatile anesthetic agents are utilized, an inspired agent analysis monitor and capnograph should be considered. Resuscitation medications and an appropriate defibrillator must be immediately available.

#### **4. Monitoring and Documentation**

A qualified dentist administering deep sedation or general anesthesia must remain in the operatory room to monitor the patient continuously until the patient meets the criteria for recovery. The dentist must not leave the facility until the patient meets the criteria for discharge and is discharged from the facility. Monitoring must include oxygenation, ventilation, circulation, and temperature.

- **Oxygenation**  
Mucosa, skin, or blood color must be continually evaluated. Oxygen saturation must be evaluated continuously by pulse oximetry.
- **Ventilation**  
Respiration rate must be continually monitored and evaluated. End-tidal CO<sub>2</sub> must be continuously monitored and evaluated when treating intubated patients. Breath sounds via auscultation and/or end-tidal CO<sub>2</sub> must be continually monitored and evaluated when treating non-intubated patients.
- **Circulation**  
The dentist must continuously evaluate blood pressure, heart rate and rhythm via ECG throughout the procedure, as well as pulse rate via pulse oximetry.
- **Temperature**  
A device capable of measuring body temperature must be readily available during the administration of deep sedation or general anesthesia and must be used whenever triggering agents associated with malignant hyperthermia are administered.

Appropriate time-oriented anesthetic record must be maintained, including the names of all drugs administered, including local anesthetics, doses and monitored physiological parameters. Pulse oximetry and end-tidal CO<sub>2</sub> measurements (if taken), heart rate, respiratory rate and blood pressure must be recorded at appropriate intervals.

#### **5. Recovery and Discharge**

Oxygen and suction equipment must be immediately available if a separate recovery area is utilized. The dentist or clinical staff must continually monitor the patient's blood pressure, heart rate, oxygenation and level of consciousness. The dentist must determine and document that level of consciousness; oxygenation, ventilation and circulation are satisfactory for discharge. Post-operative verbal and written instructions must be given to the patient, parent, escort, guardian or care giver.

## 6. Pediatric and Special Needs Patients

Because many dental patients undergoing deep sedation or general anesthesia are mentally and/or physically challenged, it is not always possible to have a comprehensive physical examination or appropriate laboratory tests prior to administering care. When these situations occur, the dentist responsible for administering the deep sedation or general anesthesia should document the reasons preventing the recommended preoperative management. In selected circumstances, deep sedation or general anesthesia may be utilized without establishing an indwelling intravenous line. These selected circumstances may include very brief procedures or periods of time, which, for example, may occur in some pediatric patients; or the establishment of intravenous access after deep sedation or general anesthesia has been induced because of poor patient cooperation.

## 7. Emergency Management

The qualified dentist is responsible for sedative/anesthetic management, adequacy of the facility and staff, diagnosis and treatment of emergencies related to the administration of deep sedation or general anesthesia and providing the equipment, drugs and protocols for patient rescue.

## Medical Evaluation

A thorough medical evaluation is mandatory prior to administering sedative drugs (see Chapter 2). The purpose of the medical evaluation is to prevent medical emergencies while patients are sedated. Most sedation emergencies result from compromised airways and respiratory problems. Cardiovascular events are less common and typically follow a compromised airway.

The risk for complications while providing moderate and deep sedation is greatest when caring for medically compromised patients.<sup>13</sup> In the author's opinion, patients presenting with complicated medical histories, severe systemic disease, inability to cooperate, or unfavorable physical features should be sedated by an anesthesiologist or maxillofacial surgeon (see Box 7.1).

The use of sedation is contraindicated during pregnancy. The administration of sedative drugs during pregnancy, especially the first trimester, increases the chance of spontaneous abortion and fetal malformation. Antibiotics are commonly prescribed during pregnancy. Pericoronitis and other minor infections can be safely treated with antibiotics and third molar removal postponed. Amoxicillin and clindamycin are generally considered safe during pregnancy.<sup>14</sup> In the rare case that surgery cannot be postponed, a consultation with the patient's obstetrician-gynecologist is recommended. Local anesthetic and nitrous oxide sedation during the second trimester is the safest technique.

The American Society of Anesthesiology defines the ASA III patient as a patient with severe systemic disease. The author recommends limiting in-office sedation to ASA I and II patients unless the sedation is administered by an anesthesiologist. Monitoring of ASA III patients requires the full attention of the person administering drugs.

**Box 7.1 Conditions warranting referral to anesthesiologist or maxillofacial surgeon.****Medical History**

Snoring and apnea  
 Multiple medications  
 Prior hospitalization  
 Prior adverse reaction

**Cooperation**

Unable to communicate  
 Unable to understand  
 Dementia  
 Psychiatric disorders

**Severe Disease**

Heart  
 Lungs  
 Brain  
 Kidney and liver

**Physical Exam**

Morbidly obese  
 Difficult airway  
 Frail  
 Elderly

## Routes of Administration

There are nine possible routes of administration for sedative drugs used in dentistry:<sup>15</sup>

- 1) Intranasal
- 2) Transdermal
- 3) Subcutaneous
- 4) Rectal
- 5) Intramuscular
- 6) Inhalation/nitrous oxide
- 7) Sublingual
- 8) Oral
- 9) Intravenous.

### Intranasal

The intranasal route is used primarily for pediatric and disabled patients who are uncooperative. This route is more readily accepted by these patients. The absorption and bioavailability of drugs administered by this route is similar to drugs administered intravenously.

### Transdermal

A transdermal patch is a medicated adhesive patch that is placed on the skin to deliver a specific dose of medication through the skin and into the bloodstream. An advantage of a transdermal drug delivery route over other types of medication delivery is that transdermal administration provides controlled release of the medication into the patient. The first commercially available prescription patch was approved by the U.S. Food and Drug Administration in December 1979 for the prevention of motion sickness.

The highest selling transdermal patch in the United States is the nicotine patch, which releases nicotine in controlled doses to help with cessation of tobacco smoking.

Nitroglycerin patches are sometimes prescribed for the treatment of angina instead of sublingual pills. Narcotic drugs are administered by this route to provide round-the-clock relief for severe chronic pain.

### Subcutaneous

A subcutaneous injection is administered with a small-gauge needle directly under dermis and epidermis. Subcutaneous tissue has few blood vessels, which results in slow, sustained absorption of injected drugs. Subcutaneous injections are a common route of administration for insulin and allergy immunotherapy. Subcutaneous injections are not used in dentistry due to the slow rate of absorption.

### Rectal

The administration of drugs rectally has obvious limitations. This route of administration is normally limited to children who cannot or will not take medication orally. The rectal route is also useful as a suppository for adults who vomit when taking a drug orally. Medication taken orally or rectally is absorbed by the digestive system and enters the liver where it is metabolized. Only a portion of the active drug enters the circulatory system. This process, known as “first pass” (through the liver before circulation), greatly reduces the bioavailability of the drug.

### Intramuscular (IM)

The intramuscular technique is the least commonly used route in dentistry.<sup>16</sup> IM injections are the administrative route of choice in two situations:

- 1) Very young pediatric patients in preparation for intubation or venipuncture. The very young pediatric patient is usually restrained while ketamine is injected IM.
- 2) Emergencies requiring the injection of epinephrine. The fastest route to administer epinephrine in the management of anaphylaxis and bronchospasm is IM.

The main disadvantages to this route of administration are the inability to titrate or rapidly reverse drug effects in the event of an adverse drug reaction.

### Inhalation—Nitrous Oxide (N<sub>2</sub>O)

Many gases are used in dentistry to produce sedation or general anesthesia. However, nitrous oxide is the only gas routinely used in dental offices. Inhalation of nitrous oxide is the safest route of administration for patient sedation. The gas enters the circulatory system from the lungs and is effective for most patients within seconds. The ratio of nitrous oxide and oxygen can be adjusted to titrate to the desired level of sedation. Another major advantage is the ability to rapidly reverse sedation when the patient inhales 100% oxygen. Patients can leave the office unaccompanied, return to work, and even drive an automobile.

## Sublingual

The sublingual route is often used in dentistry to administer sedative drugs. The main advantage of the sublingual route is that the majority of the drug is not transformed in the liver before reaching the brain. Most of the drug bypasses the GI tract and liver and enters the circulatory system directly. Onset is faster than the oral route and more drug reaches target tissue. However, some of the drug is swallowed and enters the liver. Therefore, the time to peak effect may be the same as the oral route.

The main disadvantage of this route is the inability to titrate. Another disadvantage is a bitter taste. This can be alleviated somewhat by crushing a mint lifesaver with the drug.

## Oral

Oral sedation is the most common method of sedation used in dentistry. A sedative pill is easily administered, cost effective, and well received by patients. The major disadvantages are the slow absorption (first pass in the liver) and inability to titrate to desired effect. A group of patients taking the same dosage of the same drug will experience different levels of sedation. Some patients may be lightly sedated while others may be oversedated. It is recommended that patients take the oral sedative in the dental office. This guarantees patient compliance and monitoring by office staff.

## Intravenous (IV)

Malamed states, “The IV route of drug administration represents the most effective method of ensuring predictable and adequate sedation for virtually all patients.”<sup>17</sup> This route is especially effective when removing impacted third molars. Patients anticipating the removal of their wisdom teeth have increased levels of fear and anxiety when compared to their anticipating less-invasive dental procedures.<sup>18</sup> Rapid onset of action and the ability to titrate are important features of this route. Titration allows drug dosage to be customized to the desired effect for each patient. The ability to control the level of sedation increases safety when using the intravenous route.

Of the 10 routes of drug administration used in dentistry, the most common routes are inhalation, oral, and intravenous. Inhalation, oral, and intravenous sedation are all capable of producing minimal, moderate, and deep sedation or general anesthesia. These three techniques can be used to control pain and anxiety when removing impacted third molars.

## Inhalation (N<sub>2</sub>O)

Nitrous oxide/oxygen inhalation sedation has maintained an excellent safety record as a single drug technique. However, when nitrous oxide/oxygen is used in combination with other CNS depressant drugs, potentially serious side effects can occur.

Health risks to patients and staff are possible if proper use of the inhaled and exhaled nitrous oxide is not monitored. Dental offices can safely use nitrous oxide to control patient pain and anxiety by adopting some general work practices.



The following are American Dental Association guidelines for using nitrous oxide.<sup>19</sup>

- Every nitrous oxide delivery system should be equipped with a scavenging system. A flow meter (or equivalent measuring device) should be easy to see and well maintained to ensure accuracy. The system also should have a vacuum pump with the capacity for up to 45 liters of air per minute per workstation. The system also should come with masks in various sizes to ensure a proper fit for individual patients.
- Vent the vacuum and ventilation exhaust fumes outside (for example, through a vacuum system). Do not place exhaust system in the vicinity of the fresh-air intake vents. Ensure that the general ventilation provides good room-air mixing. Chronic occupational exposure—several hours a week—to nitrous oxide has been associated with adverse health effects.<sup>20</sup>
- Test the pressure connections for leaks every time the nitrous system is first turned on and each time a gas cylinder is changed. High-pressure line connections can be tested for leaks quarterly. You can use a soap solution applied to the lines and connections to test for leaks. Alternatively, you can purchase a portable infrared spectrophotometer to test these connections.
- Before the initial use of the system for the day, inspect all of the system components—reservoir bag, tubing, masks, connectors—for wear, cracks, holes, or tears. Replace any damaged pieces.
- Once all of the components have passed inspection, you can connect the mask to the tubing and turn on the vacuum pump. Ensure that the flow rate is correct—up to 45 L/minute or according to the manufacturer's recommendation.
- The mask should be properly fitted to each patient. Check that the reservoir bag does not over- or underinflate while the patient is breathing oxygen, before the nitrous is administered.
- Ask the patient to limit talking during administration of the nitrous and to try to breathe through his or her nose—avoid breathing through the mouth if possible.
- During administration, watch for changes in the tidal volume of the reservoir bag; also keep an eye on the vacuum pump flow rate.
- After the procedure, deliver 100% oxygen to the patient for 5 minutes before removing the mask. This will purge the system, and the patient, of any residual nitrous oxide.
- Periodically, personnel—particularly those who work with the nitrous oxide delivery—can be assessed for exposure. This can be done by asking the staff members to wear personal dosimetry badges or by placing an infrared spectrophotometer in the room.

### Patient Selection

Many experts consider nitrous oxide an inert, benign gas that has little if any influence on vital physiologic functions.<sup>21</sup> The inhalation of N<sub>2</sub>O/O<sub>2</sub> is suitable for ASA I, II, and some medically compromised ASA III patients. Nitrous oxide does not irritate the respiratory mucosa and can be used safely for patients with respiratory disease. Asthmatic patients who are prone to bronchospasm are good candidates for sedation with N<sub>2</sub>O/O<sub>2</sub> since stress

is reduced. COPD patients can be safely sedated with  $N_2O/O_2$ .<sup>22</sup> Hypoxia is decreased with the use of  $N_2O/O_2$  due to the increased flow of oxygen. This is particularly beneficial when treating patients with cardiovascular disease, cerebrovascular disease, and epilepsy. Patients with hepatic disorders are good candidates since the inhalation route bypasses the liver and is not bio-transformed. Nitrous oxide is also effective in treating patients with severe gag reflex. All elective dental treatment should be avoided during pregnancy, especially during the first trimester. Nitrous oxide is the recommended sedation technique for pregnant women when treatment is unavoidable. Nitrous oxide does not cross the placenta and the fetus is unaffected. Consultation with the patient's OB/GYN is recommended.

Nitrous oxide can provide minimal or moderate sedation when used as a single drug technique. This technique is ideal for patients with mild anxiety. For example, patients with a fear of needles can be titrated to a comfortable level of sedation before injecting local anesthetic and returned to a lower level after injecting. Nitrous oxide has analgesic properties and can raise a patient's pain threshold for "difficult to numb" patients. In general, the nitrous oxide route is advantageous for short procedures.

### Advantages and Disadvantages

There are many advantages to nitrous oxide sedation:

- 1) Nitrous oxide sedation is safe, with very few side effects.
- 2) Only nitrous oxide and intravenous sedation can be titrated due to their very short latent periods. Nitrous oxide has the fastest onset among inhalation agents due its low solubility in blood and adipose tissue. Nitrous oxide can be added incrementally until the desired level of sedation is reached. Once this point is determined, patients can be rapidly sedated at this predetermined level at future office visits.
- 3) The patient can be rapidly "rescued" and returned to the desired level of sedation should they become oversedated or experience adverse effects.
- 4) Nitrous oxide is the only modality discussed in this chapter that is not metabolized by the body. Patients recover quickly after breathing 100%  $O_2$  for 5 minutes. Most patients can leave the office unescorted. However, it is the responsibility of the treating dentist to determine if the patient can be dismissed without an escort.
- 5) Nitrous oxide has no adverse effects on cardiovascular, respiratory, brain, liver or kidney.
- 6) The onset of action is very rapid. Patients with anxiety find relief within minutes and begin to relax.
- 7) Nitrous oxide has analgesic properties. In the event of a missed block or partially effective block, the analgesic properties of nitrous oxide can raise the patient's pain threshold. Patients with fear of needles can be titrated to moderate sedation prior to intraoral injections and returned to minimal sedation following injections.

Although nitrous oxide and oxygen inhalation sedation is very safe, it does have disadvantages:

- 1) Nitrous oxide and oxygen delivery systems can be portable or permanently installed in the office. Both systems represent a significant initial investment of several thousand dollars.
- 2) Regular system monitoring and maintenance is required to prevent deleterious exposure to nitrous oxide. System monitoring and maintenance increases cost to the dental office. Nitrous oxide exposure to dental staff should be minimized to prevent

short-term behavioral and long-term reproductive health effects. The National Institute for Occupational Safety and Health (NIOSH) recommends no more than 25 ppm exposure to nitrous oxide during administration. Uncontrolled exposures to  $N_2O$  have exceeded 1000 ppm.

- 3) Patients may object to the nasal mask and hoses needed to deliver the gases.
- 4) The delivery of nitrous oxide in the dental office requires additional training. The American Dental Association guidelines recommend not less than 14 hours of training.

### Equipment

Continuous flow delivery systems are replacing demand-flow systems in the United States. The systems consist of two cylinders of compressed gas, nitrous oxide, and oxygen, and an inhalation sedation unit with flow meter. The gas cylinders can be mobile or permanently stored at a central location.

Mobile systems are normally found in offices that use inhalation sedation infrequently (see Figure 7.5). Color-coded gas cylinders, called E-type cylinders, are connected to the inhalation unit via the yoke. The yoke holds the cylinders in tight contact with the inhalation unit. Each gas cylinder has a pin configuration to fit its respective gas yoke. The pin positions are unique and correspond with the correct positions for nitrous oxide or oxygen. The cylinder will only connect to the correct equipment. The pin index system ensures the correct gas is filled into the correct cylinder.

Central storage systems connect the cylinder gases to multiple inhalation units. Each operatory contains an inhalation unit at a fixed location. The central storage systems are

**Figure 7.5** Mobile delivery system and color-coded gas cylinders.



expensive to install but relatively inexpensive to operate because the gas cylinders are large H cylinders. These cylinders are cost effective when compared with the smaller E cylinders.

All continuous flow nitrous oxide delivery systems have flow meters that permit the user to visualize the flow of gases and adjust the precise amount of each gas administered to the patient. The flow meter measures the quantity of gas flowing into a tube. Increasing the flow of gas into the tube raises a ball float in the tube. Calibrations on the tube represent liters per minute flow. State-of-the-art systems use digital flow meters that measure gas flow in 0.1 L/min increments. The total flow and percentage of O<sub>2</sub> are displayed digitally (see Figures 7.6a and 7.6b).



Figure 7.6 (a) Nitrous oxide ball float. (b) Digital flow meter.

Other system components include regulators, manifolds, reservoir bags, and nasal hoods. Regulators reduce the cylinder compressed gas pressure to a safe and constant level at the flow meter. The manifold replaces the yoke in central storage systems and joins multiple H cylinders together. The reservoir bag functions as a gas reserve when the gas flow from the cylinders is insufficient, for example, when the patient takes a deep breath. Importantly, adequate respiration can be monitored by observing the reservoir bag.

A nasal hood is connected to the reservoir bag by rubber tubing. The nasal hood adapts to the patient's nose (see Figure 7.7). Scavenging nasal hoods are used to minimize nitrous oxide contamination in the dental office. These devices consist of a small inner nosepiece covered by a larger outer nosepiece. Four tubes are connected to the nosepiece. Two rubber tubes provide cylinder gas to the inner hood and two separate tubes suction exhaled gas from the outer hood. Other scavenging systems use different mask designs, but the principle is the same. Unwanted nitrous oxide is removed from room air.

Many safety features in addition to scavenging nasal hoods are mandatory for inhalation units sold in the United States. The pin index system and reservoir bags have already been discussed. Additional safety features include color coding, minimum oxygen percentage, oxygen fail safe and alarm, emergency air inlet, and positive-pressure connections.

System components and gas cylinders that handle oxygen are color coded green. Nitrous oxide components and gas cylinders are color coded blue. Nitrous oxide and oxygen sedation systems have a minimum oxygen percentage safety feature. This feature maintains oxygen percentage at a minimum of 30%. Another safety feature, known as the oxygen fail safe, terminates the flow of nitrous oxide and sounds an alarm if oxygen pressure falls below 50 psi. The oxygen fail safe prevents the delivery of 100% nitrous oxide. The emergency air inlet safety feature is activated

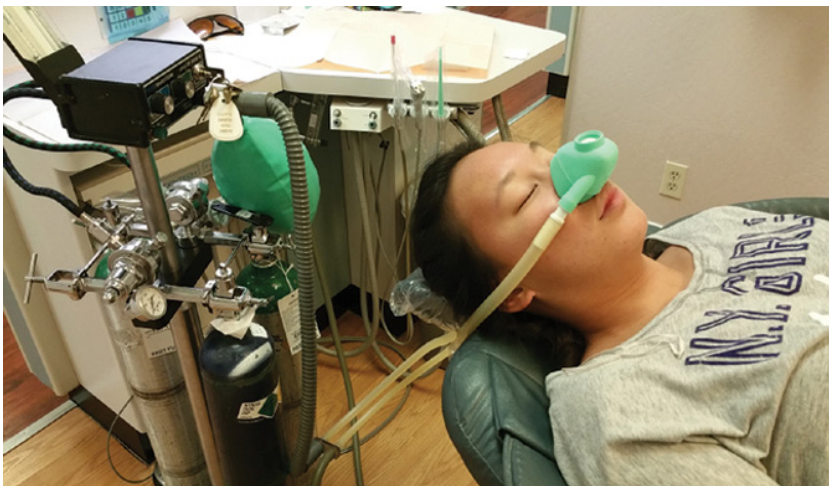

Figure 7.7 Scavenging nasal hood and tubing.

**Table 7.1** N<sub>2</sub>O required for ideal sedation.

Percentage of Population	Nitrous Percentage
70	30–40
12	<30
18	>40

when the flow of gas ceases. A valve opens, allowing the patient to breathe room ambient air. Finally, all nitrous oxide and oxygen delivery systems are required to have quick-connect positive-pressure connections.

### Administration

Nitrous oxide should be titrated to effect using either constant liter flow or constant oxygen flow technique. The constant liter flow technique gradually increases nitrous flow while decreasing oxygen flow by an equal amount. For example, once oxygen flow rate is established, nitrous flow can be increased by 1 liter per minute while oxygen flow is simultaneously decreased by 1 liter per minute. Titration of nitrous oxide continues until the desired sedation is achieved. The constant oxygen technique maintains oxygen flow rate at a predetermined level while nitrous oxide flow is gradually increased. For example, oxygen flow rate is set at 4 liters per minute and nitrous oxide flow rate is gradually increased in 1 liter/minute increments until the desired sedation level is achieved.

Unfortunately, many dentists using nitrous oxide do not titrate when using nitrous oxide. Patients vary in their response to drugs.<sup>23</sup> In any given population of patients, 70% of patients will achieve ideal sedation with a nitrous oxide percentage between 30% and 40%, 12% require less than 30%, and 18% require more than 40% (see Table 7.1). Titrating every 60 to 90 seconds will achieve ideal sedation for most patients within 3–6 minutes.

Although nitrous oxide inhalation is very safe as a single drug technique, oversedation is possible when titration is not used. Patients may complain of nausea or dizziness, laugh uncontrollably, have disturbing dreams, respond to questions slowly, or attempt to remove the nasal hood. All of these signs and symptoms are indications that the patient is oversedated and the nitrous oxide percentage should be reduced. Oversedation can also occur during periods when the patient is not being stimulated.

No drug administration route is 100% safe. Although nitrous oxide is considered very safe, complications are more likely when it is combined with other drugs. Sedation regulations of most U.S. states consider the single drug administration of nitrous oxide to be minimal sedation. Combining nitrous oxide with other drugs can result in deeper states of sedation or general anesthesia.

## Oral Sedation

The use of modern oral sedatives began in the 19th century with the use of bromides and chloral hydrate. Bromide salts were used in medicine as mild tranquilizers and sedatives. Bromides are no longer used as sedatives due to several negative side effects, including frequent urination, sweating, visual disturbances, and electrolyte disturbances. Chloral hydrate was synthesized in 1832 by the German chemist Justus von Liebig. Chloral hydrate is a generalized CNS depressant that acts rapidly, and if given alone, is capable of inducing deep sleep in approximately 30 minutes. Although chloral hydrate was first introduced over a century ago, it remains a popular option for sedation in the pediatric practice.

Most oral sedatives in the early 20th century were barbiturates. A Prussian chemist, Adolf von Baeyer, is credited with inventing and naming barbituric acid in the early 1860s. Many pharmaceutical companies developed new barbiturates in the 1920s and 1930s. Unfortunately, barbiturates produce significant cardiovascular and respiratory depressant effects. Due to their narrow margin of safety, the use of barbiturates for sedation is no longer recommended in most clinical situations. They have been replaced by safer oral sedatives (e.g., benzodiazepines).

Dr. Anthony Feck and Dr. Michael Silverman established the Dental Organization for Conscious Sedation (DOCS) in 1999. DOCS promoted oral sedation using the benzodiazepine triazolam for dental patients with fear and anxiety. The use of oral sedation in dentistry dramatically increased in the United States following the founding of DOCS.

The oral route of sedation is the oldest and most commonly used route of drug administration in dentistry. Oral drugs are easy to administer and affordable. Most patients will readily accept swallowing a pill to reduce their anxiety prior to the removal of impacted third molars.

## Patient Selection

ASA I and II patients with mild anxiety are good candidates for oral sedation. Claustrophobic patients who cannot tolerate the N<sub>2</sub>O/O<sub>2</sub> nasal hood may do well with the oral route. Oral sedation is also an option for patients refusing intravenous sedation.

The intended level of oral sedation should be minimal. A single maximum recommended dose, administered in the office, assures patient compliance and safety. The inability to titrate oral drugs is a severe limitation of this route. Incremental and supplemental oral dosages are discouraged because peak plasma levels are unpredictable. Oral sedation drugs are CNS depressants that can cause oversedation or general anesthesia.

Maximum drug activity of most orally administered drugs is reached approximately 60 minutes after ingestion. If deeper levels of sedation are required, moderate sedation can be achieved safely by titrating N<sub>2</sub>O/O<sub>2</sub> or intravenous drugs. Titration is started after a maximum recommended oral dose has reached peak plasma level.

Oral sedation should be used with caution for children and elderly patients due to age-dependent pharmacodynamic alterations. Lower dosages and shorter acting medications are typically required in order to avoid oversedation.<sup>24</sup>

## Advantages and Disadvantages

Oral sedation has several advantages over other routes of administration:

- 1) Oral sedation is effective for mild to moderate anxiety.
- 2) Oral sedation cost is similar to inhalation (N<sub>2</sub>O) sedation but less than IV sedation.
- 3) One of the main advantages of oral sedation is the route of administration. It is the easiest way to administer drugs of all possible routes. Swallowing a small pill before the appointment is all that is required. There is no need to breathe through a mask like in nitrous oxide sedation. Patients with needle phobias do not need to have a needle in a vein as in IV sedation.
- 4) Oral sedation is safer than IV sedation and general anesthesia due to its long latent period and slow absorption. The number and severity of adverse reactions is low when compared to IV sedation.
- 5) There are no needles, syringes, or equipment required.

Although the oral route of administration has many advantages, it also has many significant disadvantages:

- 1) The level of sedation is not easily reversed as it is with nitrous oxide or IV sedation. The oral route requires more monitoring than nitrous oxide sedation to insure patient safety.
- 2) Titration of drugs is difficult when using the oral route due to the long latent period. It can be 30–60 minutes following drug administration before a clinical effect is observed.
- 3) Patients may not comply with prescribed oral medication directions. When patient compliance is questionable, it is recommended that patients take their oral sedative in the office under the supervision of office staff.
- 4) Absorption of drugs from the GI tract is erratic and incomplete. Many variables affect the absorption of oral sedatives. Consistent clinical results are difficult to achieve.
- 5) The level of sedation cannot be easily increased or decreased as with nitrous oxide or IV sedation.

## Sublingual Administration

Many drugs are designed for sublingual administration, including cardiovascular drugs, steroids, barbiturates, and analgesics. One of the best-known drugs administered sublingually is nitroglycerin. Nitroglycerin sublingual tablets are vasodilators used to treat angina for patients with coronary artery disease.

Sublingual administration of sedatives can be considered a subcategory of oral administration because the sedative is delivered orally under the tongue and in a powdered form. However, there are significant differences in these two routes. As mentioned previously, sublingual drugs enter the circulatory system without significant absorption from the GI tract or metabolism in the liver. Sublingual administration results in faster onset and more profound effect when compared to oral administration.<sup>25</sup> Triazolam is a common benzodiazepine sedative hypnotic drug administered sublingually prior to dental procedures. Pills are crushed into



fine powder that easily penetrates the thin sublingual mucosa (see Figure 7.8).

Berthold et al. compared the effects of sublingual versus oral administration of triazolam for premedication prior to oral surgery.<sup>26</sup> The double-blind, placebo-controlled study compared 0.25 mg sublingual triazolam, 0.25 mg oral triazolam, and placebo administered 1 hour before oral surgery. Sublingual administration of triazolam resulted in significantly less anxiety and pain at 15 minutes intraoperatively than both orally administered triazolam and placebo. No difference was demonstrated in the rate of recovery or incidence of side effects between the two drug groups. Plasma triazolam levels were higher after sublingual administration during and after the surgical procedure. These results indicate that sublingually administered triazolam results in greater sedation and less pain perception than orally administered triazolam.

Sublingual sedatives should be administered in the dental office under the supervision of trained office staff. Patient compliance is assured.



Figure 7.8 Pill crusher.

## Intravenous Sedation

Intravenous sedation is a relatively new technique for the control of pain and anxiety in dentistry. Several scientific advancements preceded the use of intravenous sedation. Sterile technique, intravenous syringes, and new drugs were necessary before Niels Bjorn Jorgensen, the father of intravenous sedation, developed the Jorgensen technique in 1945. Dr. Jorgensen called his technique “intravenous premedication.”<sup>27</sup>

The intravenous route for patient sedation has been used almost exclusively by oral and maxillofacial surgeons until recently. Today, the placement of dental implants is included in virtually every United States dental school curriculum. Dental schools have begun to teach intravenous sedation to control the fear and anxiety of implant patients. In addition, there are many high-quality postgraduate IV sedation continuing education courses available today. Pulse oximetry and capnography are now available to monitor sedation and increase the margin of safety.

No drug administration route is perfect or without disadvantages. However, the IV route is considered the most predictable and effective sedation route due to the ability to easily titrate to the desired end point. The IV route, also known as parenteral, offers the ultimate control of drug administration. Sedative and analgesic drugs are rapidly titrated to the desired level of sedation. Benzodiazepines and narcotics can be reversed should a patient become more deeply sedated than intended. It is the most common route of drug administration used by oral and maxillofacial surgeons when removing impacted third molars.

## Patient Selection

Moderate intravenous sedation is indicated for patients with moderate to severe anxiety. These patients may have had previous sedation with other techniques that were not successful. Moderate IV sedation is the logical next step.

The IV route is especially useful when removing impacted third molars. Opioids have analgesic properties and create euphoria. These characteristics help to mitigate the pressure, sound, and unpleasantness associated with impacted third molar surgery.

Although the IV route is very safe when properly administered, adverse events are more likely and serious when compared to N<sub>2</sub>O/O<sub>2</sub> or oral sedation. The author recommends limiting IV sedation to ASA I and II patients.

## Advantages and Disadvantages

There are several advantages to the IV route of administration:

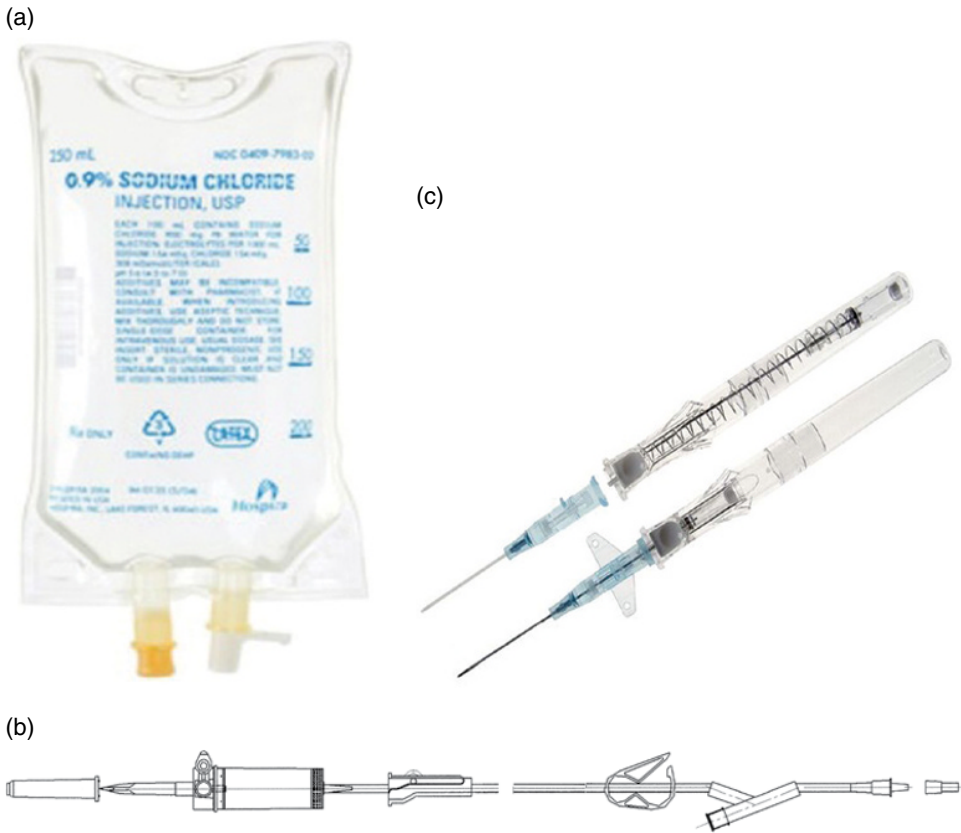
- 1) There is no “first pass” hepatic metabolism, and drugs reach the brain full strength.
- 2) Drugs are injected directly into the circulatory system and reach the brain within 20–25 seconds. The rapid onset of action of CNS-depressant drugs allows the dentist to easily titrate to the desired level of sedation.
- 3) Drug effects can be rapidly enhanced or reversed. The IV line offers a readily available route for the administration of emergency drugs if needed. This is one of the most important safety features of IV drug administration.
- 4) Recovery is more rapid than other routes, with the exception of N<sub>2</sub>O/O<sub>2</sub>.
- 5) Nausea and vomiting are uncommon when drugs are administered intravenously.

The IV route of drug administration also has disadvantages:

- 1) Venipuncture is necessary and can be difficult, requiring multiple attempts. Apprehensive patients may not cooperate.
- 2) Venipuncture site complications are rare but possible. Complications include phlebitis, hematoma, and intra-arterial injection of a drug.
- 3) Drug overdose, allergic reaction, and associated problems are more likely when compared with other routes, due to the rapid onset of action of drugs administered intravenously.
- 4) Patients can be sedated deeper than intended if drugs are not titrated properly. Monitoring of patients must be more intensive and training more extensive in order to “rescue” patients who become more deeply sedated than intended.
- 5) Recovery is not complete, as it is with N<sub>2</sub>O/O<sub>2</sub>. Patients sedated intravenously need an escort after the procedure.
- 6) IV sedation is not always successful. Patients with severe anxiety may require general anesthesia.

## Equipment

IV sedation continuous infusion requires three sterile components: infusion solution, administration set, and catheter (see Figures 7.9a, 7.9b, and 7.9c). The most common infusion solution used in dental offices is 0.9% sodium chloride, also known as normal saline. Other options include 5% dextrose in water and Lactated Ringer’s solution.



**Figure 7.9** (a) IV solution. (b) IV administration set. (Reproduced by permission of Excel International Co.) (c) BD Insite autoguard 22-gauge safety catheter. *Source:* Courtesy and © Becton, Dickinson and Company.

The purpose of continuous infusion of fluid is to prevent blood clotting at the end of the catheter. The catheter is a short flexible tube that remains in the patient's vein during continuous infusion. The catheter is connected to larger diameter tubing, known as an IV administration set, which is connected to the sterile solution. A basic IV administration set consists of sterile tubing 78 inches long with a plastic spike on one end and a male connector on the opposite end. The spike connects to the IV solution bag and the male connector connects to the catheter hub. The male connector is either Luer slip, which is a friction connection, or Luer lock, which is a threaded connection. The Luer slip is used for short dental office procedures. The IV administration set has three components to control the flow of solution: a clamp to shut off flow, a roller clamp to control the rate of flow, and a drip chamber to view fluid dripping from the solution bag.

A catheter is recommended for venipuncture, instead of scalp vein needles. The catheter has a metal needle, a syringe within its lumen, and a plastic hub that connects to the administration set. The syringe is used to puncture the vein and introduce the catheter into the vein. Blood flow back into the syringe after venipuncture indicates the needle is within the vein. The catheter is slid off of the metal syringe and into the vein. The catheter

is connected to the administration set. Many sizes and designs are available. Most catheters are radiopaque when used in hospitals. Clear catheters (SureFlash, Terumo), 22 or 24 gauge, are recommended for dental office sedation due to the instant visibility of blood in the catheter once the catheter has entered a vein.

Ancillary equipment includes a tourniquet, alcohol gauze, medical adhesive tape, Velcro restraints, and a small bungee cord. A tourniquet is needed to engorge veins, making them more visible prior to venipuncture. Alcohol gauze is used to clean and prepare the venipuncture site. Once the venipuncture is complete, the catheter is connected to the administration set and secured with medical tape. The IV solution bag must be above the patient's heart. A small bungee cord can be used to attach the bag to the ceiling or operatory light's articulating arm. Solution is allowed to drip into the drip chamber and continue from the bag of solution into the patient's vein. Drugs are injected through a port in the administration set tubing. Velcro restraints can be used to prevent the patient's arm from bending while connected to the IV administration set.

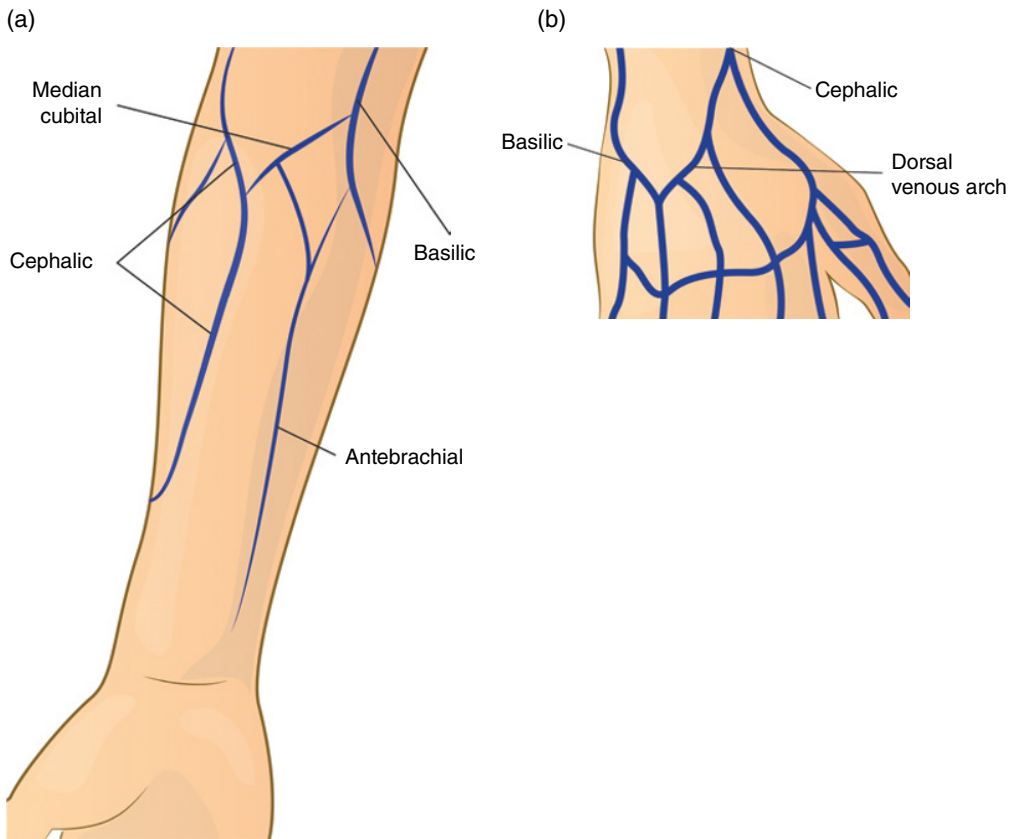
Many alternatives exist for the equipment listed in this section. For example, an IV stand can be used instead of a bungee cord, a scalp vein needle can be used instead of a catheter. The myriad equipment available for sedation can be overwhelming and confusing to the beginner. The items listed provide simple and affordable options.

## Venipuncture

The most common sites for venipuncture are the antecubital fossa and dorsum of the hand. The author recommends the antecubital fossa because the veins are large and relatively stable. Venipuncture of the dorsum of the hand is more painful and the veins are more likely to collapse or move. The median cubital vein connects the basilic and cephalic vein and is often used for venipuncture (see Figures 7.10a and 7.10b). It is also known as the median basilic vein. This vein is a superficial vein located close to the surface of the skin and away from nerves. The median cubital vein usually forms an H pattern, with the cephalic and basilic veins making up the legs of the H. Other forms include an M pattern, where the vein branches to the cephalic and basilic veins.

Venipuncture steps for the antecubital fossa.

- 1) Apply a tourniquet 3–4 inches above the antecubital fossa.
- 2) Clean the site with 70% alcohol gauze, moving in an outward spiral from the site.
- 3) Hold the catheter above the vein at a 15–30 degree angle with the bevel facing up.
- 4) Place traction on the skin below the venipuncture site in the opposite direction of the venipuncture.
- 5) Puncture the skin and enter the vein a few millimeters in one smooth motion. Blood will be seen in the stylet chamber when the vein is entered. Blood will also be seen in the catheter before the stylet chamber if a clear catheter is used. This confirms that the catheter is in the vein lumen.
- 6) Immediately reduce the catheter angle to parallel the vein and advance the catheter a few more millimeters.
- 7) Slide the catheter off the stylet. The stylet should be held in place with one hand while the other hand slides the catheter off the stylet and into the vein. Dentists



**Figure 7.10** (a) Antecubital fossa veins. (b) Dorsum of the hand veins.

experienced with venipuncture can complete the venipuncture and slide the catheter off the stylet with one hand.

- 8) Place fingertip pressure on the skin above the catheter tip to prevent blood flow from the catheter hub when the stylet is removed.
- 9) The assistant holds the free end of the IV administration set close to the catheter hub and removes the stylet.
- 10) The dentist, while holding pressure above the catheter tip, immediately connects the IV administration set to the catheter hub. The IV set is secured with tape, the tourniquet removed, and the IV drip started.

Venipuncture steps for dorsum of the hand. These steps are essentially the same as the antecubital fossa steps with the following exceptions:

- 1) The patient's hand should be slightly flexed at the wrist to stabilize the vein.
- 2) Traction is placed on the skin below the patient's knuckles in a direction opposite to the venipuncture.
- 3) The catheter enters the vein from the side, not from above the vein. Veins of the hand tend to be more mobile than the superficial veins of the antecubital fossa.

Terminating IV infusion:

- 1) Remove adhesive tape.
- 2) Place a sterile gauze pad over the puncture site, remove the catheter, and apply pressure.
- 3) Place a bandage or sterile gauze with tape over the puncture site.

Venipuncture is an art form that can be learned only through experience. Even phlebotomists and infusion nurses occasionally miss a vein. Obese patients with deep veins, elderly patients with fragile veins, and patients with small mobile veins are especially difficult.

Dental patients scheduled for the removal of impacted third molars with IV sedation have additional venipuncture challenges. Sedation patients should be NPO, with no fluids, for at least four hours prior to the appointment. The resultant dehydration shrinks veins, making successful venipuncture more difficult. Finally, patients scheduled for the removal of impacted third molars usually have anxiety and circulating catecholamines that cause peripheral vasoconstriction.

There are many methods that can help find a vein and increase successful venipuncture (see Box 7.2). Practitioners experienced in venipuncture typically spend significant time locating an appropriate vein to insure success on the first attempt. Look for the best vein on both arms. Patients with a difficult venipuncture history often remember the successful site. If veins are not obvious, ask the patient if they had difficulty in the past. Where is the best site for venipuncture? Placing a tourniquet, followed by opening and closing a fist, engorges the veins below the tourniquet and makes them more visible. Tapping or rubbing the vein may make the veins more prominent. If you can't see any veins, the best alternative is to palpate with your index finger before venipuncture. A "bouncy" sensation indicates a good vein.

Difficult venipuncture patients may require uncommon methods to find a good vein. A variation of palpating for vein bounce is to wet the palpating finger and venipuncture site with alcohol. It's a technique not found in textbooks, but the author has found it to be helpful. There's something about reducing friction on the skin that makes it easier to sense the curvature of a vein. Veins that are not visible and cannot be palpated may respond to a blood pressure cuff when used as a tourniquet. The cuff is inflated to a number near the patient's diastolic pressure. A third method for difficult veins involves heat. The application of heat increases blood flow and dilates veins. Fink et al. studied 136 patients randomly assigned to two groups using dry or moist heat. Warm towels were wrapped around each patient's arm for seven minutes prior to IV insertion. The dry heat group was 2.7 times more likely than the moist heat group to result in

#### Box 7.2 Methods for finding veins.

##### Common Venipuncture Methods

Take your time—be patient  
 Check both arms  
 Ask the patient for preferred site  
 Open and close fist  
 Tap or rub the vein  
 Palpate, feel the vein "bounce"

##### Uncommon Venipuncture Methods

Palpate with alcohol on skin  
 Use a BP cuff as tourniquet  
 Apply dry heat  
 Use a trans-illumination device  
 Breathe nitrous oxide

successful venipuncture on the first attempt.<sup>28</sup> The dry heat group was more comfortable and had significantly lower insertion times than the moist heat group. Another uncommon method is the use of a trans-illumination device. These devices use infrared LED lights to illuminate veins. They range from a few hundred dollars to several thousand. These vein-finding devices work best in a darkened room. The final uncommon method for finding veins is unique to dentistry. Because nitrous oxide is a vasodilator, the use of N<sub>2</sub>O can make veins more prominent while reducing the discomfort of venipuncture.

Once venipuncture is successful, the IV administration set is connected to the catheter and drugs can be added intravenously. Many IV drugs and administrative techniques are taught in dental schools, residencies, and postgraduate continuing education courses. This chapter focuses on the most common drugs and techniques used in dental offices when removing impacted third molars.

### Administration

The IV route of administration provides superior control when compared with other routes. The ability to rapidly titrate to moderate sedation makes the IV route very desirable when removing impacted third molars. Drugs enter directly into the circulatory system at maximum strength, bypassing the GI tract and liver. The most common drugs used for moderate IV sedation are midazolam (Versed) and fentanyl (Sublimaze). Midazolam is a benzodiazepine. Fentanyl is an opioid. Benzodiazepines and opioids can be reversed using antagonistic drugs administered intravenously. This is an important safety feature of benzodiazepines and opioids when administered intravenously.

A review of the literature by Qi Chen et al. found that the incidence of adverse events when midazolam was used during third molar removal was no higher than when a placebo was used. They concluded that midazolam can be used for ASA I and II patients as a safe and effective drug for anxiety control in third molar extraction surgery.<sup>29</sup> In spite of being relatively safe, intravenous midazolam should only be used with continuous monitoring of respiratory and cardiac function.

Direct monitoring of the patient is accomplished through verbal contact. Is the patient responsive? Other monitoring devices include pulse oximetry, capnography, precordial stethoscope, and ECG (see Chapter 8). Patients who are moderately sedated will respond purposefully to verbal commands and light tactile stimulation. They can breathe spontaneously without assistance. Signs of moderate sedation include Verrill sign, slurred speech, and delayed verbal response when questioned. Verrill sign is indicated by half-way ptosis of the upper eyelid. Patients who are moderately sedated have difficulty keeping their eyes open.

Midazolam is a sedative hypnotic that can create both sedation and amnesia. It can be used alone or with fentanyl. The intravenous administration of midazolam with fentanyl is not recommended for dentists new to moderate IV sedation. The author recommends at least 100 sedations using the single drug midazolam before adding another drug such as fentanyl.

The single-drug midazolam technique illustrates the proper administration of IV drugs. Monitors consistent with state requirements are connected to the patient and baseline vital signs recorded. Following venipuncture, the IV line is opened and the patient is placed in a supine position. Opening the IV line allows a rapid flow of IV

solution and decreases the possibility of local irritation at the venipuncture site when drugs are administered. Midazolam is administered in a concentration of 1 mg/ml. A 3 ml syringe containing 3 mg of midazolam is inserted into a port in the administration set and 1 ml (1 mg) of the drug is administered slowly. The patient is observed for hypersensitivity, allergic response, Verrill sign, slurred speech, or delayed verbal response. Additional midazolam is administered at 1-minute intervals until Verrill's sign is observed (usually 5 mg or less) or 8 mg has been administered. Exceeding 8 mg of midazolam is not recommended for the dentist new to moderate sedation.<sup>30</sup> Patients who are not sedated sufficiently with 8 mg of midazolam may need a two-drug technique or general anesthesia.

It has been the author's experience that virtually all impacted third molar surgery can be completed using fentanyl and midazolam to a level of moderate sedation. The following technique has been used successfully by the author for more than 30 years when removing impacted third molars.

This protocol is used for ASA I and II patients who are NPO for 6 hours prior to appointment. Patients arrive at the office 1 hour before the procedure. Informed consent is completed with the patient and/or parent and 0.5 mg of triazolam is administered sublingually. The sublingual sedative serves two purposes:

- 1) Sublingual administration increases safety. Administering a sublingual sedative prior to IV drug administration provides an indication of the patient's drug sensitivity. Most patients will be minimally sedated with 0.5 mg triazolam. However, this is not true for every patient. This phenomenon is illustrated by the normal distribution bell-shaped curve (see Figure 7.11).

The slow onset of sublingual triazolam provides a margin of safety for the ultra-sensitive patient. Patients who are minimally sedated with sublingual triazolam may need reduced amounts of IV drugs. Fentanyl and midazolam are administered very slowly for these patients. Conversely, IV fentanyl and midazolam can be safely

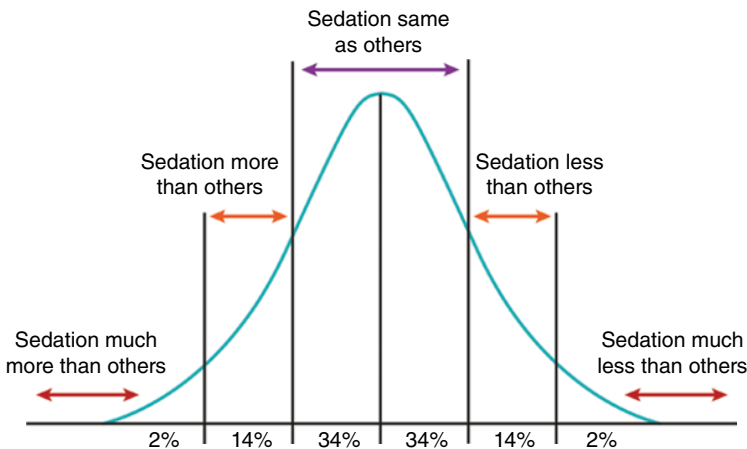


Figure 7.11 Patients vary in their response to drugs.



administered faster and in larger amounts for patients who do not exhibit signs of minimal sedation following sublingual administration.

- 2) Sublingual administration increases patient venipuncture tolerance. Difficult venipuncture may require multiple attempts. Patients who are minimally sedated are more relaxed and venipuncture is more readily accepted.

Patients are seated in the operatory one hour after administration of triazolam. The patient is observed for signs of sedation. Some patients will appear normal while others will have difficulty walking and talking normally. Patients who are significantly sedated and exhibit Verrill's sign do not receive IV midazolam. Consistent with the normal distribution curve, about 2% of patients sedated with sublingual triazolam do not need IV midazolam. Most patients, about two-thirds, receive 50 mg of fentanyl and 3 mg midazolam. A very small percentage of patients require more midazolam titrated to a moderate level of sedation. All patients receive 8 mg dexamethasone intravenously to reduce swelling and postoperative nausea and vomiting.

Following patient sedation, local anesthetic is administered (without topical) including maxillary PSA and premolar infiltration, mandibular and Gow Gates blocks, and palatal injections. The patient is observed during injections to assess the effectiveness of sedation. The palatal injection is especially noteworthy. This injection is universally acknowledged to be one of the most painful injections in dentistry. Patients who are adequately sedated will have no response or may ask "What was that?" or "Did you just give me a shot?" Obviously, these patients are adequately sedated.

The palatal injection is also useful to differentiate between true pain and pressure. The removal of teeth often requires significant pressure. Most dentists have experienced patients who are tense and gripping the operatory chair when removing teeth with forceps and local anesthesia. When patients are questioned after the procedure, it is common to hear that the extraction was not painful, but the pressure was uncomfortable. No amount of sedation will completely eliminate the sensation of pressure.

It is important to note that no sedation technique will work 100% of the time. Safe sedation requires that patients remain responsive. A common mistake made by dentists who are new to IV sedation is to add more drug if a patient moves or complains. In most cases, these are patients with high anxiety who are responding to pressure. It is also possible that mandibular anesthesia is inadequate. Sedation is not a substitute for good local anesthesia.

Most surgeons and dentists removing impacted third molars will remove one side before the other. The author prefers to remove maxillary third molars before mandibular third molars. This sequence provides extra time for profound anesthesia of mandibular third molars. Also, maxillary third molars are usually easier to remove than mandibular third molars. The removal of maxillary third molars before mandibular third molars may increase patient confidence and the effectiveness of sedation. Patients with high anxiety are often more "relaxed" during removal of mandibular third molars when preceded by removal of maxillary third molars.

Many techniques and drugs are available for sedation. This chapter reviewed the most common techniques and drugs used by dentists for patient sedation. Regardless of the technique used, patient safety is paramount.

## References

- 1 Kleinknecht RA, Thorndike RM, McGlynn FD, Harkavy J. Factor analysis of the dental fear survey with cross-validation. *J Am Dent Assoc.* 1984;108(1):59–61.
- 2 Getka EJ, Glass CR. Behavioral and cognitive-behavioral approaches to the reduction of dental anxiety. *Behavior Therapy.* 1992;23(3):433–48.
- 3 Milgrom P, Weinstein P, Getz T. Treating fearful dental patients: a patient management handbook, 2nd edition. Seattle: University of Washington, Continuing Dental Education; 1995.
- 4 Gatchel RJ, Ingersoll BD, Bowman L, Robertson MC, Walker C. The prevalence of dental fear and avoidance: a recent survey study. *J Am Dent Assoc.* 1983;107(4):609–10.
- 5 Armfield JM, Stewart JF, Spencer AJ. The vicious cycle of dental fear: exploring the interplay between oral health, service utilization and dental fear. *BMC Oral Health.* 2007;7:1.
- 6 Our most common fears. *Dental Health Advisor.* 1987 Spring.
- 7 Gale EN. Fears of the dental situation. *J Dent Res.* 1972;51(4):964–6.
- 8 Sirin Y, Humphris G, Sencan S, Firat D. What is the most fearful intervention in ambulatory oral surgery? Analysis of an outpatient clinic. *Int J Oral Maxillofac Surg.* 2012;41(10):1284–90.
- 9 Enever G. The history of dental anaesthesia. *Oxford Textbook of Anaesthesia for Oral and Maxillofacial Surgery.* 2010 Jun.
- 10 Jorgensen NB, Hayden J. Sedation, local and general anesthesia in dentistry, 3rd edition. Philadelphia: Lea & Febiger; 1980.
- 11 American Society of Anesthesiologists. Continuum of depth of sedation: definition of general anesthesia and levels of sedation/analgesia. 2004.
- 12 American Dental Association. Guidelines for the use of sedation and general anesthesia by dentists. Guidelines policy statement adopted by the ADA House of Delegates. 2012.
- 13 Becker DE, Haas DA. Management of complications during moderate and deep sedation: respiratory and cardiovascular considerations, *Anesth Prog.* 2007;54(2):59–69.
- 14 Harms RW. Antibiotics and pregnancy: what's safe? *Mayo Clinic.* 2014 Oct 3.
- 15 Malamed SF. Sedation: a guide to patient management, 5th edition. Mosby; 2010: 116.
- 16 Malamed SF. Sedation: a guide to patient management, 5th edition. Mosby; 2010: 18.
- 17 Malamed SF. Sedation: a guide to patient management, 5th edition. Mosby; 2010: 18.
- 18 Sirin Y, Humphris G, Sencan S, Firat D, What is the most fearful intervention in ambulatory oral surgery? Analysis of an outpatient clinic. *Int J Oral Maxillofac Surg.* 2012;41(10):1284–90.
- 19 ADA Council on Scientific Affairs. Nitrous oxide in the dental office. *JADA* 1997;128(3):364–5.
- 20 Becker DE, Rosenberg M. Nitrous oxide and the inhalation anesthetics, *Anesth Prog.* 2008;55(4):124–31.
- 21 Howard WR. Nitrous oxide in the dental environment: assessing the risk, reducing the exposure. *JADA.* 1997;128(3):356–60.
- 22 Malamed SF. Sedation: a guide to patient management, 5th edition. Mosby; 2010: 18.
- 23 School of Dentistry, University of Southern California. Statistics from section of anesthesia and medicine. Los Angeles: Mosby; 2006, unpublished.

- 24 Stoelting RK, Dierdorf SF. Diseases associated with aging. In: Anesthesia and co-existing disease, 4th ed. Philadelphia: Churchill Livingstone; 2002: 740.
- 25 Narang N, Sharmna J. Sublingual mucosa as a route for systemic drug delivery. *Int J Pharmacy Pharmaceutical Sci.* 2011;3(Suppl 2).
- 26 Berthold CW, Dionne RA, Corey SE. Comparison of sublingually and orally administered triazolam for premedication before oral surgery. *Oral Surg Oral Med Oral Pathol Oral Radiol Endod.* 1997;84(2):119–24.
- 27 Jorgensen, NB, Leffingwell, FB, Premedication in dentistry. *J So Calif Dent Assoc.* 1953;21:1.
- 28 Fink RM, et al. The impact of dry versus moist heat on peripheral iv catheter insertion in a hematology-oncology outpatient population. *Oncology Nursing Forum.* 2009;36(4):E198–204.
- 29 Chen Q, Wang L, Ge L, Gao Y, Wang H. The anxiolytic effect of midazolam in third molar extraction: a systematic review, *PLoS One.* 2015;10(4):e0121410.
- 30 Malamed SF. Sedation: a guide to patient management, 5th edition. Mosby; 2010: 361.



## 8

### Sedation Emergencies and Monitoring

The removal of third molars is one of the most feared surgical procedures in dentistry.<sup>1</sup> Third molars can be removed under local anesthesia alone, but most patients and dentists do not prefer this option. Conscious sedation options include nitrous oxide, oral sedation, and IV sedation. All of these options place the patient at some degree of risk for complications.

As stated previously in Chapter 7, the concept of sedation as a continuum is the foundation of patient safety. In 2004, the American Society of Anesthesiologists made the following statement: “Because sedation and general anesthesia are a continuum, it is not always possible to predict how an individual patient will respond. Hence, practitioners intending to produce a given level of sedation should be able to diagnose and manage the physiologic consequences (rescue) for patients whose level of sedation becomes deeper than initially intended.”<sup>2</sup> Dentists providing sedation must have the training, skills, drugs, and equipment necessary to manage patients who are more deeply sedated than intended until EMS arrives or the patient returns to the intended level of sedation. These attributes are the keys to patient safety.

### Patient Safety and Sedation Law

In 2002 the Dental Board of California called for a review of anesthesia laws and patient outcomes to see if any improvements could be made to the existing regulatory program. The board appointed the Blue Ribbon Panel on Anesthesia, an ad hoc committee composed of general dentists and dental specialists who were recognized experts in the field. The panel reviewed mortality data from the Dental Board of California, lawsuits from a major California malpractice insurance company, anesthesia regulations from other states, and the published scientific literature. The review found that in California, between 1991 and 2000, there were 12 deaths related to general anesthesia permits, 8 deaths related to nonpermit holders (four deaths with oral sedation in children and four deaths with local anesthesia alone), and 0 deaths related to conscious sedation permits.<sup>3</sup> The California Dental Board Blue Ribbon Panel review clearly demonstrates the efficacy of conscious sedation.

The American Dental Association has published recommended guidelines (adopted by the house of delegates in October 2016) for the use of sedation. California and the majority of states have adopted the American Dental Association’s guidelines as state law.

*Impacted Third Molars*, First Edition. John Wayland.

© 2018 John Wiley & Sons, Inc. Published 2018 by John Wiley & Sons, Inc.

Companion website: [www.wiley.com/go/wayland/molars](http://www.wiley.com/go/wayland/molars)

California sedation laws and permit requirements (2016) are discussed in this chapter with emphasis on intravenous sedation emergencies and monitoring. A permit is not required in California for the administration of nitrous oxide and oxygen. The following excerpt is from the Dental Board of California.<sup>4</sup>

To obtain a California permit for the administration of oral (moderate) conscious sedation, the applicant must have completed an approved postdoctoral or residency training program that includes sedation training, or a board-approved course that includes 25 hours of instruction and a clinical component utilizing at least one age-appropriate patient.

To obtain a California permit for IV (moderate) conscious sedation, the applicant must complete at least 60 hours of instruction and 20 clinical cases of administration of parenteral conscious sedation for a variety of dental procedures. The course must comply with the requirements of the Guidelines for Teaching the Comprehensive Control of Anxiety and Pain in Dentistry of the American Dental Association.

In California, a conscious sedation permit (IV sedation) is issued as a temporary permit for the first year. Within that time, the board conducts an onsite inspection and evaluation of the licensee. Onsite inspections are required every six years. Fifteen units of continuing education related to conscious sedation and medical emergencies are required every two years.

All offices in which conscious sedation is conducted in California must complete an office inspection and applicant evaluation. The office inspection consists of three parts:

### **Facilities and Equipment Requirements**

The following office facilities and equipment must be available and maintained in good operating condition:

- 1) An operating theater large enough to adequately accommodate the patient on a table or in an operating chair and permit an operating team consisting of at least three individuals to freely move about the patient.
- 2) An operating table or chair that permits the patient to be positioned so the operating team can maintain the airway, quickly alter patient position in an emergency, and provide a firm platform for the management of cardiopulmonary resuscitation.
- 3) A lighting system that is adequate to permit evaluation of the patient's skin and mucosal color and a backup lighting system which is battery powered and of sufficient intensity to permit completion of any operation underway at the time of general power failure.
- 4) Suction equipment, which permits aspiration of the oral and pharyngeal cavities, and a backup suction device that can operate at the time of general power failure.
- 5) An oxygen delivery system with adequate full face masks and appropriate connectors that is capable of allowing the administering of greater than 90% oxygen at a 10 liter/minute flow for at least 60 minutes (650 liter "E" cylinder)

to the patient under positive pressure, together with an adequate backup system that can operate at the time of general power failure.

- 6) A recovery area that has available oxygen, adequate lighting, suction, and electrical outlets. The recovery area can be the operating theatre.
- 7) Ancillary equipment including all of the following:
  - a) Emergency airway equipment (oral airways, laryngeal mask airways or combitubes, cricothyrotomy device).
  - b) Tonsillar or pharyngeal type section tips adaptable to all office outlets.
  - c) Sphygmomanometer and stethoscope.
  - d) Adequate equipment for the establishment of an intravenous infusion.
  - e) Precordial/pretracheal stethoscope.
  - f) Pulse oximeter.

### Records

The following records must be maintained:

- 1) Adequate medical history and physical evaluation records. Must be updated prior to each administration of sedation and shall include but are not limited to the recording of the age, sex, weight, physical status (American Society of Anesthesiologists Classification), medication use, any known or suspected medically compromising conditions, rationale for sedation of the patient, and visual examination of the airway, and for general anesthesia only, auscultation of the heart and lungs as medically required.
- 2) Conscious sedation records that show:
  - a) A time-oriented record with preoperative, multiple intraoperative, and postoperative pulse oximetry (every 5 minutes intraoperative).
  - b) Multiple blood pressure and pulse readings.
  - c) Drugs administered, amounts administered, and time administered.
  - d) Length of procedure.
  - e) Any complications of anesthesia or sedation.
  - f) Statement of the patient's condition at time of discharge.
- 3) Written informed consent of the patient or if the patient is a minor, the parent or guardian.

### Drugs

Emergency drugs of the following types must be available:

- 1) Epinephrine
- 2) Vasopressor (other than epinephrine)
- 3) Bronchodilator
- 4) Appropriate drug antagonists
- 5) Antihistaminic
- 6) Anticholinergic
- 7) Coronary artery vasodilator
- 8) Anticonvulsant
- 9) Oxygen
- 10) 50% dextrose or other antihypoglycemic

The applicant evaluation consists of two parts:

### (1) Demonstration of Conscious Sedation

A dental procedure utilizing conscious sedation administered by the applicant must be observed and evaluated. Any conscious sedation technique that is routinely employed can be demonstrated. The patient must be monitored while sedated and during recovery from sedation. The applicant for a permit must demonstrate knowledge of the uses of emergency equipment and the capability of using that equipment.

### (2) Simulated Emergencies

Knowledge of and a method of treatment must be physically demonstrated by the dentist and his or her operating team for the emergencies shown in Box 8.1.

The 13 simulated emergencies evaluated in the state of California are representative of evaluations conducted in other states. The following section discusses recognition, treatment, and prevention of these emergencies.

## Sedation Emergencies

When compared with local anesthesia alone, the two most significant negative variables introduced by any level of sedation are the added risks for either airway obstruction or respiratory depression (hypoventilation). Airway obstruction and respiratory depression are the most significant complications in deeply sedated or unconscious patients. Virtually all cardiovascular complications in healthy patients are preceded by airway complications.<sup>5</sup>

The management of any emergency begins with the ABC primary assessment taught in every basic life support course. Airway, breathing, and circulation are also the foundation of ACLS (advanced cardiovascular life support). Dr. Frank Grimaldi described this assessment in its simplest form: “air goes in and out and blood goes round and round.”<sup>6</sup>

### Airway Obstruction

Airway obstruction can be mechanical or pathological. Upper airway obstruction is caused by anatomical structures or foreign materials. The most common upper airway

#### Box 8.1 Simulated emergencies.

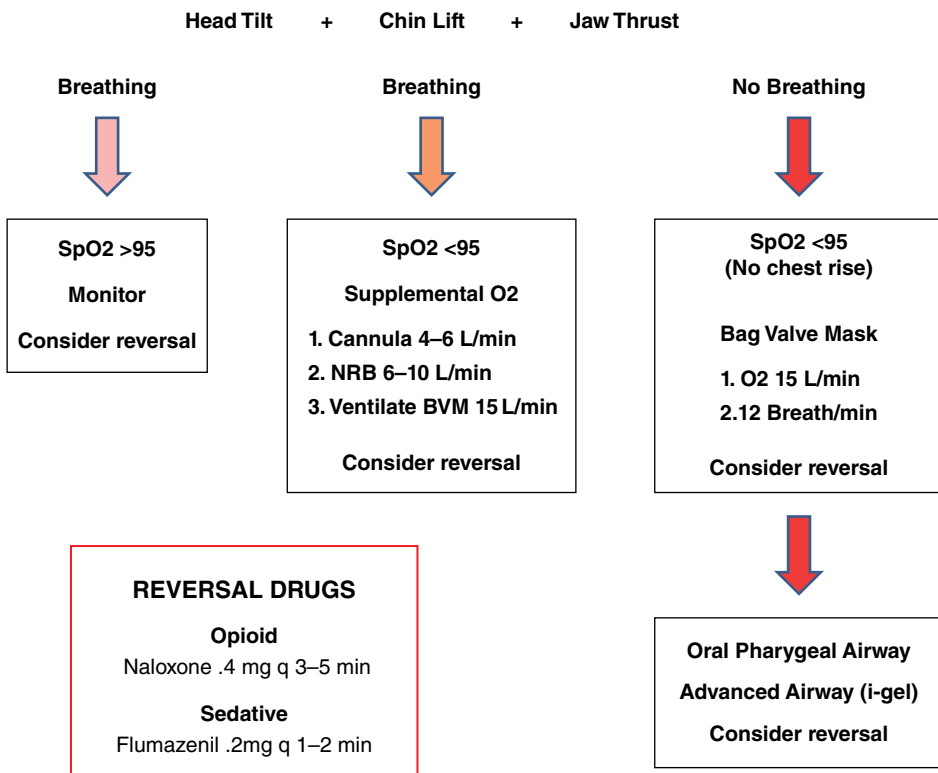
- |                           |                   |
|---------------------------|-------------------|
| 1) Airway obstruction     | 8) Cardiac arrest |
| 2) Respiratory depression | 9) Hypotension    |
| 3) Allergic reaction      | 10) Hypertension  |
| 4) Bronchospasm           | 11) Seizure       |
| 5) Emesis and aspiration  | 12) Hypoglycemia  |
| 6) Angina pectoris        | 13) Syncope       |
| 7) Myocardial infarction  |                   |



obstruction is the tongue. Common foreign materials include crowns, bridges, and teeth. Lower airway obstruction is caused by bronchospasm, laryngospasm, or allergic reaction. Airway obstruction leads to hypoventilation and hypoxemia. It can be prevented by titration of drugs and the use of a throat pack barrier. The treatment for airway obstruction begins with the triple maneuver: head tilt, chin lift, and jaw thrust (if unconscious). Supplemental oxygen should be administered with airway adjuncts added as needed. Possible airway adjuncts include oropharyngeal airways (OPA), nonrebreathing masks (NRB), and bag valve masks (BVM). Drug reversal should be considered. EMS should be called if oxygen saturation does not improve (see Figure 8.1).

### Respiratory Depression

Respiratory depression must be distinguished from airway obstruction. The risk of respiratory depression is low with moderate sedation when compared to anatomical airway obstruction (tongue, tonsils, adenoids). Patients with airway obstruction can't breathe. Patients with respiratory depression won't breathe. Respiratory depression is a side effect of CNS depressants. All opioids and sedatives have the potential to depress hypercapnic or hypoxemic drives. Opioids are the most powerful respiratory depressants. Treatment is the same as airway obstruction (see Figure 8.1).



**Figure 8.1** Airway obstruction/respiratory depression algorithm.

### Allergic Reaction

It is not uncommon for a patient’s medical history to list adverse drug reactions. Generally, these are found to be drug sensitivities and not true allergic reactions. When the patient’s history includes airway compromise or cutaneous reactions, allergy is more likely. In terms of cutaneous reactions, urticaria (hives) is most indicative of an IgE-mediated reaction.<sup>7</sup> Histories of compromised airway or difficulty breathing should be taken seriously. These reports indicate severe allergic reaction and anaphylaxis. A partial airway obstruction from anaphylaxis is characterized by a high-pitched crowing sound.

Allergic reactions can be reduced by completing a thorough medical history and interview. Intravenous administration of a drug test dose and titration may provide an early warning of adverse reactions. Mild allergic reactions are treated by oral, intramuscular, or intravenous administration of diphenhydramine. Severe allergic reactions are treated with epinephrine (see Figure 8.2).

### Bronchospasm

Bronchospasm is a lower airway obstruction resulting from contraction or spasm of bronchial smooth muscle. Laryngeal edema is a common characteristic. Bronchospasm can result from an anaphylactic reaction or from a hyperactive airway as found with asthmatic patients. Dyspnea and wheezing are common characteristics of bronchospasm due to obstructions in the chest, not the throat or mouth.

#### Primary Assessment

<b>Responsive</b>	<b>Airway</b>	<b>Oxygen</b>	<b>BP</b>
<b>Unresponsive</b>	<b>Breathing</b>	<b>SpO2</b>	<b>Rate</b>

#### Signs and Symptoms

**Allergic Reaction/Anaphylaxis**

**Pruritis Rash Hives/Crowing**



<b>Benadryl</b>
1. PO – 50 mg/ml
2. UM – 50 mg/ml
3. IV – 25 mg/0.5 ml dilute
or
4. Epinephrine 1:1000 IM .3 mg/0.3 ml

**Bronchospasm**

**Wheezing**



<b>Albuterol 2 puffs</b>
or
<b>Epinephrine 1:1000 IM .3 mg/0.3 ml</b>

#### Treatment

Figure 8.2 Allergic reaction and bronchospasm algorithm.

Stress may trigger an asthmatic attack and bronchospasm. Sedation may decrease stress and help prevent bronchospasm in patients with asthma. Treatment includes use of a bronchodilator, such as albuterol, or epinephrine (see Figure 8.2).

### Emesis and Aspiration

Emesis is possible following the administration of sedative drugs including nitrous oxide. Although aspiration of vomitus is unlikely when airway protective reflexes are intact, dentists should be prepared for this emergency. Aspiration of liquids usually results in bronchospasm. Pulse oximeter values are usually under 90% and cannot be improved. EMS should be immediately activated. Patients should be placed in the Trendelenburg position with their head turned to the right to prevent vomitus from entering the left bronchus and lungs. The pharynx should be suctioned using pharyngeal suction. Oxygen should be administered and drugs reversed.

A thorough patient interview may reveal a history of nausea and vomiting. Sedated patients should be NPO for 6 hours prior to the removal of third molars. Unfortunately, patients are not always compliant with this rule. Slow titration of drugs to light or moderate sedation reduces the possibility of nausea and vomiting (see Figure 8.3).

### Angina Pectoris

Ischemic heart disease is a condition whereby coronary perfusion is inadequate for myocardial oxygen requirements. Angina pectoris is defined as chest pain caused by narrowing of coronary arteries and reduced oxygen to the heart. Inadequate oxygen supply precipitates angina and myocardial infarctions. Patients with a history of angina whose chest pain is provoked by stress, anxiety, or inadequate local anesthesia are treated with nitroglycerin. Unprovoked chest pain may be a myocardial infarction.

#### Primary Assessment

<b>Responsive</b>	<b>Airway</b>	<b>Oxygen</b>	<b>BP</b>
<b>Unresponsive</b>	<b>Breathing</b>	<b>SpO2</b>	<b>Rate</b>

#### Treatment

1. **EMS**
2. **Trendelenburg right side**
3. **Suction**
4. **Oxygen**
5. **Reversal agents**

#### REVERSAL DRUGS

##### Opioid

Naloxone .4 mg q 3–5 min

##### Sedative

Flumazenil .2 mg q 1–2 min

Figure 8.3 Emesis and aspiration algorithm.

### Primary Assessment

<b>Responsive</b>	<b>Airway</b>	<b>Oxygen</b>	<b>BP</b>
<b>Unresponsive</b>	<b>Breathing</b>	<b>SpO2</b>	<b>Rate</b>

### Chest Pain

Provoked, nitroglycerin 1 tablet

Unprovoked, new onset, unsure



**Relief**  
 1. Resume treatment  
 2. Discharge

**No Relief**

1. **EMS**
2. Fentanyl 25 mcg, q 3–5 min
3. Oxygen 6 L/min
4. NTG prn q 5 min; SBP >90
5. ASA 325 mg (non enteric)  
 Acronym is FONA

Figure 8.4 Angina pectoris/myocardial infarction algorithm.

### Primary Assessment

1. **Unresponsive**
2. **Airway good**
3. **No breathing**
4. **No pulse**



1. **EMS**
2. **CPR**
3. **AED**

1. Compressions - fast, deep, continuous
2. Ventilations 30:2 - BVM 15 l/min
3. Listen to AED and follow

Figure 8.5 Cardiac arrest algorithm.

### Myocardial Infarction (MI)

MI is the death of myocardium caused by ischemia. MI should be suspected in patients with unprovoked chest pain and no prior history of angina. Angina patients who do not get relief from nitroglycerin may also be having an MI. An MI is a serious complication requiring EMS intervention. Treatment includes fentanyl for pain, oxygen to increase coronary perfusion, nitroglycerin for vasodilation, and chewed aspirin to prevent clot formation by decreasing platelet aggregation (FONA). Adverse cardiovascular events are reduced when stress, pain, and myocardial oxygen demand are decreased (see Figure 8.4).

### Cardiac Arrest

Cardiac arrest is confirmed by absence of a pulse. Immediate actions include EMS activation, CPR, and AED (automated external defibrillator) deployment. Deep sedation, general anesthesia, and treatment of medically compromised patients will increase the likelihood of this emergency (see Figure 8.5).

## Hypotension

Hypotension during sedation is defined as 30 mm Hg below systolic baseline. It is prevented by slow titration of fentanyl and sedatives. Treatment includes the Trendelenburg position and the rapid administration of 500 ml of IV solution. Atropine is the drug of choice for hypotension accompanied by bradycardia (pulse rate less than 60 bpm). Ephedrine is recommended when the heart rate is normal (see Figure 8.6).

## Hypertension

A hypertensive crisis is often described as diastolic blood pressure greater than 120 mm Hg. The most common cause is pain and anxiety. A “time out” is often all that is needed to restore normal blood pressure. In some cases, additional local anesthetic will correct the problem. Hypertension is considered an emergency when it is accompanied by signs or symptoms. Headache, chest pain, and visual disturbances are all indications of a hypertensive emergency. Treatment includes the administration of nitroglycerin and activation of EMS (see Figure 8.7).

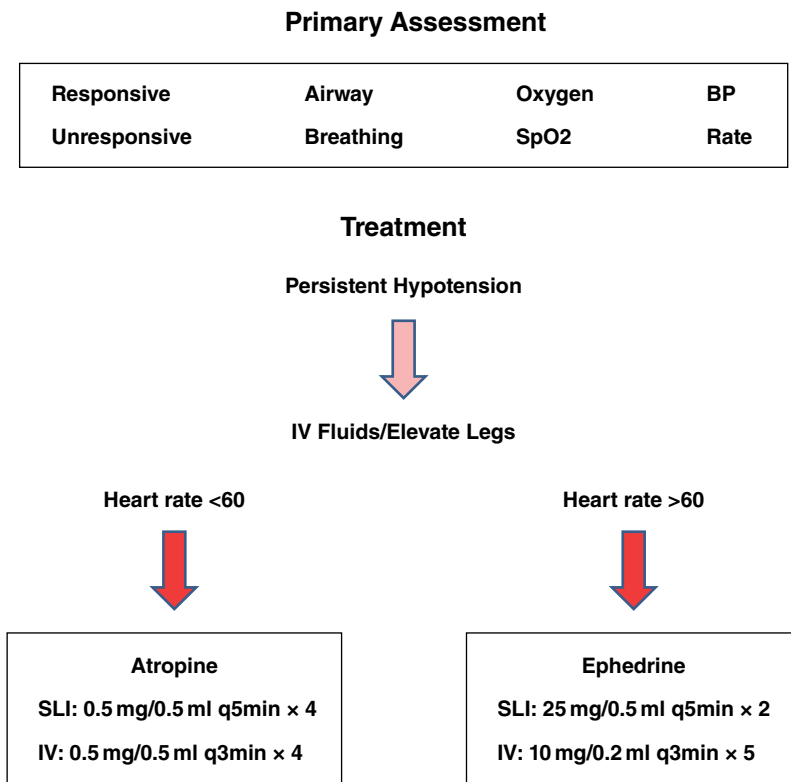


Figure 8.6 Hypotension algorithm.

### Primary Assessment

<b>Responsive</b>	<b>Airway</b>	<b>Oxygen</b>	<b>BP</b>
<b>Unresponsive</b>	<b>Breathing</b>	<b>SpO2</b>	<b>Rate</b>

### Treatment

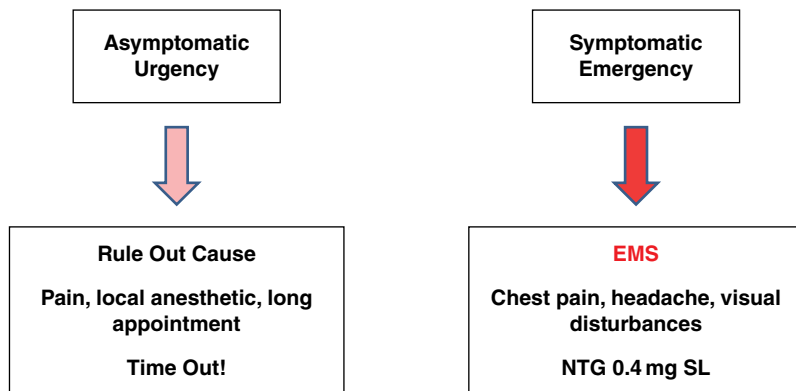


Figure 8.7 Hypertension algorithm.

### Seizure

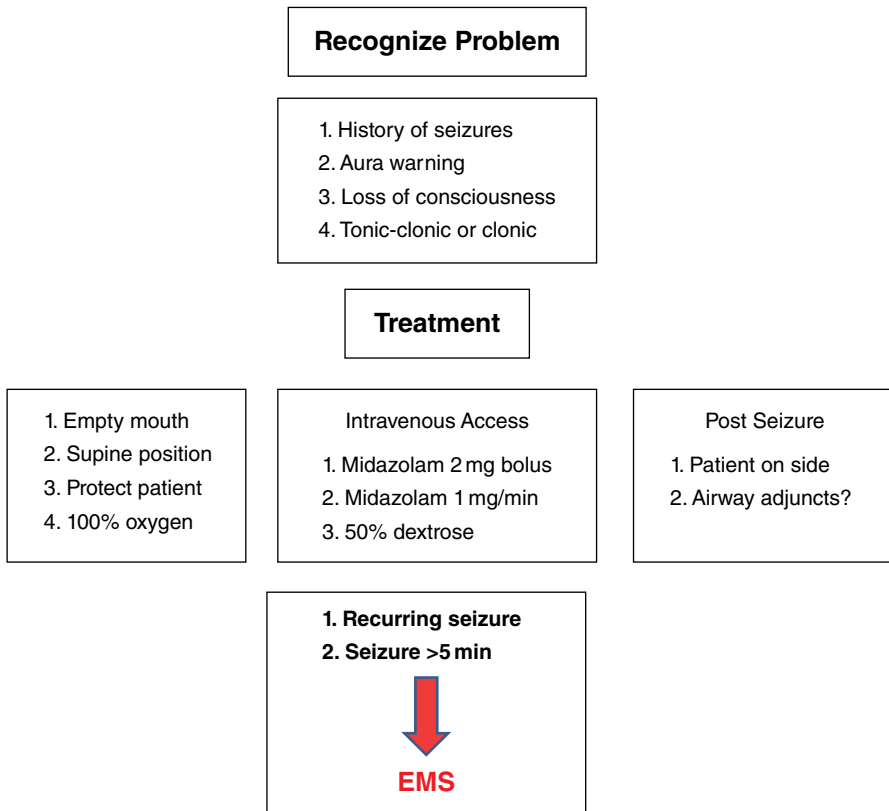
The patient will usually present with a history of seizures. A seizure is usually preceded by an aura. The aura is unique to each individual. Examples of auras include unusual odors, headaches, and changes in vision. The aura can serve as a warning of an impending seizure, allowing time to prepare the patient. The patient should be on 100% oxygen in a supine position, and objects should be removed from the mouth.

Seizure patients lose consciousness and are unaware of their surroundings during the seizure. They should be gently protected from injuring themselves. A seizure can be tonic or tonic-clonic. During a tonic seizure the patient's body assumes a ridged, arched position. Tonic-clonic seizures involve flexion and extension of the arms and legs.

Seizures are very unusual in the patient sedated with midazolam since this drug is used to treat seizures. Fifty percent dextrose should be administered if an IV line is available. Airway adjuncts may be useful to help breathing during recovery after the seizure. The patient should be turned on their right side to prevent aspiration of vomitus postseizure. Recurring seizures or seizures lasting longer than 5 minutes require EMS (see Figure 8.8).

### Hypoglycemia

Hypoglycemia is defined as blood glucose levels below 60 mg/dl. Signs and symptoms include diaphoresis, confusion, convulsions, and loss of consciousness. Prevention includes a thorough medical history, short appointments, and early morning appointments. Blood glucose should be checked before appointments. Dextrose 5% IV fluid is recommended for diabetic patients in lieu of normal saline when IV sedation is planned.



**Figure 8.8** Seizure algorithm.

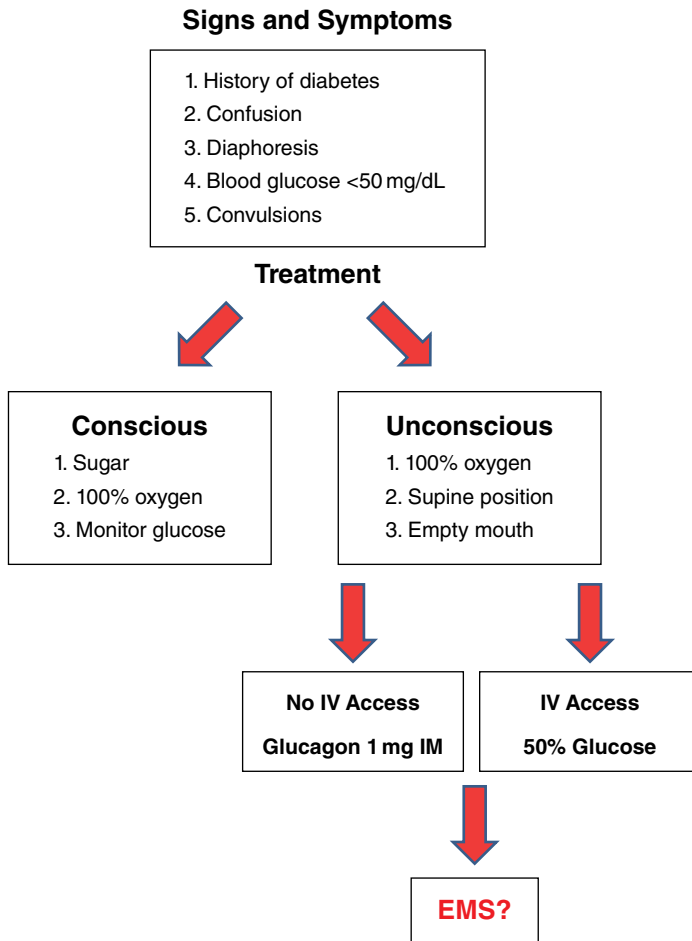
All patients with symptoms should receive 100% oxygen. Conscious patients should be given sugary food such as cake frosting. Unconscious patients should be given glucagon IM or 50% glucose IV. EMS should be activated if blood glucose level does not improve (see Figure 8.9).

### Syncope

Syncope is the most common medical complication in dentistry. It is triggered by fear or pain. Vasovagal reactions decrease oxygen/glucose to the brain, causing loss of consciousness. A brief convulsive period is possible. Patients may appear pale and exhibit diaphoresis. They may feel cold or dizzy. Treatment includes emptying the patient's mouth, triple airway maneuver, and assessment. More serious complications should be suspected if this emergency does not resolve quickly (see Figure 8.10).

### Monitors

The most reliable monitor of patients who are moderately sedated is verbal communication. Patients who are aware of their surroundings and can respond to verbal commands are able to maintain their airway. Other monitors include the pulse oximeter, precordial stethoscope, capnometer, and electrocardiogram.



**Figure 8.9** Hypoglycemia algorithm.

### Pulse Oximeter

Pulse oximetry measures the saturation of oxygen in blood. It monitors a patient's peripheral oxygen saturation ( $SpO_2$ ). A fingertip sensor compares red and infrared wavelengths of light passing through the fingertip (see Figure 8.11). The ratio of red to infrared is expressed as a percentage of oxygen in the hemoglobin molecule. Most pulse oximeters consist of a monitor, blood pressure cuff, sensor, and printer (see Figure 8.12). The Edan M3 pulse oximeter has an adjustable audible alarm and measures blood pressure, pulse rate, and mean arterial pressure in addition to oxygen saturation.

Pulse oximetry monitors oxygenation, the process of getting oxygen to blood and tissue. Capnography monitors the mechanical process of breathing, spontaneously or with help. This is important because pulse oximetry may indicate 99% oxygenation even when a patient is not breathing.

The oxyhemoglobin dissociation curve illustrates this concept (see Figure 8.13). The vertical axis is  $SaO_2$ , the amount of hemoglobin saturated with oxygen. The horizontal axis is  $PaO_2$ , the partial pressure of oxygen in the alveolus. The oxyhemoglobin dissociation curve



is important because it shows that oxygen saturation at the sensor is not equal to available oxygen in the lungs.

An  $SpO_2$  of 90 reflects a  $PaO_2$  of  $\sim 60$  mm Hg. An oxygen saturation of 90% indicates that available oxygen is at the “edge of a cliff” and is a warning to aggressively reestablish adequate ventilation. By definition, this is hypoxemia. Saturation that repeatedly drops below 95% requires action such as telling the patient, “Take a slow deep breath,” head tilt/chin lift, or nasal cannula.

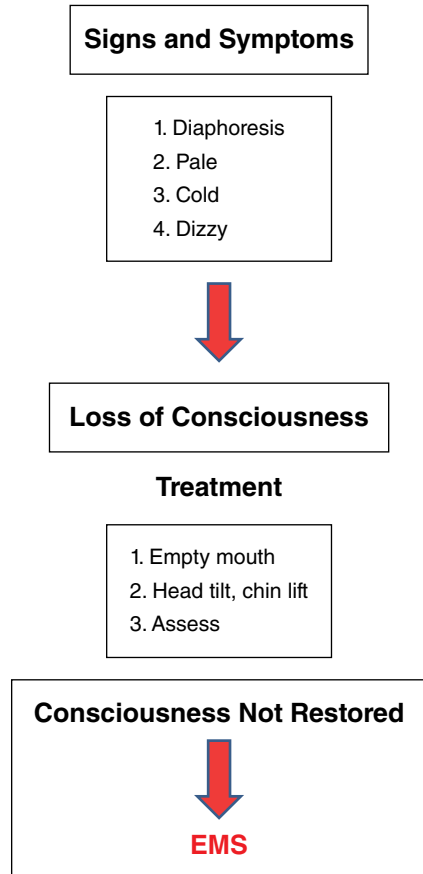
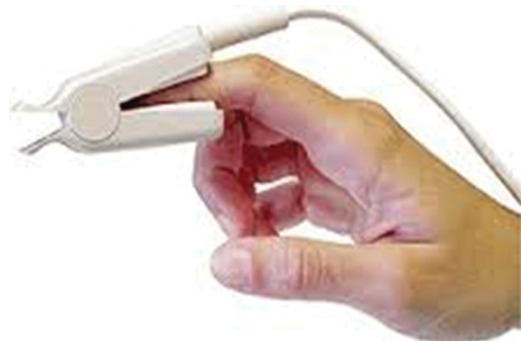### Capnometer

Capnography monitors ventilation and the partial pressure (concentration) of carbon dioxide ( $CO_2$ ) in exhaled air. A capnometer provides a waveform tracing of every breath and measures respiratory rate and end-tidal  $CO_2$  (see Figure 8.14). Infrared technology is used to analyze carbon dioxide in exhaled gas. Exhaled air enters a nasal cannula and passes between a light and a detector plate (see Figure 8.15). More light is absorbed by concentrated  $CO_2$  and less light is transmitted to the detector plate. The amount of light absorbed reflects the partial pressure of  $CO_2$  at the end of exhalation. This is called end-tidal  $CO_2$ , which is normally 35–45 mm Hg.

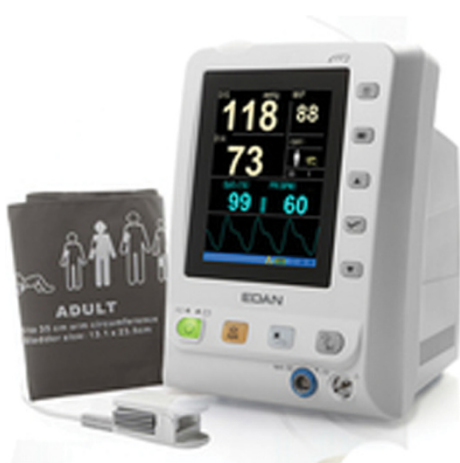Capnography provides three important parameters (see Figure 8.16):

- 1) Waveform tracing for every breath
- 2) Respiratory rate ( $AwRR$ )
- 3) End tidal  $CO_2$  value—normal is 35–45 mm Hg

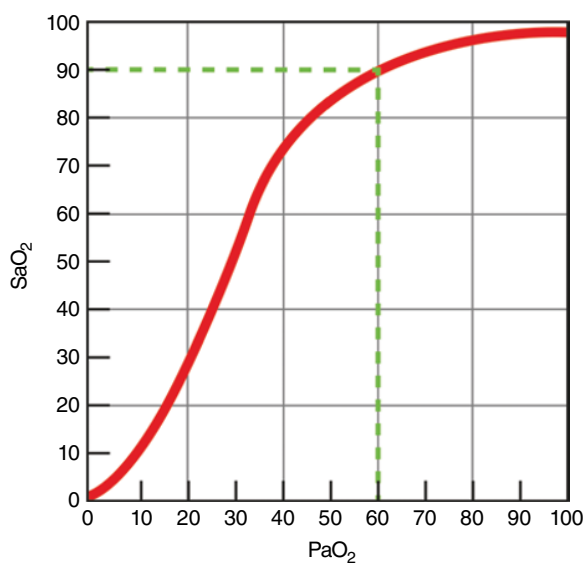
**Figure 8.11** Finger sensor. *Source:* Reproduced by permission of Medaid, Inc.



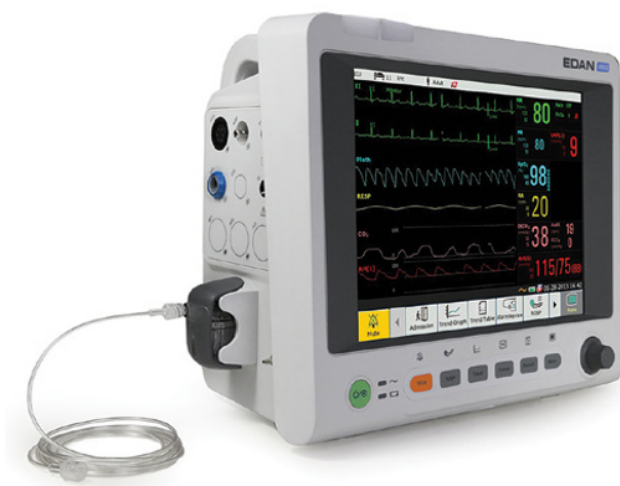**Figure 8.10** Syncope algorithm.



**Figure 8.12** Edan M3 pulse oximeter. Source: Reproduced by permission of Edan Diagnostics, Inc.



**Figure 8.13** The oxygen dissociation curve.



**Figure 8.14** Capnometer. Source: Reproduced by permission of Edan Diagnostics, Inc.

Capnography provides an earlier warning of airway obstruction or apnea when compared to pulse oximetry with supplemental oxygen. At the time of this writing, capnography is not required by most states. However, it is recommended by the American Dental Association and is likely to become the standard of care for moderate sedation.

### Precordial Stethoscope

A precordial stethoscope is an affordable and effective way to monitor ventilation. It consists of a weighted stethoscope bell, rubber tubing, and an earpiece. The weighted pretracheal stethoscope bell, placed over the suprasternal notch, monitors airway patency and ventilation. Double-sided adhesive disks stabilize its position (see Figure 8.17a and 8.17b).

A normal open airway produces a whooshing sound. Gurgling indicates liquid in the airway. Wheezing is the hallmark of bronchospasm. A high-pitched crowing sound can be heard when partial laryngospasm is present. All of these conditions can be detected when using a simple pretracheal stethoscope.

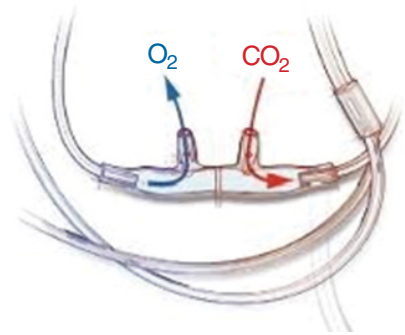


Figure 8.15 CO<sub>2</sub> sampling nasal cannula.

### Electrocardiogram (EKG)

The electrocardiogram is a graphic representation of the cardiac cycle. Each event has a distinctive waveform (see Figure 8.18). The cardiac cycle refers to a complete heartbeat

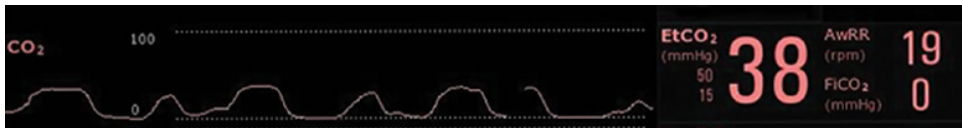
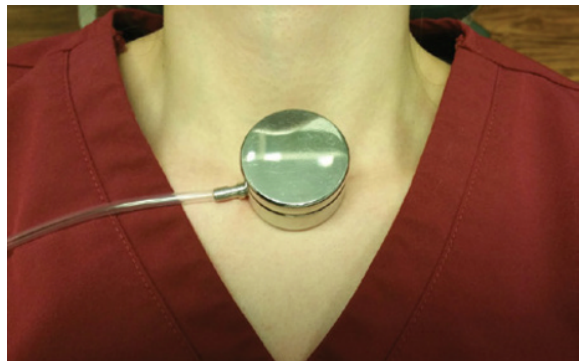
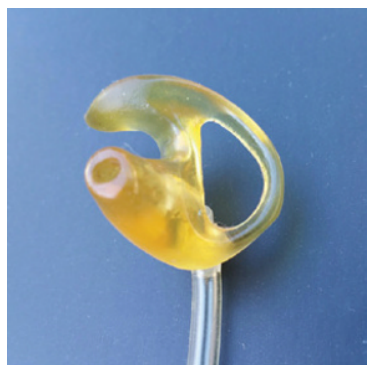Figure 8.16 Capnography parameters. *Source:* Reproduced by permission of Edan Diagnostics, Inc.

Figure 8.17a Pretracheal stethoscope bell.





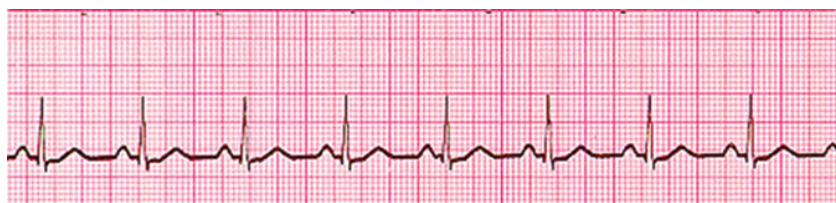**Figure 8.17b** Custom earpiece.

from its generation to the beginning of the next beat. The cardiac cycle is coordinated by a series of electrical impulses that are produced by specialized pacemaker cells found within the (SA) sinoatrial node and the (AV) atrioventricular node of the heart. Conduction of the electrical impulses produces a waveform. EKG is not required by most states for patient monitoring during moderate sedation.

The removal of impacted third molars can be done in relative comfort with moderate sedation. Patient safety is paramount when sedation is used. Monitoring patients during sedation alerts the dentist of impending sedation complications.

Dentists employing sedation must have the training and knowledge to manage sedation emergencies.

The American Dental Society of Anesthesia provides a forum for education, research, and recognition of achievement in order to provide safe and effective patient care for all dentists who have an interest in anesthesiology, sedation, and the control of anxiety and pain. Membership in this organization is recommended for dentists providing sedation when removing impacted third molars.



**Figure 8.18** Normal sinus rhythm.

## References

- 1 Sirin Y, Humphris G, Sencan S, Firat D. What is the most fearful intervention in ambulatory oral surgery? Analysis of an outpatient clinic. *Int J Oral Maxillofac Surg.* 2012 Oct;41(10):1284–90.
- 2 Continuum of depth of sedation: definition of general anesthesia and levels of sedation/analgesia. American Society of Anesthesiologists (ASA); 2004.
- 3 Merin RL. Summary of the California blue ribbon panel report on anesthesia. *J West Soc Periodontol Periodontal Abstr.* 2005;53(2):37–9.
- 4 Dental Board of California. Application for a conscious sedation permit. 2016. Available at [http://www.dbc.ca.gov/licensees/dds/permits\\_cs.shtml](http://www.dbc.ca.gov/licensees/dds/permits_cs.shtml).
- 5 Becker DE, Haas DA. Recognition and management of complications during moderate and deep sedation: part 1. Respiratory considerations. *Anesth Prog.* 2011 Summer;58(2):82–92.
- 6 Grimaldi F. Course director, ACLS Certification Course. San Francisco, CA; 2016 Oct.
- 7 Becker DE. Drug allergies and implications for dental practice. *Anesth Prog.* 2013 Winter;60(4):188–197.

## 9

### Documentation

A dentist in the United States is sued, on average, once in his or her career (more or less depending on location and scope of practice).<sup>1</sup> In other words, a dentist whose scope of practice includes high-risk procedures such as reconstruction, cosmetic dentistry, implants, or the removal of impacted third molars will, on average, be sued more than once in his or her career (see Figure 9.1).

The dental record, also referred to as the patient's chart, is the official legal document that records all of the treatment done and all patient-related communications that occur in the dental office. State and federal laws and regulations determine how it is handled, how long it is kept, and who may have access to the information. The dental record provides for continuity of care for the patient and is critical in the event of a malpractice insurance claim.<sup>2</sup> Incomplete documentation leaves dentists vulnerable to liability.

### Informed Consent

Dr. Crystal Baxter, DMD, MDS, evaluated 242 medical legal cases for dental negligence. The majority of the 242 cases were filed against general dentists, and of these cases, most were filed in the disciplines of oral surgery (extractions) and endodontics. In the oral surgery category, all general dentists who were alleged negligent were sued due to extraction complications. The majority of alleged cases also lacked proper informed consent and referral protocol.<sup>3</sup> Informed consent and complete progress notes are vital documents when litigation is an issue. This is especially true when sedation is used for the removal of impacted third molars.

State laws and court decisions determine the criteria for informed consent.<sup>4</sup> In 1914, a New York state court ruled that "every human being of adult years and sound mind has a right to determine what shall be done with his own body..."<sup>5</sup> Another ruling from the Supreme Court of North Dakota found that laws pertaining to a physician's duty to obtain informed consent also pertained to dentists.<sup>6</sup> Although most cases have involved other health professionals, dentists should follow the rulings established by these cases.

Informed consent is not well understood by most dentists. Consent is a process, not just a form. It is a process that includes a written document and a discussion with the patient that include the risks, benefits, and alternatives of third molar removal. The informed consent conversation should be completed by the doctor performing the



**Figure 9.1** Malpractice trial judge.

procedure. Overly broad statements such as “any and all treatment deemed necessary” or “all treatment which the doctor in his/her best medical judgment deems necessary, including but not limited to” should be avoided. Courts have determined generalized statements to be so broad and unspecific that they do not satisfy the duty of informed consent. The dentist should also avoid downplaying the risks involved with impacted third molar surgery. The discussion should be completed at a consultation appointment, not on the day of surgery.<sup>7</sup> Booklets or videos may be helpful to the patient in understanding the procedure. Time should be provided for the patient to review the consent in the privacy of their home. Otherwise, in court, the plaintiff’s attorney will argue that their client did not have time to make a correct decision. The plaintiff will claim they were “coerced” into treatment.

Informed consent is governed by the statutes and case laws of individual states; dentists should review the applicable laws and regulations of their state.<sup>8</sup> Risks of nerve injury, broken teeth, displacement of teeth or roots, infection, TMJ injury, and infection are examples of risks when removing third molars. See Figures 9.2 and 9.3 for examples of impacted third molar and IV sedation consent forms.

A recurrent theme throughout this book is the recommendation for the early removal of third molars. The ideal time for removal, to decrease surgical complications, is when third molar roots are  $\frac{1}{2}$ – $\frac{3}{4}$  formed.<sup>9</sup> Many of these patients are teenagers under the age of 18. In most states, this means the informed consent discussion should be given to a parent or guardian.

Dentists should be aware that the adult accompanying the patient may not be a legal guardian allowed by law to consent to medical procedures. Examples of such an adult include a grandparent, step-parent, noncustodial parent in instances of divorce, babysitter, or friend of the family.<sup>10</sup>

## Third Molar Impaction Consent

**WHAT IS AN IMPACTED TOOTH?**

An impacted tooth is a tooth that has not erupted normally. It may be covered by bone as well as gum tissue. Impacted teeth that press against other teeth may cause damage to those teeth. They may also cause crowding, infections, swelling, pain, cysts, earaches, headaches, generalized head and neck pain, and even tumors. Surgical removal of impacted and erupted third molars can correct and prevent future problems. However, as is the case with all surgical procedures, the removal of third molars involves risk. The benefit of removing third molars must be weighed against the risk.

**WHAT IS A SURGICAL EXTRACTION?**

Since impacted teeth are partially or completely beneath the surface of the gum tissue or bone, their removal is a surgical procedure. A surgical extraction requires the removal of bone, soft tissue incisions, or sectioning of teeth. Pain medication and instructions will control post-operative pain, swelling, bleeding, and discomfort.

**DISCOMFORT, SWELLING, LIMITED OPENING, AND BLEEDING ARE NORMAL FOLLOWING SURGICAL EXTRACTIONS.**

Slight bleeding may continue until the morning following surgery. The corners of the mouth may be irritated. Curved and thin root tips can fracture during extraction. They are usually removed, but may be left in place if they are near vital structures. Post-operative infections occasionally occur and are treated with antibiotics. Because of the close proximity of impacted teeth to adjacent teeth, occasionally a tooth or dental restoration may be damaged. **VERY RARELY**, post-operative complications include sinus opening, displacement of a tooth into the sinus or infra temporal fossa, lip or tongue numbness which can be temporary or permanent, damage to other oral structures, severe infections, jaw joint problems and broken jaws. In extremely rare circumstances even death may occur. A CT scan radiograph (xray) may be recommended when a wisdom tooth is near a nerve.

We will do our very best to make this a comfortable experience. If you have any questions please ask for clarification.

I UNDERSTAND THAT DR. JANE DOE IS NOT AN ORAL SURGEON. I HAVE READ AND UNDERSTAND THE ABOVE ENTIRELY AND HEREBY CONSENT TO THE PERFORMANCE OF SURGERY AS PRESENTED TO ME.

Patient's or Guardian's Signature \_\_\_\_\_ Date \_\_\_\_\_

Witness Signature \_\_\_\_\_ Date \_\_\_\_\_

Doctor's Signature \_\_\_\_\_ Date \_\_\_\_\_

Figure 9.2 Third molar impaction consent form.

Another option for obtaining authorization for treatment is a telephone conversation with the parent. The parent should be told there are two people on the telephone and asked to verify the patient's name, date of birth, and address and to confirm he or she has responsibility for the patient.<sup>11</sup> Informed consent via phone should include all elements of a valid informed consent. The conversation must be documented in the patient's chart. Consent forms are signed by the treating dentist and witnessed by the staff member who participated in the phone discussion.

**INTRAVENOUS SEDATION CONSENT**

**WHAT IS IV SEDATION?**

Intravenous sedation is a form of anesthesia. Anesthesia can create light, moderate, or deep sleep. IV sedation, administered properly, creates a light sleep. Patients are conscious, but have decreased awareness of their surroundings. Patients have little or no memory of the procedure because of the amnesia produced by the sedative agents. Intravenous sedation is not general anesthesia which creates a deep sleep and an unconscious state.

Oral sedation may be used prior to injection of small amounts of medications into a vein in the arm. Sedative agents are not completely eliminated from the body for several hours afterwards. Therefore, patients who have intravenous sedation need an escort home.

The risks and complications associated with any sedation include nausea, vomiting, allergic reaction, pain, inflammation and/or infection at the intravenous site. In extremely rare circumstances even death may occur.

**MEDICAL HISTORY:** Any personal illness, weakness, or allergy must be reported. Also, details of any drugs being taken – especially sleeping drugs, tranquilizers, or cortisone medications, must be reported to us. This includes over the counter drugs, street drugs, or prescription drugs.

**PREPARATIONS:** No food or drink within six (6) hours of the appointment time and the previous meal should be light and easily digestible. A small amount of water may be used to take any medications prescribed for your appointment. Loose clothing should be worn and sleeves should be easily drawn up past the elbow. Also, comfortable flat-heeled shoes that are easy to walk in should be worn. Dentures, glasses, and/or contact lenses should be removed prior to the appointment.

**FOLLOWING SEDATION:** A responsible adult (friend or family member) must accompany the patient home.

**NO WARRANTY OR GUARRANTEE:** No warranty or guarantee is implied or given regarding the success of sedation.

**ANY PATIENT ACCEPTING A SEDATION APPOINTMENT MUST SPECIFICALLY AGREE TO THE FOLLOWING:**

- NOT to drive a vehicle or operate any machinery after sedation for the rest of the day
- NOT to undertake any responsible business matters
- NOT to drink alcohol for 24 hours after sedation

I HAVE READ AND UNDERSTAND THE ABOVE ENTIRELY AND HEREBY CONSENT TO THE PERFORMANCE OF SEDATION AS PRESENTED TO ME.

_____	_____
Patient's or Guardian's Signature	Date
_____	_____
Witness Signature	Date
_____	_____
Doctor's Signature	Date

Figure 9.3 Intravenous sedation consent form.



Informed refusal occurs when the patient/parent refuses the proposed and alternative treatments. It is recommended by the ADA that informed refusal be documented in the chart and that the dentist inform the patient/parent about the consequences of not accepting the proposed treatment. The dentist should attempt to obtain an informed refusal signed by the parent for retention in the patient record. An informed refusal, however, does not release the dentist from the responsibility of providing a standard of care. If the dentist believes the informed refusal violates proper standards of care, he or she should recommend the patient seek another opinion and/or dismiss the patient from the practice.<sup>12</sup>

## Progress Notes

Progress notes record clinical details of each patient visit. Progress notes document patient treatment and provide written communication between health care professionals. They are legal documents that protect the interests of both patient and dentist. Adequate documentation of patient treatment is also essential information for billing and reimbursement from third-party insurance carriers.

The biggest challenge for adequate documentation is consistent and thorough progress notes. Every dentist has experienced stressful days when things do not go as planned. A staff member calls in sick, three patients are late for their appointment, the compressor stops functioning, and two patients arrive for emergency treatment. Stress and multitasking are not conducive to detailed and complete progress notes. One solution to this problem is SOAP progress notes.

Dr. Lawrence Weed, MD, introduced the concept of SOAP progress notes in an article published in 1964.<sup>13</sup> SOAP notes begin with the patient's chief complaint and history followed by objective data (tests, observations, radiographs, etc.), assessment, and plan. The SOAP note is an acronym for subjective, objective, assessment, and plan or procedure (see Box 9.1). The SOAP format virtually guarantees comprehensive notes.

Digitized progress notes are often included in dental office management software. Custom progress note templates can be created for different procedures. An impacted third molar template is shown in Box 9.2.

Abbreviations are useful to document repetitive procedures when notes are handwritten. The removal of impacted third molars is a repetitive and predictable procedure. The abbreviated notes shown in Box 9.3 are as valid as the notes in Box 9.2. Abbreviations are acceptable legal documentation when standardized and used by all staff. Excessive use of abbreviations should be avoided. This can make the dentist appear rushed and impersonal, which would not bode well in the defense of a malpractice suit.

### Box 9.1 SOAP progress notes.

- S: Subjective is the patient's chief complaint
- O: Objective is what the clinician sees or elicits with tests
- A: Assessment is the diagnosis
- P: Procedure is treatment rendered or planned

**Box 9.2 SOAP impacted third molar notes example.**

S: Pain lower left and lower right  
 O: Roots 1/2–3/4 developed, good access, 17 and 32 mesioangular  
 A: Impactions, pericoronitis  
 P: Informed consent for mother and patient, risks, alternatives, and benefits discussed, see IV record, 1, 16, 17, 32 flap, remove buccal, occlusal, and distal bone, 1 and 16 elevator delivery, 17 and 32 section, elevator delivery, bone file, irrigate, one 3.0 polyglycolic acid suture used distal #17 and #32, postoperative instructions written and oral for mother and patient, no complications

**Box 9.3 SOAP impacted third molar notes example, abbreviated.**

S: Pain LL and LR  
 O: Roots 1/2–3/4, good access, 17 and 32 MA  
 A: Impactions, pericoronitis  
 P: ICMP, RAB, CIVR, 1, 16, 17, 32 flap, RBODB, 1/16 ED, 17/32 section, ED, BF, I, 1x3.0 PGA, PO/WO/MP, n/c

A key for frequently used abbreviations should be included in the patient's chart and posted in an office manual.

## Malpractice Cases

Dental malpractice lawsuits contain four essential elements: duty, breach of duty, proximate cause, and damage. A dentist may successfully defend a suit by proving no duty existed, no breach of duty occurred, that the dentist's conduct was not the cause of damage, or that no damage exists.<sup>14</sup>

A professional duty is created when a professional relationship is established between a patient and dentist. It is the dentist's duty to provide care for the patient. A breach of duty occurs when the dentist's care is not similar to how other dentists would have acted under similar circumstances. This is often referred to as "standard of care." Dentists are judged by a national standard of care. This standard, when removing impacted third molars, is usually the care given by an oral surgeon. The plaintiff's attorney must show that damage or injury occurred to the plaintiff. They must prove that the dentist's actions caused the patient's injury and that the patient's injury was foreseeable and not extraordinary.

The Dentist's Advantage insurance company has provided medical malpractice coverage for dentists for more than 50 years. They are endorsed by the American Academy of General Dentistry. The Dentists Advantage published dental malpractice case studies occurring from 2012 to 2015. Seven cases involving the removal of third molars are presented here.<sup>15</sup>

### **1. June 2012—Jaw Fractured during Wisdom Tooth Extraction—Additional Surgery Required and Woman Claims Fibromyalgia from Trauma—Defense Verdict**

The plaintiff, age twenty-nine, went to a dental office in August 2007 for oral surgery which was performed by the defendant dentist. The plaintiff was to have three impacted wisdom teeth pulled. The plaintiff claimed that she had requested that the defendant dentist not perform the procedure, but he did.

The plaintiff claimed that the defendant dentist failed to section an impacted wisdom tooth in her lower jaw before pulling it, resulting in greater removal of bone from her jaw than necessary, which led to a fractured jaw. The plaintiff also claimed that it was ten days before she was referred to an oral surgeon. The plaintiff underwent open reduction and internal fixation of the left jaw and later underwent removal of an infected bone plate.

The plaintiff claimed that she developed fibromyalgia due to the trauma from the extraction. The plaintiff alleged battery, lack of informed consent, and negligence in the performance of the extraction.

The defendant claimed that proper consent was obtained and that jaw fracture was a risk of the procedure which was included in the consent form. The defendant claimed that the extraction was performed without complications and that the bone was thin on the left side of her jaw and that she was informed that she should avoid putting pressure on that side of her face.

The defendant also claimed that the plaintiff was given instructions to call or return to the office if she had any change in her condition. The defendant claimed that the plaintiff's follow-up visit, six days later, included complaints of swelling and tenderness on the left side of her face and she returned the next day for an X-ray, which revealed a mandible fracture.

The defendant dentist claimed that the plaintiff was informed of this and indicated that she was feeling better and had little pain and swelling. The plaintiff was told to return in three days, at which time there was good improvement. The defendant then referred the plaintiff to an oral and maxillofacial surgeon and gave her a list of surgeons and a letter detailing his treatment.

According to a published account a defense verdict was returned.

### **2. August 2012—Lingual Nerve Damage from Wisdom Tooth Extraction—Microsurgical Repair, but Some Numbness Continues—\$187,500 Settlement**

The plaintiff, age twenty-nine, had a wisdom tooth extracted from his lower jaw in January 2009 by the dentist. The plaintiff suffered numbness to the anterior two-thirds of the right half of his tongue, the floor of the mouth on the right side and the lingual gingiva of the lower right side after the procedure.

He underwent a microsurgical repair to the lingual nerve in April 2009. The repair surgery returned fifty percent of sensation to the affected part of the tongue. The plaintiff claimed that the defendant dentist severed the right lingual nerve during the extraction, perforating through the lower right lingual plate of bone and into the soft gum tissue where the right lingual nerve is located.

Photographs and a visit to an oral surgeon who finished the extraction confirmed that there was damage to the soft gum tissue.

The defendant dentist denied any negligence. According to a published account a \$187,500 settlement was reached in mediation.

### **3. Drill Bit Breaks during Wisdom Tooth Extraction and Is Retained in Jaw—Attempt to Extract Drill Bit Tip Causes Nerve Injury—\$2.69 Million Verdict Reduced to \$300,000 Under High/Low Agreement**

The plaintiff, age thirty-seven, went to the defendant dentist for treatment of mouth pain. The defendant dentist diagnosed an impacted wisdom tooth and recommended extraction. The plaintiff was referred to a contractor for the procedure. The contractor, an oral surgery resident, performed the extraction in November 2007. During the procedure the burr tip of the drill fractured in the plaintiff's mouth and was retained in her jaw.

The plaintiff returned to the defendant dentist with complaints of oral pain and was referred back to the oral surgery resident. An X-ray revealed the drill bit. An attempt was made to remove the drill bit a week after the extraction, but the bit was actually pushed into the inferior alveolar nerve canal, resulting in a nerve injury.

The plaintiff claimed permanent numbness, hypersensitivity and pain in her left, lower lip and chin. The plaintiff alleged lack of informed consent regarding the referral to an oral surgery resident, rather than an oral surgeon. The plaintiff claimed that she would have declined the extraction if she had known she was being referred to a resident.

The defendant claimed that nerve damage was listed as a possible complication of wisdom tooth extraction on the informed consent document. The defendant dentist also maintained that there was no requirement on him to inform the plaintiff that the contractor was a resident.

According to a published account a \$2,690,000 verdict was returned, which was reduced to \$300,000 under a high/low agreement.

### **4. Extraction of Wisdom Teeth Alleged to Sever Lingual Nerve—Numbness and Loss of Taste—Defendant Claims Nerve Not Damaged and Nerve Injury Was a Known Risk—\$25,000 Verdict**

The plaintiff, age fourteen, underwent extraction of wisdom teeth in 2005. The procedure was performed by the defendant dentist. The plaintiff claimed that a high-speed drill severed her lingual nerve, leading to residual numbness of the left side of her mouth and tongue. The plaintiff particularly claimed a loss of her sense of taste. The plaintiff underwent surgery for the lingual nerve, but her condition continued. The plaintiff alleged negligence in the performance of the extractions.

The defendant claimed that images of the lingual nerve did not show any damage to the nerve and that the plaintiff's post-extraction symptoms quickly improved, which would not have occurred if there was a significant injury of the lingual nerve. The defendant additionally claimed that the plaintiff and her parents were informed of the possibility of an injury to the lingual nerve.

The defendant also claimed that the plaintiff's surgery had restored most of her sense of taste and sensation and that the injury did not affect the right side of the tongue.

According to a published account a \$25,000 verdict was returned.

### **5. Man Dies Following Wisdom Tooth Extraction—Necrotizing Mediastinitis, Septic Shock, Ludwig's Angina—\$2.6 Million Net Verdict**

The plaintiff's decedent went to the defendant dental practice in March 2011 for routine dental work. The decedent returned in April for extraction of tooth number 32 (wisdom tooth), which was performed by the defendant dentist. The plaintiff suffered severe pain in the extraction area on the right side of his face, with swelling and difficulty swallowing. The decedent contacted the defendant dental practice two days after the extraction and was told to call again if his symptoms did not subside in four or five days. The decedent began vomiting and having difficulty breathing, and was transported by ambulance to a hospital five days later. Antibiotics were administered and drainage of the neck was performed. The man had developed necrotizing mediastinitis and septic shock, then Ludwig's angina from the dental abscess. The man died at the age of forty-two four days later.

The plaintiff alleged lack of informed consent regarding use of antibiotics to prevent infection, and a failure to provide proper advice in the telephone call after the procedure. The defendants denied any negligence and maintained that the decedent was given instructions verbally and in writing to contact the office or go to an emergency department if he had severe or unexpected complications. The defendant dentist claimed that she was not contacted and was not aware of the decedent's condition and that she did not give any employee of the defendant dental practice any advice or instructions for the decedent.

According to the trial reports, a jury returned \$985,000 in damages for the surviving spouse and \$2,485,000 in damages to the decedent's minor son. The decedent was found twenty-five percent at fault, the defendant dentist fifty percent at fault, and the defendant dental practice twenty-five percent at fault. The net verdict was \$2,602,500.

### **6. Lingual Nerve Injury during Wisdom Tooth Extraction—\$875,000 Settlement**

The plaintiff, age twenty-eight, went to the office of the defendant dentist in 2005 for the removal of the lower left wisdom tooth. During the procedure the plaintiff's lingual nerve was severed. The plaintiff was referred to an oral surgeon to repair the nerve damage. Despite multiple subsequent surgeries, the plaintiff's injury was irreparable, resulting in severe and chronic pain. The plaintiff claimed negligence by the defendant dentist in using a surgical technique which was unnecessarily invasive and also claimed that the method used for the extraction was not appropriate.

The plaintiff argued that the technique used by the defendant dentist was not taught by any dental school. The defendant dentist claimed that the technique he

used was proper and had been taught to him by the head of a college oral surgery department. The defendant dentist also claimed that the nerve injury was from the use of an elevator to extract the tooth, which was a common practice.

The plaintiff was able to present the person referenced by the defendant dentist as having taught him his technique (whom the defendant dentist had claimed was deceased). This individual testified that neither he nor any other instructor at the college would have taught such a surgical technique.

The matter was initially tried to a defense verdict, which was set aside on appeal and remanded for a new trial. Prior to retrial, the parties entered a high/low agreement of \$875,000/\$195,000. The matter was subsequently settled for \$875,000 four hours after the jury announced having reached a verdict on liability, but needed more time to deliberate the issue of damages.

## 7. Trigeminal Nerve Injury from Wisdom Tooth Extraction—\$1,000,000 Settlement

The plaintiff, age thirty-three, went to the defendant dentist for evaluation. At the plaintiff's next visit to the defendant, three of the plaintiff's wisdom teeth were extracted. The procedure took six hours.

The plaintiff claimed that she suffered injury to the trigeminal nerve, causing permanent trigeminal neuropathic pain. The plaintiff claimed that the defendant dentist failed to appreciate the significance of the bony involvement of her third molars and the proximity of the third molars to the inferior alveolar canal. The plaintiff argued that a specialist in complex third molar removal should have been consulted. The plaintiff also claimed that she was not informed of the complexity of the third molar extraction and the risk of nerve injury.

The defendant dentist argued that the nerve injury was a known risk of the extraction and denied any negligence. According to reports, a \$1 million policy-limits settlement was reached.

### Malpractice Case Summary

The seven cases cited represent The Dentist Advantage third molar suits published between 2012 and 2015. Each case illustrates the need for documentation.

Patient #1 claimed that she had requested that the defendant dentist not perform the procedure. However, **informed consent was completed** by the defendant dentist. The court ruled in favor of the defendant.

Patient #2 proved that damage was done to the right lingual plate and soft tissue (oral surgeon photos). The injured tissue was outside the surgical field. In this case, negligence was proven and **informed consent became irrelevant**. The court ruled in favor of the plaintiff.

Patient #3 alleged **lack of informed consent** regarding the referral to an oral surgery resident. The defendant dentist argued that there was no requirement for him to inform the plaintiff that the contractor was a resident. This case highlights the need for a thorough discussion with patients. The fact that the contractor dentist was not an oral surgeon was not discussed or documented. The court ruled in favor of the plaintiff.

Patient #4 alleged negligence in the removal of her lower left third molar. Subsequent images of the lingual nerve did not show damage. The plaintiff failed to prove negligence. **Informed consent stated** that lingual nerve injury was a possible surgical complication. A minimal award of \$25,000 was given to the plaintiff.

Patient #5's descendent claimed that the patient contacted the defendant dental practice two days after the removal of #32. The defendant dentist instructed the patient to call back if symptoms did not improve. The defendant dentist argued that she was not aware of a phone call or the patient's condition. **The plaintiff alleged lack of informed consent regarding use of antibiotics to prevent infection.** In this case, the plaintiff's attorney likely argued that the dentist's conduct contributed to the plaintiff's injury. Antibiotics may be indicated for difficult extractions or medically compromised patients. Although not required, the dentist did not make a postoperative phone call to follow up. The author recommends a postoperative phone call within 24 hours following the removal of impacted third molars. The phone call should be documented in progress notes. Verdict ruled in favor of the plaintiff.

Patient #6 claimed negligence due to a lower left severed lingual nerve. This injury was verified with a CT scan. In this case the defendant's character was questionable due to his statement that he was taught the surgical technique by an instructor in dental school. This was found to be untrue. The defendant's **duplicitous character** may have led the jury to believe the dentist's conduct caused the injury. The verdict was ruled for the plaintiff.

Patient #7 claimed that she was **not properly informed** of the complexity involved with the removal of her wisdom teeth. The amount of time required to remove three third molars calls into question the dentist's competence. The procedure was not completed within the standard of care. The case was settled for \$1,000,000.

## Summary

Informed consent and progress note documentation will not help if negligence is proven. Dentists removing impacted third molars should practice within the scope of their training and experience to avoid the appearance of negligence. Age appears to have been a significant factor in most of the Dentist Advantage cases. Only one patient was younger than 28 years old. Surgical complications increase with patient age.

The importance of the patient's relationship with the dentist, office, and staff cannot be overstated. The following quote from Wilhemina Leeuw, MS, CDA, illuminates the importance of this relationship.

“Cases have been reported in which patients decided not to file a claim against the dentist simply because they liked a staff member or felt that the dental team was polite. Patients do not expect their dentists to be perfect, but they do expect them to show compassion and honesty rather than indifference. Most medical and dental malpractice claims arise from an unfavorable interaction with the dentist and not necessarily from a poor treatment outcome.”<sup>16</sup>

Since the 1960s the frequency of medical malpractice claims filed in the United States has increased. Today, malpractice claims are relatively common.<sup>17</sup> Dentists should take

steps to protect themselves from malpractice suits. Documentation, including informed consent and SOAP progress notes, should be an essential part of every dental practice.

## References

- 1 Medical Protective Insurance. Closed claims analysis, 2003–2012.
- 2 Council on Dental Practice Division of Legal Affairs. Dental records. ADA; 2007.
- 3 Baxter C. A review of dental negligence. Dentistry IQ. <http://www.dentistryiq.com/articles/wdj/print/volume-2/issue-8/you-and-your-practice/a-review-of-dental-negligence.html>, accessed 2016 Nov 24.
- 4 Sfakis P. A duty to disclose: Issues to consider in securing informed consent. *J Am Dent Assoc.* 2003;134(10):1329–33.
- 5 *Schloendorffer v Society of New York Hospital* (105N.E. 92); 1914.
- 6 *Koapke v Herfendal*, 660 NW 2d 206 (ND 2003).
- 7 American Dental Association, Division of Legal Affairs. Dental records. Chicago: American Dental Association; 2007:16.
- 8 Council on Clinical Affairs, American Academy of Pediatric Dentistry. Guideline on informed consent. Revised 2009.
- 9 Reznick JB. The wonderful world of oral surgery. Dental Town 2nd annual gathering, Las Vegas, Nevada, 2004 Mar 27.
- 10 Council on Clinical Affairs, American Academy of Pediatric Dentistry, Guideline on informed consent. Revised 2009.
- 11 Watterson DG. Informed consent and informed refusal in dentistry. *Registered Dental Hygienist.* 2012 Sep.
- 12 American Dental Association, Division of Legal Affairs. Dental records. Chicago: American Dental Association; 2007:16.
- 13 Wachter B. Time to tackle an epic problem. *Wachters World*, <http://community.the-hospitalist.org/2012/09/03>.
- 14 Malamed SF. Sedation: a guide to patient management, 5th edition, Mosby; 2010:562.
- 15 Dentist's Advantage. Dentist's Advantage case studies 2012–2015. Available at [dentists-advantage.com](http://dentists-advantage.com).
- 16 Leeuw W. Maintaining proper dental records. Crest® Oral-B® at [dentalcare.com](http://dentalcare.com) Continuing Education Course. Revised 2013 Jul 11.
- 17 Bal BS. An introduction to medical malpractice in the United States. *Clin Orthop Relat Res.* 2009 Feb;467(2):339–47.



## 10

## The Mobile Third Molar Practice

This chapter was written in response to inquiries from dentists regarding my mobile third molar practice. These dentists are looking for an alternative to private practice. The typical private practice dentist wears many hats: CEO, business manager, negotiator, therapist, and politician. Several studies have reported a high prevalence of stress and burnout among dentists.<sup>1-4</sup>

The suicide rate of dentists is more than twice the rate of the general population and almost three times higher than that of other white-collar workers. Emotional illness ranks third in order of frequency of health problems among dentists, while in the general population it ranks tenth.<sup>5</sup>

Dr. Randy Lang sites nine causes of stress and burnout in dentistry.<sup>6</sup> Seven of these stressors are eliminated or reduced in the mobile third molar practice.

- 1) Confinement. “The average dentist spends most of his or her life confined to a small, sometimes windowless, 7ft. by 9ft. operatory, which is smaller than the cells in our penal institutions.” The mobile third molar practice work space changes every day. The office atmosphere, staff, and patient demographics change every day. This promotes an atmosphere of openness and freedom.
- 2) Isolation. “Most dentists practice alone. Consequently, they do not have the opportunity to share and solve problems with their colleagues the way other professional groups do through peer support.” The mobile third molar practice meets with a different colleague every day.
- 3) Stress of perfection. “The relentless pursuit of perfection and permanence in an inhospitable oral environment is a major cause of stress and frustration for dentists.” Restorative dentistry requires a focus on intricate and meticulous detail. The removal of impacted third molars also requires attention to detail but is less intense and prolonged.
- 4) Economic pressure. “Office overhead rises to meet income.” Private practice begins with school and practice loans. Office overhead may increase as income increases. The mobile third molar practice has consistently low overhead: no lab bills, staff, or rent, and minimal supplies.
- 5) Time pressure. “Attempting to stay on schedule in a busy dental practice is a chronic source of stress.” The mobile third molar practice sees one patient at a time in one operatory. The schedule is predictable and flexible.

- 6) Compromised treatment. “Many patients, due to financial restraints, poor insurance plans or low appreciation of quality dental care, will not accept “ideal” treatment plans.” The removal of impacted third molars is an “all or none” treatment. No compromise on ideal treatment is necessary.
- 7) Patient anxiety. “There is now considerable evidence that dentists experience patterns of physiological stress responses (increased heart rate, high blood pressure, sweating, etc.) that parallel the patient’s responses when performing dental procedures that evoke patient fear and anxiety.” Sedation is an integral part of the mobile third molar practice. Patient stress is controlled and there is little or no memory of the procedure.

A modification of lifestyle may be the answer for the practitioner who is burned out in private practice. The reader of this book who enjoys oral surgery and is looking for an alternative to private practice might consider the mobile third molar practice. My mobile practice ended my emotional and physical burnout.

My dental journey and interest in minor oral surgery began at UCSF School of Dentistry in 1977. Most dentists receive minimal oral surgery training in dental school. All challenging procedures are referred to AEGD, GPR, and oral surgery residents. This was especially true when I was in dental school. My oral surgery rotation consisted of forceps removal of mobile erupted teeth.

Oral surgery continuing education courses were virtually nonexistent when I graduated in 1981. Fortunately, Brånemark presented his research on osseointegration in 1982, and many dental implant continuing education courses became available. I began reading oral surgery books and attending implant continuing education courses. Attending implant lectures and live patient hands-on courses increased my surgical skill and confidence. I received my IV sedation training from Dr. Stanley Malamed at USC in 1983.

After associating for 3 years, I opened my first dental office in 1984 in the small San Francisco suburb of Hercules. The town of Hercules had no dentists and a population of about 7900 men, women, and children. My office was surrounded by empty land filled with fields of knee-high weeds. Hercules became a boomtown, and my practice flourished and continued to grow to more than 5000 active patients. I opened a second satellite office in 1989.

By 1999 I was burned out and struggling to practice with a herniated disc in my lower back. I sold both dental practices and took a year off to let my back heal and reflect on my life in dentistry. A year later my back was better and I had a plan to practice without stress and trauma to my back. I would open a boutique, one-operator office in an affluent suburb of San Francisco. I would limit my practice to large-case reconstruction dentistry, work 3 days a week, and treat a handful of patients each day. This plan looked perfect on paper.

However, soon after opening my dream boutique office it became obvious that an occasional big case was not going to pay my bills. It has been said that “necessity is the mother of invention.” I needed to do something. I picked up the phone and called my colleagues to offer my services removing impacted third molars with sedation. The fact that I had my IV sedation permit was a big selling point.

A few months later I was working 1 day a week in my mobile practice removing impacted third molars with IV sedation. My single-day income removing impactions was more than 3 days in my office. I reached a tipping point after a busy day removing impactions. I was driving home with my mobile gear in the back of my SUV. I had a check in my pocket, my back was OK, and I wasn’t stressed out. I sold my “dream” practice in 2005.

I now have independent contractor agreements with 37 offices in the San Francisco Bay Area. I have no office, employees, or insurance issues. My overhead is close to zero and I have unlimited scheduling flexibility. I've lived in Hawaii since 2007. I commute to California for work 10 days a month. My mobile practice has been limited to the removal of impacted third molars for 17 years.

Some of my contracted offices don't even know I live in Hawaii.

## Mobile Practice Benefits

At the time of this writing, the dental industry is evolving at a monumental pace. Dentistry is increasingly competitive with the advent of corporate dentistry and DHMOs.<sup>7</sup> New graduates are facing increasing school debt.<sup>8</sup> Specialists are receiving fewer referrals.<sup>9</sup>

The goal in a competitive market is to stand out, find a niche, or distinguish a practice in some way. One competitive niche is the independent contractor mobile dental practice offering services that the practice owner would normally refer. This alternative practice style benefits both the practice owner and mobile practice contractor.

Benefits to the practice owner:

- 1) Revenue stays in the office. In a competitive dental marketplace, the multispecialty practice makes sense.
- 2) Patients don't want to be referred. They prefer to stay with their trusted general dentist. They don't want to drive to a distant location to meet with a stranger. General dentists often have the following conversation: "Mary, you need a root canal. I'm going to refer you to Dr. X." Invariably, the patient's response is, "Doctor, are you sure you can't do it?"
- 3) Patient referrals increase. Difficult procedures that are not normally provided by the practice are completed in familiar surroundings. This enhances the practice image and increases patient referrals.
- 4) Communication is improved. The mobile dentist and practice owner can meet together with the patient.

Benefits to the contractor:

- 1) Reduced stress
- 2) Overhead close to zero
- 3) No staff or insurance headaches
- 4) Unlimited scheduling flexibility

Once established, the mobile third molar practice has many benefits. Contracted offices provide staff and manage insurance. You control your schedule. Since you don't have a leased office space and staff, you are free to travel and spend time with your family.

There are also many challenges to consider. Building your client base is a major undertaking that can take years. Maintaining the client base requires constant nurturing. You must be willing to load, unload, and transport your surgical equipment and supplies every day. It is highly recommended that you are certified in IV sedation. Patient management issues are more easily controlled and your patients will have little or no

memory of the procedure. You should be ACLS certified and able to handle sedation emergencies. Most important, there is not much point in pursuing this idea unless you can confidently, efficiently, and safely remove impacted third molars.

Can you finish most partial and full bony impaction cases (four impactions) in 30 minutes or less without complications? Can you handle surgical complications when they occur? If you are a general dentist, you will be held to the same standard as an oral surgeon. The efficient, confident, and safe removal of impacted third molars leads to happy patients, parents, and contracted offices.

## General Dentist or Specialist

Can a GP practice to the same standard as an oral surgeon when removing impacted third molars? The maxillofacial surgeon deserves respect. There is no question that the maxillofacial surgeon's training is extensive. A typical maxillofacial dual degree residency could include rotations in anesthesia, plastic surgery, surgical oncology, gastrointestinal surgery, thoracic surgery, cardiothoracic surgery, transplant surgery, trauma surgery, surgical intensive care, dentoalveolar surgery, salivary gland lesions, implants, TMJ surgery, orthognathic surgery, nerve repair, facial trauma, and more. However, exodontia represents a small part of the maxillofacial surgeon's training. A GP focused on extractions could have more exodontia experience than a maxillofacial surgeon who has just completed a residency.

Dr. Gordon Christensen has stated that if a GP "feels competent to accomplish a procedure and can do it to the level of a specialist, do not hesitate to incorporate that procedure into your practice."<sup>10</sup> The American Dental Association Principles of Ethics and Code of Professional Conduct states that "general dentists who wish to announce the services available in their practices are permitted to announce the availability of those services so long as they avoid any communications that express or imply specialization." The ADA advisory opinions, published in January 2009, state that nothing "prohibits a general dentist from truthfully informing the public that the dentist limits services to an area of dentistry not recognized as a specialty by the American Dental Association." Examples of areas of dentistry not recognized as specialties include cosmetic dentistry, temporomandibular disorders, implantology, and exodontia.

A GP with extensive experience and training in exodontia can practice in multiple offices as an independent contractor as long as he or she does not mislead the public regarding specialty status. The general dentist that limits his/her practice to the removal of impacted third molars should have extensive experience and many hours of continuing education in minor oral surgery. Alternatively, they should have completed Advanced Education in General Dentistry or General Practice residencies.

One could argue that the GP is held to a higher standard than the specialist. If a patient has inferior alveolar or lingual nerve paresthesia after a GP removes an impacted mandibular third molar, it may be assumed that the GP is incompetent or negligent. However, if a patient has paresthesia after the same procedure is completed by a maxillofacial surgeon, it may be assumed that it was a difficult procedure.

## Mobile Practice Promotion

Building a viable third mobile practice is not easy, especially for a GP. Routine procedures are usually completed by general dentists. Challenging procedures and difficult patients are referred to specialists. Dentists who want to reduce referrals are usually looking for a contractor or specialist for their office. The GP mobile third molar dentist must convince potential offices that they are as competent removing impacted third molars as the maxillofacial surgeon who has credentials and years of formal training. Potential offices want someone who will enhance their office and increase new patient flow.

The typical office will resist working with a non-oral surgeon. Building this type of practice will take time, even for the oral surgeon. I recommend maintaining your existing practice or employment while building your mobile practice. No one is going to call you to request your services until you have established a good reputation within your community and have built a solid base of referrals. How do you get started?

### Word of Mouth

Start marketing your practice by word of mouth. It doesn't cost anything and can be very effective. Offer your services to every dentist, classmate, and staff member that you know. Consider offering a complimentary day of patient treatment to demonstrate your skills. This is a small concession in exchange for a relationship that could last years.

### Community Service

Community service lets people know you can deliver quality third molar services. It's also a way to meet other dentists who might want to work with you. I have volunteered several times for Dentistry from the Heart (DFTH). DFTH is a worldwide nonprofit organization dedicated to providing free dental care to those in need. Every year, thousands of dentists, hygienists, and staff donate their time and resources at DFTH events. This type of community service represents a golden opportunity to interact with dental teams and showcase your skills and compassion.

Another example of community service is the free dental clinic. Many communities offer free medical and dental to low-income families. These clinics usually welcome volunteers, especially dentists with special skills.

### Dental Meetings

What better venue than dental meetings to meet fellow dentists? Most dentists love to talk about dentistry. Inevitably, the discussion turns to the economics of dentistry or where you practice. Most general dentists refer impacted third molars to specialists. Removal of impacted third molars is one of the most profitable services in dentistry. Take advantage of this opportunity to educate these dentists about your service.

## Business Cards

Dental meetings and community service events are great venues to offer your business card. Never miss an opportunity to introduce yourself with a business card containing your web address (see Box 10.1). A business card portrays more than just a name, phone number, and web address. It can reflect a professional image or lack of it. A poor-quality, dirty, or otherwise unimpressive business card will be quickly forgotten. Make your card stand out by using a professional printing service that offers high-quality paper and a variety of patterns and colors to create visual appeal. Don't forget to include your logo.

## Testimonials

A key part of promoting your service will be testimonials. Patient and dentist testimonials will add credibility to your mobile practice. Begin by collecting testimonials from your own patients. The patient testimonial is a powerful promotional device. Your contracted office testimonials should be added as your mobile practice grows. It's impossible to have too many testimonials. Testimonials can be written or video recorded.

Written testimonials are best used for direct mail to potential dental offices. They should contain the dentist's name and city where their office is located. This is much more meaningful than an anonymous testimonial. Video testimonials from patients work best on your website. Prospective offices need to know that their patients will be treated well.

## Website

In today's business environment, a quality website is mandatory. Your website should communicate professionalism, organization, and precision. Every contact you make should link to your website through your business card. Your website should be both personal and professional. It should contain six elements, shown in Box 10.2.

### Box 10.1 Offer your business card whenever possible.

Jane Doe, DDS – General Dentist  
 "Practice Limited to Impacted Third Molars"  
 www.thirdmolars.com  
 000-123-4567

### Box 10.2 The mobile practice website should reflect professionalism, organization, and precision.

Video greeting and introduction	Dentist-written testimonials
Your mobile practice story	Patient video testimonials
Biography and curriculum vitae	Personal interests – hobbies, family, etc.

## Social Media

Facebook, LinkedIn, Twitter, and other social media are essential marketing tools for the mobile third molar practice. Social media can have a big impact on your mobile practice success with very little cash invested. According to Social Media Examiner's seventh annual *Social Media Marketing Industry Report*, 92% of marketers working with small businesses (between 2 and 10 employees) agree or strongly agree that social media is crucial to success.<sup>11</sup>

Social media posts are like virtual flyers or internet newspaper ads. Facebook groups can be private or public. These groups can help to build a community of like-minded dentists. LinkedIn and Twitter can help you stay in contact with dentists you know and dentists met at meetings or community service events. The return on investment from social media can be impressive.

Making dentists aware of your mobile practice is good. Enticing them to visit your website is even better. Share blog posts, promote your services, and share important news about your mobile practice and third molar knowledge. When you share links on social networks, they should link to a dedicated landing page on your website. Directing dentists to your homepage isn't as effective as sending them to pages containing patient video testimonials or surgical procedures.

## Newsletter

In marketing, top-of-mind awareness (TOMA) refers to a brand or specific product being first in customers' minds when thinking of a particular industry or category.<sup>12</sup> A quarterly newsletter targeting offices in your area can help brand your services. In a survey of nearly 200 senior marketing managers, 50% responded that they found the "top-of-mind" metric very useful.<sup>13</sup> Your newsletter should contain valuable information related to the removal of impacted third molars. Case selection, complications, and surgical techniques are just a few topics available.

## Direct Mail

Direct mail can be a very effective marketing tool. According to *Direct Mail News*, in 2012 the average response rate for direct mail was 4.4% for business-to-business mailing.<sup>14</sup>

The cost per lead of direct mail is in line with print and pay-per-click, and significantly less than telemarketing. Production costs are somewhat more than email, but the response rate is far better. Direct mail contacts, converted to long-term relationships, generate many thousands of dollars in impacted third molar revenue. The value of these relationships must be weighed against the production costs of printing and mailing.

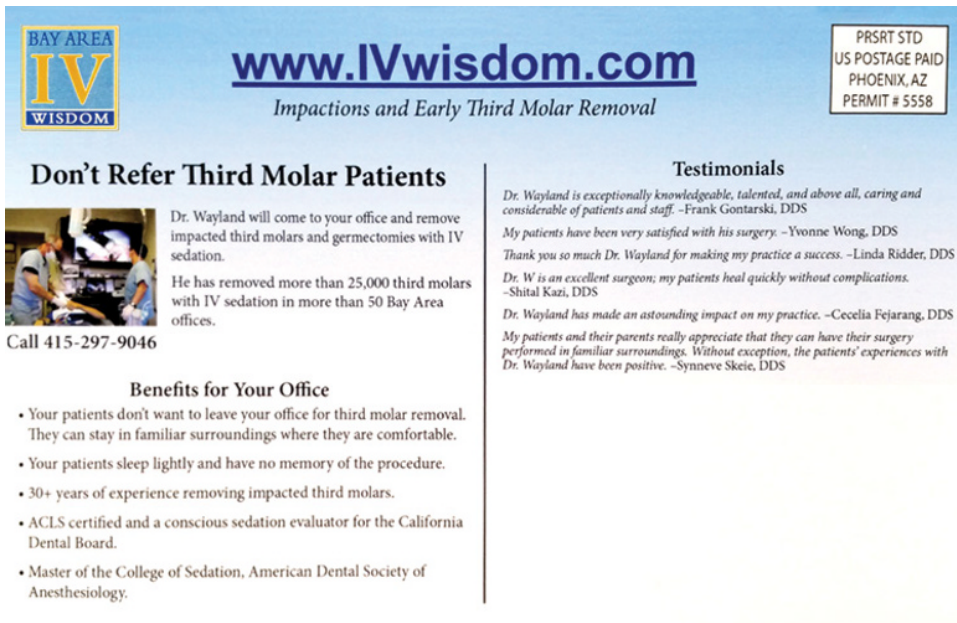
Postcards are the most cost-effective direct mail method. The card should have a "sound bite" message on the front and detailed information and testimonials on the back (see Figures 10.1a and 10.1b).

Imagine a typical day in your mobile third molar practice. A very relaxed schedule might be three patients in the morning, lunch, and three more in the afternoon. A reasonable fee for the removal of four impacted third molars with sedation, in 2018, might be \$1500. We now have a \$9000 production day. Fifty percent compensation results in

(a)




(b)



**www.IVwisdom.com**  
*Impactions and Early Third Molar Removal*

PRSR STD  
US POSTAGE PAID  
PHOENIX, AZ  
PERMIT # 5558

### Don't Refer Third Molar Patients



Dr. Wayland will come to your office and remove impacted third molars and germectomies with IV sedation.

He has removed more than 25,000 third molars with IV sedation in more than 50 Bay Area offices.

Call 415-297-9046

#### Benefits for Your Office

- Your patients don't want to leave your office for third molar removal. They can stay in familiar surroundings where they are comfortable.
- Your patients sleep lightly and have no memory of the procedure.
- 30+ years of experience removing impacted third molars.
- ACLS certified and a conscious sedation evaluator for the California Dental Board.
- Master of the College of Sedation, American Dental Society of Anesthesiology.

#### Testimonials

*Dr. Wayland is exceptionally knowledgeable, talented, and above all, caring and considerable of patients and staff. -Frank Gontarski, DDS*

*My patients have been very satisfied with his surgery. -Yvonne Wong, DDS*

*Thank you so much Dr. Wayland for making my practice a success. -Linda Ridder, DDS*

*Dr. W is an excellent surgeon; my patients heal quickly without complications. -Shital Kazi, DDS*

*Dr. Wayland has made an astounding impact on my practice. -Cecelia Fejarang, DDS*

*My patients and their parents really appreciate that they can have their surgery performed in familiar surroundings. Without exception, the patients' experiences with Dr. Wayland have been positive. -Synneve Skeie, DDS*

Figure 10.1 (a and b) Direct mail should be used as an adjunct to other promotional efforts.



\$4500 for the day with virtually no overhead. Now imagine repeating this day 10 times a month for many years. I think you get the point. Removal of third molars is profitable!

Everything you do to promote your mobile practice has one objective—an introductory meeting with the dentist and entire staff. The practice owner and staff members need to be familiar with your practice philosophy and protocol. This is your chance to impress the office. A key element of the initial office meeting is the procedure manual. It is given to every office, as a reference, at the initial meeting. The manual is reviewed with the owner and staff. Using the manual allows you to control the meeting. The manual is reviewed and questions are answered.

Your procedure manual should be customized to fit your practice. It should be comprehensive, including everything the office should know about your practice and patient treatment. It should include information about instrument setup, consultation appointments, consent forms, insurance and fees, sedation, and anything you think will benefit the office and patients. A well-organized and professional procedure manual will increase your credibility. My procedure manual is included in this chapter for reference.

## Third Molar Procedure Manual



*Early Third Molar Removal*

JOHN B. WAYLAND, DDS, FAGD, MaCSD  
*Diplomate – International Dental Implant  
Association*

123 Your Street  
Anywhere, CA 00000

FAX: 000.000.0000  
CELL: 000.000.0000  
EMAIL: DDS@aol.com

- 1) **Introduction**
- 2) **Guidelines**
- 3) **Instruments**
- 4) **Emergencies**
- 5) **Forms**
- 6) **Briefing**
- 7) **Research**
- 8) **Agreement**
- 9) **Documents**
- 10) **Scheduling**
- 11) **Insurance/Fees**

## Third Molar Removal With IV Sedation

### Introduction

Welcome to your office manual on the selected removal of impacted third molars with IV sedation. This manual has been prepared to provide you with necessary information regarding the removal of third molars with IV sedation. It is divided into sections for easy reference and review.

### Why Remove Third Molars?

A study published in the October 1985 issue of the *Journal of Oral and Maxillofacial Surgery* involved more than 16,000 impacted third molar extractions. This clinical study of more than 9,500 patients revealed that the optimum time for extraction is between the ages of 14 and 25 years. Results of the study show that as patients become older, the incidence of postoperative complications rise and become more significant and prolonged.

The American Association of Oral and Maxillofacial Surgeons also endorse the early removal of third molars. I personally have removed more than 25,000 impacted third molars without any significant complications. What I have learned is that case selection is critical to the success of third molar surgery. When specific guidelines are carefully observed, third molars can be removed safely, comfortably, and predictably.

### Why IV Sedation?

IV sedation is a safe and effective way to make patients comfortable during and after third molar surgery for the following reasons:

- Removing impacted third molars without some form of sedation is uncomfortable and patient management interferes with a quality surgery. This is not a practice builder. Conversely, virtually all of my patients have reported a comfortable experience with IV sedation.
- The degree of sedation can be controlled with IV sedation. Titration of the sedation drugs allows for complete control of the depth of sedation. Oral medication must be given in a bolus, and the degree of sedation can vary from patient to patient.
- The IV route of drug administration provides a pathway for antagonistic drugs to reverse the effects of the sedation. This is not possible with oral sedation.

## Guidelines for Third Molar Surgery

### Preoperative Appointment

- Appointment 1–2 days before surgery
- Ages 14 to 25 years old
- Healthy ASA Category I and II patients
- Record preop vital signs on sedation record
- Good venipuncture site
- Pre-op prescription given—ibuprofen, amoxicillin, triazolam
- All consent forms reviewed with patient and/or parent, signed, and dated (3).

Patient selection is paramount to a successful outcome. Any patient scheduled for third molar surgery should be seen first for a preoperative appointment. Ideal patients are aged 14 to 25. Patients in this age group are generally healthy, bone is relatively elastic, patients recover faster, and there is a lower incidence of dry socket. Vital signs are recorded at this appointment to provide a baseline measurement for the day of surgery.

All patients must be ASA category I or II to have oral or IV sedation. This means that they are healthy and without any known health risks.

### Important

Medication Rx is given at the pre-op appointment as follows:

Ibuprofen 800 mg three times a day × 15 tablets

Amoxicillin 500 mg three times a day × 15 tablets\*

Triazolam 0.25 mg × 2 tablets

Take 800 mg ibuprofen and 500 mg amoxicillin one hour before surgery and continue, three times a day, until all medication is gone.

Bring triazolam (2 tablets) to appointment.

**No food or liquids of any kind for 6 hours before appointment. A small amount of water may be used to take any medications prescribed for the appointment.**

**\*(Amoxicillin allergy—Clindamycin (Cleocin) 300 mg, three times a day × 15 tablets)**

### Surgery Appointment

- Schedule 1½ hour appointments.
- Set up operatory (see Instruments section).
- Dispense two 0.25 mg triazolam tablets (powder only) sublingual, without water, when patient arrives for their appointment. Ask them if they have had any food or liquids within the last 6 hours. Reschedule if not NPO for 6 hours.

- Wait a half hour for oral sedative to reach peak concentration before seating patient.
- Monoject 412 syringe dispensed to clean lower third molar surgical site.

Patients aged 14 to 25 can be scheduled for 1½ hour appointments. Ideally, six patients would be scheduled in a given day. If six patients cannot be scheduled on a given day, it is recommended that a minimum of four appointments be scheduled for third molar surgery in the morning or afternoon. These guidelines will assure that these procedures are completed in an efficient and profitable way.

When the patient arrives at the office, the assistant should question the patient to make sure that they are ready for surgery.

- Have they had any food or liquids six hours prior to appointment?
- Did they take their preoperative medication as prescribed?
- Are contact lenses removed?
- Are they wearing loose clothing?
- Do they have a ride home?
- Do they have any questions?

### Postoperative Appointment

- Appointment scheduled one week following surgery
- Sutures removed
- Healing checked by dentist
- Review Monoject 412 socket irrigation

Postoperative appointments should be scheduled one week after the surgery. At one week, most patients can open wide enough to comfortably remove sutures. Any remaining suture should be removed at this appointment. Polyglycolic acid (PGA) sutures should dissolve completely in 2–3 weeks.

A dentist should check for normal healing. Check for color, unusual pain, and exudate. Normal healing includes swelling, limited opening, and tenderness to palpation. Bruising is extremely unusual.

### Instruments/Operatory Setup

Dr. Wayland will provide instruments, monitors, and anesthesia supplies.

Contracted office will provide disposables listed below.

- 1 30-gauge needle
- 1 27-gauge needle
- 4 lidocaine 2% with epinephrine 1:100,000
- 2 Septocaine 4% with epinephrine 1:100,000
- 2 Marcaine 5% with epinephrine 1:200,000
- Vaseline
- 1 mask
- 1 box medium latex gloves
- 1 protective eyewear

1 alcohol gauze  
 1 blanket  
 2 sterile Monoject 412 syringes  
 #12 and #15 scalpel blades  
 2 sterile white surgical suction (101-2270) Schein\*  
 2 sterile green surgical suction (102-9023) Schein\*  
 1 ACE PGA 3.0 suture (003-3930) ACE Surgical\*  
 2x2 filled gauze (100-8608) Schein\*  
 4x4 8 ply filled gauze (100-3725) Schein\*  
 Cool Jaw—T800C-4B\* (optional)

\*Ace Surgical Supply (800) 441-3100

\*Henry Schein (800) 372-4346

\*Cool Jaw (877) 411-7009

## Instruments/Sterilization

Dr. Wayland will provide the instruments listed below.

Weider retractor  
 Minnesota retractor  
 Hemostat  
 Scissors  
 Needle holder  
 Bard parker handle (2)  
 Anesthetic syringes (2)  
 Cotton pliers  
 Periosteal elevator  
 Surgical curette  
 Root tip pick  
 46R elevator  
 Bite block  
 Metal dish

(15 instruments)

## Emergency Procedures

The State of California Board of Dental Examiners has mandated that all dentists using intravenous sedation must pass an evaluation and receive a permit to perform sedations. Knowledge of several emergencies must be demonstrated. Those emergencies and correct responses are listed below.

- 1) Airway obstruction—high pitched “crowing” on inspiration, sternal retraction, thoraco-abdominal rocking, cyanosis
  - Head position with jaw thrust
  - Suction

- Heimlich
  - Positive pressure oxygen with mask
- 2) Bronchospasm—impairment of respiratory exchange, wheezing, increased resistance to ventilation, cyanosis, desaturation
    - Patient in sitting position
    - Positive pressure oxygen with mask
    - Drugs: isoproterenol mist, epinephrine, steroids
  - 3) Emesis and aspiration—rales, dyspnea, tachycardia, partial airway obstruction, cyanosis, hypotension, desaturation
    - Patient positioning on right side, Trendelenburg position
    - Suction with large bore and cleaning
    - Positive pressure oxygen
    - Drugs for bronchospasm (Ventolin or Alupent), blood pressure
  - 4) Angina pectoris—chest pain lasting a few minutes, palpitations, faintness, dizziness, dyspnea
    - Recognize problem
    - Oxygen
    - Drugs—nitroglycerin spray sublingually up to 3 doses
  - 5) Myocardial infarction—chest pain, dyspnea, anxiety, weakness, hypotension
    - Recognize problem—chest pain unresponsive to nitroglycerin
    - Oxygen
    - Drugs
      - 1) Pain—morphine sulfate 3–4 mg IV and administer 1 aspirin orally, or Demerol or Nubain
      - 2) Heart rate—atropine
      - 3) Blood pressure
    - Hospital?
  - 6) Hypotension—progressive reduction in blood pressure, impending loss of consciousness, nausea, weakness
    - Recognize problem and cause
    - Position patient—Trendelenburg position, open airway
    - IV fluids
    - Drugs—Ephedrine or epinephrine (vasopressor); consider Narcan and flumazenil (Romazicon)
    - Sequential blood pressure
  - 7) Hypertension—elevated blood pressure, headache, blurred vision
    - Preventive measures
    - Oxygen
    - Reassure patient
    - Blood pressure
    - Nifedipine (Procardia) 10 mg sublingual?
    - Hospital?
  - 8) Cardiac arrest
    - Basic CPR
    - Positive pressure oxygen
    - Start IV

- 9) Allergic reaction—rash, edema, dyspnea/wheezing, salivation, tearing, rhinitis, pruritis, urticaria
  - Diagnosis: mild (diphenhydramine/Benadryl 50 mg) to severe (epinephrine 3–5cc 1:10,000)
  - Trendelenberg position
  - Oxygen
  - IV fluids
  - Drugs—Benadryl or epinephrine
  - Hospital?
- 10) Convulsions—tonic/clonic convulsion, excessive salivation, poor air exchange, disorientation
  - Cause
  - Prevent injury—place patient on side with head extended, restrain patient, open airway
  - Oxygen
  - Monitor respiration
  - Drugs—Valium 10 mg
  - Hospital?
- 11) Hypoglycemia—sudden onset, history of insulin administration and inadequate intake of food, dizziness, weakness, nausea, possible loss of consciousness, low blood sugar
  - Diagnosis
  - Drugs—administer oral dextrose, oxygen, IV 50% dextrose
  - Hospital?
- 12) Syncope
  - Position patient
  - Oxygen
  - Check vital signs
- 13) Respiratory depression—poor air exchange, decreased chest expansion, falling oxygen saturation, possible cyanosis
  - Correct anatomical airway
  - Positive pressure oxygen with mask
  - Drug antagonist—Narcan
  - Monitor vital signs



## Medical History

1) Have you ever had any problems with:

Heart _____	Diabetes _____
Lungs _____	Epilepsy _____
Kidney _____	High Blood Pressure _____
Liver _____	Low Blood Pressure _____
Asthma _____	Seizures _____
Allergies _____	Reaction to anesthetic _____ (General, Local, Sedation)

2) Medications routinely used at home \_\_\_\_\_

3) Past surgeries:

Dates	Operation	Type of Anesthesia (General, local, sedation)
_____	_____	_____
_____	_____	_____

4) Do you smoke? \_\_\_\_\_ Packs/day? \_\_\_\_\_ Number of years? \_\_\_\_\_

5) Do you drink alcohol? \_\_\_\_\_ How often? \_\_\_\_\_

6) Have you ever had any health problems we should know about? \_\_\_\_\_

Patient Name \_\_\_\_\_

_____	_____
Patient's or Guardian's Signature	Date

_____	_____
Witness's Signature	Date

_____	_____
Doctor's Signature	Date

## Presurgical Instructions

Patient Name: \_\_\_\_\_

Today's Date: \_\_\_\_\_ Surgery Date & Time: \_\_\_\_\_

It is extremely important that you follow these instructions prior to your appointment for surgery.

**1) No food or drink within six (6) hours of your appointment.\***

If your appointment is in the morning, you do not have anything to eat or drink from midnight the night prior to your appointment day. If your appointment is in the afternoon, you should have a light breakfast in the morning, as long as you finish your meal six (6) hours prior to your appointment.

\*A small amount of water may be used to take any medications prescribed for your appointment.

**2) Pain and infection control—TAKE MEDICATIONS AS DIRECTED**

Take ibuprofen and amoxicillin\* 1 hour prior to appointment. Bring triazolam (2 tablets) to your appointment.

\*If you are allergic to amoxicillin, you will be given another antibiotic.

**3) Do not drive on the day of your appointment.**

You will be sedated during your appointment. We will not be able to release you unless you have a responsible adult to drive you home.

**4) If you are not able to follow these instructions we cannot complete the planned treatment.**

*I HAVE READ AND UNDERSTAND THE ABOVE ENTIRELY.*

---

Patient's or Guardian's Signature

## Postsurgical Instructions

Following these directions is important to avoid complications and aid healing. Please read them carefully.

- 1) **DO NOT RINSE OR BRUSH YOUR TEETH FOR 24 HOURS.**  
After 24 hours, begin rinsing your mouth gently with salt water. Use ½ teaspoon of salt per cup of warm water. Rinse for one minute 5–6 times per day for four days.
- 2) **TAKE MEDICATION AS DIRECTED.**  
Take 800 mg ibuprofen and 500 mg amoxicillin three times a day, “by the clock,” until all medication is gone. For example, take both medications when you wake up, when you go to sleep, and once in between. You should do this even if you do not experience pain. Two Extra Strength Tylenol (500 mg) can be taken every 4–6 hours in addition to ibuprofen if needed for pain. Do not exceed 8 Extra Strength Tylenol tablets per day.
- 3) **USE ICE THE DAY OF SURGERY.**  
Swelling normally increases for 3 to 4 days following surgery and then gradually decreases. Ice (or a bag of frozen peas) may be applied for 15 minutes and removed for 15 minutes, alternating on and off for 24 hours following surgery.
- 4) **EXPECT MINOR BLEEDING OR OOZING.**
  - Bleeding will continue throughout the first day.
  - Cotton gauze should be removed after 1 hour and when sleeping.
  - If bleeding is excessive, wipe away any old clots and place a moist tea bag on the surgical site. Any tea bag will work, but black tea is the most effective.
- 5) **TALKING AND MOVEMENT OF YOUR MOUTH AND TONGUE WILL INCREASE BLEEDING.**
- 6) **SLEEP IS RECOMMENDED AFTER SURGERY.**  
Most patients will sleep after sedation if they are placed in their bed. Upon waking, clean any excess blood, begin using ice, eat something soft, and drink liquids.
- 7) **NO CHEWING THE DAY OF SURGERY.**  
Avoid all foods that require chewing for the first 24 hours. Drink lots of liquids and eat soft foods that can be swallowed easily. Ginger Ale, Ensure, Jamba Juice (no straw), ice cream, yogurt, soups (broth only), and similar food are recommended.
- 8) **PATIENTS SHOULD NOT BE LEFT ALONE THE DAY OF SURGERY.**
- 9) **DO NOT SMOKE FOR 48 HOURS AFTER SURGERY.**
- 10) **USE THE PLASTIC IRRIGATION SYRINGE AFTER FOUR DAYS.**  
Fill the syringe with warm water. After each meal, place the syringe tip into the lower sockets and flush out debris until clean. Continue using until the socket is closed, usually about 1 month.

**NOTE:** If you have any reason to believe that you are not recovering satisfactorily, please call Dr. Jane Doe at (000) 123-4567.

### Progress Notes

Patient \_\_\_\_\_ Date \_\_\_\_\_

#### SUBJECTIVE

Asymptomatic      Orthodontics      Pain      LL      LR      UL      UR

#### OBJECTIVE

Roots      0-1/3      1/3-1/2      1/2-2/3      2/3-1/1      1/1

Access      Good      Large tongue      Small mouth      Limited opening

Ramus proximity to third molar      0      0-1/2      1/2-1

Tissue distal      1 \_\_\_\_\_ 16 \_\_\_\_\_ 17 \_\_\_\_\_ 32 \_\_\_\_\_ None \_\_\_\_\_

Angulation      1 \_\_\_\_\_ 16 \_\_\_\_\_ 17 \_\_\_\_\_ 32 \_\_\_\_\_

Malampatti class      I      II      III      IV

#### ASSESSMENT

Impaction Pericoritis GP Class I II III Orthodontics

**PROCEDURE:** See IV record

Risk, alternatives, benefits      PT      MO      FA      B      S      FR      GFR      BFR      W      H

- 1      Flap      RBODB      Section      ED      BF      I      1x3.0 PGA
- 16      Flap      RBODB      Section      ED      BF      I      1x3.0 PGA
- 17      Flap      RBODB      Section      ED      BF      I      1x3.0 PGA
- 32      Flap      RBODB      Section      ED      BF      I      1x3.0 PGA

Post-op written and oral      MO      FA      B      S      FR      GFR      BF      W      H

Complications \_\_\_\_\_

Signature \_\_\_\_\_

## Progress Notes Key

**SUBJECTIVE:** LL = lower left; LR = lower right; UL = upper left; UR = upper right

**OBJECTIVE:**

Roots = root development

Access = surgical access

Ramus proximity to third molar

0 = room for eruption

0–1/2 = some of the third molar is in the ramus

1/2–1 = most or all of the third molar is in the ramus

Tissue distal = tissue covering distal of third molar

Angulation = Mesioangular, distoangular, vertical, horizontal, transverse

**ASSESSMENT:** Diagnosis. GP class is Gregory Pell position class I, II, or III

**PLAN/PROCEDURE:**

Risk, alternatives, benefits given to patient, mother, father, brother, sister, friend, girlfriend, boyfriend, wife, or husband

RBODB = remove buccal, occlusal, distal bone

ED = elevator delivery

BF = bone file

I = irrigation

1 × 3.0 PGA = one 3.0 polyglycolic suture

Postoperative instructions given to mother, father, brother, sister, friend, girlfriend, boyfriend, wife, or husband



## Third Molar Impaction Consent

### What is an Impacted Tooth?

An impacted tooth is a tooth that has not erupted normally. It may be covered by bone as well as gum tissue. Impacted teeth that press against other teeth may cause damage to those teeth. They may also cause crowding, infections, swelling, pain, cysts, earaches, headaches, generalized head and neck pain, and even tumors.

### What is a Surgical Extraction?

Since impacted teeth are partially or completely beneath the surface of the gum tissue or bone, their removal is a surgical procedure. A surgical extraction requires the removal of bone, soft tissue incisions, or sectioning of teeth. Pain medication and instructions will control postoperative pain, swelling, bleeding, and discomfort.

DISCOMFORT, SWELLING, LIMITED OPENING, AND BLEEDING ARE NORMAL FOLLOWING SURGICAL EXTRACTIONS.

Slight bleeding may continue until the morning following surgery. The corners of the mouth may be irritated. Curved and thin root tips can fracture during extraction. They are usually removed, but they may be left in place if they are near vital structures. Postoperative infections occasionally occur and are treated with antibiotics. Because of the close proximity of impacted teeth to adjacent teeth, occasionally a tooth or dental restoration may be damaged. VERY RARELY, postoperative complications include sinus opening, displacement of a tooth into the sinus or infratemporal fossa, lip or tongue numbness that can be temporary or permanent, damage to other oral structures, severe infections, jaw joint problems, and broken jaws. In extremely rare circumstances, even death may occur. A CT scan radiograph (X-ray) may be recommended when a wisdom tooth is near a nerve.

We will do our very best to make this a comfortable experience. If you have any questions, please ask for clarification.

*I UNDERSTAND THAT DR. WAYLAND IS NOT AN ORAL SURGEON. I HAVE READ AND UNDERSTAND THE ABOVE ENTIRELY AND HEREBY CONSENT TO THE PERFORMANCE OF SURGERY AS PRESENTED TO ME.*

\_\_\_\_\_  
Patient's or Guardian's Signature

\_\_\_\_\_  
Date

\_\_\_\_\_  
Witness's Signature

\_\_\_\_\_  
Date

\_\_\_\_\_  
Doctor's Signature

\_\_\_\_\_  
Date

## IV Sedation and Wisdom Teeth Briefing\*

Why is early removal of wisdom teeth recommended?

- 5-year study
- How to explain to parents that wisdom teeth need early removal. Big oak tree vs. little oak tree.

Case selection

- Age—14 to 25, with some exceptions
- Good health, ASA 1–2
- Partial root development

Pre-op visit—day before surgery

- Amoxicillin 500 mg, 15, one hour before appointment and then one three times a day until gone. For infection.
- Ibuprofen 800 mg, 15, one hour before appointment and one three times a day until gone. For inflammation and pain.
- Triazolam 0.25 mg, 2, bring medication to appointment.
- Review forms and consents and have them signed. Take BP and pulse and record on IV record.
- Give patient Presurgical Instructions to take home.

Surgery day

- Schedule 1½ hours per patient. Actual surgery averages about 30 minutes.
- Consents, medication, no food or drink for 6 hours
- Triazolam 0.5 mg, in office, 1/2 hour before appointment—for anxiety
- Post-op instructions in writing
- Cool Jaw ice and compression

Post-op visit

- Expect tenderness, normal color, and limited opening
- Check for color, exudates, and unusual pain
- Remove sutures

IV sedation/oral sedation

- Safety
- Patient and clinical expectations

Scheduling

- Schedule target date in advance
- Use letters to communicate with patient and parent

Insurance and fees

- Most are billed as completely bony impactions
- Use your office fee schedule—IV fee can be adjusted

\*This form is for the initial office meeting. Please refer to the Guidelines section of the procedure manual for pre-op, surgery, and post-op details.



## **Third Molar Research**

This section contains third molar research articles and studies. My manual has 13 articles including the 2007 AAOMS white paper on third molars.

## Contractual Agreement for Dental Services

This agreement is entered into on this 1st day of January 2018 by John Doe, DDS (hereinafter termed “Lessor”), and John B. Wayland, DDS, FAGD, MaCSD (hereinafter termed “Lessee”).

### Recitals

- A) Lessor owns and possesses a leasehold interest in the dental office located at 1234 Dental Avenue, Anywhere, CA 12345. Lessor and Lessee are both licensed dentists, duly licensed to practice their respective professions by the State of California.
- B) Lessee desires to perform and deliver oral surgery services and other associated procedures at the aforementioned premises to numbers of the general public (hereinafter termed “Patients”), subject to the terms and conditions as set forth herein.
- C) In consideration for the mutual promises herein contained, and other valuable consideration, the Lessor and Lessee agree to the following terms and conditions as set forth herein.

#### I STATUS of the PARTIES

- 1) Lessee is an independent dental contractor.
- 2) All patients referred to Lessee by Lessor for said treatment shall remain the responsibility of the Lessee for that respective treatment until that treatment has been completed, suspended either because of termination of this agreement as provided in Section X (2) or otherwise interrupted due to unforeseeable circumstances.

#### II TERMS of the CONTRACTUAL AGREEMENT

- 1) The terms of this agreement shall remain effective unless otherwise terminated by written notice from either respective party hereto at any time during any period thereof. Such termination notice shall be provided to the other party with at least 30 days prior to date of expected termination.
- 2) Following receipt of the termination notice or expiration of that respective period, any extensions beyond the “pre-agreed” deadline will not be allowed, unless superseded by a new written agreement memorialized by both parties prior to that deadline.
- 3) The terms of this agreement shall remain effective for an initial period of *one year*, unless otherwise terminated in accordance with provisions designated in Section II (1), or Section II (2).
- 4) Following the completion of the initial period, the terms of this agreement shall continue in full force for additional periods of *one year*, unless otherwise terminated in accordance with provisions designated in Section II (1), or Section II (2).
- 5) The terms of this agreement may be extended for additional *one-year* periods provided that both parties mutually agree and abide with the provisions of this agreement.

#### III DENTAL SERVICES

- 1) Lessee shall engage in the performance and delivery of oral surgery treatment aforementioned at the said premises. Said services shall be rendered in compliance with the provisions of the **Dental Practice Act** of the State of California, Rules and Regulations.

- 2) Lessee shall record and maintain accurate records of all treatment provided to all patients treated at the premises. Lessor shall maintain possession of the original charts, radiographs, and related materials for said services performed by Lessee on patients at the premises.
- 3) Lessee shall have the right to an audit of all records related to said services provided by Lessee to patients at the premises.
- 4) Upon request made by Lessee to Lessor, Lessor shall provide Lessee, within a reasonable time not to exceed 14 days, up-to-date copies of those materials requested by Lessee related to said services performed by Lessee.

#### IV FURNISHINGS, FURNITURE, and EQUIPMENT

- 1) Lessor hereby agrees to provide to Lessee and Lessee hires from Lessor non-exclusive use of the clinical and administrative equipment, furniture, and furnishings within the premise. The use of this equipment, furniture, and furnishings shall be subject to the following conditions:
  - a) Title to the Lessor's equipment, furniture, and furnishings will remain the Lessor's at all times, unless otherwise stipulated by mutual consent of both parties hereto. Title to equipment, furniture, and materials provided by Lessee shall remain the Lessee's, unless otherwise stipulated by mutual consent of both parties hereto.
  - b) Maintenance and repair of the respective equipment, furniture, and furnishings shall be the responsibility of the respective party.

#### V SUPPLIES

- 1) Lessor agrees to provide for Lessee all administrative and clinical materials to reasonably enable Lessee to carry out the professional day-to-day delivery of said services at the premises and shall be subject to the following conditions:
  - a) Lessor and Lessee agree to be responsible for providing all personal surgical instrumentation and materials used in the delivery of said services at the premises, for providing an emergency number service made available to all patients seen by Lessee. In addition, Lessee agrees to maintain malpractice insurance to cover the delivery of said services at the premises.

#### VI PERSONNEL

- 1) Lessor agrees to provide all the necessary personnel to handle all patient scheduling, clerical, bookkeeping, billing, coordination and sequencing of treatment with Lessor or other doctors, and maintenance of patient records.
- 2) Lessor agrees to provide competent staff to assist Lessee in the delivery of the said services for patients at the premises.

#### VII DISBURSEMENT for LESSEE'S SAID SERVICES

- 1) Lessor agrees to pay Lessee, **on the day services are delivered**, a fee equal to **fifty percent (50%) of Lessee's production** for the delivery of services at the premises.
- 2) The term *production for delivery of said services* means the actual fees charged for delivery of said services, services designated by procedure code, and which reflect actual services provided by Lessee at the premises.
- 3) At the end of each tax year, Lessor will provide Lessee with a copy of **IRS form 1099-MISC**.

**VIII INSURANCE**

- 1) Lessee agrees to provide, keep, and maintain malpractice insurance coverage of at least \$1,000,000 per claim and \$3,000,000 in aggregate throughout the entire term of this agreement to cover the delivery of said services at the premises.
- 2) Lessor agrees to provide, keep, and maintain general liability of insurance for the premises for the same said period.

**IX INDEPENDENT CONTRACTUAL RELATIONSHIP**

- 1) Lessor and Lessee shall indemnify, defend, and hold each other harmless from and against any liability, loss, cost, expense, demand, or claim asserted by or in behalf of any patient arising from the delivery of said services rendered to said patient by either party.

**X TERMINATION**

- 1) Lessor and Lessee agree that the clinical materials and records of patients treated by Lessee at the premises during initial period or any following periods are the property of Lessor. Said patients will always remain as Lessor's patients of records. It is further agreed and understood that ongoing professional care of those patients of record, other than the delivery of said services provided by Lessee noted herein, will remain the responsibility of Lessor.

This instrument as construed is in accordance with the laws of the State of California, and represents the complete and total agreement of both parties. Any additions, deletions, or modification to this agreement will require a new written agreement endorsed by both parties in order to become effective.

Dated this 1st day of January 2018

---

John Doe, DDS, Lessor

---

John Wayland, DDS, FAGD, MaCSD Lessee

## Documents

This section should include all legal documents pertaining to your practice. My dental license, sedation permit, DEA permit, and insurance declaration are included in this section of my procedure manual.

## Scheduling Letter

The letter below has been helpful when a new contracted office initially schedules third molar patients. Your office can send this letter to the parents of all teenagers between the ages of 13 and 19. It is a good idea to check the charts of patients slightly older as well. You can modify the letter as necessary for any patient.

This letter can also be used after a recall exam to introduce the procedure to your patients.

Mr. and Mrs. Guardian of Patient  
1234 Main Street  
Your City, CA 12345

January 1, 2016

Dear John and Jane,

The ideal time to remove wisdom teeth is before the roots are fully developed. Removing wisdom teeth early has been shown to decrease future pathology and surgical complications. Furthermore, most orthodontists recommend the removal of wisdom teeth to prevent crowding of the remaining teeth. Jill's dental record indicates that it may be time to remove her wisdom teeth.

Dr. John Wayland limits his practice to wisdom teeth removal and is available to do the procedure in our office with IV sedation. Jill will be comfortable during the procedure and will typically have little or no memory of the event. I've enclosed Dr. Wayland's biography for your review.

An updated panoramic X-ray is needed to evaluate the status of Jill's wisdom teeth. Please call our office at (000) 123-4567 to schedule an appointment for this X-ray.

Sincerely,

Your Name, DDS

## Scheduling Protocol

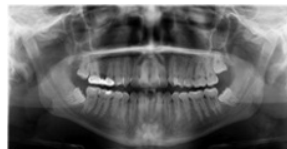
All offices have a tentative date scheduled with Dr. Wayland in their appointment book. Patient panoramic radiograph, age, and a general statement of health are sent to Dr. Wayland at [IVwisdom@aol.com](mailto:IVwisdom@aol.com) prior to scheduling and financial arrangements. Panoramic x-rays should be included in the email as an attachment. Dr. Wayland will approve panos and recommend insurance codes for each case.

Examples of email sent to Dr. Wayland:

- 1) John Doe, age 18, no medical problems
- 2) Mary Doe, age 16, asthma, tetracycline for acne
- 3) Justin Doe, age 38, recent heart bypass surgery, taking several medications

Examples of Dr. Wayland's response:

- 1) OK to schedule, 4 FBI
- 2) OK to schedule, 1 + 16 STI, 17 + 32 FBI
- 3) Recommend referral



The date reserved for Dr. Wayland can be moved to a future date if you are unable to book the original date. Preauthorization is recommended. This system has evolved over many years and is time tested. It works.

## Scheduling Tips

Scheduling dental patients is a challenge for any dental procedure, but this is especially true for removing wisdom teeth. People may have friends that have had a very bad experience removing wisdom teeth, leaving them nervous about the procedure. The best way to handle this situation is to educate the patient.

Since the ideal patient will be between the age of 14 and 25, you may be scheduling the surgery with the parent or guardian of the patient. Parents will often be extremely protective of their child and rightfully so, since they are the parents and you are trying to schedule surgery for their child. Please be aware and sensitive to the issues that concern the parents. The bottom line is, you are asking a parent to approve and allow you to schedule surgery for their child.

Get all their questions and attempt to answer them. If you cannot answer any of the questions, please assure them that you will get the answer for them as soon as you get a chance to call Dr. Wayland. Make sure they know that you will call them back later the same day to give them answers. While you may not be able to give them all the answers they need, you will need to make the parents feel comfortable, or less nervous, about the procedure by giving them information as well as answering their questions.

Explain to the patient and the parents why wisdom teeth should be removed while the patient is a teenager and how their child can benefit from early removal:

- 1) Teenagers typically do not have fully developed roots on their wisdom teeth. After the teenage years, wisdom teeth, if not removed, will have developed roots with hooks on them. These can break and cause damage to nerves or openings into their sinus.

- 2) Teenagers typically heal faster than older patients.
- 3) The procedure is much more predictable in teenagers than in older patients. Because of this, the chances of complications for teenagers are reduced to a minimum.

The patients and the parents should be informed that every patient might respond differently to any procedure. If they have friends who had a bad experience, it does not mean they will experience the same. Try to find out what “bad experience” they are concerned about. You will need to determine what the real issues are based on the information you get from your patient and their parents. Once you understand the concerns, you are on your way to putting the patient and their parents at ease by addressing their concerns as well as giving some basic information about the early third molar removals and IV sedation.

The word *surgery* may get the parent upset. It makes removing wisdom teeth more scary and risky than it really is. Try using the word *procedure* in place of *surgery* when you talk to the patient or their parents. This will leave a different and hopefully more positive impression of the procedure in their minds.

IV sedation is not general anesthesia. Sedation is used to make the patient as comfortable as possible during the procedure. Many patients will be asleep during the procedure and, although they can respond to commands, will not remember the procedure. To the patient, it will seem as if it only took 5 minutes to remove their wisdom teeth when it really took 30 minutes. Sometimes it really does only take 5 minutes to remove four teeth, but each patient will have different experiences.

If you find that the patient and/or their parents continue to have concerns about the procedure after giving them all the information you have, let them know that Dr. Wayland can call them and speak with them on the phone to address their concerns and address any questions they may have on the procedure. If this is necessary, please call and give Dr. Wayland a summary of the situation and what you think the primary concerns are, along with the patient’s name, parent’s names, and a number to contact them on. Dr. Wayland will call as soon as he possibly can.

## Insurance/Fees

The recommended sedation fee is \$500. However, insurance may not pay for IV sedation. Only a few offices get paid from Delta. Other companies are more likely to pay.

The average fee accepted by insurance companies for a completely bony impaction is \$425. The highest Delta fee that I have seen is \$550. The minimum fee for four full bony impactions, with IV sedation, should not be lower than \$1,900.

You can use the sedation fee to reach this minimum. For example, a patient with four completely bony impactions is covered at \$250 for each impaction. The patient would be responsible for their copayment for the surgery plus \$900 for the sedation. This would reach the \$1,900 minimum.

The other situation would be an office that has a high surgery fee and the patient does not want to pay for the sedation fee. For example, the same patient is covered at \$475 or more for each impaction. You have reached the minimum of \$1,900 with the surgery alone. The IV sedation fee can be used as a scheduling tool. If you feel a patient may not schedule because they do not want the out of pocket cost of the sedation fee, you could

adjust the IV sedation fee to the satisfaction of the patient. If necessary, you could waive the sedation fee, especially if you feel this is the only thing keeping them from scheduling the appointment. Keep in mind that the fee for four completely bony impactions, with IV sedation, should not be lower than \$1,900.

I believe the \$500 IV sedation fee is reasonable and should not be waived except in special cases.

#### PROCEDURE CODES

09243 IV sedation per 15 minutes

07210 Surgical removal of erupted tooth

07220 Soft tissue impaction (STI)

07230 Partial bony impaction (PBI)

07240 Completely bony impaction (FBI)



## Summary

The mobile third molar practice is not going to be a good fit for everyone. However, this niche might be the answer if you love to remove third molars and have the necessary skills. Creating a viable mobile third molar practice is challenging, but the rewards are many. Reduced stress, scheduling flexibility, low overhead, and financial freedom are just a few of the benefits awaiting you.

## References

- 1 Felton JS. Burnout as a clinical entity: its importance in healthcare workers. *Occup Med.* 1998;48:237–50.8.
- 2 Osborne D, Croucher R. Levels of burnout in general dental practitioners in the south-east of England. *Brit Dent J.* 1994;177:372–7.
- 3 Gorter RC, Freeman F. Burnout and engagement in relation with job demands and resources among dental staff in Northern Ireland. *J Affect Disord.* 2011;9:87–95.
- 4 Divaris K, Polychronopoulou A, Taoufik K, Katsaros C, Eliades T. Stress and burnout in postgraduate dental education. *Eur J Dent Educ.* 2012;16:35–42.
- 5 Lang R. Stress in dentistry—it could kill you! *Oral Health.* 2007 Sep 1.
- 6 Lang R. Stress in dentistry—it could kill you! *Oral Health.* 2007 Sep 1.
- 7 Solomon E. The future of dental practice: demographics. *Dental Economics.* 2015 Apr 10.
- 8 Diringer J, Phipps K, Carsel B. Critical trends affecting the future of dentistry: assessing the shifting landscape. Prepared for the American Dental Association. 2013 May.
- 9 Weston J. The multispecialty practice: a unique practice model for challenging times. *Dental Economics.* 2016;106(10).
- 10 Christensen GJ. Interaction between GPs and specialists. *Dental Economics.* 2016;106(10).
- 11 Olenski S. Social media for small business: how it's different from how big brands do it, *CMO Network.* 2015 Oct 29.
- 12 Lontos P. 7 publicity myths that can hurt your business. *Exchange Magazine.* 2012.
- 13 Farris et al. *Marketing metrics: the definitive guide to measuring marketing performance.* Upper Saddle River, New Jersey: Pearson Education, Inc.; 2010.
- 14 Beasley L. Why direct mail still yields the lowest cost-per-lead and highest conversion rate. *On Line Marketing Institute.* 2013 Jun 13.



## Index

Note: Page numbers in *italic* indicate Figures, and those in **bold** indicate Tables.

- 19/20 elevators 81, *81*  
 34 elevator 78, *80*, 114  
 46R elevator 78, *80*, 114, *116*, 120, *120*  
 77R elevator 78  
 190/191 elevators 81, *81*  
 301 elevator 78, *80*, 114, 120  
 1703L surgical bur 112, *112*
- a**
- abscess 48  
 acetaminophen 101, 131, 148, **148**  
   combined with ibuprofen 149–150  
 ACLS protocol 62  
*Actinomyces viscosus* 42  
 active listening 13  
 Advil *see* ibuprofen  
 AED (automated external defibrillator) 204  
 age  
   and the presence of third molars 29  
   influence third molar surgery outcome 27–29  
   risk of complications 43  
 AIDS 84  
 airway adjuncts 201, *201*  
 airway management, Mallampati airway  
   classification 18, 18  
 airway obstruction during sedation 200–201, *201*  
 albuterol 202, 203  
 allergic reaction 202  
 alveolalgia *see* alveolar osteitis  
 alveolar osteitis 40–46, *40*  
   aggressive irrigation of the extraction  
   socket 106  
   perioperative use of chlorhexidine  
   mouthwash 101  
   possible causes 41–44, **44**  
   prevention 44–45, 45  
   prophylactic antibiotics 100–101  
   treatment 45–46  
 alveolitis *see* alveolar osteitis  
 Alvogyl 45  
 Ambien *see* zolpidem  
 American Association of Maxillofacial  
   Surgeons 30  
 American Dental Association (ADA)  
   clinical guidelines on sedation 167–173  
   definitions 165–167  
   guidelines for the use of sedation  
   197–198  
   Principles of Ethics and Code of Professional  
   Conduct 228  
 American Society of Anesthesiologists (ASA),  
   physical classification system 16–17, **17**  
 amoxicillin 48, 153–154, **154**  
 Amoxil *see* amoxicillin  
 anaphalaxis 202, *202*  
 anatomy 1–10  
   blood vessels 4–6  
   buccal fat pad 6–7  
   infratemporal fossa 8–10, *10*  
   maxillary sinus 8, 9  
   nerves 1–4  
   structures relevant to safe removal of third  
   molars 1  
   submandibular fossa 7–8, 7, 8  
 anesthesia, history of 163–165  
 anesthetic gas, minimum alveolar concentration  
   (MAC) 139  
 angina pectoris 203, *204*  
 angulations, surgical technique 122–125  
 ankylosed tooth 24  
 antibiotics 48, 100–101, 153–156  
   prophylactic use 156  
   treatment of existing infection 156  
 anticoagulant medications 53  
 antiseptic mouthwash 101  
 anxious patient 102

articaine 140–142, 141  
 aspiration  
   during sedation 203, 203  
   during third molar surgery 61–62, 61  
 aspirin 149, 204  
 asthma attack 202–203, 202  
 atropine 205, 205  
 auriculotemporal nerve 3, 3  
 axonotmesis (Class II nerve injury) 39

**b**

Baeyer, Adolf von 183  
 barbiturates 183  
 Baxter, Crystal 213  
 Becker, Daniel E. 141  
 benadryl 202  
 benzodiazepines 135–137, 183, 191–192  
 Bergalis, Kimberly 84  
 bleeding and hemorrhage  
   coagulation disorders 52–53  
   excessive bleeding 52–54  
   hemorrhagic shock 53–54  
   hemostatic agents 52–53  
   hypovolemia 53–54  
   normal postoperative bleeding 52  
   persistent bleeding 52–54  
   sources of 4–6  
 blood pressure 16, 17–18, 17  
 blood vessels 4–6  
 Bloodborne Pathogens standard (OSHA Regulations) 93–94  
 bone density and elasticity assessment 24, 24  
 breach of duty 218  
 bromides 183  
 buccal fat pad 6–7  
   herniation of during third molar removal 57, 57  
 buccal nerve 3  
   effects of injury 4  
   studies 33–34, 34  
 buccal space infections 49, 50  
 bupivacaine 87, 140–142, 141, 150  
 burnout in dentists 225–226  
 business cards 230

**C**

California Dental Board Blue Ribbon Panel review of anesthesia 197–200  
 CAMP mnemonic for interview questions 14  
 canine space infections 49, 50  
 capnometer 208, 209, 210, 211, 211  
 cardiac arrest 204, 204  
 caries  
   prevalence related to age 28  
   risk in third molars xii

case selection 13–31  
   age of the patient 27–29  
   decision to refer 30–31  
   early third molar removal 27–29  
   medical evaluation 13–19  
   prophylactic removal of third molars 29–30  
   radiographic assessment 20–27  
 cavernous sinus thrombosis 49  
 celecoxib 149  
 cellulitis 48, 49, 51  
 cetrimide solution 101  
 Chain, Ernst Boris 153, 153  
 chloral hydrate 183  
 chlorhexidine mouthwash 44–45, 45, 46, 101  
 chorda tympani nerve 3, 3  
 Christensen, Gordon 228  
 Cleocin *see* clindamycin  
 clindamycin 153, 154, 155  
 clinical exam 18, 18  
 coagulation disorders 52–53  
 cocaine 140  
 Cochrane Reviews 30  
 codeine 149  
 Cogswell B elevators 77, 79  
 common carotid arteries 4  
 community service, promotion of your practice 229  
 complications  
   alveolar osteitis 40–46, 40  
   aspiration and ingestion 61–62, 61  
   bleeding and hemorrhage 52–54  
   buccal fat pad herniation 57, 57  
   damage to proximal teeth 57  
   displacement of third molars 7–9, 58–61, 59, 60  
   incidence of 62  
   infection 46–52  
   jaw fracture 54–56, 54, 55  
   maxillary sinus openings 8  
   oral-antral communication 57–58  
   osteomyelitis 56–57  
   paresthesia 33–40  
   postoperative sinus infections 8  
   temporomandibular joint (TMJ) injury 62  
 computed tomography (CT) scans 20  
 cone beam computed tomography (CT) scans 20  
 contractual agreement for dental services 250–252  
 Coumadin 53  
 Crane Pick elevators 77, 79  
 cranial nerves 1, 2  
 cricothyrotomy 62  
 Cryer elevators 77, 79

**d**

danger space (vertebral space) infection 50, 52  
 deep neck space infections 50, 51–52

- deep sedation 166, 167, 171–173  
 deep space hematomas 53  
 dental meetings, promotion of your mobile practice 229  
 Dental Organization for Conscious Sedation (DOCS) 183  
 Dentist's Advantage insurance company, review of malpractice cases 218–224  
 Dentistry from the Heart (DFTH) 229  
 dexamethasone 150–151, **151**, 193  
 diabetic patients, hypoglycemia 206–207, **208**  
 diazepam 107  
 digastric muscle 3  
 diphenhydramine 202  
 direct mail, marketing your mobile practice 230, 232  
 disinfection 100  
 displacement of third molars 7–9, 58–61, **59**, **60**  
 disposable materials 86–93  
 documentation  
   importance of 213  
   informed consent 213–217  
   informed refusal 217  
   legal issues 213–224  
   malpractice cases 218–224  
   prior to surgery 101  
   progress notes 217–218  
 drills *see* surgical drills  
 dry socket *see* alveolar osteitis  
 dry socket paste 45, 46  
 dysphagia 49  
 dyspnea 49
- e**
- E-type micromotor 72–74, **72–73**  
 early third molar removal 27–29  
 EL3CSM elevator 80, **81**, **82**, **114**  
 electrocardiogram (EKG) 211–212, **212**  
 elevators 77–83  
 emesis and aspiration during sedation 203, **203**  
 ephedrine 205, **205**  
 epinephrine 52  
   for allergic reaction 202, **202**  
   for asthma attack or bronchospasm 202–203, **202**  
   in local anesthetics 141, **141**, **142**, **142**  
 equipment 68–74  
   lighting 69, **70**  
   loupes 69, **70**  
   magnification 69, **70**  
   operating microscope 69  
   surgical drills and motors 70–74, **74**  
   surgical tables and chairs 68, **68–69**  
 ergonomics of the work space 67–68
- ether dome 164  
 exodontia training for dentists xi  
 external carotid artery 4, 5  
 eye protection 85–86, **85–86**
- f**
- face shields 85–86  
 Facebook 230  
 fascial space infections 49  
 FDA pregnancy risk categories for drugs 134, **135**  
 fear of going to the dentist 163, **183**  
 Feck, Anthony 183  
 fentanyl 135, **143**, **145**, **146**  
   IV administration 191–192  
 fibrinolytic alveolitis *see* alveolar osteitis  
 first-pass metabolism 132, **175**, **176**  
 fissure bur 108, **109**  
 flag elevators 77  
 Flagyl *see* metronidazole  
 flap designs  
   mandibular third molars 109–111, **110**, **111**  
   maxillary third molars 119–120, **119**  
 Fleming, Alexander 153, **153**  
 Florey, Howard Walter 153, **153**  
 flumazenil 138, **139**, **201**, **203**  
 follicle 23–24, **24**  
 foramen ovale 3  
 forceps 75
- g**
- gauze pharyngeal screen 61, **61**, **77**, 90–91, **92**, **93**  
 general anesthesia 19, **166–167**, **171–173**  
 germectomy 28–29, **29–30**, **125–126**  
 germicides 100  
 gloves 84, **85**  
 glucocorticoids 150–152  
 goggles 85–86, **86**  
 gowns, surgical 86, **86**
- h**
- Halcion *see* triazolam  
 Hall type drill 71–72, **71**  
 hand washing 84  
 health history 13, **14–15**, **16**  
 health history form 13, **14–15**, **16**  
 Heimlich maneuver 62  
 hemorrhage *see* bleeding and hemorrhage  
 hemostasis, epinephrine in local anesthetics 141, **141**, **142**, **142**  
 high-speed compressed air drills 70–71, **71**, **74**  
 HIV transmission 84  
 hives 202, **202**  
 House, Milus 18, **19**  
 hydrocodone 131, **143–144**, **144**, **149**

hypertension 17, **18**, 205, 206  
 hypoglycemia 206–207, 208  
 hypotension 205, 205

## i

ibuprofen 101, 131, 134, 146–147, **147**  
 combined with acetaminophen 149–150  
 for inflammation 150, 152  
 Impact Air 45 drill 71, 71  
 incisive nerve 3  
 inclined plane elevators 77–78, **80**, 80, 83  
 incremental dosing of sedation 167  
 infection 46–52  
 antibiotics 153–156  
 deep neck space infections **50**, 51–52  
 Ludwig's angina 8  
 pericoronitis 8, 46–48, **47**, **48**  
 risk of alveolar osteitis 42–43  
 space infections 49–52  
 surgical site infections (SSIs) 48–49  
 inferior alveolar artery 4, 5  
 inferior alveolar canal  
 displacement of third molars into 60  
 relative position of third molar roots 25–26,  
 25–26, 26  
 inferior alveolar nerve 3, 3, 34  
 effects of injury 4  
 studies 34–36, 35, 36, 37–39, **38**  
 inferior alveolar neurovascular bundle 4  
 inferior alveolar vein 4  
 inflammation, pharmacology for 150–152  
 informed consent 101, 213–217  
 intravenous sedation consent form 216  
 role in reviewed malpractice cases 222–224  
 third molar impaction consent form 215  
 informed refusal 217  
 infratemporal fossa 8–10, **10**  
 displacement of third molars into 58–60, 59  
 ingestion during third molar surgery 61–62, **61**  
 inhalation of nitrous oxide (N<sub>2</sub>O) 175  
 guidelines for use 176–182  
 instruments 74–83  
 basic setup for impacted third molars 75–83, 76  
 care of 75  
 elevators 77–83  
 manufacturing 74–75  
 sterilization 99–100  
 internal carotid artery 4  
 International Personality Disorder Examination 19  
 intramuscular (IM) administration 175  
 intranasal administration 174  
 intravenous (IV) administration of sedation 176,  
 185–193  
 intravenous sedation consent form 216  
 iodoform gauze 45, 46  
 irrigation syringes 93, 93

## j

jaw fracture 54–56, *54*, 55  
 Jorgensen, Niels Bjorn 164, **165**, 185

## l

Lang, Randy 225  
 Laster retractor 120, *121*  
 lateral pharyngeal space **50**, 51–52  
 lateral pterygoid muscle 3  
 lateral trepanation 28–29  
 Leeuw, Wilhemina 223  
 lidocaine 87, 140–142, *141*  
 Liebig, Justus von 183  
 lighting for the work space 69, 70  
 lincomycin 154  
 Lindemann bone cutting bur 108, *109*  
 lingual nerve 3  
 effects of injury 4  
 studies 37–38, **38**  
 LinkedIn 230  
 litigation  
 importance of dental documentation 213–224  
 issue of informed consent 213–217  
 local anesthesia 193  
 decision on the use of sedation 102  
 “difficult to numb” patient 102  
 local anesthetics 140–142, *141*  
 epinephrine in 141, *141*, 142, *142*  
 use with vasoconstrictors 43  
 localized osteitis *see* alveolar osteitis  
 logo 230  
 Loma Linda technique 164  
 long buccal nerve *see* buccal nerve  
 Lortab 131 *see also* hydrocodone  
 loupes 69, 70  
 low-speed electric drills and motors 72–74,  
 72–73, **74**  
 low-speed nitrogen drills 71–72, *71*, **74**  
 Ludwig's angina 8, 51, 221  
 luxators 81–83, 83

## m

magnification 69, 70  
 Malamed, Stanley 163, 226  
 Mallampati airway classification 18, 18  
 malpractice cases (Dentist's Advantage review of  
 third molar cases) 218–224  
 broken drill bit retained in jaw and nerve  
 injury 220  
 death following wisdom tooth extraction 221  
 elements of a malpractice lawsuit  
 218–223  
 jaw fracture and fibromyalgia 219  
 lingual nerve damage 219–221  
 lingual nerve severed 221–222

- role of informed consent in each 222–224
    - trigeminal nerve injury 222
  - mandibular foramen 3
  - mandibular fracture 54–56, 54, 55
  - mandibular nerve 1, 2, 3, 3
  - Marcaine 87
  - masks 85, 85
  - masseter muscle 3
  - masseteric space infections 50, 50, 51
  - masticator space infections 50, 50, 51
  - maxillary artery 4, 5
  - maxillary nerve 1, 2
  - maxillary sinus 8, 9
    - displacement of third molars into 58–60, 59
  - maxillary third molars, surgical technique 118–122
  - maxillary tuberosity fracture 55–56
  - maximum recommended dose 167
  - medial pterygoid muscle 3
  - medial pterygoid nerve 3
  - medical evaluation
    - clinical exam 18, 18
    - health history 13, 14–15, 16
    - patient interview 13–14
    - physical assessment 16–18
    - prior to sedation 173, 174
    - psychological evaluation 18–19
  - medical history, coagulation disorders 52–53
  - meningeal nerve 3
  - mental foramen 3, 3
  - mental nerve 3, 3
  - meperidine 132
  - methylprednisolone 150, 151–152, 152
  - metronidazole 48, 49, 153, 154–155, 155
  - midazolam 134, 135, 136–137, 137, 206
    - IV administration 191–193
  - minimal sedation 166, 167–169
  - Minnesota retractor 110, 111
  - mobile third molar practice 225–257
    - alternative to private practice 225–226
    - assessing suitability for you 257
    - author's experience 226–227
    - benefits 227–228
    - causes of stress and burnout in dentistry 225–226
    - general dentist or specialist 228
    - procedure manual 233–257
    - promotion methods 229–33
  - moderate sedation 166, 167, 169–171
  - monitoring of patients undergoing sedation 191–193
  - monitors 207–212
    - capnometer 208, 209, 210, 211, 211
    - electrocardiogram (EKG) 211–212, 212
    - precordial stethoscope 211, 211–212
    - pretracheal stethoscope 211, 211–212
    - pulse oximeter 208–209, 209, 210
  - Morton, William T. G. 163–164, 164
  - muscles, motor branches of the mandibular nerve 3
  - musculoskeletal disorders in dentists 67–68
  - mylohyoid muscle 3
  - mylohyoid nerve 3, 3
    - effects of injury 4
    - studies 33–34, 34
  - myocardial infarction 204, 204
- n**
- nalbuphine 143
  - naloxone 133, 143, 145–146, 146, 201, 203
  - naproxen 149
  - Narcan *see* naloxone
  - narcotics, oral 131
  - National Institute for Clinical Excellence (NICE)
    - UK 30
  - necrotic socket *see* alveolar osteitis
  - necrotizing mediastinitis 221
  - negligence 223
  - nerve injury
    - buccal nerve studies 33–34, 34
    - classification 39–40
    - complications following removal of impacted third molars 4
    - inferior alveolar nerve studies 34–36, 35, 36, 37–39, 38
    - lingual nerve studies 37–38, 38
    - mapping 39
    - mylohyoid nerve studies 33–34, 34
    - paresthesia 33–40
    - risk factors 39, 40
  - nerves 1–4
    - neurapraxia (Class I nerve injury) 39
    - neurotmesis (Class III nerve injury) 39–40
  - newsletter, promotion of your mobile practice 230
  - nitroglycerin 203, 204, 204, 205
  - nitrous oxide (N<sub>2</sub>O) inhalation 134, 138–139, 140, 175
    - guidelines for use 176–182
  - Norco 131 *see also* hydrocodone
  - NSAIDs 101, 133, 146–147, 149–150, 152
- O**
- open-ended questions 13–14
  - operating microscope 69
  - ophthalmic nerve 1, 2
  - opiates 142
  - opioids 101, 134, 142–146, 149
    - IV administration 191–912
  - oral access, Mallampati airway classification 18, 18

oral-antral communication 57–58  
 oral contraceptives, association with alveolar osteitis 42  
 oral sedation 176, 183–184  
 Osteomed system 72, 72  
 osteomyelitis 56–57  
 oxycodone 143, 144, **145**, 149  
 Oxycontin *see* oxycodone  
 oxyhemoglobin dissociation curve 208–209, 210

## P

pain management, drugs used in third molar removal 101, 140–150  
 paracetamol *see* acetaminophen  
 parapharyngeal space infections **50**, 51–52  
 parenteral administration of drugs 185–193  
 paresthesia 33–40  
 patient–dentist relationship 223  
 patient interview 13–14  
 patient safety  
   monitors 207–212  
   sedation law 197–200  
 pediatric patients, informed consent issues 214–215  
 penicillin 48  
   discovery of 153  
 pennant elevators 77  
 Percocet 149  
 pericoronitis 8, 46–48, **47**  
 periodontal ligament 23–24, 24  
 periodontal pathology and age 27–28  
 periosteal elevator 110, *111*  
 periostomes 81–83, 82  
 personal protective equipment (PPE) 84–86  
   OSHA Regulations 93–94  
 personality disorders 19  
 pharmacology 131–157  
   agonist drugs 133  
   antagonist drugs 133  
   antibiotics 153–156  
   author's medication regimen 156–157  
   bioavailability of drugs 131–132  
   combinations of analgesic agents 149–150, 151  
   drug interactions 134  
   drugs used in third molar removal 134–157  
   efficacy of oral analgesics 149, **149**  
   FDA pregnancy risk categories 134, 135  
   first-pass metabolism 132  
   infection 153–156  
   inflammation 150–152  
   oral narcotics 131  
   pain management 101, 140–150  
   pharmacodynamics 133–134, *133*  
   pharmacokinetics 131–133, *132*  
   plasma half-life of drugs 133

postoperative swelling 150–152  
 potential for abuse 131  
 sedation 134–140  
 selection of appropriate drugs 131  
 therapeutic index of drugs 134  
 pharyngeal screen (gauze) 61, *61*, 77, 90–91, 92, 93  
 physical assessment 16–18  
 pill crusher 184–185, *185*  
 Plavix 53  
 polyglycolic acid (PGA) suture 88, 88  
 postoperative care 107–108  
 postoperative risks and age 28  
 postoperative swelling, pharmacology for 150–152  
 Potts elevators 81, 82  
 PPL instruments 81–83, 82–83  
 precordial stethoscope 211, *211*–212  
 pregnancy  
   contraindication for sedation 173  
   FDA risk categories for drugs 134, 135  
 pretracheal stethoscope 211, *211*–212  
 prevertebral space (danger space) infection **50**, 52  
 primary space infections 49–50, **50**  
 procedure manual for third molar mobile practice 233–257  
   contractual agreement for dental services 250–252  
   emergency procedures 238–240  
   fees 255–256  
   guidelines for third molar surgery 236–237  
   instruments/operator setup 237–238  
   instruments/sterilization 238  
   insurance 255–256  
   introduction 235  
   IV sedation and wisdom teeth briefing 248  
   legal documents 253  
   medical history form 241  
   postsurgical instructions 243  
   presurgical instructions 242  
   progress notes and key 244, 245  
   scheduling letter 253  
   scheduling protocol 254  
   scheduling tips 254–255  
   sedation record 246  
   third molar impaction consent 247  
   third molar research 249  
 professional duty 218  
 progress notes 217–218  
 prophylactic antibiotics 156  
 prophylactic removal of third molars, debate about xii, 29–30  
 proximal teeth, damage during third molar removal 57  
 proximators 81–83, 82, 83



- Pseudomonas aeruginosa* 100  
 psychological evaluation 18–19  
 pterygomandibular space  
   displacement of third molars into 60  
   infections 50, 50, 51  
 pulse oximeter 208–209, 209, 210  
 pus 48, 49, 56
- r**
- radiographic assessment of third molars 20–27  
   angulation 21–22, 22  
   bone density and elasticity 24, 24  
   combined root width 22, 23  
   depth 20–21, 21  
   periodontal ligament and follicle 23–24, 24  
   position 20  
   position relative to the inferior alveolar canal 25–26, 25–26, 26  
   root length, size and shape 22–23, 23  
 rectal administration of drugs 175  
 Reed, Ken 141  
 respiratory depression during sedation 201, 201  
 retropharyngeal space infection 50, 52  
 Reznick, Jay 107  
 Romazicon *see* flumazenil  
 round bur 108, 109
- S**
- Sabra OMS45 drill 71, 71  
*Salmonella choleraesuis* 100  
 scalpel blades 90, 92  
 secondary space infections 49, 50  
 sedation  
   contraindication during pregnancy 173  
   drugs used in third molar removal 134–140  
   factors affecting the use of 102  
   postoperative care 107–108  
 sedation emergencies 200–207, 208, 209  
   airway obstruction 200–201, 201  
   allergic reaction 202  
   anaphylaxis 202, 202  
   angina pectoris 203, 204  
   aspiration 203, 203  
   asthma attack 202–203, 202  
   bronchospasm 202–203, 202  
   cardiac arrest 204, 204  
   drug reversal 201, 201  
   emesis and aspiration 203, 203  
   hypertension 205, 206  
   hypoglycemia 206–207, 208  
   hypotension 205, 205  
   myocardial infarction 204, 204  
   patient safety and sedation law 197–200  
   respiratory depression 201, 201  
   seizure 206, 207  
   syncope 207, 209  
 sedation law, patient safety 197–200  
 sedation monitoring 207–212  
 sedation techniques 163–193  
   ADA clinical guidelines 167–173  
   ADA definitions 165–167  
   history of anesthesia 163–165  
   inhaled nitrous oxide (N<sub>2</sub>O) 175, 176–182  
   intravenous sedation 185–193  
   levels of sedation 165–167  
   medical evaluation prior to sedation 173, 174  
   monitoring of patients 191–193  
   oral sedation 176, 183–184  
   routes of administration 174–176  
   sedation as a continuum 165–166  
   sublingual administration 184–185  
 seizures 206, 207  
 Seldin elevators 77, 79  
 Semmes Weinstein monofilament 39  
 septic shock 221  
 septic socket *see* alveolar osteitis  
 Silverman, Michael 183  
 sinuses, oral-antral communication 57–58  
 smoking, link with alveolar osteitis 42  
 SOAP progress notes 217–218  
 social media, promotion of your mobile practice 230  
 soft tissue flaps 107  
 space infections 49–52  
 specialty instruments 76  
 standard of care 218  
*Staphylococcus aureus* 100  
 sterilization of instruments 99–100  
 straight elevators 78  
*Streptococcus* infections 48  
*Streptococcus mutans* 42  
 stress in dentists 225–226  
 subcutaneous air emphysema 105  
 subcutaneous injection 175  
 Sublimaze *see* fentanyl  
 sublingual administration of drugs 176, 184–185  
 sublingual space  
   displacement of third molars into 60–61  
   infections 50, 50–51  
 submandibular fossa 7–8, 7, 8  
 submandibular space  
   displacement of third molars into 60–61, 60  
   infections 50, 50–51  
 submasseteric space infections 50, 50, 51  
 submental space infections 50, 50–51  
 suction, disposable 87, 87  
 superficial temporal artery 4  
 supplemental dosing of sedation 167  
 Surgairtome drill 71–72, 71  
 surgical drills and motors 70–74, 74, 104–105  
   osteotomy and sectioning 104–105

- surgical principles 97–108
    - antibiotics 100–101
    - asepsis 98–100
    - candidates for local anesthesia with sedation 102
    - documentation prior to surgery 101
    - efficiency and speed 102–103
    - osteotomy and sectioning 104–105
    - pain medication 101
    - patient management 102
    - postoperative care 107–108
    - preoperative antiseptic mouthwash 101
    - preparation for surgery 97–101
    - primary versus secondary flap closure 107
    - role of surgical assistants 102–103
    - soft tissue management 107
    - surgical access 103–104
    - surgical site debridement 105–106
    - wound healing by secondary intention 107
  - surgical site infections (SSIs) 48–49
  - surgical tables and chairs 68, 68–69
  - surgical technique 108–125
    - angulations 122–125
    - germectomy 125–126
    - mandibular third molars 108–118
    - maxillary third molars 118–122
    - variations 108
  - suture materials 87–90, 88
  - suture needles 89–90, 90, 91
  - symptomatology and age 27
  - syncope 207, 209
- t**
- teenage patients, early third molar removal 27–29
  - temporal muscle 3
  - temporal space infections 50, 50, 51
  - temporomandibular joint (TMJ), injury related to third molar surgery 62
  - tensor tympani muscle 3
  - tensor veli palatini muscle 3
  - tensor veli tympani muscle 3
  - testimonials 230
  - therapeutic index of drugs 134
  - third molar removal
    - debate over prophylactic removal xii, 29–30
    - incidence in the United States xi
    - potential income for dentists xi
    - reasons for learning the procedure xi
  - third molars, risk of caries xii
  - titration of sedation 167
  - tranexamic acid 53
  - transdermal patch 174–175
  - Trendelenburg position 203, 205
  - Treponema denticola* 43
  - triazolam 134, 135–136, 136, 183, 184–185
    - sublingual administration 192–193
  - trigeminal nerve 1, 2, 3
  - trismus 49
  - tuberculocidal disinfectants 100
  - Twitter 230
  - Tylenol *see* acetaminophen
- u**
- universal precautions 84
  - urticaria 202
- v**
- vasoconstrictors 52 *see also* epinephrine
  - venipuncture 188–193
  - Verrill sign 191, 193
  - Versed *see* midazolam
  - vertebral space (danger space) infection 50, 52
  - vestibular space infection 49, 50
  - Vicodin 131 *see also* hydrocodone
  - von Willebrand disease 53
- w**
- website for the mobile third molar practice 230
  - Weed, Lawrence 217
  - Weider retractor 75, 76, 77, 78
  - Wells, Horace 163–164, 164
  - wheel and axle elevators 77, 78, 80–81
  - Winter, George B. 21
  - word-of-mouth promotion of your practice 229
  - work space 67–94
    - Bloodborne Pathogens standard (OSHA Regulations) 93–94
    - disposable materials 86–93
    - equipment 68–74
    - ergonomics of 67–68
    - instruments 74–83
    - materials 83–93
    - musculoskeletal disorders in dentists 67–68
    - personal protective equipment (PPE) 84–86, 93–94
- x**
- X cube motor 73, 73
- z**
- zolpidem 134, 137–138, 138

# **WILEY END USER LICENSE AGREEMENT**

Go to [www.wiley.com/go/eula](http://www.wiley.com/go/eula) to access Wiley's ebook EULA.