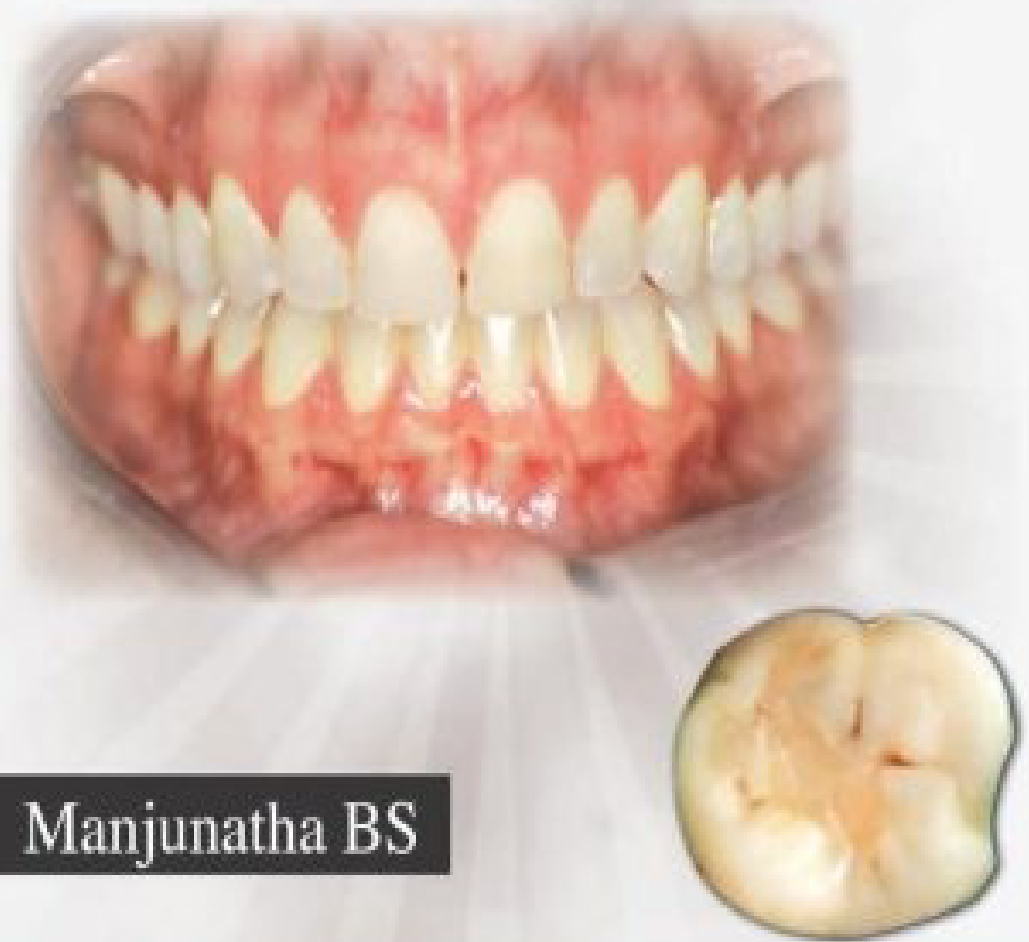

*Textbook of*  
**DENTAL ANATOMY**  
*and*  
**ORAL PHYSIOLOGY**

*Including Occlusion and Forensic Odontology*



**Manjunatha BS**

*Forewords*  
C Bhasker Rao  
GS Kumar  
R Gowramma

**JAYPEE**

# **Textbook of Dental Anatomy and Oral Physiology**



# Textbook of Dental Anatomy and Oral Physiology

*Including Occlusion and Forensic Odontology*

*Editor*

**Manjunatha BS** BDS MDS (DNB)

*Associate Professor*

Department of Oral and Maxillofacial Pathology  
KM Shah Dental College and Hospital  
Vadodara, Gujarat, India

*Forewords*

**C Bhasker Rao**

**GS Kumar**

**R Gowramma**



**JAYPEE BROTHERS MEDICAL PUBLISHERS (P) LTD**

**New Delhi • Panama City • London • Dhaka • Kathmandu**



## Jaypee Brothers Medical Publishers (P) Ltd

### Headquarters

Jaypee Brothers Medical Publishers (P) Ltd  
4838/24, Ansari Road, Daryaganj  
New Delhi 110 002, India  
Phone: +91-11-43574357  
Fax: +91-11-43574314  
**Email: [jaypee@jaypeebrothers.com](mailto:jaypee@jaypeebrothers.com)**

### Overseas Offices

J.P. Medical Ltd.  
83 Victoria Street, London  
SW1H 0HW (UK)  
Phone: +44-2031708910  
Fax: +02-03-0086180  
**Email: [info@jpmedpub.com](mailto:info@jpmedpub.com)**

Jaypee-Highlights Medical Publishers Inc.  
City of Knowledge, Bld. 237, Clayton  
Panama City, Panama  
Phone: + 507-301-0496  
Fax: + 507-301-0499  
**Email: [cservice@jphmedical.com](mailto:cservice@jphmedical.com)**

Jaypee Brothers Medical Publishers (P) Ltd  
17/1-B Babar Road, Block-B, Shaymali  
Mohammadpur, Dhaka-1207  
Bangladesh  
Mobile: +08801912003485  
**Email: [jaypeedhaka@gmail.com](mailto:jaypeedhaka@gmail.com)**

Jaypee Brothers Medical Publishers (P) Ltd  
Shorakhute, Kathmandu  
Nepal  
Phone: +00977-9841528578  
**Email: [jaypee.nepal@gmail.com](mailto:jaypee.nepal@gmail.com)**

Website: [www.jaypeebrothers.com](http://www.jaypeebrothers.com)  
Website: [www.jaypeedigital.com](http://www.jaypeedigital.com)

© 2013, Jaypee Brothers Medical Publishers

All rights reserved. No part of this book may be reproduced in any form or by any means without the prior permission of the publisher.

**Inquiries for bulk sales may be solicited at:** [jaypee@jaypeebrothers.com](mailto:jaypee@jaypeebrothers.com)

This book has been published in good faith that the contents provided by the contributors contained herein are original, and is intended for educational purposes only. While every effort is made to ensure accuracy of information, the publisher and the editor specifically disclaim any damage, liability, or loss incurred, directly or indirectly, from the use or application of any of the contents of this work. If not specifically stated, all figures and tables are courtesy of the editor. Where appropriate, the readers should consult with a specialist or contact the manufacturer of the drug or device.

***Textbook of Dental Anatomy and Oral Physiology  
Including Occlusion and Forensic Odontology***

***First Edition: 2013***

ISBN : 978-93-5025-995-5

*Printed at*

**Dedicated to**

*My*

*Great Teachers*

*Good Friends*

*Ever Loving Parents and Brothers*

*Aspiring Students*

*and*

*Two Angels, Chitti and Guddi*

*Ability is what you're capable of doing.  
Motivation determines what you do.  
Attitude determines how well you do it.*

# Contributors

---

**Ashith B Acharya** BDS, GDFO (Australia)  
Associate Professor and Head  
Department of Forensic Odontology  
SDM College of Dental Sciences  
and Hospital  
Dharwad, Karnataka, India

**Dharam Hinduja** MDS  
Associate Professor  
Department of Conservative Dentistry  
and Endodontics  
Index Dental College and Hospital  
Indore, Madhya Pradesh, India

**Gururaj B Patil** MDS  
Reader  
Department of Oral and Maxillofacial  
Pathology  
Jodhpur Dental College and Hospital  
Jodhpur, Rajasthan, India

**Mallikarjuna M Rachappa** MDS  
Reader  
Department of Pedodontics and  
Preventive Dentistry  
KM Shah Dental College and Hospital  
Vadodara, Gujarat, India

**Manjunatha BS** BDS MDS (DNB)  
Associate Professor  
Department of Oral and  
Maxillofacial Pathology  
KM Shah Dental College and Hospital  
Vadodara, Gujarat, India

**Nagarajappa Das** MDS (DNB)  
Associate Professor  
Department of Oral and Maxillofacial  
Surgery  
SJM Dental College and Hospital  
Chitradurga, Karnataka, India

**Narayan Kulkarni** MDS  
Reader  
Department of Orthodontics and  
Dentofacial Orthopedics  
KM Shah Dental College and Hospital  
Vadodara, Gujarat, India

**Rajashekhara BS** MDS  
Assistant Professor  
Department of Pedodontics and  
Preventive Dentistry  
College of Dental Sciences and  
Hospital  
Davangere, Karnataka, India

**Ramesh Naykar** MDS  
Associate Professor  
Department of Prosthodontics, Crown  
and Bridge  
KLE's Institute of Dental Sciences and  
Hospital  
Belgaum, Karnataka, India





# Foreword

---

Knowledge of Dental Anatomy and Tooth Morphology is a foundation for all dental professionals and for the practice of dentistry. Its importance as a basic science subject is highlighted by its inclusion in I BDS in the revised curriculum. I am happy to note that Dr Manjunatha BS, an alumnus of SDM College of Dental Science and Hospital, Dharwad, Karnataka, India is releasing this textbook, which will be a useful addition to the subject.

The textbook covers all traditional aspects of tooth morphology and dental occlusion; in addition, the book also includes a chapter which is a useful guide in practical exercises such as tooth carving. New and development areas of dentistry such as Forensic Odontology have also been covered from a dental anatomical perspective. All of these should make this book an essential reference used by dental student and graduate alike. I congratulate the author on his efforts, and wish him the very best in the success of this textbook.

**C Bhasker Rao** MDS FDSRCPS (Glasgow)

Chief Mentor and Medical Director, Vasan Dental Hospitals Pvt Ltd, India  
Formerly, Vice-President, Dental Council of India, New Delhi  
Formerly, Principal and Director, SDM College of Dental Sciences and  
Hospital, Dharwad, Karnataka, India



# Foreword

---

Dental Anatomy and Oral Physiology are the foundations of dentistry on which clinical dentistry rests. A textbook on these subjects should introduce the subject in such a way that it makes the basic concepts clear, at the same time bringing out the clinical relevance of the facts one has acquired. This theme has been followed in this book admirably. For the beginner, the explanations of the terms used in the introductory chapters is lucid so that the reader understands the details of the subject matter easily in the later chapters. The language used is simple and the illustrations aid in easy comprehension. The author's passion for tooth carving and his urge to reveal the 'mysteries' of tooth carving has found a place in this book.

For the postgraduate students, the section on Tooth Anomaly would be useful. Tooth Anatomy and Forensic Odontology is a novel idea and for those pursuing a career in forensic dentistry, will find the information interesting. The clinician will benefit, if he understands the concept of tooth form and function underlying his preferred treatment options.

Dr Manjunatha BS is a determined person and he will not rest till the task is completed. If he has to resolve a problem, he will go into great depths. As a postgraduate guide, these are my impressions on the author. In fact, I have realized his potential as a teacher and as a true academician, even when he was a post-graduate student. His experience in teaching and his interest in scientific pursuits, his keenness to publish in scientific journals have now, made him done the role of the author, which he has done creditably. I congratulate the contributors, who have lent a helping hand in making of this book. It was indeed a pleasure to write this foreword, and I am touched by the author's gesture to give this honor to his '*guru*'.

**GS Kumar** MDS  
Editor, Orban's Oral Histology and Embryology  
Professor and Head, Dean, KSR Institute of Dental Science and  
Research Center, Tiruchengode, Tamil Nadu, India  
Formerly, Professor and Head, Department of Oral Pathology  
SDM College of Dental Sciences and Hospital  
Dharwad, Karnataka, India



# Foreword

---

I am delighted to write foreword for this much-needed *Textbook of Dental Anatomy and Oral Physiology*, by Dr Manjunatha BS. He is known to me for the past 18 years as a student and faculty. I have found him academically oriented right from the beginning of his career and same has culminated in writing this book.

Indeed, it is very interesting to know that there are very few textbooks on Dental Anatomy written by an Indian author. Dr Manjunatha BS has made a sincere attempt to script the textbook. The attention to minute details evident in this book reflects the meticulousness and efficiency that is a quality found in abundance in the author. He has included new chapters on Forensic Odontology and Oral Physiology.

I am sure that owing to its umpteen illustrations, concise tables, simple language and color photographs, this book is undeniably appropriate not only for undergraduates but also for those pursuing graduate studies.

I congratulate the young author for all the efforts and hard work he has undertaken.

**R Gowramma** MDS  
Principal, Professor and Head  
Department of Periodontics  
SJM Dental College and Hospital  
Chitradurga, Karnataka, India



# Preface

---

This book is basically the result of more than eight years of my teaching in Dental Anatomy and Oral Physiology for dental and medical students. Some of the students have also been faculty and post-docs. I am very grateful to them for their patience and tolerance as it progressed from crude notes to the present form. Many of my teachers and friends have been a big source of inspiration and ideas.

It is my belief that Dental Anatomy and Oral Physiology have very much to contribute to basic knowledge in the field of dentistry. I hope enough students see this to make it happen. If this book contributes in any small way to the future progress, it will serve its purpose.

The material in the book is written for persons at a number of levels. Much of it is introductory for a beginner in dentistry, but serves to link to principles with other branches by association. For that reason, it needs to be studied with some care.

This list is incomplete and I wish to thank and acknowledge all those who were involved with this. I owe a special note of thanks to so many colleagues who, for various reasons, were (and many are still) skeptical of the approach. Without that skepticism and close scrutiny, there would be far more weaknesses and errors in this and related works. I hope this book provokes some strong reactions, positive and negative.

No one is complete and perfect. Thus, I accept my limitations as well as shortcomings in this book if any. I sincerely welcome all suggestions or any mistakes and look forward to improve further.

**Manjunatha BS**





# Acknowledgments

---

No one walks alone and when one is walking on the journey of life just where you start to thank those that joined you, walked beside you and helped you along the way.

First, I am extremely grateful to my teachers and would like to thank for all that what I am in this field. I take this opportunity to express my reverence to Lord “*Shiva*” with whose blessing I have been able to realize my dreams.

However, it would not have been possible without the kind support and help of many individuals and organizations where I was associated. My sincere thanks to all of them.

I also extend my heartfelt thanks to my parents, brothers and well-wishers without whom this project would have been a distant reality.

My sincere gratitude to all the contributors who have put in a lot of efforts and time in bringing out this book, without them it would have been like a tree in the fall season.

Dr Narayan Kulkarni deserves special mention and thanks for his continuous, untiring support and collaborative efforts to bring this book into the present form.

I am lucky to have good friends like Nagarajappa Das, Ashith B Acharya, Dharam Hinduja, Basavaprabhu, Abdus, whose company I cherished, whose intellect and science I admired, and steered me towards academics and research rather than purely clinical practice.

I wish to sincerely thank professor GS Kumar, my mentor and guide, Dr R Gowramma, my teacher for having given so much to all these important developments in my profession. I would also like to thank my teacher, mentor and philosopher, Dr C Bhasker Rao, Former Vice-President, Dental Council of India, New Delhi; Former Principal, SDM College of Dental Sciences, Dharwad, Karnataka, India for his encouragement and support.

I wish to thank and formally acknowledge the publishers for giving me an opportunity. My heartfelt thanks to the staff of M/s Jaypee Brothers Medical Publishers (P) Ltd, New Delhi, and Bengaluru Branch, for their patience and continuous support. I kept them waiting much longer than I care to mention.

Last and not the most important, my special thanks to my dear wife Reshma and the little angel Dhruvi who were neglected in various ways during the arduous hours required as I wrote these chapters to see that the book is completed. They were inspirational that has driven me onwards and kept me focused.

Finally, I thank all who have helped me in their own ways even without me realizing the worth of their efforts. My sincere thanks, love and respect to all of them.

Finally, I acknowledge every person who in some way or the other has motivated me and contributed towards accomplishing my objectives and dreams.



# Contents

---

<b>1. Introduction</b>	<b>1</b>
<i>Manjunatha BS, Dharam Hinduja</i>	
> Functions of Teeth	2
> Aims of Dental Anatomy	2
> Objectives of Dental Anatomy	2
> Scope of Dental Anatomy	2
> Evolution of Teeth	3
> Definitions	3
> The Deciduous Dentition	3
> The Permanent Dentition	4
> Dental Formula	4
<b>2. Definitions and Meaning of Terms Used in Dental Anatomy</b>	<b>5</b>
<i>Manjunatha BS, Dharam Hinduja</i>	
> Terms	5
> Parts of a Tooth	6
> Structures (Tissues) of a Tooth	7
> Surfaces of a Tooth	8
> Terms Used in the Description of Morphology of a Tooth	10
> Tooth Form and Function	20
> Division of Tooth in Different Directions	21
> Line and Point Angles of Different Teeth	22
<b>3. Tooth Numbering Systems</b>	<b>24</b>
<i>Manjunatha BS</i>	
> Zsigmondy/Palmer System	24
> Universal System	26
> FDI/Two Digit System	27
<b>4. Development of Occlusion</b>	<b>30</b>
<i>Manjunatha BS, Narayan Kulkarni, Rajashekhara BS</i>	
> Predentate Period	30
> Deciduous Dentition	33
> Mixed Dentition	38
> Permanent Dentition	47
<b>5. Permanent Incisors</b>	<b>49</b>
<i>Manjunatha BS</i>	
> Functions of Incisors	49
> Maxillary Incisors	50
> Maxillary Central Incisor	50
> Maxillary Lateral Incisor	57
> Mandibular Incisors	62
> Mandibular Central Incisor	62
> Mandibular Lateral Incisor	66

**6. Permanent Cuspids** **70***Manjunatha BS*

- Functions of Canines 70
- Class Traits [General Characters] of Canines 71
- Maxillary Canines 72
- Chronology of Permanent Maxillary Canine 73
- Mandibular Cuspids 77
- Chronology of Permanent Mandibular Canine 78

**7. Premolars** **81***Manjunatha BS*

- Functions of Premolars 81
- Class Traits [General Characters] of Premolars 81
- Maxillary First Premolar 82
- Chronology of Permanent Maxillary First Premolar 83
- Maxillary Second Premolar 87
- Chronology of Permanent Maxillary Second Premolar 87
- Permanent Mandibular Premolars 91
- Permanent Mandibular First Premolar 91
- Chronology of Mandibular First Premolar 92
- Mandibular Second Premolar 96
- Chronology of Mandibular Second Premolar 97

**8. Permanent Molars** **103***Manjunatha BS*

- Functions of Molars 103
- Permanent Maxillary Molars 104
- Permanent Maxillary First Molar 105
- Chronology of Permanent Maxillary First Molar 106
- Permanent Maxillary Second Molar 113
- Chronology of Permanent Maxillary Second Molar 113
- The Permanent Mandibular Molars 116
- Permanent Mandibular First Molar 116
- Chronology of Permanent Mandibular First Molar 116
- Permanent Mandibular Second Molar 124
- Chronology of Permanent Mandibular Second Molar 124

**9. Deciduous Dentition** **128***Manjunatha BS, Rajashekhara BS, Mallikarjuna M Rachappa*

- Maxillary Central Incisor 129
- Maxillary Lateral Incisor 130
- Maxillary Canine 131
- Maxillary First Molar 132
- Maxillary Second Molar 134
- Mandibular Central Incisor 135
- Mandibular Lateral Incisor 137
- Mandibular Canine 137
- Mandibular First Molar 138
- Mandibular Second Molar 140
- Differences Between Deciduous and Permanent Dentition 142

<b>10. Occlusion</b>	<b>146</b>
<i>Manjunatha BS, Narayan Kulkarni, Ramesh Naykar</i>	
‣ Other Factors Associated with Occlusion	149
‣ Dynamic Occlusion	154
‣ Keys to Occlusion	155
‣ Factors Affecting the Occlusion	158
‣ Age Changes in Occlusion	159
‣ Balanced Occlusion	159
<b>11. Vascularity and Innervation of Maxilla and Mandible</b>	<b>161</b>
<i>Nagarajappa Das</i>	
‣ Venous Drainage of Maxilla and Mandible	161
‣ Nerve Supply to the Maxilla and Maxillary Teeth	161
‣ Nerve Supply to the Mandible and Mandibular Teeth	165
<b>12. Tooth Anatomy and Forensic Odontology</b>	<b>167</b>
<i>Ashith B Acharya</i>	
‣ Definition of Metric Dental Traits	167
‣ Definition of Non-metric Dental Traits	168
‣ Sex Identification from Tooth Size	173
‣ Race Identification from the Dentition	175
<b>13. Carving Steps of Different Teeth</b>	<b>181</b>
<i>Gururaj B Patil</i>	
‣ Carving of a Rectangle from Wax Block	181
‣ Carving of a Cylinder from Wax Block	181
‣ Carving of a Basic Model	182
‣ Carving of Central Incisor	182
‣ Carving Steps in Canine	186
‣ Carving of Premolar	189
‣ Carving of Molars	192
‣ Carving of Mandibular Molar	195
<b>14. Trait Features of Teeth</b>	<b>198</b>
<i>Manjunatha BS</i>	
<b>15. Calcium and Phosphorus Metabolism</b>	<b>204</b>
<i>Manjunatha BS</i>	
‣ Physiological Functions of Calcium	204
‣ Distribution in the Body	205
‣ Dietary Sources of Calcium	205
‣ Calcium Absorption	206
‣ Recommended Dietary Allowance	206
‣ Calcium Balance	207
‣ Calcium Homeostasis	207
‣ Parathyroid Hormone	208
‣ Calcitonin	210
‣ Vitamin D	211
‣ Effects of Other Hormones on Calcium Metabolism	212
‣ Applied Physiology	212
‣ Phosphate Metabolism	213

<b>16. Functions of Teeth</b>	<b>216</b>
<i>Manjunatha BS</i>	
<b>17. Pain</b>	<b>218</b>
<i>Nagarajappa Das, Manjunatha BS</i>	
> History	218
> Components of Pain	218
> Types of Pain	219
> Theories of Pain	220
> Distribution of Pain Receptors	222
> Pathway of Pain in Orofacial Region	222
> Dentinal Sensitivity and Pulpal Pain	222
> Control of Pain	225
<b>18. Saliva</b>	<b>226</b>
<i>Manjunatha BS</i>	
> Composition of Saliva	226
> Saliva Components	227
> Properties of Saliva	228
> Factors Influencing Salivary Flow and Composition	229
> Functions of Saliva	230
> Lubrication and Protection	230
> Buffering Action	231
> Antimicrobial Activity	231
> Mechanical Cleansing Action	232
> Taste	232
> Digestion	232
> Bolus Formation for Swallowing	233
> Maintenance of Tooth Integrity	233
> Miscellaneous Functions	234
> The Diagnostic Applications of Saliva	234
> Disadvantages/Limitations of Saliva	237
<i>Index</i>	<b>239</b>

# CHAPTER

# 1

# Introduction

*Manjunatha BS, Dharam Hinduja*

Dental anatomy is primarily concerned with the external form and appearance of a tooth.

## DEFINITIONS

It is the branch of dentistry which deals with gross structure, mainly the morphology of the tooth and its associated parts.

It is the branch of dentistry which deals with the art and science of basic morphological, anatomical and functional relationships of teeth, jaws and their associated structures needed for normal harmony of an individual.

It is a branch of medicine and dentistry, which comprises of the study of morphology of both tooth and its associated structures including masticatory system.

Dental anatomy not only includes the study of tooth morphology, but also involves roots, pulp chambers, crown contours, contacts and embrasures associated with the crowns of teeth.

**Tooth:** Teeth are mineralized structures except for the pulp and are located in first part of the digestive tract. A tooth is defined as “**one of the hard tissues that are positioned on the jaws and help in holding and mastication of food, also as weapons of offense and defense in lower animals**”. The designs of the teeth are a reflection of eating habits. Teeth of a man are formed for cutting, tearing and grinding of food substances.

Human dentitions are divided into many classes of teeth based on the appearance and function or position. The types or different classes of teeth are as follows:

- **Incisors:** Incisors are named because they are used to incise or cut food. They are located in the front part of the mouth and have sharp, thin edges for cutting
- **Cuspids:** Cuspids, also referred to as canines, are at the angles of the mouth. Each tooth has a single cusp instead of an incisal edge and are designed for cutting and tearing
- **Bicuspids:** Bicuspids, also referred to as premolars, are similar to the cuspids. They have two cusps used for cutting and tearing, and an occlusal surface that is wider to crush the food
- **Molars:** Molars are located in the back part of the mouth. Their size gradually becomes smaller from the first to third molar. Each molar has four or five cusps; these teeth are shorter and more blunt in shape than other teeth and provide a broad surface for grinding and chewing solid masses of food. The detailed description of each tooth is given in following chapters.



## **FUNCTIONS OF TEETH**

Human beings have teeth with rich and unique anatomic characteristics and thus necessitate a comprehensive learning. The normal tooth form is extremely varied with every individual and is very difficult to reproduce. The normal anatomy of teeth assures the efficiency of mastication.

- Mastication is the primary function which includes cutting, shearing and chewing.
- Many others like growth of the skull and facial structures are seen with the development of teeth.
- Deglutition and swallowing are done with the help of teeth.
- Phonation and aesthetics are other major functions of teeth (note these properties in cleft lip/palate and edentulous patients).
- Protection to soft tissues of the mouth.
- Some animals, mainly carnivorous, use teeth for fighting and/or defense too. It is very important for an animal to have teeth as they are used not only for eating but also in grooming and defense.
- Last but not the least, tooth has a very important role in forensic odontology.

Each function of a tooth is described in respective chapters and in chapter 16, page 217.

## **AIMS OF DENTAL ANATOMY**

- The dentist who is intended to care for teeth should have thorough knowledge of the characteristics and fundamentals of dental morphology.
- To develop adequate manual skill to reproduce any part of the tooth, thus maintaining the perfect correlation with associated structures.
- Of great importance, a knowledge of function and anatomy that is intimately related to most dental areas.

## **OBJECTIVES OF DENTAL ANATOMY**

The objectives of dental anatomy are as follows:-

- To know the normal anatomic, physiologic, and biomechanical relationships of the dental structures.
- To be familiar with the clinical significance and define the shape and contour relationships of the normal dentition.
- Identify, describe, and to reproduce in drawings and wax, the morphology of permanent teeth from various views.
- Discuss the relationships between teeth and supporting structures.
- Correctly identify natural teeth with and without anatomical variations.

## **SCOPE OF DENTAL ANATOMY**

Though currently the use of computers and computer assisted graphics have helped out in teaching dental anatomy in three dimensional views, drawing and dental carving are considered to be very practical and objective methods for teaching and motivating dental students to obtain the knowledge till today.

The knowledge of dental anatomy is fundamental for the practice of any branch of dentistry. Clinical/practical research and other activities in dental

anatomy, carving of tooth can also be directly correlated. Carving of tooth helps in preparation of crown and bridge and other esthetic and restorative treatments.

The purpose of carving is to restore, in general by means of total or partial reconstruction, one or more parts of a tooth in its form and function as also to re-establish the lost balance in the physiology of mastication.

## EVOLUTION OF TEETH

- **Homodont:** It is a Greek term, meaning ‘same teeth’. Animals, which have one/single type of dentition where in all are similar in shape, indicative of a uniform diet.  
Example: Fishes, amphibians, and most reptiles. Crocodile has cone shaped teeth as also whales and dolphins
- **Heterodont:** Term derived from Greek, meaning ‘different teeth’, which refers to animals having more than a single type tooth morphology and are of different sizes and shapes, specialized for different tasks.  
Example: Man has different types of teeth
- **Monophyodont:** Dentition in which the species has only one set of teeth, which are functional through out the life.  
Example: Reptiles
- **Diphyodont:** Dentition in which the species have two sets of teeth, one set (called ‘deciduous’) being shed and replaced by a permanent set of teeth, which are functional throughout the life.  
Example: Cats, dogs, and humans
- **Polyphyodont:** Dentition in which the species has many sets of teeth, which get replaced and remain functional throughout the life.  
Example: Seen in lower vertebrates, mainly fishes.

## DEFINITIONS

- **Mandible:** It is the complete lower jaw which is made up of a single pair of bones
- **Maxilla:** It is a bone or part in the upper jaw that contains canine, premolar and molar teeth
- **Premaxilla:** It has paired bones present at the front of the upper jaw (maxilla) that contains incisor teeth on both sides in the midline.

As we all know, human beings have two sets of dentition: a deciduous and a permanent set. The oral cavity is divided into 4 quadrants, which represent one side of a jaw and each quadrant contains 5 deciduous teeth or 8 permanent teeth or combination of both depending on the age of the individual, which is discussed in detail in succeeding chapters.

## THE DECIDUOUS DENTITION

There are twenty deciduous teeth, ten in the maxilla and mandible respectively, and are grouped into three classes as incisors, canines and molars.

- Synonyms of deciduous teeth are primary teeth, milk teeth, baby teeth or temporary teeth or lacteal teeth or juvenile teeth. There are a total of 20 primary

teeth (8 incisors, 4 cuspids and 8 molars). Incisors are the first primary teeth to erupt and usually between 6–9 months. The last teeth usually erupt in by 24 months. These are present till the permanent are erupted, i.e. 6 years

- These teeth differ from the permanent in many ways. Specifically, no premolars are developed in this dentition.

Features of each deciduous tooth are discussed in detail in chapter 9.

## THE PERMANENT DENTITION

There are thirty two permanent teeth, out of which sixteen each are maxillary teeth and sixteen are mandibular teeth that are grouped into four classes as incisors, canines, premolars and molars.

- Synonyms of permanent teeth are secondary, permanent or succedaneous teeth. There are a total of 32 secondary teeth (8 incisors, 4 cuspids, 8 premolars and 12 molars). The first secondary tooth to erupt in the oral cavity is the first molar, and it usually erupts around 6 years of age. The last to erupt is the 3rd molar at around the age of 21 years. All other teeth are usually present by the age of 14 years
- These teeth stay in the oral cavity lifelong if maintained properly.

## DENTAL FORMULA

It is a way of designating or indicating the number or arrangement of teeth for a given species, but used mainly for mammalian teeth. Teeth of the upper jaw are listed over the lower jaw. The dental formula is described only on one side of the jaw, which represents the teeth on one side of the face of both jaws and is done so because the jaw is bilaterally symmetrical. The incisors are indicated first, followed by the canine, premolars and molars.

For instance I 3/3, C 1/1, P 4/4, M 3/3 letters indicate 3 incisors, 1 canine, 4 premolars and 3 molars on one side of both upper and lower jaws, so the dental formula would be:

Upper	I C P M	3 1 4 3
Lower	I C P M	3 1 4 3

Individual teeth can also be denoted. The disadvantage of this dental formula is that the sides of the jaw cannot be indicated.

From now onwards we take it as granted that the permanent dentition is considered generally and it is understood that the reader is aware of this. If deciduous teeth are explained, it will be specified.

## FURTHER READING

1. Ash M M and Stanley J N, 2003. Wheeler's dental anatomy, physiology, and occlusion. 8th edition.
2. Siéssere S, Vitti M, de Sousa LG, Semprini M, Regalo SCH. Educational material of dental anatomy applied to study the morphology of permanent teeth. *Braz Dent J* 2004;15(3):238-42.

# CHAPTER 2

## Definitions and Meaning of Terms Used in Dental Anatomy

Manjunatha BS, Dharam Hinduja

*Eyes can't see what mind doesn't know*

It is very much essential to be familiar with the basic knowledge of the subject when someone enters a new field of study. Without adequate knowledge in the field, one cannot understand or learn the subject properly. So it is very important to know definitions, meaning and explanations of many terminologies used in description of tooth morphology. Thus, the basic foundation of the subject of dental anatomy, one should become familiar with these terms, which are in use throughout the professional life.

### TERMS

- **Dentition:** It is defined as the arrangement of natural teeth (single or multiple sets) or artificial dentures in the mouth of an individual. Human beings have two sets of dentition, which has already been discussed in the previous chapter
- **Dental arch:** It is that part of the jaw which gives attachment to the root portion of teeth and is held in position to each other. The teeth are arranged in the upper and lower jaws in the form of two dental arches
- **Maxillary:** It refers to entities which are related to the upper jaw or the maxilla
- **Mandibular:** It refers to entities which are related to the lower jaw or the mandible
- **Quadrant:** It represents one side of a jaw either maxilla or mandible which are normally bilaterally symmetrical (Fig. 2.1)

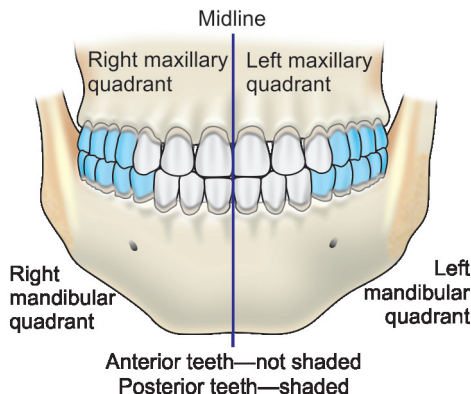


Fig. 2.1: Quadrants in maxilla and mandible

- **Alveolus:** That part of the bony jaw which surrounds the roots of teeth and gives attachment to periodontal ligament, thus supporting the tooth.

Teeth are of different groups namely incisors, canines, premolars and molars, depending on their shape, size and functions. They are bounded by the lips, cheeks and tongue on either side.

The term ‘**Anterior**’ refers to the direction towards front side close to lips and ‘**Posterior**’ refers to the direction towards the back side, next to the cheek of an individual’s head/face respectively.

Anterior teeth are the six upper and six lower front teeth that consists of incisors and canines. Incisors are used to cut the food. Cuspids are meant for the function of gripping and tearing food. Other than these prime functions, anterior teeth have significance in proper phonation and aesthetics of an individual. Mastication or chewing is the major function of posterior teeth.

## PARTS OF A TOOTH

Each tooth consists of a crown and a root joined at a slightly thinner part, called the neck. The tissue that surrounds the neck of a tooth and covers the jawbone is called the gum or gingiva.

- **Crown:** The portion of a tooth, above the gum line which is visible in the mouth (outside)
- **Root:** The part of a tooth embedded inside the jaw and holds the tooth in place within the bone.

### Anatomical Crown

It is that part of the crown of a tooth which is covered by enamel surface.

### Clinical Crown

It is that part of the tooth that is visible or exposed to outside in the oral cavity. This may be larger or smaller than the anatomic crown. The clinical crown is larger, when some part of the anatomic root is exposed due to recession or reduction in the size of gingiva.

### Anatomical Root

It is that part of the root of a tooth which is covered by cementum surface.

### Clinical Root

Part of the tooth present within the gingiva and is not exposed to oral cavity.

### Cervical Line

It is a thin line, which separates the anatomic crown and the anatomic root. It is also termed as cemento-enamel junction.

## Root Trunk

It is that part of the root which starts from the cervical line to the furcation area of multirooted teeth.

## Furcation

It is the junction of roots in multirooted teeth mainly in posterior teeth.

**Bifurcation and trifurcation:** It is the junction of two and three roots in multirooted posterior teeth.

## Apex

It is the tapered end of the root tip of a tooth.

**Apical foramina:** It is the communicating channel or opening between the periodontal membrane and the pulp. It is usually present at the apex of the root. (plural of foramen—‘foramina’)

## Pulp Cavity

It is a collective or general term used to designate the central part of a tooth which has housed the ‘pulp’ tissue of both crown and the root which is continuous in nature.

**Pulp chamber:** The part of the pulp cavity seen only in the crown of a tooth.

**Pulp canal:** The part of the pulp cavity seen in the root canal(s) of a tooth.

**Pulp horn:** It is the highest point or peak of the pulp chamber, which corresponds to the cusp or incisal tips located in the crown of a tooth.

## STRUCTURES (TISSUES) OF A TOOTH

Structurally, teeth are composed of four different tissues (Fig. 2.2), which are as follows:

- **Enamel:** The outer most part of crown of the tooth and is the hardest tissue in the body. It is an avascular and acellular tissue, so not considered as living tissue
- **Dentin:** Present below the enamel and cementum, and it is the second hardest tissue that makes up the bulk of the tooth. In contrast, it is a living tissue and is less hard than enamel. It also surrounds the pulp all around both in crown and root of a tooth
- **Cementum:** Covers the root part of a tooth that is embedded in the bone
- **Pulp:** Present in the center of the tooth and is made of loose connective tissue. It contains nerves and blood vessels, which enter the tooth through the apical foramen at the tip of the root.

Enamel, dentin and cementum are hard tissues of the tooth. The pulp is the ‘only’ soft tissue of the tooth. The crown and the root join at the cemento-enamel junction and also termed as ‘cervical line’, which is visible as a separating line on

a tooth specimen with the naked eye. It is advised to refer an oral histology text book for complete detailed information regarding the microscopic structure and histological features of these individual tissues of a tooth.

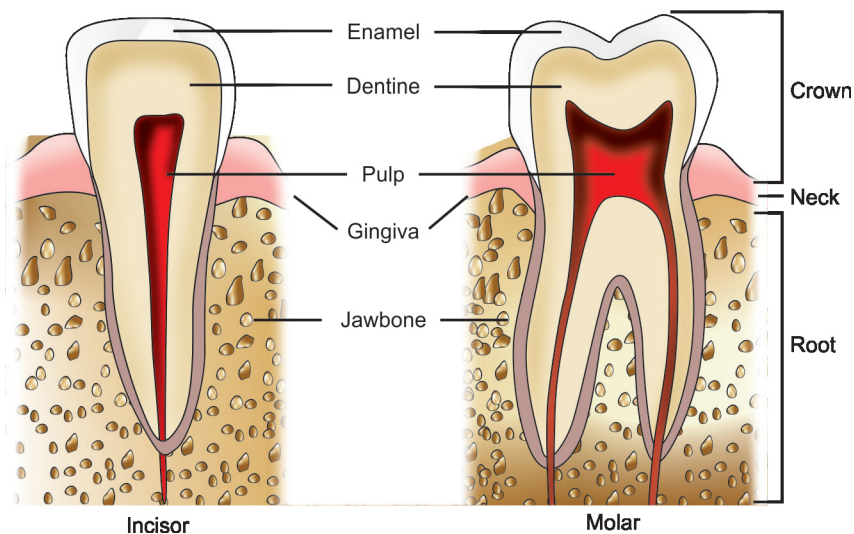


Fig. 2.2: Microscopic structure of the tooth and associated parts

## SURFACES OF A TOOTH

Both anterior and posterior teeth have five surfaces, which are named according to their positions and uses (Fig. 2.3). These are named so for the convenience of the clinician in practice and record maintenance. The following terms are used for the surfaces of the teeth:

- **Labial surface:** It refers to the side of a tooth that is adjacent or towards the inner side of the lip. Technically, only anterior teeth have a close relationship with lips. The term ‘labium’ means lips, so the surface towards lips is termed as labial surface
- **Buccal surface:** It refers to the side of a tooth that is adjacent or towards the inner side of the cheek. Applies only to posterior teeth, where the cheeks are present instead of lips. The term buccal is derived from buccinator muscle which is chief muscle in the formation of cheek
- **Facial surface:** It refers to the surface next to the face; the outside of a tooth that is adjacent to the cheek or lips. This term may be used to describe both the term buccal and labial in anterior and posterior teeth as well
- **Lingual surface:** It refers to the side of a tooth adjacent to or towards the tongue. Although this term is technically specific to the mandible, still it is in extensive use in reference to the maxilla as well
- **Palatal surface:** It refers to the side of a tooth adjacent or towards the palate. This term is absolutely used in the maxilla and not for mandibular teeth

- **Mesial surface:** It refers to the direction towards the midline, in the anterior part of a dental arch in each quadrant
- **Distal surface:** It refers to the direction furthest from the midline of a dental arch in each quadrant. All teeth except the last tooth (normally third molar in permanent and second molar in deciduous dentition) in each quadrant of a dental arch have a distal surface
- **Proximal surface:** It is a general term which includes both mesial and distal surfaces. when referring to the proximal surface i.e. mesial or distal surface of a tooth lying next to another tooth. Surfaces that are in close proximity to each other; the mesial surface of one tooth touches the distal surface of the adjacent tooth in the same arch
- **Incisal edge:** It refers to the biting edge of anterior teeth. It is usually not called as surface because incisors and canines have a thin cutting edge instead of a broad chewing surface, seen in case of posteriors
- **Occlusal surface:** It refers to the biting surface of posterior teeth
- **Cervical area:** It means ‘neck’ in Latin, refers to the narrowing of the tooth surface at or near the CEJ, where the crown meets the root
- **Gingival area:** It refers to the direction towards the gingiva.

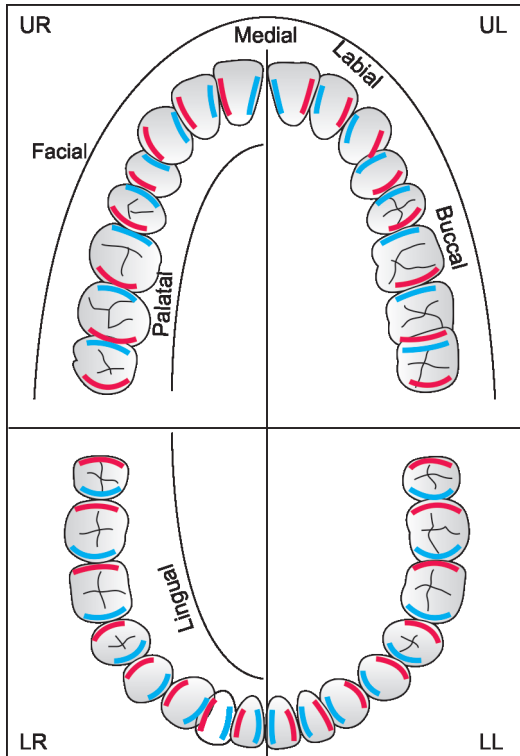


Fig. 2.3: Surfaces of a tooth

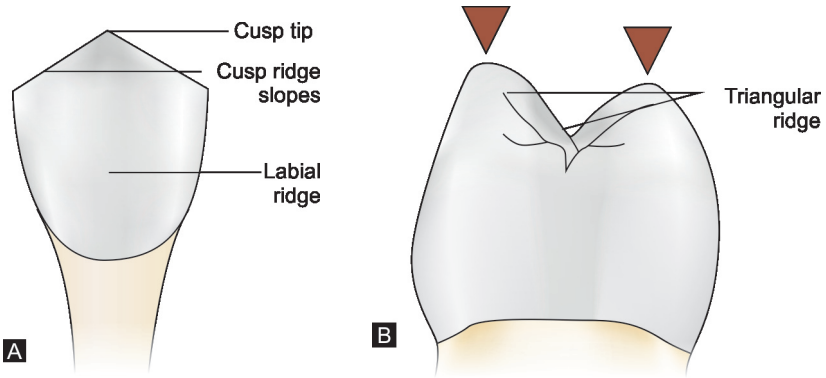


## TERMS USED IN THE DESCRIPTION OF MORPHOLOGY OF A TOOTH

### Cusp

Literally, a cusp is a sharp point or a cone at the tip seen in two or three dimensional structures respectively. A number of technical terms are derived and in use for this, giving a wide range of meaning in various fields. In dentistry, cusp is a ‘pointed’ or ‘rounded elevation’ on the crown of a tooth.

It is defined as “a functional elevation or a peak present on the chewing (incisal or occlusal) surface of the crown of a tooth, which divides the respective surface into many parts”. It is found on cuspids and on the chewing surfaces of bicusps and molars. Canine has ‘one’ cusp and premolars have ‘two’ cusps, so named as ‘cuspid’ and ‘bicusps’ respectively. Cusp has all histological components of a crown such as enamel, dentin and pulp.



**Figs 2.4A and B:** Facial and proximal view of tooth showing cusps

**Parts of a cusp:** Basically a pyramid/cone and has the following:

- Two cusp slopes or cusp ridge slopes: These are inclined surfaces that form an angle at the tip and are named as mesial and distal cusp slopes or cusp arms (Fig. 2.4A)
- One cusp tip (Fig. 2.4A)
- Labial/buccal/lingual ridge: Anyone for the respective cusp
- Triangular ridge only in occlusal surface of posteriors (Fig. 2.4B).

### Ridge

It is defined as ‘a linear elevation found on the surface of the crown of a tooth’ and named according to its location and/or form.

**Types of ridges:** Various types of ridges are seen in different teeth and are named accordingly on the surface in which they are situated.

- **Labial ridge:** It is the ridge seen on labial surface. It runs cervico-incisally almost in the center of labial surface (Fig. 2.5).

Example: Prominent labial ridge running from cusp tip to cervical area, on labial surface of canines

- **Buccal ridge:** It is the ridge seen on buccal surface. It runs cervico-occlusally approximately in the center of buccal surface.  
Example: Prominent buccal ridge noted on the buccal surface of premolars and molars mainly in permanent dentition.
- **Lingual ridge:** The ridge present on the lingual surface, which extends from the cingulum to the cusp tip in permanent canines and posteriors.

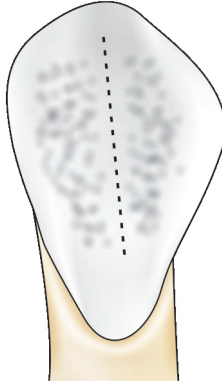


Fig. 2.5: Labial ridge in anterior tooth

- **Marginal ridge:** It is a linear, rounded border of enamel that forms the mesial and distal margins of the lingual and occlusal surfaces of anterior and posterior teeth respectively. There are two marginal ridges on each tooth seen at the mesial and distal ends respectively (Fig. 2.6). They are named as:
  - Mesial MR
  - Distal MR

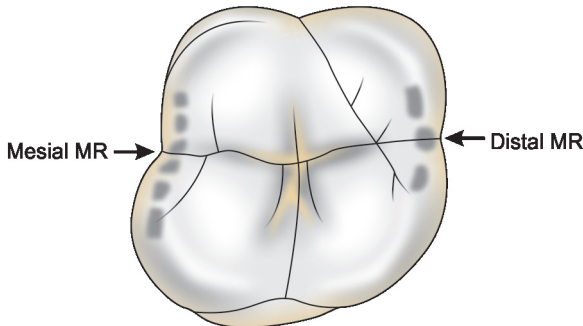


Fig. 2.6: Marginal ridge in posterior tooth

- **Triangular ridge:** Triangular ridge is present only on premolar and molars. It runs (descends/inclines) from cusp tip up to the center of the occlusal surface. It is designated so because two slopes of each side of the ridge meet to form a triangular ridge and resemble two sides of a triangle. Each triangular ridge is named according to the cusp from which it forms and located either on a facial or a lingual cusp (Fig. 2.7).

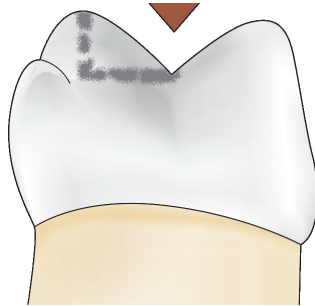


Fig. 2.7: Triangular ridge in posterior tooth

- **Transverse ridge:** This ridge is formed by union of buccal and lingual triangular ridges that crosses the surface of a posterior tooth in transverse (buccolingual) direction. These are roughly 90° to both the buccal and lingual tooth surfaces. Transverse ridges are present on the occlusal surface of premolars and permanent mandibular molars (Fig. 2.8).

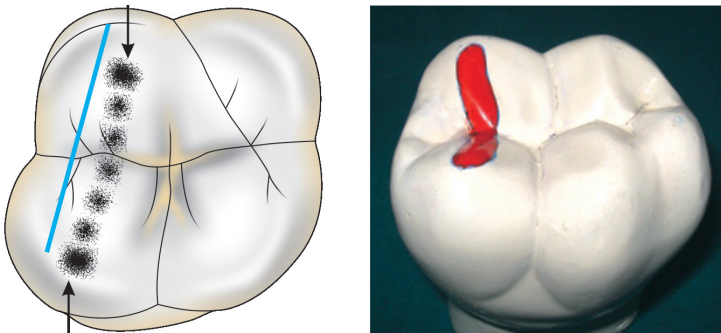


Fig. 2.8: Transverse ridge in posterior tooth

- **Oblique ridge:** It is formed by union of triangular ridges of the mesiopalatal and the distobuccal cusps, in oblique direction. Oblique ridges are present on the occlusal surface of maxillary deciduous second molar and all permanent maxillary molars (Fig. 2.9).

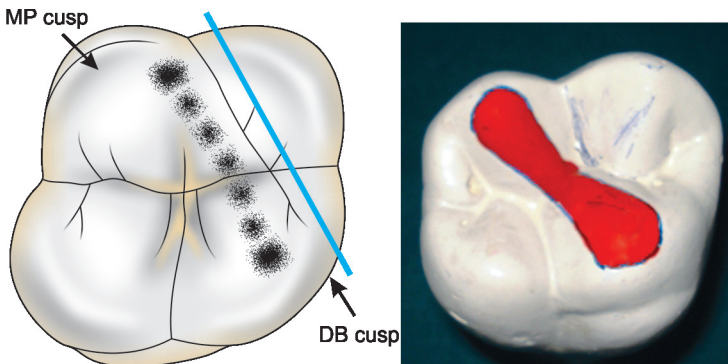


Fig. 2.9: Oblique ridge in maxillary permanent molar

- **Cervical ridge:** It runs mesiodistally at cervical 1/3rd buccal surface of the crown, present on all deciduous teeth and only on permanent molars.

### Cingulum

A cingulum is the convexity or a bulge or a lobe, found on the cervical 1/3rd of lingual aspect of anterior teeth. It is derived from a Latin word meaning ‘girdle’ or ‘belt’.

It is defined as ‘a girdle encircling the cervical 1/3rd of lingual surface of the crown of anterior teeth’. It makes up the bulk of the cervical part of the lingual surface of anteriors (Fig. 2.10).

It is prominent in permanent than in deciduous teeth and also in maxillary than mandibular teeth.

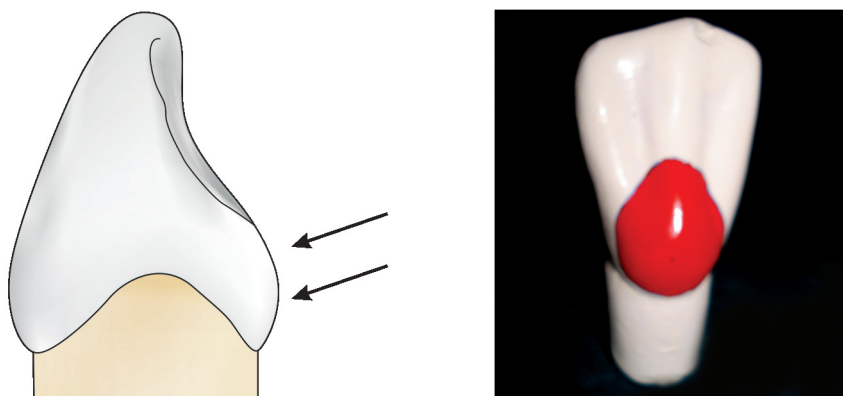


Fig. 2.10: Cingulum from proximal and lingual surfaces

### Tubercle

It is a small elevation present on the crown of a tooth due to extra formation of enamel. For example, tubercle of Carabelli present on the palatal aspect of mesiopalatal cusp of permanent maxillary first molar and maxillary deciduous 2nd molar. Tubercle of Carabelli is a small additional cusp, first described in 1842 by George Carabelli.

### Eminence

It is a prominence or projection of a bone or enamel on a tooth surface. Canine eminence is very prominent on the labial aspect of the root surface of permanent maxillary canine, which has a cosmetic value.

### Fossa

It is defined as a rounded or an irregular depression or concavity, present on a surface of the crown of a tooth (plural of fossa—‘fossae’).

#### Types of Fossa

- **Lingual fossa:** It is an Irregular, shallow depression found on the lingual surfaces of incisors and cuspids (anterior teeth) (Fig. 2.11)

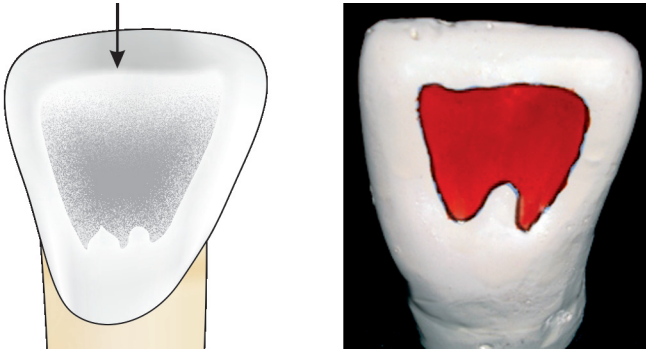


Fig. 2.11: Lingual fossa

- **Triangular fossa:** These are situated next to mesial and distal marginal ridges on the occlusal surfaces of posterior teeth. Two types of triangular fossa are mesial and distal triangular fossae (Fig. 2.12). Triangular fossae are considered as minor fossa

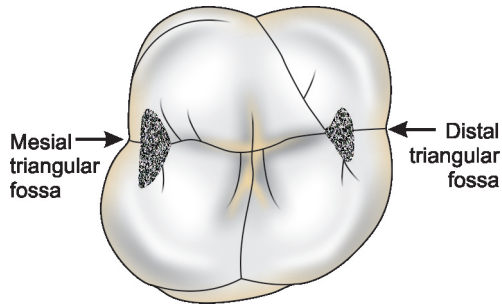


Fig. 2.12: Triangular fossa

- **Central fossa:** It is centrally located depression found on the occlusal surface of maxillary and mandibular molars. Other bicuspid have mesial and distal triangular fossa, but do not have a central fossa. Central fossa is considered as major fossa (Fig. 2.13).

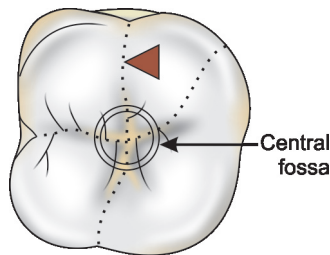


Fig. 2.13: Central fossa in posterior tooth

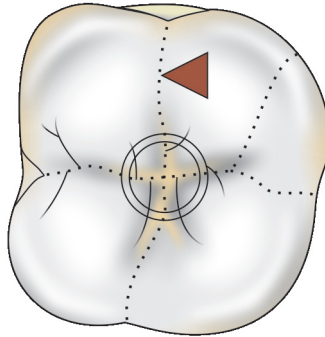
### Developmental Depression

It is a long, narrow, linear depression on the long axis of mesial and distal surfaces of the root of a tooth, formed during the development of the tooth.

### Developmental Groove

It is a short, shallow, line or depression between primary parts of the crown or root of a tooth formed during the development. Developmental grooves usually separate lobes or major parts of a tooth (Fig. 2.14).

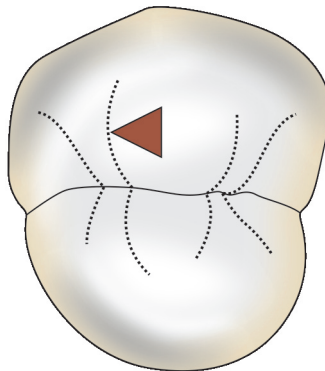
Example: Buccal and lingual/palatal developmental groove, mesial marginal ridge groove.



**Fig. 2.14:** Developmental grooves

### Supplemental Groove

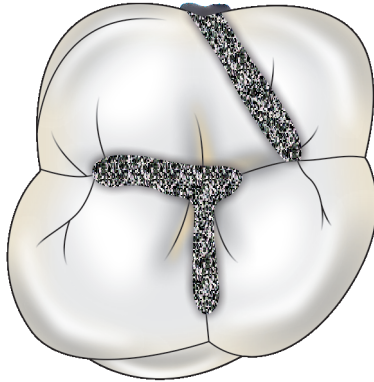
Supplemental grooves are numerous, less distinct, shallow, linear, depressions on the occlusal surface of teeth, which are supplemental to a developmental groove and do not represent the junction of primary parts of a tooth unlike the developmental groove. It is a minor, auxiliary groove that branches off from a prominent developmental groove and gives the occlusal surface a wrinkled appearance (Fig. 2.15).



**Fig. 2.15:** Supplemental grooves

## Sulcus

It is a long depression/valley on the surface of a tooth seen between ridges and cusps. Sulcus slopes/inclines towards the center and meet at an angle, which is mainly noted on the occlusal surface of posteriors (Fig. 2.16).



**Fig. 2.16:** Sulcus in molars

## Pit

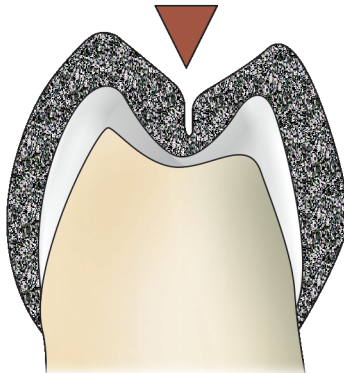
Pits are small, pin point depressions located at the junction or terminal part of developmental grooves. It is a small defect in the enamel of crown of the tooth, usually present at the junction of four formative lobes of a developing tooth.

Example: Buccal pit, lingual/palatal pit, central pits.

- Buccal pit is terminal part of buccal developmental groove
- Lingual pit is terminal part of lingual developmental groove.

## Fissure

It is a narrow channel/cleft, located at the depth of a developmental groove formed during development of a tooth (Fig. 2.17). This may rarely extend from developmental grooves inwards into the pulp.

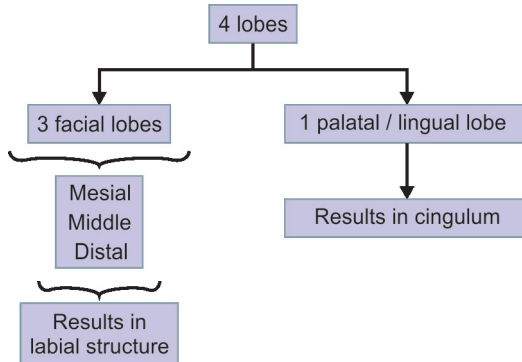


**Fig. 2.17:** Cross section of tooth showing the fissure

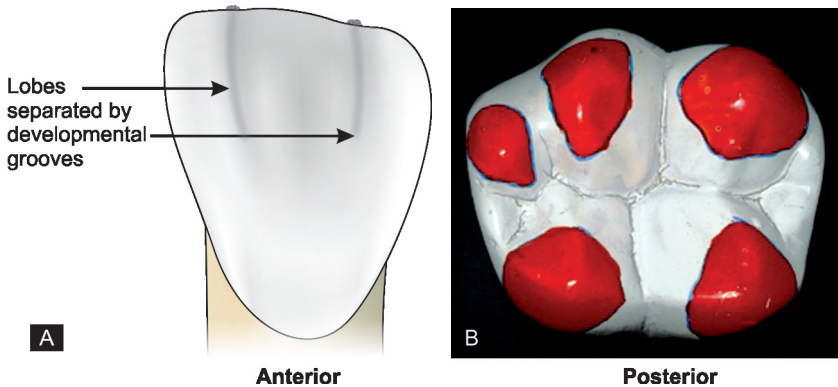
## Lobe

It is the center of formation in the development of the crown of a tooth. In simple words 'Lobe is one of the primary divisions of a crown' and is usually separated by developmental grooves. For development of any tooth minimum of 4 lobes are necessary.

In anterior teeth (Fig. 2.18A),



In posterior teeth, number of cusps is equal to number of lobes (Fig. 2.18B). Each lobe results in one cusp in all posterior teeth including deciduous teeth.

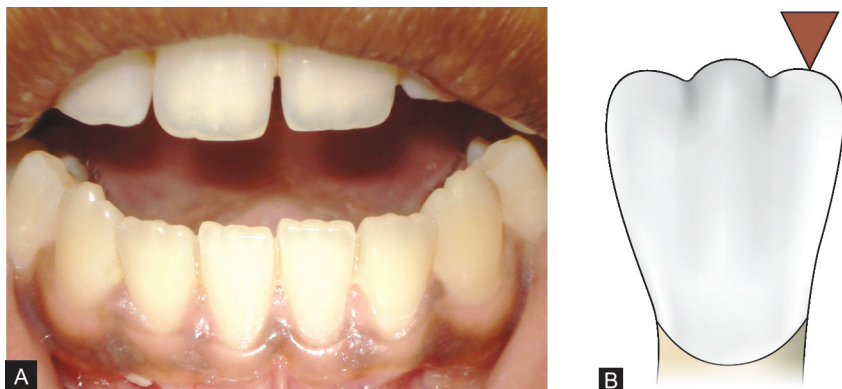


**Figs 2.18A and B:** Lobes in anterior and posterior teeth

## Mamelons

These are small rounded protuberances/projections of enamel found on the incisal edges of newly erupted incisors (Fig. 2.19A). Mamelons are found predominantly in permanent and also in maxillary than in mandibular incisors. These projections wear away soon after eruption due to masticatory forces. They are three in number which are mesial, middle and distal named according to the lobe. Mesial is the largest and middle is the smallest (Fig. 2.19B).





**Figs 2.19A and B:** Mamelons in newly erupted teeth

### Crest of Curvature

It is the greatest convexity or the bulge on the surface of a tooth.

### Contact Point

It is the crest of curvature on the proximal surface of the crown of a tooth where two adjacent teeth of the same arch are in contact for proper alignment in the jaw. Normally, it is pronounced as 'point' in anteriors as the contact is not wider as in case of posteriors.

### Contact Area

It is the crest of curvature on the proximal surface of the crown of a tooth where two adjacent teeth of the same arch are in contact for proper alignment in the jaw. Normally, it is pronounced as 'area' as the contact is broader in case of posterior teeth unlike anteriors where contact is point or a smaller area.

### Diastema

It is the space between two adjacent teeth that don't contact with each other which are supposed to be present normally.

### Interproximal Space

This is the triangular space seen between two adjacent teeth, cervical to the contact area.

### Embrassure

Embrassure is a potential 'V' shaped space that surrounds the contact areas and narrowed at contact area, widening towards facial, lingual and occlusal surfaces. There are different types of embrassures named according to the surfaces it is located. Embrassures are also termed as 'spillways', which help in escape of food during mastication and prevent food impaction (Fig. 2.20).

Types of embrassures are as follows:

- Labial/buccal embrassure termed as ‘facial embrassure’
- Lingual/palatal embrassure
- Occlusal/incisal
- Gingival embrassure.

Lingual/palatal embrassure is larger than others. This is because most teeth converge lingually.

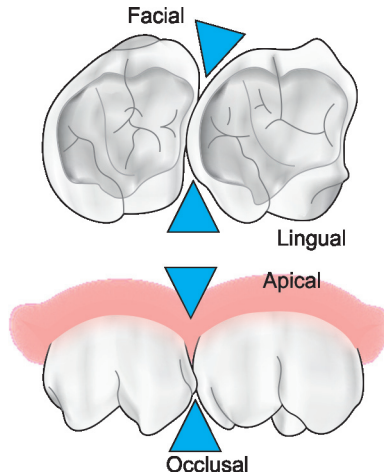


Fig. 2.20: Embrassures

### Interdental Papilla

It is the triangular pad of gingival tissue filled in the interproximal space between two adjacent teeth in the same arch (Fig. 2.21).

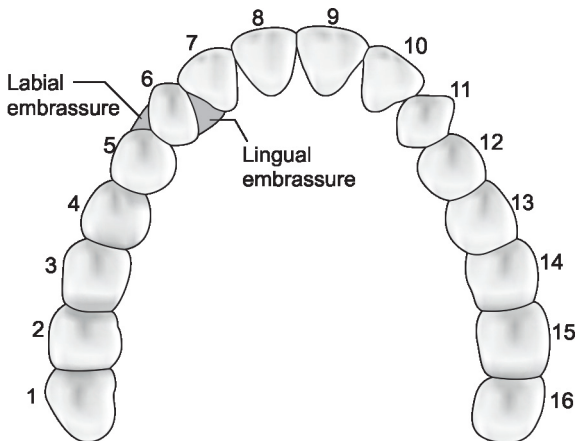


Fig. 2.21: Interdental papilla in interproximal space

## TOOTH FORM AND FUNCTION

The geometric configuration of all the crown surfaces of teeth can be categorized in one of three following types:

- Triangular
- Trapezoidal
- Rhomboidal.

From the facial (labial for anteriors and buccal for posteriors) and lingual aspects, all permanent teeth can be roughly described as trapezoidal. The incisal side forms the base of the trapezoid, while the cervical represents the shorter parallel side. Arrangement of these trapezoidal shaped crowns side by side in the dental arches creates interproximal spaces, as well as one contact area between each pair of adjacent teeth.

- **Anterior teeth:** In these teeth, the crowns of permanent anterior teeth from proximal surfaces display a triangular shape, with the base of the triangle meet at the cervical and the apex at the incisal. This shape helps in proper functioning of the anterior teeth. The apex at the incisal in the form of a wedge facilitates in tearing, biting and incising food. The wider base at the cervix provides the necessary strength for the crown form.
- **Maxillary posterior teeth:** The crowns of permanent maxillary posterior teeth have more or less trapezoidal in shape with the base at the cervical, and buccal and lingual sides constricting toward the occlusal. This shape also gives a wedge form and aids in the distribution of forces during mastication and aid in the self-cleaning process of the teeth.
- **Mandibular posterior teeth:** From the proximal aspect, the permanent mandibular posterior teeth are roughly rhomboidal, with the crowns inclined toward the lingual. This form and inclination allows for proper interlocking of the mandibular and maxillary posterior teeth during mastication.

### Trait

It is a distinguishing character or quality or peculiarity of a tooth or group of teeth or teeth of an arch or set of teeth and named accordingly as follows:

- **Type trait:** It is a distinguishing character or quality or peculiarity of a particular tooth in one group  
Example: Feature between permanent maxillary central and lateral incisor
- **Class trait:** It is a distinguishing character or quality or peculiarity of a class/ group of teeth, i.e. incisors, canines, premolars and molars.  
Example: Premolars have two cusps, hence called as bicuspid
- **Arch trait:** It is a distinguishing character or quality or peculiarity of teeth of maxillary or mandibular arch  
Example: All maxillary molars have oblique ridge on the occlusal aspect
- **Set trait:** It is a distinguishing character or quality or peculiarity of either deciduous or permanent dentition  
Example: In general, all permanent teeth are larger than deciduous teeth

### DIVISION OF TOOTH IN DIFFERENT DIRECTIONS

For descriptive purposes, the tooth can be divided into thirds in three different directions (Fig. 2.22):

- Cervicoincisal (anterior) or cervico-occlusal (posterior)
- Mesiodistal
- Labiolingual (anterior) or buccolingual (posterior).

When the surface of the crown and/or root portions are divided into ‘thirds’, they are named according to their locations. The crown of any tooth has one division as ‘middle third’, in common from all surfaces and directions. Other two thirds of the crown is named differently according to direction of the tooth division.

Cervicoincisally or cervico-occlusally, the crown of a tooth can be divided as incisal or occlusal third, middle third and cervical third. The root of a tooth can also be divided as cervical third, middle third and apical third. The division is done in horizontal direction as shown in following figures:

Mesiodistally, the crown of a tooth is divided as mesial third, middle third and distal third, in vertical direction.

Labiolingually or buccolingually, the crown of a tooth is divided as labial/buccal third, middle third and lingual third in vertical direction.

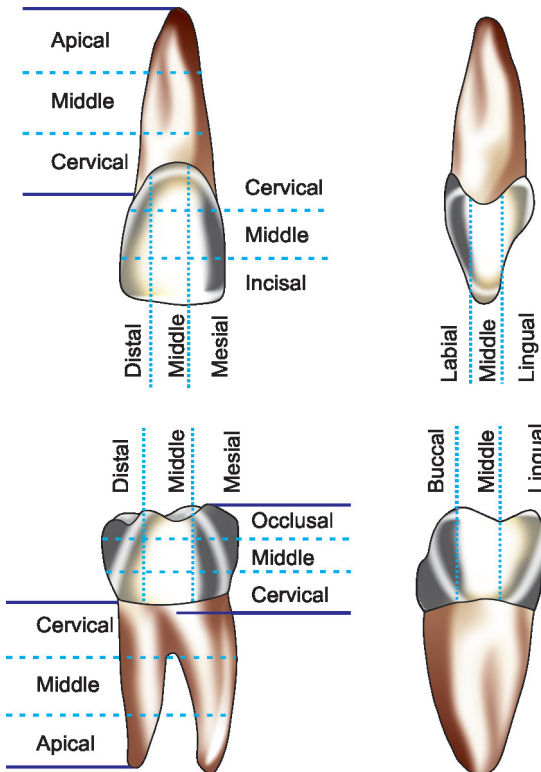


Fig. 2.22: Division of tooth into thirds from 3 different directions

## LINE AND POINT ANGLES OF DIFFERENT TEETH

### Line Angle

A line angle is formed when two surfaces meet each other and derives its name by the combination of both surfaces join.

Anterior teeth have six line angles such as follows (Table 2.1):

**Table 2.1:** List of line angles in anterior teeth

<i>Sl. No</i>	<i>Line angle formed</i>	<i>Surfaces involved</i>
1.	Mesiolabial	Mesial and labial
2.	Distolabial	Distal and labial
3.	Mesiolingual	Mesial and lingual
4.	Distolingual	Distal and lingual
5.	Labioincisal	Labial and incisal
6.	Linguoincisal	Lingual and incisal

The mesial and distal parts of incisal angles of anterior teeth are rounded, the respective line angles are considered as nonexistent. Posterior teeth have eight line angles such as follows (Table 2.2):

**Table 2.2:** List of line angles in posterior teeth

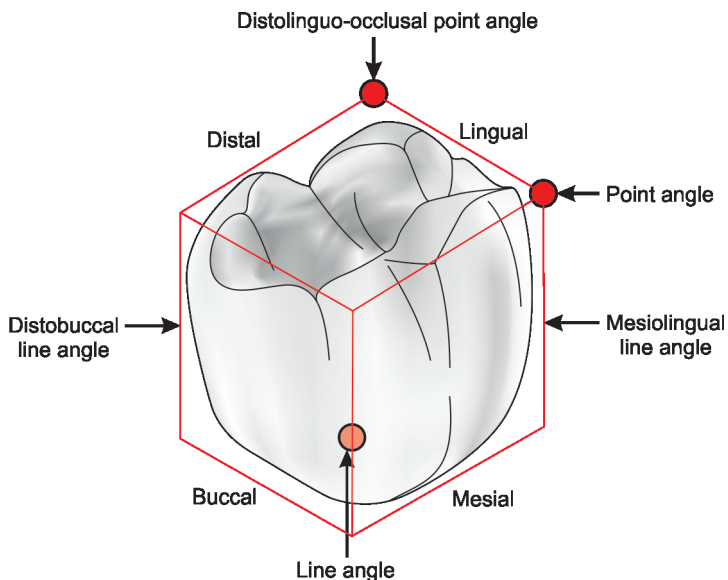
<i>Sl. No</i>	<i>Line angle formed</i>	<i>Surfaces involved</i>
1.	Mesiobuccal	Mesial and buccal
2.	Distobuccal	Distal and buccal
3.	Mesiolingual	Mesial and lingual
4.	Distolingual	Distal and lingual
5.	Mesio-occlusal	Mesial and occlusal
6.	Disto-occlusal	Distal and occlusal
7.	Bucco-occlusal	Buccal and occlusal
8.	Linguo-occlusal	Lingual and occlusal

### Point Angle

A point angle is formed at the junction of three surfaces where they meet each other and derives its name by the combination of all three surfaces join it. Anterior teeth have four point angles, which are as follows (Table 2.3):

**Table 2.3:** List of point angles in anterior teeth

<i>Sl. No</i>	<i>Point angle</i>	<i>Surfaces involved</i>
1.	Mesiolabio-incisal	Mesial, labial and incisal
2.	Distolabio-incisal	Distal, labial and incisal
3.	Mesiolinguo-incisal	Mesial, lingual and incisal
4.	Distolinguo-incisal	Distal, lingual and incisal



**Fig. 2.23:** Line angle and point angle

Even posterior teeth have four point angles which are (Fig. 2.23 and Table 2.4):

**Table 2.4:** List of point angles in posterior teeth

Sl. No	Point angle	Surfaces involved
1.	Mesiobucco-occlusal	Mesial, buccal and occlusal
2.	Distobucco-occlusal	Distal, buccal and occlusal
3.	Mesiolinguo-occlusal	Mesial, lingual and occlusal
4.	Distolinguo-occlusal	Distal, lingual and occlusal

# CHAPTER 3

## Tooth Numbering Systems

*Manjunatha BS*

Tooth numbering systems were devised originally as shortcut to reduce the labor of hand-written record keeping in dentistry. When identifying a specific tooth, dentists list the dentition, arch, quadrant and tooth name. There are several systems of naming and coding a tooth. It is necessary that the dental team (includes many persons) be familiar with a tooth numbering system so that a good communication is possible.

In this chapter, the most popular systems are described and their advantages, disadvantages are discussed.

Tooth numbering or tooth designation probably originated several centuries ago in Europe at the beginning of dental surgery era. Initially started in Latin language and mainly were employed in writings and speech.

By the mid 19th century, new dental symbolic and numeric systems were introduced to further refine and ease the task of writing and record maintenance. Keeping all these in mind, a tooth numbering system should fulfill the following criteria's:

- Simple to understand and to teach
- Easy to pronounce in conversation and dictation
- Readily communicable in print and reproduce
- Easy to translate into computer, typewriter and any other data processing systems commonly used
- Easily adaptable to standard charts in general practice.

There were about 40 different tooth numbering systems in use by 1988. Currently, only three most popular systems are favored worldwide. These popular systems are as follows:

- The Zsigmondy/Palmer (the eight-tooth quadrant) system
- The universal system
- The FDI/two digit system.

Also, other systems are briefly summarized.

### ZSIGMONDY/PALMER SYSTEM

The first advance towards today's modern tooth notation was published in 1861 by Viennese dentist **Adolf Zsigmondy**. Tooth numbering for permanent teeth is done starting with 1 for the central incisors and ending with 8 for the third molars. To indicate a single tooth located in a quadrant, a grid symbol (┘ └ ┐ ┑) is placed around the number. Surprisingly, an identical system to Zsigmondy was presented

in 1870 by Ohio dentist **Corydon Palmer** at the American Dental Association meeting. Both Zsigmondy and Palmer mentioned notation for the permanent teeth only.

Symbols of grid for primary teeth were added much later in 1947 by the Committee on Nomenclature of the American Dental Association (ADA). Roman letters I-to-V are used initially and now instead of Roman letters, English uppercase letters A-to-E are used (Fig. 3.1).

The palmer system of tooth numbering is still widely used in the USA by orthodontists and few general dentists.

This system is also referred to as the ‘eight-tooth quadrant’ or ‘symbolic’ system.

Many disadvantages such as the use of grid sign has the difficulty in adapting to standard typewriting or automated processing systems were noted with new inventions and modernization such as computerization of the data.

The palmer has advantages too such as analogues teeth can be compared from one side with the another or all quadrants and can be easily spelt as all ‘6’s or four ‘8’s easily.

**Modifications:** Many variants or modifications of Zsigmondy/Palmer system have been devised. In 1870, **Muhlreiter** combined abbreviations with numerals for tooth designation. Primary teeth are indicated by placement of a *d* immediately before the letter.

Most important among them is Haderup system designed by Danish dentist **Viktor Haderup** in 1887. In this system, a grid symbol around the number was omitted and ‘+’ and ‘-’ symbols are used beside the tooth number to designate the maxillary and mandibular teeth respectively. Left and right sides of the jaw are indicated by putting the sign before (for left side) or after (for right side) the number. Primary teeth were originally indicated by addition of a *l* immediately before the number; later *l* was replaced by a *0*. This system has been popular in Scandinavia.

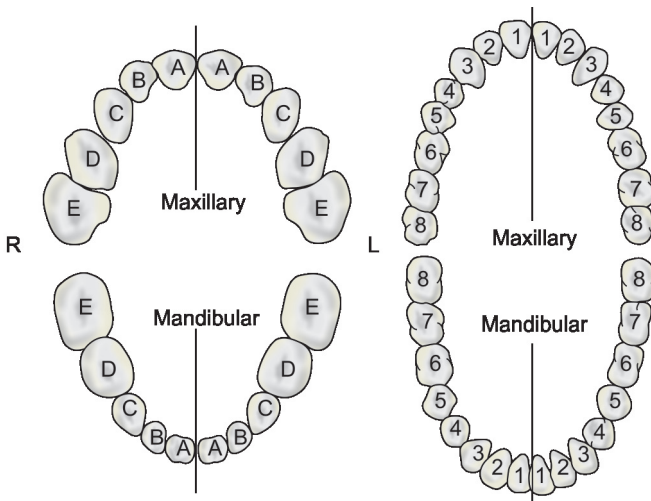


Fig. 3.1: Palmer system of tooth numbering



## UNIVERSAL SYSTEM

Today, the Universal system is the most widely used for 32 permanent teeth. This tooth numbering system was proposed by German dentist **Julius Parreidt** in 1882. The designation of word 'Universal' is uncertain. Though it is referred as 'Universal', is not universal at all and used only in the United States of America (USA) and parts of Canada.

In this system, the upper right third molar is designated as '1', moving clockwise sequence around the dentition and ending with the lower right third molar and as '32'. Originally, primary teeth were not included in this system, which were added in this century by alphabetical letters beginning from A-to-T clockwise similar to permanent teeth (Fig. 3.2).

The 'only' advantage of this system was to simplify the older systems, which were in use those days. In Contrast, many of them have had countless errors with this and seemed more artificial. Other advantage of this system is that, it relies only on counting sequence of Arabic numbers (1-to-32) or Roman letters (A-to-T), regardless of educational level for the benefit of semi-skilled clerks and other administrative personnel in Government services and other insurance agencies in USA. Hence, in 1984, American Dental Association (ADA) officially adopted this system and promoted the use by its members, all dental schools and agencies which process dental records.

**Modifications:** In 1967, **Goodman** proposed the use of numerals from '41' through '60', instead of A-to-T, as a modification to Universal system of tooth numbering for the primary teeth.

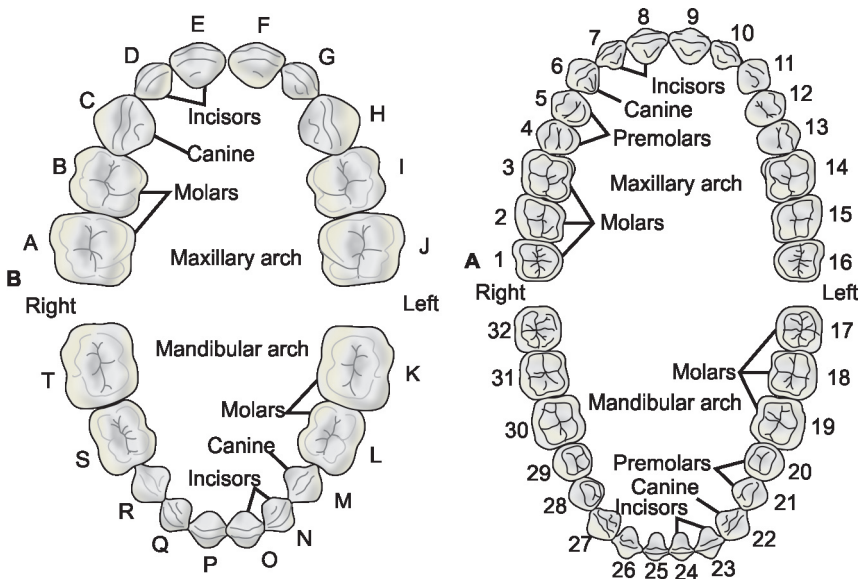


Fig. 3.2: Universal system of tooth numbering

## FDI/TWO DIGIT SYSTEM

This system is used and accepted around the world, but not in the USA. In 1968, the Federation Dentaire Internationale (FDI), the conference where it was first introduced came with a new tooth numbering system known as ‘FDI/two digit system’, it is also known as ISO-3950 notation (Fig. 3.3).

This system was originally developed by Berlin dentist **Dr Jochen Viohl** in 1966. In this two digit system, teeth are numbered from 18 to 48. The first digit indicates the quadrant (1-to-4, 1 for upper right quadrant and continues clockwise till lower right quadrant) and the second digit designates the tooth type (1-to-8, starting from the midline to third molar which is similar to Palmer system). Primary teeth are represented similarly as quadrant 5-to-8 and tooth type 1-to-5. This system is now accepted in most of the developed countries and by the World Health Organization (WHO) after its introduction in 1970. It has been recognized and used by international agencies, such as the International Standardization Organization (ISO) and Interpol.

The two digits of the FDI system should be pronounced separately, for example one-six (written as 16), not as sixteen. This makes simple and no confusion with other systems. This system represents a compromise between the principals of Zsigmondy/Palmer, Haderup and Universal systems.

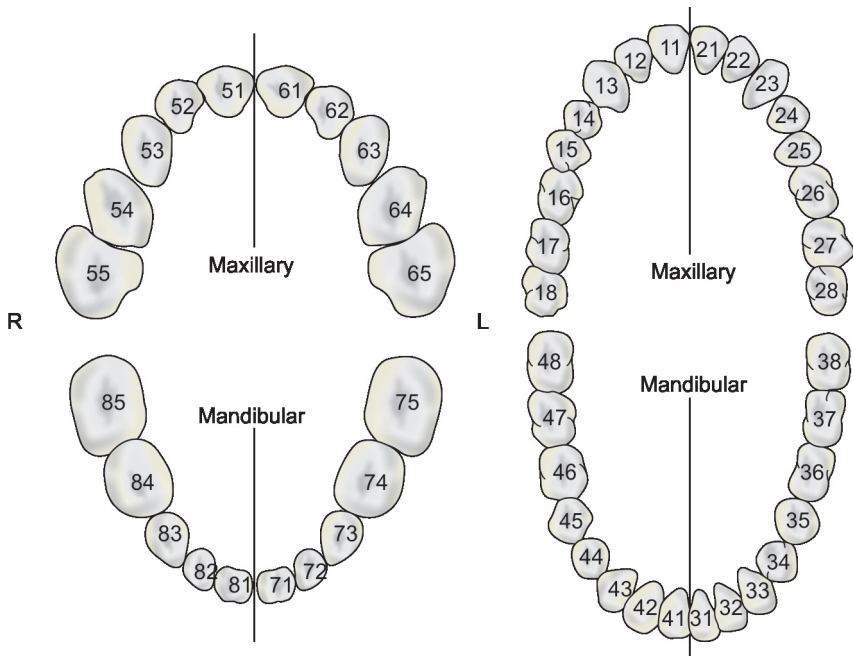
This system has advantages of other systems too:

- The Zsigmondy/Palmer system concept of assigning homologous teeth the same number
- The Universal system concept of moving from quadrant to quadrant in a clockwise direction, starting from upper right quadrant to lower right quadrant
- It works perfectly on a computer and is still far more meaningful than the Universal system.

**Modifications:** A slightly different version of two-digit system was also given by **Pirquet** in 1924 and **Denton** in 1963.

**Sharma and Wadhwa** in 1977, proposed a slight modification of the FDI/ two-digit system wherein a hyphen is used between the two digits in written records. Tooth *1-6* (one-six), for example, indicates the permanent maxillary right first molar, on the other hand, *16* (sixteen) in the Universal system refers to the permanent maxillary left third molar

This system also has an advantage of extending into a three-digit system for designating supernumerary teeth, which are very common in few ethnic groups and subpopulations. Thus, has an importance in anthropology and epidemiological dental surveys. This was suggested recently by **Krysinski** in 1986 and **Villa Vigil** et al in 1989.



**Fig. 3.3:** FDI system of tooth numbering

## CONCLUSION

Though, many tooth numbering systems have evolved over the years, “no internationally accepted single tooth numbering system is used worldwide in dentistry and related fields till today”. Few fields other than dentistry such as forensic odontology, anthropology, zoology often use different tooth numbering systems. Unfortunately, not much scientific data and studies regarding the user performance, advantages and difficulties of different tooth numbering systems are available.

However, the Zsigmondy/Palmer system is still used in some parts of the world and the Universal system in the USA.

The disadvantages of using different tooth numbering systems result in:

- Extractions of the wrong tooth
- Differences in record keeping make it extremely difficult to search dental records and identify disaster victims
- The differences among various disciplines and countries result in misinterpretations.

Hence, many authors, clinicians and researchers recommend FDI two-digit system because of its simplicity, accuracy, safety, applicability in modern technology.

## FURTHER READING

1. Ash, M M and Stanley J N. Wheeler’s dental anatomy, physiology, and occlusion. 8th edition, 2003.
2. Krysiniski Z. The three-digit system of designating supernumerary teeth. Quintessence Int. 1986;17:127-8.

3. Peck S, Peck L. A time for change of tooth numbering systems. *J Dent Educ.* 1993;57(8):643-7.
4. Sharma PS, Wadhwa P. Evaluation of the FDI two-digit system designating teeth. *Quintessence Int.* 1977;8:99-101.
5. Turp JC, Alt KW. Designating teeth: the advantages of the FDI's two-digit system. *Quintessence Int.* 1995;26(7):501-4.
6. Yurdukoru B. Standardization of the tooth numbering systems. *Ankara Univ Hekim Fak Derg.* 1989;16(3):527-31.

# CHAPTER 4

## Development of Occlusion

Manjunatha BS, Narayan Kulkarni, Rajashekhara BS

*He who sees things grow from the beginning will have the best view of them*  
—Aristotle

### INTRODUCTION

Normally, first evidence of tooth development appears during the sixth week of intrauterine life. Calcification of deciduous incisors begins at 3–4 months *in utero*. By the time of birth, calcification of all the deciduous teeth and all permanent first molars will be underway. An obvious omission is what happens before birth which is covered in oral histology and biology books. This chapter aims at the better understanding and the knowledge about the occlusion.

There is a broad range of variation in normal development and eruption of teeth, which is particularly noted in humans. The normal development of occlusion is similar in all populations. It is determined genetically and environmentally with great deal of variation individually as well. However, it is difficult to appraise and predict the normal eruption of deciduous and permanent teeth. Sometimes, eruption time and sequence of deciduous and permanent dentition are beyond the normal age range and control of the individual.

Development of dentition begins from the intrauterine life and continues till the adult life. The development of dentition is classified according to period at which the dentition development is taking place to establish an occlusion. The stages of development of dentition are as follows:

- Predentate period
- Deciduous dentition period
- Mixed dentition period
- Permanent dentition period.

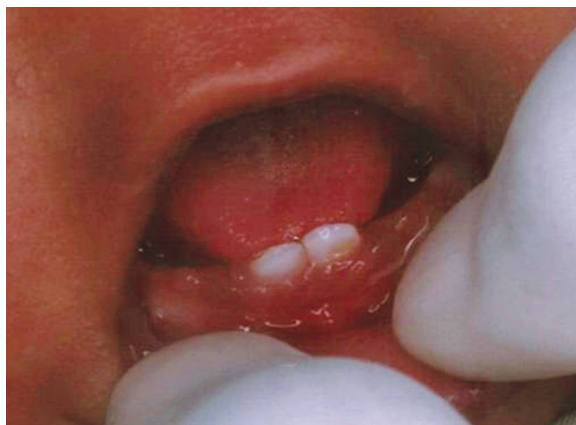### PREDENTATE PERIOD

As the name suggests, it is the period when no teeth are present in the oral cavity and are yet to come out of the jaws from the developmental position within the bony sockets. During this period, the development of dentition starts from birth till the emergence of the first deciduous teeth that takes place in the oral cavity which is ideally at the age range of 6 months.

Clinically, the infant has no teeth in the oral cavity (edentulous jaws). During this time, the alveolar arches of the upper and lower jaws of the infant are called as ‘**gum-pads**’.

Gum-pads are significantly or highly thickened oral mucosa, which soon becomes segmented giving rise to the site for development of a tooth in five different locations on either side (quadrants) of both maxillary and mandibular arches. These localized thickenings are well-demarcated by a groove, termed as 'transverse groove' which separates the gum-pads into 10 segments. The groove between canine and first molar is known as lateral sulcus.

As the infant becomes older, both jaws undergo rapid growth in all three planes of face, in downward, forward, and lateral directions. Occasionally, there is presence of teeth at birth or within a week after birth and these teeth are termed as '**Natal teeth**'. If these teeth are seen at about a month's time after the birth, they are termed as '**Neonatal teeth**' (Fig. 4.1). These teeth are considered as supernumerary or precocious and are often lost in a short span of time. The rate of incidence of such teeth is estimated to be in the ratio of 1:30000 and such teeth are predominantly observed in the anterior segment of mandibular arch. Complications such as ulceration of ventral part of tip of the tongue and labial mucosa of the lower lip may be seen in these types of teeth. This condition is termed as '**Riga-Fede disease**'. Presence of natal and neonatal teeth may cause difficulty in breast feeding in mother and infants too. Radiographic confirmation for the presence of normal deciduous teeth in the same area should be done prior to the extraction of these natal and neonatal teeth.



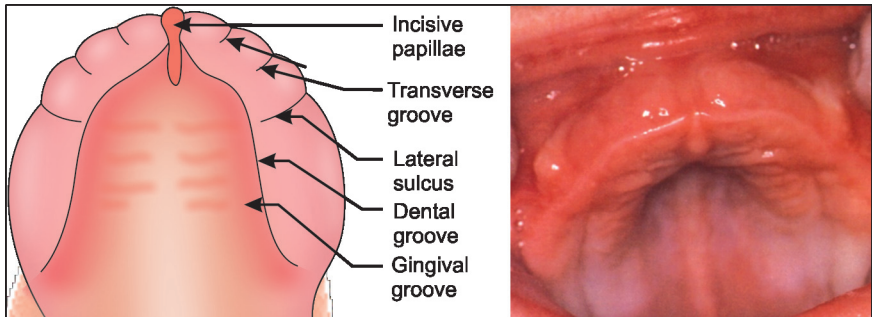
**Fig. 4.1:** Neonatal teeth

The gum-pads normally develop into 2 parts:

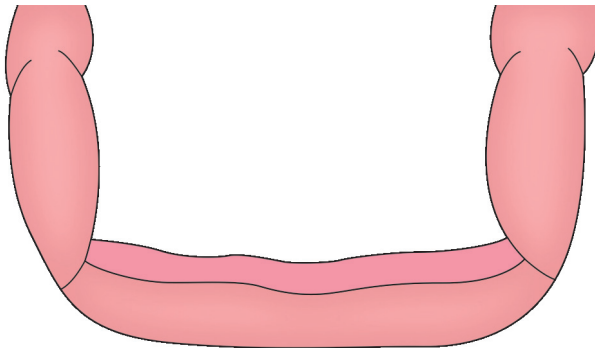
1. **Labial part:** Differentiates first to form deciduous teeth.
2. **Lingual part:** Differentiates later to form permanent teeth in anterior region.

**Maxillary gum-pad:** The maxillary gum-pad is horse-shoe shaped (Fig. 4.2). The gingival groove differentiates the maxillary gum-pad from the palate. This later divides into 5 parts with the formation of sulcus/sulci.

- The dental groove originates in incisive papilla region and extends backward to touch the gingival groove in the canine region and laterally extend to end in the molar region
- Lateral sulcus is a deepened groove separating the canine and deciduous first molar segments.



**Fig. 4.2:** Occlusal view of maxillary gum-pads



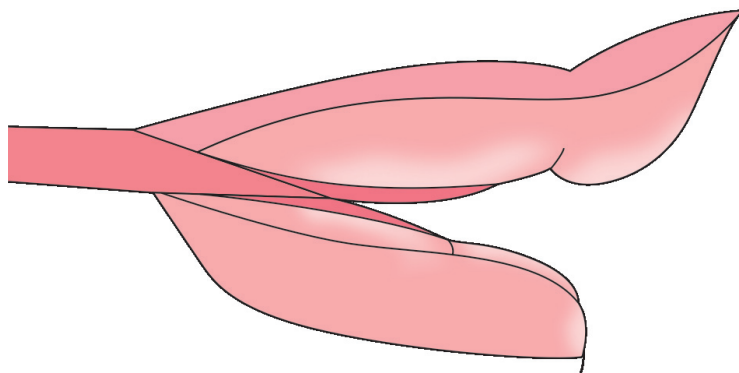
**Fig. 4.3:** Occlusal view of mandibular gum-pads

Mandibular gum pad differs for maxillary counterpart and has the following characteristics (Fig. 4.3):

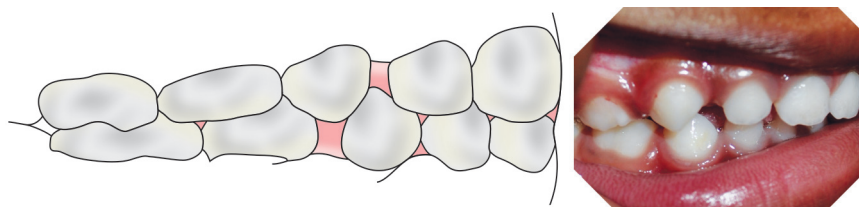
- It is 'U' shaped with its anterior portion everted labially
- It also shows the gingival groove that demarcates the lingual extent of the gum-pad
- Dental groove running from the mandible backwards laterally to join the gingival groove in the canine region
- Lateral sulcus—a deepened groove separating the canine and deciduous first molar segment.

**Spatial relation of gum-pads:**

- Gum-pad relation is arbitrary
- Upper lip is short
- Anterior open bite is noticed and contact is seen only in the posterior molar region at rest (Figs 4.4 and 4.5). Tongue protrudes anteriorly through this space, facilitating suckling in infants and is a self-correcting malocclusion
- Maxillary gum-pad is wider than the mandibular gum-pad
- Class II pattern anteroposteriorly is noted
- Length of the gum-pad increases posteriorly to incorporate molars which are wider mesiodistally
- During this period, the transverse growth is observed to be the highest



**Fig. 4.4:** Lateral view of upper and lower gum-pads



**Fig. 4.5:** Lateral view of primate space

- In this stage, usually lateral movements of jaw are restricted as the TMJ is not completely developed.

## DECIDUOUS DENTITION

As we all know that humans are diphyodont, first set of dentition observed in humans is known as deciduous dentition. It starts from the eruption of first deciduous teeth (6 months) and ends at the stage when anyone permanent tooth erupts in the oral cavity usually in the range of (6 years).

Commonly observed features:

- Both the arches are half round in shape
- Almost no curve of spee is present
- Shallow cuspal interdigitations
- Slight overjet and overbite
- Vertical inclination of the incisors
- Little or no crowding
- Different maxillomandibular molar relation.

It is generally observed that primary spacing occurs around 70% in maxilla and 63% in mandible. Primary interdental spacing was first noticed by **Delabarre** in 1918. **Baume**, in 1950, divided the deciduous dentition into spaced and non spaced dentition.



## Spaced Dentition

Deciduous dentition many times show spacing between adjacent teeth in both arches. These spaces are of two types:

1. Primate spaces.
2. Physiologic/developmental spaces.
  - **Primate spaces:** These are natural spaces which are present in both upper and lower arch. In upper arch the space is in between deciduous lateral incisors and canines (**upper mesial to canine and lower distal to canine**). In Lower arch space is present between deciduous canine and first deciduous molars. These spaces are also called as ‘anthropoid’ or ‘simian’ spaces.
  - **Physiologic/developmental spaces:** They are present in between the primary teeth and play an important role in the normal development of occlusion in permanent dentition. In maxilla space may vary from 0–8 mm with an average of 4 mm. In mandible, it may vary from 1–7 mm with an average of 3 mm.

## Non Spaced Dentition

Here primary teeth are present without any spacing in the arches. Lack of space may be due to narrowness of the arches or larger sized teeth. This type of dentition usually indicates occurrence of crowding in the future permanent dentition. However, many authors like Goldberg et al suggested this to be a hereditary phenomenon.

## Occlusal Relationship

- **Overbite:** It is vertical distance which the maxillary incisal edge overlaps vertically past the incisal edge of the mandibular teeth (Fig. 4.6). Moorrees observed that deep bite is commonly observed in the initial stages and as posteriors erupt, deep bite gets corrected. Normal range of overbite is in the range of 2–4 mm
- **Edge to edge bite:** It is also called as zero overbite. Most commonly occurs due to attrition of deciduous teeth due to lack of proper intercuspation of deciduous teeth. Zero overbite can also be due to downward and forward growth of mandible
- **Overjet:** Horizontal distance between maxillary lingual and mandibular labial surface of incisor teeth (Fig. 4.6). Normal range of overjet commonly observed was 2–4 mm. Most oftenly at the age of 2 years the overjet observed would be 4 and with a steady decrease of overjet till the age of 5 years. If attrition is observed in deciduous molars and canines in lower arch then the whole mandibular arch might be shifted anteriorly assuming edge to edge bite by the age of 6 years
- **Canine relationship:** Maxillamandibular canine relation is supposed to be one of the most stable relationship observed in deciduous dentition as observed by Baumes
  - Class I:** Mandibular canine interdigitates in between the embrasure present in maxillary lateral incisor and canine
  - Class II:** Mandibular canine interdigitates distal to the embrasure present in maxillary lateral incisor and canine
  - Class III:** Mandibular canine interdigitates in any other relation
- **Arch dimensions:** Changes in the arch dimensions take place three dimensionally. The transverse has a major impact. Here the dimensions of the

maxillary and mandibular arch are evaluated in the form of arch form, arch length and circumference (Figs 4.7 and 4.8)

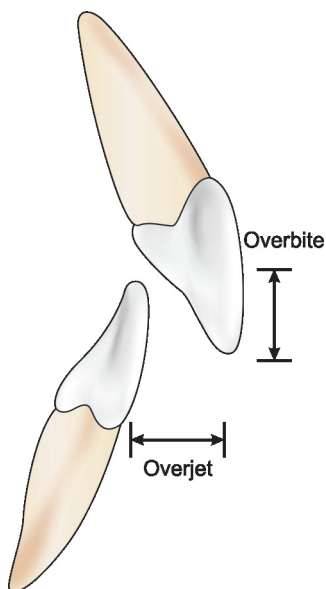
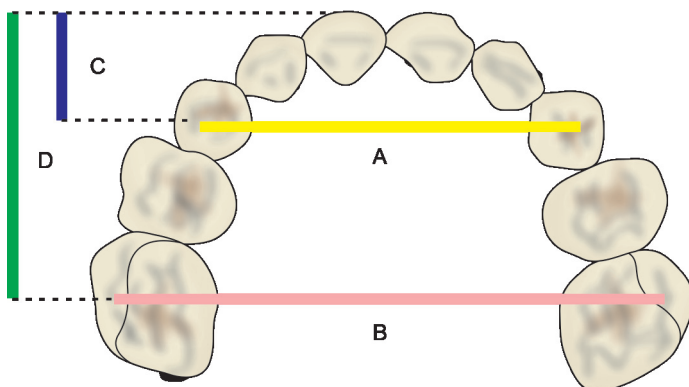


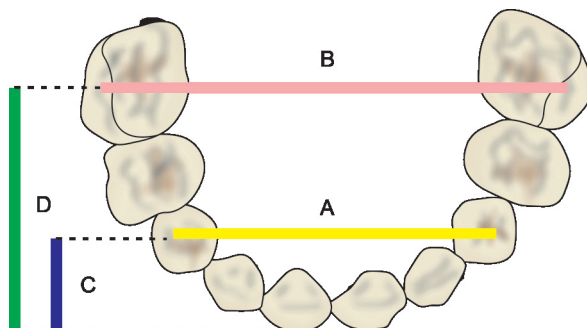
Fig. 4.6: Overjet and overbite



Figs 4.7A to D: (A) Intercanine width; (B) Intermolar width; (C) Anterior arch length; (D) Total arch length in upper arch

- **Arch form:** In maxilla it is usually ovoid in shape. Transverse width increases more in the canine area when compared to molar region. Here the expansion is achieved predominantly by skeletal growth. An increase in total intercanine width by 6 mm is observed between a span of 10 years at the age of 3–13 years (Fig. 4.7A).
- **Arch length and circumference:** Small amount of decrease in arch length and circumference is observed (Figs 4.7B and 4.7C). It could be attributed due to mesial migration of second primary molars during eruption and proximal caries.

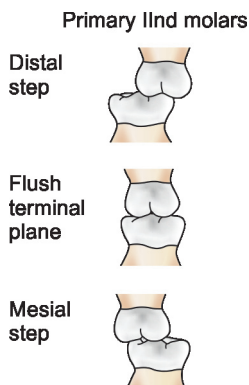
- **In mandible:** The arch form is ovoid shape and an increased intercanine width by 3.7 mm between 3–13 years is observed (Fig. 4.8A). This is less in comparison to maxillary arch wherein the size of teeth plays a role for its compensation.



**Figs 4.8A to D:** (A) Intercanine width; (B) Intermolar width; (C) Anterior arch length; (D) Total arch length in lower arch

- *Molar relations (Fig. 4.9)*

- **Flush terminal plane:** The lower second molar is wider mesiodistally than maxillary second molar. The distal surfaces of upper and the lower second molars are in one plane. Favorable for the eruption of the first permanent molars into a normal relation.
- **Mesial step:** Distal surface of mandibular second molar moves more mesial to maxillary second deciduous molar. It could be attributed due to eating habit, attrition of deciduous teeth and growing mandible. Favorable for the eruption of the first permanent molars into a normal relation or sometimes it may even lead to class III molar relation which is also termed mesio-occlusion in permanent dentition.
- **Distal step:** Distal surface of mandibular second deciduous molar is more distal to upper second deciduous molar. It could be attributed to sucking habits. Usually, it is prognostically unfavorable. It might lead to class II molar relation for the first permanent molar relation. This type of relation in permanent dentition can be termed as disto-occlusion.



**Fig. 4.9:** Molar relation in deciduous dentition

### Self-correcting Anomalies of Deciduous Dentition

- **Anterior deep bite:** This is one type of manifestation observed in the deciduous dentition (Fig. 4.10). It could be observed because the deciduous incisors are more upright in comparison to their permanent counterparts
  - **Correction:** It is achieved by forward and downward growth of mandible. Eruption of permanent molars would make the mandible rotate clockwise and would also lead to some amount of minor correction of deep bite

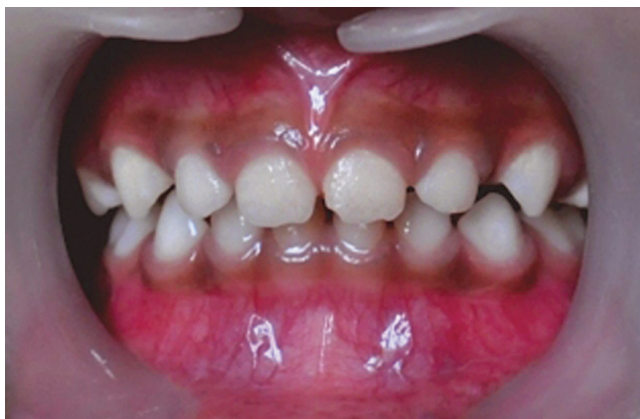

Fig. 4.10: Labial view of anterior deep bite in deciduous dentition

- **Primate spaces:** If primates present, it should not be misinterpreted as spacing this is corrected by early mesial shift of permanent molars automatically (Fig. 4.11).

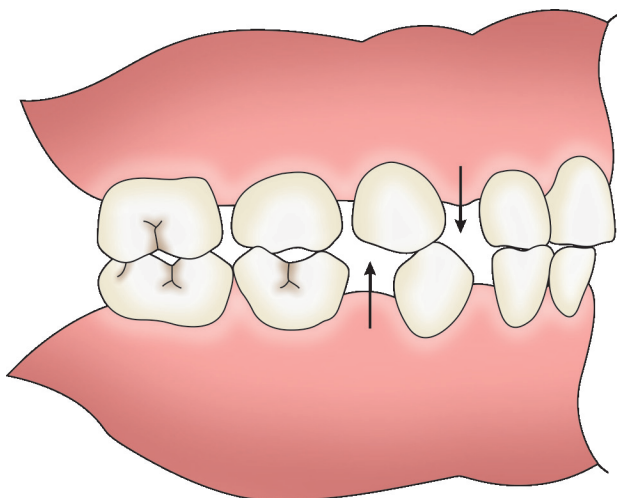


Fig. 4.11: Lateral view of occlusion showing primate spaces

- **Flush terminal plane:** This gets corrected with the help of mesial shift of permanent molar. In early mesial shift, primates space gets utilized. In late mesial shift, leeway space of Nance is utilized.

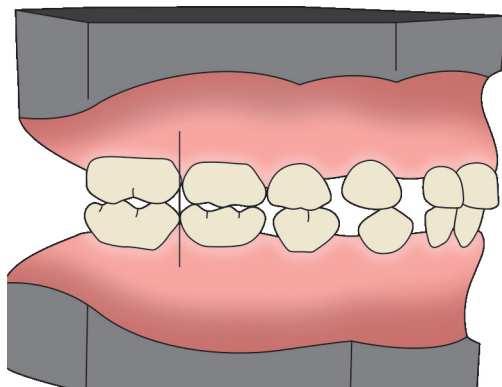


Fig. 4.12: Physiologic spaces in upper and lower arches

- **Physiologic spaces:** The permanent teeth are larger mesiodistally and require more space. In such conditions, the physiologic space gets utilized for permanent incisor accommodation (Fig. 4.12).

### MIXED DENTITION

The period during which both primary and permanent teeth are present in the mouth together. This period starts from age 6 years and continues till 12 years or onset of puberty.

Those permanent teeth that follow into place in the arch once held by primary teeth are called '**successional teeth**'—Incisors, cuspids and bicuspid. Those permanent teeth that erupt posteriorly to the primary teeth are termed as '**accessional teeth**'. The moment first permanent molar erupts the associated deep bite gets relieved, hence, also termed as natural bite openers.

There are two very important aspects of mixed dentition stage:

1. The utilization of arch perimeter.
2. The adaptive change in occlusion that occurs during the transition from one dentition to another.

### Arch Dimension Changes

- **Arch width:** As there is little skeletal width increase during the period of mixed dentition. Width dimensional increase involves predominantly the alveolar process. Maxillary alveolar processes diverge while the mandibular alveolar processes are more parallel. So maxillary arch width increase is much greater and can be easily altered during treatment. Maxillary first premolar width increases significantly more than does in mandibular. The intercanine diameter increases only slightly in mandible due to distal tipping of the primary cuspids into the primate spaces. Since the mandibular incisors are not normally moved labially through time.
- **Arch length:** Dental arch length is measured at the midline from a point midway between center incisor to a tangent touching the distal surfaces of second primary molars or second premolars. Scientific evidence suggests that the posterior teeth

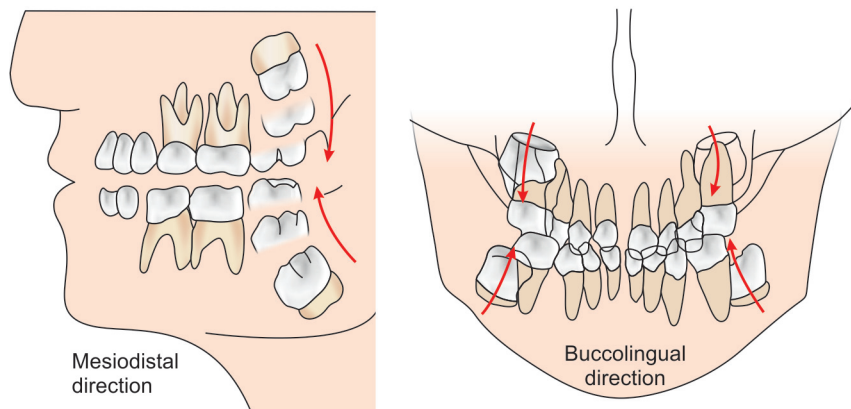
move forward throughout life. This would reduce arch length. **Moorees** has established that arch length decreases 2 to 3 mm between 10 to 12 years of age, when the primary molars are being replaced by permanent molars.

**First transitional period:** It is characterized by eruption of first permanent molars and mandibular central incisor (Figs 4.13 and 4.14). Usually, the mandibular molar precedes the maxillary molar.

- **Emergence of first permanent molars:** The anteroposterior relation between the two opposing first molars depends on:
  - Sagittal relation between maxilla and mandible
  - Their position previously occupied in the jaw
  - Occlusal relationship is established by cone (upper palatal cusp) and funnel (lower occlusal fossa) mechanism.

**Note:** Here the position of permanent mandibular first molar is dependent on the relation of second deciduous molars.

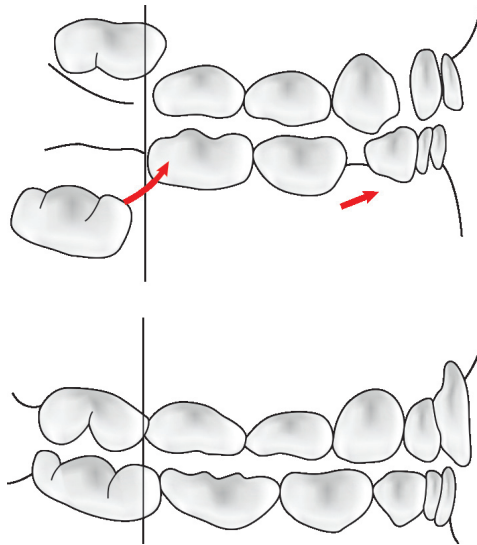
- **Mandibular first permanent molar:** Guided into its occlusal position by distal surface of mandibular second primary molar. The direction of eruption is mesial and lingual for permanent molar teeth
- **Maxillary first permanent molar:** Forward direction of maxillary growth provides space posteriorly. The direction of eruption is distal and buccal for permanent molar. The direction of both maxillary and mandibular first molar is exactly opposite, which helps in achieving class I molar relation and proper interdigitation.



**Fig. 4.13:** First permanent molar eruptive direction and first transitional occlusion

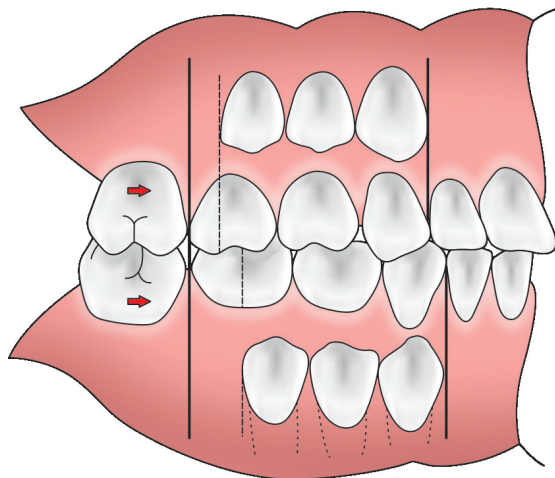
If the second deciduous molars (maxillary and mandibular) are in flush terminal plane then the erupting permanent molars will be in the same relation having a cusp to cusp relation. Change of this permanent molar relation into Class I can be accomplished by moving lower permanent molar mesially by 2–3 mm. This can be accomplished as follows:

- **Early mesial shift:** Here molar relation correction is achieved by utilization of primate space. Occurs mainly due to mesial eruptive force of permanent molars.



**Fig. 4.14:** Correction of molar relation by early mesial shift

- **Late mesial shift:** Many children lack primate spaces, in such cases leeway space was utilized for correction of molar relation after the exfoliation of deciduous molars. This shift occurs after sometime following the eruption of permanent molar (Fig. 4.15).



**Fig. 4.15:** Late mesial shift

- **Mesial step in deciduous molars:** If mesial step is observed it usually leads to Class I permanent molar relation. If mandibular growth exceeds beyond its normal limit then it will lead to Class III permanent molar relation (Fig. 4.16).
- **Distal step in deciduous molars:** If distal step is observed it usually leads to Class II permanent molar relation (Fig. 4.16).

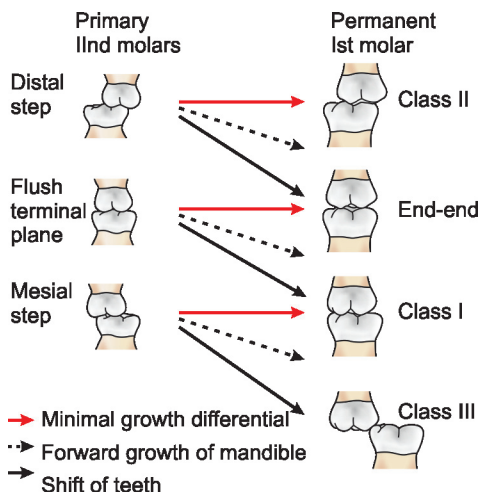


Fig. 4.16: Molar relationship establishment from deciduous to permanent dentition

**Factors affecting first molar eruption**

- Congenital absence of tooth itself
- Congenital absence of premolars
- Distal caries of deciduous second molar
- Early loss of deciduous second molar
- Developmental disturbances.
- **Leeway space:** It was first noted by Nance in 1936 hence also termed as **leeway space of Nance**. The combined mesiodistal width of deciduous canine, first molar and second molar is greater than that of permanent canine and 2 premolars. This difference between the combined mesiodistal width of the primary canine, first molar, second molar and their permanent successors canine and 2 premolars is known as leeway space of Nance (Fig. 4.17). In maxillary arch, it is 1.5 mm per side and in mandibular arch it is 2.5 mm per side.

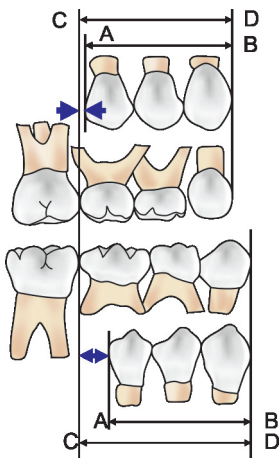
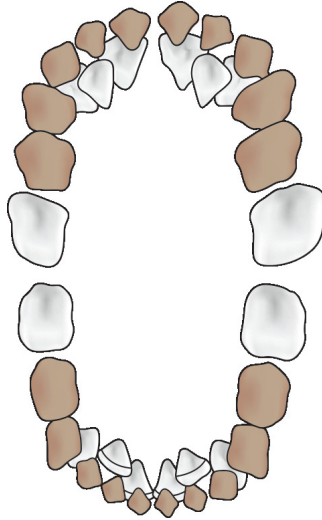


Fig. 4.17: Leeway space of Nance



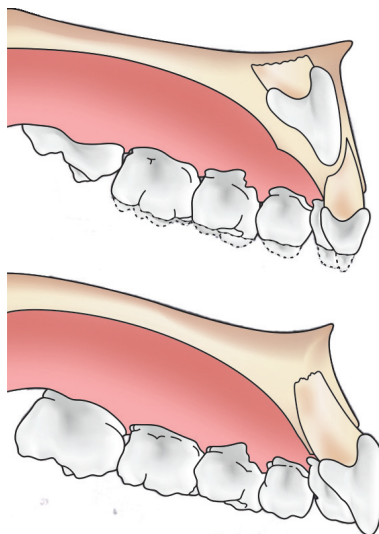
**Exchange of deciduous incisors with permanent incisors:**

- **Mandible:** Permanent central incisors usually follow mandibular first molars they erupt soon after the permanent molar erupts. They erupt labially to their normal balanced position between tongue, lip and the facial musculature. This labial eruption helps in accommodation of larger permanent incisors (Fig. 4.18).



**Fig. 4.18:** Accommodation of larger permanent teeth

- **Maxilla:** Usually follows mandibular central incisor or erupt concurrently with mandibular lateral incisors (Fig. 4.19). Here also more labial eruption of permanent incisors than primary incisors is observed. Lateral incisors erupt more labially than centrals.



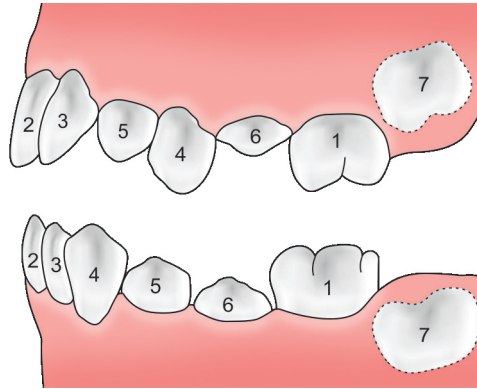
**Fig. 4.19:** Correction of incisal liability

- **Incisor liability:** Permanent incisors are larger than deciduous incisors. The difference between the amount of space needed for the permanent incisors and the amount of space available for them is known as incisal liability. It is about 6–7 mm in both the arches. More commonly a transitory stage of mandibular incisor crowding at age 8–9 years is observed, it is usually a normal developmental feature
- **Incisor liability adjustment:** Adjustment takes place by following mechanisms. Inter canine arch width increases with the help of growth, which provides space up to 3 to 4 mm (2 mm average). Interdental (Developmental) spacing observed in deciduous dentition reduces 2 to 3 mm of incisor liability (Fig. 4.20). More anterior and labial position of permanent incisors as they erupt which is 1 to 2 mm labially

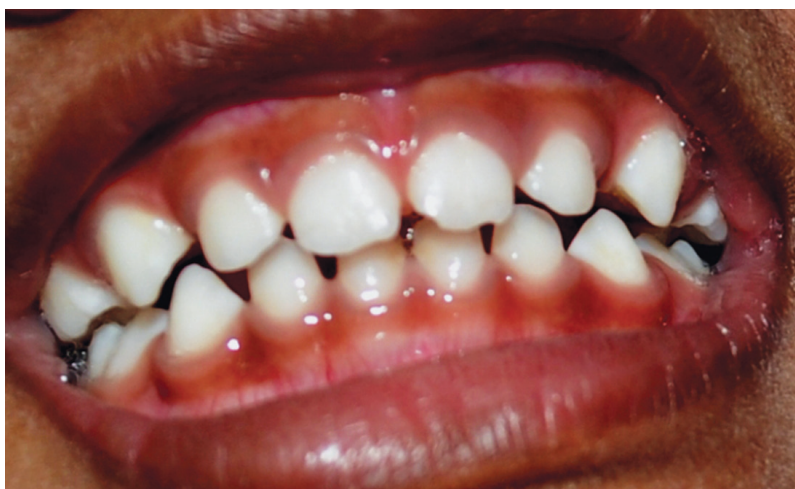

Fig. 4.20: Interdental spacing in deciduous dentition

- **Intertransitional period:** This period is present between the first and second transitional period. This is considered to be a stable phase. In this stage, permanent first molars and incisors, deciduous canines and deciduous first and second molars are present in both maxillary and mandibular arch
- **Second transitional period:** There are not much changes taking place in this period. The emergence of bicuspid is the hallmark indicating start of this period cuspids, second molars eruption also takes place in this period concurrently. Establishment of occlusion takes place
- **Mandible:** Most favorable and the most common eruption sequence (Fig. 4.21) is 6-1-2-3-4-5-7. Eruption of cuspids takes place first which helps in maintenance of arch perimeter and prevention of lingual tipping of incisors. If tooth size-space available ratio is poor, the cuspid may be delayed in its eruption by the first molar or the primary molar may be hastened in its exfoliation.



**Fig. 4.21:** Eruption of premolar and eruption sequence

- **Eruption of first bicuspids:** We usually find rarely any difficulty and sometimes show rotation due to uneven resorption of primary molar roots.
- **Eruption of second bicuspids:** Last lower succedaneous teeth to erupt. Extreme variation in calcification and development schedule is observed. It is supposed to be often congenitally missing. Complications in eruption of second *bicuspids* are observed when:
  - Mesial migration of first molar takes place
  - Poor tooth size-space available ratio
  - Premature exfoliation of second primary molar.

**Note:** First molar must not be allowed to move mesially until the second bicuspid has attained its proper position in the arch.

- **Maxilla:** The most preferable sequence of eruption 6-1-2-4-5-3-7 or 6-1-2-4-3-5-7.
  - **First bicuspid:** Minimal difficulty in eruption. The size of this tooth is nearly the same size as its predecessor.
  - **Second bicuspid:** This tooth has easy eruption as its predecessor, the primary second molar has larger mesiodistal width and this permits easy eruption to its place in the arch (Fig. 4.21).
- **Cuspid:** Favorable sequence of eruption would be before eruption of second permanent molar. This tooth uses leeway space for accommodation in the arch. In case of short arch length, canine would erupt labially (with a decided mesial inclination.)

Canines are one of the most commonly impacted teeth. One of the reasons could be difficult and tortuous path of eruption than any other tooth.

Other reasons for canine impactions could be:

- High initial position in the crypt
- Deviated path of eruption
- Lack of guidance from maxillary lateral incisor
- Lack of space
- Congenital absence of lateral incisors
- Presence of supernumerary teeth.

- **Permanent second molars:** This is the last teeth to erupt before third molars. In mandible, if eruption of permanent second molar precedes second bicuspid, then the first molar may tip mesially. Eruption of permanent second molar precedes typically before maxillary second molar (Fig. 4.22). In maxilla, if eruption of maxillary second molar is ahead of the mandibular second molars, it is said to be symptomatic of a developing class II malocclusion.

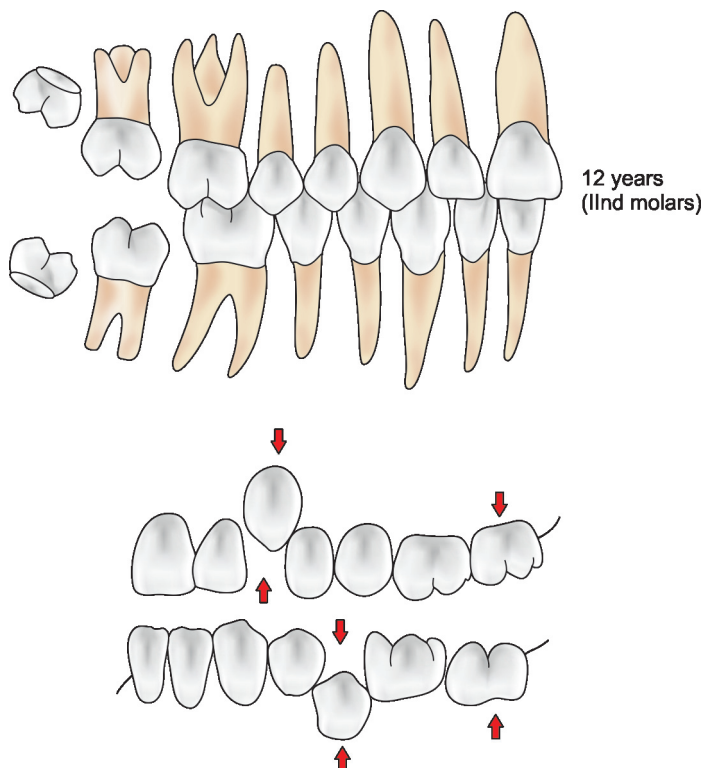
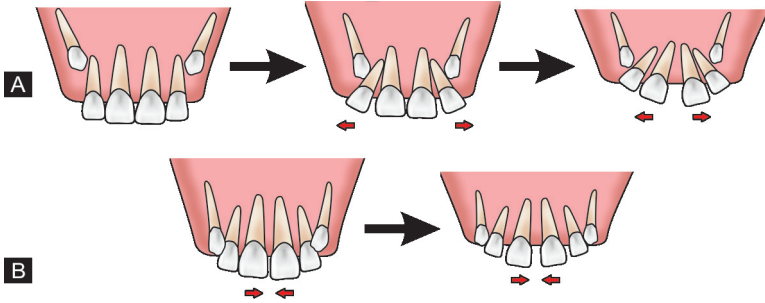


Fig. 4.22: Eruption of permanent second molar and premolar in upper and lower arches

### Self-correcting Anomalies In Mixed Dentition Stage

- **Ugly duckling midline diastema (Broadbent phenomena):** This is also termed as Broadbent phenomena. The maxillary central incisors erupt with a slight distal inclination and some midline space is noticed between them. The erupting lateral incisors are placed distal to the roots of central incisor and this causes the distal tipping of central-incisors. The developing cuspid crown lies just labially and distally to the roots of lateral incisors. The cuspid in this position can cause the crown of lateral incisor to erupt move labially than the central incisor and are flared. There is a formation of midline diastema (Figs 4.23A and B).



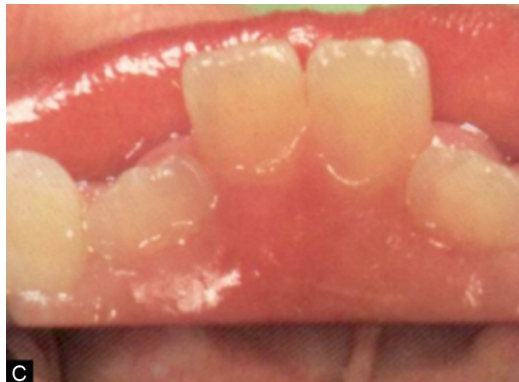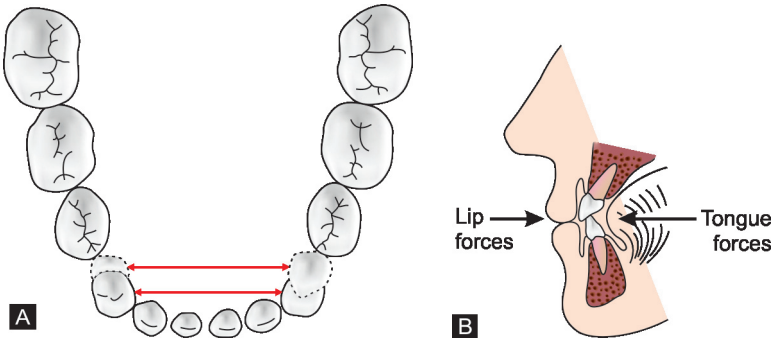
**Figs 4.23A and B:** Ugly duckling stage

**Note:** This is a temporary stage and will correct by itself with the eruption of cuspid. The cuspid which are erupting facing mesially and labially, close the space between the incisors. Hence, any type of treatment intervention is not indicated.

### Mandibular Anterior Crowding

Compensation of crowding takes place by following mechanisms:

- Increased intercanine width (Fig. 4.24A)
- Tongue pressure (Fig. 4.24B)
- Labial movement and change in inclination of incisors (Fig. 4.24C).



**Figs 4.24A to C:** Compensation of lower anterior crowding

- **End on molar relation:** Correction takes place by late mesial deciduous second molar shift utilizing leeway space (Fig. 4.25).

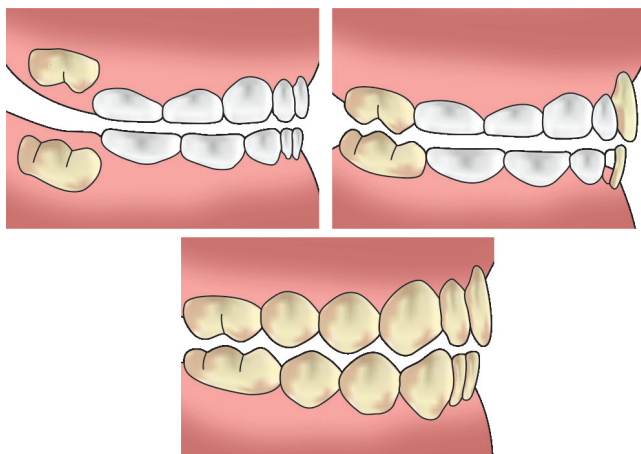


Fig. 4.25: Correction of permanent first molar relation

## PERMANENT DENTITION

As the transition takes place from mixed dentition to permanent dentition, there are many factors which determine the final position of the permanent teeth.

### Factors Determining the Tooth's Position

- **Mesial drift:** Teeth does not erupt vertically straight into the mouth. They erupt in the form of an arch. Thus, there is a strong inherent tendency of the teeth to move mesially even before they appear in the oral cavity (Fig. 4.26).
- **Anterior component of force:** Axial inclination of permanent teeth and muscle forces (muscles of mastication) are such that forces of chewing produce a mesial directed resultant force through the contact points of the teeth. This force is counteracted by proximal contacts of the teeth and by the musculature of the lips and cheeks (Fig. 4.26).

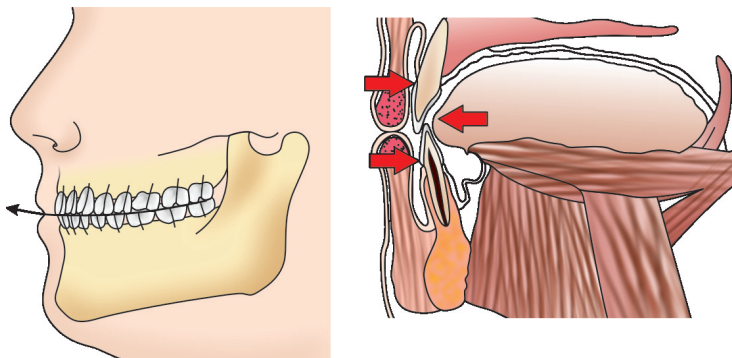


Fig. 4.26: Counteraction for anterior component of force

- **Arch width:** Width increase involves growth of the alveolar process. Maxillary alveolar processes diverge while the mandibular processes are more parallel. Maxillary width increase is much greater and they can be more easily altered in treatment. Mandible is a free movable jaw, which works against gravity. The type of bone seen is usually compact bone and widening of arch width takes place at the basal bone by deposition on lateral borders of corpus mandibularis. This is of little help to clinician to widen the arch.
- **Safety valve mechanism:** The mandibular intercanine arch width completion in girls is established at 9 years and for boys 10 years. Maxillary intercanine arch width completion in girls is established at 12 years and for boys upto 18 years.

Increase in maxillary dimensions occurs at pubertal growth spurts as observed in girls from 10 ½ – 12 years and from 12–18 years in boys. Increasing maxillary intercanine arch width serves as a *safety valve* for the dominant horizontal basal mandibular growth during growth spurts, which extends till the age of 21 years.

- **Arch circumference or perimeter:** In maxilla angulations of incisors are increased and greater increase in width and preservation of circumference leads the perimeter to increase slightly. In mandible, we find decrease in arch perimeter due to following reasons:
  - Late mesial shift
  - Mesial drifting tendency
  - Lingual positioning of incisors due to differential mandibulomaxillary growth
  - Original tipped position of incisors and molars.

### Overjet and Overbite

- **Overbite:** Increases followed by gradual decrease in overbite. Great variability is usually observed, which is correlated with a number of facial dimensions (e.g. Ramus height).
- **Overjet:** In initial period, we find there is increased overjet which gradually decreases as the age progresses. Reflection of anteroposterior skeletal relationship also bears an impact on overjet. Sensitive to abnormal lip and tongue function.

### FURTHER READING

1. Foster TD, Hamilton MC. Occlusion in the primary dentition. Br Dent J 1969;126:76-9.
2. Meyers R. Handbook of orthodontics. 4th Edition, year book publishers, 1988.
3. Nelson. Wheeler's dental anatomy, physiology and occlusion. Saunders; 9 ed. (2009).
4. Nolla CM. The development of the permanent teeth. J Dent Child 1960;27:254-66.
5. Ten cate AR. Oral histology—development, structure and function CV Mosby,1980.
6. Van der linden et al. Tooth size and position before birth. J Dent Res 1972;51:71-4.

## CHAPTER

# 5

# Permanent Incisors

Manjunatha BS

## INTRODUCTION

The term **Incisor** is derived from Latin word '*incidere*', meaning 'to cut'. Human incisors have thin, blade-like crowns, which are adapted for the cutting and shearing of food. Humans normally have a total of eight incisors in the permanent dentition. This makes two incisors per quadrant, four per arch. Among these, two incisors are seen in each quadrant of both arches. The first incisor is called as the central incisor, present next to the midline. The second incisor one is the lateral incisor, present on either side (distal) of the central incisors.

Types of incisors are:

- Maxillary Central Incisor
- Maxillary Lateral Incisor
- Mandibular Central Incisor
- Mandibular Lateral Incisor.

## FUNCTIONS OF INCISORS

- Maxillary and mandibular incisors together perform masticatory function, which includes cutting food with incisal surfaces
- These help in phonation as they contribute to proper formation of speech sounds
- Esthetics: Incisors are critical in esthetics in their proper size, form and position along with lips and facial muscles, significantly contributing to a pleasant smile and appearance. (Consider these features in a toothless person. Example: A young lady without incisors appears older than her normal counter individuals)
- Proper alignment in the arch contributes to the support of facial muscles and thus helps in maintaining a good pleasing facial height in turn the appearance
- Help in guiding the movements of mandible (lower jaw) during closing and opening of the mouth.

In general, a (any) tooth has five surfaces, one surface is used for cutting or chewing depending on whether it is an anterior or posterior tooth. Usually, any tooth will have a number of characteristic features of its own which are described as type traits of the respective tooth. Similarly teeth are identified based on features in regard to arch, class, type, set and side of the oral cavity.

When describing or discussing various traits of any tooth, the morphology is considered in all five aspects.



## Class Traits of Incisors

Before discussing the each surface, here we enlist few important class traits of all permanent incisors those can be used to differentiate other class or groups of teeth:

- Incisors are rectangular in shape
- They have a longer cervicoincisal dimension than mesiodistal dimension (CI > MD) (Height is more than width)
- Tapers from the contact area to the cervix in mesiodistal direction (Narrow at the cervical line and broad at the incisal area)
- Mesial outline is less convex than distal outline in all incisors except mandibular central incisors which is bilaterally symmetrical
- Mesioincisal line angle is less rounded than distoincisal angle except mandibular central incisor
- Mesial contact area is situated in incisal one-third and distal contact is in middle of middle one-third except for mandibular central incisor, because it is the only bilaterally symmetrical tooth with both contacts at same level
- From labial aspect, the mesiodistal dimension is less than the labiolingual dimension (MD < LaLi)
- All incisors converge lingually, both in crown and root aspect
- Roots are longer than crown, but length of the crown is comparatively longer than the root
- From proximal aspect, both labial and lingual crests of curvature are seen in cervical 1/3
- Teeth are 'wedge' shaped from proximal view and have shallow 'S' shaped lingual outline
- Incisal edges converge lingually and terminate at mesial and distal ends
- Root shape is conical, frequently taper from cervix to apex. Roots are blunt and distal tilting may be seen or straight to accommodate in dental arch.

### MAXILLARY INCISORS

The upper incisors are the most prominent teeth in the mouth and are always larger than mandibular incisors. These teeth are shovel-shaped and have one root. Maxillary incisors by definition arise in the premaxilla. The maxillary incisors are four in number. The first incisor is called as the central incisor, present on either side of the midline in the maxilla. The second incisor one is the lateral incisor, present on either side (distal) of the central incisors.

### MAXILLARY CENTRAL INCISOR (FIGS 5.1 AND 5.2)

The **maxillary central incisor** is present in the front part of upper jaw or the maxilla and is usually the most visible and prominent of all teeth in the mouth. It is located closer to the midline of the face mesial to the maxillary lateral incisor. It is larger tooth among the anteriors. Maxillary central incisors function with

lateral incisor in cutting food. Overall, both central and lateral are similar in morphology and supplement each other in function. There are no cusps on these teeth. The major function is to cut food substance during mastication with the help of their incisal surface. Formation of these teeth begins at 3–4 months of age for the permanent teeth. Generally, there are differences occur in the appearance of this tooth in males and females. In males, the size of the maxillary central incisor is usually larger than in females. It is the most prominent tooth in the mouth and has a nearly straight incisal edge.

### Type Traits of Maxillary Central Incisor

- This tooth is larger and has a greater length than width. It is the largest tooth among the anteriors. It is larger than the neighboring lateral incisor and both mandibular incisors
- The permanent maxillary central incisor is the widest tooth mesiodistally in comparison to any other anterior tooth
- This is usually not as convex as other incisors on its labial surface. Hence the labial aspect is smoother and less convex. As a result, the central incisor appears to be more rectangular or square in shape
- The maxillary central incisors are present on either side and contact each other at the midline of the maxillary arch
- The mesioincisal angle is sharper than the distoincisor angle and is approximately about  $90^\circ$ . The distoincisor angle is rounded which is obtuse
- When the tooth is newly erupted, the incisal edge has three rounded features called ‘mamelons’ which later disappear with time as the enamel wears away by friction
- Mesial outline is straight with incisor ridge or edge and distal outline is convex
- It is bilaterally symmetrical tooth expect distal outline which is convex and chronology has rounded distoincisor angle
- Root is conical in shape.

Tooth numbering systems used to designate are:

Dentistry has several systems of tooth notation to identify different teeth.

- In the palmer system, a letter is used in conjunction with a symbol designating in which quadrant the tooth is found. For the permanent teeth, the left and right central incisor would have the same number ‘1’ but the right one would have the symbol ‘J’ underneath it, while the left one would have ‘L’
- In the Universal system, the permanent maxillary central incisors are designated by a number. The right permanent maxillary central incisor is known as ‘8’, and the left is known as ‘9’
- The FDI system is a different system of tooth numbering than the previous two. For the permanent maxillary central incisor, the right one is known as ‘11’, and the left one is known as ‘21’.

Palmer's system	1   1
Universal system	8   9
FDI system	11, 21

### Labial View

From the labial view, the tooth is widest mesiodistally than any other incisor tooth. This surface refers to that portion or the side of a tooth that is adjacent or towards the inner side of the lip. The crown is longer cervicoincisally than mesiodistally. The average size of the crown is about 11 mm.

The mesial and distal outlines become narrower at the cervical part and are wider at the incisal end. The mesial outline of the tooth is relatively or almost straight or slightly convex, whereas the distal outline is much more convex. Hence, the crest of curvature (it is the highest point on a convexity or furthest point from the central axis of the tooth) is closer to the mesioincisal angle on the mesial side while more cervical on the distal side.

The contact area on the mesial surface is located in the incisal third of the tooth, whereas on the distal surface it is located near the junction of middle and incisal thirds. The mesioincisal angle is sharp and the distoincisal angle is rounded.

Mamelons are present on newly erupted, unworn central incisors. Once the mamelons are worn away, the incisal edge becomes straighter mesiodistally. The tooth converges or tapers in size mesiodistally from the labial side to lingual side of the tooth.

The cervical line is convex and the convexity is towards the apex of the root in the center of the crown. This makes the cervical line appear as a semicircle in shape.

From this view, the root is blunt and cone-shaped. Although there is a large amount of variation between people, the length of the root is usually 2–3 mm longer the length of the crown. The root also converges apically from cervical third and the root is tip blunt. Rarely, the root may be tilted at the apical part towards distal side.

The outline form of the maxillary central incisor is normally correlated with the facial form, profile and they do express either masculinity or femininity of an individual. Variations in the general morphology or outline form of the maxillary central incisor also do exist in many individuals. These variations are as follows:

- **Square form:** In this form, both mesial and distal outlines are straighter. The mesiodistal width and the cervicoincisal dimensions are almost equal
- **Rectangular form:** This form of teeth have a longer cervicoincisal dimension than Mesiodistal dimension. This type is the most common
- **Ovoid form:** Here both the mesial and distal outlines are convex and contact areas are placed equally in the same level at incisal third area (See Figs 5.3A to C).

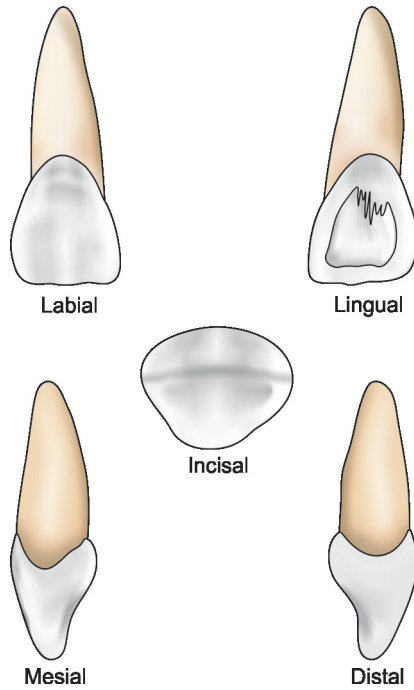


Fig. 5.1: Surface views of maxillary central incisor (Schematic representation)

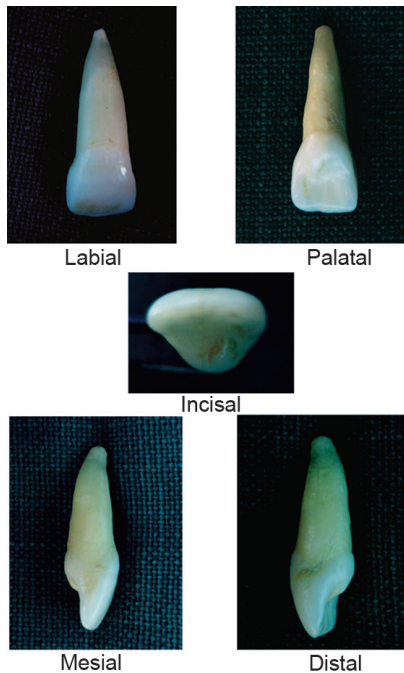
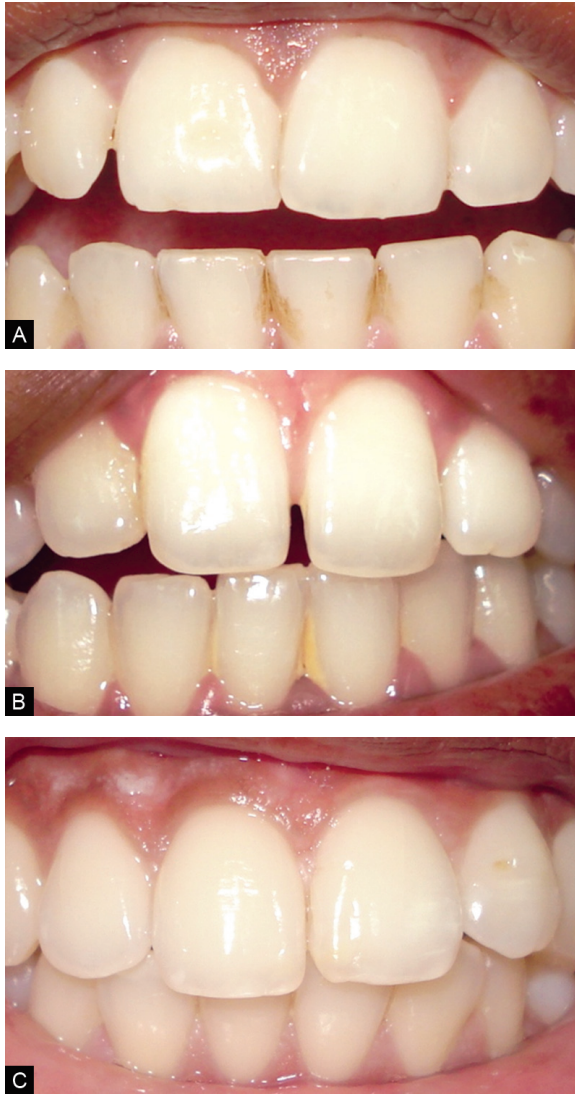


Fig. 5.2: Surface views of maxillary central incisor (Photograph)



**Figs 5.3A to C:** (A) Square form of maxillary CI; (B) Rectangular form of maxillary CI; (C) Ovoid form of maxillary CI

### Lingual View

The lingual view describes the portion of the tooth next to where the tongue rests. The lingual surface of the maxillary central incisor is irregular because of cingulum, marginal ridges, incisal ridge and lingual fossa.

Cingulum is a small convexity at the cervical third portion, above the cervical line and is placed slightly distally. Along the border of the mesial and distal sides, slightly raised portions are seen called 'marginal ridges'. The incisal end is also raised slightly to the level of the marginal ridges and few authors term this as

‘incisal ridge’. The incisal ridge becomes flatter due to masticatory forces, as the age of the individual increases.

Lingual fossa, an irregular depression or concavity bordered incisally by the incisal ridge, mesially by the mesial marginal ridge, distally by the distal marginal ridge and cervically by the cingulum. Mesial marginal ridge is longer and prominent than distal marginal ridge because cingulum is present slightly distally.

Mesial and distal outlines and contact areas are similar to labial aspect.

The cervical line is convex similar to the labial aspect. The root also converges lingually and thus, the mesial and distal aspects of the labial portion can be seen. The root is tip blunt and straighter.

### Mesial View

The mesial view considers the portion of the tooth closest to the middle line of the face. From the mesial side, the crown of the tooth appears as a ‘triangle’ or ‘wedge’ shaped with the point at the incisal edge and the base at the cervix.

The crest of curvature for the labial and lingual surfaces is located at the cervical third area above the cervical line. The labial surface of the crown is convex and the crest of curvature is at the junction of middle and cervical thirds. It is straighter from crest of curvature to the incisal edge. The lingual surface of the crown is ‘S’ shaped and is convex near the cingulum and incisal ridge areas. The concavity is at the lingual fossa the area between the cingulum and incisal ridge.

Unlike most other teeth, when a line is drawn along the long axis of the tooth, passing through root tip it passes through incisal tip. Rarely, the line is labially present. This feature is also seen in permanent maxillary lateral incisors.

The root appears cone-shaped with a blunt apex. The cervical line from this view curves more towards the incisal edge or ridge which more than any other tooth in the mouth. In an average crown, the curvature of the cervical line is about 2.5 to 3 mm.

### Distal View

The distal view of the tooth is very similar to the mesial side with two modifications. The cervical line curves less pronounced in comparison to the mesial side. The contact area is located more cervical. The distal marginal ridge is less prominent than the mesial marginal ridge. So, a part of mesial marginal ridge can be seen from this view.

### Incisal View

From the incisal view only the crown of the tooth is visible and overall the tooth looks bilaterally symmetrical. Overall appearance of incisal aspect is ‘conical’ or ‘triangle’. The labial surface is slightly convex and appears broad and flat. The lingual surface tapers toward the cingulum. The incisal edge is nearly a straight line, though slightly crescent shaped. The distance between the mesioincisal angle to the cingulum is slightly longer than the distance between the distoincisal angle

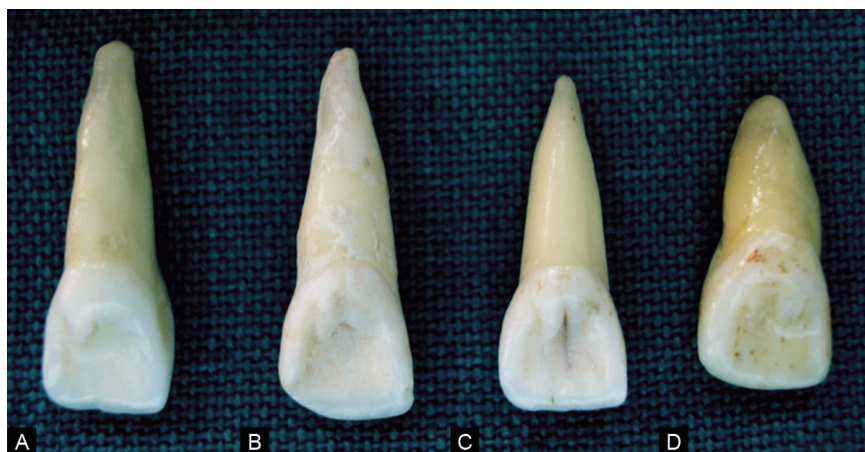to the cingulum. Because of longer mesial marginal ridge (MMR) and slight distally placed cingulum.

**Right and left:** In determining a right from left, look for following points:

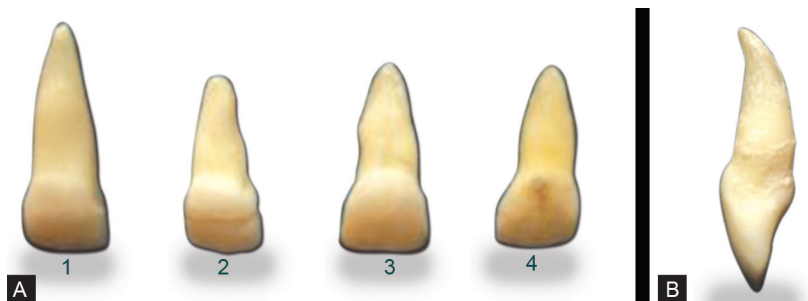
- The mesioincisal angle is sharp and the distoincisal angle is more rounded
- Position of contact points on both mesial and distal surfaces
- The curvature of cervical line is more on mesial than distal surface
- Longer mesial marginal ridge and slight distal positioning of cingulum seen on lingual surface.

**Clinical variations:** The maxillary central incisor usually develops normally. Variations include (Figs 5.4 and 5.5):

- A short crown and very rarely a long crown (See specimen 2, 3, 4 in Fig. 5.5A)
- This tooth is rarely absent



**Figs 5.4A to D:** (A) Distally placed cingulum; (B) Normal lingual fossa and cingulum; (C) Divided cingulum; (D) Prominent lingual fossa and cingulum



**Figs 5.5A and B:** (A) Variation in the size of the tooth, mainly the roots are smaller than the crown in specimen 2,3,4 (compare with specimen 1); (B) Labially tilted root. Root do not tilt normally

- The Hutchinson incisor is a malformation due to congenital syphilis *in utero*
- An important morphological variation of the maxillary central incisor is the shovel shaped incisor. It appears as a large, prominent marginal ridges and a deep lingual fossa (Fig. 5.4D). This feature is commonly associated in Chinese, Eskimos and North American Indians
- In few cases, a deep lingual pit may be present on the lingual aspect.

### MAXILLARY LATERAL INCISOR (FIGS 5.6 AND 5.7)

The **maxillary lateral incisor** is located distal to maxillary central incisor on both sides of the midline of the face and mesial to maxillary canine. Like all other incisors, the prime function is cutting of food during mastication. Both maxillary central and lateral incisors have close resemblance in morphology and maxillary lateral incisors supplement maxillary centrals in function.

Maxillary lateral incisors are smaller in size from all directions except the root. This tooth is more rectangular and is less symmetrical than the maxillary central incisor. The crown of the lateral incisor is shorter by about 1 mm to 1.5 mm in cervicoincisal dimension than any other tooth in both arches. This feature is not seen in any other tooth.

The maxillary lateral incisor has highest degree of morphologic variation than any other tooth except third molars. In many individuals, the lateral incisor is found to be missing, resulting maxillary central incisor directly in contact with maxillary canine. Absence of maxillary incisor may be unilateral and sometimes, bilateral missing is also noted.

Tooth numbering systems used to designate are:

- In the Palmer system, a letter is used in conjunction with a symbol designating in which quadrant the tooth is found. For the permanent teeth, the left and right lateral incisor would have the same number '2' but the right one would have the symbol 'J' underneath it, while the left one would have 'L'
- In the Universal system, the permanent maxillary lateral incisors are designated by a number. The right permanent maxillary lateral incisor is known as '7', and the left is known as '10'
- The FDI system is a different system of tooth numbering than the previous two. For the permanent maxillary lateral incisor, the right one is known as '12', and the left one is known as '22'.

Palmer's system	<table border="1"> <tr> <td>2</td> <td>2</td> </tr> <tr> <td></td> <td></td> </tr> </table>	2	2		
2	2				
Universal system	<table border="1"> <tr> <td>7</td> <td>10</td> </tr> <tr> <td></td> <td></td> </tr> </table>	7	10		
7	10				
FDI system	12, 22				

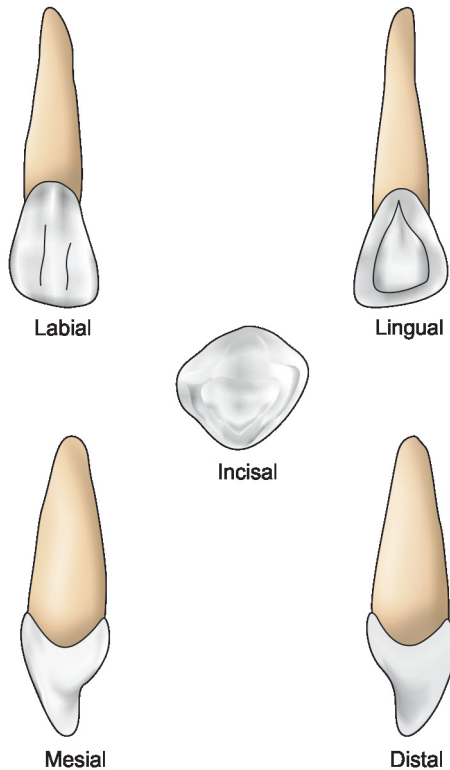


## Labial View

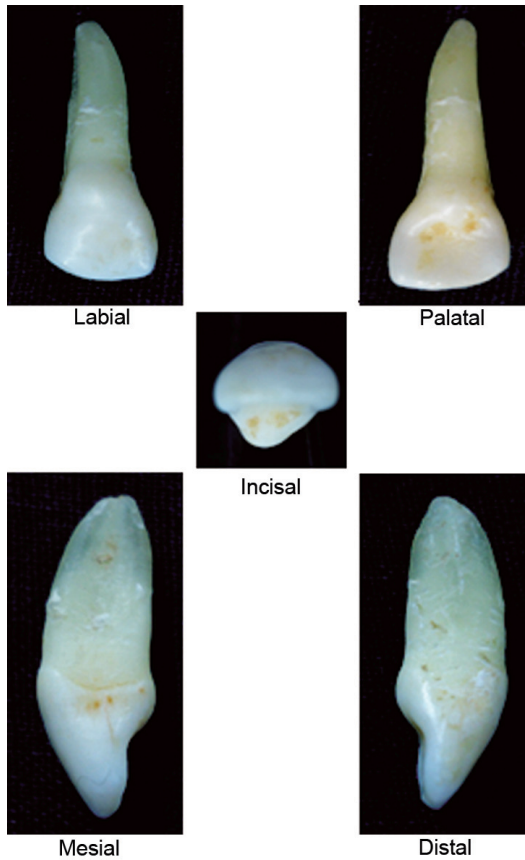
From the labial view, the maxillary lateral incisor resembles the central incisor, but is narrower mesiodistally. The crown more is longer cervicoincisally than mesiodistally. Overall the labial surface is less flat and is more convex.

The mesial and distal outlines become very narrow at the cervical part and are relatively wider at the incisal end. The mesial outline of the tooth resembles the adjacent central incisor and is convex, whereas the distal outline is much more convex and is rounded. The mesioincisal angle is rounded and the distoincisal angle is more rounded which is obtuse angle. The distoincisal angle resembles that of the mesial outline of the adjacent maxillary canine. Unlike the maxillary central incisor, the incisal edge is more curved or slightly convex. The incisal ridge is straight in central part and is rounded at the mesial and distal ends where it declines cervically.

The crest of curvature is at the junction of middle and incisal thirds on the mesial side and it is more cervical on the distal side. The contact area on the mesial surface is located at the junction of middle and incisal thirds, whereas on the distal surface it is more cervical at the center of the middle third.



**Fig. 5.6:** Surface views of maxillary lateral incisor (Schematic representation)



**Fig. 5.7:** Surface views of maxillary lateral incisor (Photograph)

Mamelons are less prominent and less common than central incisors.

The tooth converges from the labial side to lingual side in mesiodistal dimension. The cervical line is convex and the convexity is towards the apex of the root in the center of the crown.

From the labial view, the root is bent and less conical. The root also converges apically from cervical third. The root is oval in shape and bends distally in apical part.

### Lingual View

The lingual surface of the maxillary lateral incisor is small and more irregular because of prominence of cingulum, marginal ridges, incisal ridge and lingual fossa.

Lingual fossa is bordered by the incisal ridge, prominent mesial and distal marginal ridges, and cervically by the cingulum. Both the mesial and distal marginal ridges are equal and the cingulum is prominent, present in the center.

- Mesial and distal outlines and contact areas are similar to labial aspect
- The cervical line is convex

- The root converges lingually and is slightly flatter in mesiodistal direction. Thus, the mesial and distal aspects of the labial portion can be seen. The root is tip blunt and straighter or bent distally. Most often, a deep lingual pit extends gingivally where the marginal ridges converge.

### Mesial View

When viewed from the mesial side, the outline of the crown of the maxillary lateral incisor appears similar to maxillary central incisor except for prominent cingulum and deep or more pronounced lingual fossa.

The labial surface of the crown is more convex and the crest of curvature is at the junction of middle and cervical thirds. Unlike the maxillary central incisor, the crest of curvature is not straighter from to the incisal edge. The crest of curvature on lingual surface is located at the cervical third area. The lingual surface of the crown is more markedly 'S' shaped. The cingulum is convex and centrally placed.

The incisal ridge is labial to the long axis of the root as seen on maxillary central incisor.

The cervical line is curved more towards the incisal edge or ridge. In an average crown, the curvature of the cervical line is about 2 mm to 2.5 mm.

The root appears cone shaped and tapers to the apex, which is blunt from proximal view. Shallow longitudinal developmental depression is found in the middle of the mesial surface which usually extends to apical third.

### Distal View

The distal outline and surface of the tooth are very similar to the mesial side. The cervical line curves less than the mesial side. From this surface, no developmental depression is found on the root.

### Incisal View

In incisal view, the maxillary lateral incisor appears as either the maxillary central incisor or a small maxillary canine. This tooth is less symmetrical. It is markedly oval or round, not triangular. The tooth is narrower mesiodistally than labiolingually. Both the labial surface and lingual surfaces are more convex. The cingulum is centrally placed and markedly rounded. The mesioincisal angle and the distoincisal angles are rounded making the incisal edge curved.

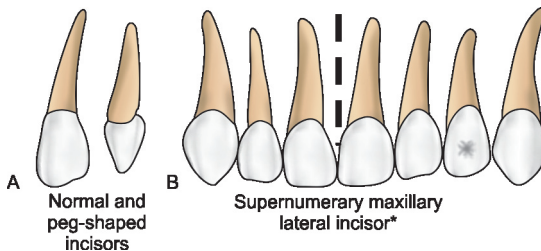
**Right and left:** In determining a right from left, following points are to be considered:

- The distal incisal angle is more rounded than the mesioincisal angle
- The root tip may be curved distally, but this is not seen routinely
- Position of contact points on mesial and distal surfaces
- The more curvature of cervical line on mesial than distal surface.

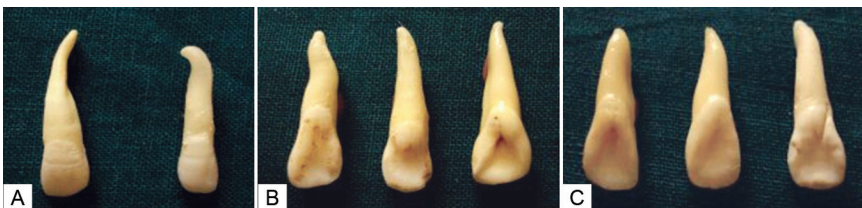**Clinical variation:** The maxillary lateral incisor usually shows lot of variations which include:

- The tooth is narrow, conical, and peg-shaped very often known as 'peg lateral' (Figs 5.8A and 5.10A)

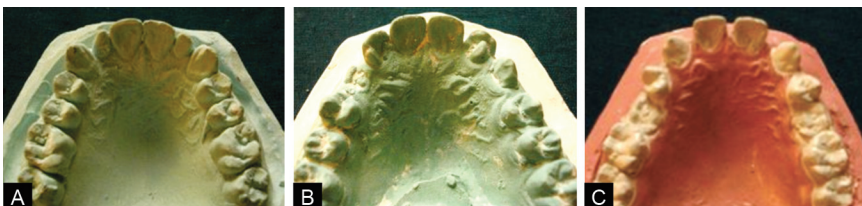- It is the second most commonly ‘missing tooth’ either unilaterally or bilaterally in more than 2% of individuals (Fig. 5.10C)
- An important variation of the maxillary lateral incisor, very similar to maxillary central incisor is the shovel shaped incisor. This trait is commonly associated in Mongols, Chinese, Koreans, Eskimos and North American Indians.
- The tooth has prominent marginal ridges and a deep lingual fossa (Fig. 5.9B)
- The presence of ‘lingual pit’ a very deep narrow lingual fossa extending cervically and is prone to early caries in many persons (Fig. 5.9C)
- The distal curving of root may be marked and results in ‘dilaceration’ of root (Fig. 5.9A)
- The Hutchinson incisor is a malformation due to congenital syphilis *in utero*.
- Mamelons are less common than central incisors
- A rare anomaly is presence of very well-formed cingulum which appears like a tubercle or a lobe or even like a non-functional cusp
- In very few occasions, an extra lateral incisor is noted and is termed as supernumerary lateral incisor or supplemental tooth (Fig. 5.8B).
- Talon’s cusp: A small cusp or projection on the lingual aspect in the fossa area is seen called as ‘Talon cusp’ (Fig. 5.10B).



**Figs 5.8A and B:** (A) Normal and peg shaped maxillary lateral incisor; (B) Supernumerary maxillary lateral incisor (indicated by \*)



**Figs 5.9A to C:** Variations of lateral incisor: (A) Distal bend of root; (B) Prominent lingual aspect; (C) Deep lingual groove



**Figs 5.10A to C:** Variations of lateral incisor: (A) Peg lateral; (B) Bilateral Talon's cusp and (C) Congenital missing bilaterally

## MANDIBULAR INCISORS

Like the upper incisors, mandibular incisors are also four in number, present on either side of the midline of the face. Mandibular incisor teeth are not as prominent as maxillary incisors. The mandibular central incisor is the first incisor, situated in the center of mandible on either side. The second incisor is the lateral incisor, located distal to central incisors.

Mandibular incisors are smaller than any other teeth. These teeth are narrower in mesiodistal dimension and have smooth surface both labially and lingually. Unlike, maxillary incisors, both mesial and distal outlines are straight in mandibular incisors. The lingual surface is less pronounced and has less prominent cingulum, lingual fossa and marginal ridges. Mandibular teeth have single root and is flatter mesiodistally.

The mandibular incisors are the first permanent teeth to replace the deciduous teeth. As a group, the mandibular incisors act as moving blade and help in cutting the food substances. Although, the mandibular incisors are anterior teeth, esthetically are not as important as the maxillary incisors. But, they are important phonetically especially in the pronunciation of ‘S’ sounds. The mandibular incisors along with the maxillary incisors support the lips. They have least developmental variations.

## MANDIBULAR CENTRAL INCISOR (FIGS 5.11 AND 5.12)

The **mandibular central incisor** is the smallest permanent tooth among both the dental arches. These are located in the center of the mandible, one on either side close to the midline. The mesial surface of each tooth is in contact to one another. Both the central and the lateral incisors are similar in morphology and complement each other in their function. The most important task is to cut food substance with the help maxillary central incisor. The formation of mandibular central incisor begins at 1–3 months of age. It has a straight incisal edge. Mamelons are worn out shortly following eruption into the mouth and are seen in later part of life if abnormal occlusion, termed as ‘malocclusion’, exists.

### Type Traits of Mandibular Central Incisor

- It is the smallest tooth and has a greater length than width. Mandibular central incisor is slightly smaller than the neighboring mandibular lateral incisor
- The mandibular central incisor is a long, narrow, symmetrical tooth
- The tooth is wider labiolingually than mesiodistally
- The labial aspect is smoother and less convex and appears more rectangular in shape
- The contact areas on both the mesial and distal surfaces are at the same level
- Both the mesioincisal angle and the distoincisor angle are sharp and make about 90° angle
- When the tooth is newly erupted, the incisal edge has three rounded structures called ‘mamelons’, which later disappear with time as the enamel wears away by friction.

### Notation

- In the Palmer notation, a number is used in combination with a symbol designating in which quadrant the tooth is situated. For the left and right central incisors the designation is by the same number '1' but the right one will have the symbol '┘' over it, while the left has '└'

Palmer's system 

- In Universal system, the right permanent mandibular central incisor is designated as '25' and the left as '24'

Universal system 

- The International notation or the FDI system has a different numbering system than the other two systems, and the right permanent mandibular central incisor is referred as '41' and the left as '31'.

FDI system 31, 41

### Labial View

From the labial view, the mandibular central incisor resembles the maxillary central incisor, but is narrower mesiodistally.

The mandibular central incisor is a long, narrow, symmetrical tooth. The crown more is longer cervicoincisally than both mesiodistally and labiolingually. Overall, the labial surface is flat and is smoother, not convex as maxillary incisors. Slight convexity is present in cervical third part of labial surface just incisal to the cervical line.

The incisal edge is straight. Mesial and distal outlines form straight lines and converge cervically. The mesioincisal and distoincisal angles are sharp and about 90° angle.

The contact areas on the mesial and distal surfaces both are at the same level located in incisal third or just incisal to the junction of middle and incisal thirds.

The cervical line is convex, dips towards the apex of the root.

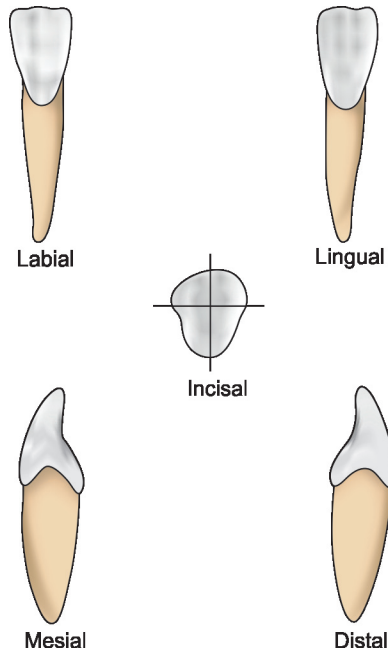
Mandibular central incisor has single root and is flatter mesiodistally. The root is straight with blunt apex. Rarely root tip bends distally or labially.

### Lingual View

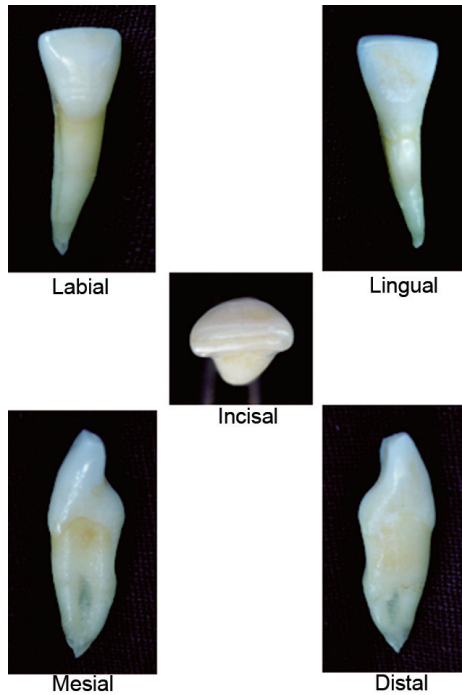
From this view, the outline is same as the labial surface. Like all other incisors, the lingual surface has mesial and distal marginal ridges and a cingulum. But these features are not very prominent. So, the lingual surface is slightly irregular. Both crown and root converge lingually from labial aspect. The root is flatter mesiodistally and is oval in shape.

### Proximal View

Both mesial and distal surfaces of the crown of the tooth present as a 'triangle' or 'wedge' shaped with the point at the incisal edge and the base at the cervix. Developmental depressions are seen both on the mesial and distal surfaces.



**Fig. 5.11:** Surface views of mandibular central incisor (Schematic representation)



**Fig. 5.12:** Surface views of mandibular central incisor (Photograph)

## Mesial View

The mesial view considers the portion of the tooth closest to the middle line of the face.

The crest of curvature for the labial and lingual surfaces is restricted to the cervical third area just above the cervical line. The labial surface of the crown is slightly convex and straight from the cervical third till the incisal edge. The lingual surface of the crown is insignificantly 'S' shaped and has a small inconspicuous cingulum. The small concavity is present at the lingual fossa area. When a line is drawn along the long axis of the tooth, passing through root tip it passes labially or the incisal edge is placed lingually to the line.

The root is wider labiolingually and end with a blunted apex. The cervical line curves more incisally on the mesial surface. The developmental depression is broader and shallow on the mesial surface of the root. The developmental depression is longitudinal, and mainly in the middle third of the root.

## Distal View

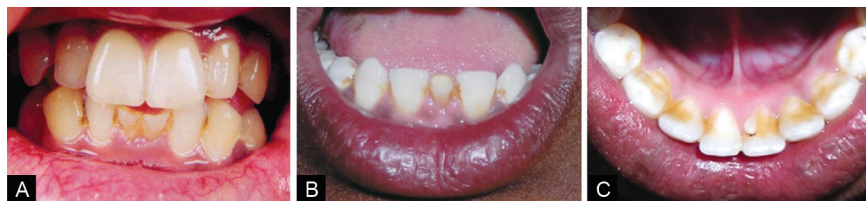The distal surface is similar to that of the mesial surface. The developmental depression is prominent and deep on the root of distal surface. The cervical line curves incisally about 1 mm less than on the mesial surface.

## Incisal View

From the incisal view most of the labial surface crown of the tooth is visible and the tooth looks bilaterally symmetrical. Overall, appearance of the incisal aspect is 'triangular'. The labial surface appears flat. The incisal edge is straight and right angles to a line passing labiolingually. Both the mesioincisal and distoincisal angles are sharp. The tooth is wider labiolingually than mesiodistally.

**Right and left:** The symmetry of this tooth makes it difficult and unreliable to distinguish the right and left.

**Variations and anomalies:** The mandibular central incisor develops normally. This tooth is very consistent in development and is very rarely absent. Occasionally supernumerary teeth may occur in the midline, called a mesoidens. Many times congenital missing of mandibular central incisor seen bilaterally (Figs 5.13A to C).



**Figs 5.13A to C:** Variations of permanent mandibular central incisor: (A and B) Congenital missing bilaterally; (C) Talon's cusp



**MANDIBULAR LATERAL INCISOR (FIGS 5.14 AND 5.15)**

The mandibular lateral incisor is located distal to mandibular central incisor and mesial to mandibular canine. The main function is shearing or cutting food during chewing. Though the tooth appears same as that of mandibular central incisor, there are some minor differences exist. Mandibular lateral incisor is somewhat (0.5 to 1 mm) larger than mandibular central incisor.

Both the mandibular central and lateral incisors have close resemblance in morphology and supplement each other in their function. This tooth is less symmetrical than the mandibular central incisor. In general, the mandibular lateral incisor resembles the mandibular central incisor.

Tooth numbering systems used to designate are:

- **Palmer notation:** The '2' is used in combination with a symbol designating in which quadrant the tooth is found. Both, the left and right lateral incisors have the same number, but the right tooth with the symbol '┐' over it and the left is designated as '┌'.
- **Universal system of notation:** The right permanent mandibular lateral incisor is designated as '26', and the left as '23'.
- **International notation or FDI:** It has a different numbering system than the previous two, and the right permanent mandibular lateral incisor is known as '42', and the left one is known as '32'.

Palmer's system	┌ 2   2 └
Universal system	┌ 26   23 └
FDI system	32, 42

**Labial View**

From the labial view, the mandibular lateral incisor resembles the central incisor, but is, somewhat, larger in most proportions. The mandibular lateral incisor is not bilaterally symmetrical as the mandibular central incisor.

The crown of the mandibular lateral incisor is wider mesiodistally. This tooth is more rounded tooth and unlike the mandibular central incisor, the distoincisor angle rounded and not 90° angle. The distal outline is not straight but is slightly convex. The crown of the mandibular lateral incisor is tilted slightly to the distal side. The mesial outline is longer than the distal outline.

Overall the labial surface is flat and smoother, not convex as maxillary incisors. The distal contact is more cervical than the mandibular central incisor.

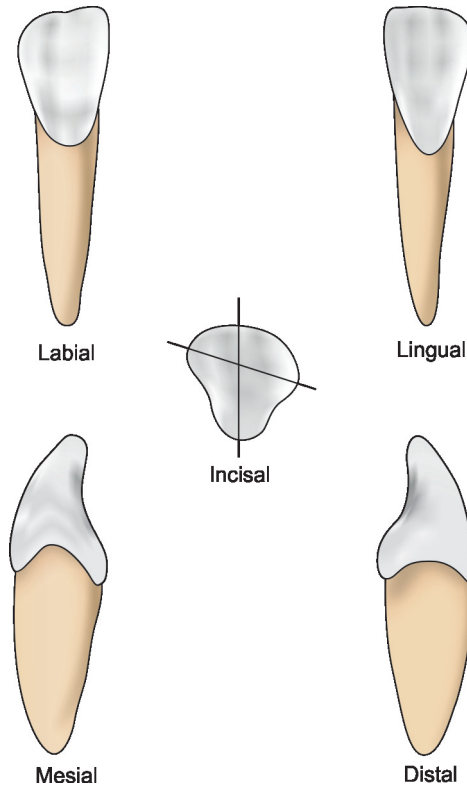
The incisal edge is almost straight similar to mandibular central incisor. The Mesial outline form is straight and converges cervically. The mesioincisor angle is sharp and about 90° angle.

The cervical line is convex, dips towards the apex of the root.

Mandibular lateral incisor has single root and is flatter mesiodistally. The root is straight with blunt apex. The root tip bends distally in the apical third area.

## Lingual View

The lingual outline is same as that of the labial surface. Like the mandibular central incisor, the lingual surface has less marked mesial and distal marginal ridges and the cingulum. The cingulum is small, less convex and lies slightly distally similar to maxillary central incisor.

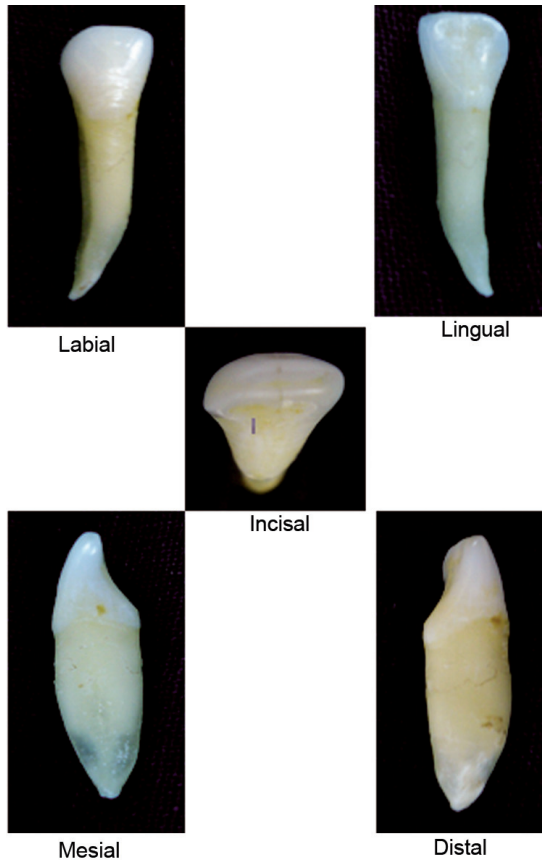


**Fig. 5.14:** Surface views of mandibular lateral incisor (Schematic representation)

Both crown and root converge lingually from labial aspect. The root is flatter mesiodistally and is oval in shape. Sometimes, developmental depressions on the proximal surfaces can be seen from lingual side.

## Mesial View

The mesial outline form is nearly identical to the mandibular central incisor, presents a triangular outline. The exception is that the cervical line curves less incisally. The root is broader labiolingually. The incisal edge is slightly lingual central axis of the root. From the mesial side, the distal part of the incisal ridge is seen, which is placed slightly lingual due to distal/distolingual twist or tilt of the crown.



**Fig. 5.15:** Surface views of mandibular lateral incisor (Photograph)

The labial outline is nearly flat and straight in the middle and incisal thirds of the crown. The crest of curvature on the labial surface is just above the cervical line in the cervical third. The lingual crest is seen at the cervical third on the cingulum. Developmental depressions are seen both on the mesial and distal surfaces.

### Distal View

The distal surface is similar to that of the mesial surface. More of the incisal ridge is visible due to twisting of the crown distolingually. The developmental depression is more distinct on the root of distal surface. The cervical line curves incisally about 1 mm less than on the mesial surface.

### Incisal View

When the tooth is viewed from incisal aspect, most of the features are similar to the mandibular central incisor. Unlike the maxillary incisors, the tooth is broader labiolingually than mesiodistally. Mandibular lateral incisor is not bilaterally symmetrical.

The labial surface is flat and slight convexity is noted in the cervical third. So, most of the labial aspect is visible from the incisal view.

The incisal ridge is not straight mesiodistally. When a line is drawn bisecting the crown labiolingually, the incisal edge is oblique or curved to distal direction which follows the curvature of the mandibular dental arch. This feature helps to recognize or distinguish the left and the right mandibular lateral incisor.

From the incisal view, the tooth has a distolingual twist and the distal half of the incisal edge is bent lingually resulting in lingual placement of the distoincisor angle. The mesial half of the incisal edge is straight and right angles to labiolingual outline. The mesioincisor angle is sharp and the distoincisor angle is rounded.

The cingulum and the lingual fossa are not as prominent as the maxillary teeth. The cingulum is slightly placed to the distal side.

**Right and left:** Two important features assist in identification of the left and right tooth are as follows:

- The incisal edge is 'twisted' or 'curved', when a line passing from the labial to the lingual simulating the curvature of the dental arch
- The cingulum is shifted toward the distolingual side.

**Variations and anomalies:** This tooth develops normally and is very consistent. But variations in root length and direction are seldom seen.

## CHAPTER

# 6

# Permanent Cuspids

*Manjunatha BS*

### INTRODUCTION

The term **Canine** is derived from the Latin word ‘canix’ means—dog. These teeth have evolved and also resemble that of carnivorous animals. They are used primarily for catching, seizing or tearing of food and occasionally as weapons, so the name ‘canine’. Canine has a prominent cusp with a long slender root that makes the tooth to be called as ‘cuspid’. Other synonyms previously used were:

- ‘Eye tooth’—for maxillary canine as this tooth develops from infra orbital region close to eyes
- ‘Spit tooth’—in Spanish language ‘cuspid’ means ‘to spit’. But these terms are no more in use today, which give a very different meaning altogether in the general population.

In humans, two canines are seen in the maxillary and mandibular arches, one in each quadrant so called as ‘single’ members of the dental arch. These are positioned distal to incisors and mesial to premolars in all quadrants. Canines are located at the corners of the mouth, so considered as the ‘cornerstones’ of the dental arch.

They are larger and stronger than incisors, and roots are deeply situated into the bones resulting in well-marked prominences upon the labial surface of the bone called ‘**canine eminences**’.

The crown is large and conical, very convex from the labial surface and slightly irregular, uneven on the lingual surface due to the presence of lingual fossae and lingual ridge. The tooth tapers as a blunted point or cusp, which projects towards the incisal surface, above the level of adjacent teeth. The root is single, conical in form, but longer and thicker than that of incisors, slightly compressed laterally which is marked by a slight groove on both sides.

### FUNCTIONS OF CANINES

These teeth have dual functions as they complement together with both incisors and premolars during mastication. Most important functions of canines are as follows:

- The primary function is to cut, pierce or shear food substances
- Canines along with incisors and associated oro-facial musculature are important in esthetics. All these significantly contribute in a pleasing smile and good facial profile

- They support lips and muscles of facial expression
- Also help in proper alignment of teeth in the arch
- As described earlier, canines are the longest and most stable teeth in the dental arch. So these are commonly used abutment teeth in fixed and removable partial denture preparations
- Canines are considered as the ‘last tooth to be lost’ either due to dental caries or periodontal problems [resistant to dental diseases]. This is because of the shape of the tooth that promotes in cleanliness (self-cleansing property)
- Help in guiding the occlusion which is mainly termed as ‘canine protected occlusion’
- The tooth size, form and position in the dental arch help in guiding the mandibular movements during intercuspation and side-to-side movements. Thus, prevent any untoward mandibular movements and also TMJ
- As mentioned in the earlier part of this chapter, these teeth have a well-marked bony prominence on the labial root surface called ‘canine eminence’ which is of cosmetic value. Canine eminence is ‘a bony elevation or ridge present over the labial aspect of root of permanent canine, seen in both maxillary and mandibular arches’
- In many species, canines are seen well-ahead of the level of the other teeth and may interlock when the teeth are closed, thus preventing side-to-side motion
- Used as organs of defense in lower animals, especially carnivorous like dogs, cats, etc.

### CLASS TRAITS [GENERAL CHARACTERS] OF CANINES

Before describing each surface of maxillary and mandibular canines, the following are some important features those used to differentiate with other group of teeth.

- Canines are longest teeth in the oral cavity and have a single, long, slender root of about 17 mm approximately
- Canines have a strong, well-developed cusp. Hence termed as ‘cuspids’
- Canines have a prominent ridge on labial aspect—‘labial ridge’ and cuspids are the only anterior teeth to have this feature

Labial ridge is ‘a liner elevation which runs vertically from the cusp tip to the cervical 1/3 of the labial aspect the crown’. This ridge is well-separated by shallow depression on either (mesial and distal) sides.

Normally any tooth develops from four developmental lobes. In case of canines, the development is as follows:

- 3 labial (facial)
  - Mesial
  - Middle: In canines highly developed into a ‘cusp’
  - Distal
- 1 lingual: Develop as cingulum and lingual ridge
- Canines also comprise of a ‘lingual ridge’ on the lingual aspect, which is less prominent than the labial ridge
- Canines have a ‘pentagon’ shaped crown (two slopes, two surfaces and the cervical line)

- Canines do not have incisal ridge. Instead, these teeth have two ‘cusp ridges slopes’ or ‘cusp slopes’ namely mesial and distal slopes. Always the distal slope is longer than the mesial slope.  
MS < DS
- In canines, the mesiodistal dimension is less than labiolingual by about 1 mm.  
MD < LaLi ~ 1 mm
- In canines, the labial aspect of the crown is more convex than incisors. But in case of maxillary incisors, only the cervical one-third is convex and rest of two-third the labial aspect of the crown is flatter.

### MAXILLARY CANINES (FIGS 6.1 AND 6.2)

The maxillary canine is present in the front part of upper jaw or the maxilla and is one of the most visible and prominent anterior tooth at the corner of the mouth. It is exactly located distal to the maxillary lateral incisor and mesial to the maxillary first premolar. Maxillary canine tooth is one of the most common tooth to erupt out of the arch either labial or palatal side and the second most common tooth to be impacted within the bone followed by mandibular third molars. It is almost same in height to that of maxillary central incisor and function with lateral incisor in holding and/or cutting food. Overall, both incisors and canines are similar in function and supplement each other in mastication. Cusps make these teeth prominent and are important aspects on these teeth which do not have the incisal edge like incisors. Generally, there are differences seen in the morphology of this tooth in males and females. In males, the size of the maxillary canine is larger and bulkier when compared to females. Mamelons are not seen in newly erupted maxillary canine.

#### Type Traits of Maxillary Canine

- It is the longest tooth and has a greater length than width. It is larger than the neighboring central and lateral incisors
- Permanent maxillary canine is last tooth to replace the deciduous counterpart
- Maxillary canines have a prominent labial and lingual ridge and the cingulum is more developed than incisors
- The permanent maxillary canine is the widest tooth labiolingually in comparison to any other anterior tooth  
MD < LaLi
- The mesial half of the tooth resembles the incisor and the distal half resembles the premolar. Hence a compromise or a transition from anterior to posterior tooth
- The maxillary canine is more convex due to the presence of prominent labial ridge
- The incisal portion of the tooth is not thinner like incisors. It is because of the presence of a well-formed middle portion of tooth into a cusp
- No incisal edge or ridge. Instead, two cusp ridge slopes or slopes are seen on the incisal surface. The distal slope is longer than the mesial slope

- The cusp tip is not centered rather it is slightly mesially placed. Hence larger distal slope
- From the labiolingual or the proximal view, the cusp tip is positioned more labial or centrally
- Root is conical in shape with prominent developmental depressions on both mesial and distal surfaces.

### CHRONOLOGY OF PERMANENT MAXILLARY CANINE

- First evidence of calcification: 4–5 months
- Crown completed: 6–7 years
- Eruption of tooth: 11–12 years
- Root completion: 13–15 years.

#### Tooth numbering systems used to designate are:

Dentistry has several systems of tooth notation to identify different teeth.

- In the Palmer system, a letter is used in conjunction with a symbol designating in which quadrant the tooth is found. For the permanent teeth, the left and right canine would have the same number '3' but the right one would have the symbol of grid 'J' while the left one would have 'L'
- In the Universal system, permanent maxillary canines are designated by a number. The right permanent maxillary canine is known as '6' and the left is known as '11'
- The FDI system is a different system of tooth numbering than previous two. For the permanent maxillary right canine it is designated as '13' and the left one is known as '23'.

Palmer's system	<table border="1"> <tr> <td>3</td> <td>3</td> </tr> <tr> <td colspan="2" style="text-align: center;"> </td> </tr> <tr> <td colspan="2" style="text-align: center;">—</td> </tr> <tr> <td colspan="2" style="text-align: center;"> </td> </tr> </table>	3	3			—			
3	3								
—									
Universal system	<table border="1"> <tr> <td>6</td> <td>11</td> </tr> <tr> <td colspan="2" style="text-align: center;"> </td> </tr> <tr> <td colspan="2" style="text-align: center;">—</td> </tr> <tr> <td colspan="2" style="text-align: center;"> </td> </tr> </table>	6	11			—			
6	11								
—									
FDI system	13, 23								

### Labial View

The labial or the facial surface of the crown differs considerably from that of the maxillary central or lateral incisors. Canines have a 'pentagon' shaped crown formed by mesial and distal surfaces, two cusp slopes and the cervix. The canine is approximately 1 mm narrower than the central incisor from the mesiodistal direction. The crown is much longer cervicoincisally than mesiodistally and labiolingually. The average height of the crown is about 10.5 mms to 11 mms.

The labial surface of the crown is smooth; with a well-developed middle lobe forming the labial ridge that runs cervicoincisally from the cusp tip till the cervical line. The cusp is made of two slopes, the mesial and the distal. The distal slope is the longest. These slopes make an angle of about 105° at the cusp tip.



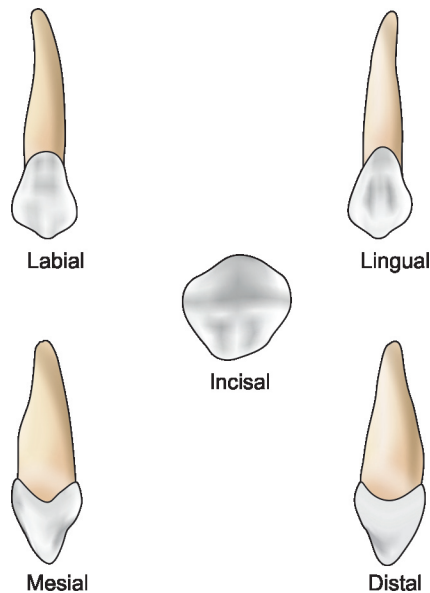
The mesial and distal outlines are wider at the contact area from cervical part and become narrower at the incisal area to end as the cusp tip. Central and lateral incisors nearly have a straight incisal edge. Cuspids have a definite pointed edge, or a cusp.

The mesial aspect resembles the adjacent lateral incisor and the distal aspect looks like the first premolar present next to it. Unlike incisors, both outlines are convex from the cervical area extending till contact areas. The mesial outline is relatively or slightly convex from the cervical line to the contact area, whereas the distal outline is concave at the cervical line and becomes slightly convex at the contact area. The contact area on the mesial surface is located at the incisal third of the tooth, whereas on the distal surface it is located near or cervical to the junction of middle and incisal thirds.

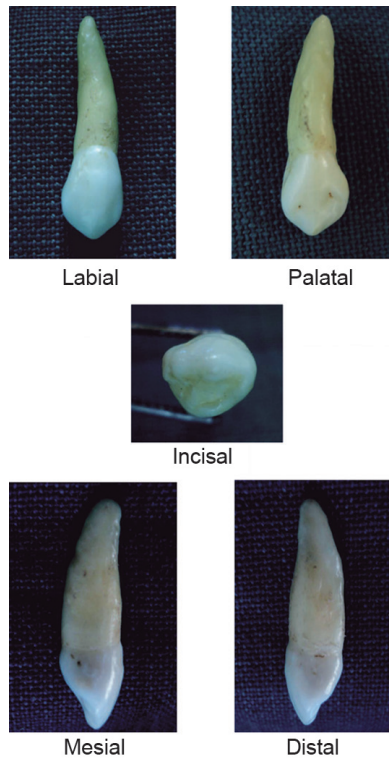
No mamelons are noted normally in this tooth. The tooth converges or tapers in size mesiodistally from the labial side to the lingual side of the tooth as any other tooth does.

The cervical line is slightly convex and the convexity is towards the apex of the root in the center of the crown. This makes the cervical line to appear as a curve or a sickle.

From this view, the root is slightly blunt and cone-shaped. Although, there is a large amount of variation between people, the length of the root is much more longer than the crown and the ratio is about 1:1.6 or 1:1.7. The root also converges apically from cervical third and the root is usually tilted at the apical part towards the distal side. The root may be tilted to the mesial side in seldom cases.



**Fig. 6.1:** Diagrammatic view of all surfaces of maxillary canine



**Fig. 6.2:** Surface views of maxillary canine (Photograph)

### Lingual View

The lingual surface is somewhat smaller because the mesial and distal surfaces of the crown converge towards the lingual surface. The lingual surface of the maxillary canine is very irregular due to distinct mesial and distal marginal ridges, a well-developed cingulum and cusp ridges form boundaries of the lingual surface.

The cingulum is seen as a prominent convexity at the cervical third portion, above the cervical line mimicking a small cusp. Along with pronounced ridges and the cingulum, lingual surface is marked by lingual fossae. A well-defined lingual ridge extends from the cusp tip to the cingulum, dividing the lingual fossa into mesial and distal fossae.

Along the border of mesial and distal sides, marginal ridges are noted. The incisal end is also raised slightly to the level of the marginal ridges and becomes flatter due to masticatory forces, as the age advances. Even the cusp tip becomes blunted along with the age.

Mesial and distal outlines, contact areas and the cervical line are similar to labial aspect.

The root also converges lingually and thus, part of the mesial and distal aspects of the labial surface can be seen. The root is tip blunt and is curved distally.

## Proximal View

The mesial and distal aspects are in a triangular outline. Generally, they resemble the incisors, but are strong at the cingulum region.

## Mesial View

From the mesial side, the crown of the tooth appears as a 'triangle' or 'wedge' shaped with the pointed cusp tip at the incisal area and the base towards the cervix.

The crest of curvature for the labial and lingual surfaces is located at the cervical third area above the cervical line. The labial surface of the crown is more convex and the crest of curvature is at the junction of middle and cervical thirds. The lingual surface of the crown is 'S' shaped and is convex near the cingulum. The concavity is at the lingual fossa area between the cingulum and incisal ridge slope.

Unlike most other teeth, when a line is drawn along the long axis of the tooth, passing through root tip it passes through the cusp tip or slightly lingual meaning the cusp tip is placed central or labially to the line drawn along the crown root axis.

The cervical line from this view curves more towards the cusp tip. In an average crown, the curvature of the cervical line is about 2 mm to 2.5 mm.

## Distal View

The distal view of the tooth is very similar to the mesial side with two changes. The cervical line is less pronounced in comparison to the mesial side. The contact area is located more cervical.

## Incisal View

From this view, the asymmetry of this tooth is readily apparent. Incisally, the crown looks almost bilaterally symmetrical. Overall appearance of incisal aspect is 'conical' or 'triangle'. It is usually thicker labiolingually unlike maxillary incisors which are wider mesiodistally. The mesial half of the crown is more convex and the distal half appears slightly stretched to make contact with the first premolar which has wider contact area.

The cusp tip is placed labially from labiolingual and mesially from mesio-distal directions to the central long axis of this tooth respectively. The labial surface is slightly convex due to prominent labial ridge. The lingual surface tapers towards the cingulum, which is placed at the center. The incisal edge is nearly a straight line, but slightly crescent shaped. The distal slope is longer than the mesial.

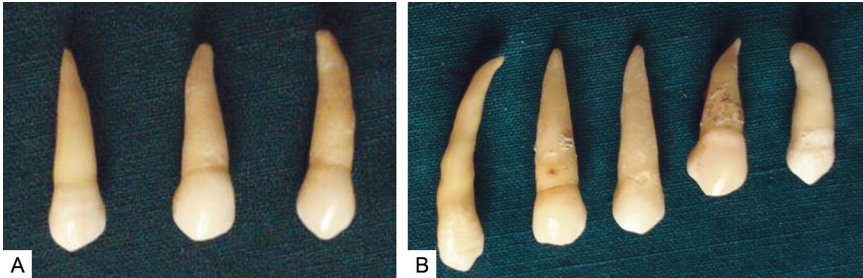**Right and left:** To differentiate right from left canine, look for following points:

- The distal slope is longer than the mesial slope
- The mesial contact point is at the junction of the incisal and middle third. Distally, the contact is situated more cervically at the middle of the middle third
- The mesial surface of the crown is more convex than the distal

- Cusp tip is situated at labial from labiolingual and mesial from mesiodistal directions to the central long axis
- The curvature of cervical line is more towards incisal on the mesial than distal
- The mesial outline is slightly convex, whereas the distal outline is concave at the cervical area.

**Clinical variations:** The maxillary canine usually develops normally (Fig. 6.3A). But rarely shows variations which include the following:

- A pronounced cusp-like tubercle is found on the cingulum
- Lingual pits occur only infrequently
- On rare occasion, the root is unusually longer or unusually short (Fig. 6.3B).



**Figs 6.3A and B:** (A) Permanent maxillary canine with normal crown and root morphology; (B) Permanent maxillary canine teeth with variation in both crown and root length

### MANDIBULAR CUSPIDS (FIGS 6.4 AND 6.5)

The mandibular canine is located distal to mandibular lateral incisors and mesial to mandibular first premolars. Both the maxillary and mandibular canines are called as ‘cornerstones’ of the mouth. These teeth, like the mandibular incisors, are smaller and more slender than the opposing maxillary canine. Like the upper canines, mandibular canines are also single member present on either side of the face. Mandibular canine are not as prominent as maxillary counterparts.

Mandibular canines erupt into the oral cavity before the maxillary canines. Mandibular canines are almost similar in mesiodistal dimension and have smooth surfaces both labially and lingually. Unlike maxillary, the lingual surface is less pronounced and has less prominent cingulum, lingual fossae and lingual ridge. As a group, the mandibular canine act along with maxillary canines in function.

#### Type Traits of Mandibular Canine

- Mandibular canine is also the longest tooth and has a greater length than width. It is larger than the neighboring central and lateral incisors. Both maxillary and mandibular teeth are almost equal in their dimension (including crown and root)
- Unlike maxillary canines, mandibular canines do not have prominent labial and lingual ridges and as well as the cingulum
- The mesial outline of the tooth from labial view is more or less straighter. There is no/very little cervical constriction. So the mesial outline of the crown and root are in line

- From the labiolingual or the proximal view, the cusp tip is positioned more lingual
- Root is conical in shape with prominent developmental depressions on both mesial and distal surfaces.

### CHRONOLOGY OF PERMANENT MANDIBULAR CANINE

- First evidence of classification: 3–4 months
- Crown completed: 4–5 years
- Eruption of tooth: 9–10 years
- Root completion: 11–12 years.

Tooth numbering systems used to designate are:

Dentistry has several systems of tooth notation to identify different teeth.

- In the Palmer system of tooth notation, a number is used in conjunction with a symbol designating in which quadrant the tooth is found. For the permanent teeth, the left and right canine would have the same number '3' but the right side tooth is indicated by '┐' over it and the left one by '┌'
- In the universal system of tooth notation, the right permanent mandibular canine is designated as '27' and the left one as '22'
- The FDI or the international tooth notation system has a different numbering system than the other two. The right permanent mandibular canine is denoted as '43' and the left one by '33'.

Palmer's system	3		3
	┌		
	┐		
Universal system	27		22
	┌		
	┐		
FDI system	33, 43		

### Labial View

From this view, the mandibular canine is distinctly narrower mesiodistally than and appears with that of the maxillary counterpart. The mandibular canine is wider mesiodistally than both lower incisors. The cusp of mandibular canine is not longer and slopes make an angle of about 120° at the tip. The cusp is more blunted than the maxillary and becomes still flatter as age of the individual increases (if more attrition is present, it is difficult to differentiate).

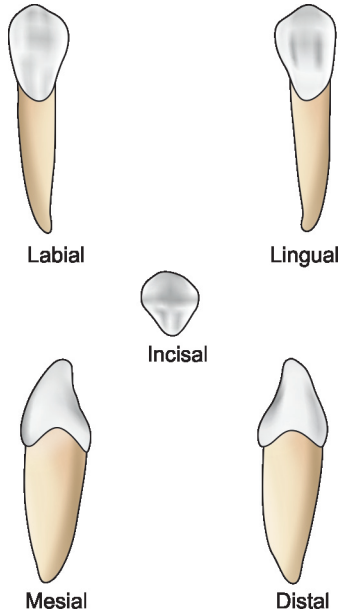
The mesial slope is higher, shorter and almost straighter than the distal slope. Whereas the distal slope is more obliquely placed, longer and runs more cervically from the cusp tip. This makes the tooth very asymmetrical in appearance.

The labial surface of the crown is smoother than maxillary canine due to the presence of less prominent labial ridge.

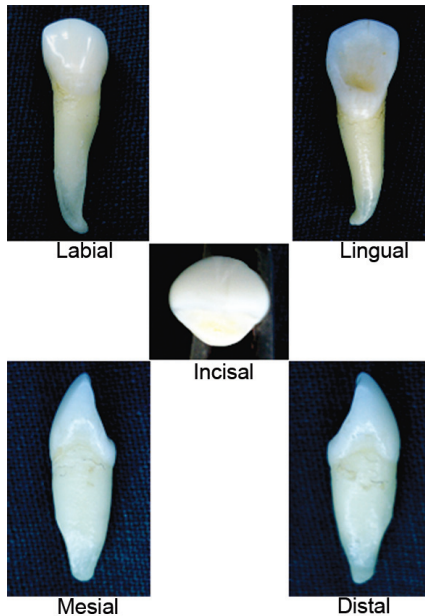
One of the most important characteristic feature is that the mesial outline of both the crown and the root is nearly straight (meaning no cervical constriction on the mesial outline). The distal outline is more convex from the contact area till the cervical third like that of the maxillary canine.

The distal part of the crown appears tilted distolingually to the long axis of the root.

The root is convex and tapers apically. The root is slightly longer than maxillary and is usually straight. In rare instances, it may either mesially or distally.



**Fig. 6.4:** Diagrammatic view of all surfaces of mandibular canine



**Fig. 6.5:** Surface views of mandibular canine (Photograph)

### Lingual View

The lingual outline of mandibular canine is similar to labial outline. The lingual surface is smooth and regular. All features on the lingual surface of the mandibular canine are same to that of maxillary canine. The marginal ridges and cingulum are less prominent, mesial and distal parts of the lingual fossa are shallow. The lingual ridge, if present, is usually quite less defined.

Mesial and distal outlines, contact areas and the cervical line are similar to labial aspect. Both the crown and the root converge lingually and thus, part of the mesial and distal aspects of the labial surface can be seen.

### Proximal View

The mesial and distal aspects have a triangular outline. The cingulum is less well-developed. Unlike the maxillary canine, the cusp tip is placed lingually to the long axis of the root. The labial surface of the crown is less convex and the lingual surface of the crown is shallow 'S' shaped and is slightly convex near the cingulum area.

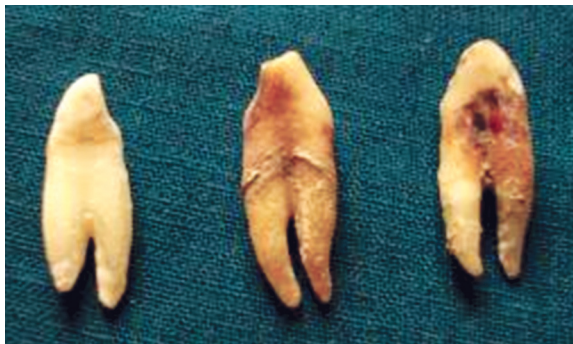### Incisal View

The mesiodistal dimension is less than the labiolingual dimension. The tooth is bilaterally symmetrical. Both the mesial and distal 'halves' of the tooth are more identical than the maxillary canine from this view. The cusp tip is placed more mesial from mesiodistal direction and lingual from the labiolingual direction.

**Right and left:** To differentiate right from left canine, look for following points.

- The distal slope is longer than the mesial slope
- The mesial slope is horizontal and the distal slope is oblique and runs more cervically.

**Variations and anomalies:** One variation of this tooth is noted. On rare instances, the root is bifurcated near its tip (Fig. 6.6).



**Fig. 6.6:** Proximal view of mandibular canine showing bifurcation of roots

## CHAPTER

# 7

# Premolars

*Manjunatha BS*

### INTRODUCTION

As the name indicates, premolars are just located before the molars. A premolar is a tooth that is always present in permanent dentition, located between the canines and molars and are preceded by deciduous molars in the adolescents between 10 to 12 years. These are considered transitional teeth, guiding the food from canines back to the molars for chewing. The major role of premolars is to begin the crushing of foods before they are transferred to the molars for the final grinding. Premolars, mainly first premolars are important component in a pleasant, pleasing smile.

Humans have eight premolars, four in each arch and two in each quadrant which are identified as first and second premolars. Premolars have at least two cusps and one to two roots, firmly implanted in the bone for stabilization.

### FUNCTIONS OF PREMOLARS

In general, both upper and lower premolars function with molars. Premolars are involved in the following functions mainly:

- Mastication of food complementing with molars
- Maintain the vertical height of the face in the check area
- Assist canines in shearing or cutting the food
- These teeth also support the corners of the mouth and cheek to keep them from sagging or drooping. This feature is very well-appreciable in older individuals
- When all or most molars are lost, the individual can still masticate or chew well with the help of premolars.

### CLASS TRAITS [GENERAL CHARACTERS] OF PREMOLARS

- Premolars are commonly referred to as 'bicuspid'. This term is not appropriate, because it denotes a tooth with two cusps. Many a times, the lower second premolar presents with two lingual cusps with a total of 3 cusps
- These teeth strongly resemble canines from buccal aspect and occupy a position between canines and molars in the dental arch. These teeth have a sharp buccal cusp for piercing and an altered occlusal surface for grinding. Hence, functionally and morphologically these are considered as 'intermediate teeth'



- These have strong, well-developed two major cusps, a buccal and lingual of almost similar size. Exception for this is the mandibular first premolar which always has one large buccal cusp and a small lingual cusp which is non-functional
- In the buccal cusp, buccal ridge is well-separated by two shallow depressions on either side called as ‘**Thomas notches**’. These are important and named after Peter K Thomas who recommended, because these act as spillways for food
- Crowns are much shorter than anterior teeth and roots are of same length to that of incisors
- From the buccal view, the crowns appear pentagon shaped formed by two cusp ridge slopes and the mesial and distal sides from contact to cervix
- The crowns from the buccal view are broader at the contact area and are narrower at the cervix
- In premolars, when viewed facially, the buccal cusp tip is always placed slightly mesial to the long axis of the tooth except in the case of the maxillary first premolar where it is located slightly distally
- In premolars, the buccal cusp always shows a longer distal slope than the mesial except in the maxillary first premolar  
Buccal—MS < DS
- In premolars, the buccolingual dimension is broader than the mesiodistal dimension when viewed from proximal aspect  
MD < BL
- The proximal contact is cervically located and much broader than anterior teeth. So it is termed as ‘**contact area**’ in these teeth
- Crest of curvature is generally more occlusally placed on both buccal and lingual surfaces
- Unlike canines and incisors (anterior), premolars have cusps, marginal ridges and grooves oriented in horizontal plane being part of the occlusal surface not the lingual aspect
- Buccal and lingual triangular ridges descend from respective cusps to the central part of the occlusal surface meeting at the central groove and form a transverse ridge. The exception for this is on the three cusped mandibular second premolar without any transverse ridge formation.

### MAXILLARY FIRST PREMOLAR (FIGS 7.1 AND 7.2)

The maxillary first premolar is exactly seen distal to the maxillary canine and mesial to the maxillary second premolar. It is mostly visible and prominent tooth at the corner of the mouth. This tooth replaces the deciduous first molar and erupts approximately at the age of 10 to 12 years. It is much shorter than that of maxillary anteriors and function with maxillary canine in holding and/or cutting food. In general, it complements with canine as well as the second premolar in masticatory function.

## Type Traits of Maxillary First Premolar

- It has two cusps and two roots
- The lingual cusp is shorter than the buccal cusp by 1 mm approximately
- Buccal cusp tip is placed more to the distal and hence the mesial slope is longer than the distal slope
- Buccal cusp is pointed and sharp making an angle of 105° to 110° with mesial and distal slopes
- It has a prominent mesial marginal ridge groove on the mesial surface, crossing the occlusal surface
- Mesial surface has a concavity or a small depression, (termed as ‘**mesial developmental depression**’) just below the cervical line and above the contact area and sometimes as **canine fossa**.

### CHRONOLOGY OF PERMANENT MAXILLARY FIRST PREMOLAR

- First evidence of classification: 1 ½ –2 years
- Crown completed: 6–7 years
- Eruption of tooth: 10–12 years
- Root completion: 12–13 years.

#### Tooth numbering systems used to designate maxillary first premolar are:

- In the Palmer system, the left and right first premolar would have the same number ‘4’ but the right one would have the symbol of grid ‘J’ while the left one would have ‘L’
- In the Universal system, permanent maxillary first premolars are designated by a number. The right permanent maxillary first premolar is denoted as ‘5’ (five), and the left is known as ‘12’ (twelve)
- The FDI system is a different system and the maxillary right first premolar is designated as ‘14’ (one four) and the left first premolar is denoted as ‘24’ (two four).

Palmer’s system	4   4
Universal system	5   12
FDI system	14, 24

## Buccal View

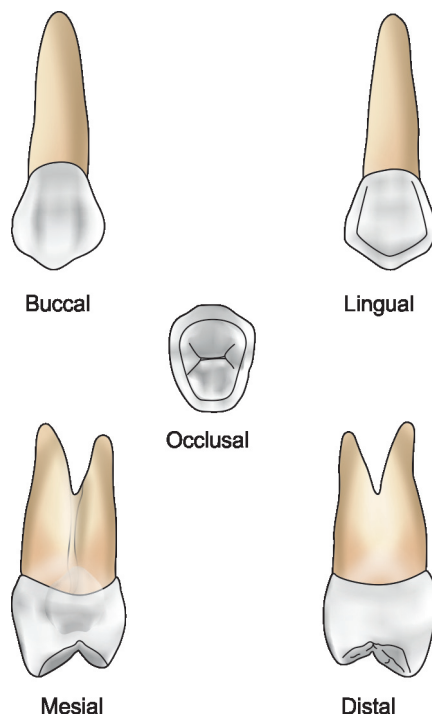
From the facial view, the buccal surface is quite similar to the maxillary canine. The buccal cusp is long, sharp or pointed. The buccal ridge is prominent descends downwards to join the cervical line of the tooth. The mesial and distal slopes make an angle of about 105° to 110°. Unlike canines, the buccal cusp tip is placed slightly to the long axis of the tooth and the mesial slope is slightly longer than the distal slope.

The buccal ridge is prominent and shows vertical depressions on both sides in the occlusal third of the crown, these depressions are termed as ‘**Thomas notches**’.

The mesial and distal outlines are convex from the contact till the cervical third. In the cervical third, due to the presence of mesial developmental depression the mesial outline is concave and slightly straighter on the distal side.

Both contact areas are almost at the same level. The mesial contact area is smaller and is more buccal placed when compared to the distal. The distal contact area becomes boarder as the tooth adjacent is also similar in dimension.

The root is similar to canine which is cone shaped with a blunt apex. The root is shorter than the canine and bends to the distal side at the apical third area.



**Fig. 7.1:** Surface views of maxillary first premolar (Schematic representation)

### Lingual View

The lingual cusp is nearly 1 mm smaller than the buccal cusp and rounded in all aspects. The tooth is narrower on the lingual surface from the buccal surface. The cusp tip is slightly bent toward the mesial side. Both the mesial and distal slopes are almost equal and identical. A part of mesial and distal surfaces and buccal cusp tip are visible.

The lingual root is slightly shorter than buccal and the apical end is tilted to distal side. Root also tapers to the lingual similar to the crown.

### Proximal View

From this view, two cusps and two roots are evident. The lingual cusp is shorter by 1 mm approximately than the buccal cusp.

The buccolingual dimension is wider than mesiodistal dimension. Both buccal and lingual ridges are prominent and are convex.

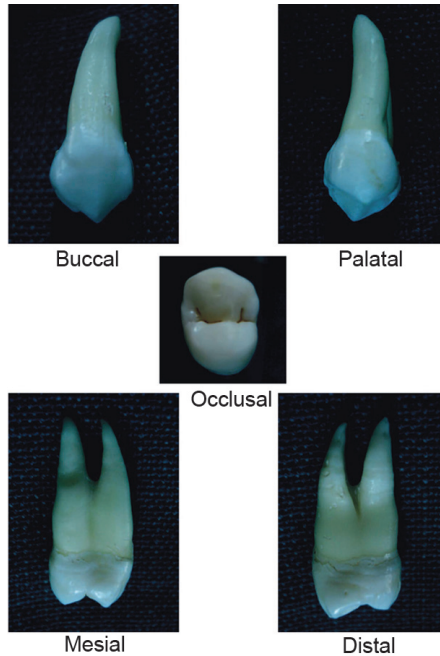


Fig. 7.2: Surface views of maxillary first premolar (Photograph)

### Mesial View

The crest of curvature of the buccal cusp is seen at the junction cervical and middle third area and lingual crest of curvature is more convex located at the center of middle third.

Both buccal and lingual triangular ridges run from cusp tip at about 45° and meet in the center of the occlusal surface.

The mesial aspect of this tooth has a distinctive concavity or a small depression just above the cervical line that extends onto the root termed as the '**mesial developmental depression**', '**mesial concavity**' and also as '**canine fossa**'—a confusing term.

Mesial marginal ridge is transversed or crossed toward the lingual surface by a groove termed as '**mesial marginal groove**'. This is an important feature present in the occlusal third of mesial surface, which is extension of the central groove crossing the mesial marginal ridge.

The cervical line from this view is almost straight and slightly dips towards cusps by about 0.5 mm.

The buccal and lingual root, with bifurcation area are located mainly in the middle third area. Both buccal and lingual roots are convex till middle third and become straighter towards the apex. The root trunk is prominent which is about 6

to 8 mm and has a developmental depression, which runs from the root trunk to bifurcation area.

### Distal View

The distal aspect of the maxillary first permanent molar is quite similar to that of the mesial surface with the following exceptions:

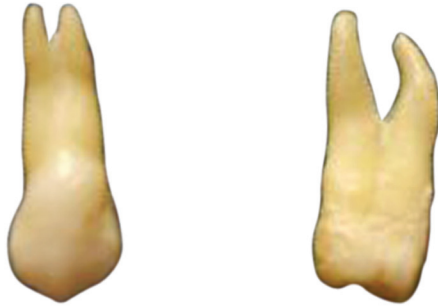
- No concavity or depression in the crown
- No marginal ridge groove
- Cervical line is much straighter than mesial
- The level of marginal ridge is slightly cervical hence more of occlusal surface is seen.

### Occlusal View

The occlusal outline form is roughly the shape of a ‘**hexagon**’-six sided geometric figure. All sides of the hexagon figure are not equal in this tooth. There are two well-defined cusps, buccal and lingual.

Mesial and distal slopes of both cusps form two sides each and remaining two sides are formed by mesial and distal surfaces. The tooth is wider buccolingually than mesiodistally. The buccal cusp is larger and is located slightly distal or almost midway mesiodistally. The lingual cusp tip is slightly shifted mesially. The lingual surface is more rounded than buccal. The buccal outline has pronounced surface due to the presence of prominent buccal ridge. Both the mesial and distal surfaces of tooth converge lingually. The mesial side is shorter than the distal due to the following reasons:

- The mesial surface is in contact with the canine which is not wider when compared to distal surface which contacts the second premolar.
- The lingual cusp is slightly shifted mesially.
- **Ridges:** The occlusal surface is bordered by well-formed mesial and distal marginal ridges at mesial and the distal ends; and by cusp ridges of buccal and lingual cusps. Both the buccal and lingual cusps have triangular ridges which are well-developed. These triangular ridges descend from cusp tips to the center of the occlusal surface to form a transverse ridge. The triangular ridges are well-separated by a long well-defined central developmental groove
- **Grooves:** The central developmental groove divides the occlusal surface buccolingually and extends from the distal marginal ridge to the mesial marginal ridge. The groove crosses the mesial marginal ridge and ends as mesial marginal ridge groove on the mesial surface. The central developmental groove ends as mesial pit and distal pit near the mesial and distal marginal ridges respectively.
- **Fossae:** The occlusal surface has the mesial and distal triangular fossae. The mesial triangular fossa is seen just distal to the mesial marginal ridge, bounded by the mesial marginal ridge, the transverse ridge and the mesial slopes of buccal and lingual cusps. The distal triangular fossa is placed mesial to the distal marginal ridge and the boundaries are similar to those of the mesial triangular fossa.



**Fig. 7.3:** First premolar with incomplete two buccal and lingual roots

**Right and left:** Two distinctive features help in distinguishing right and left:

- The mesial developmental depression and the mesially shifted lingual cusp tip
- The mesial marginal ridge groove is also a clue to differentiate right and left.

**Clinical variation:** Among the maxillary premolars, the first premolar is considered to be morphologically more stable with fewer variations than the second premolar. Most upper first premolars have two roots:

- However, it is found a single root is seen in about 20% of teeth
- Three rooted premolars are found occasionally (Fig. 7.3).

### MAXILLARY SECOND PREMOLAR (FIGS 7.4 AND 7.5)

The permanent maxillary second premolar is the fifth tooth from the midline. It shares a mesial contact with the maxillary first premolar and a distal contact with the maxillary first molar. It replaces the deciduous maxillary second molar tooth. Morphologically, the maxillary second premolar closely resembles the first premolar, with few exceptions. Both maxillary first and second premolar resemble very closely and hence direct comparison is made between these two teeth.

#### Type Traits of Maxillary Second Premolar

- The crown of the second premolar is slightly smaller in all dimensions than the first premolar
- The crown of maxillary second premolar is generally more rounded from all aspects
- The buccal and lingual cusps are of nearly equal height in the maxillary second premolar
- There is no mesial concavity and mesial marginal ridge groove on the mesial surface of crown of the second premolar
- The maxillary second premolar is normally a single rooted tooth
- More variations are observed with maxillary second premolar.

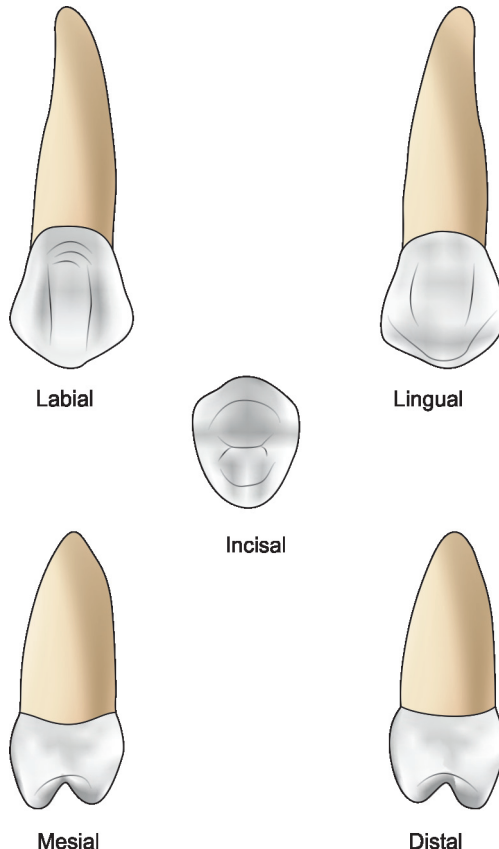
### CHRONOLOGY OF PERMANENT MAXILLARY SECOND PREMOLAR

- First evidence of classification: 2–2 ½ years
- Crown completed: 6–7 years
- Eruption of tooth: 11–12 years
- Root completion: 12–14 years.

**Tooth numbering systems used to designate maxillary second premolar are:**

- In the Palmer system, the left and right second premolar would have the same number '5' but the right one would have the symbol of grid '┘' while the left one would have '└'
- In the Universal system, permanent maxillary second premolars are designated by a number. The right permanent maxillary second premolar is denoted as '4' (four), and the left is known as '13' (thirteen)
- The FDI system is a different system and the maxillary right second premolar is designated as '15' (one five) and the left second premolar is denoted as '25' (two five).

Palmer's system	$\begin{array}{c c} 5 & 5 \\ \hline \end{array}$
Universal system	$\begin{array}{c c} 4 & 13 \\ \hline \end{array}$
FDI system	15, 25



**Fig. 7.4:** Surface views of maxillary second premolar (Schematic representation)

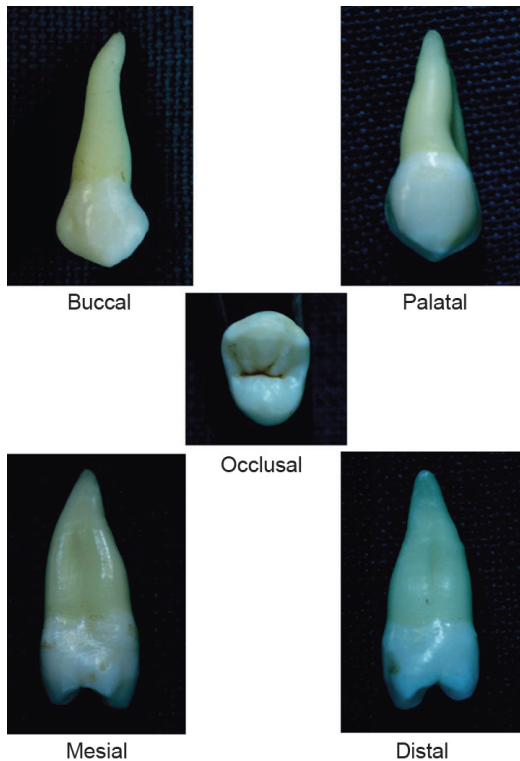


Fig. 7.5: Surface view of maxillary second premolar (Photograph)

### Buccal View

From this aspect, the tooth closely resembles the maxillary first premolar. The buccal cusp is shorter, less pointed and more rounded than the first premolar. The buccal aspect is similar to the maxillary first premolar, but has the following exceptions:

- The buccal cusp of the maxillary second premolar is not sharp or pointed
- The cusp tip is placed slightly to the mesial, thus the mesial slope is shorter than the distal slope. It is the opposite (vice versa) in case of the maxillary first premolar.

The root is normally single, and tapers rather evenly from the cervical line to a relatively blunt apex. It is often bent slightly to the distal in its apical portion. The mesial and distal surfaces of the root are either convex or flat from this aspect.

### Lingual View

The lingual aspect has slight variation to the maxillary first premolar. The following are variations:

- The lingual cusp is of same height to that of buccal cusp, so less of the occlusal surface is visible from this aspect
- The lingual cusp tip is not shifted to the mesial.



### Proximal View

From this aspect, buccal and lingual cusps of same height are noted. The buccal cusp appears to be more prominent than the lingual. Root length is slightly greater than the first premolar and is wider buccolingually than mesiodistally. Buccal and lingual surfaces are convex.

### Mesial View

The mesial aspect in maxillary second premolar is quite similar to the maxillary first premolar, with the following exceptions:

- The two cusps are nearly of the same height
- There is no mesial concavity and somewhat it is flattened or convex
- The mesial marginal ridge groove is usually absent
- Both the contact area and marginal ridge are located at a slightly more cervical level on the mesial than that of the first premolar
- Both cusp tips are wider and placed more apart than in maxillary first premolar. In simple words, the buccolingual dimension is more in second premolar
- The developmental depression on the root is shallow with no bifurcation and root trunk.

### Distal View

The distal aspect is very similar to that of the maxillary first premolar. It has only one exception and it is the contact area, which is slightly broader because distal contact of the second premolar is with the mesial surface of the first molar of permanent dentition.

### Occlusal View

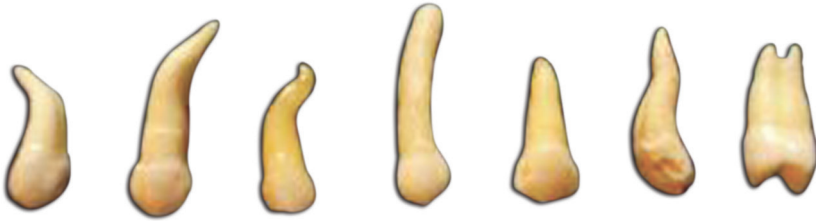The occlusal aspect differs from the maxillary first premolar and most important ones are in the following:

- The line angles of the crown are more rounded, and consequently the crown appears more rounded. The outline is less of hexagonal shape
- The central groove is often shorter and more irregular with the presence of multiple supplemental grooves arising from the central groove. Hence, the surface appears more rough and irregular
- The mesial marginal ridge groove is absent normally, if present, it is quite indistinct
- The lingual cusp tip is not shifted to the mesial side.

**Right and left:** The one consistent clue to right and left is the buccal cusp tip which is shifted mesially. Hence, distal slope of buccal cusp is longer than mesial slope.

#### Variations and anomalies (Fig. 7.6)

- The crown varies more than the first premolar
- There is wide variability in root size, curvature, and form
- The distal bending of the apical third of the root is not uncommon
- There are two roots in many occasions, buccally and lingually positioned, similar to those of the first premolar



**Fig. 7.6:** Maxillary second premolar specimen with variation in root length, size, number, bending, and the appearance

- As with the other maxillary posterior teeth, the root seldom penetrates the maxillary antrum.

### PERMANENT MANDIBULAR PREMOLARS

The two mandibular premolars do not resemble each other nearly as much as do their maxillary counterparts. The buccolingual and mesiodistal crown dimensions are approximately equal. These have two or more than two cusps, and lingual cusps are less prominent than those of the maxillary premolars. The single buccal cusp is always more prominent than lingual cusp/s. From the proximal aspect, the crown tilts toward the lingual. The mandibular premolars are transitional teeth in real sense and the first premolar reflecting the transition from the canine, and the second premolar showing the change toward the molars. These teeth also show great amount of variations in external as well as internal morphology.

### PERMANENT MANDIBULAR FIRST PREMOLAR (FIGS 7.7 AND 7.8)

The mandibular first premolar is present between the mandibular canine mesially and the mandibular second premolar distally. It is a succedaneous tooth, replacing the deciduous first molar. Although this tooth has two cusps, like most premolars, only the buccal cusp is functional and mimics the canine closely.

The mandibular first premolar is closer to a canine than to the other premolar in form and masticatory function. Only in relative size and appearance from the facial aspect this tooth resembles the adjacent second premolar. The mandibular first premolar is smaller in size than the second premolar. The first premolar has a miniature lingual cusp which is non-functional. Hence, the morphology and role in mastication are similar to those of the canine.

### Type Traits of Mandibular First Premolar

- This is the smallest tooth among all premolars
- It has 2 cusps and single root. The lingual cusp is very small compared to the buccal cusp
- The lingual cusp appears as a well-developed (prominent) cingulum and is non-functional. It is almost half or one third the size of the buccal cusp
- Both mesial and distal marginal ridges are angulated at 45°
- The mesial contact is placed at a lower level than the distal
- ‘**Mesiolingual groove**’ is present at the corner of the mesial marginal ridge and the mesial slope of lingual cusp

- The tooth converges to lingual surface. So, most part of the mesial and distal surfaces can be seen from lingual view
- Root is conical in shape.

### CHRONOLOGY OF MANDIBULAR FIRST PREMOLAR

- Initiation of calcification: 1 $\frac{3}{4}$ –2 years
- Completion of enamel: 5–6 years
- Eruption: 10–11 years
- Completion of root: 12–13 years.

#### Tooth numbering systems used to designate are:

Several systems of tooth notation to are used to identify teeth.

- In the Palmer system of tooth notation, the left and right mandibular first premolar would have the same number '4' but the right side tooth is indicated by '┘' over it and the left one by '└'
- In the universal system of tooth notation, the right mandibular first premolar is designated as '28' and the left one as '21'
- In the FDI or the international tooth notation system, the right mandibular first premolar is denoted as '44' and the left one by '34'.

Palmer's system	$\begin{array}{c c} & \\ \hline 4 & 4 \\ \hline \end{array}$
Universal system	$\begin{array}{c c} & \\ \hline 28 & 21 \\ \hline \end{array}$
FDI system	34, 44

### Buccal View

From this aspect the tooth has 'pentagon' outline which is similar to the facial form of both the canine and second premolar. The crown height is shorter than any anterior tooth and longer than the posterior teeth. The buccal cusp tip is pointed and has short mesial slope and longer distal slope. Hence, the cusp tip is placed slightly towards the mesial. The buccal ridge is the prominent on the buccal surface. Both the mesial and distal surfaces are slightly convex to flat, and converge more toward the lingual.

The root is normally single, fairly straight, and its outline tapers from the cervical line to a relatively sharp apex. The root length is considerably less than the lower canine.

The cervical line is slightly convex and curves toward the root apex. The convexity is less than that of the anterior teeth. Mesiobuccal and distobuccal developmental depressions are usually present, but imbrications lines are not normally found.

## Lingual View

The lingual aspect has a small non-functional lingual cusp, which is equivalent to a prominent or well-developed cingulum than the cusp itself. The lingual cusp tip is very short, but may be sharp. The lingual surface is convex from all directions. Most of the buccal half or more of the occlusal table is visible from this aspect because of the small lingual cusp, and the inclination of the crown toward the lingual side. All dimensions from this aspect are less than those of the buccal surface. The lingual surface is much narrower mesiodistally, due to the lingual convergence of the mesial and distal surfaces thus allowing a wider view of most of the mesial and distal surfaces as well.

One of the characteristic or distinguishing features of this tooth is the presence of mesiolingual developmental groove at its mesial and lingual aspects in particular. This groove originates in the mesial pit and crosses the occlusal surface onto the mesial surface near the mesiolingual line angle or corner. It is noticeable from this aspect because of the convergence of the proximal surfaces toward the lingual. The cervical line is slightly convex toward the apical foramen.

## Proximal View

The tooth is wider buccolingually than mesiodistally. The buccal and lingual surfaces are convex, while the mesial and distal surfaces are flat. Developmental depressions on the root are noted occasionally.

## Mesial View

Since the lingual cusp is so short, the mesial surface is roughly rhomboidal in form. The buccal outline is generally convex, and is greatly inclined toward the lingual with the height of contour in the gingival third. This is typical of all mandibular posterior teeth. The lingual cusp is less convex and much shorter than the buccal outline. The crest of curvature is the middle third of the crown and close to the occlusal part of the lingual cusp, since it is short.

The contact area is circular to ovoid in shape and more toward the buccal, located in the middle third.

The mesial marginal ridge is at a more cervical level, because of the fact that the crown is inclined toward the lingual and the buccal cusp tip is located over the center of the root. The mesial marginal ridge is the buccal portion of the transverse ridge slopes from buccal to lingual side at approximately 45° angle and the marginal ridges of other posterior teeth are roughly horizontal. In fact, it more closely resembles the angulation of the marginal ridges of anterior teeth, especially the canine. The distal marginal ridge is longer, more prominent, and does not exhibit as steep slope toward the lingual. Part of the distal marginal ridge is seen from this surface because of more cervical presence of mesial marginal ridge.

As described earlier, the mesiolingual developmental groove is completely visible on the mesial surface near the lingual margin. The cervical line is curved slightly toward the occlusal.

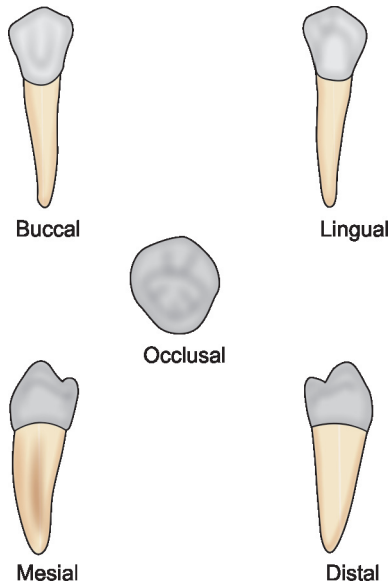


Fig. 7.7: Surface views of mandibular first premolar (Schematic representation)

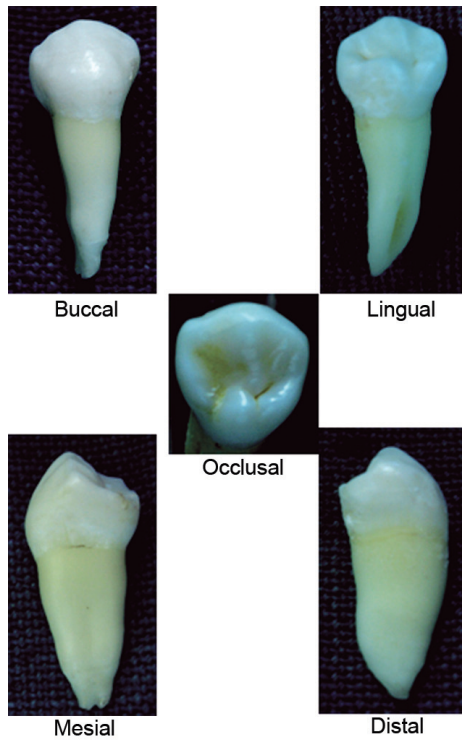


Fig. 7.8: Surface views of mandibular first premolar (Photograph)

## Distal View

The basic outline of the distal surface is similar to the mesial surface, with few exceptions which are as follows:

- There is no distolingual developmental groove at the distal corner
- The distal surface is slightly shorter and is wider buccolingually than the mesial surface because it is in contact with wider second premolar
- The cervical line is slightly less curved
- The contact area is similar, but it is broader in area, since it approximates the second premolar, which is a larger tooth than the canine
- The distal marginal ridge does not slope steeply toward the lingual.

## Occlusal View

From the occlusal aspect, the crown profile is diamond shaped or rhomboidal, with a notch at the mesiolingual developmental groove at the mesial outline. There are two cusps, a buccal and a lingual, with the buccal being much larger, prominent and the only functional cusp. The buccal surface is uniformly convex with presence of the prominent buccal ridge.

The lingual cusp is very small, usually not more than half the height of the buccal cusp. Sometimes, it is more of a tubercle or a prominent cingulum than a true cusp and this cusp is considered normally as a nonfunctional one. The lingual aspect is also convex, but is much shorter than the buccal. Mesially, it has the mesiolingual developmental groove.

Due to the mesial shift of buccal cusp tip and the transverse ridge, the distal end of the tooth appears larger than the mesial. Because of the lingual inclination of the crown, much of the buccal surface is seen from the occlusal aspect.

The buccal cusp tip is located in the center approximately over the long axis of the tooth.

The occlusal surface is bounded by the mesial and distal marginal ridges proximally. The boundaries on the buccal and lingual aspects have mesial and distal slopes of respective cusps.

Unlike in the maxillary premolars, the buccal triangular ridge is considerably larger and longer than the lingual, thus comprising a greater portion of the transverse ridge.

The occlusal surface has two triangular depressions, designated as the mesial and distal fossae. These are bounded by the transverse ridge, the marginal ridges, and the cusp ridges (slopes). The mesial fossa is roughly linear in shape, while the distal fossa is larger and more or less circular.

The central groove extends mesiodistally, which separates the two triangular ridges and ends as mesial and distal pits in the deepest portions of mesial and distal triangular fossae. It is sometimes indistinct, so the two triangular ridges appear to be continuous.

The mesial pit is the terminal part of the mesial developmental groove, located just distal to the mesial marginal ridge and the distal developmental groove positioned in the deepest portion of the distal fossa ends as the distal pit and is very similar to the mesial pit. Both pits are situated at about the midpoint buccolingually on the occlusal surface.

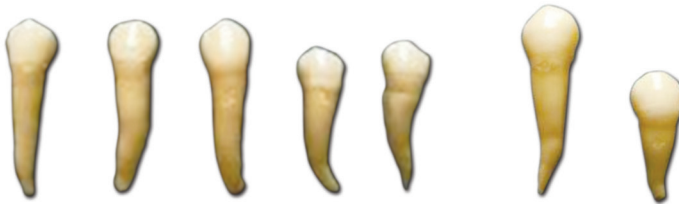The mesial developmental groove extends further from the mesial triangular fossa in mesiolingual direction, where it crosses the mesial marginal ridge onto the mesial and forms the '**mesiolingual developmental groove**'. The distal developmental groove ends at the distal pit and do not cross the distal marginal ridge.

**Right and left:** Two following distinctive features help in distinguishing right and left:

- The mesiolingual developmental groove is a vital clue to differentiate right and left
- The mesially placed buccal cusp tip and more cervically placed mesial marginal ridge.

**Variations and anomalies:** This tooth exhibits wide variation in form (Fig. 7.9). Few common variations include:

- An absence of the mesiolingual developmental groove
- The size of the lingual cusp, which can range from complete absence to nearly as large as the buccal cusp.
- Presence of inconspicuous central groove and the continuity of the transverse ridge
- The root, on rare occasions, may display a bifurcation, thus creating buccal and lingual roots.



**Fig. 7.9:** (A) Mandibular first premolars with variation in root length; (B) Comparison of normal tooth with the short tooth

### MANDIBULAR SECOND PREMOLAR (FIGS 7.10 AND 7.11)

The mandibular second premolar is the fifth tooth from the midline in the lower arch. It is in contact with the mandibular first premolar mesially, and the distal contact with the permanent mandibular first molar. It is the succedaneous tooth for the deciduous mandibular second molar. Unlike maxillary premolars, the mandibular second premolar has a slightly larger crown and a longer root than the first premolar. The opposite arrangement is true for maxillary premolar, where the first premolar is slightly larger. From the facial aspect the crown is similar to that of the mandibular first premolar. However, from all other aspects, few differences are noticeable. There are two general forms of the mandibular second premolar, with the most common form having three cusp form showing two lingual cusps, while the other type displays single lingual cusp. The difference between the two types is largely in the occlusal form and other surface contours are similar. Regardless of the number of lingual cusps, the occlusal table is most similar to that of a small molar. Consequently, this tooth functions in a grinding capacity with the molars, as contrasted to the first premolar which functions much like the canine.

### Type Traits of Mandibular Second Premolar

- Mandibular second premolar occurs in two forms: 3 cusp type and 2 cusp type
- Larger than the mandibular first premolar
- The lingual cusp/s are well-developed and are functional
- The tooth converges very little to lingual surface. No lingual convergence is seen in three cusp pattern
- The occlusal plane (marginal ridges and triangular ridges) is horizontal.

### CHRONOLOGY OF MANDIBULAR SECOND PREMOLAR

- Initiation of calcification: 2–2 ½ years
- Completion of enamel: 6–7 years
- Eruption: 11–12 years
- Completion of root: 12–14 years.

#### Tooth numbering systems used to designate are:

Several systems of tooth notation to are used to identify teeth.

- In the Palmer system of tooth notation, the left and right mandibular second premolar would have the same number ‘5’ but the right side tooth is indicated by ‘ $\neg$ ’ over it and the left one by ‘ $\Gamma$ ’
- In the Universal system of tooth notation, the right mandibular second premolar is designated as ‘29’ and the left one as ‘20’
- In the FDI or the international tooth notation system, the right mandibular second premolar is denoted as ‘45’ and the left one by ‘35’.

Palmer's system	$\begin{array}{c c} 5 & 5 \\ \hline \end{array}$
Universal system	$\begin{array}{c c} 29 & 20 \\ \hline \end{array}$
FDI system	35, 45

### Buccal View

The mandibular second premolar resembles the mandibular first premolar from the buccal, with the following exceptions:

- The tooth is slightly larger and shorter. Since the cusp tip is not as sharp and the mesial and distal slopes are less inclined
- The buccal ridge is less prominent than first premolar.

The tooth appears similar from the facial aspect both in three cusp and two cusp forms. Both mesial and distal outlines are convex from the cusp tip to the contact areas. Both the mesial and the distal contact area are almost at the same level. The cervical line is more or less straighter. The shape of the root from all aspects is similar to that of the first premolar in general. It has a single root, which is broader than the first premolar in mesiodistal direction. The root tapers evenly to the apex which is relatively blunt. It often has a slight distal bend in the apical third.



## Lingual View

The lingual cusp or cusps, better developed and higher in contrast to the first premolar. The lingual surface is generally smooth and convex. The lingual surface is considerably wider mesiodistally, and longer occlusocervically than the first premolar. The lingual cusps are well-formed and are much higher when compared to the first premolar, and hence less of the occlusal surface can be seen from this aspect. The height of the lingual cusp(s) is slightly less than the buccal cusp height.

In the three cusp pattern, the lingual surface has a mesiolingual and a distolingual cusp. The lingual groove extends between the two lingual cusps for a short distance onto the lingual surface. The mesiolingual cusp is wider and longer, while the distolingual cusp is smaller and often sharper among the two. This makes the lingual groove shift to the distal. In this type, the crown does not converge lingually.

The two cusp type has a single lingual cusp and no lingual groove. The single cusp is approximately the same height as that of buccal cusp. The height of contour of the lingual surface is found in the occlusal third of the crown. The crown converges slightly and the cusp is slightly rounded with centrally placed cusp tip.

## Proximal View

The second premolar is wider buccolingually, but slightly shorter in cervico-occlusal dimension. The lingual inclination of the crown is lesser than that of the mandibular first premolar. Both buccal and lingual surfaces are less prominent.

## Mesial View

From the mesial aspect, both (mandibular) premolars are similar, but can be differentiated from this aspect. The buccal cusp tip is shorter, less sharp and so the mesial and the distal slopes are shorter too. The lingual cusps are prominent, well-formed, little shorter than buccal and are not as short as in case of first premolar. The height of contour on the buccal surface is located in the middle third and on the lingual surface it found in the occlusal third. The contact area is broader, roughly circular and is located at the junction of the occlusal and middle thirds, which is more towards the buccal surface than on the mesial contact as in case of the first premolar.

Unlike the mandibular first premolar, both marginal ridges are not inclined at 45° and are nearly horizontal, which makes the occlusal surface less visible except triangular ridges. The mesiolingual developmental groove is not seen normally on the second premolar.

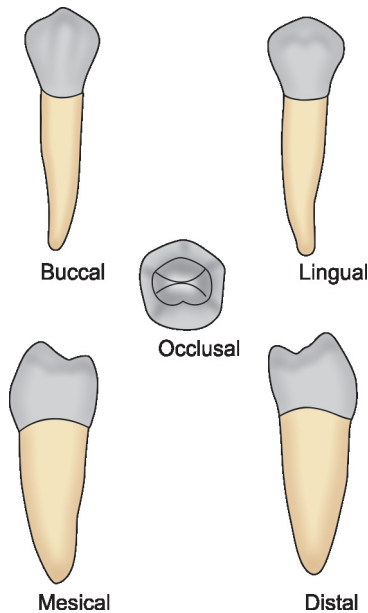
In case of three cusp form, mesiolingual and buccal cusps are visible along with respective triangular ridges. The distolingual cusp and its triangular ridge are not seen as this cusp is shorter than the mesiolingual one.

The cervical line is horizontal and the root converges towards the apex with a blunt root tip.

## Distal View

The distal surface is similar to the mesial surface, except in the following ways:

- The distal marginal ridge is more cervically placed than the mesial, resulting in more of the occlusal surface being visible from this aspect



**Fig. 7.10:** Surface views of mandibular second premolar (Schematic representation)

- In the three cusp type, the tips of both the mesiolingual cusp and the distolingual cusp are visible
- The contact area located similarly which is larger, wider buccolingually and ovoid shape because it is in contact with the permanent first molar.

### Occlusal View

The general shape from the occlusal aspect is more 'square' in the three cusps type and 'rounded' or 'oval' in two cusp type tooth forms. The lingual convergence is not seen in three cusp pattern and a slight lingual convergence is seen in two cusp pattern.

First, we will study about the three cusp type tooth, which is quite common than the other (two cusp type) crown.

- **Three cusp type:** The occlusal outline of the three cusp type tooth is roughly square from lingual to the buccal cusp ridge. The buccolingual dimension is slightly more than mesiodistal dimension.

Two lingual cusps are separated by the 'lingual developmental groove'. All the three cusps vary in height and size; the buccal cusp being the largest followed by the mesiolingual cusp and distolingual cusp is the smallest. Only a part of buccal surface is visible and the mesial slope of the buccal cusp is shorter than the distal. There is no transverse ridge formed even though three triangular ridges from three cusps are present.

The occlusal groove pattern in three cusp form is 'Y' pattern, formed by a combination of the central and lingual grooves. This 'Y' type of central groove is the most common form of mandibular second premolar and is present in the majority of cases.

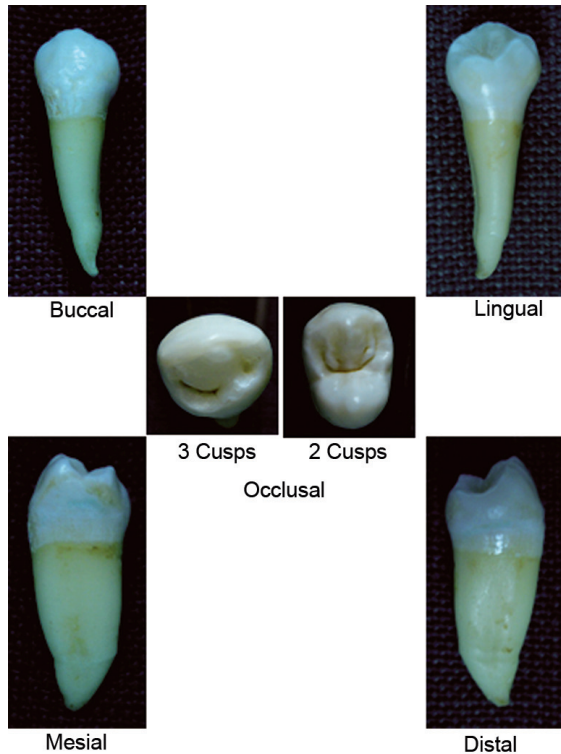


Fig. 7.11: Surface views of mandibular second premolar (Photograph)

There are two triangular fossae; the mesial and distal triangular fossae which are relatively shallow and irregular, more linear in form than the maxillary premolars. These are bounded by two cusp ridges and marginal ridges. The mesial triangular fossa is bounded by the lingual cusp ridges of the buccal cusp, the buccal cusp ridges of the mesiolingual cusp and mesially by the mesial marginal ridge.

There are three pits present on the occlusal surface of three cusp type mandibular second premolar. The mesial pit is located in the deepest portion of the mesial triangular fossa, which is the point of union of two grooves. They are the 'central groove' that extends from the mesial pit to the distal pit in a shallow 'V' form and the 'mesial developmental groove'. Distal pit is seen in the depth of the distal triangular fossa is similar to that of the mesial pit. The central pit is the deepest of the three pits, which is located towards the lingual side and more to the distal, since the mesiolingual cusp is wider than the distolingual cusp. In the central pit, the central groove joins the lingual developmental groove present on the occlusal surface between the two lingual cusps. Thus, the central pit is the junction of two grooves.

- **Two cusp type:** Two cusp type second premolars exhibit a rounded outline lingual to the buccal cusp ridge and the buccal surface is more rounded and

less distinct than in three cusp type. The mesial and distal surfaces converge somewhat towards the lingual surface making the lingual portion narrower than the buccal. This lingual convergence is not to the extent of the first premolar.

The buccal cusp is larger and little higher than the lingual cusp. The lingual cusp is placed directly opposite the buccal cusp and the respective triangular ridges form a transverse ridge. There is no lingual developmental groove or a central pit.

The two cusp type tooth also has two fossae and is roughly circular in shape, termed mesial and distal fossa. They are bounded by the transverse ridge, a marginal ridges and the cusp ridge.

The main groove pattern on the two cusp type resembles a 'U' or 'H'. The central groove extends from the mesial pit to the distal pit and joined by portions of the buccal grooves and few secondary grooves of the buccal cusp. Thus, it can be characterized as crescent shaped.

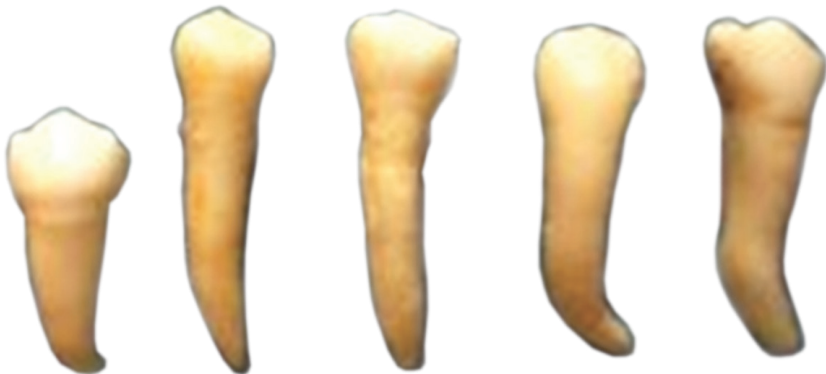
The 'H' pattern is formed by the central groove, portions of the mesial and distal developmental grooves, and the secondary grooves of the buccal and lingual cusps. The central groove runs roughly in a straight line between the two pits, in contrast to the crescent shape of the 'U' type.

**Right and left:** Two following distinctive features help in distinguishing right and left:

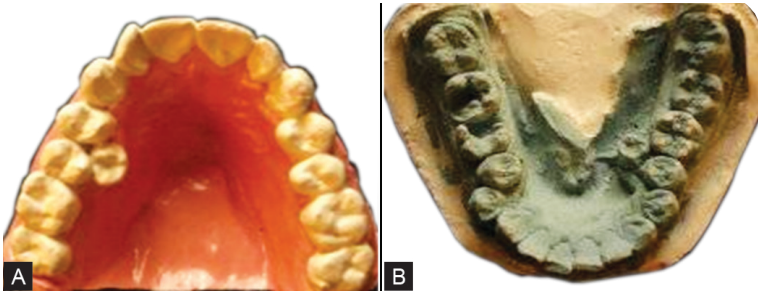
- In three cusp type crowns, the size of two lingual cusps is variable
- Bifurcation of root into buccal and lingual is seen sometimes.

**Variations and anomalies:** Anomalies are rare

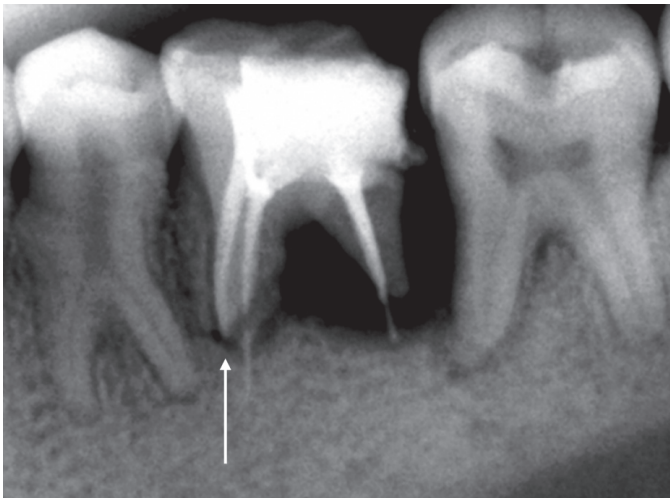- On occasion, the root may be unusually longer or unusually shorter (Fig 7.12)
- Supernumerary teeth termed as 'supplemental teeth' (Fig. 7.13 A) are sometimes observed in the mandibular premolar area (Fig. 7.13B).
- Rarely, the root may be bifurcated near its tip resulting in two incomplete roots (Fig 7.14).
- The mandibular second premolar on occasion, congenitally missing (Fig. 7.15)



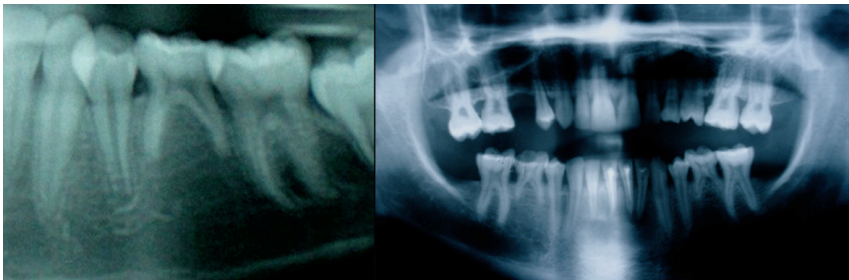
**Fig. 7.12:** Mandibular second premolar with variation in root size



**Figs 7.13A and B:** Maxillary and mandibular casts showing supernumerary teeth in premolar region



**Fig. 7.14:** Two roots in mandibular second premolar



**Fig. 7.15:** Congenitally missing mandibular second premolar

## CHAPTER

# 8

# Permanent Molars

*Manjunatha BS*

## INTRODUCTION

The permanent molars are the largest and most posteriorly located teeth in the dental arch. Molars are present next to the cheek and support the structures present next to the cheek.

The most important function of molars in mastication is grinding. The name ‘molar’ derives from the Latin word ‘mola’ meaning ‘millstone’

In a normal eruption sequence of permanent teeth, molars are the initial as well as the final teeth to emerge into the oral cavity. Eruption of all other teeth takes place between the first and the third molar normally.

The term ‘accessional teeth’ is applicable because these teeth erupt distal to the deciduous dentition and do not replace primary teeth. Permanent incisors, canines and premolars are called successional teeth, which replace deciduous teeth.

Humans and most primates have three molars per quadrant, which are important in chewing and maintaining the vertical dimension. From mesial to distal in each quadrant, they are named permanent first, second and third molars. The first and second molars are also called six year molars and twelve year molars respectively, because of their estimated time of eruption. The third molar, also known as the wisdom tooth is extremely variable in its time of eruption, as well as its anatomical form. Third molars exhibit wide range of variations in crown shape, size, contour and form and root numbers.

Similar to permanent canines, which are considered as cornerstones of each arch, the permanent first molars are known as **cornerstones** in the development of **occlusion**. This is due to early eruption, the location in the arch compared to other teeth of both dentitions.

## FUNCTIONS OF MOLARS

- The main function of molars is grinding of food. So, they are ideally designed and situated to accomplish this role
- They also function in esthetics and phonetics, but are limited and less than the anterior teeth
- The function of esthetics is accomplished by supporting muscles of face and muscles of mastication (this feature can be appreciated very well when all posterior teeth, both premolars and molars are lost, changes in muscle position and function are severe)

- They do help in the maintenance of the vertical dimension
- Molars are very important teeth in occlusion as well. These act as keys to occlusion and also in classification of malocclusion.

### Class Traits of Molars

There are several important features, which help in distinguishing molars from other permanent teeth. They are as follows:

- The crowns are generally largest and complex in morphology
- They have large occlusal surface compared to any of the teeth and have three to five major cusps
- These are the only teeth with two buccal cusps
- Both the buccolingual and mesiodistal dimensions are more than cervico-occlusal dimension
- The crowns are shorter than any teeth with a complex occlusal morphology
- Crown of molars taper from the buccal to the lingual surface except maxillary first molars
- Crown of molar teeth taper cervico-occlusal, buccolingual as well as mesio-distal at the distal side
- They are normally multirooted having more than two roots.

### PERMANENT MAXILLARY MOLARS

The maxillary molars are the largest teeth in the maxillary arch. Their crown is usually shorter cervico-occlusally than the crowns of the anteriors and premolar teeth. Normally, the first molar is the largest in size, and the second and third molars are progressively smaller.

Features of maxillary molars, which aid in differentiating them from other permanent teeth, particularly mandibular molars, include:

- The crowns are rhomboidal in shape
- Crowns which are wider buccolingually than mesiodistally
- The crowns are straighter or vertical and less convex
- Maxillary molars have four well-developed cusps, out of which the two lingual cusps differ the size greatly
- Three cusps are prominent and the distolingual cusp is smaller in size. Hence, a triangular pattern of arrangement takes place between the mesiobuccal, distobuccal and mesiolingual cusps
- One characteristic feature on the occlusal surface is the presence of an '**oblique ridge**', that connects the mesiopalatal and the distobuccal cusp or triangular ridges
- The occlusal surface has two major and two minor fossae
- They have three roots, two on the buccal and one on the lingual (or palatal)
- The trifurcation and bifurcation areas are not closer to the cervical line and so the root trunk is very prominent.

## PERMANENT MAXILLARY FIRST MOLAR

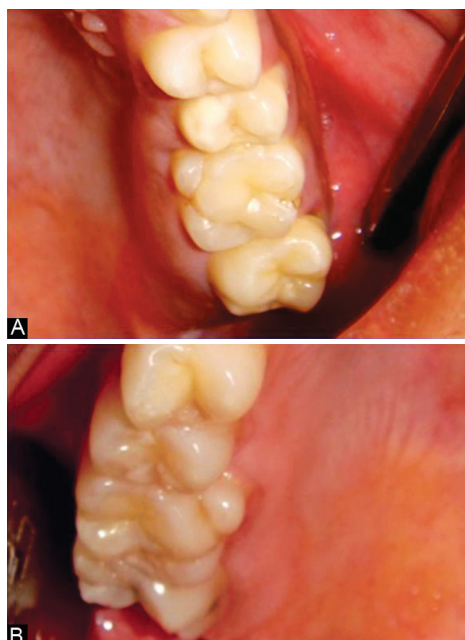
The permanent maxillary first molar is the largest tooth in the maxillary arch and the largest tooth among both dentitions in the mouth. It is the first permanent tooth to erupt into the oral cavity at about six years of age. The permanent first molars are known as ‘**cornerstones of the dental arches**’ in the development of occlusion.

Normally, like other maxillary molars it has three roots, two buccally located and one palatally placed. The two buccal roots are wider buccolingually, while the lingual root is wider mesiodistally. The lingual root outline is generally the largest, followed closely by the MB root outline, while the outline of the DB root is the smallest.

The maxillary first molar is complex in both crown and root form compared to other maxillary teeth. Among all maxillary molars, the maxillary first molar has the least variations in anatomic form and thus has the standard morphology, which the other maxillary molars are always compared. The main function is grinding during masticatory, as with all the molars.

### Type Traits of Maxillary First Molar

- It is the largest tooth in both arches as well as both dentitions
- The maxillary first molar has four well-developed functional cusps and a supplemental or non-functional cusp on the palatal aspect of mesiopalatal cusp. This supplemental or non-functional cusp is called as ‘**cusp of Carabelli**’ or ‘**tubercle of Carabelli**’ (Figs 8.1A and B). This characteristic trait can be used in distinguishing different ethnical populations



**Figs 8.1A and B:** Prominent cusp of Carabelli in permanent maxillary first molar



- The crown is wider buccolingually than mesiodistally
- The crown of this tooth is shorter cervico-occlusally than premolars and anteriors
- All four surfaces of crown have a trapezoidal outline
- The occlusal aspect has a unique rhomboidal configuration with four sides having almost equal dimensions
- All the roots of maxillary permanent tooth are long, divergent and very close to the maxillary sinus.

### CHRONOLOGY OF PERMANENT MAXILLARY FIRST MOLAR

- First evidence of classification: At birth
- Crown completed: 3–4 years
- Eruption of tooth: 6 years
- Root completion: 8–9 years.

#### Tooth numbering systems used to designate maxillary first premolar are:

- In the Palmer system, the left and right first molar would have the same number '6' used in conjunction with the symbol '┘' designating in which quadrant the tooth is found. For this tooth, the right one would have the symbol of grid '┘' and the left side tooth will have the symbol '└'
  - In the Universal system of tooth notation, right permanent maxillary first molar is designated as '3' (three), and the left one as '14' (fourteen).
3. The FDI or the international notation system has a different numbering system than the other systems and the maxillary right first premolar is designated as '16' (one six) and the left first premolar is denoted as '26' (two six).

Palmer's system	<table border="1"> <tr> <td>6</td> <td>6</td> </tr> <tr> <td colspan="2" style="text-align: center;">┘</td> </tr> </table>	6	6	┘	
6	6				
┘					
Universal system	<table border="1"> <tr> <td>3</td> <td>14</td> </tr> <tr> <td colspan="2" style="text-align: center;">┘</td> </tr> </table>	3	14	┘	
3	14				
┘					
FDI system	16, 26				

### Buccal View (Fig. 8.2)

From the buccal aspect, the tooth is trapezoidal in shape with the mesial and distal sides almost parallel to the occlusal surface.

Two buccal cusps and all the three roots are seen from this surface. The mesio-distal dimension on buccal surface is much larger than premolars and anteriors as well and the cervico-occlusal dimension is slightly less.

Two buccal cusps are the mesiobuccal and distobuccal cusps according to their position and are separated by the '**buccal developmental groove**' which extends to middle third area where it most often fades out. Sometimes, the buccal developmental groove may end as a pinpoint depression called as the 'buccal pit'. The two buccal cusps are approximately the same height, and the mesiolingual cusp tip is visible between them. The mesiobuccal cusp is wider, but

the distobuccal cusp tip is sharper. The buccal ridges of both buccal cusps have ridges, which are seen on either side of the buccal developmental groove. In very few cases, the cervical ridge is found which extends mesiodistally in the cervical third of the buccal surface.

The mesial outline is flat from the cervix to the contact area which is located at the junction of the occlusal and middle thirds. The distal outline is convex from the cervix to the contact area which is noted in the middle third. The height of contour of the buccal surface is located in the cervical third.

All three roots are visible from this aspect, with the large lingual root in the center between two buccal roots. The MB root is the second largest and longest of the roots. It inclines mesially and buccally to the apical third, where it curves distally. It is thicker buccolingually, than mesiodistally, and it has a somewhat blunted apex. The DB root is the smallest and shortest, which inclines distally and buccally to the apical third, where it curves mesially. It is little thicker buccolingually than mesiodistally, and tapers to a fairly sharp apex. From the buccal aspect, part of the lingual root is visible between the two buccal roots, and the apex is normally located almost directly under the buccal groove.

The cervical line is irregular and slightly curved apically and the curvature is much lesser than found in anterior teeth or premolars.

### Lingual View (Fig. 8.2)

The lingual surface is more convex than the buccal surface cervico-occlusally. Two lingual cusps, a tubercle on the mesiopalatal cusp termed as '**tubercle of Carabelli**' and the palatal root along with portions of two buccal roots are seen from this view.

The two lingual cusps are of unequal size and are separated by the '**lingual developmental groove**' which is continuous with the distolingual groove of the occlusal surface. The distolingual groove originates on the occlusal surface and crosses onto the lingual surface slightly distal to the center. This groove extends till the middle half and sometimes terminates in a lingual or palatal pit approximately at the middle of the lingual surface. The height of contour is located in the middle third of the lingual surface.

The mesiopalatal cusp is larger, blunt and has a tubercle or small cusp on the palatal portion, known as the cusp of Carabelli. A groove separates the cusp of Carabelli from the mesiopalatal cusp and is named as the 'cusp of Carabelli groove'. The mesial and distal outlines are similar to the buccal aspect. In fact, the mesiolingual cusp is the largest cusp on this tooth.

The palatal root is the largest, longest, and strongest of all the three roots. It is observed that the order of root size corresponds to the cusp size as described above. The palatal root inclines mostly in a lingual direction from the trifurcation. It is wider mesiodistally than buccolingually, a feature which is unique to this root. Portions of two buccal roots are visible from this aspect. The cervical line is similar to the buccal surface.

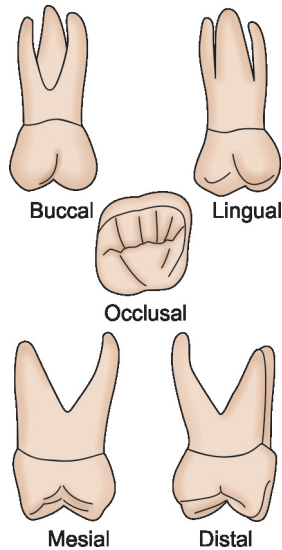


Fig. 8.2: Maxillary right first permanent molar

### Proximal View (Fig. 8.2)

In mesial view, the mesiopalatal and mesiobuccal cusps, the mesial marginal ridge are seen. When present, the Carabelli trait is also noted from this view. In its distal aspect, the two distal cusps are clearly seen; however, the distal marginal ridge is somewhat shorter than the mesial one. A small concavity on the distal surface that continues onto the distobuccal root is occasionally described.

### Mesial View

The mesial surface is roughly trapezoidal, wider at the cervical area than at the occlusal. The buccal outline is convex in the cervical third mainly because of buccal ridges. Then it is flatter or slightly convex till the cusp tip. The lingual outline is convex throughout its length, but may be uneven if the cusp of Carabelli on the mesiopalatal cusp is prominent. The height of contour on the buccal surface is in the cervical third and it is in the middle third on the lingual.

Only two mesial cusps, the mesiopalatal and mesiobuccal cusps are visible from this surface. The mesial surface is wider at the cervical than at the occlusal, due to the convergence of both the buccal and lingual surfaces toward the occlusal and also due to prominent buccal ridges on the buccal surface.

The cervical line is shallow, irregular and curved toward the occlusal. The outline of the mesial marginal ridge curves irregularly toward the cervical line. There is normally a mesial marginal groove notching the marginal ridge outline about midway along its length. Long palatal and the mesiobuccal roots are evident from this surface.

## Distal View

The general outline of the distal surface resembles the mesial surface with few alterations. The mesial cusp tips and part of the occlusal surface are visible above the outline of the distal cusps. The distal marginal ridge is placed cervically than the mesial marginal ridge, thus a part of the occlusal surface is seen. The tooth converges distally from buccolingual dimension; so much of the buccal surface can be seen from the distal aspect. The buccal and lingual outlines are very similar to mesial aspect except for the cusp of Carabelli. The distal contact area is larger than the mesial contact area, irregular and broader buccolingually.

The cervical line is almost a straight line. The furcation area is located more apical than other two surfaces. So long root trunk and shows a depression from the furcation to the cervical line.

## Occlusal View (Figs 8.3 to 8.5)

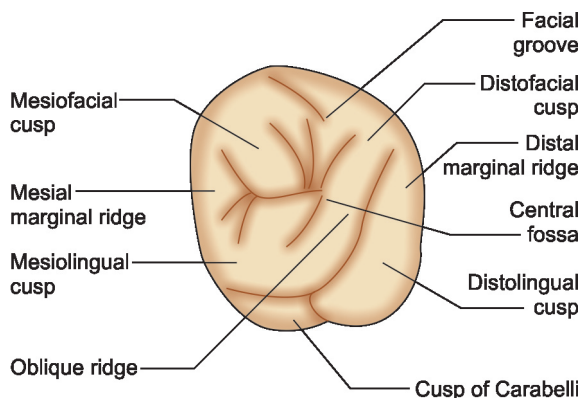
From the occlusal aspect, the tooth has a typical rhomboidal form. According to size, the cusps are arranged as mesiopalatal is the largest among all and is followed by mesiobuccal, distobuccal and distolingual. The mesiopalatal and the mesiobuccal cusps comprise of almost two thirds of the occlusal surface. The one third area of the flat buccal surface and half of the lingual surface are visible from this surface. The mesiobuccal and distolingual angles meet at an acute angle and the mesiopalatal and distobuccal line angles are obtuse.

The buccolingual dimension is little wider or almost equal mesiodistal measurement. The lingual half is slightly wider mesiodistally than the buccal side. This is due to absence of lingual convergence in this tooth. The buccal surface is divided by the buccal developmental groove. The lingual margin is also divided into two convex portions by the distolingual groove. The occlusal surface is bounded mesially and distally by the marginal ridges and on the buccal and lingual by the triangular ridges of the four major cusps.

**Components of the occlusal surface:** For the descriptive purpose and better understanding, the occlusal surface is divided into many parts and explained under various subtitles.

## Cusps

There are four major cusps and one minor cusp, i.e. cusp of Carabelli which is indistinct sometimes. The mesiopalatal cusp is the largest cusp, but its tip is rounded and blunt cusp tip and runs in an oblique direction, where it meets the triangular ridge of the distobuccal cusp to form an oblique ridge. The mesiobuccal cusp is quite sharp and the second largest in size. It extends from the tip as the triangular ridge to the central fossa area lingually and joins the mesiopalatal cusp to form a transverse ridge. The distobuccal cusp is the sharpest and third largest of the four major cusps. The distolingual is the smallest and most variable of the four major cusps (Fig. 8.3).



**Fig. 8.3:** Occlusal view of maxillary first molar showing cusps and ridge (Diagrammatic)

The triangular figure formed by three cusps (mesiopalatal, mesiobuccal and distobuccal cusps), the mesial marginal ridge and the oblique ridge, is characteristic of maxillary molars. The mesial marginal ridge and the oblique ridges form two sides of the triangular outline.

This pattern is also called as ‘**trigone**’ or ‘**primitive triangular molar cusp pattern**’ or ‘**maxillary molar primary cusp triangle**’. The distolingual cusp formed by the respective lobe becomes progressively smaller on maxillary molars from first molar to third molar and is thought as recent acquisition of reflection of the evolutionary origin.

This is explained by the **Cope-Osborn hypothesis** of tooth origin. According to this, there was a stage when the molar forms on the occlusal surface had only three cusps developed. This most critical design is reflected in maxillary molars mainly in second and third maxillary molars.

## Ridges

The occlusal surface of the maxillary first molar has one transverse ridge, one oblique ridge and two marginal ridges (Fig. 8.3).

- **Transverse ridge:** The mesial triangular ridge of the mesiopalatal cusp and triangular ridge of the mesiobuccal cusp form a transverse ridge
- **Oblique ridge:** It is formed by the union of the distal triangular ridge of the mesiopalatal cusp and the triangular ridge of the distobuccal cusp
- **Marginal ridges:** The two marginal ridges are named accordingly as mesial and distal marginal ridges like other posterior teeth. They border the occlusal surface at these two margins. The mesial marginal ridge is longer and more prominent than the distal marginal ridge.

## Fossae

There are four fossae, two major and two minor fossae which are named according to the location as:

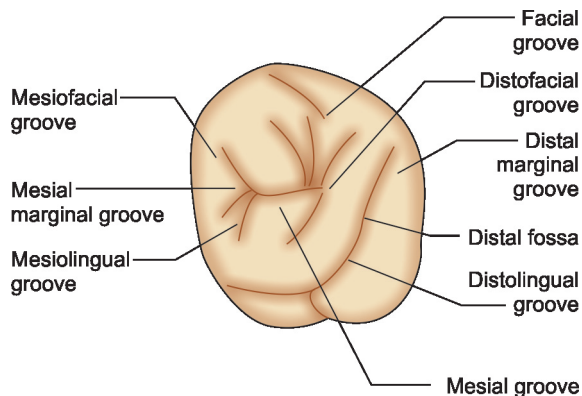
- **Central fossa:** The central fossa is roughly triangular in shape and located mesial to the oblique ridge and distal to the transverse ridge in the center of

the occlusal surface. The central fossa is the largest and deepest and the major fossa among the four fossae. It is bounded by the mesial slope of DB triangular ridge, the oblique ridge distally and the distal slope of the MB triangular ridge, the transverse ridge (formed by MB and MP cusps) mesially

- **Distal fossa:** The distal fossa is linear in shape and located directly distal to the oblique ridge. It is also a major fossa and is continuous with the distal triangular fossa. The distal fossa is bounded by the oblique ridge mesially and the mesial and distal slopes of the DL and DB triangular ridges distally
- **Mesial triangular fossa:** As the name suggests, this fossa is triangular in shape and is located just distal to the mesial marginal ridge. It is bounded by the mesial marginal ridge, the transverse ridge, and the mesial slopes of the MB and MP triangular ridges
- **Distal triangular fossa:** This fossa is also triangular in shape, located just mesial to the distal marginal ridge. It is continuous with the distal fossa in its mesial portion and is bounded by the distal marginal ridge at the distal end.

### Grooves (Fig. 8.4)

- **Buccal groove:** The buccal groove extends from the central fossa in a buccal direction crosses the occlusal surface and continues as the buccal developmental groove on the buccal surface
- **Central groove:** The central groove extends in a mesiodistal direction connecting the mesial and distal triangular fossae. The central extends mesially from the central pit or fossa crosses the triangular ridge and ends in the mesial triangular fossa. The distal extension of the central groove is rare which runs distally crossing the oblique ridge and ends in the distal triangular fossa. This groove is called as transverse groove of the oblique ridge
- **Distolingual groove:** This groove extends from the distal triangular fossa lingually in oblique direction along the distal fossa distal to the oblique ridge and continues onto the lingual surface as lingual developmental groove. The distolingual groove is also known as distal oblique groove
- **Fifth cusp groove:** A groove separates the cusp of Carabelli from the mesiopalatal cusp and is named as the ‘cusp of Carabelli groove’ or fifth cusp groove.



**Fig. 8.4:** Occlusal view of maxillary first molar showing groove pattern (Diagrammatic)

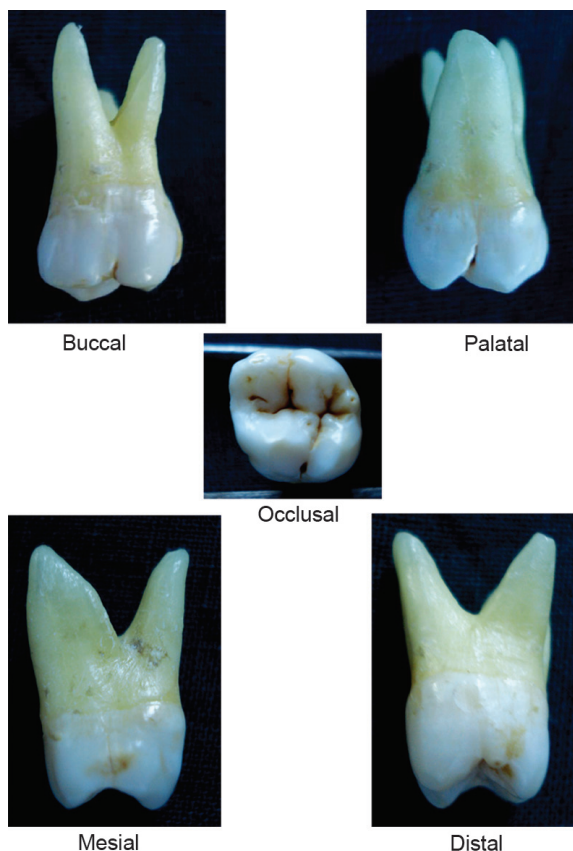


Fig. 8.5: Surface views of maxillary first molar (Photograph)

### Pits

- **Central pit:** The central pit is the deepest portion of the central fossa at about the center of the occlusal surface. This pit is the junction of two primary developmental grooves
- **Mesial pit:** The mesial pit is the deepest portion of the mesial triangular fossa, located just distal to the mesial marginal ridge
- **Distal pit:** The distal pit is a component of both the distal fossa and distal triangular fossa and is located in the area just mesial to the distal marginal ridge.

**Right and left:** The following features help in distinguishing the right and left maxillary first molar.

- The largest mesiopalatal cusp
- Single large palatal root
- Cusp of Carabelli trait.

**Variations and anomalies:** Maxillary first molars are considered to be morphologically more stable and deviation or variation from the normal morphology is uncommon.

1. The most important point is that the crown variations are very minimal or extremely rare. The prominence of the cusp of Carabelli and its groove varies significantly from tooth to tooth, but most people show at least a trace of it
2. A sharp projection of enamel into the furcation area is found in the maxillary molars
3. Root variations are most often evident as fusion of the roots particularly the buccal roots
4. Others such as abnormal root lengths and curvatures
5. Like maxillary posterior teeth, roots of the maxillary first molar may penetrate the overlying maxillary sinus.

### PERMANENT MAXILLARY SECOND MOLAR (FIGS 8.6 AND 8.7)

The crown of maxillary second molar is very much similar in form to the maxillary first molar, but is usually smaller, particularly in the distolingual area. The buccolingual dimension of the second molar is about the same, but mesiodistally it is markedly narrower and also shorter cervico-occlusally. It supplements the function of grinding with first molar. The fifth cusp is not present. Root numbers and contours are similar to those of the first molar and total root length may be equal to, or even greater than in the first molar.

### CHRONOLOGY OF PERMANENT MAXILLARY SECOND MOLAR

- First evidence of classification: 2 ½–3 years
- Crown completed: 7–8 years
- Eruption of tooth: 12–13 years
- Root completion: 14–16 years.

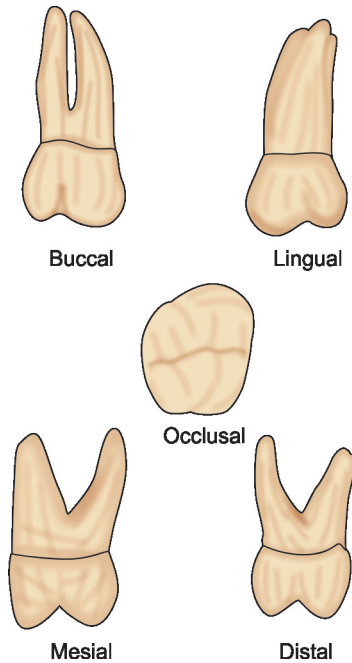
**Tooth numbering systems used to designate maxillary second molar are:**

4. In the Palmer system, the left and right second molar would have the same number '7' used in conjunction with the symbol 'J' designating in which quadrant the tooth is found. For this tooth, the right one would have the symbol of grid 'J' and the left side tooth will have the symbol 'L'.
5. In the Universal system of tooth notation, right permanent maxillary second molar is designated as '2' (two), and the left one as '15' (fifteen)
6. The FDI or the international notation system has a different numbering system than the other systems and the maxillary right second molar is designated as '17' (one seven) and the left second molar is denoted as '27' (two seven).

Palmer's system	<table border="1"> <tr> <td>7</td> <td>7</td> </tr> <tr> <td colspan="2" style="text-align: center;"> </td> </tr> <tr> <td colspan="2" style="text-align: center;">—</td> </tr> <tr> <td colspan="2" style="text-align: center;"> </td> </tr> </table>	7	7			—			
7	7								
—									
Universal system	<table border="1"> <tr> <td>2</td> <td>15</td> </tr> <tr> <td colspan="2" style="text-align: center;"> </td> </tr> <tr> <td colspan="2" style="text-align: center;">—</td> </tr> <tr> <td colspan="2" style="text-align: center;"> </td> </tr> </table>	2	15			—			
2	15								
—									
FDI system	17, 27								

This tooth very closely resembles the maxillary first molar, hence only the differences will be described.





**Fig. 8.6:** Diagrammatic representation of all surface of maxillary second molar

### Buccal Aspect

The crown is narrower both cervico-occlusally and mesiodistally. The buccal developmental groove is situated more distally resulting in a relatively larger mesiobuccal cusp and a smaller distobuccal cusp. The distobuccal cusp is relatively sharper but is shorter. Due to smaller size of the distobuccal cusp, portions of the distal marginal ridge and distolingual cusp may be visible from the buccal aspect on some occasions.

The two buccal roots are have same length and are closer, nearly parallel than in the first molar. They also show more distal inclination and have a greater chance of their fusion.

### Lingual Aspect

The distolingual cusp is much smaller than in the first molar in all dimensions. Thus allows much of the distobuccal cusp to be seen from this aspect. Sometimes, the distolingual cusp is very small or even missing. There is no cusp of Carabelli. The lingual root does not flare so much as in the first molar.

### Mesial Aspect

Cervico-occlusal crown height is less, but the buccolingual dimension is about the same as in the first molar. The contact area appears to be larger, because it is joined with the first molar. The contact area is irregular, ovoid and wider bucco-lingually.

## Distal Aspect

Due to the shorter and smaller distobuccal and distolingual cusps, the mesiobuccal and mesiolingual cusps are visible.

## Occlusal Aspect

The crown is about the same width buccolingually, but is narrower mesiodistally which due to less prominent distal structures. This tooth shows two major types of occlusal form.

The **rhomboidal type** looks much like the first molar, except the rhomboidal outline is more accentuated due to the fact that acute angles are more acute and obtuse angles are more obtuse. This is the **most common** form.

The **heart-shaped** is similar to a typical third molar, with a very small distolingual cusp and short distolingual groove. Sometimes the DL cusp is completely absent and the distolingual groove is confined to the occlusal surface. Cusps, grooves, pits are similar and named like those of the first molar. There are often more secondary grooves on the occlusal surface.

Variations and anomalies:

- The heart-shaped occlusal form is the most common and the DL cusp is absent
- The two buccal roots are sometimes fused together
- Deflections and root curvatures are occasionally severe.

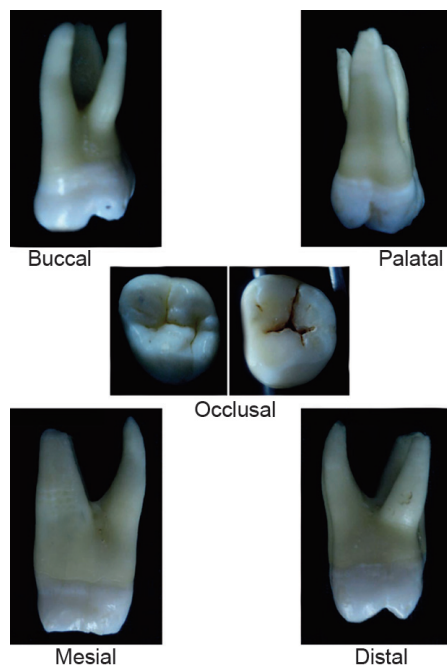


Fig. 8.7: Surface views of maxillary second molar (Photograph)

## THE PERMANENT MANDIBULAR MOLARS

The permanent mandibular molars are three in number and situated in the most posterior part of each lower quadrant. Like their maxillary counterparts, they are named first molar, second molar, and third molar. They are the largest and strongest teeth in the mandibular arch.

Mandibular molars are wider in the mesiodistal dimension. The size normally decreases from first molar to third molar. Mandibular molars are rhomboidal and inclined to the lingual in a proximal view. The crowns are trapezoidal in outline from the proximal and a rectangular or pentagonal outline from the occlusal aspect. Mandibular molars normally exhibit two roots. The mandibular molars function with the maxillary molars in grinding.

### PERMANENT MANDIBULAR FIRST MOLAR (FIGS 8.8 AND 8.9)

The mandibular first molar is located distal to the second deciduous molar in mixed dentition for about five years until the deciduous second molar is replaced by the second premolar. Hence, it is not a succedaneous tooth. The normal eruption time of mandibular first molar is at six years, so it is often called as ‘six year’ molar.

#### Type Traits of Mandibular First Molar

- The mandibular first molars are also considered as the cornerstones of occlusion
- The first molar is the largest and strongest tooth in the lower arch
- This tooth has five well-developed functional cusps and two roots
- The crown is wider mesiodistally than buccolingually
- The mesiodistal dimension is greatest that of any tooth in the mouth
- The crown is relatively shorter cervico-occlusally, which is less than that of both anteriors and premolar teeth
- It exhibits a trapezoidal outline from the buccal and lingual and has a rhomboidal form from the proximal aspect
- From the occlusal aspect the tooth has the ‘pentagonal’ or ‘rectangular’ outline.

### CHRONOLOGY OF PERMANENT MANDIBULAR FIRST MOLAR

- First evidence of classification: At birth
- Crown completed: 2 ½–3 years
- Eruption of tooth: 6 years
- Root completion: 9–10 years.

#### Tooth numbering systems used to designate mandibular first molar are:

- In the Palmer system, the left and right first molar would have the same number ‘6’ but the right one would have the symbol of grid ‘┘’ while the left one would have ‘└’
- In the Universal system, permanent mandibular first molars are designated by a number. The right permanent mandibular first molar is denoted as ‘30’ (thirty), and the left is known as ‘19’ (nineteen)

- The FDI system is a different system and the mandibular first molar is designated as '46' (four six) and the left first molar is denoted as '36' (three six).

Palmer's system	6	6
Universal system	30	19
FDI system	46, 36	

### Buccal Aspect

The lower first permanent molar has the widest mesiodistal diameter of all the molar teeth as well as all teeth in the oral cavity. The buccal surface is the largest surface of the mandibular first molar. It is trapezoidal in outline, with the greatest mesiodistal width at the occlusal margin. The occlusal margin is wider than at the cervical margin. Three cusps and two roots are seen from this aspect.

The buccal surface itself is divided into the mesiobuccal, distobuccal and distal cusps by the mesiobuccal and distobuccal grooves respectively. The mesiobuccal groove is present between the mesiobuccal and distobuccal cusps. This groove extends straight cervically and terminates almost halfway till the middle third and little mesial in the mesiodistal dimension. Sometimes, the groove is fissured and deep forming a pinpoint depression called buccal pit. The distobuccal groove is located between the distobuccal and distal cusps. It runs close to the distal margin and then extends cervically and slightly distally, ends in the middle third.

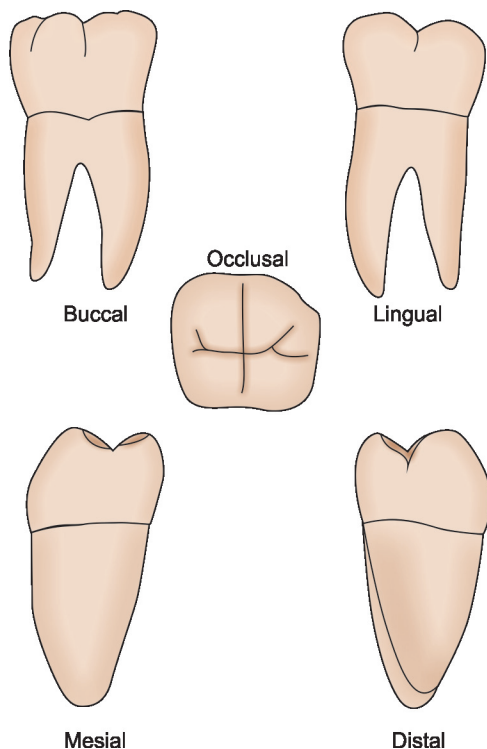
The mesiobuccal cusp is the widest and the largest of all the five cusps. The distal cusp is smaller than any of the buccal cusps and it contributes little to the buccal surface. The mesiobuccal and distobuccal cusp tips are relatively blunt. The distal cusp is placed lower and is sharper than the other two cusps.

The mesial outline is slightly concave from the contact area to the cervix and is convex from the contact to cusp tips in the occlusal third. The distal outline is more convex than the mesial outline. The height of contour of the mesial outline is located at the junction of the occlusal and middle thirds and the distal is slightly more cervical to the junction of the occlusal and middle thirds.

The cervical ridge is not found on all first molars and if present, appear as a mesiodistal convexity in the cervical third of the buccal surface. It is usually more prominent in the mesial end.

All three cusps on the buccal and two lingual cusp tips and two roots are clearly seen. The mandibular first molar has two roots which are wider buccolingually, and both may show developmental depressions on the mesial and distal root surfaces. The two roots are usually about the same length, but the mesial root is slightly longer. Normally, the two roots have slight distal bend or tilt, occasionally they are nearly straight.

The distal root is usually less curved than the mesial root. The cervical line is regular but sometimes it is slightly curved apically.



**Fig. 8.8:** Mandibular right first permanent molar

### Lingual Aspect

The lingual surface is also roughly trapezoidal in outline. The mesial and distal surfaces taper toward the lingual, and hence a little area of both proximal surfaces can be seen from this aspect.

A short lingual developmental groove divides the lingual surface into the mesiolingual and distolingual cusps. The mesiolingual cusp is slightly wider than that of the distolingual cusp. Two lingual cusps are more pointed and placed higher than the buccal cusps. A small portion of the distal cusp is also visible from this aspect.

The lingual groove crosses the occlusal surface seen on the lingual surface slightly to the distal, extends cervically and terminates in the occlusal third or near the junction of the middle third. On rare occasions, it ends in a lingual pit.

The mesial outline is convex and the crest of curvature is in the contact area which is located at the junction of the occlusal and middle thirds. From the contact area, the outline is concave cervically. The distal outline is convex and more convex in the contact area. The height of contour of the distal outline is also at the junction of the occlusal and middle thirds.

The cervical line is located more occlusal than on the buccal surface. It is usually wavy and nearly straight sometimes, can show a pointed projection in the bifurcation area.

### Proximal Aspect

From the mesial and distal aspects, the crown has lingual inclination which is unique to all the mandibular posterior teeth. The crest of curvature of the buccal surface is seen in the cervical third which is due to the cervical ridge. The lingual cusps are pointed and placed higher than the buccal cusps which are slightly blunt.

### Mesial Aspect

The mesial surface is rhomboidal and is wider at the cervical than at the occlusal. The mesial surface is convex in the middle and occlusal thirds. The mesial outline is marked by the mesiobuccal cusp, mesiolingual cusp, and the mesial marginal ridge.

The buccal outline is usually convex from cervical to occlusal, but the convexity is greatest at the cervical third area due to the presence of prominent cervical ridge. The lingual outline is straight or slightly convex at the height of contour in the middle third.

The mesial marginal ridge is confluent with the mesial triangular ridges of the mesiobuccal and mesiolingual cusps.

The mesial root is the broader buccolingually. The cervical line relatively straight or slightly curved occlusally.

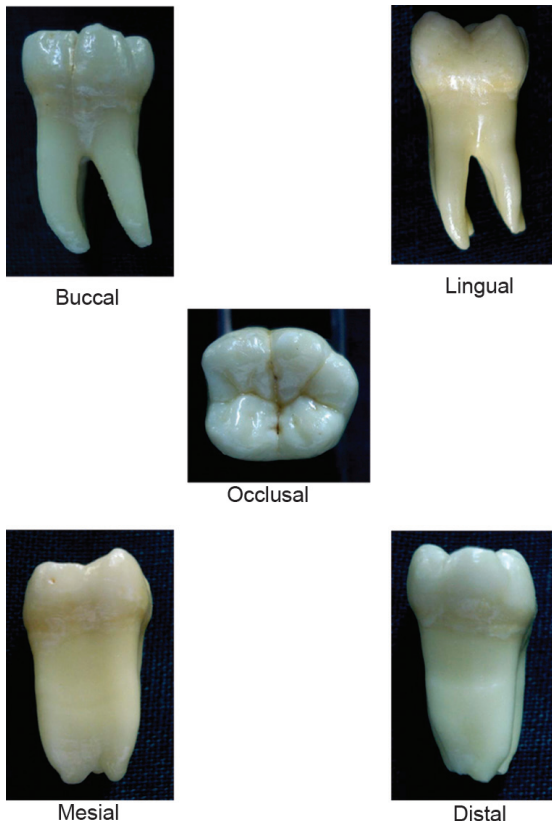


Fig. 8.9: Surface views of mandibular first molar (Photograph)

## Distal Aspect

The distal surface is similar in outline to the mesial, and is also wider buccolingually at the cervical than at the occlusal. The distal surface of the crown is narrower buccolingually than the mesial surface. Three cusps, the distobuccal cusp, the distal cusp, and the distolingual cusp, are seen from the distal aspect.

The distal marginal ridge is difficult to locate from the outline of the distal cusp. Therefore, the height of the distal marginal ridge is dependent on the prominence of the distal cusp. Normally, the distal marginal ridge is located more cervical level than on the mesial. The height of the distal marginal ridge is also variable because of its relation to the distal cusp. The tip of the distal cusp is situated toward the buccal and occlusal to the contact area.

The distal surface is shorter cervico-occlusally than the mesial and so part of the occlusal surface, mainly cusp tips of all five cusps may be seen. The distal cusp is the most prominent feature of this view and part of the buccal surface is equally visible, since it converges toward the distal, resulting in a narrower buccolingual dimension. Because of the convergence from the buccal surface, the distobuccal groove is also visible from this aspect. The distal contact area is ovoid in outline, wider buccolingually since it contacts the second molar and located similar to the mesial.

## Occlusal Aspect

The occlusal form is roughly pentagonal in shape. The crown is wider mesio-distally than buccolingually. The distal portion of the buccal outline tapers more toward the lingual. The mesiodistal dimension at the buccal end and bucco-lingual dimension at the mesial end is more.

The buccal outline is separated into three parts by the two buccal grooves. The relative size of the three cusps decreases. The mesiobuccal is the largest, distobuccal is the next and the distal is smallest. The lingual outline is divided into two parts by the lingual groove. The mesiolingual cusp is slightly the longer and larger among the two. The occlusal surface is bounded proximally by the two marginal ridges.

For better understanding and to put all features in a systematic manner, different components of the occlusal surface are described under various subtitles:

## Cusps (Fig. 8.10A)

There are five cusps normally and all are functional. Regardless of the name, the distal cusp, it is grouped with the buccal cusps as one of the cusps on the buccal aspect. The mesiobuccal cusp is the largest, followed by the mesiolingual, distolingual, distobuccal, and distal cusps. The mesiolingual is higher, followed by the distolingual, mesiobuccal, distobuccal, and distal cusps.

### Ridges (Fig. 8.10A)

- **Transverse ridges:** There are no transverse ridges on the occlusal surface of the mandibular first molar
- **Marginal ridges:** The two marginal ridges, the mesial and distal marginal ridges, border the occlusal surface.

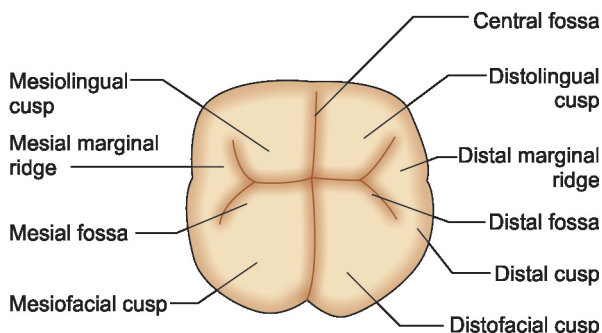


Fig. 8.10A: Occlusal view of mandibular first molar showing cusps and ridge

### Fossae (Fig. 8.10A)

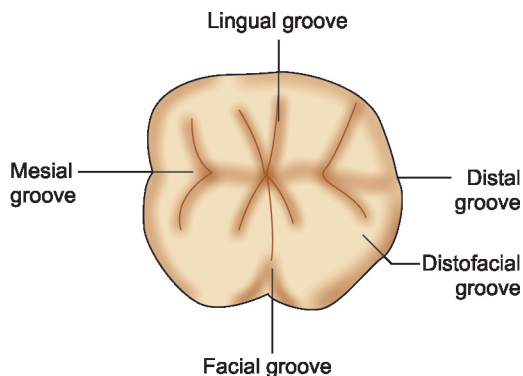
There are three fossae on the occlusal surface.

- **Central fossa:** This major fossa is located in the center of the occlusal table. It is roughly circular in shape and the largest and deepest of the three fossae. It is bounded by the triangular ridges of the four major cusps, as well as the distal slopes of the MB and the ML cusps and the mesial slopes of the DB and DL cusps
- **Mesial triangular fossa:** It is deeper and more prominent than the distal triangular fossa. It is bounded by the mesial marginal ridge, the triangular ridges of the two mesial cusps and the mesial slopes of the two mesial cusps
- **Distal triangular fossa:** It is the shallow and least prominent than other two fossae. It is bounded by part of the distal cusp and distal marginal ridge, as well as the triangular ridges of the distal and DL cusps.

### Pits and Grooves (Fig. 8.10B)

The occlusal surface of the first molar has the most complex groove pattern among the mandibular molars. The two buccal grooves and the single lingual groove form the 'Y' pattern typical of this tooth. The five cusp and 'Y' pattern is important in dental anthropology. The central pit is located in the central fossa and is deep. It is situated in the center mesiodistally and more buccally from BL direction. It is at the junction of three developmental grooves.





**Fig. 8.10B:** Occlusal view of mandibular first molar showing groove pattern

- **Buccal grooves:** The mesiobuccal groove extends from the central pit onto the buccal surface and divides buccal cusps into MB and DB cusps. The distobuccal groove also extends buccally in a distobuccal direction from the central pit onto the buccal surface. The DB groove divides DB and distal cusps.

The lingual groove extends from the central pit lingually onto the lingual surface and divides the lingual cusps into ML and DL cusps.

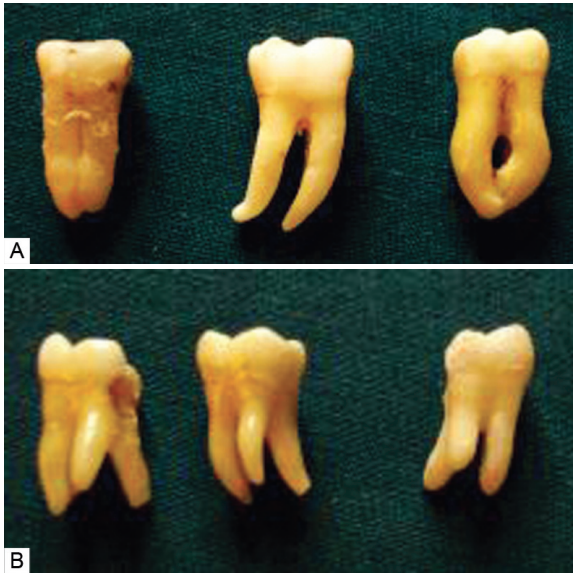
- **Central groove:** The central groove extends mesio-distally from the mesial pit to the distal pit and includes terminal parts of the mesiobuccal and distobuccal grooves as well as lingual grooves.
- **Mesial pit:** The mesial pit is situated in the deepest part of the mesial triangular fossa. The distal pit is located in the distal triangular fossa.

**Right and left:** The following features help in identification of right and left tooth:

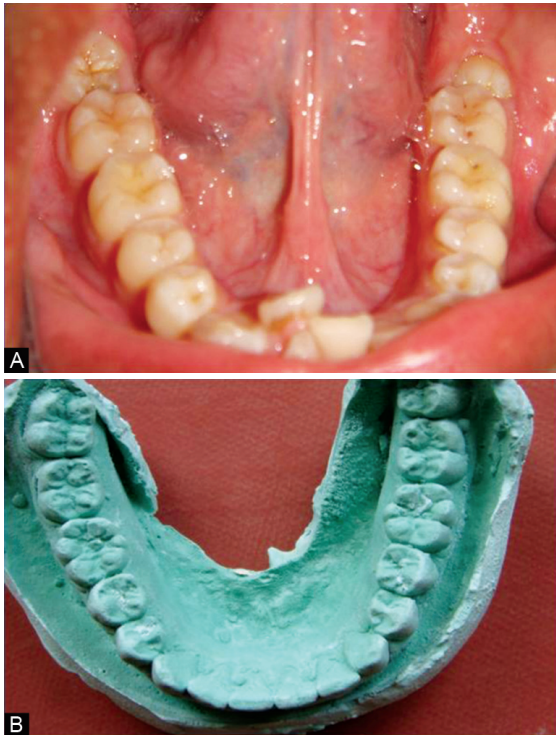
- The buccal aspect has two buccal cusps
- Along with these, the distal cusp provides identification of the buccal aspect
- The distal cusp is the smallest and is displaced along the occlusal aspect.

**Variations and anomalies:** The permanent mandibular first molar exhibits few developmental anomalies.

- **Mulberry molar:** The mulberry molars are a consequence of congenital syphilis
- Normally, roots in first molar are straight with bend/tilt at apical 1/3. Sometimes, roots may be fused, curved or bent (Fig 8.11A) due to periodontal pathologies or trauma. Occasionally, the first molar exhibits three roots, when the mesial root has mesiobuccal and mesiolingual branches (Fig. 8.11B)
- Most teeth have five cusps. Occasionally the distal cusp is missing
- More rarely, in few cases, the distal cusp is joined by a sixth cusp, the 'cusp six' (Figs 8.12A and B).



**Figs 8.11A and B:** Fused, distal tilted, curved and three roots in mandibular first molar



**Figs 8.12A and B:** Six cusps pattern in mandibular first molar seen bilaterally both clinically and in study model

**PERMANENT MANDIBULAR SECOND MOLAR (FIGS 8.13 AND 8.14)**

The mandibular first molar is located distal to the permanent mandibular first molar. It is also known as the ‘twelve year’ molar, due to its normal time of eruption. The second molar resembles the first molar in many respects. It is more symmetrical and smaller in all dimensions than the first molar. It has the least varied occlusal surface among all molars. Normally, this tooth has only four cusps and so there is no distobuccal groove and no distal cusp. The second molar complements the other molars in their grinding function.

**CHRONOLOGY OF PERMANENT MANDIBULAR SECOND MOLAR**

- First evidence of classification: 2 ½–3 years
- Crown completed: 7–8 years
- Eruption of tooth: 11–13 years
- Root completion: 14–15 years.

Tooth numbering systems used to designate maxillary second molar are:

- In the Palmer system, the left and right second molar would have the same number ‘7’ but the right one would have the symbol of grid ‘┘’ while the left one would have ‘└’
- In the Universal system, permanent mandibular second molars are designated by a number. The right permanent mandibular second molar is denoted as ‘31’ (thirty one), and the left is known as ‘18’ (eighteen)
- The FDI system is a different system and the mandibular second molar is designated as ‘47’ (four seven) and the left second molar is denoted as ‘37’ (three seven).

Palmer’s system	$\begin{array}{c c} & \\ \hline 7 & 7 \\ \hline \end{array}$
Universal system	$\begin{array}{c c} & \\ \hline 31 & 18 \\ \hline \end{array}$
FDI system	47, 37

The second molar is very similar to the first molar so only contrasting features with the first molar will be discussed here.

**Buccal Aspect**

The buccal surface like that of the first molar and is trapezoidal. The tooth is shorter cervico-occlusally and narrower mesiodistally.

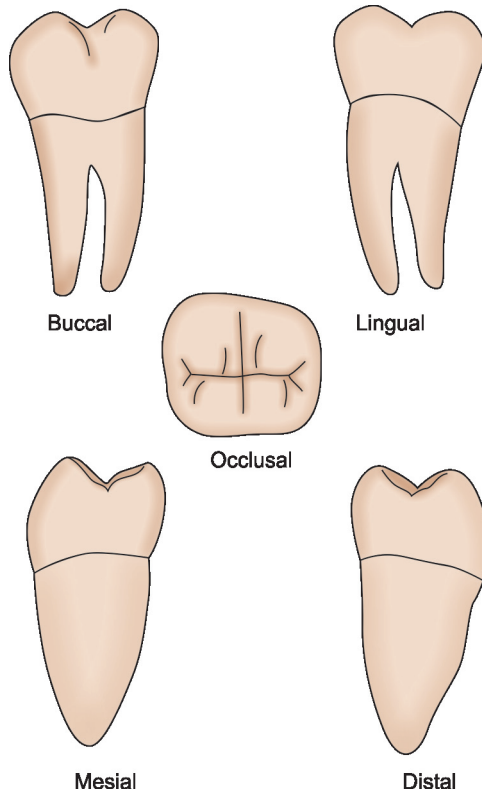
The mesial margin is similar to the first molar and is convex in the occlusal and concave in the cervix. Distal margin is generally convex and more so than the mesial margin. The cervical line normally has little curvature. The occlusal border is separated by the buccal groove and forms the mesiobuccal and distobuccal cusps. Both are about equal in length and cusp outlines. The buccal cusps have buccal ridges on either side of the buccal groove.

The two roots are closer together and partial or total fusion is more common. They usually have a greater distal bend than the roots of the first molar.

### Lingual Aspect

The lingual surface is trapezoidal in outline. It is also shorter cervico-occlusally and narrower mesiodistally than the first molar.

The occlusal part of the lingual outline is divided by the lingual groove approximately the center.



**Fig. 8.13:** Mandibular right second permanent molar

The lingual groove crosses the occlusal outline onto the lingual surface and fades out in the occlusal third. Since the mesial and distal surfaces of the second molar converge slightly toward, partly these surfaces are visible from the lingual aspect. The height of contour in the middle third and other surface contours is similar to those of the first molar.

### Mesial Aspect

The mesial aspect is similar to the first molar except:

- It is smaller in size and is more convex in all directions
- The cervical outline is straighter, cervically positioned on the buccal
- The mesial contact area is definitely ovoid, when compared to the first molar.

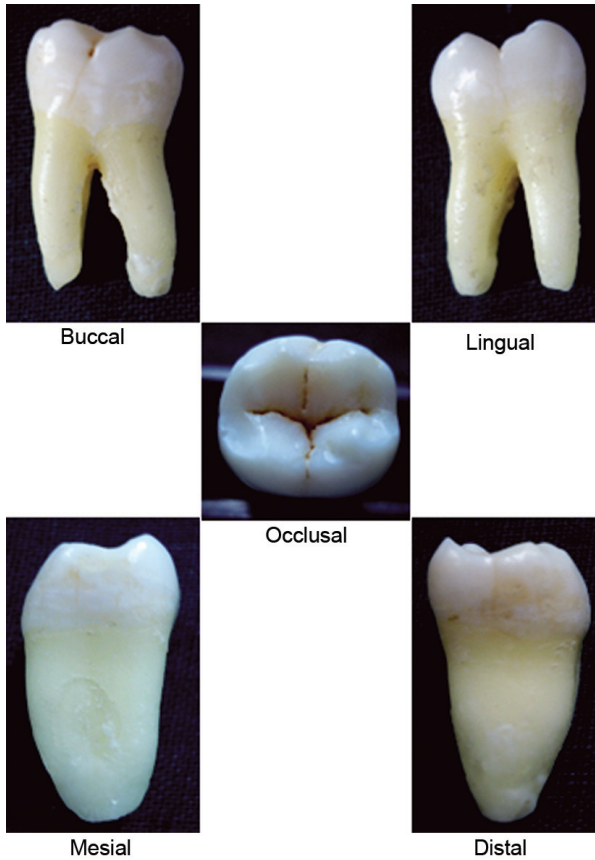


Fig. 8.14: Surface views of mandibular second molar (Photograph)

### Distal Aspect

The distal aspect is similar to the first molar except:

- There is no distal cusp and no distobuccal groove. Since there is no distal cusp, the buccal surface shows much less convergence toward the distal
- The distal surface is about the same size as the mesial surface and only part of the cervical third of the buccal surface is visible
- The contact area is in the center buccolingually and cervico-occlusally.

### Occlusal Aspect

The occlusal surface is rectangular in shape in most of mandibular second molars. Though the occlusal outline is rectangular the mesiobuccal area bulges due to the prominence of the mesial portion of the cervical contour and the lingual inclination of the crowns of mandibular posterior teeth. The occlusal aspect is the simplest of any molar. The occlusal outline is bounded by the two marginal ridges along with the mesial and distal triangular ridges of all four cusps.

There are normally four cusps on the mandibular second molar and all are functional. The cusps are mesiobuccal, distobuccal, mesiolingual and distolingual. All cusps are nearly equal in size than the cusps of the first molar. Yet, the mesiobuccal cusp is normally the largest and the distolingual cusp is normally the smallest. The triangular ridges of the buccal cusps meet the triangular ridges of the lingual cusps to form two transverse ridges.

There are two marginal ridges, which are similar and are same as those of other posterior teeth.

The three fossae are similar to those of the first molar and the central fossa is more regular in shape.

Unlike the first molar, the major groove pattern is almost symmetrical with the central groove and the buccal and lingual grooves join to form a cross pattern. The junction of which is in the central pit. There are more supplemental grooves on the second molar. The central pit is located centrally on the occlusal surface which is the deepest of the three pits, and is formed by the junction of the buccal groove, the lingual groove and the central groove. The central groove extends between the mesial and distal pits in a straight line, which passes through the central pit.

**Variations and anomalies:** Crown anomalies are uncommon.

- Five-cusp crowns are occasionally seen
- Root anomalies are more common and may be fused roots or irregular curvatures.

## CHAPTER

# 9

# Deciduous Dentition

*Manjunatha BS, Rajashekhara BS, Mallikarjuna M Rachappa*

### INTRODUCTION

Until now in this textbook, the deciduous dentition has been given modest importance. Though the deciduous teeth have been given less significance than to the permanent teeth, they are nevertheless important and will be discussed in this chapter.

Until the last decade or so, most parents were responsible of ignoring the value of the deciduous teeth of their children. However, it is very unfortunate that, many dentists also overlooked deciduous teeth. As a consequence, the primary teeth were considered as simply a transitory phase in the more important process of getting a brand new set of permanent dentition.

Occasionally, deciduous teeth were given a little attention and the routine treatment was extraction of any deciduous tooth, which had resulted in pain to the child. The majority of such cases due to or lack of or this attitude of treatment resulted in loss of space with the potential for crowding and malocclusion in the permanent dentition. Fortunately, at present attitudes have changed and the dental profession along with the general public have an extra practical importance of the primary teeth.

As indicated earlier in chapter one, there are a total of twenty deciduous teeth, five per quadrant. Each quadrant has two deciduous incisors and one canine in the anterior segment, similar to that of the permanent dentition. However, deciduous teeth exhibit a functional role similar to their permanent counterparts.

The synonyms of deciduous dentition are:

- Milk teeth
- Baby teeth, meaning they are present during lactation
- Primary teeth
- Temporary teeth
- Juvenile teeth
- Lacteal teeth.

Most important functions of deciduous dentition are as follows:

- Cutting, shearing, grinding and mastication of food substances
- Maintenance of normal facial appearance
- Formulation of normal speech during development
- For proper diet, in turn for general development of an individual (if missing or badly decayed, the child will have food rejection habit)

- To prevent spread of infection and inflammation to the underlying permanent teeth
- For the maintenance of space in the arch
- Directs path of eruption for the underlying permanent teeth.

A brief review of key points of the deciduous dentition which are concerned would be of value to the student. Instead of describing the deciduous teeth in detail as much as the permanent teeth, greater use of comparisons will be made in the subsequent part of this chapter.

### MAXILLARY CENTRAL INCISOR (FIG. 9.1)

The deciduous maxillary central incisor is similar in many aspects to its permanent successor. It is analogous in the position, function and relative shape. In addition to the earlier general features, there are two major specific distinctions to be made out with the permanent maxillary central incisor. The differences are as follows:

- No mammelons are noted in newly erupted teeth
- It is the only anterior tooth having greater mesiodistal width than the cervico-incisal height of the crown.

#### Labial Aspect

The mesial and distal outlines are more convex than in the permanent central. The labial surface is generally convex, smooth and rarely exhibits developmental depressions or grooves. The incisal outline is relatively flat, lacks mammelons and usually slopes toward the distal. The distoincisal angle is slightly more rounded than the mesioincisal angle. The cervical line curves evenly toward the root.

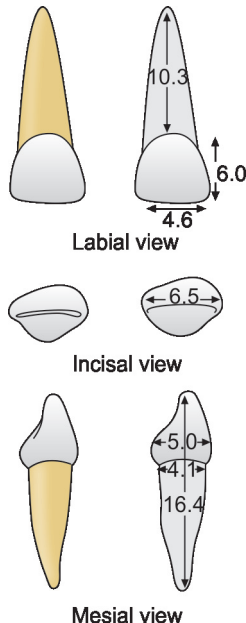


Fig. 9.1: Maxillary central incisor



### Lingual Aspect

The cingulum is prominent and extends incisally than on the permanent tooth. The marginal ridges are also more prominent and the fossa is deeper.

### Mesial Aspect

The mesial surface is similar to that of the permanent tooth except that it is wider labiolingually and the cervical line exhibits less curvature incisally.

### Distal Aspect

The distal is similar to the mesial aspect, except that the cervical line is less curved.

### Incisal Aspect

The incisal edge is almost straight and divides the crown into labial and lingual equal halves. The most important feature is that the crown is relatively wider mesiodistally.

The root is single, usually round and tapers evenly to the apex.

### MAXILLARY LATERAL INCISOR (FIG. 9.2)

This tooth will not be described in detail, since it is very similar to the central incisor. Only the following differences are sufficient to identify this tooth:

- The lateral incisor is smaller than the central in all dimensions
- However, unlike the central incisor, the crown of the lateral incisor is longer cervicoincisally than mesiodistally ( $MD < CI$ )

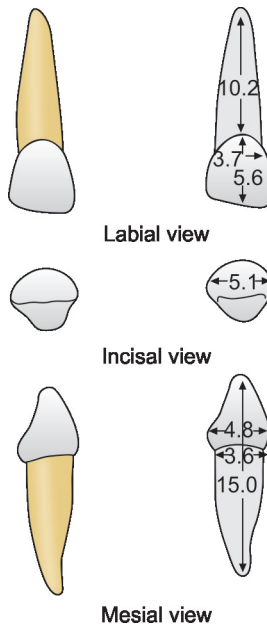


Fig. 9.2: Maxillary lateral incisor

- Both incisal angles are more rounded, with the distoincisal angle more than the mesioincisal
- The marginal ridges on the lingual are more prominent with a deeper lingual fossa
- From the incisal aspect, the mesiodistal dimension is much narrower and more convex
- The root outlines are similar, but the root of the lateral incisor is relatively longer.

### MAXILLARY CANINE (FIG. 9.3)

The crown of deciduous maxillary canine has a wider mesiodistal dimension. However, this is slightly less than the cervicoincisal measurement.

#### Labial Aspect

Similar to the deciduous maxillary incisors, the mesial and distal outlines are convex from the contact area to the cervical line. The height of contour is located at the level of the contact area. Both the mesial and distal contact areas are located at the same level in the middle of middle third area. Prior to cuspal wear, the cusp tip is long and relatively sharper than that of the permanent tooth. The mesial slope is normally longer than the distal slope. The cervical line exhibits an even curvature apically. Normally, no developmental depressions are seen.

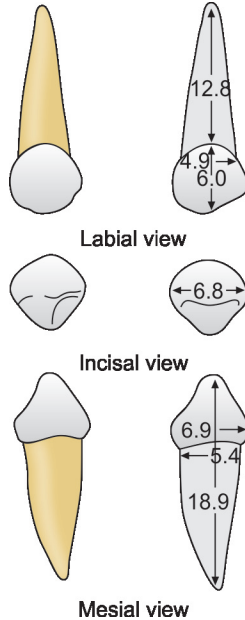


Fig. 9.3: Maxillary canine

### Lingual Aspect

The lingual aspect is more irregular due to the presence of prominent cingulum, lingual ridge and marginal ridges. Normally, the lingual fossa is divided by lingual ridge resulting in ML and DL fossae. Root tapers lingually as well as distally.

### Proximal (Mesial and Distal) Aspect

This is similar to the primary maxillary incisors, except that the labiolingual dimension of the crown and root of the tooth is wider and the cervical line depth is less.

### Incisal Aspect

From this aspect, the outline is rhomboidal, but is more convex than the permanent canine. The cusp tip is placed to the distal and hence the mesial slope is longer. The buccal ridge, cingulum, marginal ridges and the lingual ridge are less prominent than the permanent teeth.

### Root

From all aspects, the root is similar to the deciduous maxillary incisors, except that it is longer.

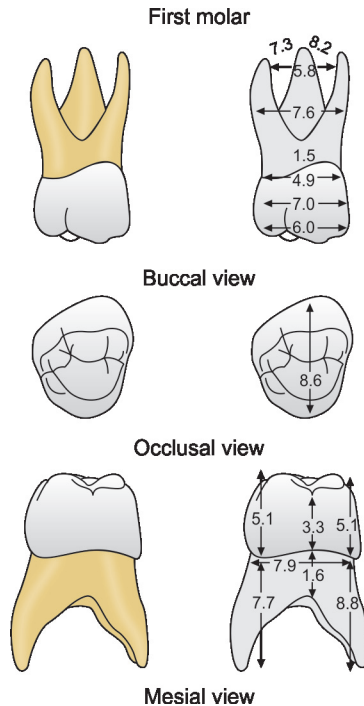
## MAXILLARY FIRST MOLAR (FIG. 9.4)

The crown of this tooth resembles premolars and roots are typical of maxillary molars. The crown does not resemble any other primary or permanent molar crown, but has some similarities to the crown of premolars. However, the roots are classical of maxillary molars. Like all permanent maxillary posterior teeth, the crown has greatest buccolingual dimension. Occlusal surface has only two prominent cusps, the MB and ML cusps. The other two distal cusps, DB and the DL cusp are smaller to a great extent. This characteristic feature has the most striking comparison to a permanent maxillary premolar crown.

### Buccal Aspect

The mesiodistal dimension is much greater than the crown height. The mesial and distal outlines are convex and constrict greatly toward the cervix from the heights of contour which are located at the contact areas near the junction of the occlusal and middle thirds. The buccal ridge is prominent on the mesiobuccal cusp.

The entire surface is relatively smooth and lacks grooves or depressions. Occlusally, the buccal surface is mostly flat, but in the cervical third a prominent ridge in the mesial portion is noted. This ridge is called as '**cervical ridge or buccal cingulum**'. The surface has a crest of curvature in the cervical third. Three roots are seen from this surface which is very similar to other maxillary molars.



**Fig. 9.4:** Maxillary first molar

### Lingual Aspect

The lingual outline is much like that of the buccal view, but with a lesser mesiodistal dimension. Even though the ML cusp is not sharp and prominent, it is quite bulky and seen on the occlusal outline. The DL and the DB cusps are smaller and are also partially visible from this aspect. Unlike the buccal surface, the cervical line is evenly and slightly curved towards the apex. The lingual surface is generally convex and smooth without grooves or depressions. The height of contour is more cervically located, at about the middle and cervical third junction, as compared to permanent maxillary teeth.

### Mesial Aspect

The buccolingual dimension varies at the cervical and occlusal margins. Cervically, the BL dimension is significantly wider due to the prominent cervical ridge on the buccal and also more taper of the buccal and lingual outlines toward the occlusal. The crest of curvature on the buccal surface is in the cervical third, dominated by the cervical ridge. The remainder of the buccal surface is usually straight. The lingual outline is generally convex, but with a more cervically located crest of curvature than on the permanent molars. The two mesial cusps and the mesial marginal ridge are seen from this outline. The ML cusp is higher and bigger in size than the MB cusp. The cervical line is slightly curved toward the occlusal.

## Distal Aspect

The distal surface is considerably smaller than the mesial surface. The buccal surface tapers toward the distal, and hence much buccal surface is visible from this aspect. The DB cusp is more prominent than the smallest DL cusp and the distal marginal ridge is less pronounced than is the mesial. The mesial cusps are seen from this aspect. The cervical ridge is not very prominent in the buccal outline as it is from the mesial aspect. The cervical line is straight to slightly curve occlusally.

## Occlusal Aspect

From the occlusal aspect it is an unusual five-sided figure or oblong shape. The crown converges buccolingually toward the distal and mesio-distally toward the lingual aspects. Among four cusps, the mesiobuccal is the largest and the mesiolingual is smaller and sharper. The distobuccal and distolingual are inconspicuous or absent. The buccolingual dimension is wider than the mesiodistal which is very similar to maxillary premolars.

**Cusps:** Like most maxillary molars, there are four cusps. But the two distal cusps are so small that there is a closer similarity to a premolar from the occlusal aspect. In fact, the lingual side of the triangular ridge of MB cusp is the most prominent single elevation within the occlusal table.

**Transverse ridge:** A very prominent transverse ridge is noted at the mesial end of the occlusal table of this tooth and consists of the lingual slope of the MB triangular ridge and the buccal slope of the ML triangular ridge.

**Oblique ridge:** The majority of specimens exhibit an oblique ridge, extending from the ML cusp to the DB cusp analogous to permanent molars. But, this is not as prominent as that of permanent molars.

**Fossae:** It has three fossae: a well-defined central fossa, mesial and distal triangular fossae. Among three fossae, the mesial triangular fossa is the largest, followed by the central fossa and the distal fossa is smallest.

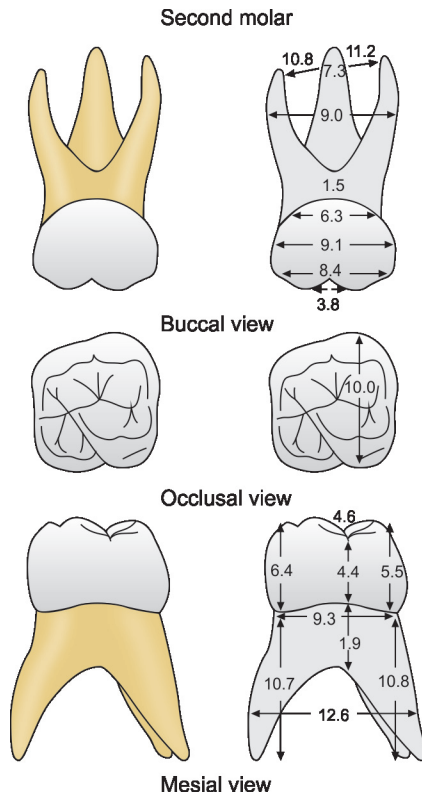
**Pits and grooves:** There are mesial and distal pits, which are located in the depth of their respective triangular fossae. There is also a central pit, with a central groove connecting it with the mesial and distal pits. The buccal groove, which also originates in the central pit, extends buccally, separating the MB and DB cusps extending to the occlusal third of buccal aspect. The distal triangular fossa also contains a groove, which extends obliquely and parallel the oblique ridge just distal to it.

**Roots:** As previously described, deciduous molars have little or no root trunk and the roots are more slender and flare more. The lingual root is the largest and longest, followed by the MB root and the DB root respectively.

## MAXILLARY SECOND MOLAR (FIG. 9.5)

It is not needed to explain this tooth in detail. In spite of the many differences between deciduous and permanent molars, deciduous second molars closely resemble the permanent first molars. Other than general differences, this tooth follows the permanent tooth in its contours, occlusal pattern and roots. In fact this

tooth, even exhibits either a prominent or a trace of the cusp of Carabelli trait in most specimens.



**Fig. 9.5:** Maxillary second molar

### MANDIBULAR CENTRAL INCISOR (FIG. 9.6)

The mandibular central incisor crown is symmetrical, when viewed from the labial, lingual, or incisal, just like its permanent successor. This tooth bears a much closer resemblance to the deciduous mandibular lateral incisor too, or to any deciduous maxillary incisor. In relation to the height, the crown is relatively wider mesiodistally than in permanent incisors. However, the mesiodistal dimension is not greater than the cervico-incisal dimension, as in the case of the deciduous maxillary central incisor.

#### Labial Aspect

The mesial and distal outlines are evenly convex from the sharp mesio-incisal and disto-incisal angles to the cervical line. The convexity is less than the deciduous maxillary incisors. The height of contour is at the contact area in the incisal third. The incisal margin is almost straight and no mammelons are noted. The labial surface is smooth, flatter and lacks developmental depressions. The root is single,

relatively long, and slender. the mesial and distal surfaces of the root are flat to some extent.

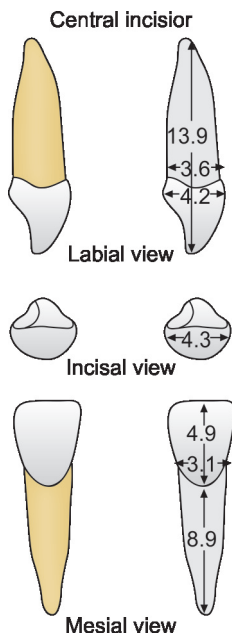


Fig. 9.6: Mandibular central incisor

### Lingual Aspect

The cingulum is well-formed but the marginal ridges are not so well-developed as in the maxillary incisors. The lingual fossa is quite shallow and linear.

### Mesial Aspect

From this view the labiolingual width is greater, when compared to the permanent incisors. The incisal edge is located in the center over the root center. The cervical line contour is evenly curved toward the incisal. The labial and lingual surfaces of the root are convex.

### Distal Aspect

The distal surface is similar to the mesial, except that the cervical line exhibits less depth of curvature.

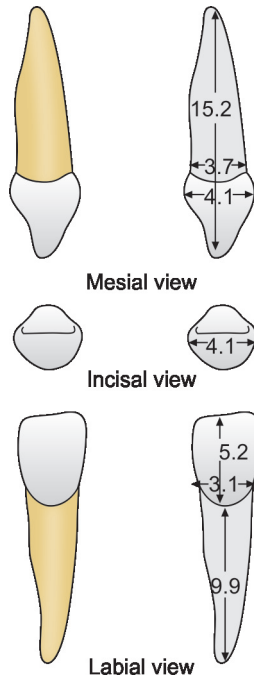
### Incisal Aspect

From this view, the incisal edge is straight and it divides the labial and lingual into nearly equal halves. The mesiodistal and labiolingual dimensions are nearly equal. Like the permanent counterpart, the mesial and the distal halves of the crown are symmetrical.

**MANDIBULAR LATERAL INCISOR (FIG. 9.7)**

It is similar to the deciduous mandibular central incisor, with the following exceptions:

- The crown is slightly longer cervicoincisally and wider mesiodistally
- From the labial, the incisal edge slopes slightly toward the distal and the distoincisal angle is more rounded. The distal margin is also a little shorter
- The cingulum and marginal ridges are slightly larger and the lingual fossa is a little deeper
- From the incisal aspect, the crown is not symmetrical like the central
- The root shows a distal curvature in its apical third.



**Fig. 9.7:** Mandibular lateral incisor

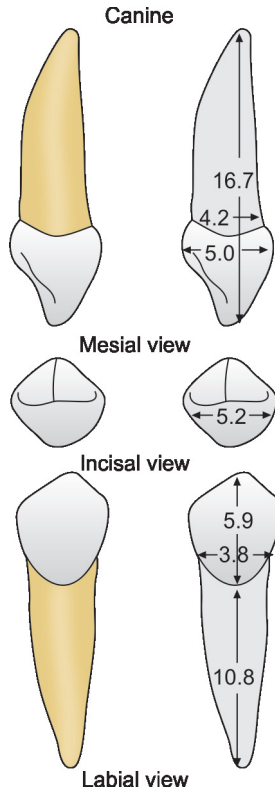
**MANDIBULAR CANINE (FIG. 9.8)**

In general, it resembles the deciduous maxillary canine. But the relative dimensions are somewhat different and are less. The most important contrasts with the maxillary canine are:

- The mandibular canine is a much narrower tooth labiolingually
- The mesiodistal width of the mandibular canine is also considerably less than that of the maxillary canine. The cervicoincisal dimension of the two deciduous canines is the same



- The distal slope is longer on the mandibular canine, whereas on the maxillary canine, the mesial slope is longer
- The cingulum, marginal ridges and cervical ridges are less pronounced on the mandibular canine
- The mandibular canine root is shorter.



**Fig. 9.8:** Mandibular canine

### MANDIBULAR FIRST MOLAR (FIG. 9.9)

The crown of deciduous mandibular first molar does not resemble any other primary or permanent tooth and hence has no analogous tooth in both dentitions. However, it has two roots which are similar to other mandibular molars. The crown is wider mesiodistally than buccolingually, which is characteristic of all mandibular molars in both dentitions.

#### Buccal Aspect

From this aspect, two buccal cusps are seen, of which the MB cusp is much larger. A shallow depression separates the two buccal cusps, but it rarely contains the buccal groove extend onto the buccal surface in the depression. The cusp outlines

are prominent than those of the deciduous maxillary first molar. The mesial outline is straight its entire length cervico-occlusally, but the distal outline is convex. The cervical line is deeper and more toward the mesial. The cervical ridge is also quite prominent, especially in the mesial portion. This cervical bulge is also known as ‘**tubercle of Zuckerkandl**’.

Both roots are wide buccolingually. The mesial root is longer and wider than the distal root. The distal root is short and the root apices are normally flat with rounded tip.

### Lingual Aspect

The lingual surface is smooth and convex and has no any depressions or ridges. The cervico-occlusal measurement on the lingual surface is shorter than the buccal surface. The lingual surface shows two lingual cusps, of which the ML cusp is larger and sharper. Cusp tips of the two buccal cusps can also be seen. The mesial and distal outlines are similar to the buccal aspect and the cervical outline is almost straight.

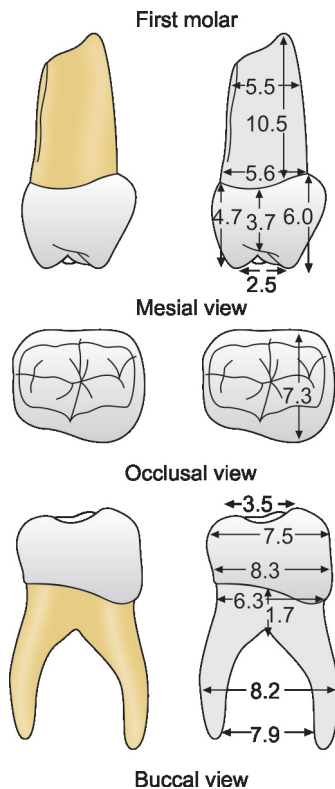


Fig. 9.9: Mandibular first molar

### Mesial Aspect

From this view, a prominent feature is the presence of cervical ridge on the buccal surface. Both ML and MB cusps are visible. The cervical line is located farther cervically on the buccal, and extends to a more occlusal level at the lingual.

### Distal Aspect

All four cusps are visible from this aspect and the MB cusp is the longest. The distal marginal ridge is less prominent than the mesial and is located more cervically. The cervical line is relatively straight.

### Occlusal Aspect

The occlusal outline is rectangular. The crown is wider mesiodistally, which is characteristic of mandibular molars.

- **Cusps:** It has four cusps, the MB, ML, DB and DL from largest to smallest in size. The two mesial cusps are much larger than the distal cusps, similar to the deciduous maxillary first molar.
- **Transverse ridge:** The buccal part of the ML triangular ridge and the lingual part of the MB triangular ridge form a prominent transverse ridge.
- **Fossae:** Three fossae are present as in the case of the deciduous maxillary first molar.
- **Pits:** There are only two pits. The central pit is the deepest pit, located in the central fossa. The central fossa is toward the distal margin rather than centrally located. The mesial pit is in the depth of the mesial triangular fossa.
- **Grooves:** The central groove crosses the transverse ridge and connects the mesial and central pits. The buccal groove also originates in the central pit and extends buccally between the two buccal cusps. A third groove originates in the central pit and extends lingually is called as the lingual groove which separates the two lingual cusps.
- **Roots:** The mesial and distal roots are similar to those of permanent mandibular molars. Both roots are wider buccolingually. The mesial root is longer and wider than the distal root.

### MANDIBULAR SECOND MOLAR (FIG. 9.10)

The deciduous mandibular second molar closely resembles the permanent mandibular first molar and it will not be necessary to describe it in detail. Other than the size and few general features are used in differentiating:

- The MB, DB and distal cusps are nearly equal in size on the deciduous tooth
- The occlusal outline is relatively narrower buccolingually and less pentagonal than the permanent first molar
- The mesial root is longer and wider than the distal root on the deciduous tooth, whereas both are of equal length on the permanent first molar.

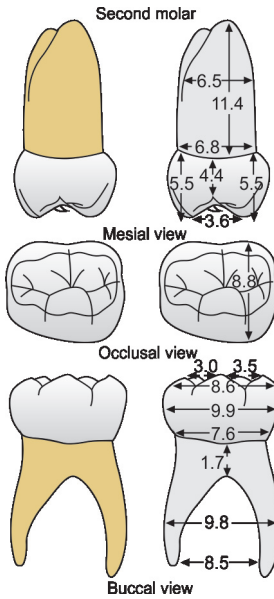


Fig. 9.10: Mandibular second molar

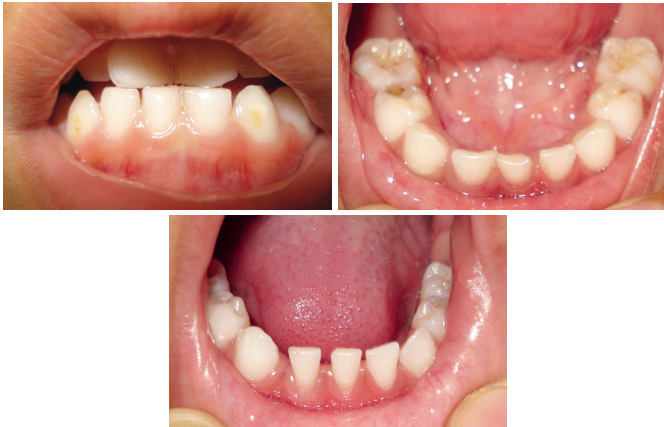

Fig. 9.11: Congenitally missing incisors

## CONCLUSION

Although deciduous teeth are replaced by the succedaneous teeth, they play a very important role in the proper alignment, spacing, and occlusion of the permanent teeth.

The deciduous incisor teeth begin to erupt from six months, they are functional in the mouth for approximately five years, while the deciduous molars are functional for approximately nine years. Hence, deciduous teeth have considerable functional significance. When deciduous teeth are lost prematurely, this results in improper alignment of the permanent teeth. Congenitally missing deciduous teeth is infrequent or very rare (Fig. 9.11). So, healthy, well-aligned deciduous teeth are important in a

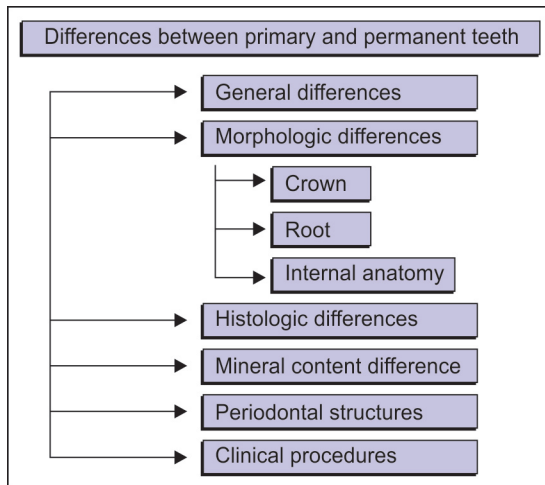
child, if not may have difficulty chewing and may not be able to eat a well-balanced diet.

## DIFFERENCES BETWEEN DECIDUOUS AND PERMANENT DENTITION

### TABLE 9.1

#### Introduction

The appearance of individuals keeps changing as they become older. This is also applicable with the jaws and the teeth. Human beings have two sets of dentition. This is already discussed in detail in previous chapters of this book. The first set of dentition (deciduous) is replaced by the second set (permanent) as per the body needs for esthetic harmony and functional efficiency.



Consequently, the appearance of teeth from deciduous to permanent also changes, which are not limited to the size and shape. There are various other differences and similarities among both the dentitions. The differences can be categorized as follows.

The differences between deciduous and permanent teeth are enumerated as follows:

**Table 9.1:** List of differences between deciduous and permanent dentition

Sl. No	Features	Deciduous	Permanent
<b>General features</b>			
1.	Total number	20, 5 in each quadrant	32, 8 in each quadrant
2.	Premolars	Absent	Present
3.	Molars	Only 2	3 in number
4.	Posteriors—largest	Second molars	First molar
5.	Duration	Short period	Lifelong
6.	Beginning of eruption	At six months	Six years
7.	Complete set of teeth	2½ to 3 years	18 to 21 years
8.	Presence in oral cavity	6 months to 13 years	6 years onwards (lifelong)

Contd...

Contd...

**Morphological features**

9.	Crown size	Smaller in all dimensions	Larger in all dimensions
10.	Width and height	Mesiodistal is more than cervico-occlusal (short)	Cervico-occlusal is more than mesiodistal except molars (long)
11.	Color	Milky white to bluish	Yellowish white to grayish
12.	Cervical ridge	More prominent on buccal aspect of all teeth	Flatter, occasionally pronounced in molars
13.	Occlusal table	Narrow	Wide
14.	Developmental grooves and depressions	Few and less prominent	More and are prominent
15.	Cervix	More constricted	Less constricted
16.	Contact area	Small	Broad
17.	Molar appearances	Bulbous and sharply constricted at cervix	Wider and less constricted
18.	Occlusal plane	Flat (cusps and grooves are less prominent)	More curved (prominent cusps and grooves)
19.	Supplemental grooves	More	Less
20.	Roots	Longer and slender	Shorter and bulkier
21.	Furcation	Close to the cervix	More apical
22.	Root trunk	Smaller	Larger
23.	Root—MD dimension	Narrow	Wider
24.	Molar roots—flaring	More (contain permanent tooth buds)	Less or no flaring (within the boundaries of the crown)
25.	Crown root ratio	Less (roots are longer than crown)	More (relatively less of about 1:1.5)
26.	Root resorption	Present and is physiological	Absent and if seen, pathological
27.	Exfoliation	Present and physiological	Absent and pathological
28.	Internal anatomy	Closely resembles external anatomy	Less resembles, especially in pulp chamber anatomy
29.	Pulp chamber—size	Large	Small
30.	Pulp horns	Prominent, higher and close to surface	Less prominent, placed lower and more apical
31.	Mamelons	Not present	Common in newly erupted
32.	Canines	Slender and conical	Long and bulbous
33.	Roots in anterior	Labially tilted	Distally tilted
34.	Anatomical variations	Less	Common
35.	Structural variations	Absent or very minimal	Common e.g. fluorosis, Turner's hypoplasia

Contd...

Contd...

**Histologic differences**

36.	Enamel—thickness	Thinner and uniform of about 2mm	Thicker and varies, ranges from featheredge to 2.5mm
37.	Enamel—rods	Slopes occlusally	Slopes gingivally (cervically)
38.	Pulp—wall and floor	Thicker, and porous	Less thicker not porous
39.	Pulp—cellularity and vascularity	High	Less
40.	Repair	High chances and faster	Less and if slow
41.	Root canals	Thin, curved and branched	Well-defined, less branched
42.	Apical foramen	Large	Constricted
43.	Nerve endings in pulp	Cell free zone and odontoblastic area	Extend beyond the odontoblastic area into the predentin
44.	Nerve innervations	Less	More
45.	Mineralization	Less	High
46.	Neonatal lines	Present, in all teeth (teeth develop before birth)	Absent, seen only in first molars
47.	Dentinal tubules	Less regular	More regular
48.	Total dentin thickness	Half that of permanent	Double that of primary
49.	Interglobular dentin	Absent	Present below the mantle dentin
50.	Dentino enamel junction	Less prominent and linear	More prominent and scalloped
51.	Cementum	Thin and mainly primary	Thick and secondary
52.	Pulp—infection and inflammation	Poorly localized	Well-demarcated
53.	Periodontal problems	Less	Common
54.	Age changes	Less (present for short duration)	More (lifelong)

**Clinical procedures**

- Cavity preparations: Enamel and dentin in deciduous teeth are thinner, hence modifications in cavity are required

55.	Cavity size	Small	Large
56.	Cavity depth	Shallow	Deep
57.	Cavity width	Narrow	Broad
58.	Cavity walls	Less converging occlusally	more converging occlusally
59.	Proximal walls	More converging occlusally	Less converging occlusally
60.	Bevel	Not given	Given at gingival seat

Contd...

*Contd...*

## • Endodontic treatment

61.	Pulpotomy—molars	Involvement of furcation more (thin pulpal floor)	Involvement of furcation less
62.	Pulpectomy—molars	Difficult (thin, curved and irregular canals)	Relatively easy (Well-defined and straight canals)

## • Surgical procedures

63.	Roots—anterior	Conical, facilitate easy removal	Long, conical and distally tilted. Extract carefully
64.	Roots—posterior	Roots divergent extract carefully, premolar buds located between roots	Roots fused or distally tilted



# CHAPTER 10

## Occlusion

*Manjunatha BS, Narayan Kulkarni, Ramesh Naykar*

### INTRODUCTION

Occlusion is key to dentistry, generally means the teeth contact relationship in function that is common to all branches of dentistry. The complex nature of temporomandibular joint (TMJ) and facial musculature, the teeth can meet in variety of occlusal positions. Thus, few concepts of occlusion vary with almost every specialty of dentistry.

The term occlusion is derived from the latin word ‘occlusio’ which means to close.

Occlusion in prosthetics, is simply be defined as contacts between teeth of upper and lower jaw

According to Ash and Ramfjord, occlusion in periodontics may be defined as “the contact relationship of the teeth in function or para function”.

According to Angle, occlusion in orthodontics is “the normal relation of the occlusal inclined planes of the teeth when the jaws are closed”.

Mosby’s dental dictionary (Zwemer 1998) defines occlusion as “a static morphological tooth contact relationship”.

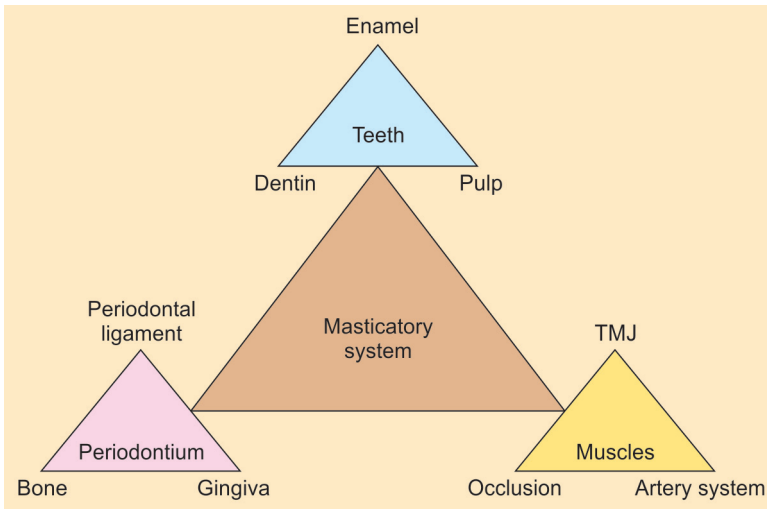
Malocclusion is any deviation from the normal range of occlusion is known as malocclusion.

Before discussing about the occlusion, first let us know the bigger picture of occlusion that forms a part of the stomatognathic system or the masticatory system. Occlusion consists of 3 components (Fig. 10.1):

- Teeth
- Periodontium
- Articulatory system.

Occlusion is the contact between teeth and has types which are as follows:

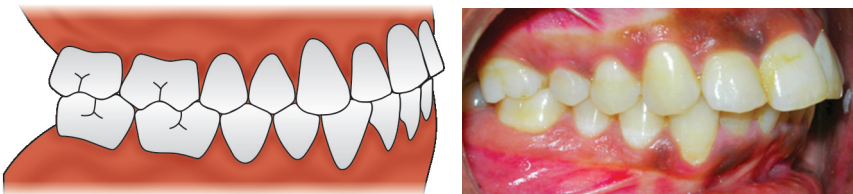
- **Static occlusion:** The occlusion produced when the mandible is closed and stationary
- **Dynamic occlusion:** When the mandible is moving relative to the maxilla.



**Fig. 10.1:** Components of masticatory system

**Static occlusion:** It is the contact between teeth of both jaws, when the mandible is closed and kept stationary is termed as ‘the static occlusion’.

- a. **Centric occlusion:** It is the occlusion when a person gets his teeth close together in maximum intercuspation. It is also referred to as ‘intercuspaton position bite of convenience’ or ‘habitual bite’.
  - It is the occlusion; the individual always closes the teeth together
  - It is the ‘bite’ that is most easily recordable and generally reproducible
  - It is the occlusion to which the patient is accustomed.
- b. **Centric relation:** It is the bony jaw relationship of maxilla and mandible to the cranium. It is reproducible with or without teeth present in the oral cavity. It has nothing to do with teeth.
- c. **Molar relation:** Molar relation was first proposed by Angle who classified various molar relations and are as follows:
  - *Class I:* The mesiobuccal cusp of the permanent maxillary first molar occludes in the groove between the mesiobuccal and distobuccal cusps of the permanent mandibular first molar (Fig. 10.2)



**Fig. 10.2:** Class I molar relation

- *Class II:* The distobuccal cusp of the permanent maxillary first molar occludes in the groove between the mesiobuccal and distobuccal cusps of the permanent mandibular first molar (Fig. 10.3)

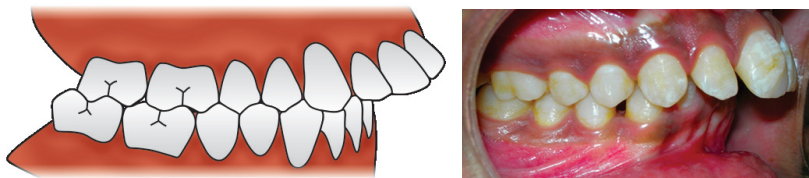


Fig. 10.3: Class II molar relation

- *Class III:* The mesiobuccal cusp of the permanent maxillary first molar occludes in the interdental groove between the permanent mandibular first and second molars (Fig. 10.4).

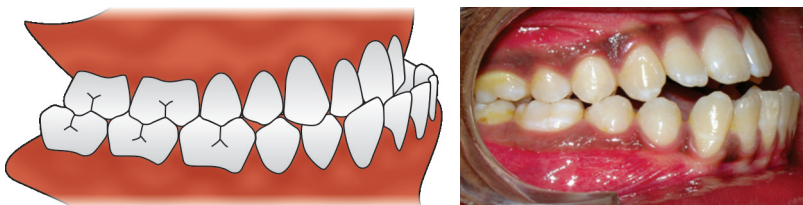


Fig. 10.4: Class III molar relation

- d. **Overjet:** Ideally maxillary incisors are present labial to mandibular incisors in the horizontal plane. The horizontal distance between the lingual surface of maxillary incisors and the labial surface of mandibular incisors is called as '**overjet**'. Ideally overjet should be 2 mm, but a variation of 2–4 mm is considered normal. Overjet is usually found to be increased beyond normal range in patients having Angle's class II malocclusions except Angle's class II div II. Edge to edge bite or reverse overjet (maxillary incisors located lingual to mandibular incisors) is usually observed in Angle's class III malocclusions. Even in Angle's class I malocclusions overjet can be increased or decreased beyond the normal range.
- e. **Overbite:** In the vertical relation, the maxillary incisors partly cover the mandibular incisors by 2 mm. The vertical overlap of maxillary and mandibular incisors on the incisal surfaces of the crowns of teeth is defined as '**overbite**'. If this vertical overlap of incisor increases it is known as '**deep bite**'. If there is no vertical overlap of incisors, then there exists a condition termed as '**open bite**' (Fig. 10.5).

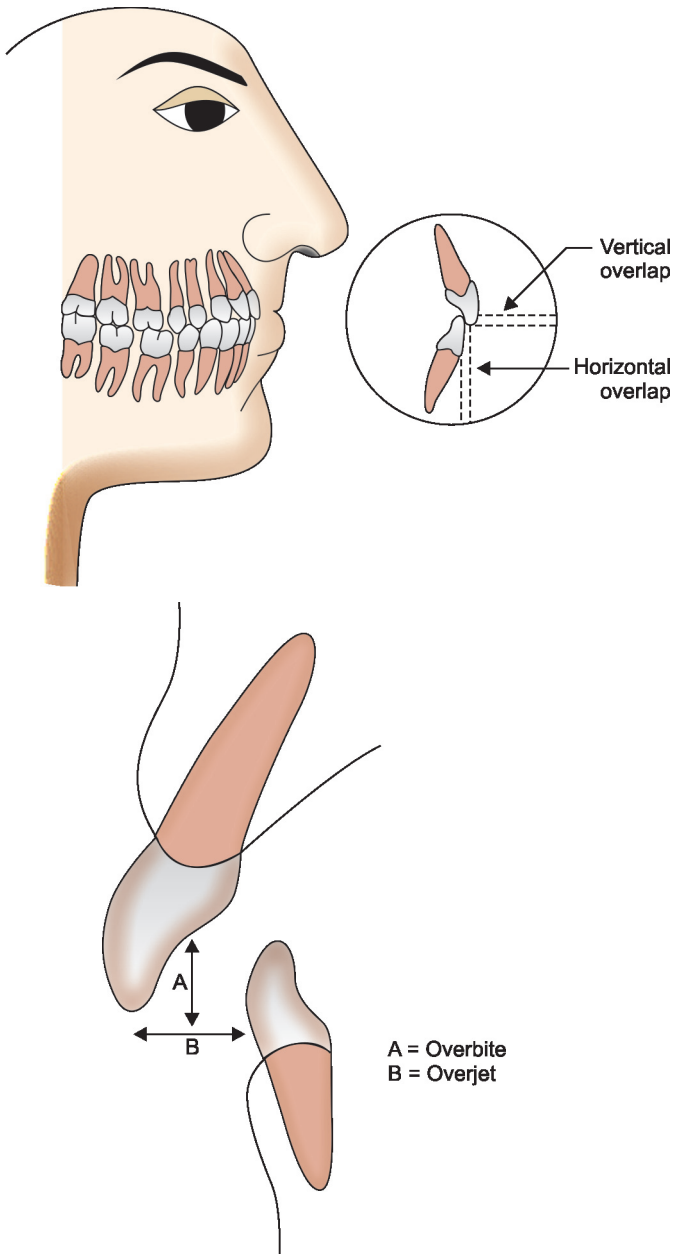


Fig. 10.5: Overjet and overbite

### OTHER FACTORS ASSOCIATED WITH OCCLUSION

- **Bonwill's triangle:** In 1899, Bonwill described that the mandible and mandibular arch would adopt itself in part to an equilateral triangle of 4 inches

formed from bilateral head of condyle's to the dental midline present between mandibular central incisors (Fig. 10.7A)

- **Bennett movement:** It is the lateral bodily movement or lateral shift or side shift of the mandible during jaw movement. During this movement, greatest lateral force is exerted and is responsible for the lateral chewing stroke. For this reason, it is extremely important that the articulating surfaces are in good, exact harmony with this side shift. If a discrepancy in this harmony will result in the most destructive lateral forces (Fig. 10.7B)
- **Freeway space:** It is of interocclusal space which is present between the maxillary and mandibular teeth when the mandible is at rest position. It is about 2–5 mm normally.

### Compensatory Curves

These are anteroposterior and lateral curves incorporated during the artificial teeth arrangement in denture construction. They are called compensatory, because they compensate for something called as the '**Christensen's phenomenon**' (Christensen's phenomenon—when a flat occlusal scheme is given, an opening takes place in the posterior region during protrusive movement of the mandible. This opening is because of the effect of the condylar inclination). The compensatory curves are determined by the inclination of the posterior teeth and their vertical relationship to the occlusal plane so that the occlusal surface results in a curve that is in harmony with the movement of the mandible as guided posteriorly by the condyle path. Functionally and mechanically, it is beneficial to keep this curve satisfactorily. Following are some of the compensating curves:

- **Anteroposterior curve:** Curve of Spee
- **Lateral curves:** Curve of Monson and curve of Wilson.

**Curve of Spee:** Maxillary and mandibular teeth come into centric occlusion and meet along anteroposterior and lateral curves. In 1890, a German Anatomist, **Ferdinand Graf Von Spee** first described an anteroposterior curve called the **curve of Spee**. According to curve Spee, the mandibular arch forms a concave (a bowl-like upward) curve. It was first observed in natural teeth and skulls and found that this curve has clinical importance in orthodontics, prosthodontics and restorative dentistry. The curve of Spee is two dimensional and moves upward from anterior to posterior direction (Fig. 10.6).

It is an imaginary (virtual) curve, begins at the incisal edges and tips of lower anteriors and touches the buccal cusp tips of all the mandibular premolar and molar teeth and continues to the anterior border of the ramus (Figs 10.7C and D). When measured at the deepest point near the premolar area, 1–1.5 mm of concavity is acceptable. The concavity increases or deepens in deep bite patients and a flat reverse curve of Spee (convexity) is seen in open bite patients. This curve allows for the normal functional protrusive movement of the mandible. There are 2 types of curve of Spee:

- Dual curve of Spee
- Rainbow curve of Spee.

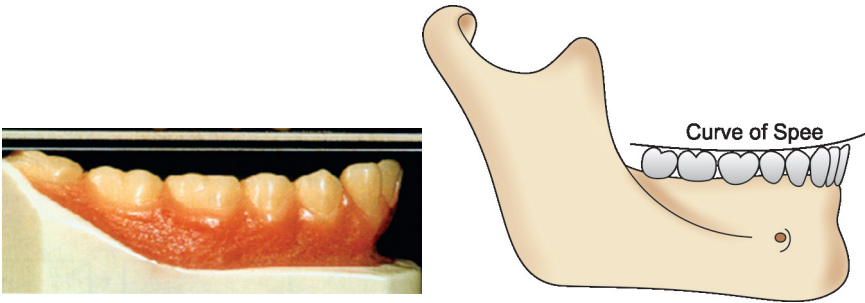
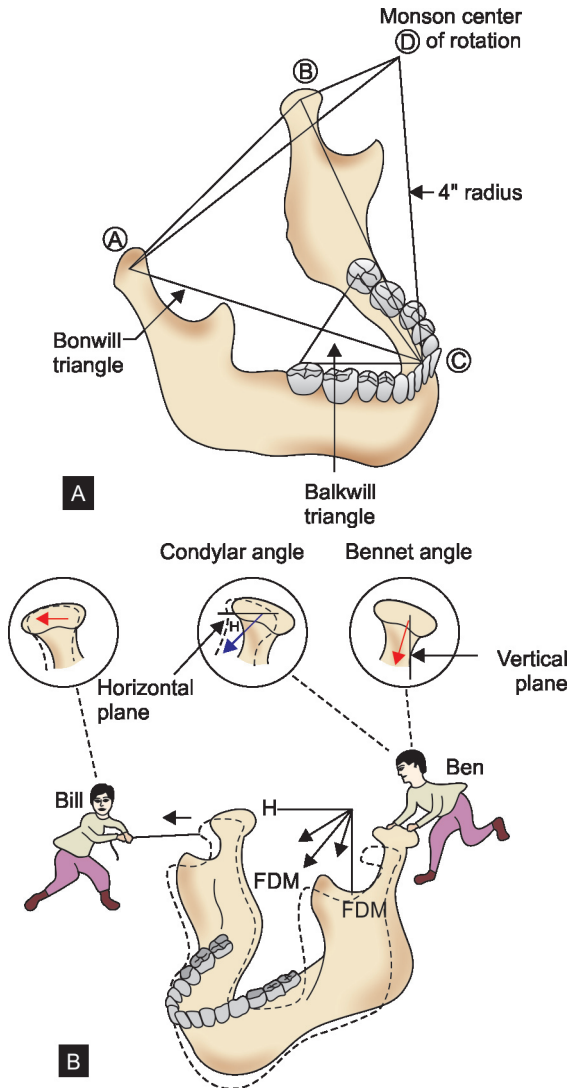
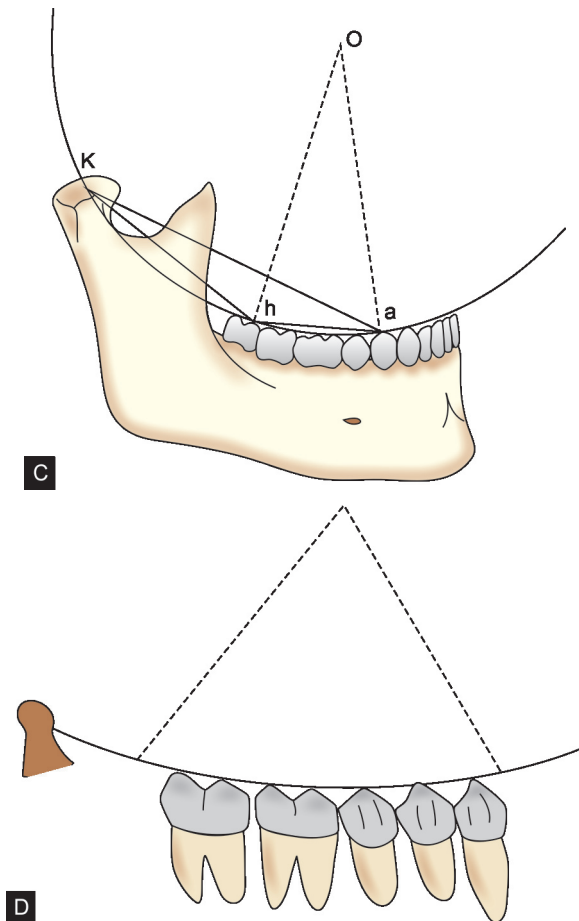


Fig. 10.6: Curve of Spee



Figs 10.7A and B: Compensatory curves with Bonwill triangle and Bennet movement



**Figs 10.7C and D:** Diagram illustrating the curve of Spee

**Curve of Monson:**—The spherical theory of occlusion was proposed by **Dr George S Monson** in 1918, an orthodontist from United States. Monson associated Bonwill's triangle with his own observations and formulated the spherical theory. The spherical theory of occlusion shows that lower teeth move over the surface of the upper teeth similar to the surface of a sphere, on a diameter of 8 inches (20 cm) for normal dentition. The center of the sphere is located at the region of the glabella and the surface of the sphere passes through the glenoid fossa bilaterally along the articulating eminences or concentric with them (Fig. 10.8). It is also termed as '**compensating occlusal curvature**'. This three dimensional curvature of the occlusal plane, is the combination of the curve of Spee and the curve of Wilson. From the definition, it can be learnt that the curvature is in the form of a portion of a ball, or sphere. The curvature is concave for the mandibular arch and convex for the maxillary arch.

Monson's spherical theory = Bonwill's triangle + Curve of Spee

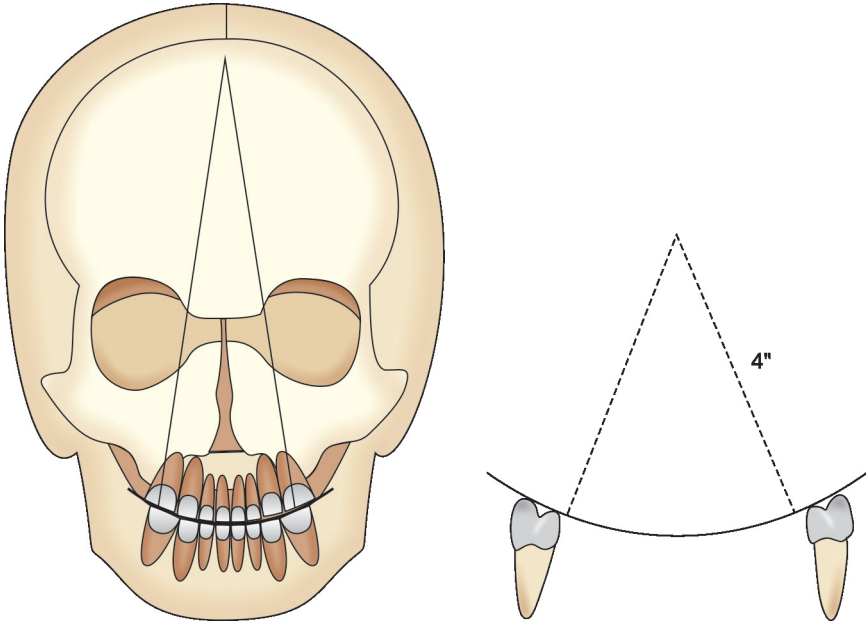


Fig. 10.8: Curve of Monson

**Curve of Wilson:** In general, the posterior teeth in the maxillary arch have a slightly buccal inclination and in the mandibular arch a slight lingual inclination. When a line is drawn touching the buccal and lingual cusp tips of right and left posterior teeth, a curved plane of occlusion is observed. This curvature is convex in the maxillary arch and concave in the mandibular arch. This curvature mediolateral curve in the occlusal plane when from the frontal side is called as the **curve of Wilson**. This curve is also two dimensional, but in a direction more or less at right angles to that of the curve of Spee and complement the paths of the condyles during mandibular movements. It is a lateral curve created by the contact of the upper and lower teeth as shown in the Figure 10.9.

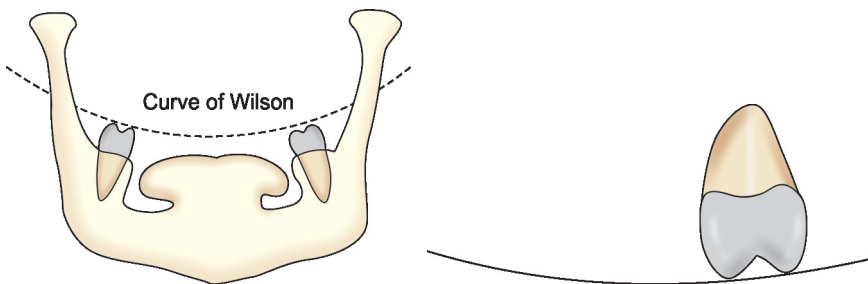


Fig. 10.9: Curve of Wilson



## DYNAMIC OCCLUSION

It is the occlusal contacts made while the mandible is moving, by the muscles of mastication, relative to the maxilla. The pathways along which it moves are determined not only by the muscles but also by two guidance systems, which are as follows:

- a. **Posterior guidance (condylar guidance):** The posterior guidance of the mandible is provided by the temporomandibular joint (TMJ). When the head of the condyle moves downwards and forwards the mandible is moving along a guidance pathway which is determined by the intra-articular disk and the articulatory surfaces of the glenoid fossa, all of which are enclosed in the joint capsule. It is the posterior and controlling factor of mandibular movements. The angulation in condylar guidance is usually in the range of 28–35° ideally it is 33°.
- b. **Anterior guidance (incisal guidance):** Anterior guidance is the anterior end controlling factor of mandibular or articulator movements. The gliding influence, results from the positional relationship of the upper and lower anterior teeth, when the mandible is moved into eccentric relation to the maxilla and the anterior teeth remain in contact. It is the angle formed by the horizontal and vertical overlap of the upper to the lower anterior teeth and depends upon the extent to which the upper anterior teeth overlap the lower anterior teeth in both horizontal and vertical direction (Fig. 10.10).

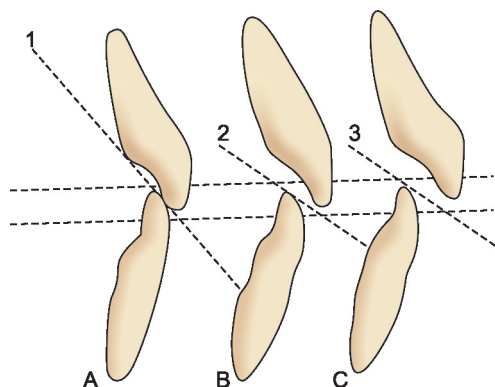


Fig. 10.10: Anterior guidance

Because of the proximity of the incisal guidance to the masticatory surfaces, it has a major influence on the contacting surfaces of the teeth posterior to it. Fortunately, the anterior guidance is largely under the control of the dentist and is usually set at an angle between 10° to 20°. It should never be more than the condylar guidance.

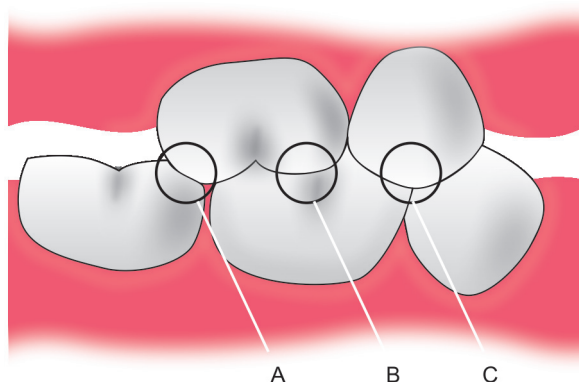
The greater the vertical overlap (deep bite) of the anterior teeth, the steeper the incisal guidance and greater the separation will occur between the posterior teeth during protrusive movements.

## KEYS TO OCCLUSION

The compensatory curves are essential to achieve harmonious occlusion in both natural dentition and artificial dentures. **Dr Lawrence F Andrews** in 1972 studied 120 casts of naturally optimal occlusion and identified a set of six characteristics that were consistently present and he called these characteristics as ‘**six keys to occlusion**’.

### Key I: Interarch Relationships

- The mesiobuccal cusp of the permanent maxillary first molar occludes in the mesiobuccal groove between the mesiobuccal and distobuccal cusps of the permanent mandibular first molar. This feature was originally given by Edward Heartley Angle in the classification of malocclusion in 1898 (see point ‘b’ in the Fig. 10.11).
- The distal surface of the distobuccal cusp of the permanent maxillary first molar occludes with the mesial surface of the mesiobuccal cusp of the mandibular second molar (see point ‘a’ in the Fig. 10.11).
- The distal slope of the buccal cusp of maxillary second premolar occludes with mesial slope of the mesiobuccal cusp of permanent mandibular first molar (see point ‘c’ in the Fig. 10.11).



**Fig. 10.11:** Cusp tips of molars and premolars in interarch relations

### Key II: Crown Angulation

- Crown angulation represents the mesiodistal tip of the long axis of the crown
- It is measured as the angle formed between the long axis of the crown and a line drawn perpendicular ( $90^\circ$ ) from the occlusal plane
- The gingival portion of the long axis of crown is more distal than the incisal portion (Fig. 10.12).

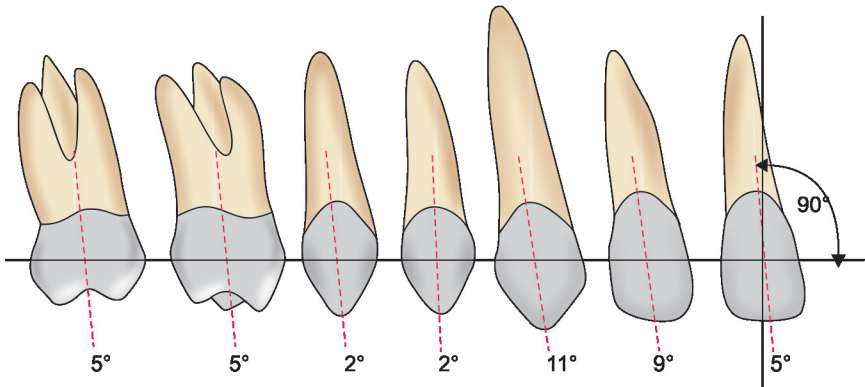


Fig. 10.12: Crown angulation in maxillary arch

### Key III: Crown Inclination

- Labiolingual or buccolingual inclination. Measured as the angle formed by a line, which is drawn 90° degrees to the occlusal, plane and a line that is tangent to the bracket side. Most maxillary incisors have a positive inclination; mandibular incisors have a slightly negative inclination. For posterior teeth a progressively minus inclination is seen from canine through the second molars (Fig. 10.13).

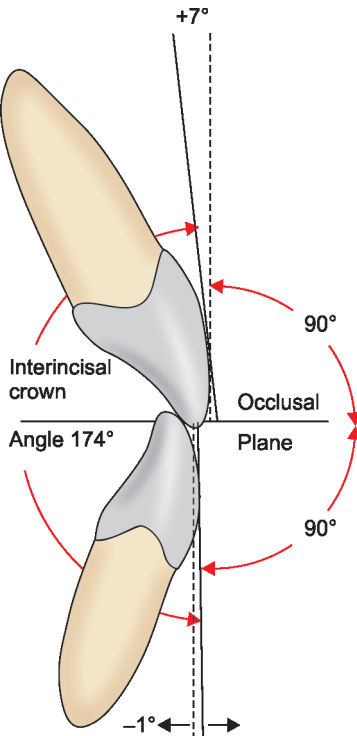


Fig. 10.13: Crown inclination in buccolingual direction

### Key IV: Rotations

- This key highlights mainly the alignment of teeth in the form of smooth arch in the anterior teeth and all central grooves of posterior teeth in a continuous line indicating no rotations or any change in these features. In short, absence of rotations (Fig. 10.14).

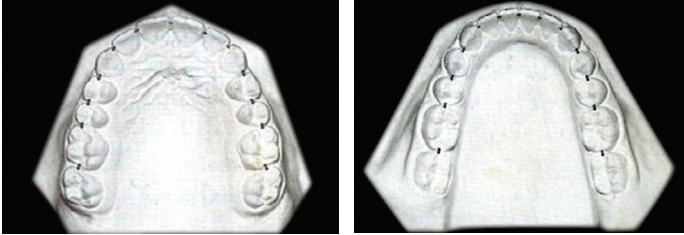


Fig. 10.14: Absence of rotation

### Key V: Tight Contacts

- Contact points should adjoin unless a discrepancy exists in mesiodistal crown diameter. There should be no spacing or crowding in both the dental arches (Fig. 10.15).

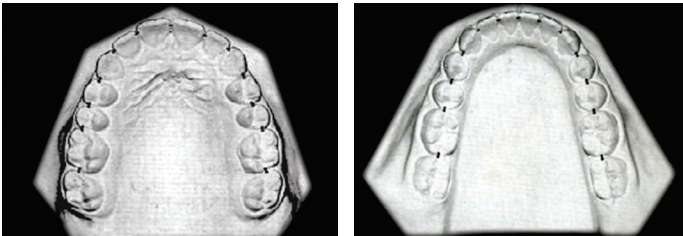


Fig. 10.15: Tight contacts

### Key VI: Flat Occlusal Plane or Curve of Spee

- The depth of the curve of Spee ranging from a flat plane to slightly concave surface is acceptable for normal occlusion
- It is observed that the intercuspation of teeth is best when the plane of occlusion is relatively flat (Fig. 10.16).

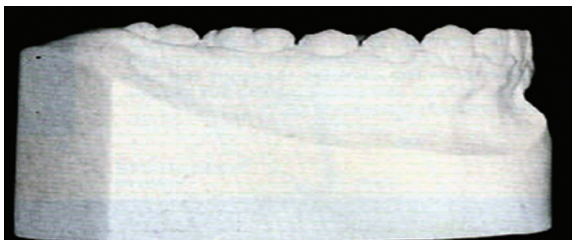


Fig. 10.16: Curve of Spee or flat occlusal plane

## Seventh Key to Occlusion

- According to **McLaughlin and Bennett**, tooth size is the seventh key to occlusion. Evaluation of tooth size discrepancy is calculated by Bolton's analysis. According to Bolton, a mean ratio of 91.3% (combined mesiodistal width of all permanent mandibular teeth anterior to second molar versus combined mesiodistal width of all permanent maxillary teeth anterior to second molar) will result in ideal overbite-overjet relationships as well as posterior occlusion.

### FACTORS AFFECTING THE OCCLUSION

Occlusion is the sum total of many factors. These factors include genetic, environmental and musculoskeletal.

1. **Genetic factors:** For each individual there is a basic pattern or blueprint for the development of dentofacial structures. According to **Lundstorm**, the following features have an impact on normal occlusion.
  - *Tooth size:* Teeth vary in size. Small sized teeth are referred to as microdontia and teeth larger than normal are referred as macrodontia. Example: Australian origins have larger molar tooth size of about 35% larger than normal
  - *Teeth number:* Teeth can be congenitally missing (partial or complete anodontia), or there can be extra (supernumerary) teeth
  - *Arch length and width:* The skeletal support (maxilla/mandible) and how they are related to each other can vary considerably from the norm
  - *Crowding or spacing:* Absence of spacing in deciduous and presence of crowding in permanent or vice versa may result in variation of normal occlusion
  - *Eruption of teeth:* They can vary when and where they erupt, or they may not erupt at all (impaction)
  - *Overbite and overjet:* Any small variations results in minor to major occlusal variations. All these factors play a major role in making normal harmonious occlusion.
2. **Environmental factors:** These factors have an adverse influence on the occlusion and are classified as follows:
  - *Prenatal*
    - Trauma
    - Maternal diet
    - Maternal metabolism and diseases
    - Maternal consumption of alcohol.
  - *Postnatal*
    - TMJ and birth injuries
    - Habits
    - Trauma.
3. **Muscular pressure:** Once the teeth erupt into the oral cavity, the position of teeth is affected by other teeth, both in the same dental arch and by teeth in the opposing dental arch. Teeth indirectly are affected by muscular pressure on the facial side (by cheeks/lips) and on the lingual side (by the tongue).

## AGE CHANGES IN OCCLUSION

Occlusion constantly changes with development, maturity and aging.

- There is change with the eruption and shedding of teeth as the successional changes from deciduous to permanent dentitions take place
- Tooth wear is significant over a lifetime. The wearing away of the occlusal surface reduces crown height and alters occlusal anatomy
- Attrition of the proximal surfaces reduces the mesial distal dimensions of the teeth and significantly reduces arch length over a lifetime
- Tooth loss leaves one or more teeth without an antagonist
- Also, teeth drift, tip, and rotate when other teeth in the arch are extracted.

## BALANCED OCCLUSION

Balanced occlusion involves a definite arrangement of tooth contacts in harmony with the mandibular movements. The mandibular cusps contact the maxillary cusps evenly throughout the dentures so that the dentures can perform the masticatory function most effectively. This type of occlusion may be termed as ‘**physiologic occlusion**’ or ‘**balanced occlusion**’ or ‘**planned occlusion**’.

The necessity of balanced occlusion or distribution of occlusal stresses over the greatest possible supporting area has been emphasized for many years by both prosthodontist and periodontist.

Balanced occlusion, in complete dentures can be defined as a stable simultaneous contact of the opposing upper and lower teeth in centric relation position and a continuous smooth bilateral gliding from this position to any eccentric position within the normal range of mandibular function. Balance in complete denture is unique and man-made. The average edentulous patient does not require a balanced occlusion in order to carry the functions of the prosthesis successfully. But in certain individuals with a low pain threshold, unusual masticatory habits and or eccentric non-masticatory movements, dentures will not be tolerated. In such cases, balancing the occlusion is very important. Few differences between natural and artificial dentition are listed in Table 10.1.

**Table 10.1:** Differences between natural and artificial occlusion

Sl. No	Natural occlusion	Artificial occlusion
1.	Teeth are retained by periodontal tissues with proprioception	Teeth are retained on the denture bases, seated on wet tissues without proprioception
2.	Each tooth is independent and move as single unit	Artificial teeth along with the denture base move as a single unit
3.	Malocclusion may be uneventful for years	Incorrect arrangement of teeth evokes an immediate response and involves all the teeth and bases
4.	Incising does not affect the posterior teeth	Incising results in lifting of artificial dentures in posterior region
5.	The 2nd molar is the favored area for masticating hard foods	The 2nd molar in artificial teeth will tilt the base and shift it

Contd...

Contd...

6.	Bilateral balance is rarely found, if present, it is called balancing side interference	Bilateral balance is necessary for stability of bases
7.	Centric occlusion is ahead of centric relation	Centric occlusion has to coincide with centric relation
8.	Nonvertical forces affect only the teeth involved and are usually well-tolerated	The effect involves all the teeth causing trauma to the supporting tissues

## CONCLUSION

Occlusion, good or bad, is the result of complex amalgamation or combination of genetic and environmental factors, and interactions at work right through the early developmental stages of childhood and young adulthood. Understanding these concepts has thus, got far reaching implications in diagnosis, treatment planning and prognosis of malocclusion.

## FURTHER READING

1. Andrews LF. The six keys to normal occlusion. *Am J Orthod.* 1972;6(3):296-309.
2. Ash MM, Ramfjord S. Occlusion. 4th ed. W B Saunders Company, Philadelphia. 1996.
3. Bennett JC, McLaughlin RP. Orthodontic management of the dentition with the pread-justed appliance. Elsevier Health Sciences, 2002.
4. Dawson PE. Evaluation, diagnosis, and treatment of occlusal problems. Mosby, 1989.
5. Lo RT, Moyers RE. Studies of the etiology and prevention of malocclusion:I. The sequence of eruption of the permanent dentition. *Am J Orthod.* 1953; 39:460-7.
6. Moyers RE. Handbook of orthodontics. 4th ed. Ann Arbour, Michigan: Year Book Medical Publishers Inc; 1988.
7. Nelson S. Wheeler's dental anatomy, physiology and occlusion. 9th Ed, Saunders, 2009.
8. Okeson JP. Management of temporomandibular disorders and occlusion. 6th ed, Elsevier Health Sciences, 2007.
9. Proffit WR, Fields HW, Sarver DM. Contemporary orthodontics. 4th ed, Mosby Elsevier, 2007.
10. Roth RH. Functional occlusion for the orthodontist. *J Clin Orthod.* 1981;15(1):32-51.

## CHAPTER

# 11

# Vascularity and Innervation of Maxilla and Mandible

*Nagarajappa Das*

Maxillary artery (formerly called internal maxillary artery) is of most importance to dentist and dental hygienist.

- The mandibular artery and pterygopalatine artery is concerned with the blood supply to maxilla (Fig. 11.1) and mandible (Flow chart 11.1)
- Inferior alveolar artery along with the inferior alveolar nerve enters the mandibular canal and supplies to the premolars and molars, runs forward and divides into mental artery, incisive artery to supply to the anterior teeth
- Pterygopalatine part is not directly involved with the teeth. It is divided into:
  - Posterosuperior alveolar artery
  - Infraorbital artery
  - Descending palatine artery
- **Posterosuperior alveolar:** Supplies to the maxillary molars
- **Infraorbital artery:** Like infraorbital nerve it gives off middle superior alveolar artery which supplies to premolars and first emerges out from foramen to supply to anterior teeth
- **Descending palatine artery:** Branch of maxillary artery supplying to part of nasal cavity, it descends down the pterygopalatine fossa and emerge along with greater palatine nerve to supply to soft palate, hard palate and lingual gingival.

### VENOUS DRAINAGE OF MAXILLA AND MANDIBLE (FIG. 11.2)

Venous drainage of this region is extremely variable. The facial vein is the main vein draining the face. The small veins from the teeth and alveolar bone passes into larger veins, which surround the apex of each tooth into veins running in interdental septa. In mandible, the veins are collected to one or more inferior dental veins that drains through mental foramen to join facial vein or posteriorly through the foramen to join pterygoid plexus in infratemporal fossa. In maxilla veins drains to join facial vein or posteriorly through the foramen to join pterygoid plexus in infratemporal fossa.

### NERVE SUPPLY TO THE MAXILLA AND MAXILLARY TEETH

The trigeminal nerve, fifth largest cranial nerve, contains both sensory and motor nerve fibers, and further divides into ophthalmic, maxillary, mandibular nerve. The maxillary nerve innervates the maxilla and maxillary teeth. The mandibular part innervates the mandible and mandibular teeth respectively (Fig. 11.3).



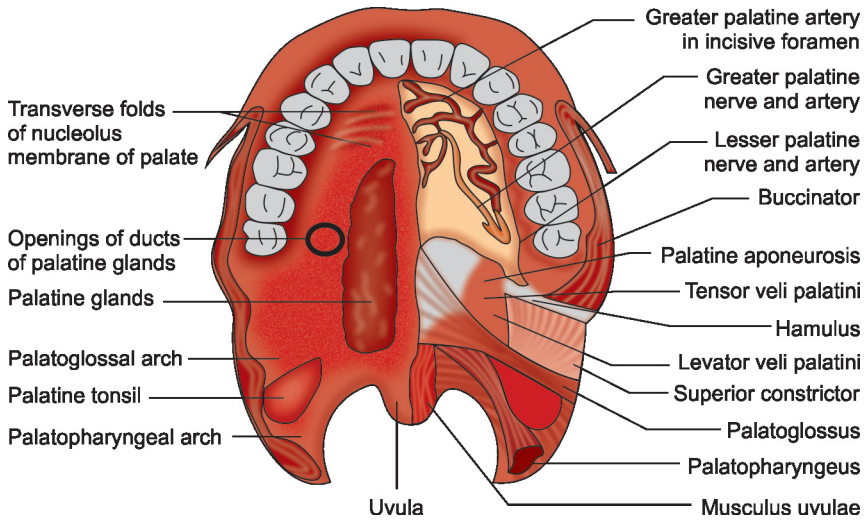
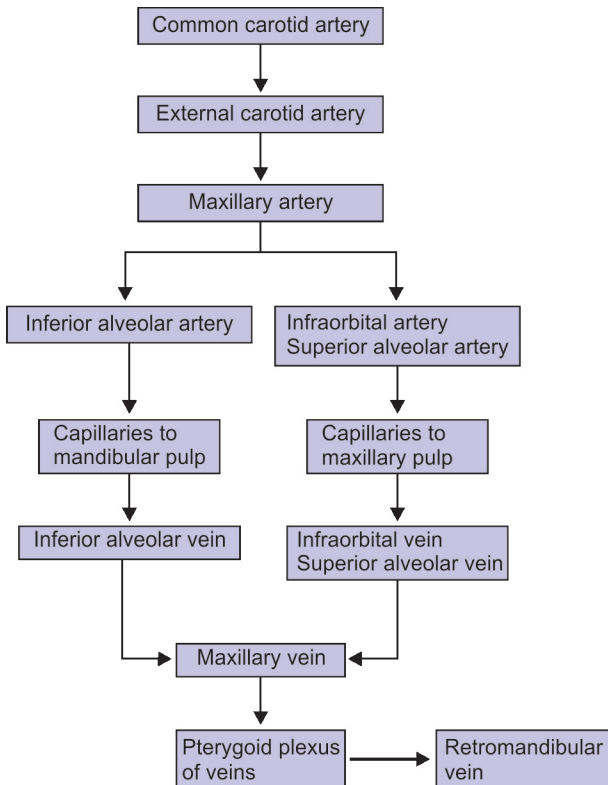


Fig. 11.1: Blood supply to maxilla

Flow chart 11.1: Schematic representation of arterial supply and venous triangle of maxilla and mandible



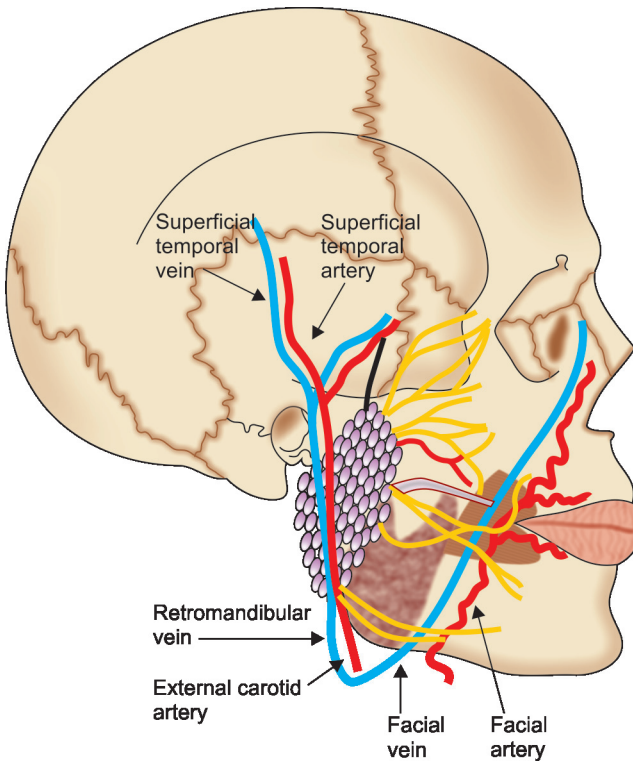


Fig. 11.2: Vein blood supply to maxilla and mandible

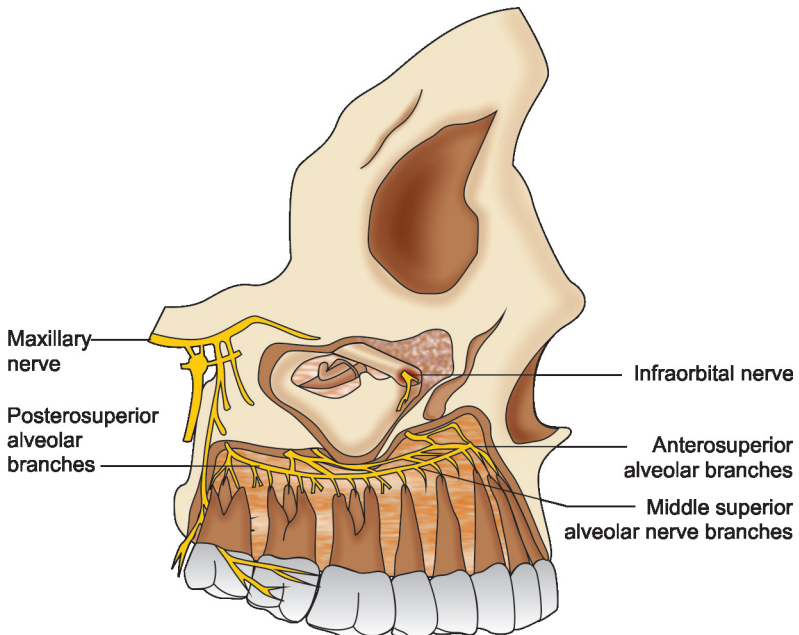


Fig. 11.3: The maxillary nerve and its distribution

Nerve supply to the maxilla and maxillary teeth (Fig. 11.4 and Flow chart 11.2):

- Infraorbital nerve
- Anterosuperior alveolar nerve
- Middle superior alveolar nerve
- Posterosuperior alveolar nerve
- Greater palatine nerve
- Nasopalatine nerve
- **Infraorbital nerve:** This is the branch of maxillary division of trigeminal nerve. It innervates lower eyelids, lateral aspect of nose, upper lip and medial aspect of cheek, labial mucosa and labial gingiva of anterior teeth

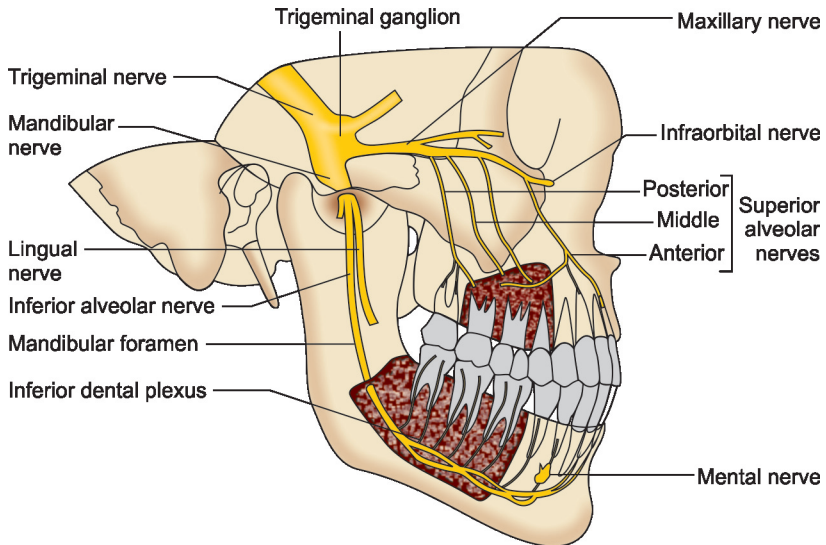


Fig. 11.4: Innervation of teeth

Flow chart 11.2: Nerve supply to maxillary teeth

Nerve supply to the maxillary teeth

Central incisor Lateral incisor Canine	Buccally	Palatally
	Anterosuperior alveolar nerve	Nasopalatine nerve
1st premolar 2nd premolar	Buccally	Palatally
	Middle superior alveolar nerve	Greater palatine nerve
1st molar 2nd molar 3rd molar	Buccally	Palatally
	Posterosuperior alveolar nerve	Greater palatine nerve

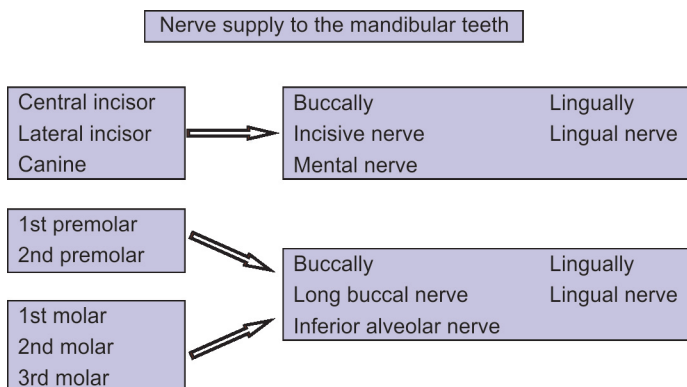
- **Anterosuperior alveolar nerve:** This is the branch of maxillary nerve. It supplies the incisor and canines along with labial gingiva of respective teeth
- **Middle superior alveolar nerve:** This is the branch of maxillary division of trigeminal nerve, which innervates premolars, mesiobuccal roots of maxillary 1st molar and buccal gingiva in relation to these teeth
- **Posterosuperior alveolar nerve:** This is the branch of maxillary division of trigeminal nerve. It innervates the maxillary 1st, 2nd and 3rd molars with the exception of the mesiobuccal root of 1st molar, buccal periodontium and buccal gingiva in relation to these teeth
- **Greater palatine nerve:** It exits from the greater palatine foramen, which is present in between second and third molars of palate and it innervates the bone, soft tissue of palate in a groove to supply palatal gingiva, roots of premolars and molars
- **Nasopalatine nerve:** Branch of pterygopalatine branch of maxillary division. It enters the oral cavity through incisive foramen and innervates the palatal gingiva of maxillary anterior teeth.

### NERVE SUPPLY TO THE MANDIBLE AND MANDIBULAR TEETH

Nerve supply to the mandible and mandibular teeth (Flow chart 11.3):

- Inferior alveolar nerve
- Long buccal nerve
- Lingual nerve
- Mental nerve
- Incisive nerve
- **Inferior alveolar nerve:** This is the branch of posterior division of mandibular branch of trigeminal nerve, which innervates central incisors to 3rd molar on the same side, labial gingiva anterior to the 1st premolar, labial mucosa, lower lip and chin on same side
- **Long buccal nerve:** This is the branch of anterior division of mandibular branch of trigeminal nerve, which innervates the buccal mucosa, buccal gingiva in relation to 2nd premolar and molar

**Flow chart 11.3:** Nerve supply to mandibular teeth



- **Lingual nerve block:** This is the branch of posterior division of mandibular branch of trigeminal nerve which innervates the lingual gingiva of the mandibular teeth, floor of the mouth and anterior two-third of tongue on same side
- **Mental nerve block:** It is one of the terminal branches of inferior alveolar nerve, which innervates the soft tissues of lip and chin on same side, labial gingival in relation to anterior teeth and first premolar. Mental nerve does not supply to hard tissues i.e....teeth and bone
- **Incisive nerve:** It is the terminal branch of inferior alveolar nerve, which innervates the anterior teeth on same side.

### FURTHER READING

1. Cunningham's manual of practical anatomy: Vol III, by Romanes GJ, 15th edn, Oxford Medical Publications, 2002.
2. Gray's anatomy of the human body. 20th edn, 2000.
3. Monheim's local anaesthesia and pain control in dental practice. Crichard Bennet, 7th edn.

# CHAPTER 12

## Tooth Anatomy and Forensic Odontology

*Ashith B Acharya*

### INTRODUCTION

Forensic odontology, or forensic dentistry, is the branch of dental sciences which has legal applications. Forensic odontology has primarily found use in postmortem identification, i.e. utilizing teeth to identify dead individuals who, for various reasons, cannot be visually recognized. These reasons include traumatic death (e.g. road-traffic accidents, air-disasters) or prolonged duration since the time of death (where the body is in various stages of decomposition). The teeth have variegated and complex morphology, withstand circumstances that surround unnatural death and are resistant to the vagaries of time after death. Hence, teeth play an important role in forensic identification (Shields et al, 1990).

Forensic specialists utilize a variety of methods to help law enforcement officials identify individuals. When the mortal remains comprise only the skeletal-dental complex, the means to identification involves ascertaining the age, sex, race/ethnicity and stature, among others (Scott and Turner, 2000). This process is referred to as reconstructive identification and limits the pool of missing persons to which a match can be made through comparative methods (Edgar, 2005). The present chapter will explore sex and racial differences in tooth anatomy and its application to forensic investigation.

Both size and morphology of the teeth can be utilized for reconstructive identification. In forensic and anthropological parlance, tooth size and morphology are referred to as metric and non-metric dental traits, respectively. According to Hillson (1996), metric traits of the teeth are those features that are measured directly (e.g. mesiodistal or buccolingual dimensions) whereas non-metric dental traits are recorded by visual observation in terms of presence, absence or degree of development (e.g. Carabelli's cusp may be present, absent or expressed as intermediate depressions).

### DEFINITION OF METRIC DENTAL TRAITS

In forensic and anthropological investigations, the maximum dimensions of the tooth crown are commonly used (Hillson, 1996). The tooth measurements utilized are the mesiodistal and buccolingual dimensions. These are relatively easy to record on dental casts obtained from living individuals and repeatable on skeletal remains in forensic casework.

### Mesiodistal Dimension


The mesiodistal (MD) dimension is the greatest distance between the contact points on the approximal surfaces of the crown. In case of tooth rotation or malposition, the measurement is taken between points on the approximate surfaces of the crown where it is considered that contact with adjacent teeth would have normally occurred. This definition was given by Moorrees and coworkers (1957) and is widely followed in anthropological and forensic studies. The mesiodistal dimension is ideally taken using digital callipers that can measure teeth with a precision of up to 0.01 mm. The calliper beaks should fit into the proximal areas between teeth and are placed occlusally along the long axis of the tooth (Fig. 12.1). However, a major disadvantage of mesiodistal measurements is that they are susceptible to approximal wear and attrition, which may reduce the dimension and render them of little use in forensic investigation.

### Buccolingual Dimension


The buccolingual (BL) dimension may be defined as the greatest distance between the labial/buccal surface and the lingual surface of the tooth crown. This measurement is taken at right angles to the plane in which the mesiodistal crown dimension is obtained (Fig. 12.2). The calliper beaks are placed at the most prominent portions of the buccal and lingual surfaces. It is easier to measure buccolingual dimensions if the calliper beaks have broad flat surfaces (Hillson, 1996). While buccolingual surfaces are not altered by approximal wear, they are modified by marked attrition. They may also be affected by large deposits of dental calculus.

## DEFINITION OF NON-METRIC DENTAL TRAITS

Thirty-three non-metric dental traits have been described by Scott and Turner (2000) in an excellent compilation on the anthropology of human teeth. These have been defined and analyzed for variations in human races. Presented here are only a few of these traits for the purpose of brevity. Also, as is evident in a



**Fig. 12.1:** The calliper beaks held along the long axis of tooth 35 snugly fits interproximally to measure the mesiodistal dimension



**Fig. 12.2:** To measure buccolingual dimensions, the calliper beaks are positioned in a plane that is at right angles to the mesiodistal measurement. The calliper beaks are placed at the maximum curvatures lingually and buccally

later section of this chapter, the purpose is to highlight population similarities/differences in the Indian subcontinent, and data exists mostly for the following traits.

### Shovelling

Shovelling refers to the presence of mesial and distal marginal ridges on the lingual surface of the maxillary and mandibular anterior teeth. The marginal ridges may be absent, slightly developed or very prominent (Fig. 12.3). The lingual fossa is a secondary reflection of marginal ridge development. The maxillary central incisors are the recommended teeth for observing the trait for assessing population differences.

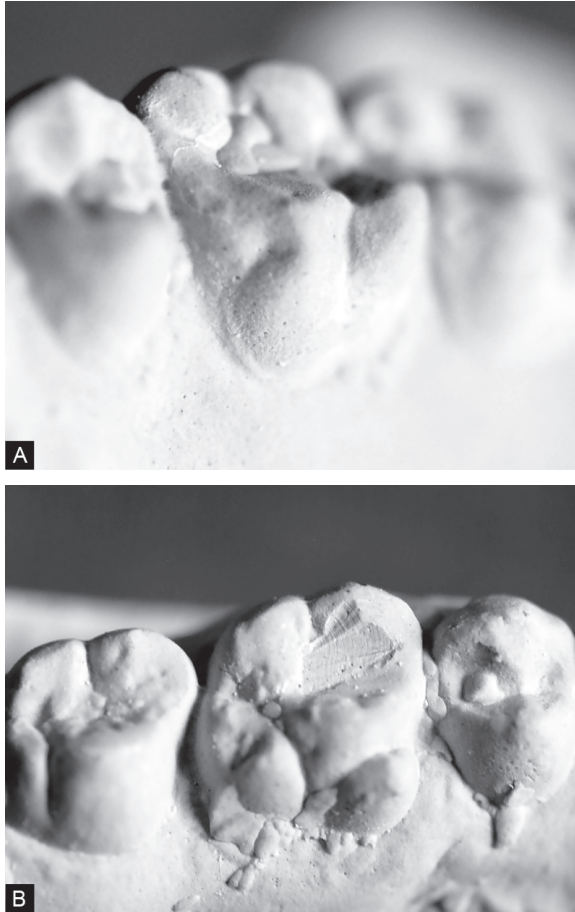### Carabelli's Trait

The Carabelli's cusp, or tubercle of Carabelli, is a 'cingular derivative' expressed on the mesiolingual or lingual aspect of the mesiolingual cusp of maxillary molars. The trait may be absent, expressed as minor depressions or well-developed tubercles with free apices (Figs 12.4A and B). For assessing population differences, the maxillary first molar is examined.



**Fig. 12.3:** Shovelling of the maxillary central and lateral incisors





**Figs 12.4A and B:** (A) A moderate expression of Carabelli's trait on tooth 26; (B) A pronounced cusp of Carabelli on tooth 16

### Three-cusped Maxillary Second Molar

The distolingual (distopalatal) cusp of the maxillary molars is usually retained on the first molar, but tends to be of reduced size or absent in the second molar (Fig. 12.5).

### Mandibular Molar Groove Pattern

Occlusal groove pattern on the mandibular molars is the result of varying modes of cusp contact at the central fossa:

- When the mesiolingual and distobuccal cusps are in contact, the resultant groove pattern is referred to as the Y-groove (Fig. 12.6)
- When the mesiobuccal and distolingual cusps are in contact at the central fossa, the groove pattern is known as the X-groove



**Fig. 12.5:** A maxillary second molar (tooth 27) with missing distolingual cusp



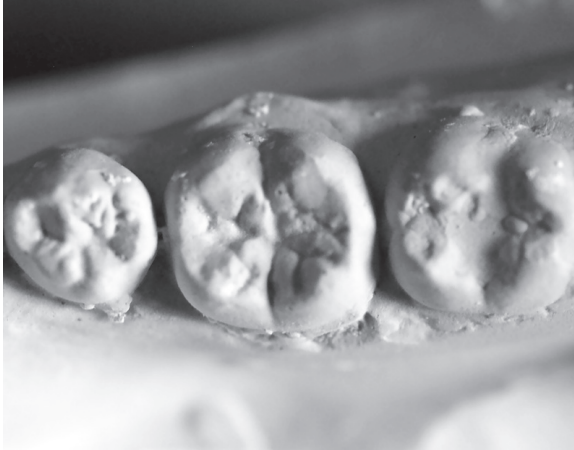**Fig. 12.6:** Contact between the mesiolingual and distobuccal cusp of the mandibular molar results in the Y-groove pattern

- When all major cusps are in contact at the central fossa, the groove pattern takes the form of a '+' sign (Fig. 12.7).

The mandibular second molar is used to assess groove pattern differences in populations.

#### **Four-cusped Mandibular Molars**

Conventionally, the mandibular first molar is considered to have five cusps, while the second molar is regarded as having four. However, the distal cusp may




**Fig. 12.7:** A four-cusped mandibular first molar can result in a '+' groove configuration

be absent on the first molar (Fig. 12.7) and/or expressed on the second molar. Therefore, both first and second mandibular molars are studied for the absence of the distal cusp.

### Cusp 7

Cusp 7 refers to a supernumerary cusp expressed between the mesiolingual and distolingual cusps of the mandibular first molar (Fig. 12.8) (there is also a cusp 6, which may be present between the distal and distolingual cusps). A well-developed cusp 7 appears triangular in shape when viewed from the occlusal aspect, with the base towards the lingual surface and apex pointing to the central fossa.



**Fig. 12.8:** A moderately developed cusp 7 between the lingual cusps of tooth 46

## SEX IDENTIFICATION FROM TOOTH SIZE

Most species of living mammals show overall sexual dimorphism, but the extent of differences vary between species (Hillson, 1996). For example, male and female gibbons are of similar size, whereas male gorillas are considerably larger than females. Humans lie between these extremes.

Human dental sex differences vary from tooth-to-tooth, with canines consistently showing the greatest degree of sexual dimorphism. Table 12.1 illustrates the magnitude of sex difference for teeth on the right side among Nepalese, and gives an indication of the amount of sex differences that may exist in Indians. These values represent the percentage by which male tooth dimensions exceed those of females—closer the value is to zero, smaller the male-female differences. A negative value indicates that females have larger dimensions for that particular tooth. Indeed, some studies have found that the average size of some teeth can be smaller in males on occasion (Ghose and Baghdady, 1979; Harris and Nweeia, 1980; Acharya and Mainali, 2007), which is termed as ‘reverse dimorphism’. The answer is to why some female teeth are larger than those in males can be drawn from the study of human evolution: sexual dimorphism is believed to have reduced in contemporary humans over the course of evolution. While no specific cause can be attributed for this, it is considered to be the result of “a convergence in the requirements of male and female roles” (Frayer and Wolpoff, 1985). This has reduced dental sex dimorphism among humans, resulting in an overlap of male and female tooth sizes and, consequently, in reverse dimorphism.

While reverse dimorphism may be observed for a few teeth in some populations, the male dentition, as a whole, is larger than that of females. This becomes apparent

**Table 12.1:** Percentages dimorphism\* for the different teeth

Tooth and dimension		Maxillary	Mandibular
Central Incisor	BL	3.5%	2.8%
	MD	3.1%	0.9%
Lateral Incisor	BL	2.6%	1.9%
	MD	0.8%	2.0%
Canine	BL	6.2%	7.0%
	MD	4.5%	5.8%
First premolar	BL	2.9%	2.3%
	MD	0.6%	0.9%
Second premolar	BL	2.9%	2.1%
	MD	1.2%	-0.9%
First molar	BL	3.8%	0.8%
	MD	2.5%	1.4%
Second molar	BL	3.2%	1.1%
	MD	0.7%	3.6%

[\*Calculated as  $[(x_m/x_f - 1) \times 100]$ , where ‘ $x_m$ ’ is the mean male tooth dimension, and ‘ $x_f$ ’ is the mean female tooth dimension; greater the percentage dimorphism, larger the male tooth size.]

when statistical methods such as discriminant function analysis is utilized for sex differentiation. Given below are formulas derived using discriminant function analyzes and is applicable for sex identification in the people of India.

### Formula 1

When all teeth are present in the skeletal remains, the mesiodistal dimensions of tooth 22, 24, 36, 43 and buccolingual dimensions of 24, 33, 42 are measured (in mm) and substituted in the following formula:

$$\text{Sex} = [(MD22) \times -1.287] + [(BL24) \times 2.737] + [(MD24) \times -4.386] + [(BL33) \times 1.829] + [(MD36) \times -0.889] + [(BL42) \times -2.033] + [(MD43) \times 3.802] - 3.63$$

The above seven dimensions only are used since the remaining teeth do not provide additional information for sex identification. If the value obtained using the formula is less than  $-0.81$ , the individual is considered as female; a value more than  $-0.81$  would indicate that the skeletal remains belong to a male. The accuracy of this formula in sex identification is 95%.

### Formula 2

When the maxillary teeth only are available, one may use the mesiodistal dimensions of tooth 12, 13, 14, 17, 21 and the buccolingual dimension of 24.

$$\text{Sex} = [(MD12) \times -1.678] + [(MD13) \times 1.791] + [(MD14) \times -2.971] + [(MD17) \times -0.967] + [(MD21) \times 1.825] + [(BL24) \times 2.357] - 10.557$$

If the value obtained using the formula is less than  $-0.509$ , the individual is considered as female; a value more than  $-0.509$  would indicate a male. The accuracy of this formula in sex identification is 90%.

### Formula 3

When the mandibular teeth only are available, the mesiodistal dimensions of tooth 31, 36, 43 and the buccolingual dimension of 33 can be used in sex identification using the formula given below:

$$\text{Sex} = [(MD31) \times -2.548] + [(BL33) \times 1.004] + [(MD36) \times -0.944] + [(MD43) \times 2.9] - 3.237$$

If the value obtained using the formula is less than  $-0.4675$ , the individual is considered as female; a value more than  $-0.4675$  would indicate that the skeletal remains belong to a male. The accuracy of this formula in sex identification also is 90%.

A limitation of these formulas is that they have been derived from a sample of 40 individuals (13 females and 27 males) only. A larger sample would certainly make it more reliable and the intention here is to use these until comprehensive tooth size data is available for Indians. In addition, the formulas may not always be applicable in forensic scenarios where, frequently, the jaws may be further fragmented and only parts of the maxilla and/or mandible with few teeth are recovered. In such instances, custom-made formulas can be developed depending on teeth present in the skeletal remains. The accuracy levels of the formulas may, however, decrease with the availability of fewer teeth. Nevertheless, this approach is valuable as a supplementary method of sex assessment.

**Table 12.2:** Mean percentage dimorphism in different population groups

<i>Population group</i>	<i>Maxillary</i>		<i>Mandibular</i>	
	MD	BL	MD	BL
India (Punjab)	3.5%	–	4.5%	–
Nepal	1.9%	3.6%	1.9%	2.7%
Yemenite Jew	0.0%	–	2.2%	–
Iraq	1.4%	–	1.1%	–
Jordan	3.4%	–	3.8%	–
Turkey	–	7.3%	–	7.3%
Australian aborigine	3.6%	4.0%	3.7%	3.9%
Native African	4.0%	3.9%	–	–
South African Caucasoid	6.2%	4.8%	–	–
Sweden	4.2%	3.8%	4.3%	2.8%
American Caucasoid	4.0%	6.1%	4.3%	5.2%
Native South American	0.5%	1.9%	1.5%	1.4%

Formulas used for sex identification should be derived from tooth dimensions of the local population, since sexual dimorphism varies from population-to-population. Table 12.2 compares the magnitude of sex difference in diverse populations. While sexual dimorphism is relatively high in the Turks and Caucasoids, it is lower in Yemenite Jews and Native South Americans. Indians (from Punjab) have intermediate levels of sexual dimorphism.

### RACE IDENTIFICATION FROM THE DENTITION

As stated in page 168, race identification can be important in individualizing human remains, especially in reconstructing the identity of skeletal remains. In general, craniometric traits are the preferred method for determining race in forensic cases (Scott and Turner, 2000). However, “in severely damaged human remains tooth morphology often provides the most useful clues to identification” (Scott and Turner, 2000); the crania may be too damaged by postmortem factors but the dentition is well-preserved. The use of teeth, therefore, is ‘an established procedure’ to determine race affiliation (Edgar, 2005).

### Population Differences in Tooth Size

Tooth size differences do exist between populations, but they are generalized. Australian aborigines have relatively large teeth, Europeans and Asians have small teeth while Native Americans form an intermediate group. In Table 12.3, one can appreciate that the buccolingual measurements of the maxillary second molar in Australian aborigines is almost 15% larger than that of Swedish Caucasoids. Although population differences in tooth size are not specific, the use of statistical methods such as discriminant function analysis may yield results that enable population identification in forensic contexts. However, this approach is yet to be applied on

**Table 12.3:** Tooth crown dimensions in males of diverse populations

	<i>Australian aborigine (Barrett et al, 1963 and 1964)</i>		<i>Native American (Harris and Nweeia, 1980)</i>		<i>Swedish Caucasoid (Lund and Mörnstad, 1999)</i>		<i>Chinese (Goose, 1977)</i>		<i>Indian (Singh and Goyal, 2006)</i>
Maxilla	MD	BL	MD	BL	MD	BL	MD	BL	MD
CI	9.35	7.95	8.73	7.83	8.88	7.13	8.55	7.45	9.05
LI	7.65	7.03	7.45	6.83	6.98	6.47	7.02	6.83	7.07
C	8.31	9.12	8.46	8.62	8.26	8.37	7.96	8.51	8.16
PM1	7.69	10.38	7.54	9.67	6.87	9.32	7.25	9.51	7.35
PM2	7.19	10.29	6.98	9.38	6.73	9.82	6.86	9.41	7.10
M1	11.34	12.63	10.39	11.72	11.00	11.03	10.43	11.40	10.35
M2	10.7	12.83	9.81	11.5	10.4	11.01	9.73	11.44	9.95
Mandible									
CI	5.87	6.87	5.33	5.87	5.48	6.19	5.47	6.24	5.68
LI	6.60	7.01	6.36	6.23	6.09	6.53	6.03	6.61	6.31
C	7.49	8.39	7.24	7.45	7.19	7.55	7.04	7.95	7.26
PM1	7.49	8.83	7.17	7.86	7.12	7.88	7.11	8.00	7.42
PM2	7.56	9.15	7.24	8.19	7.36	8.62	7.18	8.25	7.55
M1	12.04	11.85	11.32	10.51	11.13	10.42	11.23	10.78	11.23
M2	11.45	11.60	10.68	10.32	10.52	10.25	10.41	10.61	10.33

a large scale. Matis and Zwemer (1971) used a number of dental measurements, including buccolingual and mesiodistal dimensions of some teeth, and obtained respectable levels of accuracy in identifying similar racial groups. It is plausible that accuracy levels of identification would be higher when attempting to differentiate genetically dissimilar groups. However, the population identification may need to be viewed with caution considering that sex differences within a population may have a bearing on the outcome. Also, tooth size is not entirely under genetic control; it is believed to be under considerable influence of the prenatal environment (Bailit, 1975) and postnatal growth influences such as availability of intraoral arch space. This susceptibility of tooth size to change according to the environmental setting is known as 'plasticity' (Scott and Turner, 2000).

## Population Differences in Non-metric Dental Traits

### *The Inheritance of Non-metric Dental Traits*

Studies on twins and unrelated individuals have led some researchers to conclude that non-metric traits have a 'definite genetic control,' although environmental factors have some influence (Kaul et al, 1985). These observations are supported by Scott and Turner (2000), who believe that non-metric traits have a polygenic mode of

inheritance (i.e. multiple genes affect a trait). However, all traits are not necessarily inherited in the same manner—some traits may have a greater environmental component “while others are influenced primarily by genetic factors” (Scott and Turner, 2000). Traits that are inherited by polygenic mode include the mandibular molar groove pattern (Y, X and +). Carabelli’s cusp and shovelling have dominant mode of inheritance while three-cusped maxillary second molar fits a model of recessive inheritance (Scott and Turner, 2000). Overall, in contrast to tooth size, non-metric traits have a greater genetic and smaller environmental influence, making them more amenable to race differentiation. However, one should be aware that “it is very unlikely that a certain feature will be found exclusively in a given race” (Lasker, 1957). To speak of non-metric dental traits as indicators of race merely implies that they occur in higher frequencies in one race than in another (Lasker, 1957). Most dental anthropological studies undertaken over the past fifty years corroborate this conclusion (Scott and Turner, 2000).

### *Non-metric Dental Traits in Indians*

Non-metric traits show noteworthy differences in frequency and grade of expression between populations and can provide clues about race affiliation. However, they can be used to determine racial affiliation not when used as isolated traits, but when viewed as a ‘constellation of characters’ (Scott and Turner, 2000). For example, an individual with Carabelli’s cusp and four-cusped lower molars, but minimal or no shovelling, would probably be of Eurasian descent.

As stated in page 170, frequency data for few non-metric dental traits in a limited number of Indian populations exists and only these have been described in this chapter. The data enumerated in Table 4 has been compiled from Sharma and Kaul (1977), Kaul and Prakash (1981) and Kulkarni et al (1985). Considering that these three studies differ in certain aspects of methodology, it may not be completely appropriate to compare the Indian populations reported in them. However, for the purpose of comment, it may be stated that there are some similarities between the Haryana Jats and Punjabis, while the Andh tribals are relatively dissimilar (Table 12.4). This is not surprising, considering the geographic proximity (and possibly common genetic background) of the first two groups.

While shovelling and Carabelli’s cusp are the two most widely researched non-metric dental traits worldwide, data for these is not available for two populations listed in Table 12.4. Nevertheless, they have been studied in other regions of India, encompassing diverse caste and religious groups. Data for shovelling and Carabelli’s cusp from two states are presented in Tables 12.5 and 12.6. Observing the figures from Karnataka (Table 12.5), there appears to be minimal difference in central incisor shovelling between Hindus, Muslims and Christians. However, when caste-groups among Hindus are examined, there appears to be a dichotomy, with Lingayats on the one hand and Brahmins and other castes on the other. In contrast, Carabelli’s cusp shows negligible caste-based differences but does reveal differences between religious groups. Comparing the figures from Andhra Pradesh (Table 12.6), differences exist between the two Hindu groups (Brahmins and Pattusalis), however there are high similarities between Brahmins and Muslims. Further studies and in-depth analysis is required to explain the similarities and differences.



**Table 12.4:** Frequency of select non-metric dental traits for some populations of India

Trait	Haryana (Jats)	Punjab	Maharashtra (Andh tribe <sup>†</sup> )
Carabelli's cusp	16.61%*	–	–
Shovelling	55.64%*	–	–
Three-cusp upper second molar	33.47%	–	5.97%
Four-cusp lower first molar	16.61%	17.05%	17.72%
Four-cusp lower second molar	94.06%	74.42%	36.99%
Y-groove pattern	22.34%*	25.58%	67.57%
X-groove pattern	23.71%*	0.00%	12.16%
+groove pattern	53.95%*	74.4%	20.27%

[\*Significant sex differences were observed for these traits

<sup>†</sup>The sample comprised exclusively of males; the traits were observed on paraffin wax impressions, not on plaster casts]

**Table 12.5:** The frequency of shovelling and Carabelli's cusp in religious and caste groups of Karnataka\*

Population group	Shovelling	Carabelli's cusp
Muslim	9.6%	31%
Christian	11.4%	11.4%
Hindu	10.4%	25.3%
• Lingayat	13.3%	25.4%
• Brahmin	9.7%	25%
• Others (e.g. Kuruba, Kshatriya)	8.2%	25.6%

[\*Data was recorded through direct intraoral examination]

**Table 12.6:** The frequency of shovelling and Carabelli's cusp in religious and caste groups of Andhra Pradesh

Population group	Shovelling	Carabelli's cusp
Muslim	3.47%	24.68%
Brahmin	4.16%	24.89%
Pattusalis	18.62%	18.2%

### *The Accuracy of Non-metric Traits in Race Identification*

The preceding passages have provided an overview of population differences in a few non-metric dental traits in some Indian groups. However, of interest to forensic specialists is whether these population differences can be translated to successful forensic identification. In an attempt to investigate this potential, Edgar (2005) studied the teeth of African Americans ('Blacks') and American Caucasoid

**Table 12.7:** Probability of the presence and/or absence of two non-metric traits in American races

LM2C4	Present		Absent	
	Absent	Present	Absent	Present
LM1C7				
African American (AA)	18	13	26	19
American Caucasoid (AC)	86	14	22	3
Total	104	27	48	22
Probability of AA	17%	49%	55%	86%
Probability of AC	83%	51%	45%	14%

(‘Whites’) and found non-metric traits on eight teeth had sufficient differences between the two populations to aid in forensic situations. The traits included the four-cusped lower second molar (LM2C4) and cusp 7 on lower first molar (LM1C7), among others. Using complex statistical analysis such as logistic regression and Bayesian probabilities, she developed tables that could be referred to for allocating unidentified skeletal remains to one of the two races. An example is given in Table 12.7. Consider the presence and/or absence of LM2C4 and LM1C7. If the former is present and the latter absent in unidentified skeletal remains, there is 83% likelihood that the individual is American Caucasoid (AC). On the other hand, if the situation is reversed there is an 86% probability that the individual is African American (AA).

This process of differentiating two population groups, as is predominantly the case in the U.S.A, is relatively straightforward. Such an exercise, however, would be more complex in India, where a multitude of distinct communities co-exist. But it is certainly possible. Scott and Turner (2000) are optimistic that the ever-expanding database on non-metric traits, coupled with advanced statistical methods to calculate population differences, will allow the forensic investigator to assign a population to an unidentified individual with more precision.

## SUMMARY

Teeth resist postmortem change and destruction on account of their inorganic content. Consequently, the dentition has been routinely applied in forensic investigations around the world. The variable tooth anatomy, in terms of size and surface morphology, has applications in reconstructive identification of skeletal remains. While tooth measurements can be used as an adjunct in sex assessment, morphological features have relevance in identifying the population. However, further research is needed to establish tooth size and morphology databases and validate the methods for forensic investigation.

## FURTHER READING

1. Acharya AB, Mainali S. Univariate sex dimorphism in the Nepalese dentition and the use of discriminant functions in gender assessment. *Forensic Sci Int* 2007;173(1):47-56.
2. Bailit HL. Dental variation among populations: an anthropologic view. *Dent Clin North Am* 1975;19(1):125-39.

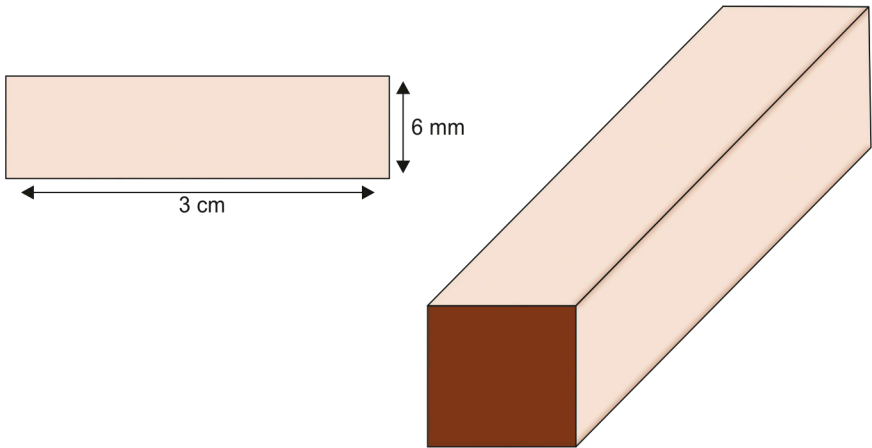
3. Barrett MJ, Brown T, Arato G, et al. Dental observations on the Australian aborigines: buccolingual crown diameters of deciduous and permanent teeth. *Aust Dent J* 1964;9:280–5.
4. Barrett MJ, Brown T, MacDonald MR. Dental observations on the Australian aborigines: mesiodistal crown diameters of permanent teeth. *Aust Dent J* 1963;8:150–6.
5. Edgar HJH. Prediction of race using characteristics of dental morphology. *J Forensic Sci* 2005;50(2):269–73.
6. Frayer DW, Wolpoff MH. Sexual dimorphism. *Ann Rev Anthropol* 1985;14:429–73.
7. Ghose LJ, Baghdady VS. Analysis of the Iraqi dentition: mesiodistal crown diameters of permanent teeth. *J Dent Res* 1979;58:1047–54.
8. Goose DH. The dental condition of Chinese living in Liverpool. In: Dahlberg AA, Graber TM. (Eds). *Orofacial growth and development*. The Hague: Mouton Publishers, 1977:183–94.
9. Harris EF, Nweeia MT. Tooth size of Ticuna Indians, Colombia, with phenetic comparisons to other Amerindians. *Am J Phys Anthropol* 1980;53:81–91.
10. Hillson S. Variation in size and shape of teeth. *Dental anthropology*. Cambridge: Cambridge University Press, 1996:68–102.
11. Kaul SS, Sharma K, Sharma JC, et al. Non-metric variants of the permanent dental crown in human monozygous and dizygous twins. In: Reddy VR. (Ed). *Dental anthropology: application and methods*. New Delhi: Inter-India Publications, 1985: 187–93.
12. Kaul V, Prakash S. Morphological features of Jat dentition. *Am J Phys Anthropol* 1981;54:123–7.
13. Kulkarni VS, Bhanu BV, Walimbe SR. Some observations on dental morphology of Andh tribe in Maharashtra. In: Reddy VR. (Ed). *Dental anthropology: application and methods*. New Delhi: Inter-India Publications, 1985: 139–47.
14. Lasker GW. Racial traits in the human teeth. *J Forensic Sci* 1957;2:404 [cited in: Scott GR and Turner CG II. *The anthropology of modern human teeth: dental morphology and its variation in recent human populations*. Cambridge: Cambridge University Press, 2000: 315].
15. Lund H, Mörmstad H. Gender determination by odontometrics in a Swedish population. *J Forensic Odontotomatol* 1999;17:30–4.
16. Matis JA, Zwemer TJ. Odontognathic discrimination of United States Indian and Eskimo groups. *J Dent Res* 1971;50(5):1245–8.
17. Moorrees CFA, Thomsen SØ, Jensen E, et al. Mesiodistal crown diameters of the deciduous and permanent teeth in individuals. *J Dent Res* 1957;36(1):39.
18. Reddy VR. Dental morphology in Karnataka and other parts of the world. In: Reddy VR (Ed). *Dental anthropology: application and methods*. New Delhi: Inter-India publications, 1985:196–249.
19. Scott GR and Turner CG II. *The anthropology of modern human teeth: dental morphology and its variation in recent human populations*. Cambridge: Cambridge University Press, 2000.
20. Sharma JC, Kaul V. Dental morphology and odontometry in Punjabis. *J Indian Anthropol Soc* 1977;12:213–26.
21. Shields ED, Altschuller B, Choi EY. Odontometric variation among American black, European, and Mongoloid populations. *J Craniofac Genet Dev Biol* 1990;10:7–18.
22. Singh SP, Goyal A. Mesiodistal crown dimensions of the permanent dentition in North Indian children. *J Indian Soc Pedod Prev Dent* 2006;24(4):192–6.

# CHAPTER 13

## Carving Steps of Different Teeth

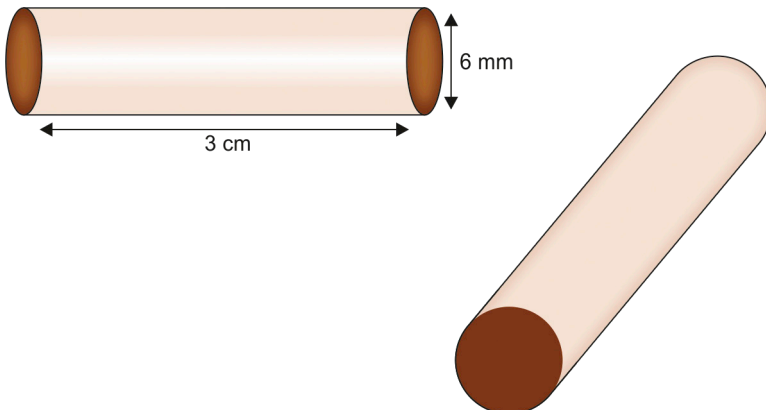
*Gururaj B Patil*

### CARVING OF A RECTANGLE FROM WAX BLOCK



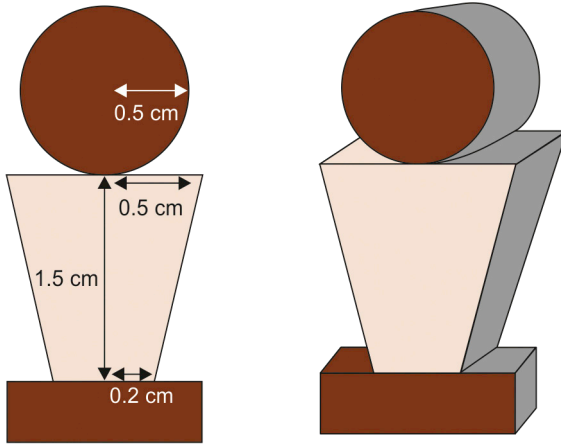
**Fig. 13.1:** Carving of a rectangle from wax block

### CARVING OF A CYLINDER FROM WAX BLOCK



**Fig. 13.2:** Carving of a cylinder from wax block

### CARVING OF A BASIC MODEL



Basic model

Fig. 13.3: Carving of a basic model

### CARVING OF CENTRAL INCISOR

1. Clean the wax block with gauze.
2. Select appropriate area to be used for carving.
3. Mark that area as mesial (M), starting from it.
4. Hold it in anatomical position and mark other areas (it should be held in anatomical position during every time when carving being observed).
5. Draw central line (1), mark required length for crown and root (2), divide crown into 3 parts as occlusal, middle, cervical 3rd (3).

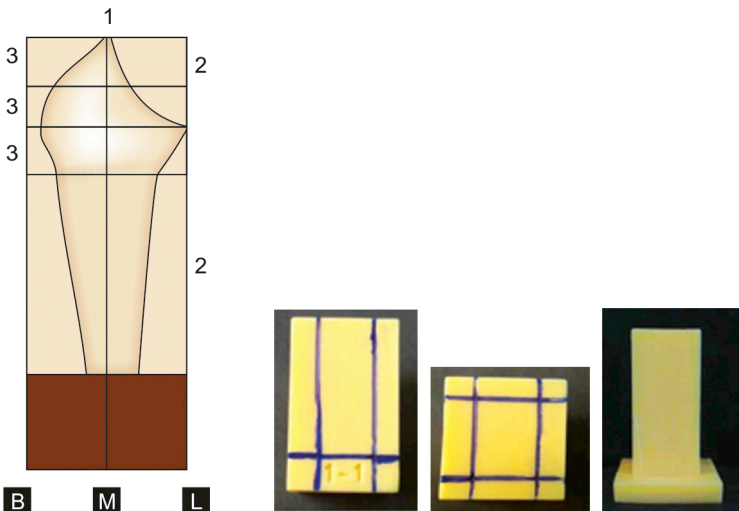
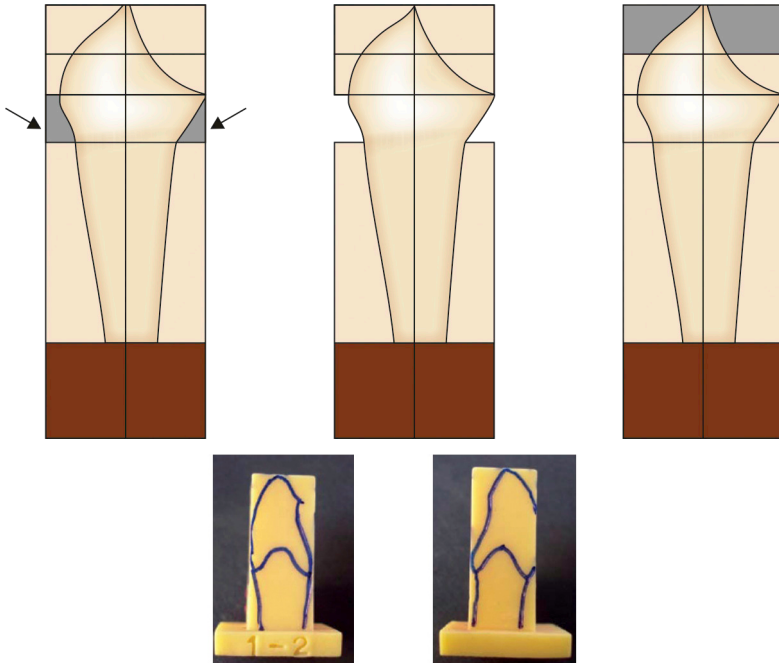



Fig. 13.4: Marking of measurements

6. Make a sharp and deep groove at cervical region (Arrow). Carve the cervical area, followed by occlusal 3rd.



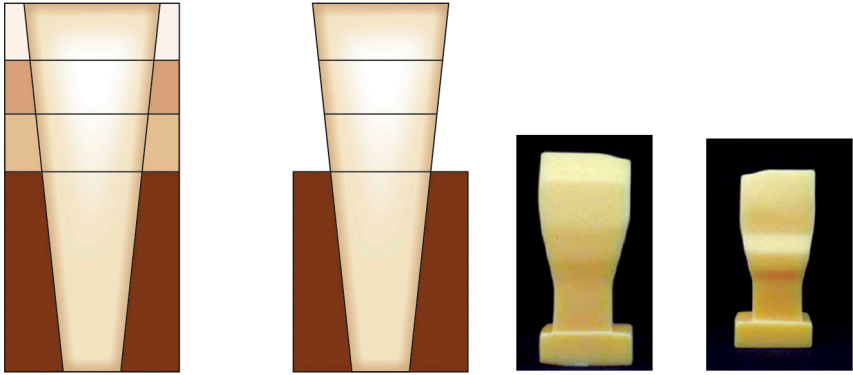
**Fig. 13.5:** Tooth outline marking from proximal surface

7. Carve the middle 3rd (Arrow).



**Fig. 13.6:** Carving of the crown from markings

8. Carve the buccal side in the similar manner.



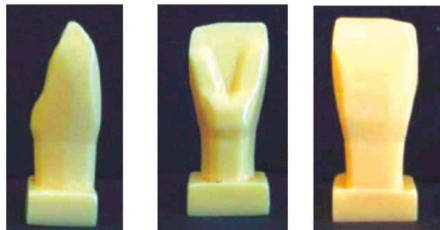
**Fig. 13.7:** Tooth outline marking from labial surface

9. Give a lingual convergence.



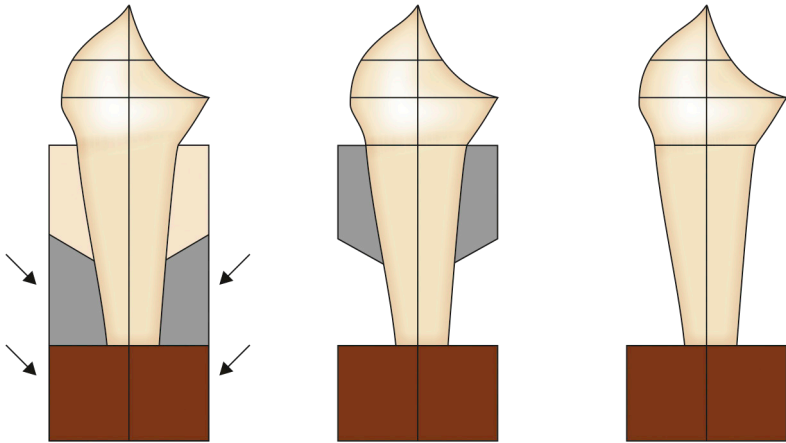
**Fig. 13.8:** Crown outline from lingual surface

10. Carve or make all line angles round.



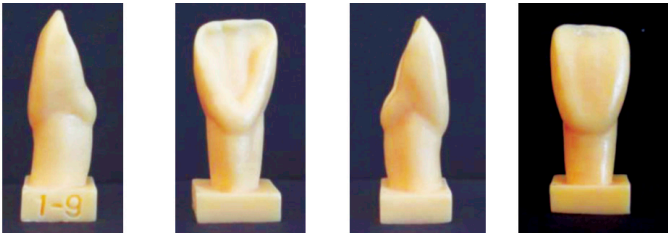
**Fig. 13.9:** Crown carving before root carving

11. Carve the apical area by making deep groove, followed by carving remaining part of the root.



**Fig. 13.10:** Carving of root

12. Carve the remaining part.



**Fig. 13.11:** Final changes to the tooth carving

13. Carve the cingulum.
14. Carve the lingual fossa.
15. Make the cervical line.
16. Make it little merging towards root.
17. Finishing polishing.



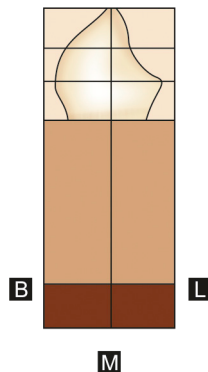
**Table 13.1:** Measurements of maxillary and mandibular incisors

Tooth no	11	12	41	42
Cervico-incisal length	10.5	9.0	9.0	9.5
Length of root	13	13.0	12.5	14.0
Mesiodistal diameter of the crown	8.5	6.5	5.0	5.5
Mesiodistal diameter of the crown at cervix	7.0	5.0	3.5	4.0
Labial or buccolingual diameter	7.0	6.0	6.0	6.5
Labial or buccolingual diameter	6.0	5.0	5.3	5.8
Curvature of cervical line—mesial	3.5	3.0	3.0	3.0
Curvature of cervical line—distal	2.5	2.0	2.0	2.0

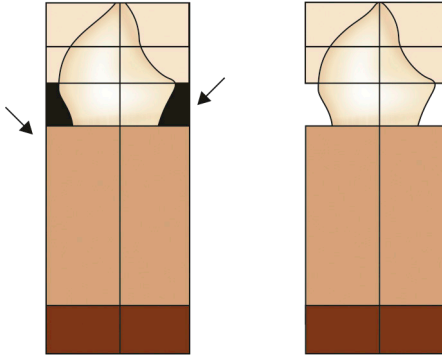
- Dimensions are in millimeter
- Mesiodistal diameter are from the contact point to contact point on both side
- And labio/buccolingual should be measured from highest line of curvature on either side.

### CARVING STEPS IN CANINE

1. Clean the wax block with gauze.
2. Select appropriate area to be used for carving.
3. Mark that area as mesial (M), starting from it.
4. Hold it in anatomical position and mark other areas (it should be held in anatomical position during every time when carving being observed).
5. Draw central line (1), mark required length for crown and root (2), divide crown into 3 parts as occlusal, middle, cervical 3rd (3).

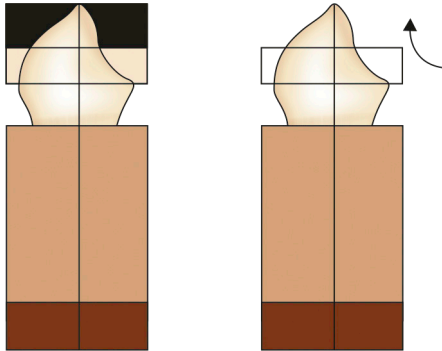
**Fig. 13.12:** Tooth outline marking from proximal surface

6. Make a sharp and deep groove at cervical region (Arrow).  
Carve the cervical area.



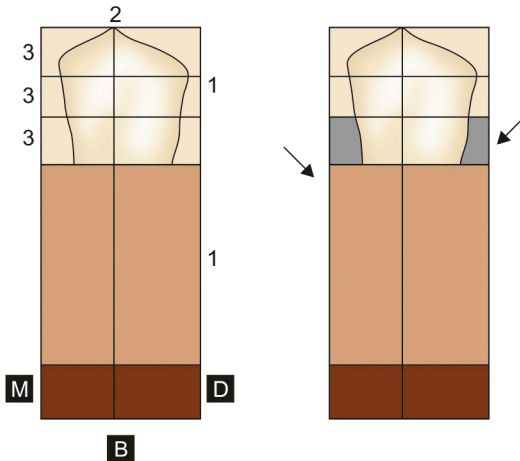
**Fig. 13.13:** Reduction of wax at cervical area

7. Carve the occlusal 3rd and carve the middle 3rd (Arrow).



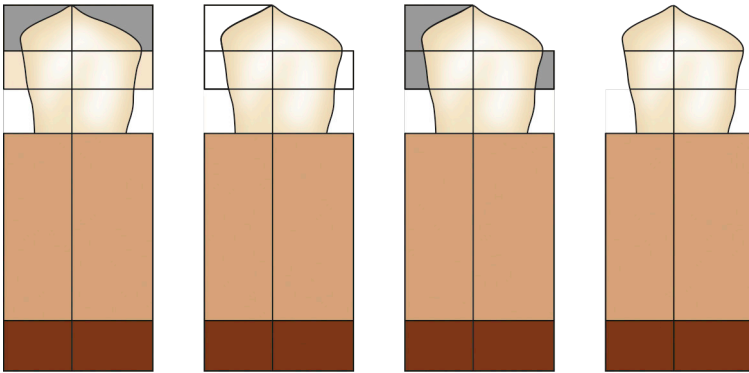
**Fig. 13.14:** Occlusal and incisal reduction

8. Buccal aspect mark mesial and distal slope and carve the adjacent part.



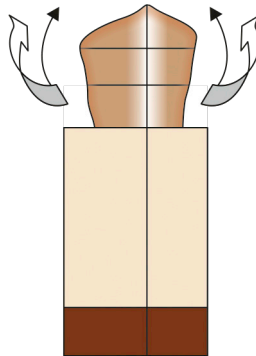
**Fig. 13.15:** Labial markings and wax reduction

9. Carve remaining parts.



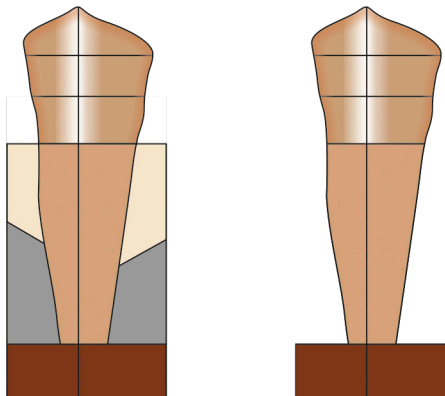
**Fig. 13.16:** Carved form of the crown

10. Carve from mesial aspect to till midline on one side, and later on other side. Maintain the labial slope running from incisal tip to cervical line (see two types of arrows).



**Fig. 13.17:** Carving of labial ridge and cusp slopes

11. Carve the root part.



**Fig. 13.18:** Root carving

12. Make the palatal side 1mm smaller and converging towards palatal side.
13. Carve the cingulum.
14. Carve the lingual fossa.
15. Make the cervical line.
16. Make it little merging towards root.
17. Finishing polishing.

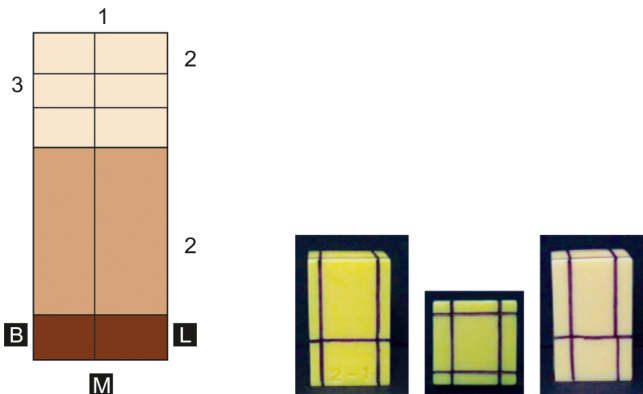
**Table 13.2:** Measurements of maxillary and mandibular canines

Tooth no	13	43
Cervico-incisal length	10.0	11.0
Length of root	17.0	16.0
Mesiodistal diameter of the crown	7.5	7.0
Mesiodistal diameter of crown at cervix	5.5	5.5
Labial or buccolingual diameter of crown	8.0	7.5
Labial or buccolingual diameter of crown at cervix	7.0	7.0
Curvature of cervical line—mesial	2.5	2.5
Curvature of cervical line—distal	1.5	1.0

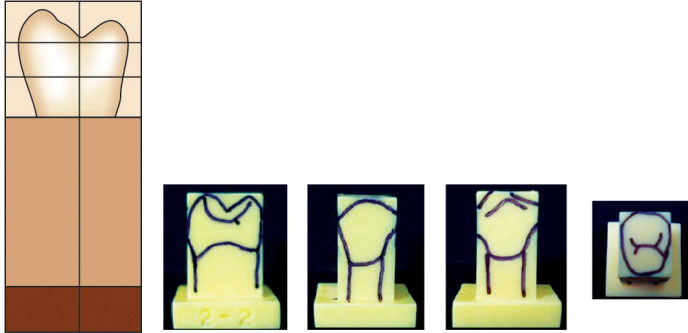
- Dimensions are in millimeter
- Mesiodistal diameter are from the contact point to contact point on both side
- And labio/buccolingual should be measured from highest line of curvature on either side.

## CARVING OF PREMOLAR

1. Clean the wax block with gauze.
2. Select appropriate area to be used for carving.
3. Mark that area as mesial (M), starting from it.
4. Hold it in anatomical position and mark other areas (it should be held in anatomical position during every time when carving being observed).
5. Draw central line (1).
6. Mark required length for crown and root (2).

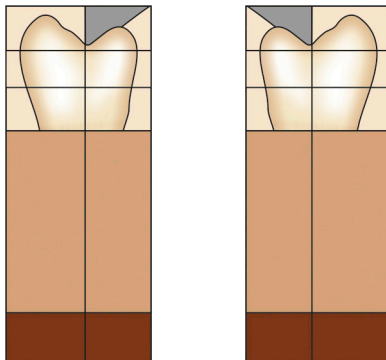
**Fig. 13.19:** Enlarged portion of crown mesial, occlusal and labial

7. Divide crown into 3 parts as occlusal, middle, cervical 3rd (3).
8. Mark the required outline on the surface (Eg; Palatal cusp of 1st premolar is 1 mm shorter than buccal cusp).



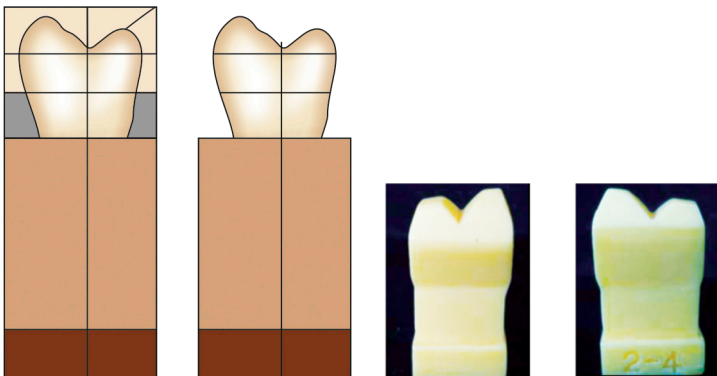
**Fig. 13.20:** Markings from all surfaces

9. Carve that part first, i.e. reduce that to central groove.



**Fig. 13.21:** Outline markings for cusps and grooves

10. Starting from cervical region, carve occlusal and middle 3rd areas.



**Fig. 13.22:** Carving of crown from proximal view

11. Carve labial aspect similar to canine, take care to not to extend on palatal cusp. And carve palatal cusp in similar but reducing the prominence of slope.

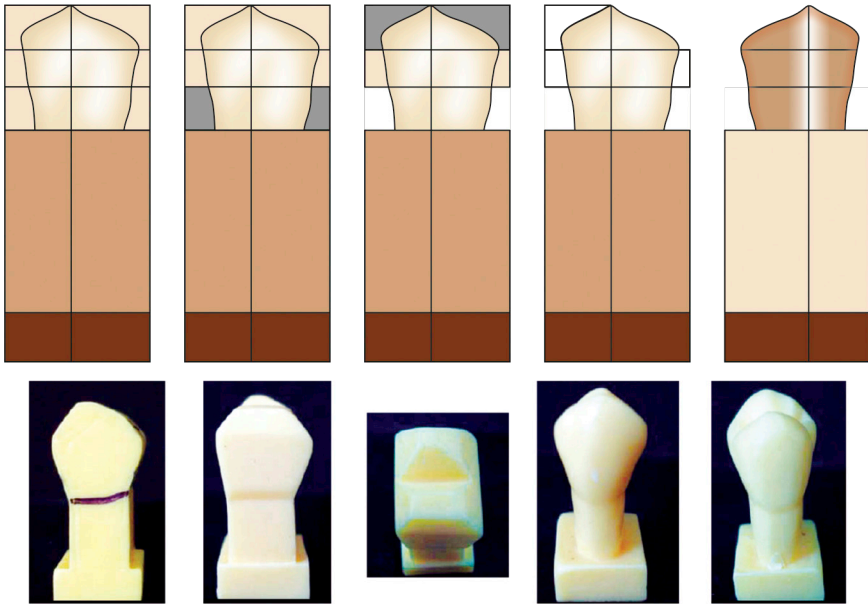


Fig. 13.23: Markings from buccal and lingual surfaces

12. Carve the occlusal aspect extend the cusp formation making cuspal slope (arrow) and forming marginal ridges.

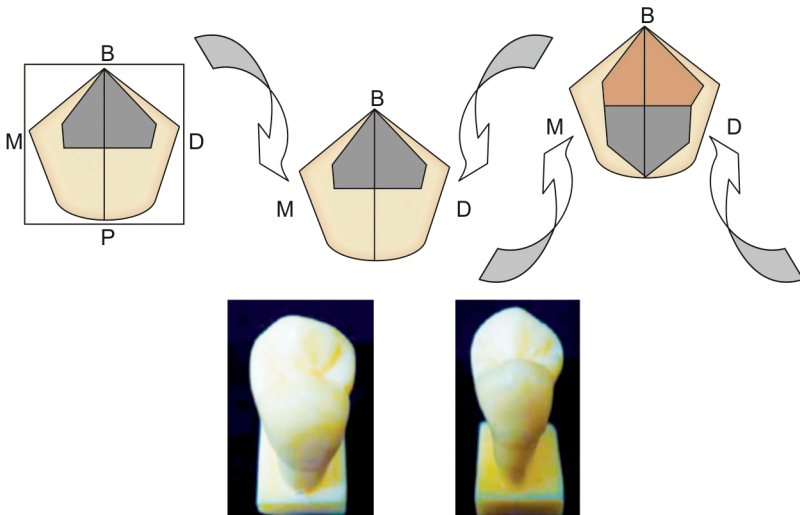


Fig. 13.24: Carving of occlusal surface

## 13. Carve the root

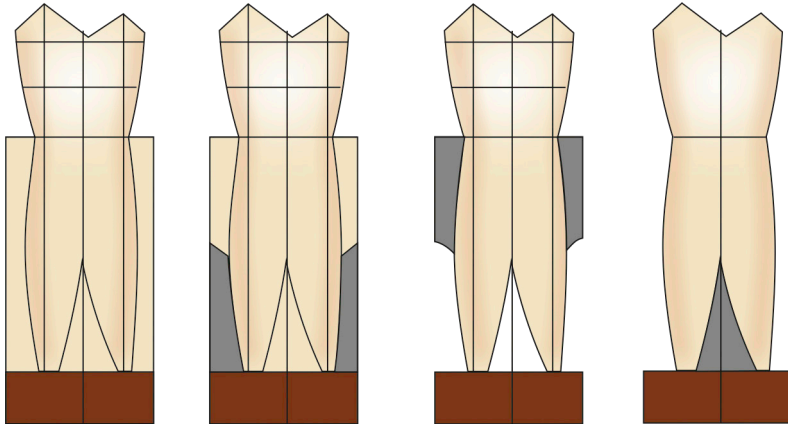


Fig. 13.25: Root carving

14. Make the cervical line.
15. Make it little merging towards root.
16. Finishing polishing.

Table 13.3: Measurements of maxillary and mandibular premolars

Tooth no	14	15	44	45
Cervico-incisal length	8.5	8.5	8.5	8.0
Length of root	14.0	14.0	14.0	14.5
Mesiodistal diameter of the crown	7.0	7.0	7.0	7.0
Mesiodistal diameter of crown at cervix	5.0	5.0	5.0	5.0
Labial or buccolingual diameter of	9.0	9.0	7.5	8.0
Labial or buccolingual diameter of	8.0	8.0	6.5	7.0
Curvature of cervical line—mesial	1.0	1.0	1.0	1.0
Curvature of cervical line—distal	0.0	0.0	0.0	0.0

- Dimensions are in millimeter
- Mesiodistal diameter are from the contact point to contact point on both side
- And labio/buccolingual should be measured from highest line of curvature on either side.

## CARVING OF MOLARS

1. Clean the wax block with gauze.
2. Select appropriate area to be used for carving.
3. Mark that area as mesial (M), starting from it.
4. Hold it in anatomical position and mark other areas (it should be held in anatomical position during every time when carving being observed).
5. Draw central line (1), mark required length for crown and root (2), divide crown into 3 parts as occlusal, middle, cervical 3rd (3).

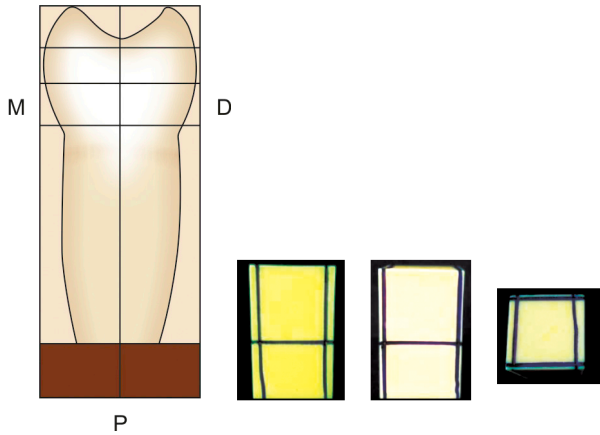


Fig. 13.26 Palatal/buccal, mesial and occlusal

6. Carving of mesial aspect and palatal aspect.

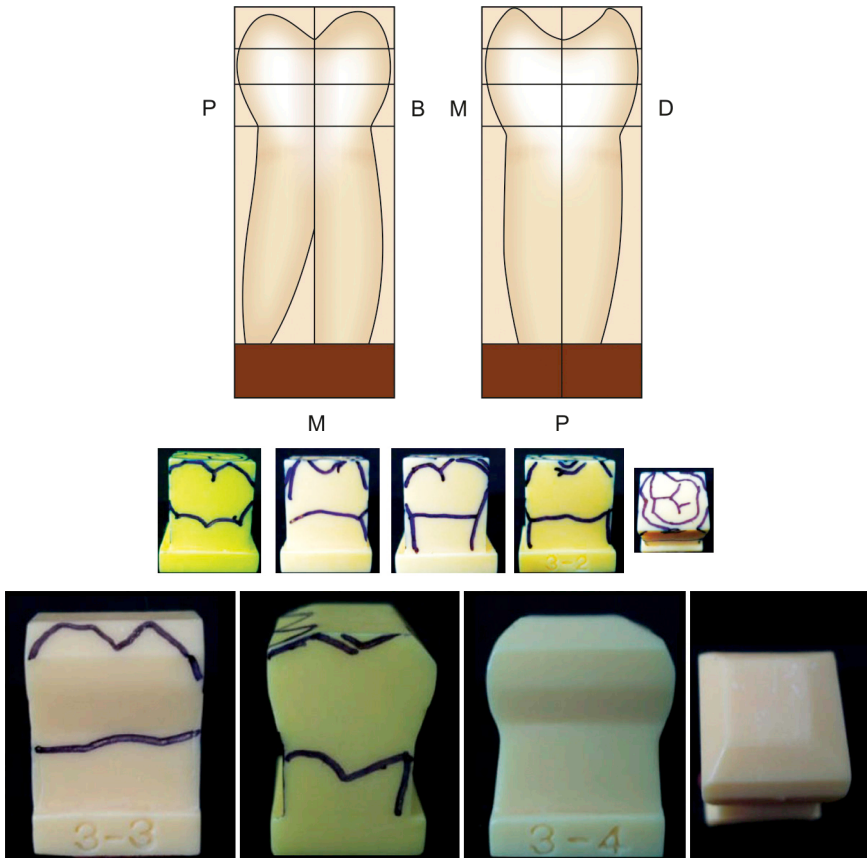


Fig. 13.27: Carving of mesial and palatal aspects



7. Draw the occlusal outline make it rhomboidal shape.

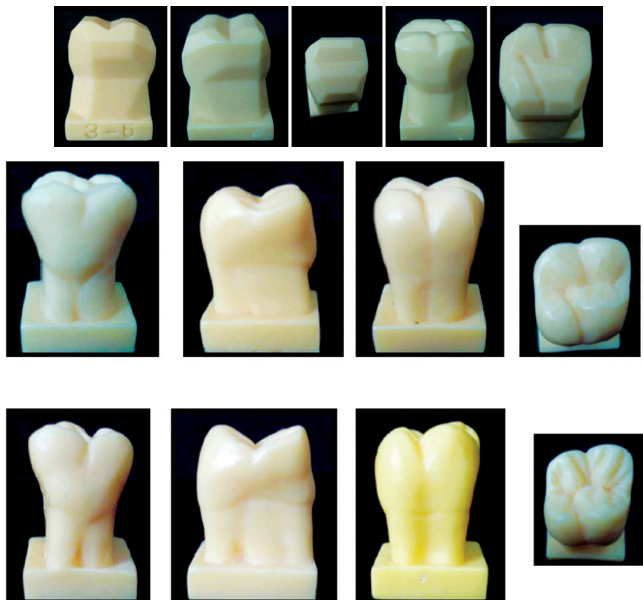
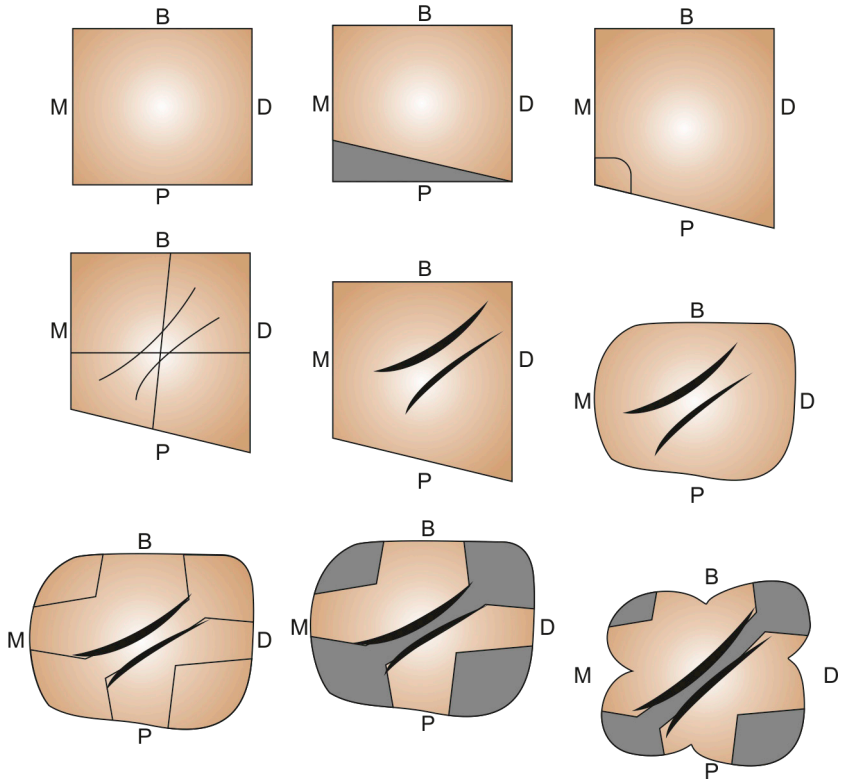


Fig. 13.28: Occlusal outline marking and carving

8. Carve the root on all sides.

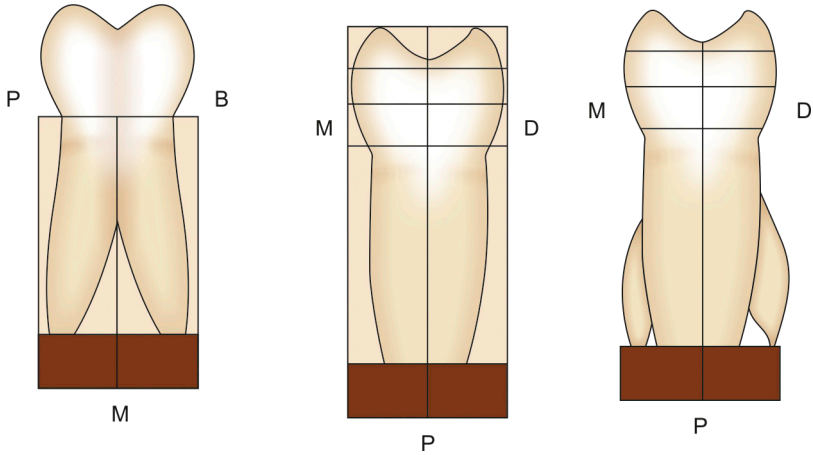


Fig. 13.29: Root carving

9. Make the cervical line.
10. Make it little merging towards root.
11. Finishing polishing.

### CARVING OF MANDIBULAR MOLAR

1. It has similar steps to that of maxillary molar.

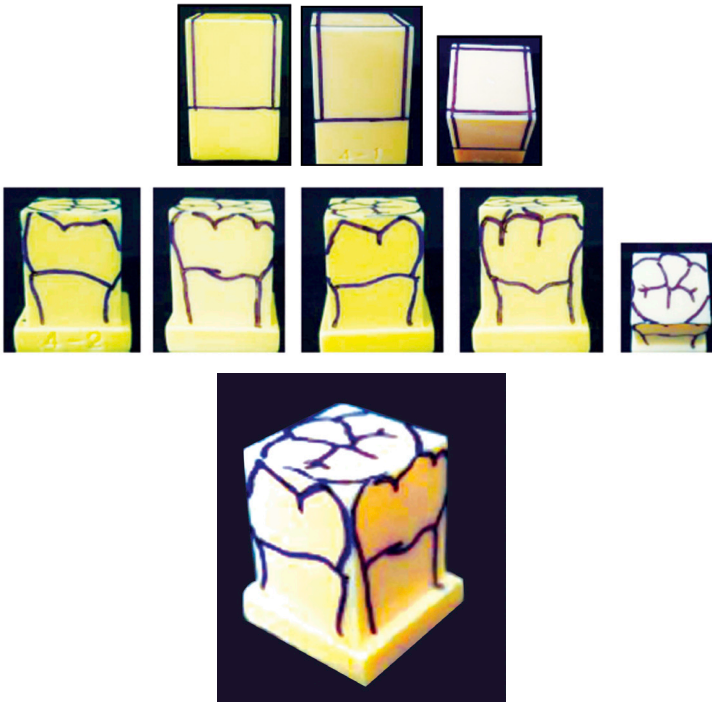


Fig. 13.30: Buccal, mesial and occlusal outline markings

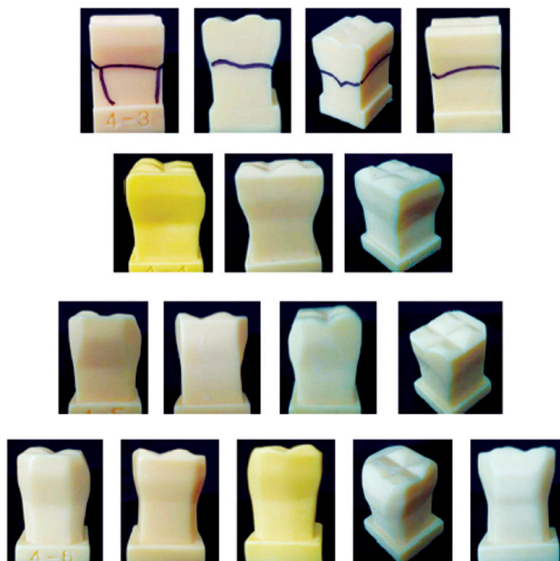

Fig. 13.31: Cervical line and root markings

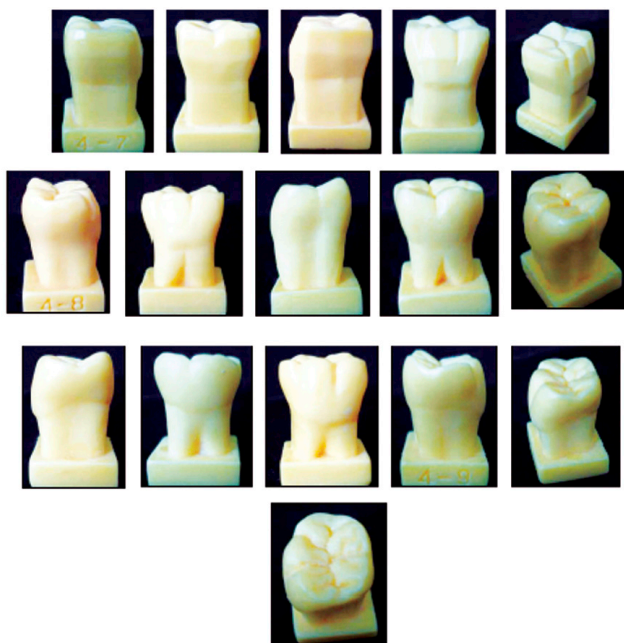

Fig. 13.32: Root carving

**Table 13.4:** Measurements of maxillary and mandibular molars

Tooth no	16	17	46	47
Cervico-incisal length	7.5	7.0	7.5	7.0
Length of root	B-12 L-13	B-11 L-12	14.0	13.0
Mesiodistal diameter of the crown	10.0	9.0	11.0	10.5
Mesiodistal diameter of crown at cervix	8.0	7.0	9.0	8.0
Labial or buccolingual diameter of	11.0	11.0	10.5	10.0
Labial or buccolingual diameter of	10.0	10.0	9.0	9.0
Curvature of cervical line—mesial	1.0	1.0	1.0	1.0
Curvature of cervical line—distal	0.0	0.0	0.0	0.0

- Dimensions are in millimeter
- Mesiodistal diameter are from the contact point to contact point on both side
- And labio/buccolingual should be measured from highest line of curvature on either side.

# CHAPTER

# 14

## Trait Features of Teeth

Manjunatha BS

<i>Maxillary central incisor</i>	<i>Maxillary lateral incisor</i>
<i>Facial view</i>	
1. Crown size is larger from all surfaces	1. Crown size is smaller from all surfaces
2. The crown shape is almost square	2. The crown shape is oblong
3. The crown is more symmetrical	3. The crown is more less symmetrical
4. The mesio-incisal (MI) line angle is 90°	4. The mesio-incisal (MI) line angle is rounded and acute
5. The disto-incisal (DI) line angle is rounded	5. The disto-incisal (DI) line angle is more rounded
6. The Incisal edge is almost straight	6. The Incisal edge slopes cervically in distal end
7. Crown and root length are almost same { C: R ratio is 1: 1.25}	7. Crown and root length vary much { C: R ratio is 1: 1.4}
8. The root is conical and straight	8. The root is more flatter and curved distally at the apical third
9. Mamelons common and prominent	9. Mamelons rare and crown is shorter 1 mm
<i>Lingual view</i>	
1. Cingulum is placed slightly to distal	1. Cingulum is placed in center
2. lingual fossa is large and shallow	2. lingual fossa is small and deeper
<i>Incisal view</i>	
1. The crown is wider MD than LaLi	1. The MD width is almost equal to LaLi
2. The outline is triangular	2. The outline is oval or round
3. Developmental variations are seldom	3. The second most common tooth to have many developmental variations

*Mandibular central incisor*

1. The crown is symmetrical bilaterally
2. The tooth is smaller than LI by 0.5 to 1 mm
3. Both the MI and DI angles are sharp and 90°
4. Both the mesial and distal contacts are at the same level at the incisal third
5. The crown is not tilted and is straight
6. Both mesial and distal outlines are equal
7. Cingulum is placed in center
8. The incisal edge is straight

*Mandibular lateral incisor*

1. The crown is not symmetrical
2. The tooth is larger than CI by 0.5 to 1 mm
3. The MI angle is sharp the DI angle is rounded
4. The mesial and the distal contacts are at different levels. Mesial at the incisal third and the distal slightly cervical
5. The crown is tilted to distal side
6. The mesial outline is longer than the distal outline
7. Cingulum is placed slightly to distal
8. The incisal edge curved slightly lingual

*Maxillary incisors*

1. Crowns are larger in size
2. Irregular lingual surface with prominent cingulum, lingual fossa and marginal ridges
3. Roots are conical
4. The mesiodistal (MD) width is more than Labiolingual (LaLi)
5. Crowns are wider in MD dimension
6. The mesial and distal outlines are more convex
7. The Incisal edge is labial to central line of long axis of the tooth
8. Maxillary incisors are esthetically very important
9. The outline from incisal is triangular
10. Developmental variations are common

*Mandibular incisors*

1. Crowns are smaller in size (smaller teeth than any other)
2. The lingual surface is less pronounced and very smooth
3. Roots are flatter mesiodistally
4. The Labiolingual (LaLi) width is more than mesiodistal (MD)
5. Crowns are narrower in MD dimension
6. Both the mesial and distal outlines are straight
7. The Incisal edge is lingual to central line of long axis of the tooth
8. These teeth are esthetically not as important as the maxillary incisors
9. The outline is oval or round
10. Developmental variations are not many

**Maxillary canine****Mandibular canine***Facial view*

- |   |  |
|---|--|
| <ol style="list-style-type: none"> <li>1. Crown size is larger from all surfaces</li> <li>2. The cusp tip is sharp and 105°</li> <li>3. The mesiodistal dimension is more</li> <li>4. The crown is more symmetrical</li> <li>5. The distal slope is more horizontal</li> <li>6. The labial ridge is prominent</li> <li>7. The mesial outline is convex till cervix</li> <li>8. The root is conical and bulky</li> </ol> | <ol style="list-style-type: none"> <li>1. Crown size is smaller from all surfaces</li> <li>2. The cusp tip is blunt and 120°</li> <li>3. The mesiodistal dimension is less and constricted</li> <li>4. The crown is less symmetrical</li> <li>5. The distal slope is more oblique</li> <li>6. The labial ridge is less prominent</li> <li>7. The mesial outline is in line with root</li> <li>8. The root is more flatter</li> </ol> |
|---|--|

*Lingual view*

- |   |   |
|---|---|
| <ol style="list-style-type: none"> <li>1. Cingulum and lingual fossae are prominent</li> <li>2. The cingulum is more prominent and distally placed</li> </ol> | <ol style="list-style-type: none"> <li>1. Cingulum and lingual fossae are less prominent</li> <li>2. The cingulum is less prominent and centrally placed</li> </ol> |
|---|---|

*Incisal view*

- |   |   |
|---|---|
| <ol style="list-style-type: none"> <li>1. The slopes are straight from MD</li> <li>2. The cusp tip is placed labial to the long axis</li> </ol> | <ol style="list-style-type: none"> <li>1. The distal slope is bent lingually</li> <li>2. The cusp tip is placed lingual to the long axis</li> </ol> |
|---|---|

**Maxillary first premolar****Maxillary second premolar***General features*

- |  |   |
|--|---|
| <ol style="list-style-type: none"> <li>1. The crown has two cusps and two roots</li> </ol> | <ol style="list-style-type: none"> <li>1. The crown has two cusps and one root</li> </ol> |
|--|---|

*Facial view*

- |   |   |
|---|---|
| <ol style="list-style-type: none"> <li>1. The buccal cusp tip is distally placed</li> <li>2. The mesial slope of buccal cusp is longer</li> <li>3. The buccal cusp is more pointed and is about 105°</li> </ol> | <ol style="list-style-type: none"> <li>1. The buccal cusp tip is mesially placed</li> <li>2. The distal slope of buccal cusp is longer</li> <li>3. The buccal cusp is pointed and wider about 120°</li> </ol> |
|---|---|

*Proximal view*

- |  |   |
|--|---|
| <ol style="list-style-type: none"> <li>1. The lingual cusp is shorter than buccal by 1 mm</li> <li>2. Two roots and furcation seen</li> <li>3. Has mesial marginal ridge groove on mesial surface</li> <li>4. Has a concavity on the mesial surface below the cervical line</li> </ol> | <ol style="list-style-type: none"> <li>1. The lingual cusp is equal to the buccal cusp</li> <li>2. Only one root and no furcation area</li> <li>3. No such groove</li> <li>4. Has no concavity</li> </ol> |
|--|---|

*Occlusal view*

- |   |  |
|---|--|
| <ol style="list-style-type: none"> <li>5. Hexagonal appearance</li> <li>6. Central groove is longer</li> <li>7. No or few supplemental grooves</li> </ol> | <ol style="list-style-type: none"> <li>5. More oval</li> <li>6. Central groove is shorter</li> <li>7. Supplemental grooves are many</li> </ol> |
|---|--|

*Mandibular first premolar*

*General features*

1. The crown has two cusps
2. Lingual cusp is non-functional
3. Crown and roots are longer

*Facial view*

1. The buccal cusp tip is sharp and pointed, about 110°
2. The mesial contact and the marginal ridges are more cervical than distal

*Lingual view*

1. The lingual cusp is very much shorter than buccal
2. Lingual convergence is more
3. Most of mesial and distal surfaces are seen
4. Has a mesiolingual groove separating the mesial and lingual surfaces
5. Do not have such groove

*Proximal view*

1. Marginal ridges and triangular ridges slope cervically at about 45°
2. The crest of curvature on buccal surface is at the cervical third

*Occlusal view*

1. Diamond shaped
2. A small transverse ridge is formed

*Mandibular second premolar*

1. The crown has two or three cusps
2. All cusps are functional
3. Shorter than first premolar

1. The buccal cusp tip is blunt and about 130°
2. The mesial contact and the marginal ridges are occlusal than distal

1. The lingual cusp/s equal to the buccal cusp
2. Lingual convergence is slight or absent
3. Not seen
4. Do not have such groove
5. Has lingual groove separating two lingual cusps

1. Marginal ridges and triangular ridges are horizontally placed
2. The crest of curvature on buccal surface is at the middle third

1. Square shaped
2. No such ridge is formed

*Maxillary premolars*

1. Crowns are trapezoidal
2. Lingual cusps are almost equal
3. Buccal and lingual cusps are well-developed
4. No lingual tilt or bending of crown
5. Cusp tips are in the center
6. Hexagonal from occlusal outline
7. Wider buccolingually

*Mandibular premolars*

1. Crowns are rhomboidal
2. Lingual cusps are shorter than buccal
3. Lingual cusps are not as developed as buccal
4. Crowns tilt or bend lingually
5. Cusp tips are lingual to the root
6. Diamond or square in outline
7. Almost equal BL and MD



**Maxillary first molar**

1. Largest tooth in both arches
2. Cusp of Carabelli present
3. MD and BL are almost same
4. The DL is better developed
5. Less varied occlusal surface
6. Roots are flaring or spread wider
7. Few supplemental grooves on occlusal surface
8. Prominent oblique ridge
9. Distal cusps are well-formed
10. Crown square to rhomboidal (both acute angles and obtuse angles are slightly so)

**Maxillary second molar**

1. Smaller than first molar
2. No cusp of Carabelli
3. MD is more than BL
4. The DL cusp is smaller or rudimentary
5. Varied occlusal surface (3 cusp type or heart shaped)
6. Roots do not flare
7. Supplemental grooves are many
8. Less prominent or smaller
9. Both distal cusps are well-developed
10. Completely rhomboidal (acute angles are more acute and obtuse angles are more obtuse)

**Mandibular first molar****General features**

1. The crown has five cusps
2. Tooth is less symmetrical
3. The crown and root height are longer
4. Roots more divergent

**Facial view**

1. The buccal surface has two grooves and 2–3 cusps
2. The mesial contact less wider

**Lingual view**

1. The lingual convergence is more
2. Contact areas are more occlusal

**Proximal view**

1. Broader buccolingual
2. Distal cusp is seen
3. Distobuccal groove seen

**Occlusal view**

1. Five cusps seen
2. Pentagonal outline
3. Transverse ridges are not prominent
4. Groove pattern is zigzag
5. Few supplemental grooves

**Mandibular Second Molar**

1. The crown has four cusps
2. Tooth is more symmetrical
3. Shorter than first molar
4. Roots parallel and close together

1. The buccal surface has one groove and two cusps
2. The mesial contact is more wider

1. The lingual convergence is less
2. Contact areas are more cervical

1. Less broader
2. No distal cusp
3. No distobuccal groove

1. Four cusps
2. More rectangular outline
3. Two well-formed transverse ridges
4. Groove pattern cross shaped
5. Supplemental grooves are more

*Maxillary molars*

1. Wider buccolingually
2. 3 to 5 cusps are seen
3. Lingual cusps vary more in size
4. Buccal cusps are sharp and higher
5. More square or rhomboidal outline
6. Two major and two minor fossae
7. Fifth cusp is non-functional and on ML
8. One buccal groove on buccal surface of first molar
9. Crown do not tilt lingually
10. Three roots
11. Oblique ridge present and no transverse ridge

*Mandibular molars*

1. Wider mesiodistally
2. 4 to 5 cusps are seen
3. Lingual cusps are equal
4. Lingual cusps are sharp and higher
5. More rectangular or pentagonal outline
6. One major and two minor fossae
7. Fifth cusp in functional and distal
8. Two buccal grooves on buccal of first molar
9. Crowns tilt lingually
10. Two roots
11. No oblique ridge and transverse ridge seen

# CHAPTER 15

# Calcium and Phosphorus Metabolism

*Manjunatha BS*

## INTRODUCTION

Calcium is very essential for everyone from infants to elder and a major component in the mineralization of bones and teeth. Calcium is the most abundant mineral in the human body. It is vital for all age group including growing children, youngsters, pregnant women and old people in maintenance of bone. “Calcium plays an important role in making stronger, denser bones early in life and keeping bones strong and healthy later in life.” Calcium and phosphate metabolism is based on a balance between intestinal absorption, bone mineralization and demineralization, and urinary filtration and reabsorption. Calcium is not only involved with structure of bone but also has many other important functions.

## PHYSIOLOGICAL FUNCTIONS OF CALCIUM

Calcium plays a central role in a number of physiological processes that are essential for life. Most important of them are as follows:

- Calcium is necessary for several activities including neuromuscular transmission, smooth and skeletal muscle contraction, nerve function, cell division and movement, and certain oxidative processes
- Intracellular calcium plays an important role in signal transduction pathways, where it acts as a second messenger. Calcium ion is a co-factor or ‘biologic transducer’ in the depolarization of cell membranes
- It is also involved in many intracellular responses to chemical and electrical stimuli and helps in the activation of many intracellular enzyme systems for highest activity
- Calcium entry via specific channels leads to direct effects, e.g. neurotransmitter release in neurons
- Plays a vital role in muscle contraction. Calcium function in muscle contraction was found as early as 1882 by Ringer and binds to several different calcium-modulated proteins such as troponin-C, which are necessary for promoting contraction in muscle. Calcium ion is involved in conversion of electrical activity into contraction of skeletal, cardiac, and smooth muscles
- Many different calcium binding proteins such as troponin and calmodulin have been described. Calmodulin causes changes in arrangement to proteins and enzyme activation.

- Extracellular calcium is also important for maintaining the potential difference across excitable cell membranes
- Calcium ion has a role in the process of blood coagulation and acts as co-factor in many steps during blood coagulation
- Calcium plays a crucial role in maintaining body metabolism and digestion
- The levels of calcium in the body are also important as it helps to produce enzymes and hormones necessary for releasing energy.

### DISTRIBUTION IN THE BODY

Majority of calcium in combination with phosphate form hydroxyapatite crystals seen both in the skeleton and teeth. Calcium is also an integral component of body muscles, nervous system, bones and teeth. So, it is an important component of a healthy diet and a mineral necessary for life. 99% of body calcium is stored in bones and teeth and the remaining 1% is mostly found between the intracellular (1%) and extracellular (0.1%) fluid compartments. The extracellular calcium occurs in three forms: 50% ionized form, 40% protein bound (mainly albumin) as calcium–anion complexes and 10% complexed to anions (such as phosphate). Ionized calcium is the physiologically active form that is regulated by the body for normal functioning of numerous biochemical processes. The total amount of calcium in a tissue may be measured using an instrument called ‘**atomic absorption spectrometry**’.

### DIETARY SOURCES OF CALCIUM

Fortunately, many good sources of calcium exist. The best sources of calcium (Figs 15.1 and 15.2) are dairy products such as milk, cheese, yogurt, etc. The vegetable sources include: peas, beans, almonds, soybeans, lentils, fresh leafy



**Fig. 15.1:** Calcium-rich dietary sources

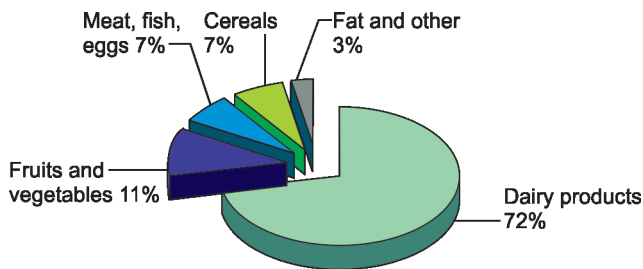


Fig. 15.2: Calcium content of different foods

vegetables, eggs, and fish. It is important to note that vitamin D is needed for the absorption of calcium in to the bloodstream. Therefore, one need to add vitamin D in the diet to facilitate calcium absorption in the body.

### CALCIUM ABSORPTION

Thirty to eighty percent of ingested calcium is absorbed, primarily in the upper part of the small intestine. Absorption of calcium involves a combination of passive and active processes. Absorption is related to calcium intake. If intake is low, active transport in the duodenum is increased and a larger proportion of calcium is absorbed by the active process compared with the passive process that occurs in the jejunum and ileum. Active transport of calcium depends on the presence of vitamin D. Passive absorption in the jejunum and ileum predominates when dietary calcium intake is adequate or high.

Calcium first enters the body by crossing the epithelial surface of the gastrointestinal (GI) tract and transverse the tight junctions between epithelial cells and passively diffuses down due to electrical and concentration gradient that occurs throughout the intestinal tract. The active transport of calcium absorption takes place predominantly in the duodenum and upper jejunum. Transcellular transport is a protein-mediated process that is driven by vitamin D and has a larger role in calcium absorption when dietary calcium intake is low.

Usually, not more than 10% of total absorption takes place in the large intestine, but this site becomes nutritionally important in conditions of significant small bowel resection. Calcium absorption is inhibited by phosphates and oxalates because these form insoluble salts with calcium in the intestine.

Hence, the absorption of calcium is predominantly via an active transport mechanism in the GI tract. The amount of calcium absorption depends on many factors such as age, gender, vitamin D stores and the amount of calcium containing food that is ingested.

### RECOMMENDED DIETARY ALLOWANCE

The element calcium is essential for children and youngsters in their body growth. However, women during pregnancy require more calcium rich diet as during nursing period, they lose the element to their baby.

Recommended dietary allowance (RDA) is the average daily level of intake sufficient to meet the nutrient requirements of nearly all (97%–98%) healthy

individuals. Studies indicate the average daily amount of calcium consumed by normal adult is about 500–1,000 mg. A general recommendation of daily calcium intake is 1,200–1,500 mg usually and most people consume calcium from their diets. These values usually vary depending on the age and gender, physiological conditions which include pregnancy, lactation, puberty, menopause, etc. and hence a total calcium intake is ranged between 800–2400 mg. Recommended daily intake of calcium varies accordingly and is as follows:

- For infants: 400–600 mg
- For children upto 10 years: 800 mg
- For teenagers and adults of ages 11–24 years: 1000–1200 mg
- A pregnant woman requires additional calcium and is about 1200–1400 mg
- For Lactating women: 1300 mg
- Many experts believe that elderly persons should take as much as 1,500 mg.

### CALCIUM BALANCE

Calcium balance refers to the state of the body stores of calcium at equilibrium over a period of time. The urinary excretion of calcium ions is approximately equal to the net absorption from the gastrointestinal tract. Bone remodeling takes place at all times and bone being the major source of calcium, a continuous balance between the processes of bone formation and bone resorption is needed. Such a balance is brought about by several hormonal and non-hormonal factors. These factors include inorganic phosphate, calcium ion, magnesium ion, vitamin D, adrenal glucocorticoids, parathyroid hormone, and calcitonin.

Bone balance changes throughout the normal lifespan, depending on relative rates of bone formation and resorption. Children are in positive bone balance (formation > resorption), which ensures normal, healthy musculoskeletal growth. Healthy, young adults are in neutral bone balance (formation = resorption) and have achieved maximum bone mass. Elderly individuals are typically in negative bone balance (formation < resorption), which leads to age-related bone loss. Numerous factors are involved that produce both positive and negative bone balance in all age groups.

### CALCIUM HOMEOSTASIS

Calcium metabolism or calcium homeostasis is the mechanism by which the body maintains adequate calcium levels. Calcium metabolism is comprised primarily of absorption, urinary excretion, endogenous secretion and bone turnover. The maintenance of a constant free ionized calcium concentration is biologically important for the function of excitable tissues. Abnormalities in serum calcium values may have profound effects on neurological, gastrointestinal and renal function. Plasma calcium levels are regulated by hormonal and non-hormonal mechanisms.

The normal serum level calcium is closely regulated with total calcium of 9–10.5 mg/dl. When the circulating concentration of calcium falls below the normal range of 8.5 to 10.5 mg/dl, parathyroid hormone (PTH) is released from parathyroid glands to correct this fluctuation.

The calcium concentrations in blood are very stable in normal healthy individuals because of the homeostatic system involving the actions of calciotropic hormones on the target organs. The plasma calcium concentration is tightly controlled by a complex mechanism involving movement or exchange of calcium between the extracellular fluid and the kidney, bone, and gut. Normal calcium homeostasis is primarily dependent on the interactions to maintain the ionized calcium concentration within a very normal range (Fig. 15.3).

The hormones which regulate calcium level in blood are:

- Parathyroid hormone (PTH)
- Calcitonin
- Vitamin D or 1, 25-dihydroxyvitamin D [1,25(OH)<sub>2</sub>D<sub>3</sub>].

### PARATHYROID HORMONE

Parathyroid hormone (PTH) is synthesized by the chief cells of the parathyroid glands, which are located behind the thyroid. The parathyroid hormone is produced in response to low calcium levels. The half life of PTH is about 10 minutes and is excreted via kidneys as smaller peptides. The normal PTH level in the blood is 10–50 pg/ml.

PTH is a very potent regulator of plasma calcium and plays a central role in the rapid control of calcium homeostasis. Secretion of PTH is highly dependent on the ionized calcium concentration and represents in a simple negative feedback method. Its synchronized actions on bone, kidneys and intestine increase the flow of calcium into the extracellular fluid and increase the concentration of calcium in blood. The serum PTH concentration decreases as the serum calcium concentration

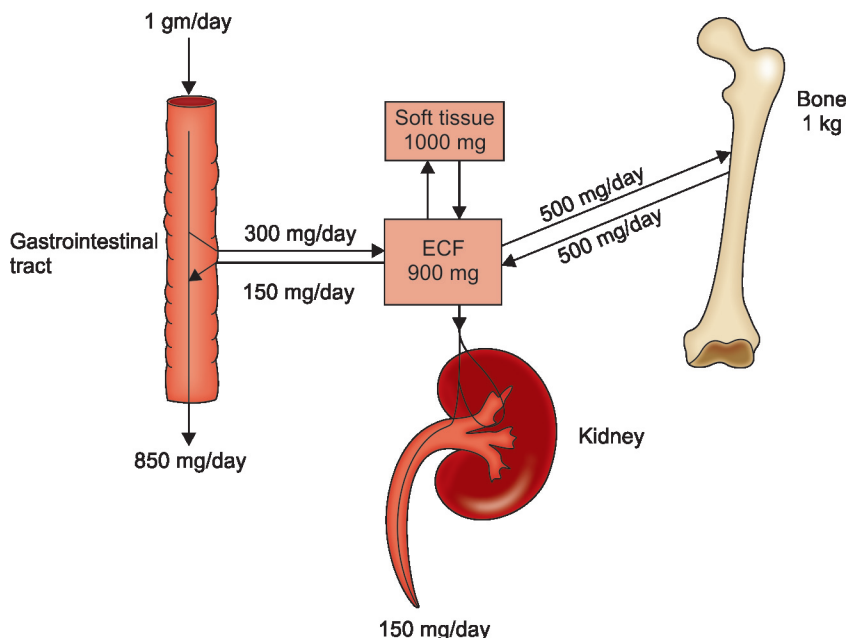


Fig. 15.3: Normal calcium homeostasis

increases. PTH binds to specific receptors on the membrane of target cells such as renal and bone cells, fibroblasts, chondrocytes, vascular smooth muscle, etc. PTH acts on membrane receptors to produce its effects on target cells. The receptors are  $\text{PTH}_1\text{-R}$  present on renal cells and osteocytes.  $\text{PTH}_2\text{-R}$  and  $\text{CPTH-R}$  are seen in non calcified tissues.

The biological actions of PTH include the following (Fig. 15.4):

- Stimulation of osteoclastic bone resorption and release of calcium and phosphate from bone
- Stimulation of calcium reabsorption and inhibition of phosphate reabsorption from the renal tubules
- Stimulation of renal production of  $1,25(\text{OH})_2\text{D}_3$ , which increases intestinal absorption of calcium and phosphate.

### Parathyroid Hormone and Kidneys

The effects of PTH on the kidney include:

- Increased reabsorption of  $\text{Ca}^{2+}$  from the glomerular filtrate. The major physiological effect of PTH is enhancement of  $\text{Ca}^{2+}$  reabsorption. This is due to effects on: the thick ascending loop of Henle, the distal convoluted tubule and the collecting tubules. Hence, the  $\text{Ca}^{2+}$  clearance is decreased by PTH and increased in the absence of PTH
- Increased phosphate excretion. PTH acts on the proximal and distal convoluted tubules and inhibits  $\text{Na}^+$  dependent phosphate absorption
- Increased bicarbonate clearance and reabsorption of  $\text{Ca}^{2+}$  in the proximal renal tubule
- Increased activity of vitamin D1 hydroxylase.

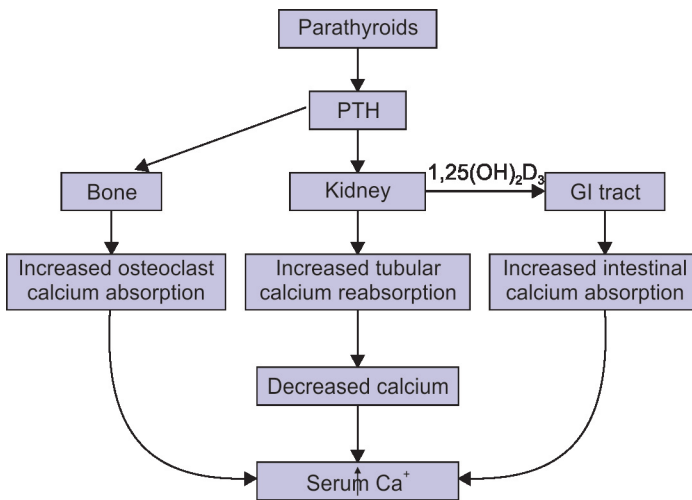


Fig. 15.4: Parathormone and calcium



## Parathyroid Hormone and Bone

When there is a major fall in calcium concentration in blood, PTH acts on bone matrix and increases the outflow of calcium from bone. PTH acts on:

- Osteoblast receptors to secrete mRNA (messengers) which stimulate osteoclasts to resorb bone matrix and release calcium into the ECF. Osteoblasts are the primary bone cells that interact directly with PTH. PTH inhibits osteoblasts and stimulates osteoclast-mediated bone resorption, leading to an increase in acid phosphatase and increased urinary hydroxyproline which are markers of increased breakdown of bone matrix. Signals from osteoblast receptors stimulate the development of osteoclasts from blood precursors
- PTH produces both anabolic and catabolic effects, which can be differentiated as early phase (involving the mobilization of  $\text{Ca}^{2+}$  from bone in rapid equilibrium with the extracellular fluids) and late phase resulting on increased synthesis of bone enzymes, such as lysosomal enzymes which promote reabsorption and bone remodelling
- PTH acts both on osteoblasts and osteoclasts via intracellular cAMP resulting in increase in the permeability to calcium ions
- PTH related hormone protein (PTHrHP) stimulates chondrocyte proliferation in cartilage and decreases the mineralization of cartilage.

## Parathyroid Hormone and Intestine

PTH does not directly affect gastrointestinal absorption of  $\text{Ca}^{2+}$ . Its effects are mediated indirectly through regulation of synthesis of vitamin D [ $1,25(\text{OH})_2\text{D}_3$ ] in the kidney.

## CALCITONIN

Calcitonin is synthesized and secreted by the parafollicular or 'C' cells of the thyroid gland in response to high calcium levels, but its significance is much smaller than that of PTH. Calcitonin is secreted as 'preprocalcitonin'. The ionized calcium concentration is the most important regulator of calcitonin secretion. Increased calcium level in blood results in an increased calcitonin secretion and conversely, a fall in the calcium concentration inhibits calcitonin secretion. The precise biological role of calcitonin in the calcium homeostasis is uncertain. The half life of calcitonin is less than 10 minutes. The effects of calcitonin are transient and likely have little role in calcium homeostasis in long run, although they may be important in short-term control of calcium levels. Calcitonin is slightly higher in males than in females and this may be one reason for osteoporosis more susceptible in females.

Actions of calcitonin are as follows (Fig. 15.5):

- Reduces the number of active osteoclasts and inhibit bone resorption. Calcitonin acts directly on osteoclasts
- Increases the urinary excretion of calcium by inhibiting reabsorption in distal part of nephrons
- Has protective influence on bone formation in foetus and children
- Protects maternal bone during pregnancy.

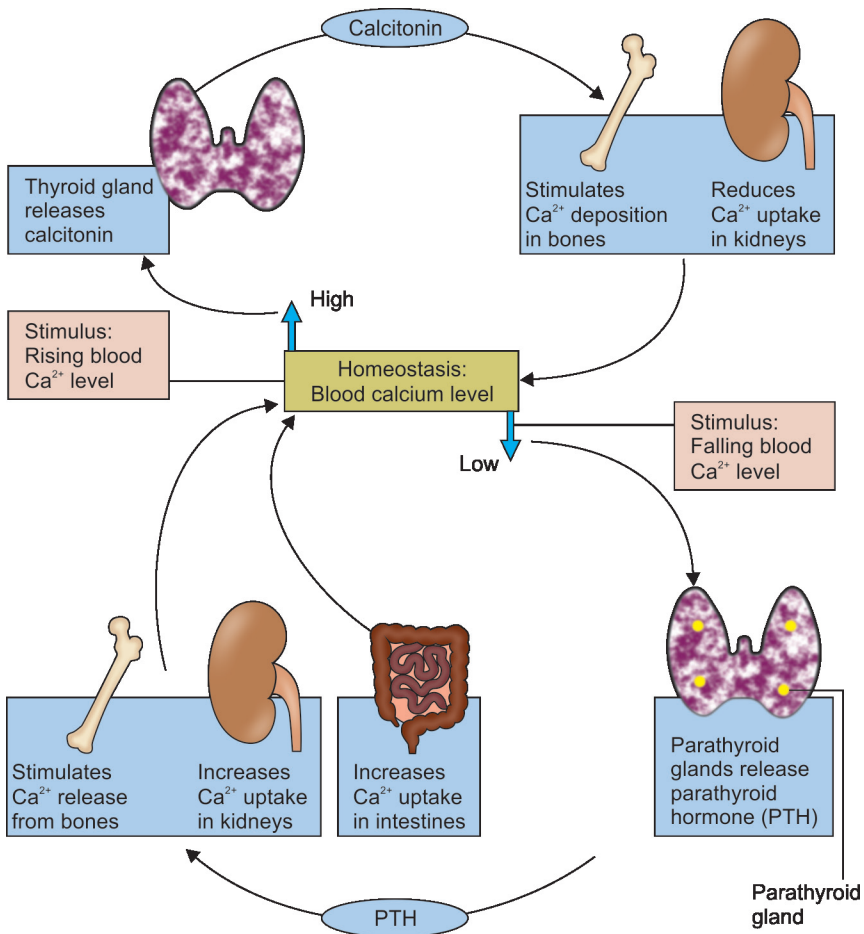


Fig. 15.5: Calcium homeostasis

Calcitonin is many hormones like gastrin, cholecystokinin-pancreozymin, secretin and glucagon which are seen in gastrointestinal tract.

## VITAMIN D

The hormone 1,25(OH)<sub>2</sub>D<sub>3</sub> [vitamin D<sub>3</sub>] is the major biologically active metabolite of the vitamin D. The vitamin D precursor (previtamin D<sub>3</sub>) is either ingested in the diet or synthesized in the skin through exposure to sunlight. Hydroxylation of 7-dehydrocholesterol occurs in the liver from 25-hydroxyvitamin D. 25-Hydroxyvitamin D is again hydroxylated in the kidney by hydroxylase, to form 1,25(OH)<sub>2</sub>D<sub>3</sub>. Vitamin D increases plasma calcium and phosphate concentrations by:

- Increasing the absorption of calcium and phosphate from the gastrointestinal tract
- It also increases bone resorption and enhances the effects of PTH in the kidneys to promote renal tubular calcium reabsorption

- It is a potent agent for differentiation of osteoclast resulting in multinucleated giant cells (osteoclasts) that are capable of resorbing bone.

By these actions, vitamin D [1,25(OH)2D3] provides a supply of calcium and phosphate available at bone surfaces. In humans, the half-life of active form of vitamin D [1,25(OH)2D3] in the circulation is approximately 5 hours.

### EFFECTS OF OTHER HORMONES ON CALCIUM METABOLISM

Many hormones, which are normally present in the body also have their effect on calcium. But these hormones have minimum effect on calcium stability in blood and sometimes the effects may be quite significant. Most important are:

- **Growth hormone:**
  - Increases the calcium excretion in the urine, but it also increases intestinal absorption of calcium. Thus, maintains the total body calcium level
  - Stimulates the synthesis of proteins in bone by production of insulin like growth factors
  - Stimulates the long bones to increase in length with the help of stomatomedin C acting on cartilage during growth
  - Contributes significantly in thickening and lengthening of bones. Example: In acromegaly, growth hormone level is increased.
- **Insulin:** It favors the formation of bone and it is important during development of the foetus and early life of an individual. Hence, there is significant bone loss in untreated diabetes
- **Testosterone:** Acts on cartilage resulting in increased growth of secondary sexual characteristics of bones like increase in dimension of shoulders, development of supraorbital ridges and increase in size of mandible in males.
- **Estrogens:**
  - Act on cartilage and convert to endochondral ossification
  - Prevent osteoporosis by a direct effect on osteoblasts
- **Prolactin:** It stimulates both intestinal absorption and mobilization of calcium from bone by favoring hydroxylation of vitamin D
- **Thyroid hormones:** This stimulate bone growth and may cause hypercalcemia, hypercalciuria, and in some cases osteoporosis
- **Glucocorticoids:** Lower the serum calcium levels by inhibiting formation and activity of osteoclast cells. They also decrease the absorption of calcium from the intestine by an anti-vitamin D action and increased renal excretion of calcium. However, long periods they cause osteoporosis by decreasing bone formation and increasing bone resorption.

### APPLIED PHYSIOLOGY

Disorders of calcium metabolism occur when the body has too little or too much calcium. The serum level of calcium is closely regulated within a fairly limited range in the human body. Hypocalcemia and hypercalcemia are terms used clinically to refer to abnormally low and high serum calcium concentrations. They indicate serious disruption of calcium homeostasis but do not reflect calcium balance on their own. Hypercalcemia is marked elevation of serum calcium, usually more than 14 mg/dL and can result from many disorders.

## Causes

One of the most common causes of hypercalcemia is an overproduction of parathyroid hormone, or hyperparathyroidism. Hypercalcemia is divided into PTH-mediated hypercalcemia (primary hyperparathyroidism) and non-PTH-mediated hypercalcemia.

- PTH-mediated hypercalcemia is related to increased calcium absorption from the intestine
- Non-PTH-mediated hypercalcemia includes the following:
  - Hypercalcemia associated with malignancy
  - Granulomatous disorders
  - Iatrogenic
- Other causes
  - Neoplasms
  - Pharmacologic agents—thiazide, calcium carbonate (antacid), hypervitaminosis A and D
  - Endocrinopathies—hyperthyroidism, adrenal insufficiency, pheochromocytoma
  - Miscellaneous—immobilization, hypophosphatasia, advanced chronic liver disease.

## Hypocalcemia

The absence of enough calcium in blood is known as hypocalcemia. In this condition, the level of serum calcium in blood is less than 9 mg/dl. Hypocalcemia is very common to see among the patients who are hospitalized for a long time. Hypocalcemia can be life-threatening which depends on the duration and severity. The causes of hypocalcemia are very wide. The main reasons for this disease are deficiency of parathyroid hormone or PTH, deficiency of vitamin D. It has a close relation with low PTH level. In case of chronic renal failure, the vitamin D is not competent as the calcium level falls.

Hypocalcemia may happen for these reasons:

- Hypoparathyroidism
- Vitamin D deficiency/resistance
- Chronic renal failure
- Intestinal malabsorption
- Pseudohypoparathyroidism
- Alkalosis
- Very low birth weight
- Hypoalbuminemia
- Hyperphosphatemia.

## PHOSPHATE METABOLISM

Phosphate is needed for bone mineralization and structural components of cells such as phospholipids, nucleotides, phosphoproteins for energy storage as ATP, for oxygen transport in red blood cell and for acid-base balance as a cellular and urinary buffer.

Phosphates in blood exist as either organic or inorganic compounds. Plasma phosphate measures the inorganic component. Total plasma phosphate in an adult ranges from 0.80 to 1.35 mmol/L. The range in children is 1.2–1.9 mmol/L due to the increased activity of growth hormone and reduced levels of gonadal hormones. The distribution of plasma phosphate between protein-bound, ionized and complexed forms when the total plasma phosphate is 1.00 mmol/L is:

- 15% protein bound
- 53% ionized
- 47% complexed with calcium or magnesium.

Intracellular phosphate is approximately 100 mmol/L, with 5 mmol/L existing in the inorganic form and 95 mmol/L existing in the organic form (ATP, ADP, creatine phosphate). These intracellular forms are readily changeable.

### Distribution of Total Body Phosphate

- Bone and teeth—85 %
- Soft tissues—4.3 %
- Interstitial fluid—0.03 %
- Plasma—0.2 %
- RBC—0.26 %.

### Phosphorus Balance

Phosphorus balance includes both the organic and inorganic forms. Like calcium, phosphorus balance is also maintained by intestinal absorption, renal excretion, and bone formation. However, there are several important differences between phosphorus and calcium balance. Phosphorus absorption is rarely limited. Unlike calcium, phosphorus is present in abundance in most foods. Dietary phosphorus is absorbed almost twice as efficiently as calcium. Thus, phosphorus absorption is rarely a nutritional problem.

### Daily Phosphorus Requirement

The normal daily phosphate intake is approximately 40 mmol. Around 60–70% is absorbed in the duodenum and upper jejunum. Normal urinary phosphate excretion is 30 mmol/day, 15 mmol/day is excreted with feces. There is no tubular secretion of phosphate. Of the 180 mmol/day of filtered phosphate, approximately 70–85% is reabsorbed in the proximal tubule and 20% is reabsorbed by the distal part of nephrons. Ionized calcium controls PTH secretion, indirectly controls urinary phosphate excretion. When plasma phosphate increases then tubular reabsorption also increases up to a maximum subsequently phosphate is excreted. The tubular reabsorption is decreased by PTH, renal vasodilation, saline and sodium bicarbonate. The minimum oral requirement for phosphate is about 20 mmol/day.

### Calcium-phosphate Interactions

Calcium and phosphate interact in several fundamental processes. In the skeleton, calcium and phosphate metabolism work in close association with osteoblasts, osteocytes and extracellular matrix proteins resulting in mineralization of osteoid

when deposited. On the other hand, in nonskeletal tissues, prevents the harmful deposition of calcium-phosphate complexes in soft tissues. The phenomenon of this regulatory system is a less understood.

### SUMMARY

A decrease in ionized calcium concentration is immediately recognized by the parathyroid glands, which respond with an increase in PTH secretion. PTH increases osteoclastic bone resorption, releasing calcium and phosphate from bone into the ECF. PTH also causes increased renal tubular reabsorption of calcium as well as inhibition of phosphate reabsorption. PTH stimulates synthesis of vitamin D, which further increases absorption of calcium and phosphate from the intestine. All these mechanisms result in the extracellular calcium concentrations to normal.

In the reverse situation, a rise in ionized calcium concentration causes a decrease in PTH secretion from the parathyroid glands. Thus, renal tubular calcium reabsorption and osteoclastic bone resorption are decreased. Synthesis of vitamin D is also decreased, which, in turn, decreases absorption of dietary calcium and phosphate. Thus, a healthy individual responds to increase in ionized calcium with an increase in renal calcium excretion and a decrease in intestinal absorption of calcium. In general, these hormonal responses are more effective in protecting against hypocalcemia than hypercalcemia.

### FURTHER READING

1. Baker SB, Worthley LI. The essentials of calcium, magnesium and phosphate metabolism: part I. Physiology. *Crit Care Resusc.* 2002;4(4):301-6.
2. Bronner F, Pansu D. Nutritional aspects of calcium absorption. *J of Nutri* 1999;129:9-12.
3. Bushinsky DA, Monk RD. Calcium. *Lancet* 1998;352:306-11.
4. Guyton AC. Parathyroid hormone, calcitonin, calcium and phosphate metabolism, vitamin D, bone and teeth. *Text Book of Medical Physiology*;2001:899-915.
5. Peacock M. Calcium metabolism in health and disease. *Clin J Am Soc Nephrol* 2010; 5:23-30.

Human beings have teeth with rich and unique anatomic characteristics and thus necessitate a comprehensive learning. Every individual has extremely varied tooth form normally and is very difficult to reproduce. The functions of teeth vary, depending on their individual shape and size, contour and alignment and location in the jaws. Each type of tooth has its own function and shape. Hence, all these features are to be learned accordingly. The human teeth have three major functions, and are grouped as follows for descriptive purposes.

- Mastication—chewing
- Esthetics—appearance
- Phonetics—speech.
- **Mastication or chewing of food:** Teeth are part of the digestive system. Mastication is the primary function of all teeth and are used in cutting, holding or grasping, shearing and chewing or grinding. Functions of deglutition and or swallowing are done with the help of teeth.

Incisors are located in the anterior part of the oral cavity and are designed to cut food without the use of heavy forces. Canines, also known as cuspids, located at the corners of the arch and are designed for cutting and tearing foods. Premolars are seen between canines and molars, having both pointed cusps and a broader surface to hold and chewing food. Molars are larger than any other teeth having more than two cusps that are used to chew or grind the food

- **Keep pleasant appearance:** Teeth help in keeping the normal harmonious facial profile. Without teeth, an individual's face looks shrunken. If the teeth are kept in good health, the facial appearance will be better
- **Pronunciation and articulation:** Pronunciation is basically controlled by vocal cord, but it needs to work along with teeth in order to pronounce different sounds accurately (Please note both these features in cleft lip/palate and edentulous patients)
- **Others:** Many other functions such as
  - Maintain space for permanent teeth to erupt: Beneath each deciduous tooth, a developing permanent tooth is present. Deciduous teeth reserve the space needed for the eruption of permanent teeth into oral cavity. When permanent teeth begin to erupt, deciduous teeth will fall off naturally and are replaced by permanent teeth

- Growth of the skull and facial structures are seen with the development of teeth. When teeth are not formed, the growth of associated structures such as alveolar bone and other facial structures are also affected
- Protection to soft tissues of the mouth
- Next to fingerprints, teeth are the most useful tool in determining positive identification of human remains. The use of dentition for identification of an individual has been well-established in the field of forensics. Many significant relationships exist between the characteristics of teeth and the identifiers sex, race, and age. Hence, dentists should have the basic knowledge and skills to perform forensic dental analysis. Analysis of dentition generally includes examination of number and shape of teeth. Many dental traits such as crown size and shape, tooth eruption and Carabelli's cusp have been used for this purpose. There is a separate branch specialized for this and is termed as 'forensic odontology' and is discussed in detail in Chapter 12.



# CHAPTER 17

## Pain

Nagarajappa Das, Manjunatha BS

*“Pain is not a sensation, it is an experience”*

—Dr Welden E Bell

### DEFINITIONS

According to the International Association for the Study of Pain, Pain is “an unpleasant sensory and emotional experience associated with actual or potential tissue damage, or described in terms of such damage” (Merskey, 1986).

**Monheim:** Pain is “an unpleasant emotional experience usually initiated by noxious stimulus and transmitted over a specialized neural network to the CNS where it is interpreted as such”.

### HISTORY

- Homer—arrows shot by the gods
- Aristotle—‘passion of the soul’
- Plato—emotional experience
- Bible—anguish of the soul
- Freud—solution to emotional conflicts.

### COMPONENTS OF PAIN

- Fast pain
- Slow pain.

The differences between these two types are enlisted below as Table 17.1

**Table 17.1:** Differences between fast and slow pain

<i>Fast pain</i>	<i>Slow pain</i>
1. Thermal, mechanical stimuli	1. Chemical stimuli
2. Easily localized,	2. Difficult to locate
3. Sharp, A $\delta$	3. Deep, dull, aching suffering, persistence C, subs P-increase
4. Directly to thalamus (ventrobasal complex)cortex (somatosensory area) -motor cortex-muscle action\reflex	4. Via reticular formation (bulboreticular facilitory area/reticular inhibitory area) thalamus (intralaminar nuclei) frontal cortex, limbic, hypothalamus-affective

## TYPES OF PAIN

- Acute and chronic
- Primary and heterotopic
- Inflammatory and non-inflammatory

Major differences between acute and chronic pain are presented in Table form (Table 17.2)

**Table 17.2:** Acute and chronic pain

<i>Acute pain</i>	<i>Chronic pain</i>
1. Associated with tissue damage	1. Associated with infections
2. Wound threat to tissue damage e.g. excessive pressure	2. Disease process e.g. rheumatoid arthritis TMJ dysfunction
3. Shorter duration	3. Longer periods
4. Intermittent	4. Continuous

### Primary Pain and Heterotopic Pain

- Primary—structures—hurt
- Heterotopic pain felt at some distance from actual lesion
  - Central pain
  - Projected pain
  - Referred pain.

### Referred Pain

The pain sensation produced in some parts of the body is felt in other structures away from the place of pain development. This is known as referred pain e.g. Cardiac pain is felt at the inner part of left arm and left shoulder.

Referred pain is wholly spontaneous and is not accentuated by provocation of site. It ceases immediately if primary pain is arrested. It may be felt in either superficial or deep structures depending on the site of primary pain. Referred pain usually occurs within a single nerve passing from one branch to other. It follows dermatome pattern.

Pain may be referred from teeth to other orofacial structures, or it may be referred from distant anatomic sites to teeth. Acute odontogenic pain often has a component that is felt in one or more adjacent teeth of the same arch, in teeth of opposing arch or in both locations.

Referred odontogenic pain is most commonly associated with irreversible pulpitis and frequently felt as headache. Pain from distant anatomic sites is also referred to teeth and commonly resembles odontogenic pain. A thorough clinical examination and diagnosis is essential to differentiate true odontogenic pain from such kind of referred pain.

## THEORIES OF PAIN

- Specificity theory (Descartes-1644)
- Pattern theory (Goldscheider-1894)
- Gate control theory (Melzac and Wall-1965)
- Protopoctic and epicritic theory
- Intensity theory.

### Specificity Theory (Descartes 1644)

This theory was provided by Descartes in 1644 when he conceived of pain as a straight through channel from skin to the brain. It refers to a pain system based on a specific set of peripheral nerve fibers that are nociceptive in function.

At the periphery are sets of free nerve endings. A-delta and C-fibers associated with two qualities of pain—short latency prickling pain and long latency burning pain respectively. A pain center was thought to exist within the brain, which was responsible for all the avert manifestations.

Specificity theory cannot explain:

- Any pathologic pain produced by mild noxious stimuli
- Referred pain that can be triggered by mild innocuous stimulation of normal skin
- Do not explain the paroxysmal episodes of pain produced by mild stimulation of trigger zone in trigeminal neuralgia.

### Pattern Theory (Gold Sheider 1894)

In 1894, Gold Sheider was the first to propose that stimulus intensity and central summation are the critical determinants of pain. The theory suggested that particular pattern of nerve impulses that evoke pain are produced by the summation of sensory input within the dorsal horn of the spinal column. Pain results when the total output of the cells exceeds a critical level.

For example, touch + pressure + heat  $\longrightarrow$  pain

### Gate Control Theory (Melzac and Wall 1965)

This theory was proposed by Melzac and Wall in 1965. This theory of pain contains elements of both specificity and pattern theories. Gate control theory propose a dorsal spinal gating mechanism in the substantia gelatinosa that modulates sensory input by the balance of activity of small diameter (A-delta C) and large diameter (A-beta) fibers (Figs 17.1 and 17.2).

#### *Postulates of Gate Control Theory*

- Information about presence of injury is transmitted to the CNS by small peripheral nerves
- Cells in the spinal cord or nucleus of the 5th cranial nerve which are excited by these injury signals are also facilitated or inhibited by other large peripheral nerves that also carry information about innocuous event
- Descending control systems originating in the brain modulate the excitability of cells that transmit information about injury.

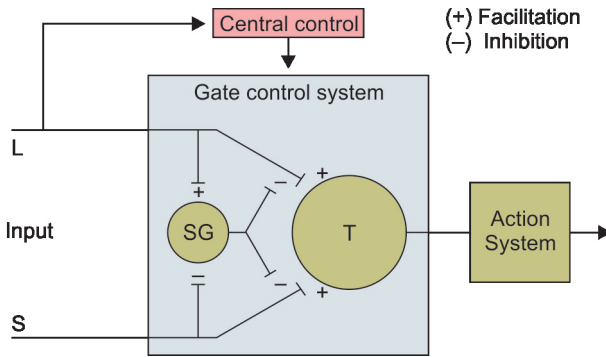


Fig. 17.1: Diagrammatic representation of gate control system

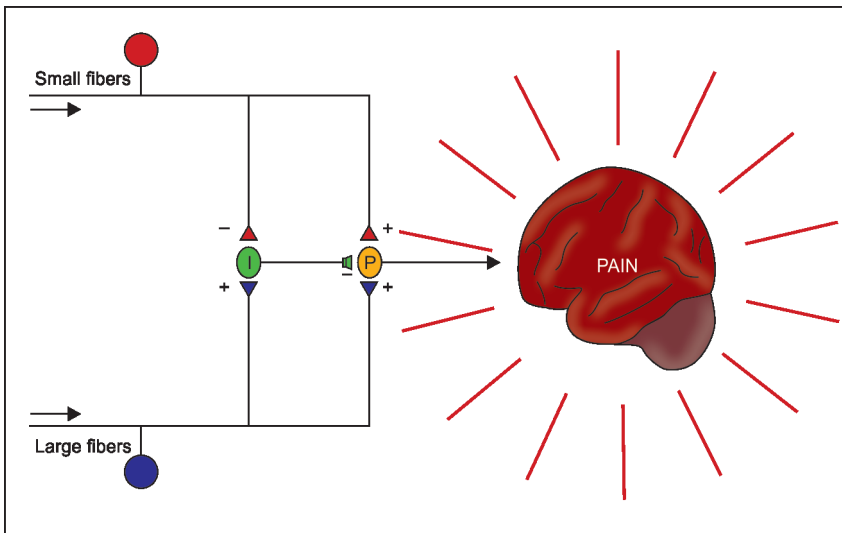


Fig. 17.2: Brain stimulation during gate control

Therefore, the brain receives messages about injury by the way of Gate control system, which is influenced by:

- Injury signals
- Other types of afferent impulses
- Descending control

### *Protopathic and Epicritic*

This theory postulated the existence of 2 groups of cutaneous sensory nerves extending from periphery to CNS. Protopathic is a primitive system, whereas epicritic is concerned with tactile discrimination and small change in temperature.

### **Intensity Theory**

Pain is produced when any sensory nerve is stimulated beyond a certain level. This pain is a non-specific sensation and depends only on high intensity stimulation. But in case of trigeminal neuralgia, this theory does not hold good.

Factors influencing pain experience:

- Level of arousal of brainstem
- Prior experiences
- Memory
- Autoconditioning
- Expectancy
- Emotional state
- Fear, rage
- Helplessness, sadness, depression
- Emotional stress—Glaros et al (JADA, 2005).

### DISTRIBUTION OF PAIN RECEPTORS

Pain is an unpleasant sensory experience elicited by the application of noxious stimuli. The receptors of pain are known as nociceptors (Noceo in greek means hurt). These receptors respond to variety of stimuli producing pain.

Nociceptors are present all over in our body except in the brain. They are abundant in the superficial layer, skin and mucosa. Approximately, each square centimeter of skin contains 200 pain receptors.

- **Oral cavity:** In the oral cavity receptors are abundant in the oral mucosa, tooth, periodontal ligament and TMJ.

### PATHWAY OF PAIN IN OROFACIAL REGION

This pathway is a somatosensory kinesthetic pathway, which is constituted by 2 groups of neurons:

- First order neurons
- Second order neurons

Pain sensation from face is carried by the trigeminal nerve. Trigeminal nerve carries somatosensory information from face, teeth, periodontal tissues, oral cavity, nasal cavity, cranial duramatter and major part of scalp to sensory cortex. The sensory fibers of the nerve arise from the trigeminal ganglion and the peripheral neurons in this ganglion form the 3 divisions of the nerve namely ophthalmic, mandibular and maxillary divisions. The central processes from the neurons of the ganglion enter pons in the form of sensory root.

### DENTINAL SENSITIVITY AND PULPAL PAIN

- **Tooth innervation:** The dental pulp is richly innervated. Nerves enter the pulp through the apical foramina and together form the neurovascular bundle. Each nerve fiber provides with a number of terminal branches that contribute to form an extensive plexus of nerves in the cell free zone of Weil called the subodontoblastic plexus of Rashkow (Figs 17.3 and 17.4). The nerve bundles that enter the tooth pulp consist of sensory afferent nerves of the trigeminal nerve and sympathetic branches from the superior cervical ganglion. Each structure consists of myelinated and unmyelinated axons. Although most of the nerve bundles terminate in the plexus are free unmyelinated nerve endings a small number of axons pass between the odontoblastic cell bodies to enter

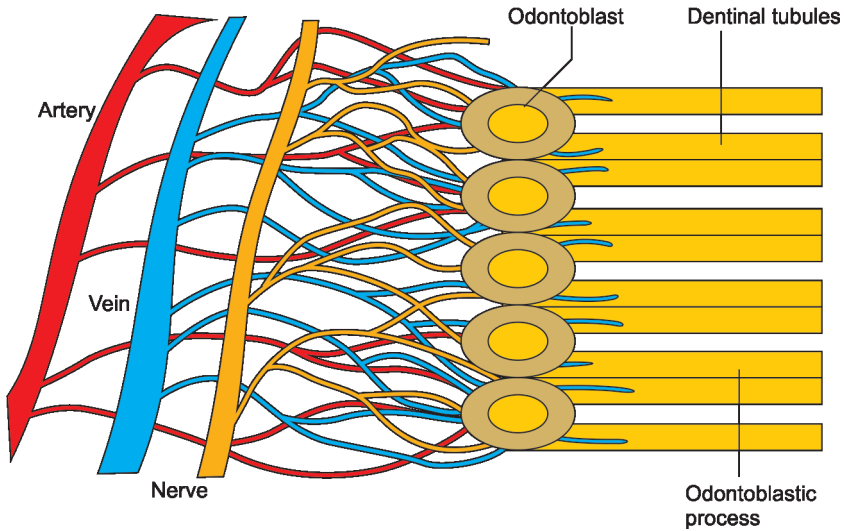


Fig. 17.3: Nerve and vascular ultrastructure of dental pulp

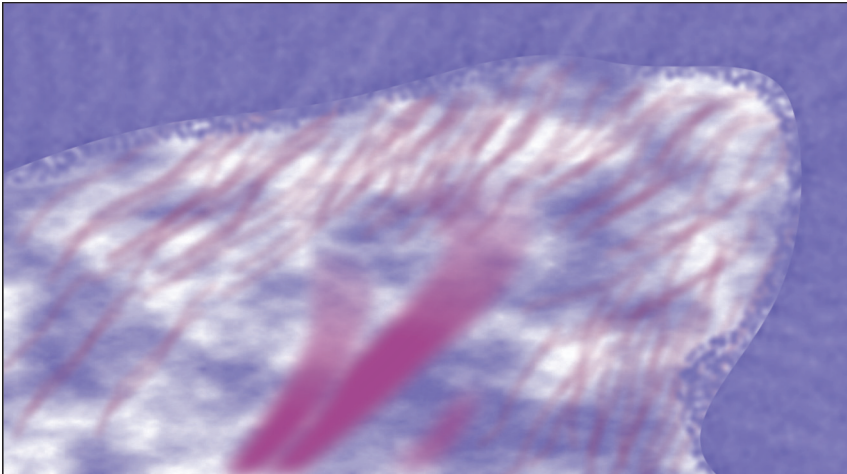
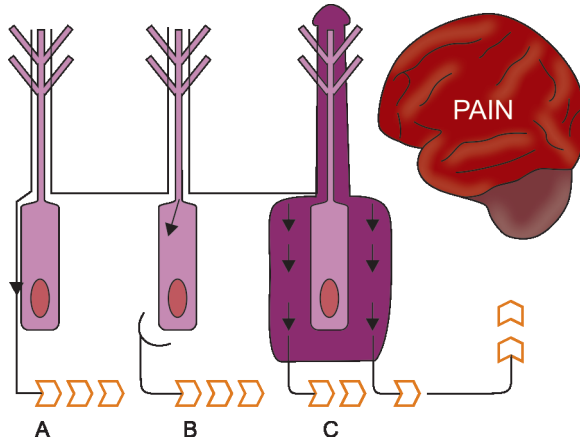


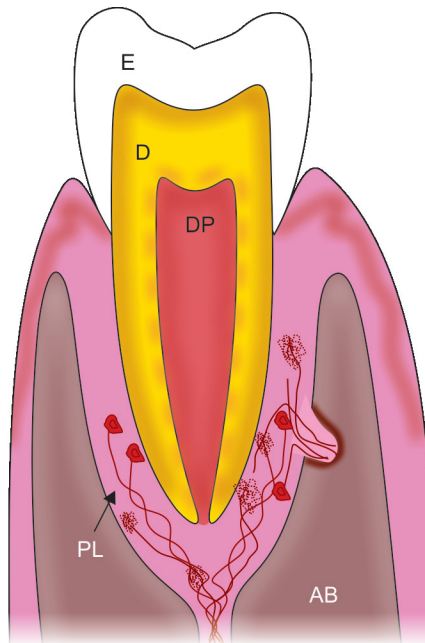
Fig. 17.4: Plexus of Rashkow in demineralized section. The ascending nerve trunks branch to form this plexus, which is situated beneath the odontoblast layer

the dentinal tubules in close proximity to the odontoblastic process at times entering the tubules upto  $\frac{1}{3}$ rd the length of the root. This close relationship between nerves and odontoblastic processes and the presence of nerve endings in dentinal tubules explains the phenomenon of dentinal sensitivity on stimulation. Pulp has no other general sensory receptors. Hence any stimulation causes pain in the dentin-pulp complex (Fig. 17.5).



**Fig. 17.5:** Three theories of dentin sensitivity. A suggests that the dentin is directly innervated. B suggests that the odontoblast acts as a receptor. C suggests that the receptors are in the pulp and are stimulated by fluid movement through the tubules

- **Periodontal ligament pain:** In the periodontal ligament pain receptors are present along with the mechanoreceptors. The receptors are more abundant at apical regions. They are also present at regular intervals along the length of root. The origin of these receptors is from unmyelinated fibers (Fig. 17.6).



**Fig. 17.6:** Nerve terminals in a human PDL

- **Denture pain:** Denture soreness, like all pain, is a complex experience, in which a multitude of factors interact. Pressure is probably the initial cause of irritation to denture bearing tissue. Once the tissue is damaged, substances released by the damaged tissue (histamine and prostaglandins), and substances released by the nerve endings themselves (substance P), contribute to causing swelling and increased sensitivity.
  - *Uneven distribution of force:* This includes sharp underlying bone, poorly fitting denture base, excessive vertical height, uneven occlusion
  - *Abnormal force:* This includes chewing hard foods, clenching, and in single denture cases
  - *Poor resistance:* This includes systemic factors and ageing
- **Temperomandibular joint pain:** Pain receptors are abundantly present except for in the central portion of the disk. Pain here mainly has a protective role.

### CONTROL OF PAIN

- Removing the cause
- Blocking the pathway of painful impulses
- Raising the pain threshold—NSAIDs, opioids
- Preventing pain reaction by cortical depression—GA
- Using psychosomatic methods—information, assurance

### FURTHER READING

1. Bennett CR, Monheim's local anesthesia and pain control in dental practice. 7th ed. CV Mosby Co, St. Louis, 1984.
2. Cormack DH. Ham's Histology. 9th ed, J. B. Lippincott, Philadelphia, 1987.
3. Graaff VD, Kent M, Fox SI, Karen M. Concepts of Human Anatomy and Physiology, 4th ed, McGraw-Hill Publishers, London, 1995.
4. Guyton AC, Hall JE. Text book of medical physiology. 10th Ed. W.B. Saunders Company, Singapore, 2000.
5. Levelle CL. Applied oral physiology. 2nd Sub ed, John Wright, 1998.
6. Ten Cate AR. Oral histology; development, structure and function. 5th ed. St. Louis, CV Mosby, 1998.



# CHAPTER 18

## Saliva

Manjunatha BS

*Saliva is not one of the popular bodily fluids. It lacks the drama of blood, the sincerity of sweat and the emotional appeal of tears.*

—Irwin D Mandel

### INTRODUCTION

Saliva, as most people think it as a convenience, handy for licking stamps and sealing envelopes. Neglected by dentist and ignored by physicians, saliva is least known and appreciated of all body fluids. Saliva is most valuable oral fluid that is often taken for granted. But saliva is much more than water. It is ‘the aqua-vita’ of the oral cavity.

Saliva is largely an unheralded, unsung and ignored secretion. There is an old proverb which states “you never miss the water till the well runs dry”. How true this is, especially for saliva. The fact, is a world without saliva is a world without pleasure....like living with a drought.....

Consequently, it is necessary for clinicians to have a good knowledge base concerning the norm of salivary flow and function.

Saliva is a clear, dilute, aqueous, hypotonic solution and mucoserous exocrine secretion. It is a complex mixture of fluids, with contributions from major salivary glands, the minor or accessory glands and the gingival crevicular fluid. Additionally, it contains a high population of bacteria normally resident in the mouth, desquamated epithelial cells and transient residues of food or drink following their ingestion.

### COMPOSITION OF SALIVA

Saliva is a very dilute fluid constituted by water 98% to 99% and remaining 2% or less is organic and inorganic components and others such as electrolytes (Na, K, Ca, Mg, hydrogen carbonates, and phosphates), mucus, antimicrobial substances (hydrogen peroxide, IgA) and various enzymes ( $\alpha$ -amylase, lysozymes, lingual lipase). Gases are also found in saliva. All these components have biological functions essential for homeostasis of the oral cavity. The mucus is made up of mainly mucopolysaccharides and glycoproteins.

**SALIVA COMPONENTS (FIG. 18.1)**

- Water
- Inorganic
  - Calcium
  - Phosphates
  - Ammonia
  - Magnesium
  - Bicarbonate
  - Potassium
  - Others like fluoride, sodium, iodide, chloride, sulphates, thiocyanate
- Organic
  - *Mucus*: Mainly consists of mucopolysaccharides and glycoproteins
  - *Antibacterial compounds*: Thiocyanate, hydrogen peroxide and secretory Ig A
  - *Growth factors*: Epidermal growth factor (EGF), Nerve growth factor
  - *Salivary proteins*: Mainly Sialin and albumin comprise approximately 200 mg/100 ml
  - *Various enzymes*: There are three major enzymes found in saliva
    - Digestive enzymes
      - $\alpha$ -amylase—starts the digestion of starch
      - Lingual lipase—not activated until entering the acidic environment of stomach
    - Antimicrobial enzymes—that kill bacteria
      - Lysozyme
      - Salivary lactoperoxidase
      - Lactoferrin
      - Immunoglobulin A
    - Minor enzymes include salivary acid phosphatases, dehydrogenase, glucose-6-phosphate isomerase and kallikrein
    - Others
      - Esterase
      - Lactic dehydrogenase
      - Peptidase
      - Phosphatase
      - Carbonic anhydrase
  - *Cells*: Many human and bacterial cells are seen.
  - *Proline-rich proteins*: Function in enamel formation,  $\text{Ca}^{2+}$ -binding
  - *Blood group components*: Factor VII, VIII, IX, platelet factor
  - Lactoferrin, cystatin
  - Fibronectin
  - Gustin
  - Histatin, statherin
  - IgA, IgG, IgM and secretory IgA
  - Steroid hormones
  - Amino acids
  - Ammonia
  - Urea

- Gases
  - Oxygen
  - Nitrogen
  - Carbondioxide.

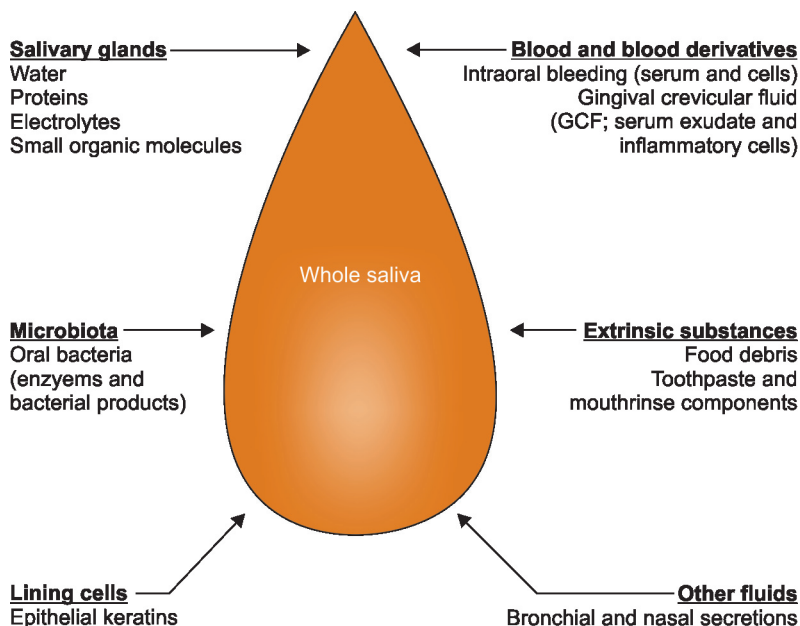


Fig. 18.1: Composition of saliva

## PROPERTIES OF SALIVA

- **Volume:** A considerable volume of saliva is secreted in a day which ranges from 0.7 to 1.5 liters (approx about 1 ml/min). This represents about 1/5 of the total plasma volume in the body and is not lost as most of it is swallowed and reabsorbed by the gut. There is much debate about the amount of saliva that is produced in a healthy person per day. It is generally accepted that during sleep the amount of saliva secretion is almost zero. The greatest volume of saliva is produced before, during and after meals, reaching its maximum peak at around noon, and falls considerably at night, while sleeping. Diminished salivary output can have deleterious effects on oral and systemic health. A wide variation among individuals has been found. Men have higher flow rates than women. The factors affecting the flow of saliva are nature of stimulus, vomiting, smoking, gland size, gag reflex, olfaction, unilateral stimulation and food intake. Reduced salivary flow may cause a variety of mostly unspecific symptoms to the patient. There are multiple causes of salivary hypofunction including oral disorders, systemic diseases, prescription and non-prescription medications, chemotherapy, head and neck radiotherapy, psychogenic factors and decreased mastication

- **pH:** 6.85–7.2 and can reach 8 during active secretion. Salivary buffering capacity is important in maintaining a pH level in saliva
- **Specific gravity:** 1.002–1.012
- **Tonicity:** Hypotonic to plasma. Initially, saliva is isotonic when it is formed in the acini. However, it becomes hypotonic as it travels through the duct network. This allows the taste buds to perceive different tastes and hydration of glycoproteins, which protect the tissues of the mouth
- **Appearance:** Turbid
- **Flow rate:**
  - Normal range of unstimulated salivary flow is 0.1 ml/min
  - Stimulated salivary flow is 0.2 ml/min and contributes 80–90% of average daily salivary production
  - Flow rate less than 0.12–0.16 ml/min is hypofunction
  - Flow rate is increased when the amount of proteins, sodium chloride and bicarbonate are more and is decreased in the presence of phosphates and magnesium
- **Viscosity:**
  - Large amount of water is attached to the glycoproteins and this contributes to the viscosity of saliva. The viscosity varies a lot and depends on nature of secretion from various glands. The viscosity is directly proportional to mucous content of the saliva.
    - Parotid—1.5 centipoise (due to watery secretion)
    - Submandibular—3.4 centipoise (due to mixed secretion)
    - Sublingual—13.4 centipoise (due to mucous secretion)
  - *Spinnbarkeit:* It is the ability or property of saliva to be drawn out into long elastic threads. This is mainly due to the viscous nature and mainly contributed by sublingual glands.

## FACTORS INFLUENCING SALIVARY FLOW AND COMPOSITION

Several factors may influence salivary flow and its composition. As a result, these vary greatly among individuals and in the same individual under different circumstances.

- **Age:** Despite numerous studies on salivary secretion the effect of aging on salivary flow remains unclear due to conflicting observations in the literature leaving little information available regarding salivary flow in healthy elderly persons. Histologically, salivary glands showed slight atrophy as well as fatty replacement in older individuals in comparison with younger, which may contribute to reduced salivary secretion in older individuals
- **Gender:** The differences in salivary secretion between men and women have been attributed to two theories: women present smaller salivary glands in comparison with men and the female hormonal pattern may contribute to diminished salivary secretion
- **Medications:** Many groups of drugs, particularly antidepressants, anti-anxiety, antipsychotics, antihistaminics, and antihypertensives, may cause reduction in salivary flow and alter its composition.
- **Physical exercise:** Physical exercise can alter secretion and induces changes in various salivary components, such as: immunoglobulins, hormones, lactate,

proteins, and electrolytes. In addition to the intensity of the exercise, a clear rise in levels of  $\alpha$ -amylase and electrolytes (especially,  $\text{Na}^+$ ) are seen

- **Individual hydration:** The hydration of person is the most important factor that interferes in salivary secretion. When the body water content is reduced by 8%, salivary flow is almost zero, whereas hyperhydration causes an increase in salivary flow. During dehydration, the salivary glands cease secretion to conserve water
- **Fasting and nausea:** Although short-term fasting reduces salivary flow it does not lead to hyposalivation and the flow is restored to normal values immediately after the fasting period ends
- **Stress:** Alterations in the psycho-emotional state may alter the biochemical composition of saliva. Depression is accompanied by diminished salivary proteins
- **Alcohol:** The intake of alcohol causes a significant reduction of stimulated salivary flow
- **Systemic diseases and nutrition:** In some chronic diseases such as diabetes mellitus, renal failure, anorexia, and others, the amylase level is high. Nutritional deficiencies may also influence salivary function and composition.

## FUNCTIONS OF SALIVA

*“The health of salmon - a long life, a full heart and a wet mouth”*

—Irish proverb

The properties and functions of saliva have been studied extensively for more than sixty years. This complex biofluid plays an essential role in the maintenance of oral health. Saliva has multiple functions, which are related both to its fluid characteristics and specific components. Many components of saliva have overlapping, multifunctioning roles and work concurrently, which are beneficial. For ease of understanding, salivary functions can be organized into 7 major categories that serve to maintain the oral health and create an appropriate ecologic balance. These important functions are as follows:

- Lubrication and protection
- Buffering action
- Antimicrobial activity
- Mechanical cleansing of food and bacteria
- Taste and digestion
- Bolus formation for swallowing
- Maintenance of tooth integrity.

## LUBRICATION AND PROTECTION

- Saliva acts as a lubricant and always keeps the mucosa hydrated (moist) and protects oral tissues, acting as a barrier against irritants, it also prevents cracking. The mucins are best lubricating components of saliva, which have the properties of low solubility, high viscosity, high elasticity and adhesiveness
- Protects the lining mucosa by forming a thin mechanical barrier against the microbial toxins and other minor trauma. The most common irritants are

proteolytic and hydrolytic enzymes produced in plaque, potential carcinogens from smoking and exogenous chemicals and desiccation from mouth breathing

- Aids in normal process of mastication, speech and swallowing mainly by the lubricating effects of mucins
- The water content or fluid nature provides a mechanical washing action and flushes away nonadherent bacteria and acellular debris
- Mucins also perform an antibacterial function by the adhesion of microorganisms to oral tissue surfaces, which prevents bacterial and fungal colonization
- Mucins help in formation of enamel pellicle from normal oral flora, forming a protective barrier against acid penetration and limiting mineral going out from the tooth surface.

### BUFFERING ACTION

- Many bacteria require a specific pH or an acidic environment for maximal growth, the buffering action prevents this. A controlled pH range of 6.8–7.0 (almost neutral) of saliva denies this action of pathogens and also prevents their colonization
- Saliva has three major buffers such as bicarbonate ( $\text{HCO}_3^-$ ), phosphates ( $\text{PO}_4^+$ ), and proteins. These buffers have a pH range of maximal buffer capacity having a pH value range of 6.3–7.0. As a result, the saliva maintains the steady pH for maximum antimicrobial effects. Bicarbonate is the principle buffer of saliva
- Saliva neutralizes the acids produced by microbes and bicarbonate  $\text{HCO}_3^-$  plays a key role in this function
- Sialin, a salivary peptide plays a main role in raising the pH when the salivary pH is decreased after the exposure to carbohydrates or sugars.

### ANTIMICROBIAL ACTIVITY

- Another important function of saliva is its antibacterial activity. Salivary glands are exocrine glands and contain immunologic and nonimmunologic agents for the protection of teeth and mucosal surfaces. Salivary immunoglobulins such as IgA, IgG and IgM come from plasma and nonimmunologic contents from ductal cells
- Saliva contains few antimicrobial agents such as peroxidase, lysozyme, secretory IgA and thus can act on the pathogenic organisms. Lysozyme, an enzyme that cleaves the linkage between N-acetyl muramic acid and N-acetyl glucosamine component of the bacterial cell wall
- Secretory IgA, a predominant immunoglobulin helps in aggregation of oral bacteria and makes them difficult to bind to oral epithelial cells/hard tissue surfaces. Secretory IgA coats the bacteria and these are easily phagocytosed and destroyed by leukocytes (Helps in opsonization)
- Histatins help in aggregation of bacteria and their clearing from the oral cavity
- Cystatins reduce the activity of bacterial proteases which are seen in the gingival crevice
- Salivary lactoperoxidase inhibits the growth as well as production of acids by microorganisms

- Lactoferrin, an iron binding protein binds to free iron and prevents the supply of nutrients essential for their growth and metabolism. Lactoferrin also binds to target sites on a number of bacterial species such as staphylococci, streptococcus mutans
- Mucins in the saliva trap and limit the actions as well as prevent the colonization of bacteria
- Other antibacterial components like thiocyanate and hydrogen peroxide in saliva combine to form potent antibacterial agents when certain enzymes are secreted
- Lactoferrin also functions with lysozyme and lactoperoxidases synergistically.

### MECHANICAL CLEANSING ACTION

- Saliva is watery in nature; this dilutes and removes substances such as food debris, noxious agents from the oral cavity. Consequently, a high salivary flow rate results in a high clearance and vice versa
- Apart from food debris, saliva also clears dietary acids, and thereby protects the teeth against erosion. In general, the higher the flow rate, the faster the clearance and the higher the buffer capacity.

### TASTE

- A vital function of saliva is to enhance taste and begin the digestive process. Taste is a main stimulant for formation of saliva. The sense of taste is activated during the initial stage of ingestion of food particles allowing for identification of essential nutrients and harmful, potentially toxic compounds
- The presence of saliva in the oral cavity is also essential for taste perception. Food particles require a solvent in order to stimulate taste receptor cells in the taste buds within the lingual papillae (fungiform, foliate, and circumvallate papillae). This makes the eating more enjoyable
- The hypotonicity of saliva improves the tasting capacity of salty foods and nutrient sources. This enhanced tasting capability is due to 'gustin', which binds zinc. Gustin is a protein found to be necessary for the growth and maturation of various taste buds.

### DIGESTION

Saliva has a very limited role in total digestion and the enzymatic digestion of the food particles starts from the oral cavity itself. This is possible due to the presence of enzyme amylase and salivary lipase. Both these enzymes will act on the moist and mechanically broken down cooked food particles namely starch and fats respectively.

- The breakdown of starch begins with amylase, a major digestive enzyme of saliva and an important secretory component of parotid saliva that initially dissolves sugar. The digestion of starch is inadequate because most of breakdown of starch results from pancreatic amylase, not by the salivary amylase

- Salivary enzymes also initiate fat digestion with the help of lipase, secreted by the lingual salivary glands. Lipase in saliva is responsible for the first step in fat digestion and particularly important when pancreatic levels of lipase are low as in case of new born and diseases like cystic fibrosis.

### **BOLUS FORMATION FOR SWALLOWING**

- The moistening nature of the saliva helps to make the food into a bolus and thus lubricates the oral cavity and pharynx in easy swallowing. When a person secretes less amount of saliva, additional water may be needed to push the food into the stomach
- Adequate amounts of saliva in the oral cavity is also needed to initiate the digestive process. Saliva helps in chewing as well as mixing of food within the mouth and will assists in swallowing the food.

### **MAINTENANCE OF TOOTH INTEGRITY**

Maintaining tooth integrity is one of many important functions of saliva. Maintenance of tooth integrity is the one that facilitates the demineralization as well as remineralization process. Demineralization occurs when acids diffuse through plaque and the pellicle into the enamel mainly between enamel crystals, resulting crystalline dissolution occurs at a pH of 5 to 5.5. This pH is the critical pH range for the development of caries. Dissolved minerals subsequently diffuse out of the tooth structure and into the saliva surrounding the tooth.

- The buffering capacity of saliva greatly influences the pH of plaque surrounding the enamel, thereby inhibiting caries progression
- Calcium and phosphate ions in saliva makes it supersaturated to hydroxyapatite crystals of teeth at normal intraoral pH and thus help in remineralization from the surface
- Statherin (Greek term 'statheropio' meaning 'to stabilize'), an important component of saliva inhibits hydroxyapatite crystal growth and prevents the precipitation of calcium phosphates from supersaturated saliva and hence inhibitor of calculus formation as well
- Green's factor a globulin attaches to lactobacilli and inhibits the growth and lyses them. Lactobacilli one group of microbes, responsible for dental caries
- Ions like calcium, phosphorus, magnesium and chloride help in maturation and increase the hardness, decrease the permeability of tooth and increase the resistance to dental caries
- Trace elements like fluoride have anticaries action by increasing the resistance of enamel to dental caries by forming fluorapatite crystals
- Presence of clotting factors like factor VII, VIII, IX and calcium speed up clotting
- Growth factors such as epidermal growth factor (EGF), transforming growth factors, fibroblast growth factor (FGF), insulin-like growth factors (IGF's) and nerve growth factor fasten the wound healing.



### MISCELLANEOUS FUNCTIONS

- Further saliva regulates temperature by evaporative cooling
- Some drugs are dissolved in saliva when they are used as sublingual administration. During this, saliva acts as vehicle for drug administration and beginning of action of the drug is also faster than any other route
- Saliva is one of the excretory route for several blood components, viruses/viral particles (in mumps, poliomyelitis) and heavy metals (lead, mercury, bismuth).

All these are some of the most common as well as the most important functions performed by saliva and its physiological value is still under investigations. In future, we might identify many more functions which are provided by the saliva. In recent years, in addition to the studies referring to the role of saliva in health and disease, major efforts have been made to better understand the composition of whole human saliva and its individual variations.

### THE DIAGNOSTIC APPLICATIONS OF SALIVA

Salivary diagnosis has now become an increasingly important field not only in dentistry, and also in physiology, internal medicine, endocrinology, pediatrics, immunology, clinical pathology, forensic medicine, psychology and sports medicine (Mandel, 1993). The idea of using saliva in diagnostics started in the latter half of the 20th century. Due to many potential advantages, salivary diagnosis provides an attractive alternative to more invasive, time-consuming, complicated and expensive diagnostic approaches.

**History:** Saliva was first recognized by the ancient judicial community who employed the absence of salivary flow as the basis of a lie detector test. The first documented use of saliva was in 1912 when a horse called **Bourbon Rose** won the Gold Cup at Maison Lafitte in France but was disqualified because it yielded the first 'positive' drug test. **Percy R Howe**, a Boston dentist was the first to demonstrate an actual excretion of medicaments into saliva. Main medicaments which showed traces in saliva are capsules of iron, iodine, antiseptics, salicylates, benzoates and menthol. The analysis of saliva, like blood has two purposes: the first, to identify individuals with disease and second, to follow the progress of the affected individual under treatment.

The most commonly used laboratory diagnostic procedures involve the analyses of the cellular and chemical constituents of blood. Other biologic fluids are utilized for the diagnosis of disease, and saliva offers some distinctive advantages.

Advantages of saliva are as follows:-

- Easy and noninvasive sample taking compared to peripheral blood. Whole saliva can be collected noninvasively
- No special equipment is needed for collection of the fluid
- Collection of saliva is associated with fewer problems as compared with the collection of blood. Hence, the diagnosis of disease using of saliva is potentially valuable for children and older adults

- Analysis of saliva is cost-effective approach for the screening of large populations
- A number of drugs, hormones and antibodies can be reliably monitored in saliva, which is an easily obtainable, noninvasive
- Salivary diagnosis is useful in cases where repeated samples of body fluid are needed but where drawing blood is impractical
- Samples can be taken by individuals with limited training.

Saliva offers an alternative to serum as a biologic fluid that can be analyzed for diagnostic purposes. Despite many limitations, the use of saliva for diagnostic purposes is increasing in popularity. Several diagnostic tests are commercially available and are currently used by patients, researchers, and clinicians. Saliva is particularly useful for qualitative (detection of the presence or absence of a marker) rather than quantitative diagnosis. In the following section, some important uses concerning the saliva in diagnostics will be discussed.

### Oral Lesions

- For decades, dental health professionals have used saliva to help assess the risk of caries by measuring its buffering capacity and bacterial content
- The use of saliva in diagnosing caries risk is well-known, owing to the possibility of detecting the presence of *Streptococcus mutans* and Lactobacillus, as well as lactic acid, which causes the demineralization and the onset of the caries lesion
- The presence of periodontal pathogenic bacteria can also be diagnosed using saliva. There is a proven inverse relation between activity of salivary alpha-amylase and number of dental cavities, periodontal disease and level of bacteria in the saliva
- Other infectious diseases of the oral cavity can be diagnosed in this way, such as candidiasis through the presence of Candida in the saliva.

### Systemic Diseases

- Detection of the human immunodeficiency virus (HIV) is a very good example of using saliva to diagnose infectious disease. Direct detection and identification of the presence of the virus in saliva using the PCR method is gradually becoming the standard method. HIV antibody detection is as precise in saliva as in serum and is applicable in both clinical and epidemiological studies. The presence of HIV virus antibodies and viral components in the saliva can assist in the diagnosis of acute infection, congenital infection and reactivations of the infection
- Certain viral diseases, detection of hepatitis A antigen and hepatitis B antigen in the saliva has been used in epidemiological studies, as has that of IgM and IgG type antibodies to both types of hepatitis. There are commercial kits for determining antibodies to hepatitis B and C viruses that are 100% sensitive and specific using saliva
- Saliva has also been used to detect antibodies to the rubella, parotitis and rubeola viruses. In neonates, the presence of IgA is an excellent marker of rotavirus infection

- Some studies have suggested that reactivation of herpes virus type 1 infections is related to the pathogenesis of Bell's palsy and detection of the virus in the saliva using PCR would be a suitable method for early detection
- The introduction of polymerase chain reaction methods has led to the use of oral fluids as a source of microbial DNA for detecting herpes viruses, Kaposi's sarcoma and bacteria such *Helicobacter pylori*, which is associated with gastritis, peptic ulcers and possibly stomach cancer. *Helicobacter pylori* are difficult to culture and takes longer time to detect
- Saliva aids in the diagnosis of sarcoidosis, tuberculosis, lymphoma
- For diagnosing celiac disease, IgA and antigliadin antibody detection in saliva shows high specificity and low sensitivity
- The presence of antibodies to other infectious organisms such as *Borrelia burgdorferi*, *Shigella* or *Tenia solium* can also be detected through the saliva.

### Autoimmune Disorders

Now, saliva is increasingly being used as an investigational aid in the diagnosis of autoimmune and systemic diseases that affect the function of the salivary glands and the composition of the saliva, such as Sjögren's syndrome, cystic fibrosis, sarcoidosis, diabetes mellitus and diseases of the adrenal cortex.

- Attempts have been made to use saliva for the diagnosis of Sjogren's syndrome. In Sjögren's syndrome, minor salivary gland biopsy is an accepted diagnostic procedure. IgA, IgG and IgM autoantibodies can also be detected in the saliva.

### Neoplasms

Oral fluid is also used in diagnosing other malignancies:

- In some malignant diseases, markers in the saliva, such as p53 antibodies in patients with oral squamous cell carcinoma, or high levels of defensin-1 positively correlated with the serum levels
- The presence of the c-erbB-2 tumor marker in the saliva and blood serum of breast cancer patients and its absence in healthy women is a promising tool for the early detection of this disease
- In ovarian cancer too, the CA 125 marker can be detected in the saliva with greater specificity and less sensitivity than in serum.

### Cardiovascular Diseases

- Markers in saliva may be useful in postoperative follow-up among patients undergoing cardiovascular surgery. Studies have confirmed increase in salivary amylase enzyme in the presence of cardiovascular disease
- The latest studies also report raised activity of salivary alpha-amylase connected to stress in adolescents who had levels measured at 145% higher than the average

### Drug Monitoring

- Saliva can also be useful in the monitoring of therapeutic drug levels and the detection of illicit drug use

- Saliva has been used to monitor the levels of lithium, carbamazepine, barbiturates, benzodiazepines, phenytoin, theophylline and cyclosporine
- The presence of thiocyanate in the saliva is an excellent indicator of active or passive smoking
- Other drugs such as cocaine or opiates can also be detected in saliva.

### Endocrine Disorders

- Further, analysis of saliva may provide valuable information regarding certain endocrine disorders.

### Monitoring of Hormones

- Saliva is also useful for the monitoring of hormone levels, especially steroids, and facilitates repeated sampling in short time intervals, which may be particularly important for hormone monitoring
- Detection in the saliva of certain hormones such as cortisol, aldosterone, testosterone, estradiol or insulin is highly correlated with concentrations in serum.

### Saliva in Forensic Sciences

Saliva is a simple, painless and non-radical way of obtaining DNA.

- For the DNA to be extracted from the saliva, the area where saliva is present has to be outlined. This is called as '**saliva stain mapping**'. Forensic scientists can retrieve enough saliva even from a postage stamp to identify the person who licked the stamp and is possible to extract about 1–50 ng of DNA per stamp.

### DISADVANTAGES/LIMITATIONS OF SALIVA

Normal salivary gland function is usually required for the detection of salivary molecules with diagnostic value. Salivary composition can be influenced by the method of collection and the degree of stimulation of salivary flow. Changes in salivary flow rate may affect the concentration of salivary markers and also their availability due to changes in salivary pH. Variability in salivary flow rate is expected between individuals and in the same individual under various conditions. Furthermore, different substances reach saliva by different mechanisms. In addition, many serum markers can reach whole saliva in an unpredictable way through GCF and oral wounds. These parameters will affect the diagnostic usefulness of many salivary constituents. Certain systemic disorders, numerous medications, and radiation may affect salivary gland function and consequently the quantity and composition of saliva. Whole saliva also contains proteolytic enzymes derived from the host and from oral microorganisms. These enzymes can affect the stability of certain diagnostic markers. Some molecules are also degraded during intracellular diffusion into saliva. Any condition or medication that affects the availability or concentration of a diagnostic marker in saliva may adversely affect the diagnostic usefulness of that marker. For accurate diagnosis, a defined relationship is required between the concentration of the biomarker in serum and the concentration in saliva.

## CONCLUSIONS

With advances in microbiology, immunology and biochemistry, salivary testing in clinical and research settings is rapidly proving to be a practical and reliable means of recognizing oral signs of systemic illness and exposure to risk factors. The components of saliva act as a 'mirror of the body's health,' and the widespread use and growing acceptability of saliva as a diagnostic tool is helping individuals, researchers, health care professionals and community health programs to better detect and monitor disease and to improve the general health of the public.

## FUTHER READING

1. De Almeida P del V, Gaeqio AM, Machado MA, et al. Saliva composition and functions: a comprehensive review. *J Contemp Dent Pract*, 2008;9:72-80.
2. Dodds MW, Johnson DA, Yen CK. Health benefits of saliva: a review. *J Dent* 2005;33(3):223-33.
3. Edgar NW. Saliva: Its secretion, composition and functions. *Br Dent J*, 1992;172:305-12.
4. Farnand SJ, Kostic O, Getting SJ, et al. Saliva: physiology and diagnostic potential in health and disease. *Scientific World Journal*, 2010;10:434-56.
5. Greabn M, Battino M, Mohora M et al. Saliva—a diagnostic window to the body, both in health and in disease. *J Med Life*, 2009;2:124-32.
6. Kanfman E, launster IB. The diagnostic application of saliva—a review. *Crit Rev Oral Bio Med*, 2002;13:197-212.
7. Mandel ID. The diagnostic uses of saliva. *J Oral Pathol Med* 1990;19:119-25.
8. Miles TS, Nanntofte B, Svensson P(Ed). *Clinical oral physiology*. Quintessence Publishing, 1st ed. 2004.
9. Newbrun E(Ed). *Cariology*. 3rd ed, Quintessence Publishing Company, 1989.
10. Schenkefs LC, Veerman EC, Amerongen AV. Biochemical composition of human saliva in relation to other mucosal fluid. *Crit Rev Oral Biol Med*, 1995;114:681-90.
11. Streckfus CF, Bigler LR. Saliva as a diagnostic fluid. *Oral Dise*, 2002;8:69-76.

# Index

Page numbers followed by *f* refer to figure and *t* refer to table

## A

- Absence of rotation 157*f*
- Accessional teeth 38
- Acute and chronic pain 219*t*
- Advanced chronic liver disease 213
- Alkalosis 213
- Alveolus 6
- Anatomical
  - crown 6
  - root 6
- Anterior
  - arch length 35, 36*f*
  - component of force 47
  - deep bite 37
    - in deciduous dentition 37*f*
  - teeth 20
- Anterosuperior alveolar nerve 164, 165
- Apex 7
- Apical foramina 7
- Arch
  - circumference 48
  - dimensions 34
  - length 38
    - and circumference 35
    - and width 158
  - trait 20
  - width 38, 48
- Arterial supply and venous triangle of maxilla and mandible 162
- Articulatory system 146
- Atomic absorption spectrometry 205
- Autoimmune disorders 236

## B

- Baby teeth 128
- Balanced occlusion 159
- Bennett movement 150, 151*f*

- Bifurcation of roots 80*f*
- Bilateral Talon's cusp 61*f*
- Blood group components 227
- Bonwill's triangle 149, 151*f*, 152
- Borrelia burgdorferi 236
- Broadbent phenomena 45
- Buccal
  - cingulum 132
  - developmental groove 106
  - groove 111, 122
  - ridge 11
  - surface 8
- Buccolingual dimension 168
- Buffering action 231

## C

- Calcitonin 208, 210
- Calcium 205
  - absorption 206
  - and phosphorus metabolism 204
  - balance 207
  - carbonate 213
  - homeostasis 207, 211*f*
  - metabolism 212
  - phosphate interactions 214
  - rich dietary sources 205*f*
- Canine 173
  - eminences 70
  - fossa 83
- Carabelli's
  - cuspid 178
  - trait 169, 170*f*
- Carbonic anhydrase 227
- Cardiovascular diseases 236
- Carve
  - cingulum 185
  - lingual fossa 185

- Carving of  
 basic model 182, 182*f*  
 central incisor 182  
 crown from markings 183*f*  
 cylinder from wax block 181, 181*f*  
 labial ridge and cusp slopes 188*f*  
 mesial and palatal aspects 193*f*  
 molars 192  
 occlusal surface 191*f*  
 premolar 189  
 rectangle from wax block 181  
 root 185*f*
- Carving steps in canine 186
- Cementum 7
- Central  
 fossa 14, 110, 121  
 in posterior tooth 14*f*  
 groove 111, 122  
 incisor 173  
 pain 219  
 pit 112
- Centric occlusion 147
- Cervical  
 line 6  
 and root markings 196*f*  
 ridge 13, 132
- Christensen's phenomenon 150
- Chronic renal failure 213
- Chronology of  
 mandibular  
 first premolar 92  
 second premolar 97  
 permanent mandibular  
 canine 78  
 first molar 116  
 second molar 124  
 permanent maxillary  
 canine 73  
 first molar 106  
 first premolar 83  
 second molar 113  
 second premolar 87
- Cingulum 13  
 from proximal and lingual surfaces 13*f*
- Class traits of  
 canines 71  
 incisors 50  
 molars 104  
 premolars 81
- Compensating occlusal curvature 152
- Compensatory curves 150
- Components of  
 masticatory system 147*f*  
 occlusal surface 109  
 pain 218
- Composition of saliva 226, 228*f*
- Condylar guidance 154
- Congenital  
 absence of  
 lateral incisors 44  
 premolars 41  
 missing mandibular second premolar 102*f*
- Congenitally missing incisors 141*f*
- Contact  
 area 18, 82  
 point 18
- Control of pain 225
- Cope-Osborn hypothesis 110
- Cornerstones of dental arches 105
- Correction of permanent first molar relation 47*f*
- Counteraction for anterior component of force 47*f*
- Crest of curvature 18
- Cross-section of tooth 16*f*
- Crown 6  
 angulation 155  
 in maxillary arch 156*f*  
 inclination 156  
 in buccolingual direction 156*f*
- Curve of  
 Monson 152, 153*f*  
 Spee 150, 151*f*, 152, 152*f*, 157, 157, 157  
 Wilson 153, 153*f*
- Cusp 10, 109, 120, 134, 140, 172  
 of Carabelli' 105  
 tips of molars and premolars in interarch relations 155*f*
- Cuspid 44
- D**
- Daily phosphorus requirement 214
- Deciduous  
 and permanent dentition 142, 142*t*  
 dentition 33, 128  
 period 30

- Deep
    - bite 148
    - lingual groove 61*f*
  - Definition of
    - metric dental traits 167
    - non-metric dental traits 168
  - Dental arch 5
  - Dentin 7
  - Dentinal sensitivity and pulpal pain 222
  - Denture pain 225
  - Descending palatine artery 161
  - Development of occlusion 30
  - Developmental
    - depression 15
    - disturbances 41
    - groove 15, 15*f*
  - Deviated path of eruption 44
  - Diagnostic applications of saliva 234
  - Diastema 18
  - Digestion 232
  - Distal
    - aspect 115, 120, 126, 130, 134, 136
    - bend of root 61
    - caries of deciduous second molar 41
    - fossa 111
    - pit 112
    - step in deciduous molars 40
    - triangular fossa 111, 121
  - Distolingual groove 111
  - Distribution
    - in body 205
    - of pain receptors 222
    - of total body phosphate 214
  - Drug monitoring 236
  - Dual curve of Spee 150
  - Dynamic occlusion 146, 154
- E**
- Edentulous jaws 30
  - Edge to edge bite 34
  - Embrassure 18
  - Emergence of first permanent molars 39
  - Enamel 7
  - Endocrine disorders 237
  - Enlarged portion of crown mesial 189*f*
  - Eruption of
    - first bicuspid 44
    - permanent second molar and premolar in upper and lower arches 45*f*
    - premolar and eruption sequence 44*f*
    - second bicuspid 44
    - teeth 158
  - Estrogens 212
  - Exchange of deciduous incisors with permanent incisors 42
- F**
- Facial embrassure 19
  - FDI system 27, 52, 57, 66, 73, 78, 83, 88, 92, 97, 106, 113, 117, 124
    - of tooth numbering 28*f*
  - Fifth cusp groove 111
  - Finishing polishing 185
  - First
    - bicuspid 44
    - molar 173
    - permanent molar eruptive direction and first transitional occlusion 39*f*
    - premolar 173
    - transitional period 39
  - Fissure 16
  - Flat occlusal plane 157
  - Flush terminal plane 36, 37
  - Fossae 13, 86, 110, 121, 134, 140
  - Four
    - cuspid lower
      - first molar 178
      - second molar 178
    - cuspid mandibular molars 171
  - Freeway space 150
  - Frequency of Shovelling and Carabelli's cusp 178*t*
  - Functions of
    - canines 70
    - incisors 49
    - molars 103
    - premolars 81
    - saliva 230
    - teeth 216
- G**
- Gate control
    - system 221*f*
    - theory 220
  - Glucocorticoids 212
  - Granulomatous disorders 213
  - Greater palatine nerve 164, 165



Grooves 86, 111, 140  
 Growth hormone 212  
 Gum-pads 30

## H

*Helicobacter pylori* 236  
 Heterotopic pain 219  
 Hexagon 86  
 Hyperphosphatemia 213  
 Hypervitaminosis 213  
 Hypoalbuminemia 213  
 Hypocalcemia 213  
 Hypoparathyroidism 213  
 Hypophosphatasia 213

## I

Iatrogenic 213  
 Incisal aspect 130, 132, 136  
 Incisive nerve 165, 166  
 Incisor 49  
 Inferior alveolar nerve 165  
 Infraorbital  
   artery 161  
   nerve 164  
 Inheritance of non-metric dental traits 176  
 Innervation of teeth 164*f*  
 Insulin 212  
 Intensity theory 221  
 Interarch relationships 155  
 Interdental  
   papilla 19  
   papilla in interproximal space 19*f*  
   spacing in deciduous dentition 43*f*  
 International notation or FDI 66  
 Intertransitional period 43  
 Intestinal malabsorption 213

## J

Juvenile teeth 128

## K

Kaposi's sarcoma 236

## L

Labial  
   part 31  
   ridge 10

    in anterior tooth 11*f*  
     surface 8  
 Lacteal teeth 128  
 Lactic dehydrogenase 227  
 Larger permanent teeth 42*f*  
 Late mesial shift 40*f*  
 Lateral  
   curves 150  
   incisor 173  
 Leeway space 41  
   of Nance 41*f*  
 Limitations of saliva 237  
 Line angle 22  
 Lingual  
   aspect 114, 118, 125, 130, 132, 133,  
     136, 139  
   developmental groove 107  
   fossa 13, 14*f*  
   nerve 165  
     block 166  
   part 31  
   ridge 11  
   surface 8  
 List of  
   line angles in  
     anterior teeth 22*t*  
     posterior teeth 22*t*  
   point angles in  
     anterior teeth 22*t*  
     posterior teeth 23*t*  
 Lobe 17  
   in anterior and posterior teeth 17*f*  
 Long buccal nerve 165  
 Lower anterior crowding 46*f*  
 Lysozyme 227

## M

Maintenance of tooth integrity 233  
 Mamelons in newly erupted teeth 18*f*  
 Mandible 36, 42, 43  
 Mandibular  
   anterior crowding 46  
   canine 137, 79*f*, 80*f*  
   central incisor 49, 62, 64*f*, 135, 136*f*  
   cuspid 77  
   first  
     molar 119*f*, 121*f*, 122*f*, 138, 139*f*  
     permanent molar 39  
     premolar 94*f*

- gum-pads 32*f*
  - incisors 62
  - lateral incisor 49, 66, 67*f*, 68*f*, 137, 137*f*
  - molar groove pattern 170
  - posterior teeth 20
  - right
    - first permanent molar 118*f*
    - second permanent molar 125*f*
  - second
    - molar 126*f*, 140, 141*f*
    - premolar 96, 99*f*, 100*f*
  - Marginal ridge 11, 110, 121
    - in posterior tooth 11*f*
  - Maternal
    - consumption of alcohol 158
    - diet 158
    - metabolism and diseases 158
  - Maxilla 42, 44
  - Maxillary
    - and mandibular casts 102*f*
    - canine 72, 75*f*, 131, 131*f*
    - central incisor 49, 50, 53*f*, 129, 129*f*
    - first
      - molar 110*f*, 112*f*, 132, 133*f*
      - permanent molar 39
      - premolar 82, 84*f*, 85*f*
    - gum-pads 31, 32*f*
    - incisors 50
    - lateral incisor 49, 57, 58*f*, 59*f*, 130, 130*f*
    - nerve 163*f*
    - posterior teeth 20
    - right first permanent molar 108*f*
    - second
      - molar 115*f*, 134, 135*f*, 171*f*
      - premolar 87, 88*f*, 89*f*, 91*f*
  - Measure mesiodistal dimension 168*f*
  - Measurements of maxillary and mandibular
    - canines 189*t*
    - incisors 186*t*
    - molars 197*t*
    - premolars 192*t*
  - Mechanical cleansing action 232
  - Mental nerve 165
    - block 166
  - Mesial
    - aspect 114, 119, 125, 130, 133, 136
    - developmental depression 83, 85
    - drift 47
    - drifting tendency 48
    - marginal groove 85
    - pit 112, 122
    - step 36
      - in deciduous molars 40
    - surface 9
    - triangular fossa 111, 121
  - Mesiodistal dimension 168
  - Mesiolingual
    - developmental groove 96
    - groove 91
  - Microscopic structure of tooth and associated parts 8*f*
  - Middle superior alveolar nerve 164, 165
  - Milk teeth 128
  - Miscellaneous functions 234
  - Mixed dentition 38
    - period 30
  - Molar relation in deciduous dentition 36*f*
  - Monitoring of hormones 237
  - Monson's spherical theory 152
  - Morphology of tooth 10
  - Muscular pressure 158
- N**
- Nasopalatine nerve 164, 165
  - Natal teeth 31
  - Natural and artificial occlusion 159*t*
  - Neonatal teeth 31, 31*f*
  - Nerve
    - and vascular ultrastructure of dental pulp 223*f*
    - supply to
      - mandible and mandibular teeth 165
      - mandibular teeth 165
      - maxilla and maxillary teeth 161
      - maxillary teeth 164
    - terminals in human PDL 224*f*
  - Non-metric dental traits in Indians 177
  - Non-spaced dentition 34
  - Normal
    - and peg shaped maxillary lateral incisor 61*f*
    - calcium homeostasis 208*f*
    - crown and root morphology 77*f*
    - lingual fossa and cingulum 56*f*
- O**
- Oblique ridge 104
    - in maxillary permanent molar 12*f*
  - Occlusal surface 9

- Oral  
 cavity 222  
 lesions 235
- Overbite 34, 48, 148  
 and overjet 158
- Overjet 34, 48, 148  
 and overbite 35, 48, 149*f*
- P**
- Pain 218
- Palatal surface 8
- Palmer's  
 notation 66  
 system 52, 57, 63, 66, 73, 78, 83, 88, 92, 97, 106, 113, 117, 124  
 of tooth numbering 25*f*
- Parathormone and calcium 209*f*
- Parathyroid hormone 207, 208  
 and bone 210  
 and intestine 210  
 and kidneys 209
- Parts of  
 cusp 10  
 tooth 6
- Pathway of pain in orofacial region 222
- Percentages dimorphism for different teeth 173*t*
- Periodontal ligament pain 224
- Permanent  
 cuspids 70  
 dentition 47  
 period 30  
 incisors 49  
 mandibular  
 central incisor 65*f*  
 first molar 116  
 first premolar 91  
 molars 116  
 premolars 91  
 second molar 124  
 maxillary  
 canine 77*f*  
 canine teeth 77*f*  
 first molar 105  
 molars 104  
 second molar 113  
 molars 103  
 second molars 45
- Phosphorus balance 214
- Physiological functions of calcium 204
- Pits 112, 140  
 and grooves 121, 134
- Planned occlusion 159
- Point angle 22
- Population differences in  
 non-metric dental traits 176  
 tooth size 175
- Posterior guidance 154
- Posterosuperior alveolar 161  
 nerve 164, 165
- Postulates of gate control theory 220
- Predentate period 30
- Primary  
 pain 219  
 teeth 128
- Primate spaces 34, 37
- Prolactin 212
- Proline-rich proteins 227
- Prominent  
 cusp of carabelli in permanent maxillary  
 first molar 105*f*  
 lingual  
 aspect 61*f*  
 fossa and cingulum 56*f*
- Properties of saliva 228
- Proximal  
 aspect 119, 132  
 surface 9
- Pseudohypoparathyroidism 213
- Pulp 7  
 canal 7  
 chamber 7  
 horn 7
- Q**
- Quadrant 5  
 in maxilla and mandible 5*f*
- R**
- Race identification from dentition 175
- Rainbow curve of Spee 150
- Referred pain 219
- Rhomboidal type 115
- Ridges 10, 86, 110, 121
- Riga-Fede disease 31
- Root 6, 132, 134, 140  
 carving 188*f*, 192*f*, 195*f*, 196*f*  
 trunk 7
- Rotations 157

**S**

- Safety valve mechanism 48
- Saliva 226
  - components 227
  - in forensic sciences 237
  - stain mapping 237
- Salivary lactoperoxidase 227
- Second
  - bicuspid 44
  - molar 173
  - premolar 173
  - transitional period 43
- Sex identification from tooth size 173
- Shigella 236
- Shovelling 169, 178
  - of maxillary central and lateral incisors 169*f*
- Six cusps pattern in mandibular first molar 123*f*
- Spaced dentition 34
- Spatial relation of gum-pads 32
- Square form 52
- Static occlusion 146, 147
- Streptococcus mutans* 235
- Structures of tooth 7
- Successional teeth 38
- Sulcus 16
  - in molars 16*f*
- Supernumerary teeth 44
  - in premolar region 102*f*
- Supplemental groove 15, 15*f*
- Surface of
  - maxillary second molar 114*f*
  - mandibular canine 79*f*
  - maxillary canine 74*f*
  - tooth 8, 9*f*
- Systemic diseases 235
  - and nutrition 230

**T**

- Talon's cusp 65*f*
- Teeth number 158
- Temporary teeth 128
- Temporomandibular joint 146, 154
  - pain 225
- Tenia solium* 236
- Testosterone 212
- Theories of pain 220
- Thiazide 213

- Thomas notches 82, 83
- Three
  - cusp upper second molar 178
  - cusped maxillary second molar 170
- Thyroid hormones 212
- Tight contacts 157, 157*f*
- TMJ and birth injuries 158
- Tongue pressure 46
- Tooth
  - anatomy and forensic odontology 167
  - carving 185*f*
  - crown dimensions in males of diverse populations 176*t*
  - innervation 222
  - numbering systems used to designate 73, 92, 97
    - mandibular first molar 116
    - maxillary first premolar 83, 106
    - maxillary second molar 113
    - maxillary second premolar 88
  - size 158
- Total arch length in
  - lower arch 36*f*
  - upper arch 35*f*
- Trait features of teeth 198
- Transverse
  - ridge in posterior tooth 12*f*
  - ridges 121
- Triangular
  - fossa 14, 14*f*
  - ridge 11
    - in posterior tooth 12*f*
- Tubercle 13
  - of Carabelli 105, 107
  - of Zuckerkandl' 139
- Two
  - digit system 27
  - roots in mandibular second premolar 102*f*
- Type traits of
  - mandibular
    - canine 77
    - central incisor 62
    - first molar 116
    - first premolar 91
    - second premolar 97
  - maxillary
    - canine 72
    - central incisor 51
    - first molar 105
    - first premolar 83
    - second premolar 87

Types of  
fossa 13  
pain 219  
ridges 10

## U

Ugly duckling  
midline diastema 45  
stage 46*f*  
Universal system 26, 52, 57, 63, 66, 73,  
78, 83, 88, 92, 97, 106, 113, 117, 124  
of notation 66  
of tooth numbering 26*f*  
Upper and lower gum-pads 33*f*

## V

Variations of lateral incisor 61*f*  
Venous drainage of maxilla and mandible  
161  
Very low birth weight 213  
Vitamin D 208, 211  
deficiency 213

## X

X-groove pattern 178

## Z

Zsigmondy/palmer system 24