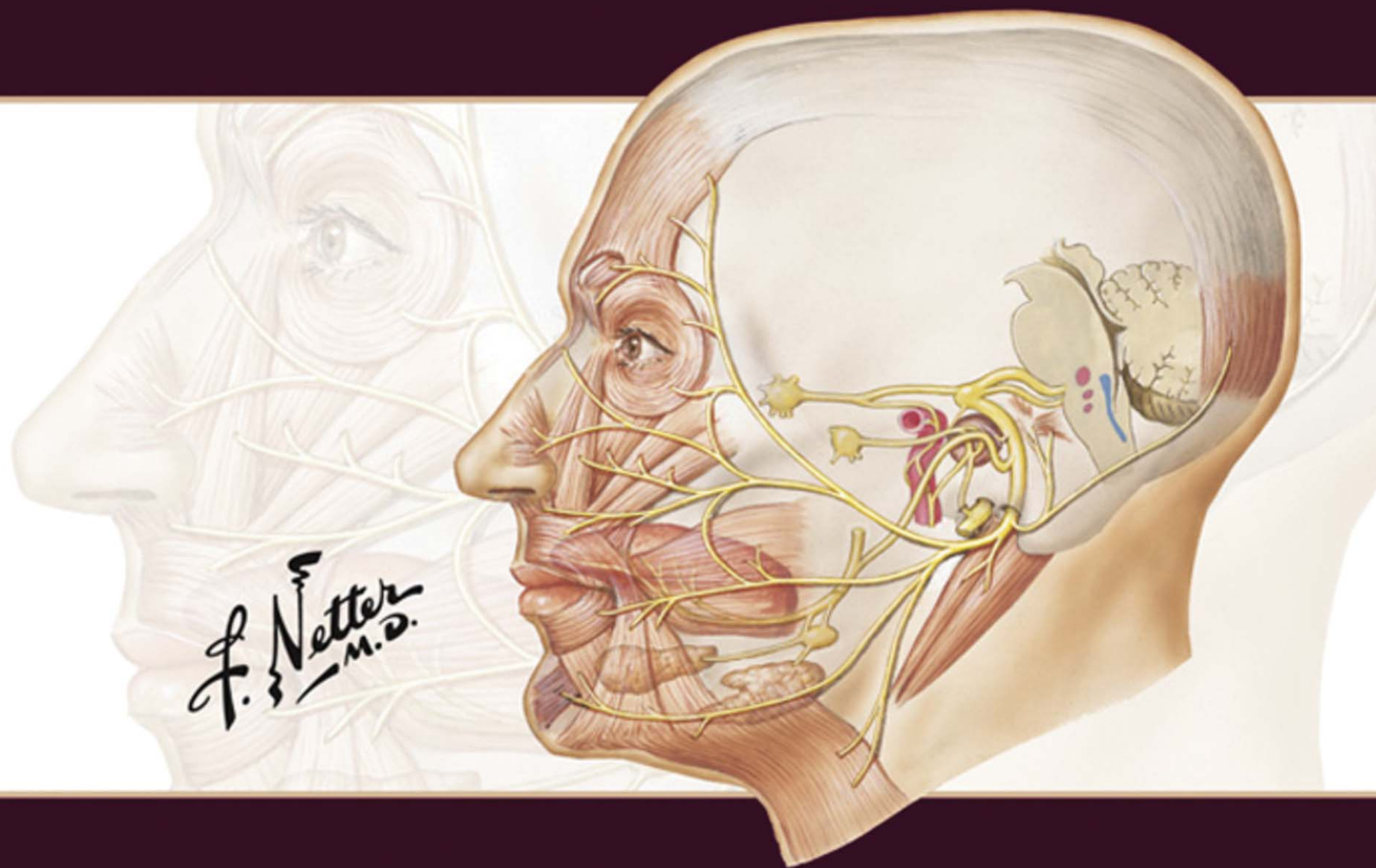


FRANK H. NETTER

# NETTER'S CRANIAL NERVE COLLECTION



ELSEVIER



# Netter's Cranial Nerve Collection

*Content excerpted from*

Allam G, Biousse V, Gwathmey K, Newman N: Section 1. Cranial Nerve and Neuro-ophthalmologic Disorders. In Jones HR, Burns TM, Aminoff MJ, Pomeroy SL (eds). *The Netter Collection of Medical Illustrations—Nervous System, Part II: Spinal Cord and Peripheral Motor and Sensory Systems*. ed 2, vol 7. Philadelphia: Elsevier, 2013, pp 1-48.

Lee TC, Mukundan S. *Netter's Correlative Imaging: Neuroanatomy*. Philadelphia: Elsevier, 2015, pp 175-271.

Videos from **Netter's Dissection Video Modules** adapted from *Netter's Online Dissection Modules* by University of North Carolina, Chapel Hill.

*Illustrations by Frank H. Netter, MD*

## **CONTRIBUTING ILLUSTRATORS**

Carlos A. G. Machado, MD  
Tiffany Slaybaugh DaVanzo

# ELSEVIER

1600 John F. Kennedy Blvd.  
Ste. 1800  
Philadelphia, PA 19103-2899

NETTER'S CRANIAL NERVE COLLECTION

ISBN: 978-0323-37514-6

Copyright © 2016 by Elsevier, Inc. All rights reserved.

No part of this publication may be reproduced or transmitted in any form or by any means, electronic or mechanical, including photocopying, recording, or any information storage and retrieval system, without permission in writing from the publisher. Details on how to seek permission, further information about the Publisher's permissions policies and our arrangements with organizations such as the Copyright Clearance Center and the Copyright Licensing Agency, can be found at our website: [www.elsevier.com/permissions](http://www.elsevier.com/permissions).

This book and the individual contributions contained in it are protected under copyright by the Publisher (other than as may be noted herein).

Permission for Netter Art figures may be sought directly from Elsevier's Health Science Licensing Department in Philadelphia, PA: phone 1-800-523-1649, ext. 3276, or (215) 239-3276; or email [H.Licensing@elsevier.com](mailto:H.Licensing@elsevier.com).

## Notices

Knowledge and best practice in this field are constantly changing. As new research and experience broaden our understanding, changes in research methods, professional practices, or medical treatment may become necessary.

Practitioners and researchers must always rely on their own experience and knowledge in evaluating and using any information, methods, compounds, or experiments described herein. In using such information or methods they should be mindful of their own safety and the safety of others, including parties for whom they have a professional responsibility.

With respect to any drug or pharmaceutical products identified, readers are advised to check the most current information provided (i) on procedures featured or (ii) by the manufacturer of each product to be administered, to verify the recommended dose or formula, the method and duration of administration, and contraindications. It is the responsibility of practitioners, relying on their own experience and knowledge of their patients, to make diagnoses, to determine dosages and the best treatment for each individual patient, and to take all appropriate safety precautions.

To the fullest extent of the law, neither the Publisher nor the authors, contributors, or editors, assume any liability for any injury and/or damage to persons or property as a matter of products liability, negligence or otherwise, or from any use or operation of any methods, products, instructions, or ideas contained in the material herein.

International Standard Book Number: 978-1-4557-7566-8



Working together  
to grow libraries in  
developing countries

[www.elsevier.com](http://www.elsevier.com) • [www.bookaid.org](http://www.bookaid.org)

# OVERVIEW OF CRANIAL NERVES

---

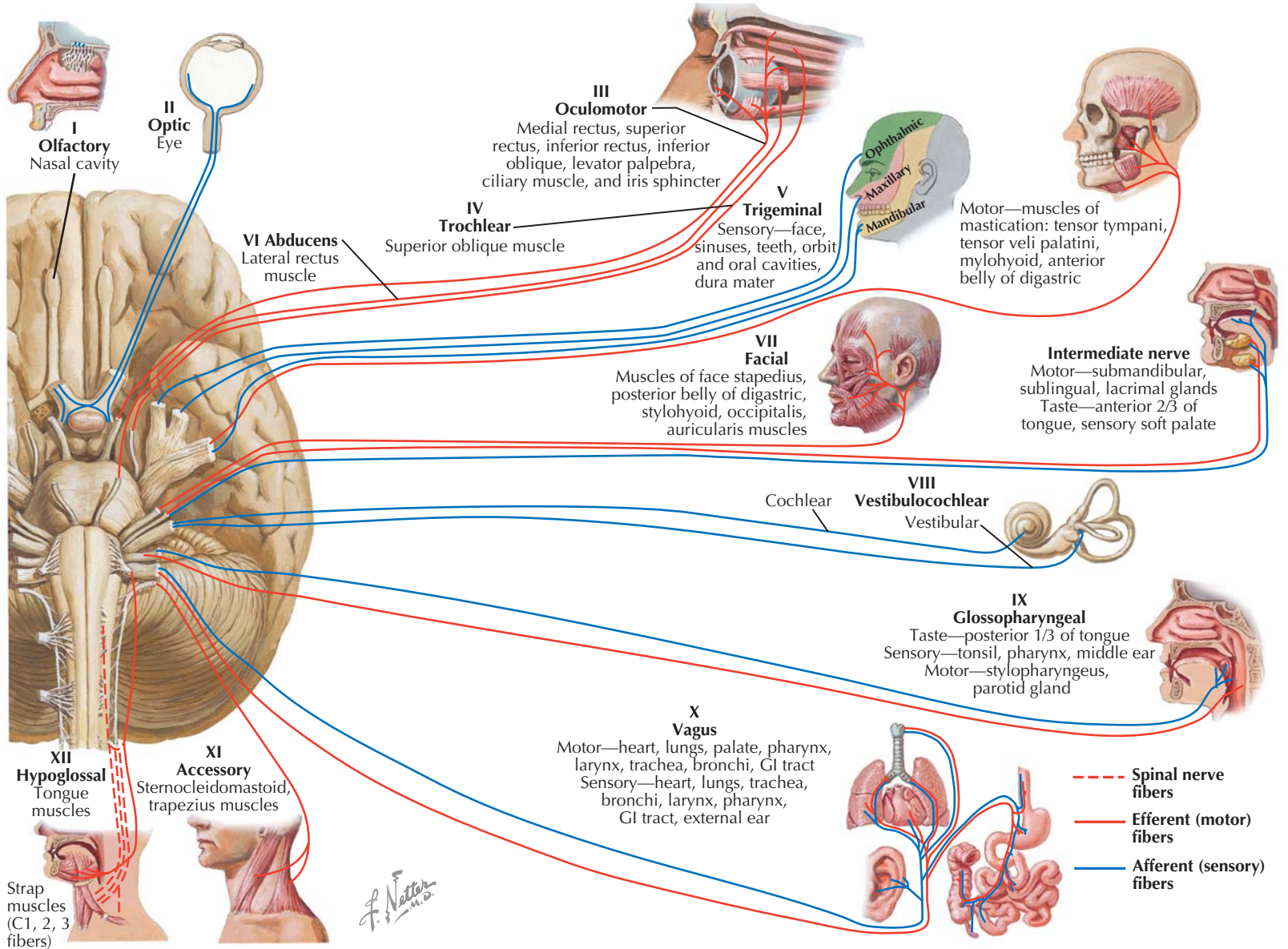
Excerpted from Allam G, Biousse V, Gwathmey K, Newman N: Section 1. Cranial Nerve and Neuro-ophthalmologic Disorders. In Jones HR, Burns TM, Aminoff MJ, Pomeroy SL (eds). *The Netter Collection of Medical Illustrations—Nervous System, Part II: Spinal Cord and Peripheral Motor and Sensory Systems*. ed 2, vol 7. Philadelphia: Elsevier, 2013, pp 1-48.

For more from this publication visit <http://www.us.elsevierhealth.com/netter-green-book-collection/the-netter-collection-of-medical-illustrations-nervous-system-volume-7-part-ii-spinal-cord-and-peripheral-motor-and-sensory-systems-hardcover/9781416063865/>

**For Downloading Dental Books!**  
**Join us on telegram app:**

**<https://t.me/RoyalDentistryLibrary>**

DISTRIBUTION OF MOTOR AND SENSORY FIBERS



OVERVIEW OF CRANIAL NERVES

The brainstem is the source of all the cranial nerves and provides sensory, motor, and, through the vagus nerve, parasympathetic preganglionic innervation to the face, head, thorax, and most of the abdominal viscera. Distinct motor and sensory nuclei within the brainstem project to the various structures of the head to provide (1) general sensory information from the face, ears, and oropharynx and (2) motor innervations for facial movement and expression, mastication, extraocular eye movements, and complex functions such as speech and swallowing. The specialized olfactory, visual, auditory, and gustatory senses are provided by highly specialized receptor cells and end organs, with ultimately wide cortical projections.

Cranial nerve motor nuclei are located medially, whereas the sensory nuclei are found generally more lateral. Three types of motor nuclei are present innervating voluntary striated muscles (somatic), muscles of facial expressions and mastication (special motor derived from embryonic branchial arch structures), and autonomic smooth muscles (visceral). Each cranial

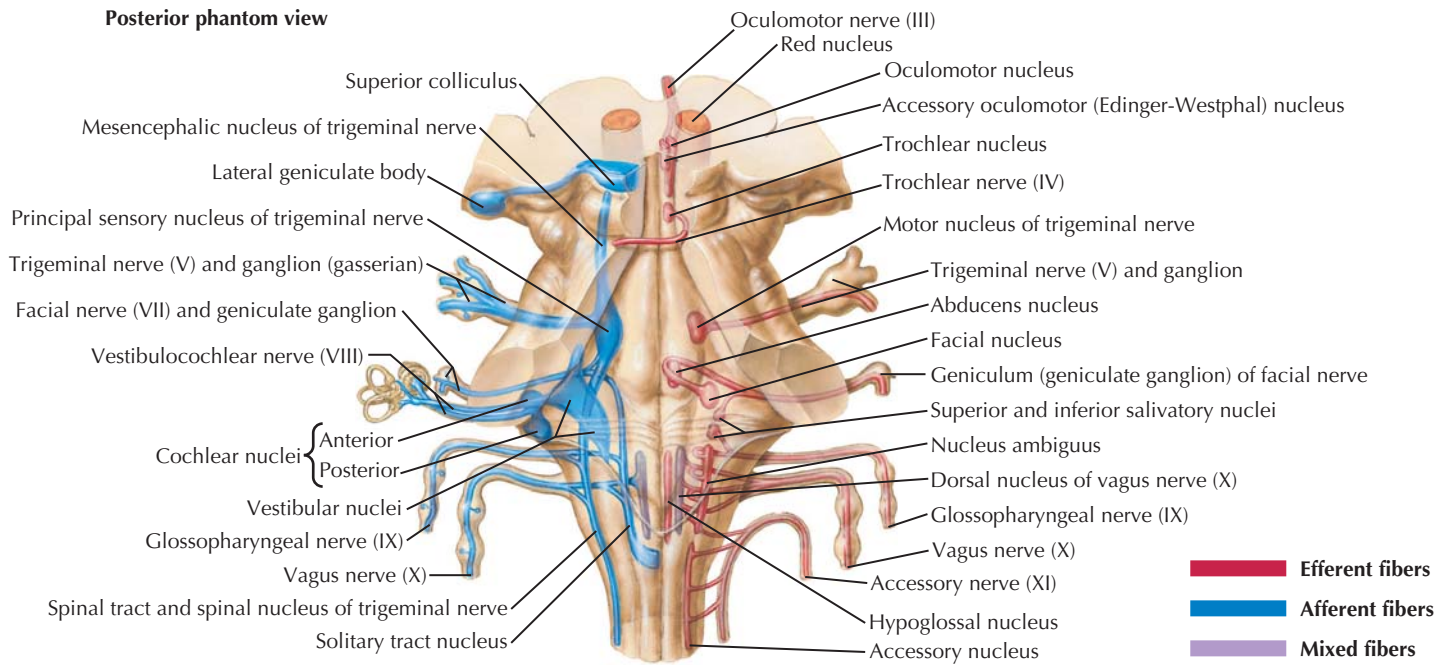
nerve serves a regional skull area and may provide more than one function to that area and therefore is not restricted to a single nucleus or nerve type. For example, the facial nerve provides voluntary motor innervations to the face as well as taste sensation to the anterior tongue. The pure motor nerves (except for perhaps some proprioceptive function) are the oculomotor III, trochlear IV, abducens VI, spinal accessory nerve XI, and hypoglossal XII. The special sensory nerves are the olfactory, optic, and vestibulocochlear. Mixed cranial nerves are the trigeminal V, facial VII, glossopharyngeal IX, and vagus X. A summary of the origin, course, and distribution of each cranial nerve is outlined on the next plates.

Cranial neuropathies may manifest as a single cranial neuropathy or, less commonly, as multiple cranial neuropathies. Single cranial neuropathies are discussed in their respective sections. For example, Bell palsy is reviewed in the cranial nerve VII (facial nerve) section. Multiple cranial neuropathies involve any combination of cranial nerves, although cranial nerves III, V, VI, and VII are the most commonly affected in most clinical

series. The manifestations of multiple cranial neuropathies reflect the sites of injury and function of the cranial nerves affected. The many different causes of multiple cranial neuropathies include infectious, neoplastic, autoimmune disease, trauma, and vascular disease. Infections associated with multiple cranial neuropathies include Lyme disease, tuberculous meningitis, cryptococcus, histoplasmosis, botulism, mucormycosis, certain viruses (e.g., herpes simplex virus, varicella-zoster virus) and bacterial meningitis. Guillain-Barré syndrome (GBS) and the Miller Fisher variant of GBS are monophasic, autoimmune polyradiculoneuropathies that can frequently involve multiple cranial nerves. Neoplasms cause multiple cranial neuropathies either by direct compression and local extension, such as with meningiomas, schwannomas, and nasopharyngeal tumors, or by diffuse dissemination and meningeal infiltration, such as with lymphoma and various carcinomas. Myasthenia gravis (MG) mimics multiple cranial neuropathies but the site of autoimmune attack in MG is directed against the postsynaptic muscle end rather than the nerve.

Name and number: Type of fibers	Origin, course, and distribution	Chief functions
<b>Olfactory (I):</b> <i>Special sensory</i>	Olfactory cells in nasal mucosa aggregate into olfactory nerves that penetrate the cribriform plate and join to form the olfactory bulb. The bulb's posteriorly extending tract divides into a medial branch, which fans into the parolfactory and subcallosal areas, and a lateral branch, which ends in the uncus and the parahippocampal gyrus.	<b>Smell</b>
<b>Optic (II):</b> <i>Special sensory</i>	Axons of the inner retinal <i>ganglion cell layer</i> form the retina's <i>nerve fiber layer</i> and gather at the optic disk (optic nervehead) before turning 90° and penetrating the scleral canal to exit the globe, now myelinated, as the <i>optic nerve</i> . The <i>optic chiasm</i> is the intersection of the optic nerve from each eye coming through the optic canal and is located above the pituitary body within the sella turcica. Axons from the temporal retina (nasal field) remain ipsilateral as they pass through the chiasm to the optic tract. In contrast, the nasal retinal fibers decussate, carrying temporal visual field information to the contralateral side. Inferior nasal fibers decussate within the chiasm more anteriorly than superior ones. As the inferior nasal retinal fibers approach the posterior aspect of the chiasm, the fibers shift to occupy the lateral aspect of the contralateral optic tract. The optic tract leads to the lateral geniculate bodies. The lateral geniculate nucleus (LGN) is a thalamic nucleus that serves as the synapse point as the retinal ganglion cells and relays visual information through the optic radiations to the striate and occipital cortex.	<b>Vision</b>
<b>Oculomotor (III):</b> <i>Motor</i> <i>Visceral motor</i>	<p>This nerve emerges as a collection of nine rostral midbrain subnuclei located ventral to the aqueduct at the level of the superior colliculus and includes the <i>accessory autonomic (Edinger-Westphal)</i> nucleus.</p> <p>Axons from the CNIII subnuclei gather into a fascicle that arcs through the red nucleus and emerges at the medial surface of the cerebral peduncle. In the interpeduncular cistern, the nerve passes beneath the posterior cerebral artery, then pierces the dura crossing next to the internal carotid artery en route to the cavernous sinus. From the lateral wall of the cavernous sinus, it enters the orbit through the superior orbital fissure to supply the superior rectus, medial rectus, inferior rectus, and inferior oblique.</p> <p>The fibers subserving pupillary constriction are located superficially and are susceptible to compression but are less prone to microvascular or ischemic changes than the deeper fibers are. These parasympathetic fibers split off the oculomotor nerve in the orbit and synapse in the ciliary ganglion from which postganglionic <i>short ciliary nerves</i> supply the pupillary sphincter and ciliary muscles.</p>	<p><b>Somatic motor:</b> Upper lid elevation (levator palpebrae superioris) and extraocular movements upward, medially, and downward</p> <p><b>Visceral motor:</b> Parasympathetically mediated pupillary constriction and accommodation reflex</p>
<b>Trochlear (IV):</b> <i>Motor</i>	The CNIV nuclei are located in the midbrain at the level of the inferior colliculi off midline at the anterior edge of the periaqueductal gray. Axons from the trochlear nucleus arc posteriorly around the periaqueductal gray and cross the midline to emerge laterally beneath the inferior colliculus and wrap forward around the medial border of the brachium conjunctivum. CNIV completely decussates, a unique feature among the cranial nerves, and exits the brainstem from its posterior aspect. It passes the ambient cistern and through the lateral wall of the cavernous sinus to then enter the orbit via the superior orbital fissure. The trochlear nerve innervates a single extraocular muscle, the superior oblique.	<b>Somatic Motor:</b> Superior oblique muscle, extraocular eye movement downward and intorsion
<b>Trigeminal (V):</b> <i>Somatic sensory and special motor</i>	<p>The <i>trigeminal somatic sensory column</i> is a posterolateral series of nuclei extending from the mid pons to the upper cervical cord and receive general sensory input from the eye, orbit, face, forehead, upper and lower jaws, sinuses, teeth, and nasopharynx. Proprioceptive receptors in the extraocular and masticatory muscles end in the <i>mesencephalic nucleus</i>. Pain, touch, and temperature fibers end in the <i>principal (pontine) sensory nucleus</i> and <i>spinal nucleus of trigeminal nerve</i>. <i>Trigeminal motor nucleus</i> in the upper part of the pons is the origin of special branchiomotor fibers to the muscles of mastication.</p> <p>Large sensory and smaller motor roots enter and emerge laterally at the midpons level. As the trigeminal nerve exits the posterior fossa, it expands over the apex of the petrous temporal bone into the <i>trigeminal (semilunar) ganglion</i> made of sensory nuclei from the <i>ophthalmic</i>, <i>maxillary</i>, and <i>mandibular</i> nerves that pass through the superior orbital fissure, foramen rotundum, and foramen ovale, respectively. The <i>ophthalmic nerve</i> divides into lacrimal, frontal, and nasociliary branches, which participate in innervating eye, nose, and scalp. The <i>maxillary nerve</i> traverses the pterygopalatine fossa, enters the infraorbital groove (canal), and emerges as the <i>infraorbital nerve</i> through infraorbital foramen; supplies meningeal, zygomatic, superior alveolar, inferio-palpebral, nasal, and superior labial branches, and is connected with pterygopalatine ganglion through which it supplies orbital, nasal, palatine, and pharyngeal branches. The <i>mandibular nerve</i> is joined by entire motor root of trigeminal nerve in the foramen ovale and gives off meningeal, buccal, auriculotemporal, lingual, and inferior alveolar branches, as well as motor nerves supplying masticatory muscles, the tensors of the soft palate, and the tympanic membrane.</p>	<p><b>Somatic sensory (touch, pain and temperature):</b> Eyes, face, anterior scalp, sinuses, teeth, oral and nasal cavities as well as the dura mater</p> <p><b>Proprioceptive sensory (deep pressure, position, and movement):</b> Teeth, temporomandibular joint, hard palate, and muscles of mastication</p> <p><b>Special motor:</b> Branchiomotor fibers to the muscles of mastication, anterior belly of the digastrics, tensor tympani, and tensor veli palatini mylohyoid</p>
<b>Abducens (VI):</b> <i>Motor</i>	<p>The abducens CNVI nucleus is in the floor of the fourth ventricle just lateral to the median eminence of the pons. It is enveloped by looping CNVII fibers (genu) that form the facial colliculus.</p> <p>The CNVI nucleus contains two physiologically distinct groups of neurons: one innervating the ipsilateral lateral rectus muscles and the other projecting across the midline up the contralateral medial longitudinal fasciculus (MLF) to the ventral nucleus of the contralateral CNIII nuclear complex. These internuclear connections produce the simultaneous activation of the contralateral medial rectus muscle and the ipsilateral lateral rectus that ensures conjugate lateral horizontal gaze.</p> <p>The CNVI fasciculus projects anteriorly and caudally to exit the inferior edge of the pons just medial to the corticospinal tracts. The nerve ascends between the pons and the clivus within the pontine cistern. It pierces the dura and then enters the lateral cavernous sinus below the trochlear nerve. It reaches the orbit through the superior-orbital fissure.</p>	<b>Somatic motor:</b> Lateral rectus muscle extraocular eye movement, eye abduction

NERVES AND NUCLEI VIEWED IN PHANTOM FROM BEHIND

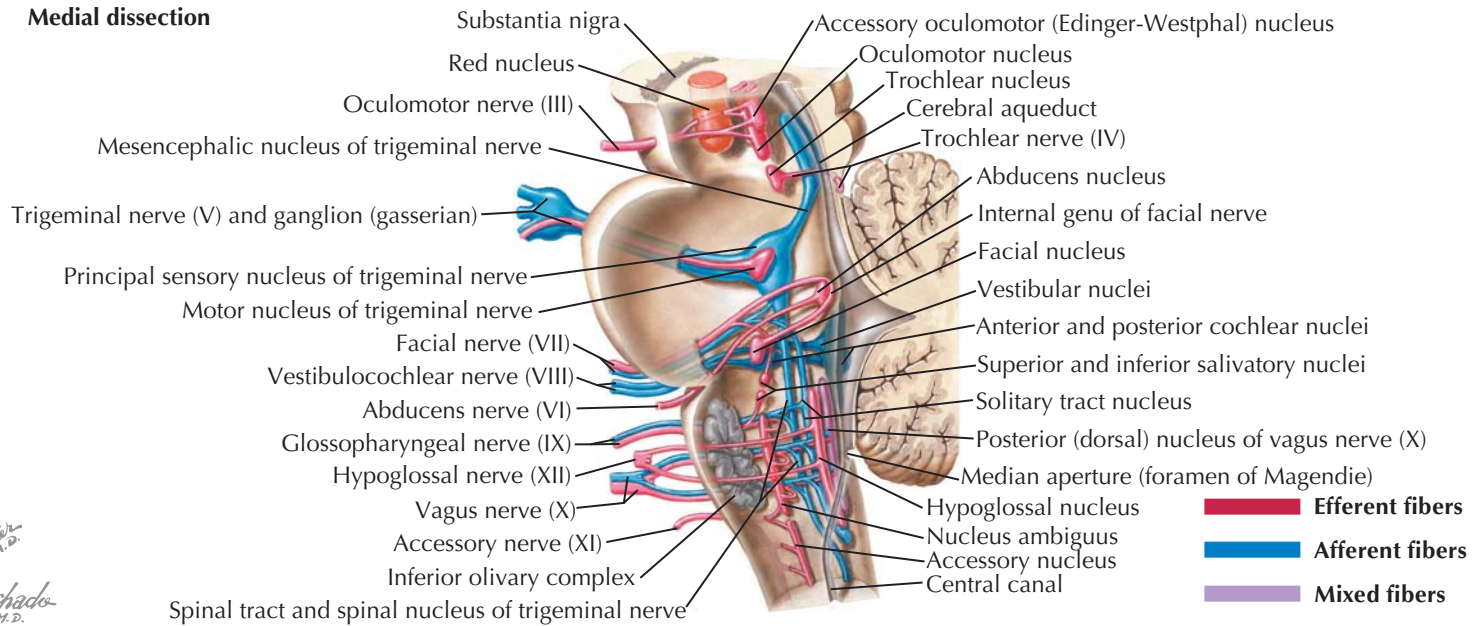


F. Netter M.D.

Name and number: Type of fibers	Origin, course, and distribution	Chief functions
<p><b>Facial (VII):</b>  <b>Special motor</b>  <b>General visceral motor</b>  <b>Somatic sensory</b>  <b>Special sensory</b></p>	<p>Branchiomotor fibers arise from the <i>facial nucleus</i> in the lower pons and ascend to loop around the abducens nucleus and then descend anterolaterally between the spinal trigeminal complex and the VII nerve motor nucleus. The nerve emerges as two divisions through the recess between the inferior cerebellar peduncle and the medulla; a larger <i>motor root</i> and smaller <i>nervus intermedius</i> containing mainly afferent special sensory fibers for taste and secretomotor fibers to the <i>pterygopalatine ganglion</i> (lacrimation and mucous membrane secretory function in the mouth and nose). Both divisions of the facial nerve, along with CN VIII, then pass through the internal acoustic meatus. At the level of the geniculate ganglion secretomotor fibers (originating from the <i>superior lacrimal/salivatory nucleus</i>), separate and proceed superiorly to the pterygopalatine ganglion. The chorda tympani (carrying secretomotor fibers to the submandibular ganglion and special sensory taste fibers from the anterior two thirds of tongue and soft palate) separates distal to the geniculate nucleus and joins the lingual nerve to the tongue. The branchiomotor fibers proceed through the bony facial canal and emerge in the face anterior to the mastoid process from the stylomastoid foramen. It enters the parotid gland to divide into diverging branches toward the facial muscles and the platysma (Plate 2-21).</p>	<p><b>Special motor:</b> Muscles of facial expression, stapedius, stylohyoid, and posterior belly of the digastrics muscle</p> <p><b>General visceral motor:</b> Parasympathetic innervations of the submandibular, sublingual, lacrimal, and nasal/oral mucous membrane glands</p> <p><b>Somatic sensor:</b> External auditory meatus and skin over mastoid</p> <p><b>Special sensory:</b> Taste anterior 2/3rds of the tongue</p>
<p><b>Vestibulocochlear (VIII):</b>  <b>Special sensory</b></p>	<p>The vestibulocochlear nerve emerges through the internal acoustic meatus at the pontomedullary angle posterolateral to the facial nerve. The primary neurons are bipolar cells located in the vestibular and multiple spiral ganglia. Peripheral processes pass from special auditory (cochlea) and vestibular (ampullae, utriculus, and sacculus) receptors, while the central processes project to two cochlear, and four vestibular brainstem nuclei, respectively. The ventral and dorsal cochlear nuclei are located at the level of the inferior cerebellar peduncle in the superior medulla. Most cochlear nuclear fibers decussate through the trapezoid body, after which third- and fourth-order neurons then ascend the lateral lemniscus to the inferior colliculus with projections ultimately to the auditory cortex. The superior, inferior, medial, and lateral vestibular nuclei lie in the anterolateral floor of the fourth ventricle and connect with the cerebellum, the nuclei of CNs III, IV, and VI (through the medial longitudinal fasciculus) and to anterior horn cells controlling muscles of head and neck (vestibulospinal tract).</p>	<p><b>Hearing</b></p> <p><b>Equilibrium and balance</b></p> <p><b>Reflexive eye movements</b></p>
<p><b>Glossopharyngeal (IX):</b>  <b>Special motor</b>  <b>General visceral motor</b>  <b>Visceral sensory</b>  <b>Somatic sensory</b></p>	<p>Special branchiomotor fibers arise from cranial end of nucleus ambiguus and supply the stylopharyngeus muscle. Secretomotor fibers arise from inferior salivatory nucleus and proceed as parasympathetic fibers through the tympanic nerve to the otic ganglion; postganglion fibers (lesser petrosal nerve) innervate the parotid gland. Special sensory taste fibers from the posterior third of tongue have their cell bodies in the petrosal ganglion and then project centrally to the solitary tract nucleus. "Visceral" sensory fibers from the posterior tongue, fauces, tonsil, tympanic cavity, eustachian tube, and mastoid cells end in a combined dorsal glossopharyngeal vagal nucleus but with ordinary sensory fibers probably ending in the spinal tract and nucleus of trigeminal nerve. Special visceral afferents from pressure receptors in the carotid sinus mediate decreased heart rate and blood pressure through vagus nerve connections.</p> <p>The nerve emerges from the medulla above the vagus nerve and leaves the skull through the jugular foramen. It runs forward between the internal carotid artery and internal jugular vein and curves over the stylopharyngeus muscle, to end in branches for the tonsils, and mucous membrane and glands of pharynx and pharyngeal part of tongue. The tympanic branch forms the main part of the tympanic plexus, which supplies the tympanic cavity and the lesser petrosal nerve carrying secretomotor fibers for the parotid gland.</p>	<p><b>Special motor:</b> Stylopharyngeus; elevation of pharynx</p> <p><b>General visceral motor:</b> Parotid and mucous glands secretion</p> <p><b>Special sensory:</b> Taste posterior third of tongue, and numerous taste buds in vallate papillae</p> <p><b>General visceral sensory:</b> General sensation from posterior tongue, fauces, tonsil, tympanic cavity, eustachian tube, and mastoid cells. Carotid body and sinus</p> <p><b>Somatic sensory:</b> Outer ear sensation</p>

NERVES AND NUCLEI IN LATERAL DISSECTION

Medial dissection



*F. Netter M.D.*  
*C. Machado M.D.*

Name and number: Type of fibers	Origin, course, and distribution	Chief functions
<b>Vagus (X):</b> <i>Special motor</i> <i>General visceral motor</i> <i>Somatic sensory</i> <i>Visceral sensory</i> <i>Special sensory</i>	<p>The dorsal vagal nucleus is a mixture of visceral efferent and afferent cells forming elongated column on each side of midline and extending through the length of the medulla, lateral to the hypoglossal nuclei. From here, preganglionic parasympathetic fibers go to parasympathetic ganglia innervating cardiac and unstriated muscles in the thoracic and abdominal viscera. Motor fibers for striated muscles of larynx and pharynx originate in the midportion of the nucleus ambiguus (ill-defined column of large cells located in the reticular formation).</p> <p>Afferent fibers from visceral receptors have their cell bodies in the inferior vagal (nodose) ganglion and end in the mixed dorsal vagal nucleus. They convey sensation from the pharynx, larynx, trachea, and viscera. However, a few special sensory taste fibers from the epiglottis and the adjacent tongue end in the solitary tract nucleus. General somatic afferents from auricular and meningeal branches with cell bodies in the jugular ganglion end in the spinal tract and nucleus of the trigeminal nerve.</p> <p>The nerve is attached by a series of medullary rootlets located laterally between the olive and inferior cerebellar peduncle. The vagus nerve leaves the skull through the jugular foramen and is soon joined by the cranial part of the accessory nerve to then descend in the neck within the carotid sheath. The vagus nerve continues through the thorax and contributes to cardiac, pulmonary, and esophageal plexuses. It enters the abdomen as the anterior and posterior vagal trunks.</p>	<p><b>Special Motor:</b> Intrinsic laryngeal muscles and contribute to pharyngeal constrictors</p> <p><b>General visceral motor:</b> Parasympathetic supply (movement and secretion) to the heart, the great vessels, trachea, bronchi, and alimentary canal, and associated glands from pharynx almost to left colic (splenic) flexure</p> <p><b>Somatic sensory:</b> Parts of auricle, external acoustic meatus, and tympanic membrane meninges of posterior cranial fossa</p> <p><b>General visceral sensory:</b> Pharynx, larynx, trachea, and abdominal viscera</p> <p><b>Special sensory:</b> Taste from epiglottis and valleculae</p>
<b>Accessory (XI):</b> <i>Special motor</i>	<p>The accessory nerve consists of cranial and spinal roots. Cranial roots arises from cells within the lower end of the nucleus ambiguus and supply intrinsic laryngeal muscles. The spinal roots arise from a group of anterior horn cells in the upper five or six cervical segments (the spinal accessory nucleus) and supply the sternocleidomastoid and trapezius muscles.</p> <p>The cranial root fibers form the internal branch of the accessory nerve and arise as a series of rootlets on the surface of medulla oblongata below, and in line with the glossopharyngeal and vagal nerve rootlets. The spinal rootlets emerge through the lateral white column of the spinal cord and ascend behind the denticulate ligaments and unite to form the external branch of the accessory nerve entering the skull through the foramen magnum behind vertebral artery. Cranial and spinal roots unite for a short distance, before leaving the skull through the jugular foramen. The internal branch joins the vagus nerve. The external branch runs downward and backward through the sternocleidomastoid muscle, then crosses the posterior triangle of neck and ends in the trapezius muscle. It also communicates with branches of spinal nerves C2–C4.</p>	<p><b>Special Motor</b></p> <p><b>Internal branch (vagus n.):</b> Intrinsic muscles of the larynx via the recurrent laryngeal nerve (except cricothyroid-superior laryngeal nerve) and soft palate (except tensor veli palatine-mandibular division of the trigeminal nerve)</p> <p><b>External branch:</b> Sternocleidomastoid and trapezius muscles</p>
<b>Hypoglossal (XII): Motor</b>	<p>The hypoglossal nucleus is a medial column of cells situated in the lower floor of the fourth ventricle and extends the length of the medulla anterior to the central canal in the “closed” part of medulla oblongata. Axons from the nucleus course anteriorly and just lateral to the medial lemniscus and cross the most medial portion of the inferior olive to exit the brainstem in the anterolateral sulcus between the pyramidal tract and the prominence of the inferior olive. The fibers emerge as 10-15 rootlets and fuse to form two bundles that unite as they pass through the hypoglossal canal of the occipital bone. The hypoglossal nerve then runs forward between the internal carotid artery and internal jugular vein and inclines upward into tongue. It is joined by a filament from spinal nerve C1, but this soon leaves to form the superior root (descendens hypoglossi) of the ansa cervicalis.</p>	<p><b>Somatic motor:</b> Intrinsic and extrinsic muscles of the tongue</p>



This page intentionally left blank

# THE 12 CRANIAL NERVES

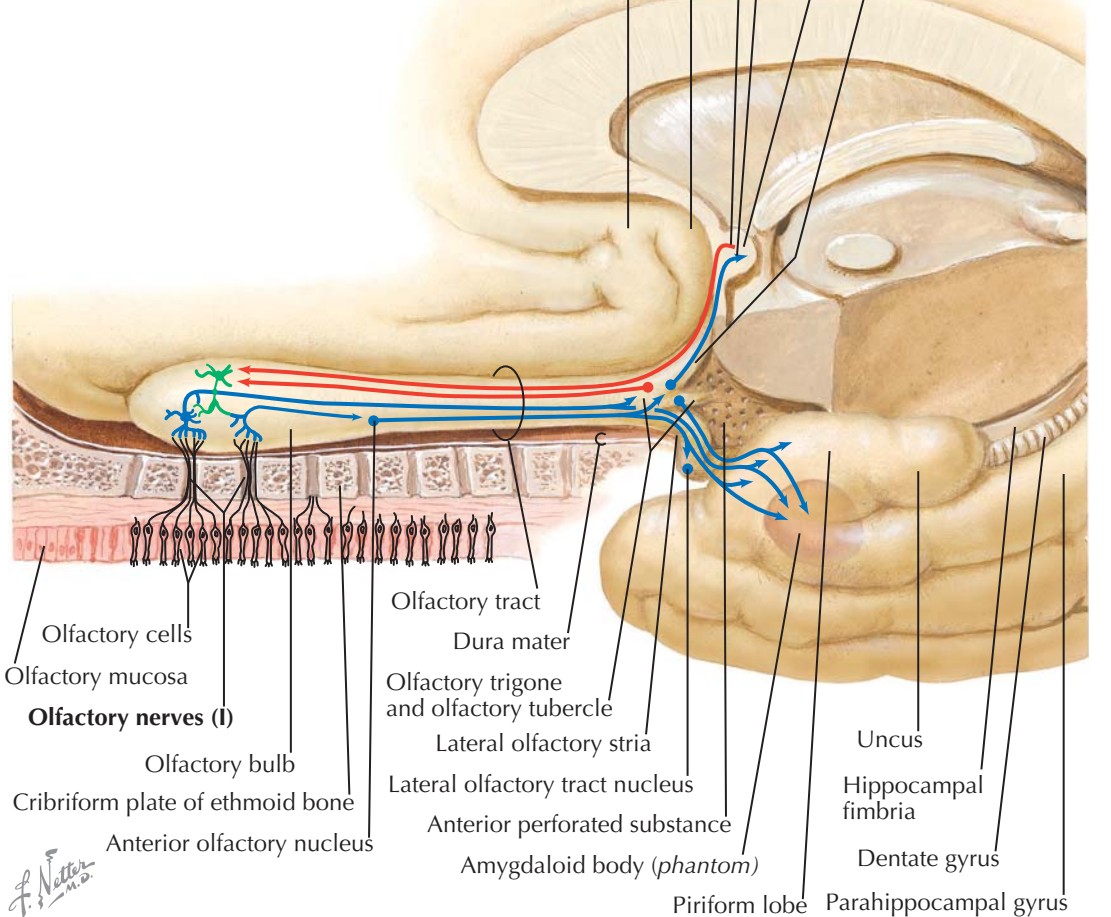
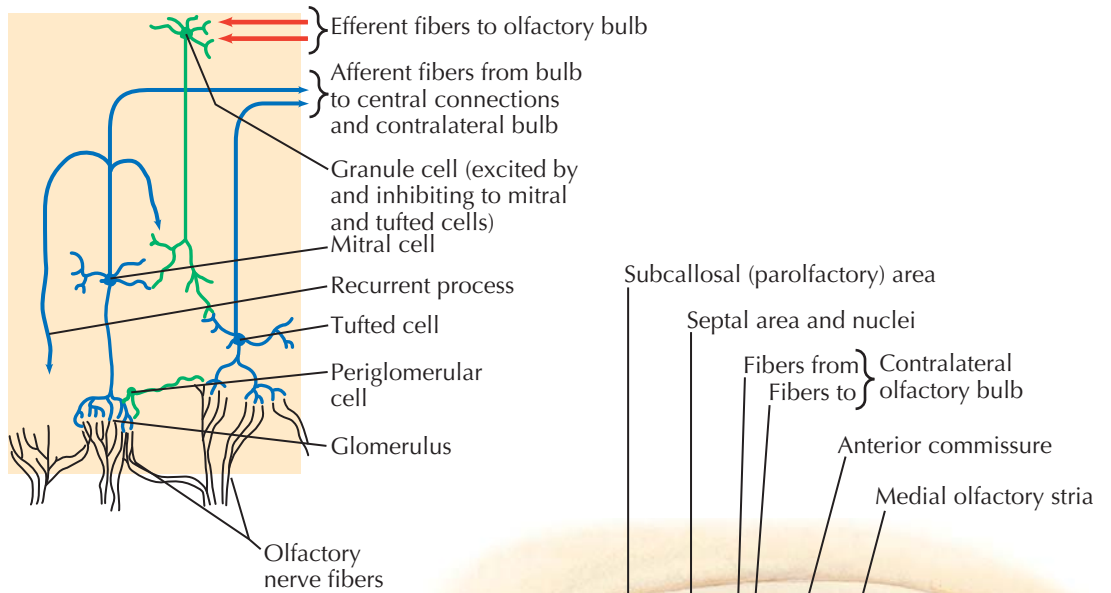
---

Excerpted from Allam G, Biousse V, Gwathmey K, Newman N: Section 1. Cranial Nerve and Neuro-ophthalmologic Disorders. In Jones HR, Burns TM, Aminoff MJ, Pomeroy SL (eds). *The Netter Collection of Medical Illustrations—Nervous System, Part II: Spinal Cord and Peripheral Motor and Sensory Systems*. ed 2, vol 7. Philadelphia: Elsevier, 2013, pp 1-48.

For more from this publication visit <http://www.us.elsevierhealth.com/netter-green-book-collection/the-netter-collection-of-medical-illustrations-nervous-system-volume-7-part-ii-spinal-cord-and-peripheral-motor-and-sensory-systems-hardcover/9781416063865/>

OLFACTORY PATHWAYS

Olfactory bulb cells: schema



**CRANIAL NERVE I:  
OLFACTORY NERVE**

**ANATOMY**

The olfactory nerves are concerned with the special sense of smell. The nerve fibers are the central processes of bipolar nerve cells located in the olfactory epithelium, which covers most of the superior-posterior nasal septum and the lateral wall of the nasal cavity. The unmyelinated peripheral olfactory fibers aggregate into approximately 20 slender olfactory bundles that make up the olfactory nerve. The nerve traverses the ethmoidal cribriform plate surrounded by finger-like extensions from the dura mater and arachnoid to end in the “glomeruli” of the homolateral olfactory bulb. Within the bulb, these fibers synapse with second-order neurons called mitral and tufted cells whose axons constitute the olfactory tract that courses along the frontal lobe base. It then divides into the medial and lateral olfactory striae on either side of the anterior perforated substance and projects directly into the primary olfactory cortex within the temporal lobe. This direct pathway without a central sensory relay site (such as in the thalamic nuclei) is unique among the cranial nerves. Although most of the olfactory tract fibers have ipsilateral central connections, some fibers decussate in the anterior commissure, making the cortical representation of smell bilateral. The human primary olfactory cortex includes the uncus, hippocampal gyrus, amygdaloid complex, and entorhinal cortex.

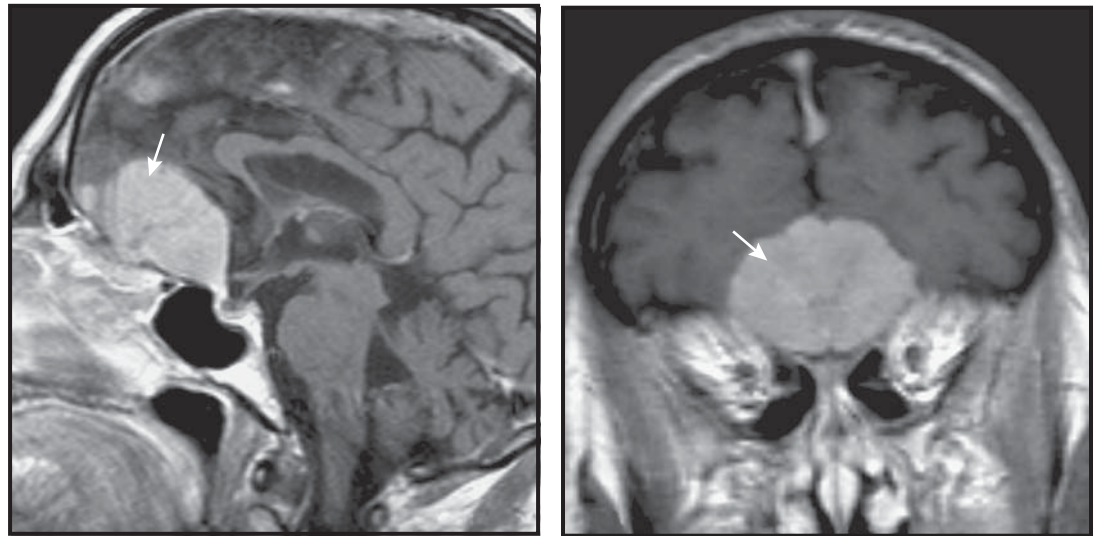
**OLFACTORY NERVE DISORDERS**

Anosmia is not always apparent to the patient, and due to the close association of flavor perception and olfaction, may be reported as altered taste rather than loss of smell. Bilateral anosmia is more common and usually of benign nature, whereas unilateral anosmia should raise suspicion for a more serious disorder, such as an olfactory groove meningioma or frontal basal tumor. The most common cause of anosmia is nasal and paranasal sinus infection with inflammation and is referred to as transport or conductive olfactory disorders. Post-traumatic olfactory dysfunction is the cause for 20% of patients with anosmia and is the result of olfactory nerve shearing as it passes through the cribriform plate. In more substantial damage, the olfactory nerve is torn by fractures involving the cribriform plate, with cerebrospinal fluid rhinorrhea and possible meningial

infection. Post-traumatic anosmia or hyposmia may be either unilateral or bilateral. Tumors of the olfactory groove affect the olfactory bulb and tract. The most common are olfactory groove meningiomas, which are usually histologically benign tumors causing mostly unilateral, and occasionally bilateral, gradual olfactory dysfunction. Other tumors include sphenoid and frontal osteomas, pituitary tumors, and nasopharyngeal carcinomas. Unless specifically tested, a presentation of

anosmia is unusual because of generally unilateral involvement and slow tumor growth with slow decline in olfactory function. Once such tumors are large enough (>4 cm in diameter), they cause pressure on the frontal lobes and the optic tracts, with symptoms of headaches, visual disturbances, personality changes, and memory impairment. Very large olfactory groove tumors on rare occasion cause ipsilateral optic atrophy by exerting direct pressure on the optic nerve with

OLFACTORY RECEPTORS



**Subfrontal meningioma.** T1-weighted, gadolinium-enhanced sagittal and coronal MR images show a large enhancing skull-based mass displacing and compressing the olfactory apparatus.

**CRANIAL NERVE I: OLFACTORY NERVE** (Continued)

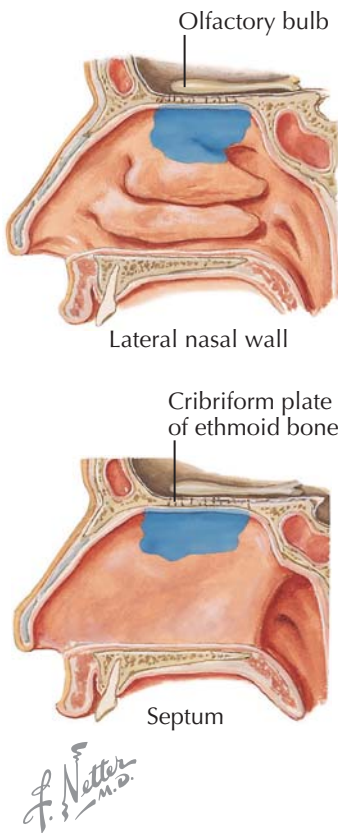
contralateral papilledema from increased intracranial pressure. The finding of ipsilateral optic atrophy, contralateral papilledema, and ipsilateral anosmia is known as the Foster-Kennedy syndrome. Esthesioneuroblastomas arise from the upper nasal cavity and manifest with nasal obstruction and epistaxis. Rarely, they involve the orbit and cause diplopia, visual loss, proptosis, and periorbital swelling. Anosmia is an early sign of neurodegenerative processes, particularly Parkinson disease, Alzheimer disease, and Lewy body dementia. It frequently precedes other neurologic signs, such as motor findings or cognitive changes. Olfactory discrimination is affected by many medications thought to disrupt the physiologic turnover of receptor cell and includes opiates, anticonvulsants, and various immunosuppressive agents. Congenital or hereditary anosmia is rare. Kallmann syndrome consists of congenital hypoplasia or absence of the olfactory bulbs and hypogonadotropic hypogonadism.

**OLFACTORY RECEPTORS**

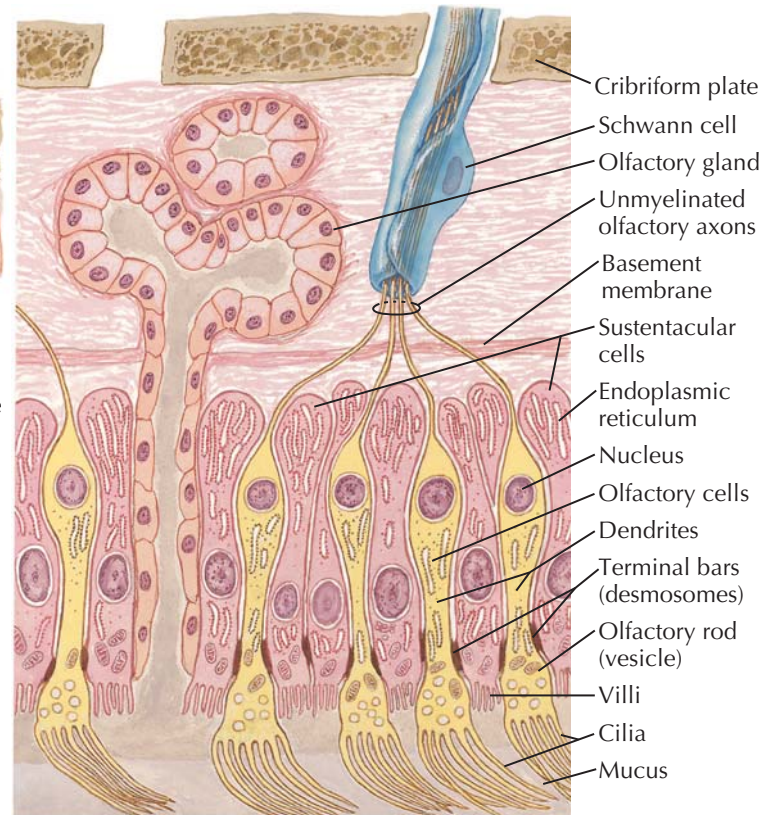
Receptors responsible for the sense of smell are found in the patch of olfactory epithelium that is located on the superior-posterior nasal septum and the lateral wall of the nasal cavity. In addition to the receptor cells, this epithelium contains olfactory (Bowman's) glands and sustentacular cells, both contribute to the mucous secretion that coats the epithelial surface and makes odorants soluble. The sustentacular cells also act as supporting cells for the slender olfactory receptors.

Olfactory receptor cells may be considered specialized, primitive-type, bipolar neurons. Their nuclei are located at the base of the epithelial layer. Basal stem cells located along the basement membrane differentiate into olfactory receptors or supporting cells, replenishing the olfactory epithelium about every 2 weeks. From the nuclear region of the olfactory receptor cell, a thin dendritic process extends toward the surface of the epithelium. At its apical end, this process widens into an olfactory rod, or vesicle, from which 10 to 15 motile cilia project into the mucous layer covering the epithelium. Desmosomes at the base of the olfactory vesicle provide a tight seal between the membranes of olfactory and sustentacular cells, thus preventing external substances from entering the intercellular spaces. At its base, the olfactory receptor cell narrows and gives

**Distribution of olfactory epithelium** (blue area)



**Section through olfactory mucosa**

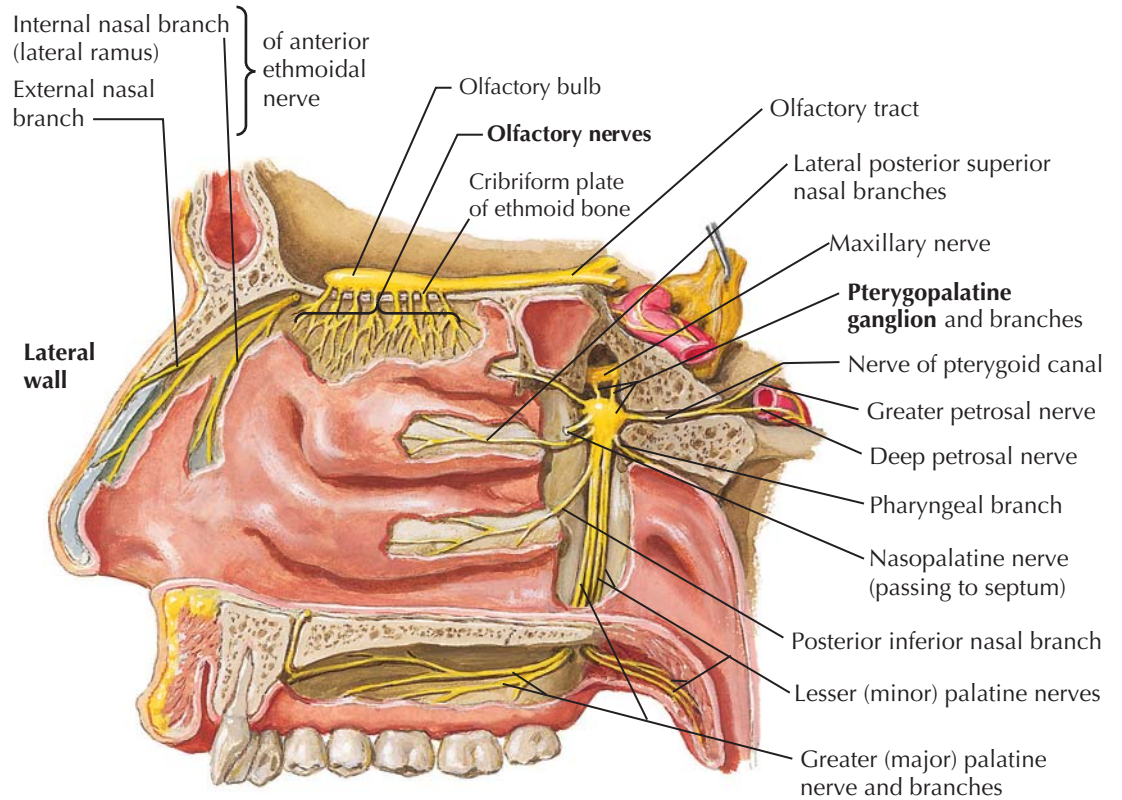


rise to a fine (0.2 to 0.3 μm) unmyelinated axon. Large numbers of these axons converge to run together within a single Schwann cell sheath. The fibers then penetrate the cribriform plate to collectively form the olfactory nerve. In humans, this nerve contains on the order of 100 million axons.

**Odorant Transduction.** The cell membranes of the olfactory receptor cells are able to convert chemical odorants into an electrical signal by activation of a

G-protein-coupled protein receptor cascade that activates the enzyme adenylate cyclase, which produces cyclic adenosine monophosphate (cAMP) as a second messenger. cAMP then changes the structure of the cell membrane channel proteins to an open state. The channel is permeable to cations that flow from the nasal mucosa into the cell. The negative resting membrane potential (-70 mV) is shifted to a more positive value. Once a certain threshold is reached, the analog sensor

**OLFACTORY BULB AND NERVE**



**CRANIAL NERVE I: OLFACTORY NERVE (Continued)**

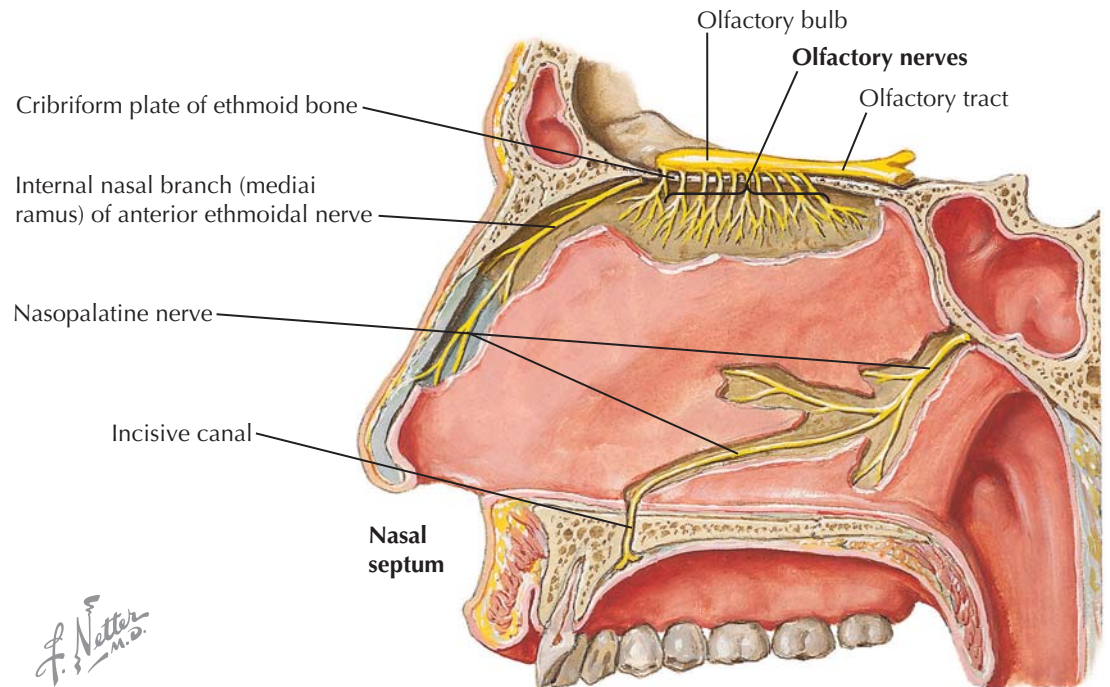
potential is converted to a digital action potential, which is conducted via the axon of the olfactory cell to the brain.

*Sense of Smell.* As with taste fibers, which may respond to a variety of taste stimuli, individual olfactory nerve fibers respond to a number of different odors. Humans differentiate the odors of thousands of chemicals; nevertheless, it has not been possible to identify a set of primary odor qualities analogous to the four primary tastes.

**OLFACTORY PATHWAY**

*Olfactory Bulb.* About 100 million olfactory afferent fibers enter the olfactory bulb, a flattened, oval mass lying near the lateral margin of the cribriform plate of the ethmoid bone. The incoming olfactory fibers coalesce in the outermost layer of the olfactory bulb to form presynaptic nests, or glomeruli. Each glomerulus is composed of about 25,000 receptor cell axon terminals. The terminals synapse and excite the dendrites of mitral and tufted cells, which are the second-order neurons in the olfactory bulb. Each mitral cell sends its dendrite to only a single glomerulus, while each tufted cell sends dendrites to several glomeruli. Olfactory afferents within the glomeruli also activate periglomerular cells, which then inhibit mitral and tufted cells. Further inhibition arises at the dendrodendritic contacts between mitral and tufted cells and the processes of granule cells, which lie deeper still within the olfactory bulb. These contacts are an example of two-way synaptic feedback connections: the granule cells are excited by mitral and tufted cells and, in turn, inhibit them. Integration of olfactory information occurs when excitation is spread throughout the multiple-branched granule cell processes, and also when granule cells are excited by the centrifugal efferent fibers that reach the olfactory bulb from higher centers. Another factor in this highly complex integrative process is the recurrent collaterals of mitral cells that appear to excite mitral, tufted, and granule cells.

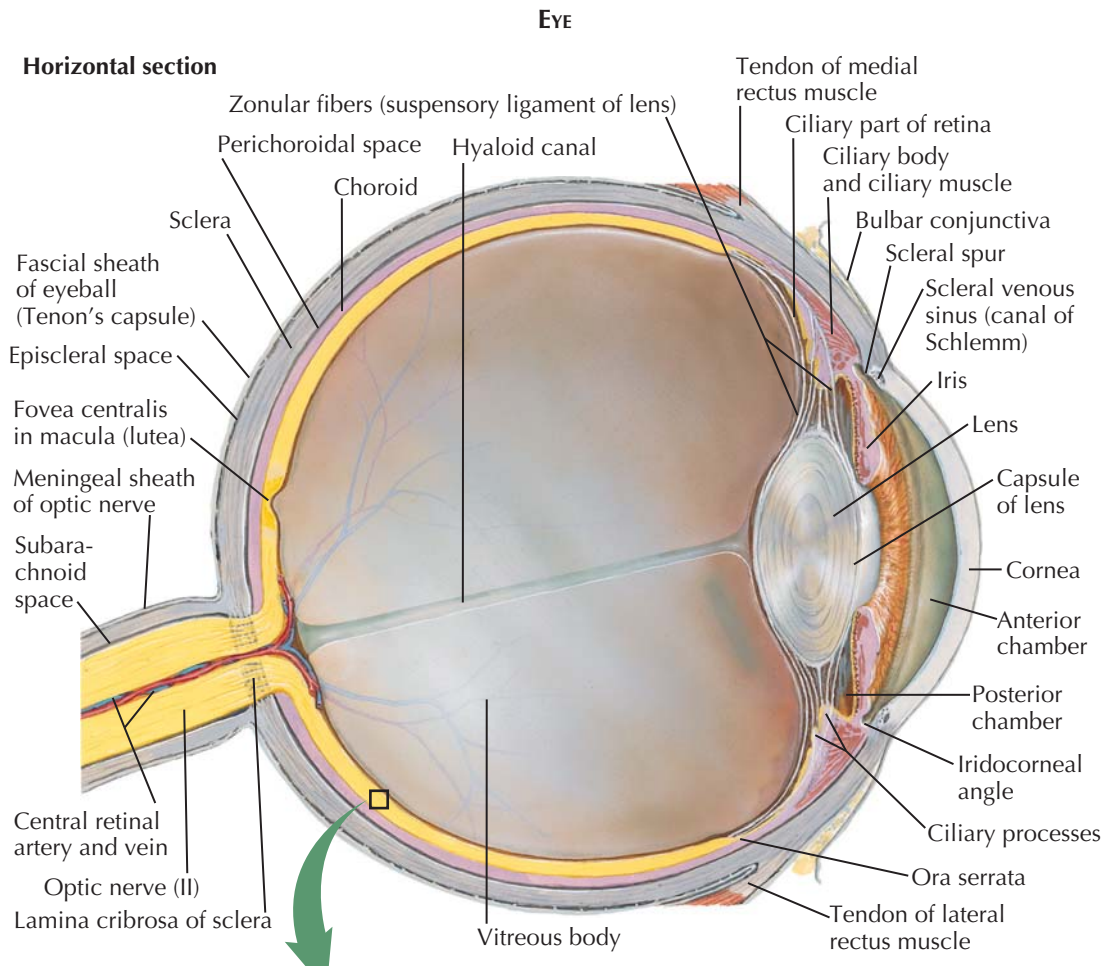
There is a dramatic transformation in the response to odors between the glomeruli and the mitral cells. The glomeruli respond to different substances based on their physicochemical properties, whereas mitral cells



respond to groups of substances that evoke subjective sensations.

*Olfactory Tract and Central Connections.* The axons of mitral and tufted cells form the olfactory tract, through which they project to the olfactory trigone and into the lateral and medial olfactory striae, establishing a complex pattern of central connections. Some mitral and tufted cell axons terminate in the anterior olfactory

nucleus (a continuation of the granule cell layer throughout the olfactory tract) and olfactory tubercle, the sites of origin of the efferent fibers projecting to both the ipsilateral and contralateral olfactory bulbs. Other axons from the lateral stria reach the piriform lobe of the temporal cortex and terminate in the amygdala (amygdaloid body), the septal nuclei, and the hypothalamus.



## CRANIAL NERVE II: OPTIC NERVE

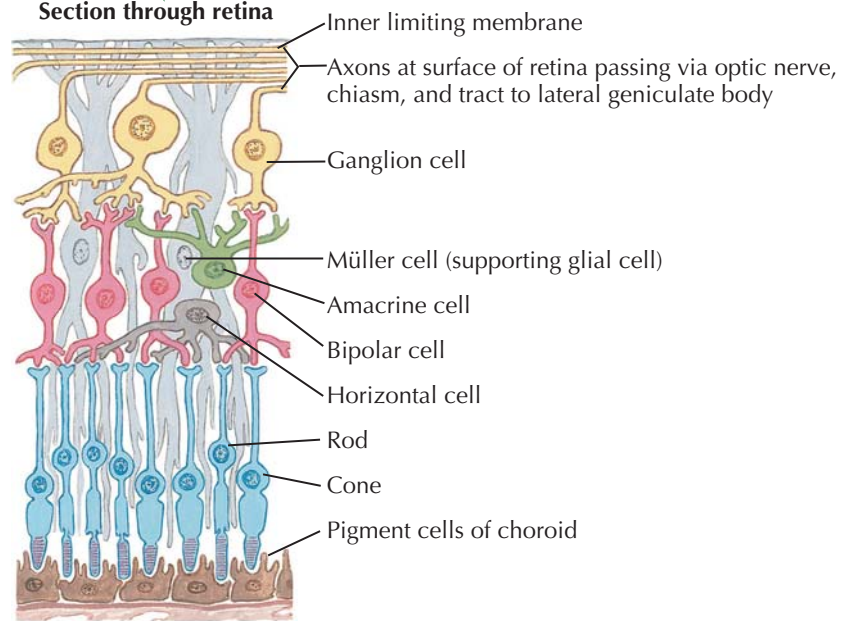
### HUMAN EYE

The human eye is a highly developed sense organ containing numerous accessory structures that modify visual stimuli before they reach the photoreceptors. The *extraocular muscles* move the eyeball, thus causing the image of the object viewed to fall on the *fovea*, the retinal area of highest visual acuity. The shape of the eyeball, its surfaces, and the refractive properties of the *tear film*, *cornea*, *lens*, and *aqueous* and *vitreous humors* assist in focusing the image on the retina. To allow viewing of near and far objects, this focus can be adjusted by the action of the *ciliary muscle*, which changes the shape of the lens. The intensity of the light reaching the retina is controlled by the muscles of the *iris*, which vary the size of the *pupillary aperture*. Incident light must traverse most of the retinal layers before it reaches the *photoreceptor cells* lying in the outer part of the retina. Beyond the photoreceptors is a layer of *pigment cells*, which eliminates back reflections by absorbing any light passing through the photoreceptor layer.

### RETINA

The retina has several distinct layers. *Rods* and *cones* form synaptic connections with bipolar and horizontal cells. *Bipolar cells* are relay neurons that transmit visual

### Section through retina

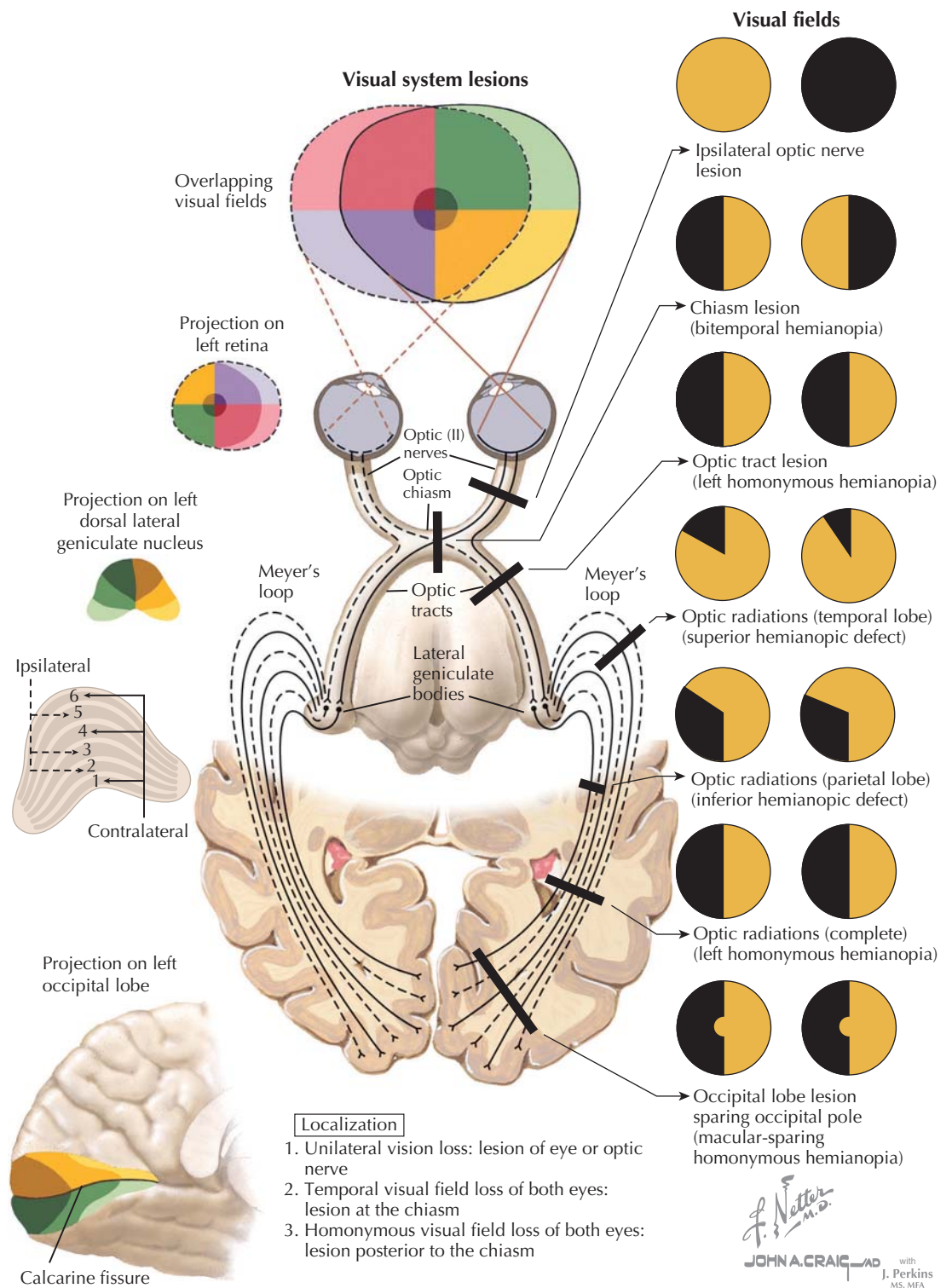


signals from the inner to the outer plexiform layer of the retina; *horizontal cells* are interneurons activated by rods and cones and send their axons laterally to act on neighboring bipolar cells. As a result of the actions of horizontal cells, bipolar cells have concentric receptive fields; that is, their membrane potentials are shifted in one direction by light reaching the center of their receptive field, and in the opposite direction by light

reaching the surrounding area. Neither bipolar nor horizontal cells generate action potentials; all information is transferred by changes in membrane potential, which spread passively through the cell bodies and axons.

The processes of bipolar cells that reach the outer plexiform layer form synapses with ganglion cells and amacrine cells. *Ganglion cells* are output neurons whose

CRANIAL NERVE II AND VISUAL PATHWAYS



**CRANIAL NERVE II: OPTIC NERVE** (Continued)

axons comprise the optic nerves and optic tracts; *amacrine cells* are interneurons. Unlike other retinal neurons, both amacrine and ganglion cells generate action potentials.

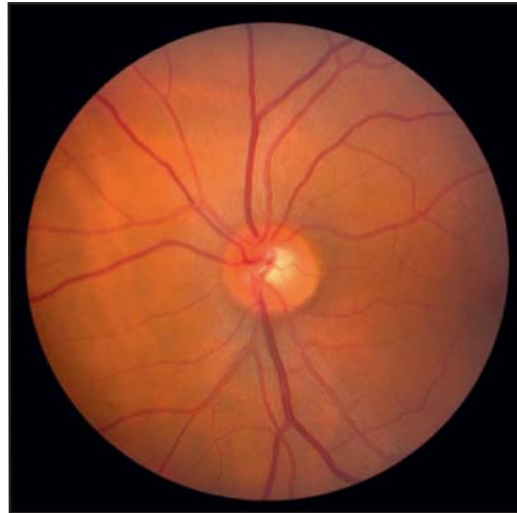The *photoreceptor cells* are called rods and cones because of the shapes of their outer segments. *Rods* function as receptors in a highly sensitive, monochromatic visual system, whereas *cones* serve as receptors in the color vision system, which is less sensitive but more acute. Both receptors, however, are activated in a similar manner—they are hyperpolarized by photons of light falling directly upon them. For example, the detection of light in the rod begins with the absorption of photons by the visual pigment, *rhodopsin*. Rhodopsin is a combination of the protein, opsin and the *cis* isomer of retinine, a compound derived from vitamin A. It is located within the membranous lamellae of the rod's outer segment, a highly modified cilium associated with a typical basal body. Upon the absorption of a photon, rhodopsin is converted to *lumirhodopsin*, which is unstable and changes spontaneously to *metarhodopsin*, which is then degraded by a chemical reaction known as bleaching. Rhodopsin lost by this bleaching process is restored to its active form by enzymatic reactions that require metabolic energy and vitamin A. After a brief time lag, the absorption of a photon leads to changes in the ionic permeability of the membrane of the outer

segment. The change in the receptor membrane triggered in the rod by light absorption is not the typical increase in ion permeability most sensory receptors undergo when activated; rather, there is a decrease in the permeability of the outer segment membrane to sodium ions ( $\text{Na}^+$ ). In the absence of light, this permeability is relatively high, and there is a steady inward flow of  $\text{Na}^+$  (the current flow resulting from this ionic movement, known as the "dark current," keeps the

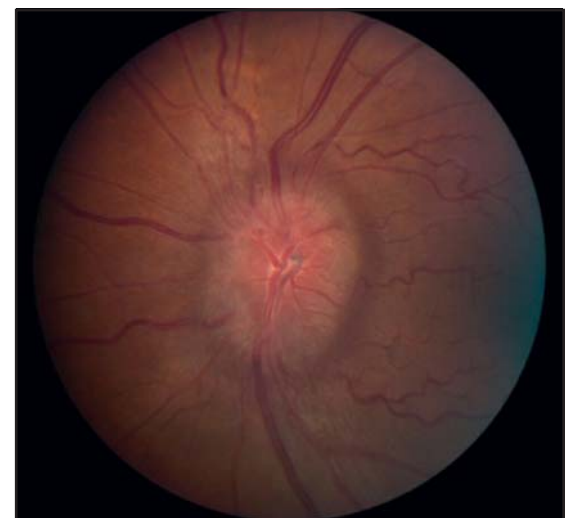entire rod in a depolarized state). When light absorption provokes a decrease in  $\text{Na}^+$  permeability, the dark current is cut off and the rod becomes more hyperpolarized. This hyperpolarization influences the synaptic action of the rod on horizontal and bipolar cells. Polarization changes in one rod may also spread to neighboring receptors via electrical synapses. Any photon that is successfully absorbed by photopigment produces the same electrochemical result, regardless of

*J. Netter M.D.*  
 JOHN A. CRAIG, MD with J. Perkins MS, MFA

## OPTIC NERVE APPEARANCE



Normal optic nerve



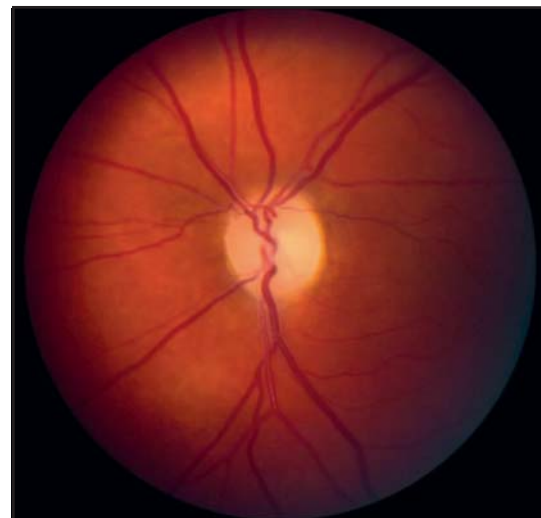Swollen optic nerve

## CRANIAL NERVE II: OPTIC NERVE (Continued)

the wavelength of that photon. However, the probability that a photon will be absorbed by photopigment varies considerably with the wavelength of the incident light, and rhodopsin has a maximal absorbency for light with a wavelength of 500 nm. Cones may contain one of three different photopigments, with a maximum absorbency at 445 nm (blue), 535 nm (green), and 570 nm (red). Cone pigments all contain *cis* retinene but have different forms of opsin, which modify the light absorption pattern. By analyzing the relative activity produced by the three types of cones, the central nervous system (CNS) is able to determine the wavelength of the incident light, and a sensation of color vision results.

### RETINOGENICULOSTRIATE VISUAL PATHWAY

In mammals, most retinal ganglion cells send excitatory or inhibitory impulses via the *optic nerves* and *tracts* to the *dorsal lateral geniculate nucleus* of the lateral geniculate body of the thalamus, from where retinal information is relayed to the primary visual cortex via the *geniculostriate projection*, or *optic radiations*. In man, this cortical area covers both walls of the posterior calcarine fissure and adjacent parts of the occipital pole (Brodmann's area 17). The transmission of information from retina to visual cortex is *topographically organized*. Stimuli



Pale optic nerve

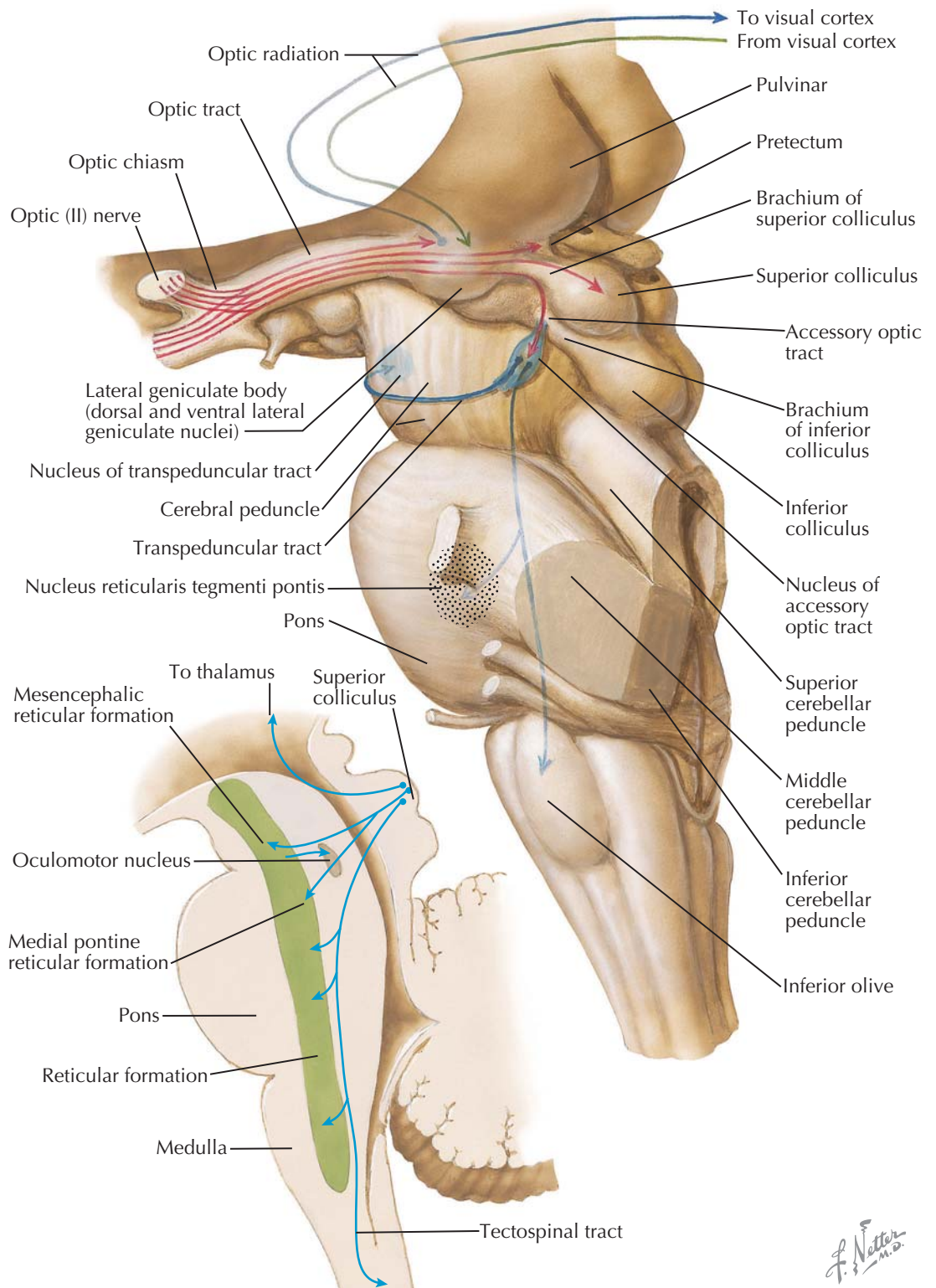
in the right half of the visual field activate neurons in the left half of each retina. Ganglion cells from these areas project to the left lateral geniculate body, which then projects to the left visual cortex. Input from both eyes is relayed by neurons in different layers of the lateral geniculate body. Similarly, stimuli in the left half of the visual field are relayed to the right visual cortex.

The upper and lower visual fields are also topographically mapped onto the lateral geniculate body and

visual cortex. The upper field is represented in the lateral parts of the lateral geniculate nuclei and the inferior portions of the visual cortex, and the lower visual field is represented in the corresponding medial and superior regions. The *macula* (central visual field) is represented in the central parts of the lateral geniculate nuclei and the posterior visual cortex, and in the *peripheral retina*, in the peripheral parts of the lateral geniculate nuclei, and the anterior visual cortex. The



RETINAL PROJECTIONS TO THALAMUS, MIDBRAIN, AND BRAINSTEM



**CRANIAL NERVE II: OPTIC NERVE** (Continued)

fovea, the central spot of the macula, is represented by a proportionally larger cortical area than the periphery of the retina.

**NEUROLOGIC DEFICITS OF THE RETINA AND OPTIC NERVE**

Neurologic deficits in the visual system can be localized by determining the type and extent of the resultant visual field deficit. Retinal and optic nerve damage produces vision loss in the affected eye. Most retinal lesions will be visible on ophthalmoscopy of the ocular fundus. Optic nerve lesions will produce central scotomas and visual field defects that might respect the horizontal meridian. If the optic nerve is affected in its anterior portion (i.e., where it is visualized on ocular funduscopy), one may see swelling of the optic nerve head during the acute phase of injury. If the retrobulbar portion of the optic nerve is the site of injury, then the optic nerve head (so-called “optic disc”) will look normal acutely. After several weeks, injury to the optic nerve anywhere along its course will manifest as relative pallor of the optic nerve head. Unilateral or asymmetric bilateral optic nerve damage will cause a relative afferent pupillary defect (less transmission of light along the more damaged optic nerve to the brain centers controlling pupillary constriction).

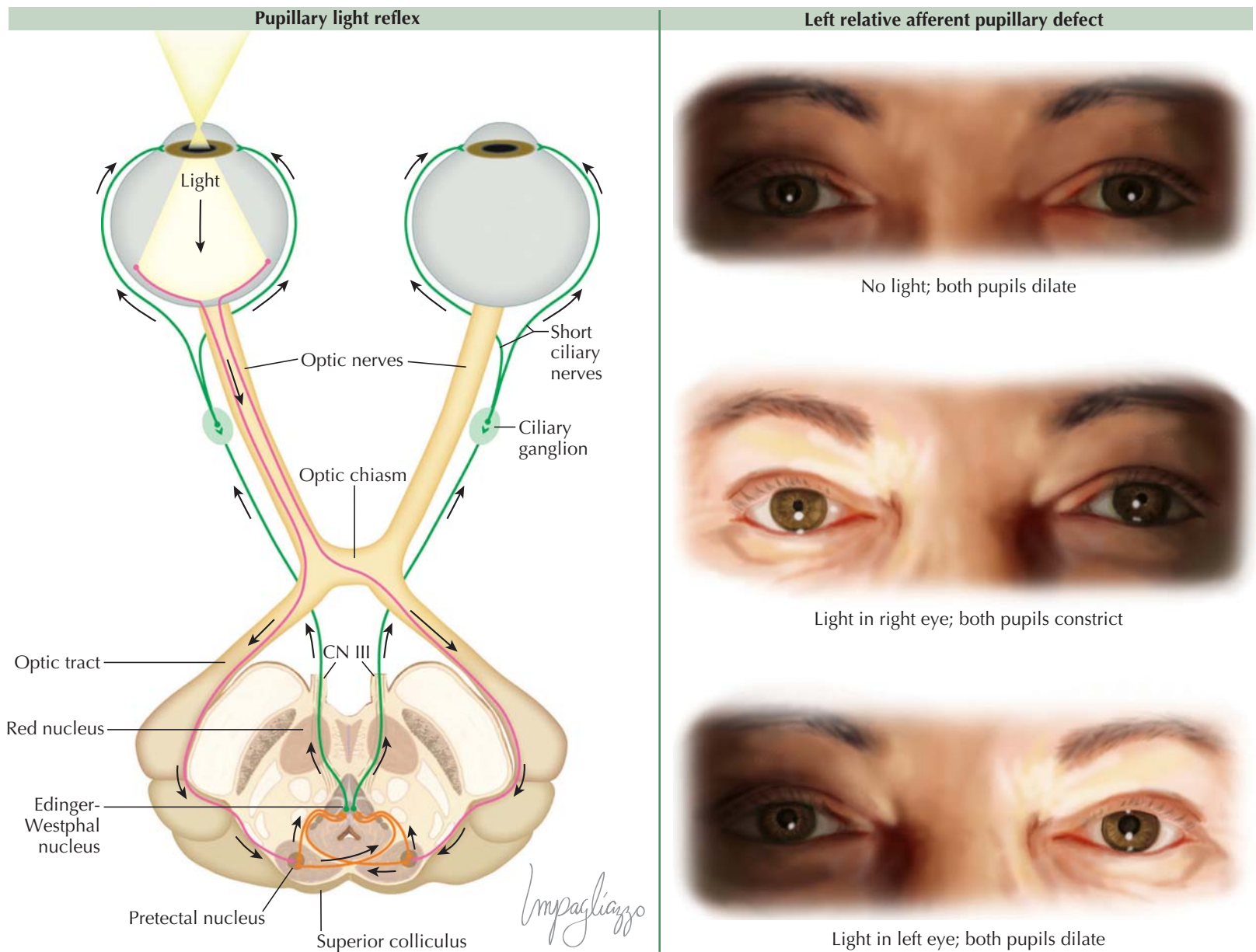
**CHIASMAL AND POSTCHIASMAL NEUROLOGIC DEFICITS**

Lesions at the optic chiasm will result in bitemporal hemianopsia, caused by damage to the fibers from the nasal segment of both retinas. Interruption of the optic tract (that portion of the visual pathways between the chiasm and lateral geniculate body) results in a contralateral homonymous hemianopsia. Similarly, lesions of

the optic radiations or striate cortex will cause partial or complete contralateral homonymous hemianopic defects.

**VISUAL SYSTEM: RETINAL PROJECTIONS**

The main retinal projection is to the *dorsal lateral geniculate nucleus*, which then projects to the visual cortex. The retinogeniculostriate system thus formed is



**CRANIAL NERVE II: OPTIC NERVE** (Continued)

the basis for essentially the entire visual consciousness in man.

Other optic nerve fibers terminate within the *superior colliculus*. This multilayered structure plays an important role in orienting the reactions that shift the head and eyes in order to bring an object of interest into the center of the visual field. In addition to direct optic nerve input, the superior colliculus receives indirect visual input via the visual cortex. As is the case throughout the visual system, this input is topographically organized so that each point within the colliculus corresponds to a particular region within the visual field. Collicular neurons tend to respond best to interesting or moving stimuli, and the discharge of neurons in the deeper layers of the colliculus is closely related to the orienting movements of the eyes evoked by such stimuli.

The deeper collicular layers are the source of several efferent projections. One group of fibers crosses the

midline and runs caudally, sending terminals to the brainstem reticular formation and then continuing on to cervical and thoracic levels as the *tectospinal tract*; these fibers are probably involved in the orienting movements of the head and body. A second group of fibers projects to the posterior thalamus (pulvinar), which then projects to the cortical association areas. Fiber projections responsible for eye movements relay in the mesencephalic reticular formation below the superior colliculus (vertical eye movements), and in the paramedian pontine reticular formation (horizontal eye movements).

**PUPILLARY LIGHT REFLEX AND THE ACCOMMODATION REFLEX**

The *pretectum*, like the superior colliculus, receives visual information from optic nerve fibers not destined to synapse in the lateral geniculate bodies. This area is involved in the pupillary light reflex (which regulates the size of the pupil) and the accommodation reflex

(which controls the degree of curvature of the lens). The former is a subcortical reflex and relays in the accessory oculomotor (Edinger-Westphal) nucleus, whereas the latter involves pathways through the cerebral cortex. In the pupillary light reflex, afferent pupillary fibers leave the optic tract before the lateral geniculate bodies, travel in the brachium of the superior colliculus, and synapse in the pretectal nuclei (explaining why lesions of the geniculate bodies, the optic radiations, or the visual cortex do not affect the pupillary reactivity, and why lesions of the brachium of the superior colliculus can cause a relative afferent pupillary defect without causing a visual field defect). Both pretectal nuclei receive input from both eyes, and each sends axons to both Edinger-Westphal nuclei. Parasympathetic fibers for pupillary constriction leave the Edinger-Westphal nucleus and travel along the ipsilateral third cranial nerve to the ipsilateral ciliary ganglion within the orbit. The postganglionic parasympathetic fibers innervate the pupillary constrictor muscle and the ciliary muscle for accommodation.

OCULOMOTOR (III), TROCHLEAR (IV), AND ABDUCENS NERVES (VI)

**CRANIAL NERVES III, IV, AND VI (OCULOMOTOR, TROCHLEAR, AND ABDUCENS)**

**OCULOMOTOR NERVE**

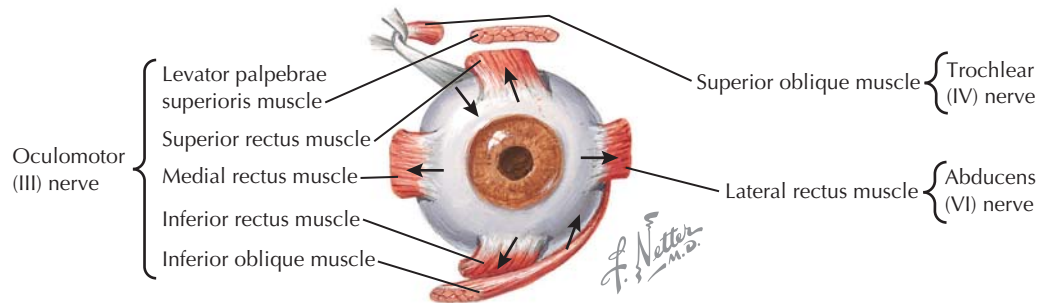
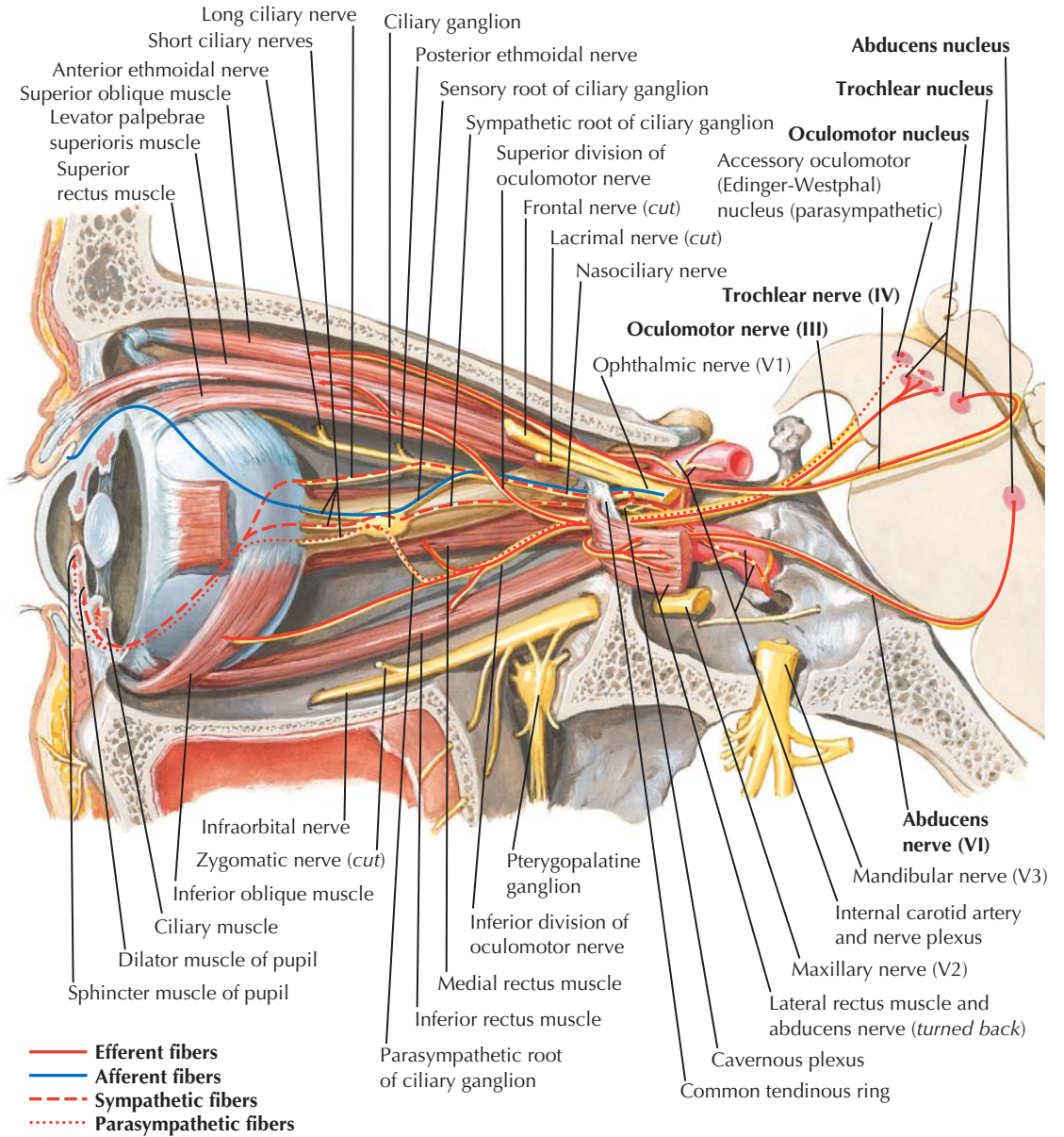
The oculomotor nerve carries somatic motor fibers to the levator palpebrae superioris muscle and to the medial, superior, and inferior rectae muscles, and to the inferior oblique muscle. It also conveys important parasympathetic fibers to intraocular structures, such as the sphincter pupillae and ciliary muscles, and is joined by sympathetic fibers from the internal carotid plexus, which are distributed with its branches. Some oculomotor proprioceptive fibers may reach the midbrain through the oculomotor nerve; most of them join the ophthalmic branch of the trigeminal nerve via its communications with the oculomotor nerve.

**Oculomotor Nuclei.** The somatic and parasympathetic efferent fibers in the oculomotor nerve are the axons of cells located in the complex oculomotor nuclei situated anterolateral to the upper end of the cerebral aqueduct. The nuclei are composed of groups of large and small multipolar cells. The main groups of large cells are arranged in two columns of *posterolateral*, *intermediate*, and *anteromedial nuclei*, one on each side of the midline, which control the rectus and oblique extraocular muscles. A single *median nucleus*, composed of similar cells and partly overlying the caudal and posterior aspects of the bilateral columns, controls the levator muscles of the upper eyelids. Cranial to the median nucleus, and also partially overlying the posterior aspects of the main bilateral columns, are two narrow, wing-shaped nuclei, which are interconnected across the midline at their cranial ends—the *accessory (autonomic) nuclei (Edinger-Westphal)*. They are the source of parasympathetic preganglionic fibers for the ciliary ganglion. The multiple subnuclei of the oculomotor nucleus each project ipsilaterally via the oculomotor nerve to the individual muscles that they innervate, with the exception of the superior rectus subnucleus, which projects contralaterally via the contralateral oculomotor nerve to the contralateral superior rectus muscle.

**Oculomotor Nerve.** The axons from the bilateral oculomotor nuclear cells form minute bundles, which run through the mesencephalic tegmentum, traversing the red nuclei to emerge from the mesencephalic oculomotor sulcus as the oculomotor nerve rootlets.

Each *oculomotor nerve* runs forward between the posterior cerebral and superior cerebellar arteries and lateral to the posterior communicating artery in the interpeduncular subarachnoid cistern. It pierces the arachnoid and dura mater in the angle between the free and attached margins of the tentorium cerebelli to enter first the roof of the cavernous sinus and then its lateral wall. Continuing forward above the trochlear nerve, the oculomotor nerve divides into superior and inferior rami as it enters the orbit through the superior orbital fissure.

The smaller *superior division* supplies the superior rectus muscle and the main superficial (voluntary, or striated, muscular) lamina of the levator palpebrae superioris. The deep lamina is a tenuous layer of involuntary, or unstriated, fibers—the superior tarsal muscle; a similar but even more tenuous inferior tarsal muscle



is present in the lower eyelid, and both these tarsal muscles are innervated by sympathetic fibers. The larger *inferior division* supplies the medial and inferior recti and the inferior oblique muscles.

**CILIARY GANGLION**

The ciliary ganglion is tiny and lies in the posterior part of the orbit between the optic nerve and the lateral

rectus muscle. Only the first of its three roots is constant because the sensory and/or sympathetic roots may bypass the ganglion.

**Motor Root.** The ciliary ganglion is the relay station for preganglionic *parasympathetic fibers*, which originate in the accessory (autonomic) oculomotor nucleus and reach the ganglion through a short offshoot from the oculomotor branch to the inferior oblique muscle. The postganglionic fibers form the 12 to 20 delicate *short*

NERVES OF ORBIT AND CAVERNOUS SINUS

**CRANIAL NERVES III, IV, AND VI (OCULOMOTOR, TROCHLEAR, AND ABDUCENS)** (Continued)

*ciliary nerves* that penetrate the sclera around the optic nerve and continue forward in the perichoroidal space to supply the ciliaris and sphincter pupillae muscles and the intraocular vessels.

The *sensory and sympathetic roots* of the ciliary ganglion are derived from the nasociliary nerve and the internal carotid vascular nerve plexus, but they do not always join the ganglion. Instead, their fibers may reach the eye by joining the ciliary nerves directly, while the *sympathetic fibers* (already postganglionic after relaying in the superior cervical trunk ganglia) may follow the ophthalmic artery and its branches to their destinations. The *sensory fibers* convey impulses from the cornea, iris, and choroid and the intraocular muscles.

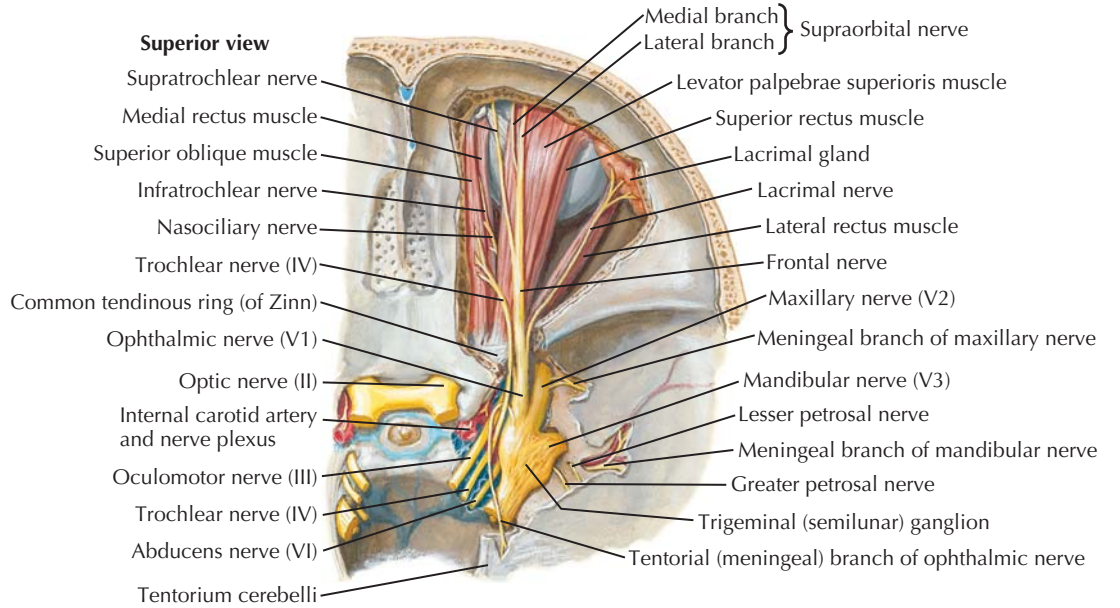
**TROCHLEAR NERVE**

The trochlear nerve is slender, and its nucleus of origin is located in the midbrain just caudal to the oculomotor nuclei. The trochlear fibers curve posterolaterally and slightly caudally around the cerebral aqueduct to reach the upper part of the superior medullary velum; here the nerve fibers from opposite sides decussate before emerging on either side of the frenulum veli, below the inferior colliculi. No other cranial nerves emerge from the dorsal aspect of the brainstem.

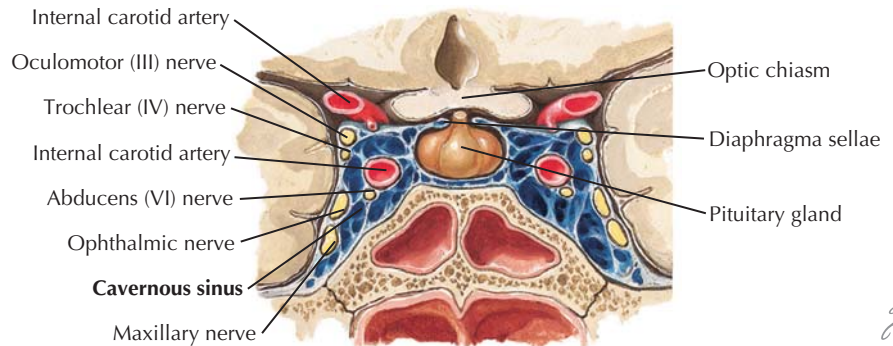
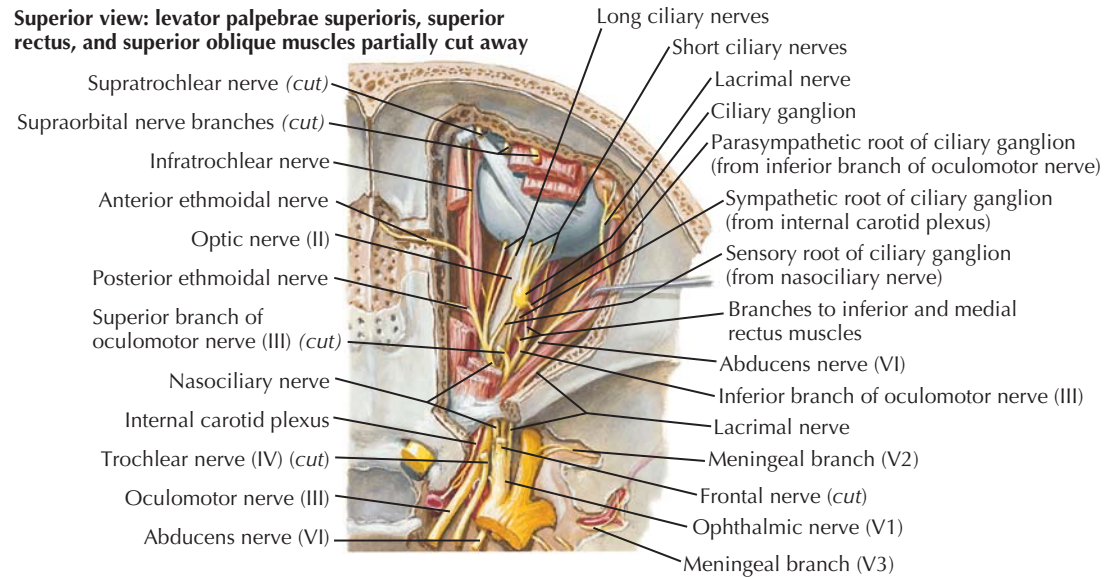
Each trochlear nerve winds forward around the midbrain below the free edge of the tentorium cerebelli, passes between the superior cerebellar and posterior cerebral arteries and above the trigeminal nerve, and pierces the inferior surface of the tentorium near its attachment to the posterior clinoid process to run forward in the lateral wall of the cavernous sinus between the oculomotor and ophthalmic nerves. The nerve enters the orbit through its superior fissure, immediately lateral to the common annular tendon, and passes medially between the orbital roof and the levator palpebrae superioris to supply the *superior oblique muscle*. Proprioceptive fibers are transferred through a communication with the ophthalmic nerve to the trigeminal nerve. The trochlear nerve usually receives sympathetic filaments from the internal carotid nerve plexus.

**ABDUCENS NERVE**

The abducens nerve arises from the abducens nucleus, which is located in the pons, subjacent to the facial colliculus in the upper half of the floor of the fourth ventricle. The nucleus is encircled by fibers of the homolateral facial nerve. The abducens nerve fibers pass forward to emerge near the midline through the groove between the pons and the pyramid of the medulla oblongata. Each abducens nerve then inclines



Superior view: levator palpebrae superioris, superior rectus, and superior oblique muscles partially cut away

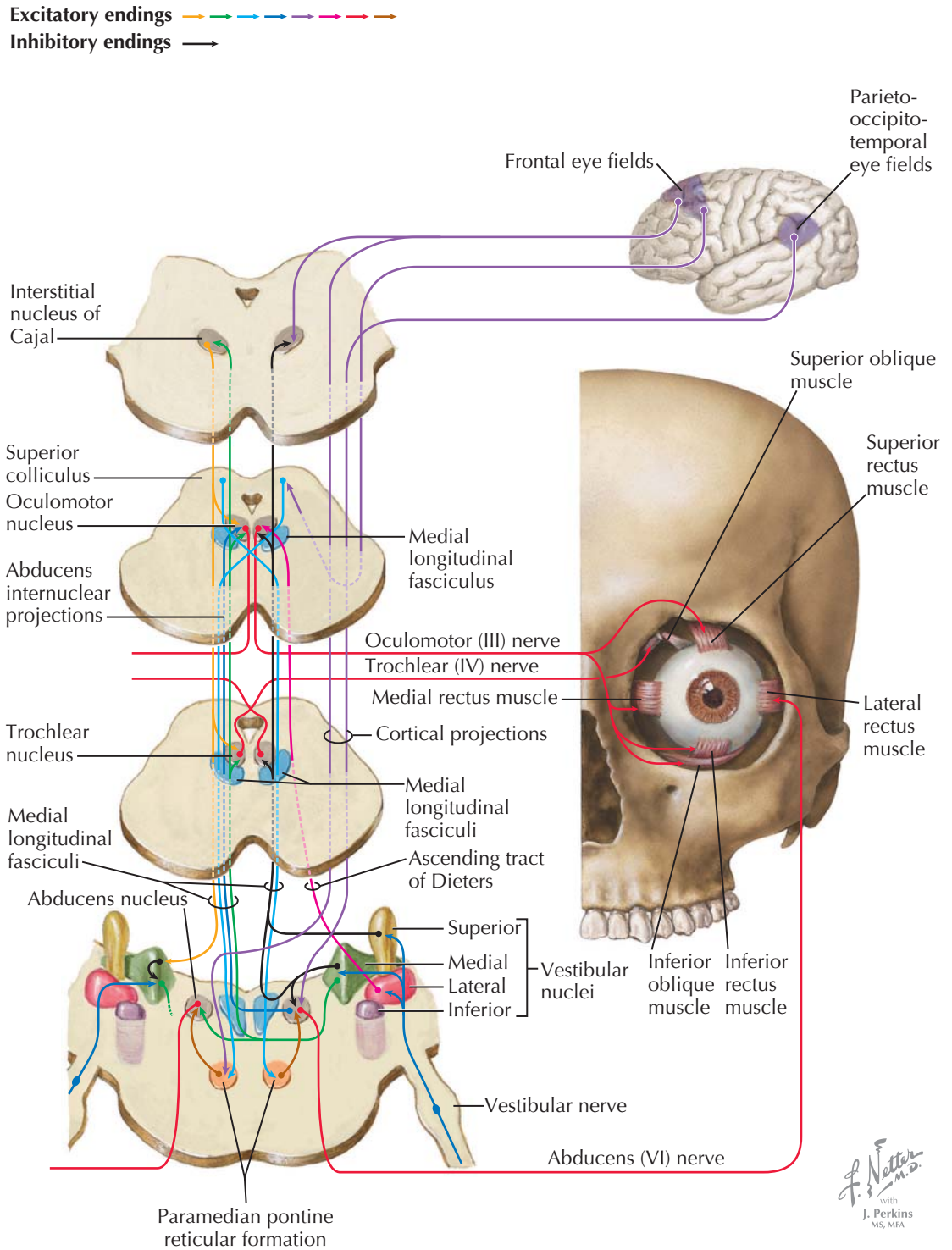


upward in front of the pons, usually behind the inferior cerebellar artery. Near the apex of the petrous part of the temporal bone, the nerve bends sharply forward above the superior petrosal sinus to enter the cavernous sinus, where it lies adjacent to the internal carotid artery. There the abducens may transfer proprioceptive fibers to the ophthalmic branch of the trigeminal nerve and receive sympathetic filaments from the internal carotid nerve plexus. The abducens nerve enters the

orbit through the superior orbital fissure, within the common annular tendon, and ends by supplying the *lateral rectus muscle*.

The abducens has a relatively long intracranial route in the posterior cranial fossa and cavernous sinus. Consequently, it is vulnerable to increases in intracranial pressure and to pathologic or traumatic lesions affecting nearby parts of the brain, skull, or sinus.

*F. Netter M.D.*



**CONTROL OF EYE MOVEMENTS**

The extraocular muscles responsible for eye movements are controlled by motor neurons located in various nuclei. Thus the lateral rectus is controlled by the abducens nucleus, the superior oblique by the trochlear nucleus, and the superior, inferior, and medial recti and the inferior oblique muscles by the oculomotor nucleus. Both smooth (pursuit) and rapid (saccadic) eye movements depend on patterns of activity produced in these muscles by direct projections from the vestibular nuclei and the reticular formation, and by indirect activation from the superior colliculus and the cerebral cortex.

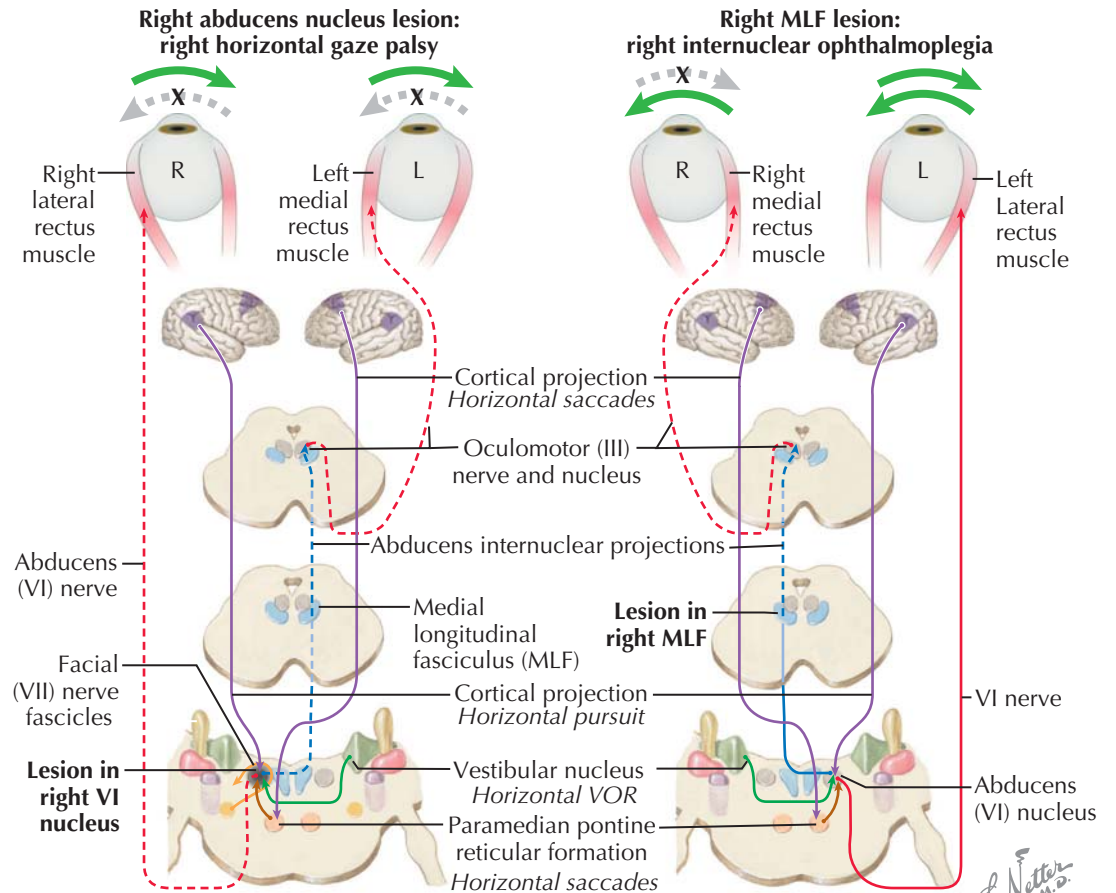
The *medial* and *lateral rectus muscles* move the eyeball horizontally, causing the cornea to look medially or laterally. The actions of the superior and inferior rectus muscles and those of the oblique muscles are more complicated. The *superior* and *inferior rectus muscles* move the eyeball upward and downward, respectively. Because they are disposed at an angle of about 20 degrees to the sagittal plane (due to the long axis of each orbit being directed slightly outward), they also impart a minor degree of rotation to the eyeball (intorsion for the superior rectus and extorsion for the inferior rectus). When the eyeball is abducted, the superior and inferior rectus muscles purely elevate and depress the eyeball. The *inferior oblique muscle* rotates the eyeball outward (excyclotorsion) and elevates the eyeball when it is adducted. However, an exact idea of the actions of the extrinsic eye muscles cannot be obtained by considering each muscle separately because, under normal circumstances, none of the six extraocular muscles acts alone. Consequently, all eye movements are the result of highly integrated and delicately controlled agonist and antagonist activities. The actions of individual muscles have been determined from studies of congenital defects or from functional disturbances caused by disease or injury to the nerve supply.

**VESTIBULAR PROJECTIONS IMPORTANT FOR VISUAL FIXATION**

The vestibular projection is important for the maintenance of visual fixation during head movements. To effect smooth movement, tracking, and proper visualization, the contraction of one eye muscle must be accompanied by the relaxation of its antagonist. The

action of turning the head excites *vestibular afferent fibers* from semicircular canal receptors. Fibers from an individual semicircular canal excite two specific groups of relay neurons in the *vestibular nuclei*. One group excites the extraocular motor neurons that cause the eyes to move in the direction opposite to the head movement, and the other group inhibits motor neurons that activate movement of the eyes in the same direction as the

*F. Netter M.D.*  
with  
J. Perkins  
MS, MFA

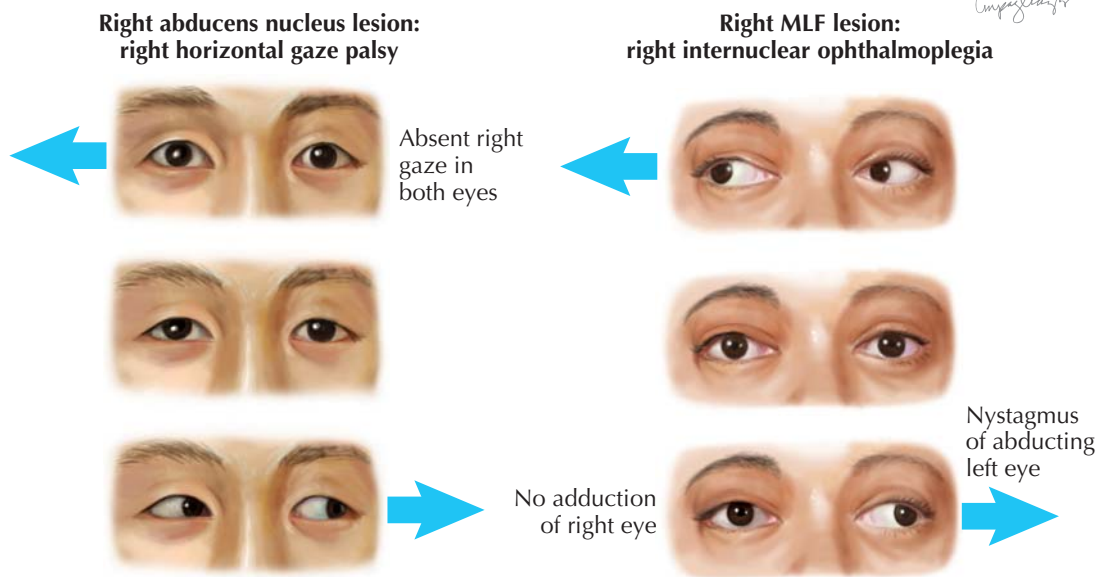


**CONTROL OF EYE MOVEMENTS**  
(Continued)

head. For example, turning the head to the right will excite fibers from the right horizontal semicircular canal, which, in turn, will activate neurons in the right medial and lateral vestibular nuclei. Some of these vestibular neurons will then excite motor neurons controlling the right medial and left lateral rectus muscles. Other vestibular neurons will inhibit motor neurons controlling the right lateral rectus and internuclear neurons controlling the left medial rectus. The result will be a compensatory movement of both eyes to the left. The vestibulocerebellum modulates the vestibulo-oculomotor reflex in such a way that the resulting eye movement precisely compensates for the head movement and thus keeps the gaze fixed on the same point.

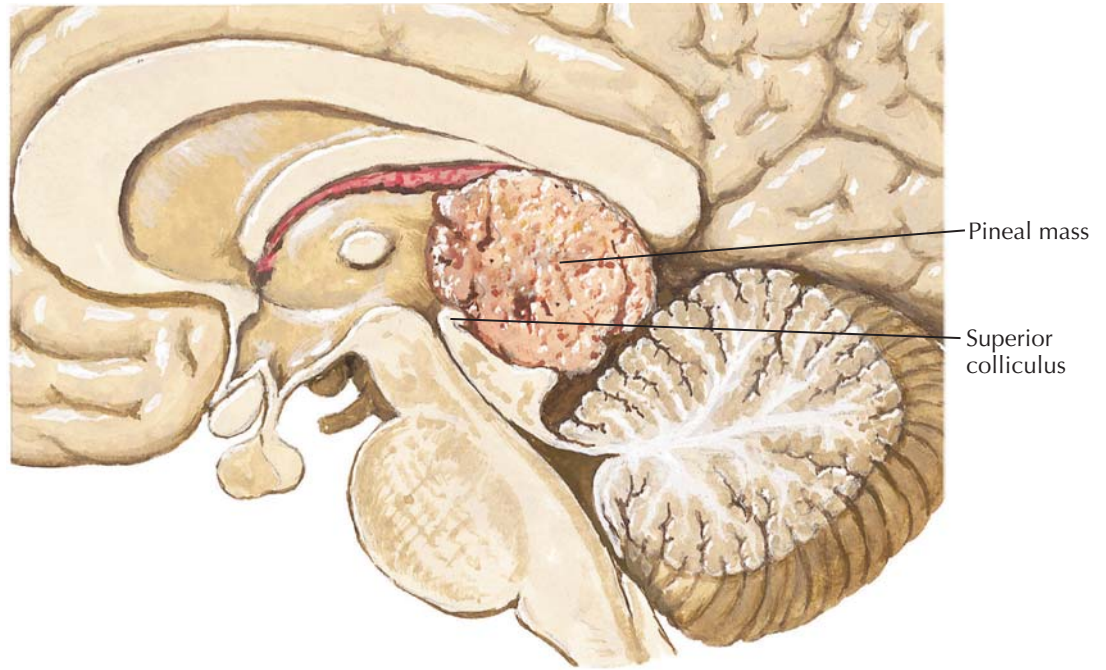
The connections of the right vestibular nuclei to the *abducens*, *trochlear*, and *oculomotor nuclei* can be divided into two sections. The first section comprises vestibular projections to motor neurons supplying the superior and inferior rectus and superior and inferior oblique muscles. These motor neurons all receive excitatory input from the contralateral medial nucleus and inhibitory input from the ipsilateral superior nucleus. The innervation of medial and lateral rectus motor neurons, which mediate horizontal eye movements, is organized differently. The medial vestibular nucleus sends excitatory fibers to the contralateral abducens nucleus and inhibitory fibers to the ipsilateral abducens nucleus. These fibers excite or inhibit the lateral rectus motor neurons and another group of neurons within the abducens nucleus, the internuclear neurons, which project to the opposite oculomotor nucleus to excite the medial rectus motor neurons. The latter neurons are also excited by fibers that originate in the lateral vestibular nucleus and pass upward in the ascending tract of Deiters.

In addition to the pathways described above, each ocular motor nucleus also receives input for saccadic



and pursuit eye movements that do not involve the vestibular nuclei. These pathways ultimately converge on the final common pathways for horizontal and vertical ocular motor control also used in the vestibulo-ocular system, but initially via different anatomic pathways. For example, saccadic eye movements (fast conjugate eye movements to a fixed target, either voluntary or reflex in origin) are initiated in the frontal and parietal lobes. The horizontal saccade pathway is a

crossed pathway. Pathways from the frontal and parietal eye fields descend via the superior colliculus into the brainstem and cross at the level of the midbrain-pontine junction to synapse on the contralateral paramedian pontine reticular formation. The paramedian pontine reticular formation projects to the ipsilateral abducens nucleus, from which abducens neurons project to the ipsilateral lateral rectus muscle, whereas abducens interneurons project cross the midline to ascend in the

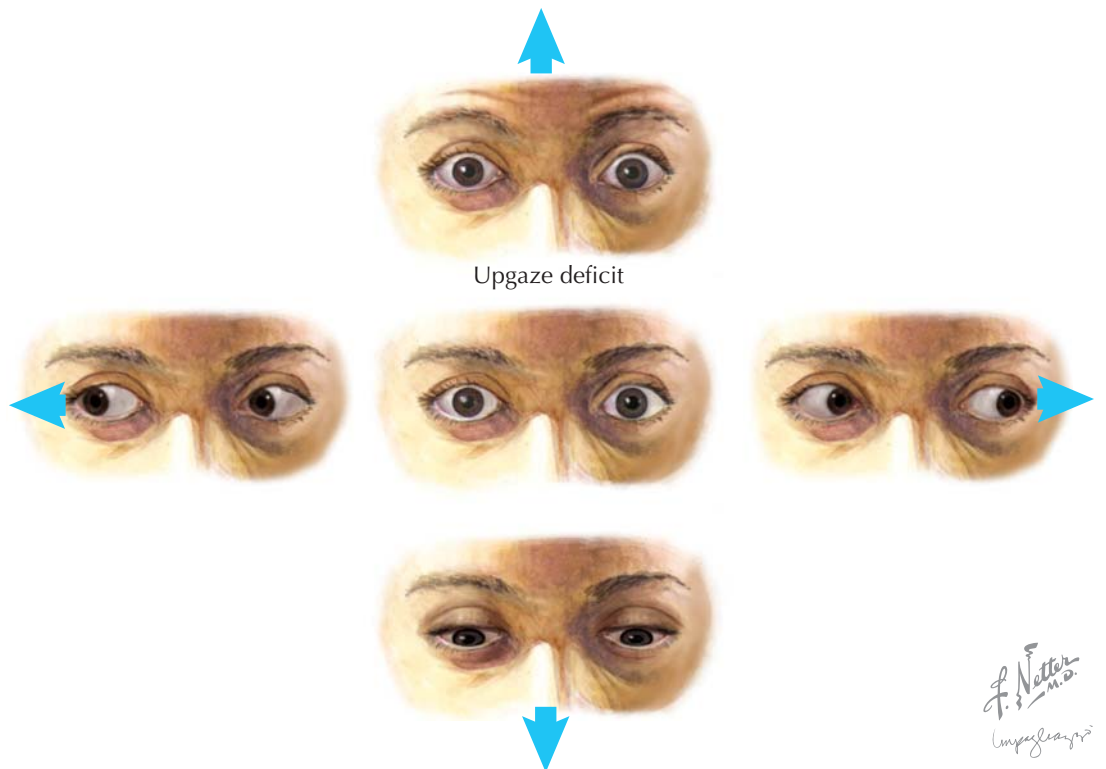


**CONTROL OF EYE MOVEMENTS**

*(Continued)*

contralateral medial longitudinal fasciculus and synapse on the medial rectus subnucleus of the contralateral oculomotor nucleus. The pathways for vertical saccades involve the rostral interstitial nucleus of the medial longitudinal fasciculus, the interstitial nucleus of Cajal, the posterior commissure, and the nucleus of the posterior commissure.

In contrast to the saccadic pathways, the pathways for horizontal smooth pursuit (conjugate maintenance of fixation of the eyes while following a moving target) descend ipsilaterally from cortical centers of eye movement control to synapse directly on the abducens nucleus, and from there to the ipsilateral abducens nerve and lateral rectus and the contralateral oculomotor nerve and medial rectus. This internuclear connection between the abducens nucleus and the contralateral oculomotor nucleus via the medial longitudinal fasciculus is the final common pathway responsible for conjugate horizontal gaze, whether initiated reflexively via the vestibulo-ocular system or voluntarily via the saccadic or pursuit systems.



Posterior midbrain syndrome (with upgaze palsy and lid retraction) secondary to a pineal mass

**NEUROLOGIC DEFICITS**

Eye movement disorders from brainstem involvement of the pathways subserving horizontal and vertical gaze are usually exquisitely localizing. For example, a lesion in the right abducens nucleus will cause a complete loss of gaze of either eye toward the right (usually with an associated ipsilateral lower motor neuron facial palsy because the fascicles of the facial nerve wrap around the abducens nucleus before exiting the brainstem), whereas a lesion of just to the right paramedian pontine reticular formation will cause an absence of voluntary and reflex saccades to the right, with relative preservation of the vestibulo-ocular reflex (VOR) and pursuit eye movements. A lesion of the right medial longitudinal

fasciculus will disrupt only the abducens interneuron projections, and therefore the patient will have all eye movements intact except for poor adduction of the right eye (poor movement of the right eye toward the nose), a so-called internuclear ophthalmoplegia.

Vertical gaze may be selectively abnormal, with lesions in the midbrain and pretectal area, especially from compression from above, such as typically seen

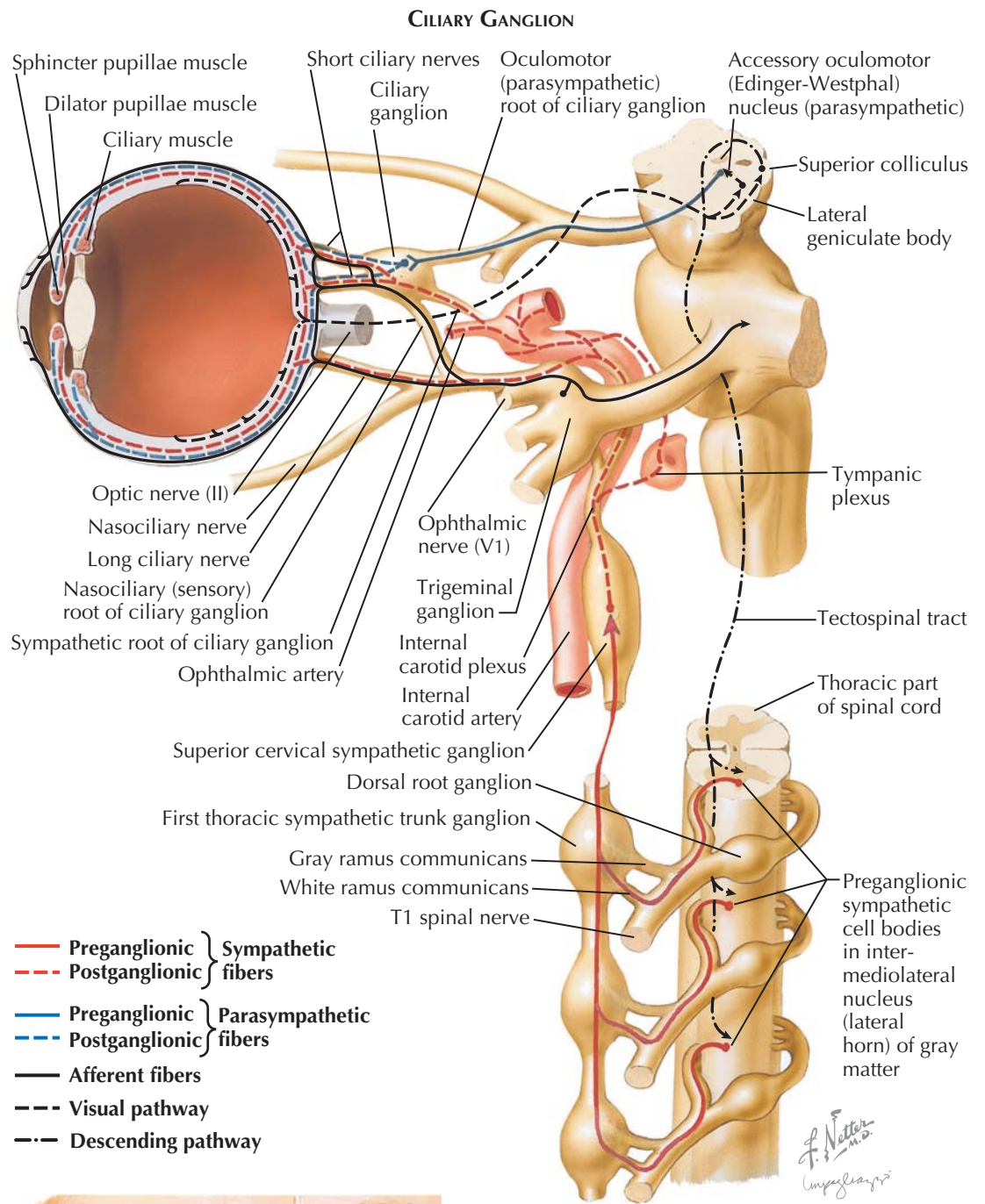
with pineal tumors. If the posterior commissure is primarily involved, these patients may have selective absence of upward eye movements with preservation of all other eye movements. Associated clinical abnormalities include upper lid retraction and nonreactive pupils to light with intact pupillary constriction when viewing a near target (all part of the so-called dorsal midbrain syndrome).

## AUTONOMIC INNERVATION OF THE EYE

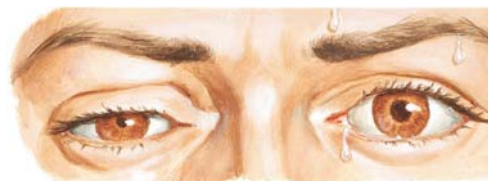**Sympathetic Fibers.** The sympathetic *preganglionic* fibers for the eye emerge in the ipsilateral first and second, and occasionally in the third, thoracic spinal nerves. They pass through white or mixed rami communicantes to the sympathetic trunks in which the fibers ascend to the superior cervical ganglion, where they relay, although a proportion may form synapses higher up in the internal carotid ganglia. The *postganglionic* fibers run either in the internal carotid plexus and reach the eye in filaments that enter the orbit through its superior fissure, or else they run alongside the ophthalmic artery in its periarterial plexus.

Some of the filaments passing through the superior orbital fissure form the *sympathetic root of the ciliary ganglion*; their contained fibers pass through it without relaying to become incorporated in the 8 to 10 *short ciliary nerves*. Other filaments join the ophthalmic nerve or its nasociliary branch and reach the eye in the two to three *long ciliary nerves* that supply the radial musculature in the iris (dilator pupillae). Both long and short ciliary nerves also contain afferent fibers from the cornea, iris, and choroid. Fibers conveyed in the short ciliary nerves pass through a communicating ramus from the ciliary ganglion to the nasociliary nerve; this ramus is called the *sensory root of the ciliary ganglion*. The parent cells of these sensory fibers are located in the trigeminal (semilunar) ganglion, and their central processes end in the *sensory trigeminal nuclei* in the brainstem. The sensory trigeminal nuclei have multiple interconnections with other somatic and autonomic centers and thus influence many reflex reactions. Other sympathetic fibers from the internal carotid plexus reach the eye through the ophthalmic periarterial plexus and along its subsidiary plexuses around the central retinal, ciliary, scleral, and conjunctival arteries.

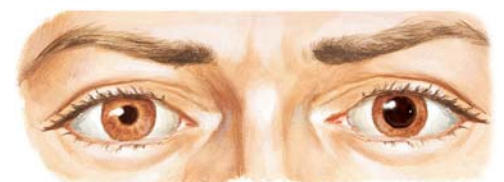**Parasympathetic Fibers.** The parasympathetic preganglionic fibers for the eye are the axons of cells in the *accessory, or autonomic, (Edinger-Westphal) oculomotor nucleus*. They run in the third cranial nerve and exit in the *motor root of the ciliary ganglion*, where they relay. The axons of these ganglionic cells are postganglionic parasympathetic fibers, which reach the eye in the *short*



- Preganglionic } Sympathetic
- - - Postganglionic } fibers
- Preganglionic } Parasympathetic
- - - Postganglionic } fibers
- Afferent fibers
- - - Visual pathway
- · - · - Descending pathway



Interruption of the sympathetic fibers causes ipsilateral ptosis, anhidrosis, and miosis without abnormal ocular motility (Horner syndrome)



Left dilated pupil with no other sign

*ciliary nerves* and are distributed to the constrictor fibers of the iris (sphincter pupillae), to the ciliary muscle, and to the blood vessels in the coats of the eyeball.

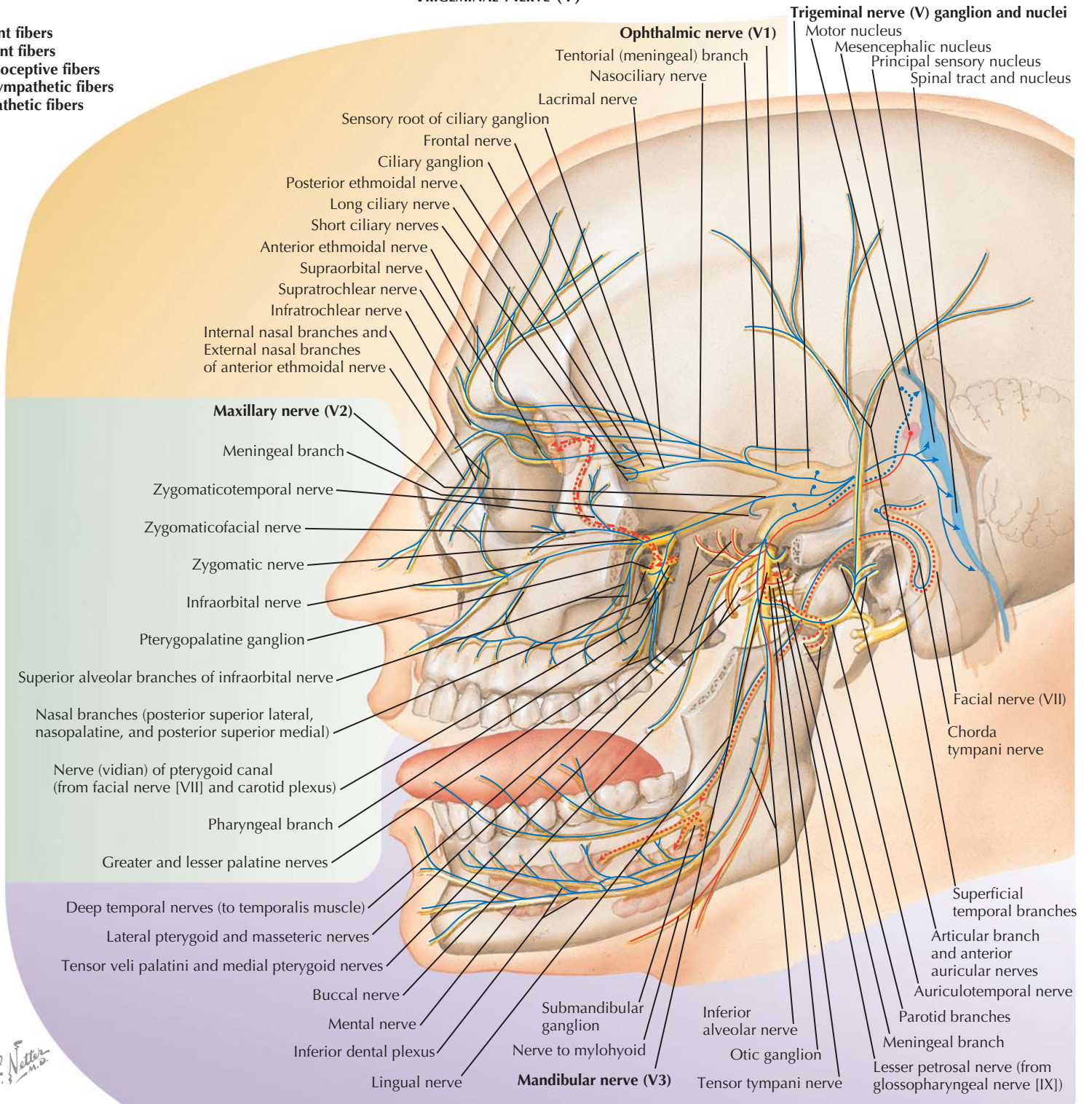
**Neurologic Disorders.** Disruption of the sympathetic innervation to the eye at any level along the sympathetic pathways will result in a Horner syndrome, in which the pupil on the involved side is smaller and dilates poorly, especially notable in the dark, and the upper lid droops slightly (ptosis). Depending on where

the sympathetic chain is disrupted, there may also be loss of sweating on the ipsilateral face. A lesion of the ciliary ganglion will cause disruption of the parasympathetic fibers to the pupillary constrictor muscle, and there will be isolated enlargement of the ipsilateral pupil, especially notable in lighted conditions, but no findings such as ptosis or extraocular muscle weakness to suggest a lesion along the course of the oculomotor nerve.



TRIGEMINAL NERVE (V)

- Efferent fibers
- Afferent fibers
- ⋯ Proprioceptive fibers
- ⋯ Parasympathetic fibers
- ⋯ Sympathetic fibers



**CRANIAL NERVE V:  
TRIGEMINAL NERVE**

**ANATOMY**

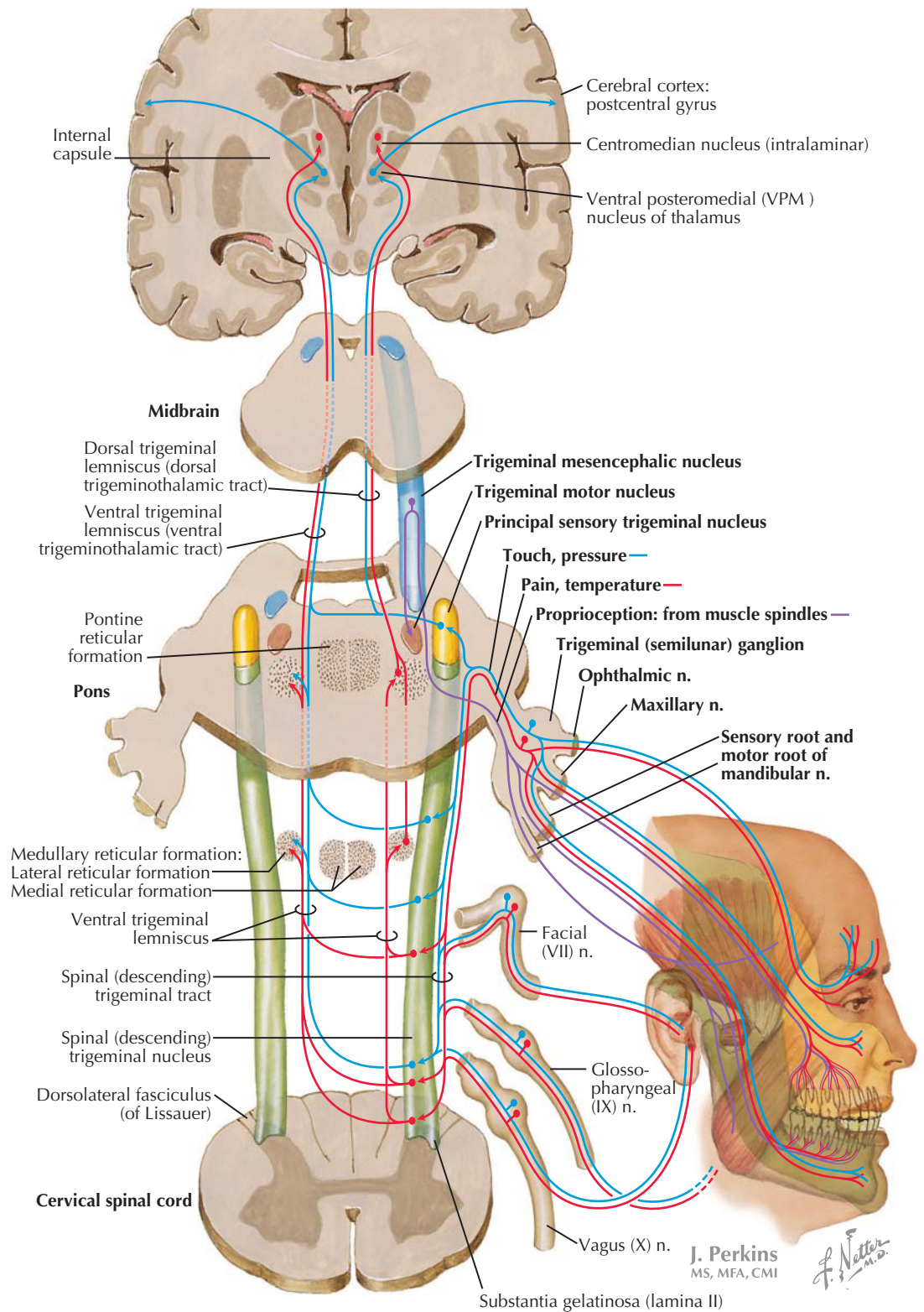
The trigeminal nerve is the largest cranial nerve and gives rise to three major branches: the ophthalmic, maxillary, and mandibular nerves. It is a mixed nerve that provides motor innervation to the muscles of

mastication and sensory innervation to the face and mucous membranes of the nasal and oral cavities.

The trigeminal nerve emerges from the anterolateral aspect of the upper pons. The large sensory root conveys sensation from most of the face and scalp; parts of the auricle; and the external acoustic meatus, the nasal, and oral cavities; teeth; temporomandibular joint; nasopharynx; and most of the meninges in the anterior and middle cranial fossae. It carries proprioceptive impulses from masticatory and, likely, from extraocular

and facial muscles. The smaller medial motor root supplies muscles derived from the first branchial arch: the masticatory muscles, the mylohyoid, the anterior belly of the digastric, the tensor veli palatine, and tensor tympani. Numerous parasympathetic and sympathetic fibers join branches of the trigeminal nerve through interconnections with the oculomotor (III), trochlear (IV), facial (VII), and glossopharyngeal (IX) nerves. The sensory and motor roots emerge from the pons and travel over the superior border of the petrous temporal

TRIGEMINAL NUCLEI: AFFERENT AND CENTRAL CONNECTIONS



**CRANIAL NERVE V: TRIGEMINAL NERVE** (Continued)

bone near its apex. The sensory root expands into the semilunar-shaped trigeminal ganglion (gasserian ganglion) and contains pseudounipolar cells with peripheral processes conveying sensory impulses from the face and head structures through the three major trigeminal divisions.

The central processes coalesce to form the sensory root, which enters the brainstem to end in one of three major nuclear complexes, the spinal (inferior) trigeminal nucleus, the principal sensory (pontine) nucleus, or the mesencephalic nucleus. The spinal tract of the trigeminal nucleus descends from the pons, through the medulla, and into the spinal cord, where it is contiguous with Lissauer's tract. The spinal tract gives off fibers to the medially located nucleus of the spinal tract of the trigeminal nerve. The spinal nucleus of the trigeminal nerve receives pain, temperature, and soft touch input from the face and mucous membranes. From the spinal nucleus, the ascending fibers travel ipsilaterally in the trigeminothalamic tract to the ventral posteromedial (VPM) and intralaminar nucleus of the thalamus. Projections ascend to the proximal sensory cortex for pain and temperature perception.

The principal sensory nucleus, which is located in the lateral pons, receives tactile and proprioceptive sensation. It gives off fibers that travel in the trigeminal lemniscus and the uncrossed dorsal trigeminothalamic tract, both of which terminate in the VPM nucleus of the thalamus. It is represented bilaterally in the cortex.

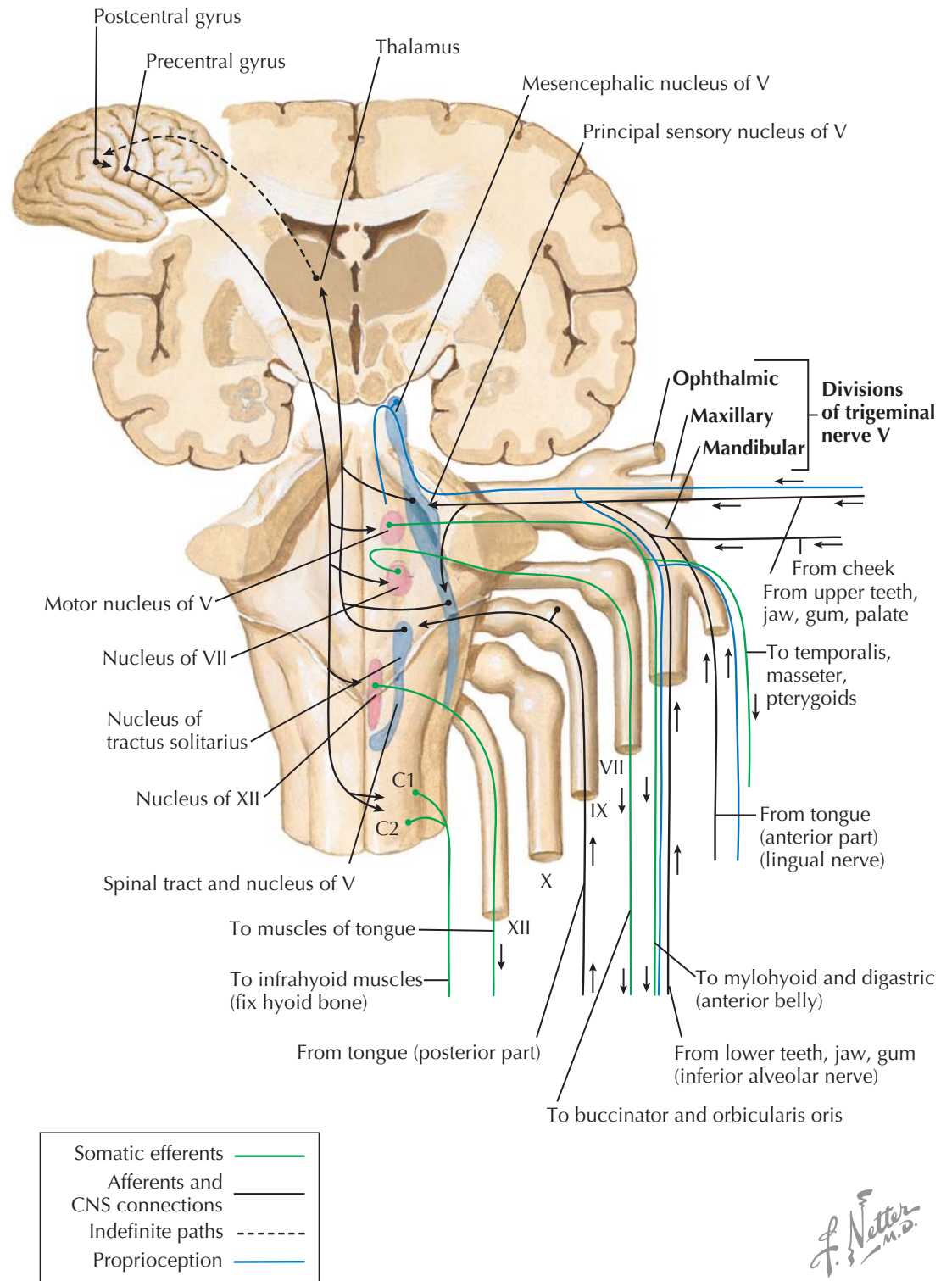
The mesencephalic nucleus contains cell bodies that carry proprioceptive input from masticatory and extraocular muscle spindles. It is the only place in the central nervous system (CNS) where cell bodies of primary sensory afferents are found in the CNS and not in sensory ganglia. The trigeminal mesencephalic nucleus

extends from the main sensory nucleus to the superior colliculus of the mesencephalon.

The motor fibers originate in the trigeminal motor nucleus. The sensory and motor roots of the trigeminal nerve leave the pons and pass through Meckel's cave to form the trigeminal ganglion. This ganglion then divides into the three nerve trunks: the ophthalmic, maxillary, and mandibular nerves. The small motor root passes under the ganglion to join the mandibular nerve.

The ophthalmic nerve (V1) collects pain, temperature, touch, and proprioceptive information from the upper third of the face, top of the nose, scalp regions, and adjacent sinuses. It is joined by filaments from the internal carotid sympathetic plexus and communicates with the oculomotor, trochlear, and abducens nerves as it runs forward in the lateral wall of the cavernous sinus. Near its origin, it gives off a small recurrent tentorial (meningeal) branch to the tentorium cerebelli and then

TRIGEMINAL NUCLEI: CENTRAL AND PERIPHERAL CONNECTIONS



**CRANIAL NERVE V: TRIGEMINAL NERVE** (Continued)

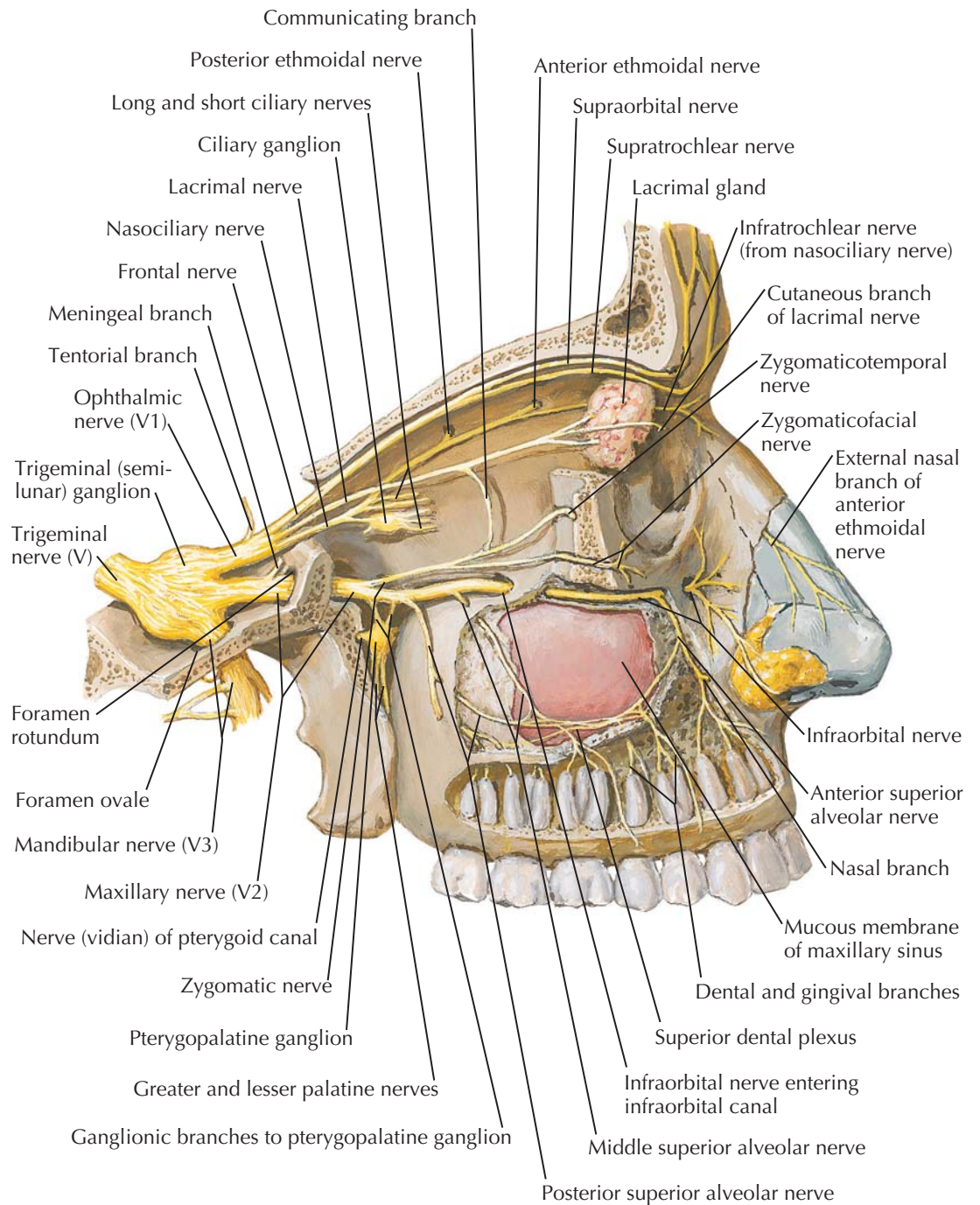
divides into the lacrimal, frontal, and nasociliary branches, which enter the orbit through the superior orbital fissure.

The maxillary nerve (V2) is larger than the ophthalmic nerve and is also sensory. It supplies the side of the forehead, medial cheek, side of the nose, upper lip, palate, upper teeth, nasopharynx, anterior and medial cranial fossae, meninges, and the skin overlying the maxilla. As with the other branches of the trigeminal nerve, it serves as a vehicle for the distribution of autonomic fibers to the skull structures. The maxillary nerve gives off a small meningeal branch to the meninges of the middle cranial fossa before passing through the lower part of the lateral wall of the cavernous sinus. It then leaves the skull through the foramen rotundum and enters the pterygopalatine fossa, where it communicates with the pterygopalatine ganglion before branching into different directions. In the pterygopalatine fossa, the maxillary nerve superiorly gives off the zygomatic nerve (with the zygomaticotemporal and zygomaticofacial branches), and inferiorly the superior posterior alveolar nerves. The superior middle and superior anterior alveolar nerves arise from the infraorbital part of the nerve that descend in the wall of the maxillary sinus between the bone and the mucous membrane, with dental and gingival rami uniting to form the superior dental plexus of the upper teeth and gums. The maxillary nerve ultimately moves anterolaterally across the upper part of the posterior surface of the maxilla to traverse the inferior orbital fissure on the way to the orbit. It then passes through the infraorbital groove as the infraorbital nerve, with the external and internal nasal, inferior palpebral, and superior labial branches, which supply the nasal alae, lower lid, upper lip skin, and mucous membranes, respectively.

The mandibular nerve (V3) is the largest branch of the trigeminal nerve and consists of a large sensory root and a small trigeminal motor root. The sensory portion innervates the cheeks, chin and lower lip, gums, inferior teeth, mucous membranes of the mouth, anterior two thirds of the tongue, side of the head, lower jaw, anterior wall of the external auditory meatus, external wall of the tympanic membrane, and the temporomandibular joint. The sensory and motor parts leave the skull

through the foramen ovale and unite to form a short nerve that lies between the lateral pterygoid and tensor veli palatine muscles, anterior to the middle meningeal artery. The small otic ganglion closely adheres to the medial side of the nerve. Just below the foramen, the mandibular nerve gives off a meningeal branch (nervus spinosus). It supplies the meninges of the middle and anterior cranial fossae and calvaria, and the mucous membrane of the mastoid air cells. The nerve to the

OPHTHALMIC (V1) AND MAXILLARY (V2) NERVES



**CRANIAL NERVE V: TRIGEMINAL NERVE** (Continued)

medial pterygoid muscle sends fibers through the otic ganglia without relay to supply the tensor veli palatine and tensor tympani muscles. The main mandibular nerve divides into a small anterior and a larger posterior part. The anterior part contains primarily motor fibers through the nerve to the lateral pterygoid and two or three deep temporal nerves that innervate the temporalis muscle. The anterior portion has one sensory branch, the buccal nerve, which innervates the areas of skin overlying the buccinators muscle and the mucous membranes beneath. The posterior part of the mandibular nerve is primarily sensory and divides into the auriculotemporal, lingual, and inferior alveolar nerves. The mylohyoid muscle and the anterior belly of the digastrics are supplied by a few motor fibers that are distributed in the mylohyoid branch of the inferior alveolar nerve. At its origin, the auriculotemporal nerve divides in two around the middle meningeal artery. It ends in the superficial temporal branches that supply the skin and fascia of the temple and adjacent areas of the scalp. The auriculotemporal nerve also gives branches to the temporomandibular joint, the external acoustic meatus, and the tympanic membrane, and an anterior auricular branch to the skin of the tragus and part of the helix. It supplies filaments containing secretomotor and vasomotor fibers to the parotid gland, which reach the nerve through the otic ganglion. Sensation to the anterior two thirds of the tongue and floor of the mouth is carried by the lingual nerve. It is joined near its origin by the chorda tympani, a branch of the facial nerve, which conveys taste from the part of the tongue anterior to the V-shaped sulcus terminalis. The lingual nerve supplies the mucous membrane of the anterior two thirds of the tongue, lower part of the isthmus of the fauces, and the floor of the mouth,

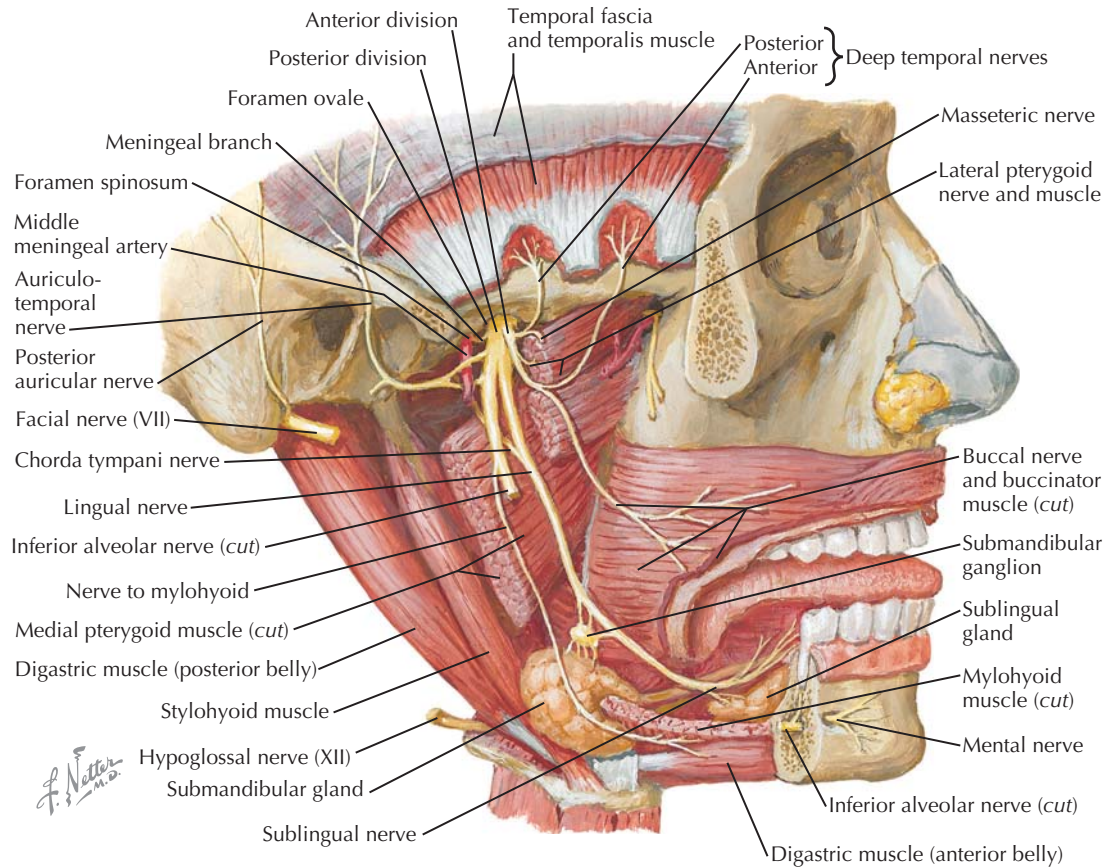
*F. Netter M.D.*

including the lingual surfaces of the lower gums. The branches communicate with the terminal branches of the glossopharyngeal and hypoglossal nerves. The inferior alveolar nerve descends behind the lingual nerve. It gives off its only motor branch, the mylohyoid nerve, before entering the canal. The mylohyoid nerve supplies the mylohyoid muscle and the anterior belly of the digastric. The other branches of the inferior alveolar nerve are the mental nerve and inferior dental and

gingival rami, which arise from the nerve as it passes through the mandibular canal. The latter are delicate nerves that unite to form the inferior dental plexuses supplying the lower teeth and gums. They may be joined by branches of the buccal and lingual nerves or by filaments from nerves supplying the muscles attached to the mandible. These branches may carry sensory fibers, which explains why blocking the inferior alveolar nerve alone does not always anesthetize the lower teeth.

**MANDIBULAR NERVE (V3)**

**Lateral view**

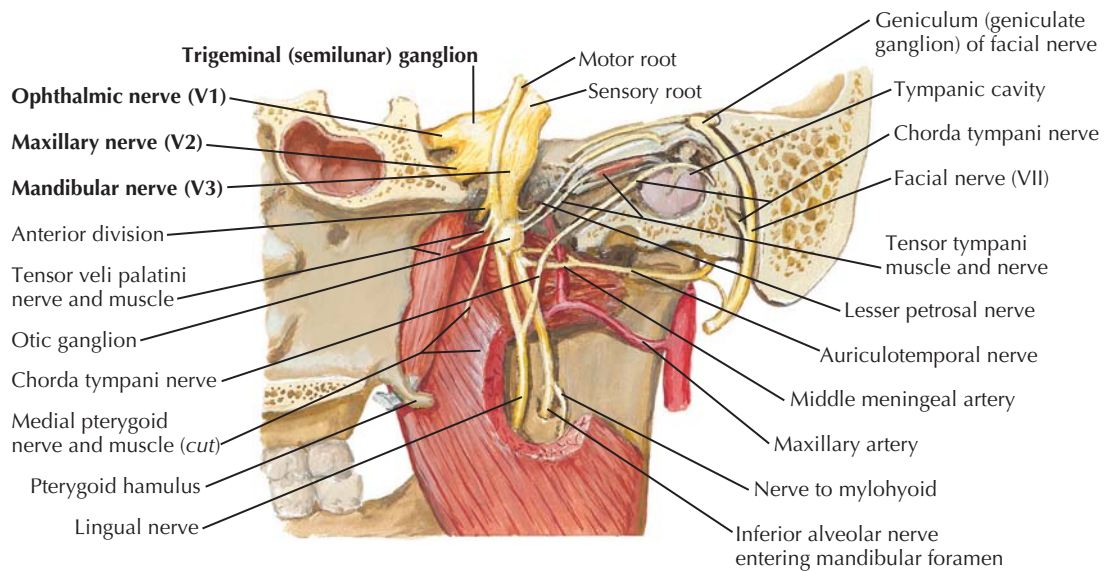


**CRANIAL NERVE V: TRIGEMINAL NERVE (Continued)**

**TRIGEMINAL NERVE DISORDERS**

Patients with trigeminal neuropathy frequently have facial numbness. The examination of touch, pain, and temperature in the three divisions of the trigeminal nerve, as well as the blink reflex, is routinely checked. Although the muscles of mastication are frequently difficult to assess, jaw deviation toward the paretic anterior pterygoid muscle on forward protrusion may help to indicate trigeminal motor weakness or isolated V3 division involvement. Impairment of general sensation from the tongue and palate carried by the trigeminal nerve can, at times, result in mild taste disturbances, even though the special sensory fibers providing primary taste sensation, supplied by the facial and glossopharyngeal nerves, are not involved. Facial trauma or, rarely, invasive dental treatments account for the majority of trigeminal nerve injuries with sensory loss depending on the involved site. Herpes zoster is a common viral cause of a trigeminal neuropathy and occurs when latent varicella-zoster virus within the trigeminal ganglion becomes reactivated. A vesicular rash and neuralgic pain along the involved division are characteristic, with a chronic postherpetic neuralgia persisting for months to years. Herpes zoster ophthalmicus occurs when the ophthalmic division is involved. If not promptly addressed, corneal scarring and visual loss is the most serious potential complication. Rarely, ipsilateral carotid and middle cerebral artery granulomatous angiitis with infarctions may occur as the virus travels retrograde from the ganglion along the trigeminal nerve. Worldwide leprosy or Hansen disease is the most common cause of trigeminal neuropathy. It affects with coolest areas of the skin, and sensory loss confined to the pinna of the ear or tip of the nose raises Hansen disease as a consideration.

**Medial view**



*Trigeminal ganglionopathy* in association with connective tissue disease is likely caused by circulating autoantibodies to ganglion cell bodies. This is particularly seen in scleroderma or Sjögren syndrome. Numbness begins around the mouth and spreads slowly over months to involve all trigeminal divisions. Frequently, the ophthalmic division is less involved or spared. In Sjögren syndrome, trigeminal ganglionopathy is

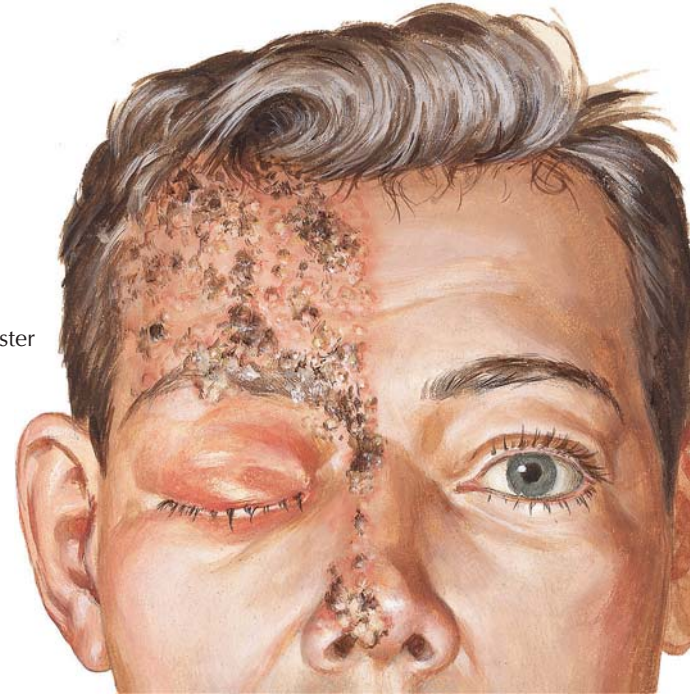
typically part of a more widespread sensory ganglionopathy.

Metastatic neoplasm or tumors involving the face, such as squamous cell carcinoma, microcystic adnexal carcinomas, and keratoacanthoma, may invade cutaneous nerve branches, especially at their exit point from the skull (mental and infraorbital neuropathies), and exhibit focal sensory loss. The numb chin syndrome (or

Varicella-zoster with probable keratitis

Herpes zoster

F. Netter M.D.

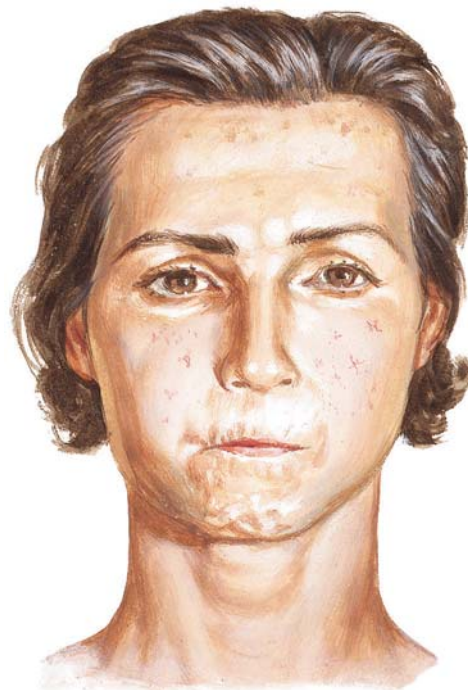


Progressive systemic sclerosis (scleroderma)

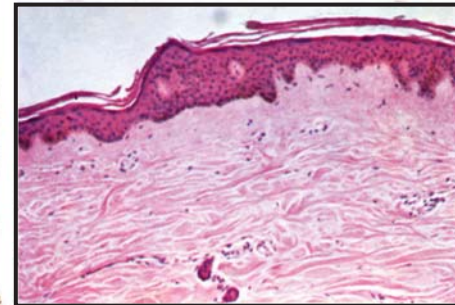
**CRANIAL NERVE V: TRIGEMINAL NERVE** (Continued)

isolated mental neuropathy) consists of unilateral numbness of the chin and adjacent lower lip and may be an ominous sign of primary or metastatic cancer involving the mandible, skull base, or leptomeninges. The most common etiologies are metastatic breast cancer and lymphoproliferative malignancies.

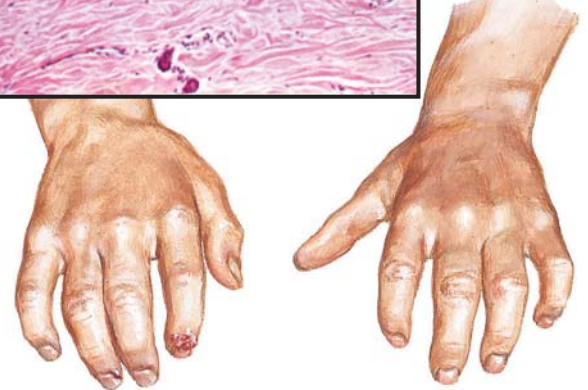*Trigeminal neuralgia*, also known as tic douloureux, is an often severe and disabling lancinating or electrical facial pain syndrome occurring in the trigeminal nerve distribution (typically maxillary or mandibular) without associated neurologic deficits. It characteristically affects middle-aged people, women more than men, and involves the right side more than the left. It is rare to have bilateral attacks of trigeminal neuralgia except in the setting of multiple sclerosis. The attacks are mostly unilateral and brief, lasting for seconds to several minutes, and rarely occur during sleep. Paroxysms of pain are frequently provoked by non-nociceptive triggers, including talking, chewing, shaving, drinking hot or cold liquids, or any form of sensory facial stimulation. Between paroxysms, a constant dull ache can persist, often leading patients to believe the problem is of dental origin. The frequency of attacks fluctuates markedly, disabling a patient for weeks and then remitting for months to years. The etiology is thought to involve loss of myelin insulation within the posterior root of the trigeminal nerve. It may be idiopathic or due to compression at the entry zone of the trigeminal nerve root by the ectatic artery, (branch of the superior cerebellar artery), multiple sclerosis plaque, infarction, vascular malformation, cerebellopontine angle tumor, or rarely, posterior communicating or distal anterior inferior cerebellar artery (AICA) aneurysm. Magnetic resonance imaging (MRI) scanning of the brain with gadolinium is indicated for all patients with trigeminal



**Characteristics.** Thickening, tightening, and rigidity of facial skin, with small, constricted mouth and narrow lips, in atrophic phase of scleroderma



Typical skin changes in scleroderma. Extensive collagen deposition and some epidermal atrophy.

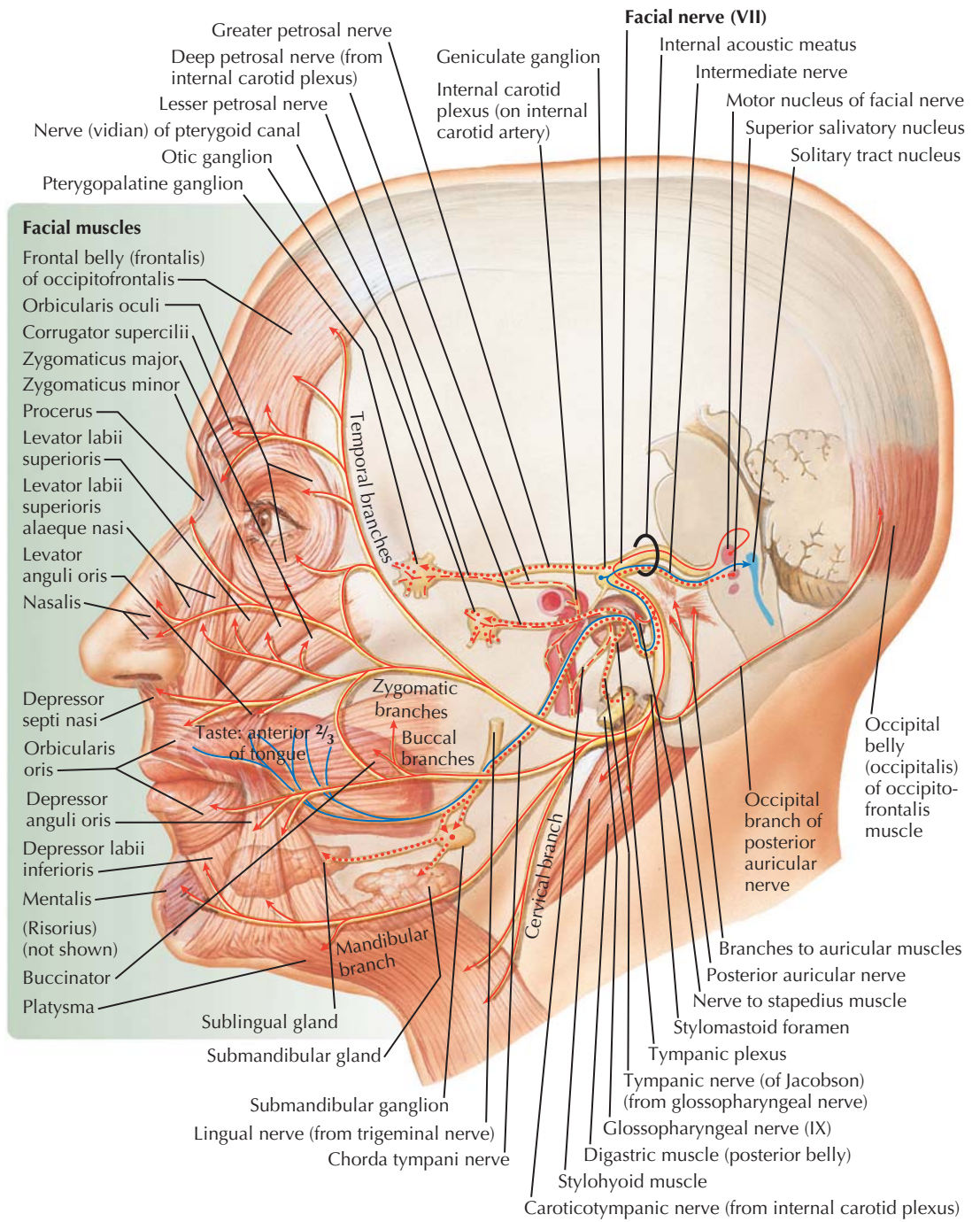


**Sclerodactyly.** Fingers partially fixed in semiflexed position; terminal phalanges atrophied; fingertips pointed and ulcerated

neuralgia. Bilateral symptoms, trigeminal sensory findings, and loss of corneal reflexes are strong indicators of secondary trigeminal neuropathy and should raise concern. Anticonvulsants are the primary medical therapy for trigeminal neuralgia, with most patients responding to carbamazepine and, more recently, oxcarbazepine. Baclofen, an antispasmodic, is advocated by some as an adjuvant treatment to carbamazepine if

higher doses alone are inadequate or cause side effects. Tricyclic antidepressants and other anticonvulsants, such as phenytoin, gabapentin, lamotrigine, topiramate, and pregabalin, may also be useful as adjuvant drugs or monotherapy. Several surgical approaches are available for patients who do not respond to medical therapy. Trigeminal neuralgia can recur after any procedure at a lifetime rate of about 20%.

FACIAL NERVE (VII)



**Facial muscles**

- Frontal belly (frontalis) of occipitofrontalis
- Orbicularis oculi
- Corrugator supercilii
- Zygomaticus major
- Zygomaticus minor
- Procerus
- Levator labii superioris
- Levator labii superioris alaeque nasi
- Levator anguli oris
- Nasalis

- Depressor septi nasi
- Orbicularis oris
- Depressor anguli oris
- Depressor labii inferioris
- Mentalis
- (Risorius) (not shown)
- Buccinator
- Platysma

- Efferent fibers
- Afferent fibers
- - - Parasympathetic fibers
- - - Sympathetic fibers

**CRANIAL NERVE VII: FACIAL NERVE**

**ANATOMY**

The facial nerve is a mixed nerve containing special motor, special sensory, general sensory, and parasympathetic fibers. The facial nerve comprises two roots: a larger motor root, which supplies the facial mimetic musculature, the stapedius, the stylohyoid, and the posterior belly of the digastric, and a smaller sensory root called the nervus intermedius, which carries sensation and parasympathetic fibers.

**THE MOTOR DIVISION**

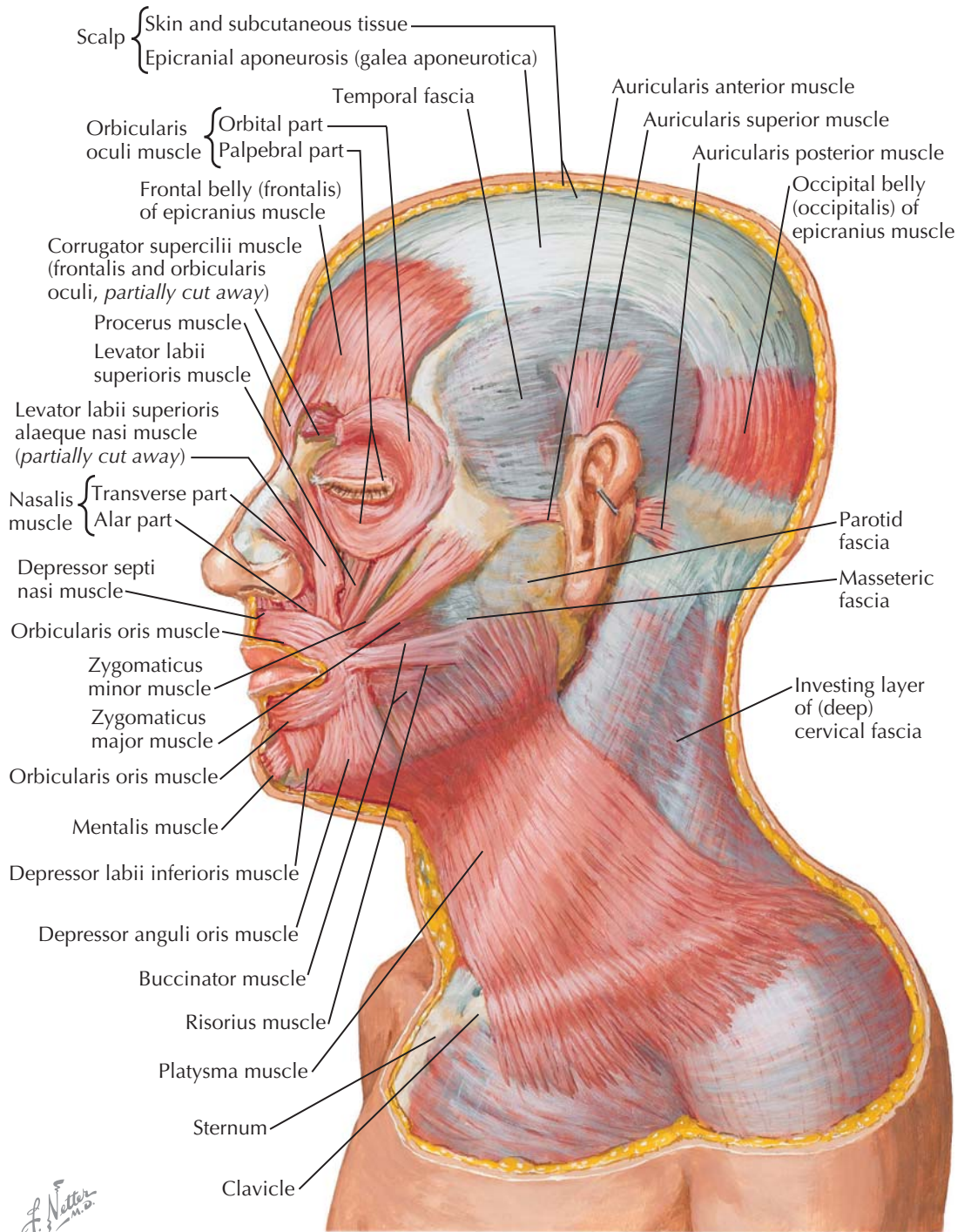
Fibers arise from the motor facial nucleus, located in the reticular formation of the lowest part of the pons. The nucleus is posterior to the superior olive, medial to the nucleus of the spinal tract of the trigeminal nerve, and anterolateral to the nucleus of the abducens nerve. The supranuclear control of facial movements occurs through the corticonuclear fibers originating in the precentral gyrus. These fibers course through the corona radiata, genu of the internal capsule, and the medial portion of the cerebral peduncle to the pons. The posterior portion of the facial nucleus controls the upper facial musculature and receives bilateral supranuclear input, while the anterior facial nucleus controls the lower facial muscles and receives predominantly contralateral input. Supranuclear lesions, such as with stroke, would therefore produce a pattern of contralateral predominantly lower facial weakness. The efferent fibers of the motor nucleus form a motor root and course around the abducens nucleus superiorly and exit the brainstem laterally in the cerebellopontine angle. The motor root travels with the nervus intermedius and CN VIII in the cerebellopontine angle and enters the internal auditory meatus of the temporal bone. Within the temporal bone, there are four portions of the facial nerve. (1) In the meatal (canal)

segment, the motor division is on the superoanterior surface of CN VIII, and the nervus intermedius is in between them. (2) In the labyrinthine segment, the motor root, and nervus intermedius enter the facial canal in the petrous bone. The labyrinthine segment passes above the labyrinth and reaches the geniculate ganglion, which contains the sensory fibers of the nervus intermedius. Here the greater superficial

petrosal nerve arises from the geniculate ganglion. This nerve is composed of preganglionic parasympathetic efferents that innervate the nasal, lacrimal, and palatal glands via the pterygopalatine ganglion. The greater superficial petrosal nerve also carries sensory fibers from the external auditory meatus, lateral pinna, and mastoid. (3) The horizontal (tympenic) segment contains the facial nerve as it runs horizontally backward

*F. Netter M.D.*

MUSCLES OF FACIAL EXPRESSION: LATERAL VIEW



**CRANIAL NERVE VII: FACIAL NERVE** (Continued)

below and medial to the horizontal semicircular canal. (4) In the mastoid (vertical) segment the facial nerve bends inferiorly. The nerve to the stapedius muscle branches off in this segment. The chorda tympani also branches off here and joins the lingual nerve. It contains the preganglionic parasympathetic fibers from the superior salivatory nucleus and innervates the submandibular and sublingual glands via the submaxillary ganglion. The chorda tympani also contains afferent taste fibers from the anterior two thirds of the tongue that then continue on to the nucleus of the solitary tract. CN VII exits the facial canal through the stylomastoid foramen and gives off the posterior auricular nerve (to the posterior auricular, transverse and oblique auricular muscles, and occipitalis) and digastric and stylohyoid branches. The facial nerve pierces the parotid gland and divides into temporofacial and cervicofacial branches, which further divide into temporofrontal, zygomatic, buccal, marginal mandibular, and cervical branches.

**THE SENSORY AND PARASYMPATHETIC DIVISION (NERVUS INTERMEDIUS)**

The nervus intermedius is the parasympathetic and sensory division of the facial nerve. It carries the preganglionic parasympathetic fibers to the submaxillary ganglion (and then postganglionic fibers travel to the submandibular and sublingual glands) and to the pterygopalatine ganglion (postganglionic fibers travel to the lacrimal, nasal, and palatal glands). The nervus intermedius receives sensory fibers from the geniculate ganglion. This ganglion receives afferents from the mucosa of the pharynx, nose, palate, and skin of the external auditory meatus, lateral pinna, and mastoid, and it carries taste sensation from the anterior two thirds of the tongue. The superior salivatory nucleus of the pontine tegmentum gives rise to the parasympathetic fibers. The lacrimal nucleus contains the fibers

controlling lacrimation. The gustatory afferents end in the nucleus of the tractus solitarius in the medulla. Fibers conveying general sensations from the external auditory meatus, lateral pinna, and mastoid likely come through interconnections between the chorda tympani and the auricular branch of the vagus and terminate in the spinal nucleus of the trigeminal nerve. The afferents from the meninges and their arteries in the middle


cranial fossa likely reach the facial nerve through the greater petrosal branch.

**FACIAL NERVE DISORDERS**

Facial weakness is caused by both central and peripheral lesions, and differentiating between the two frequently requires close examination. Peripheral facial weakness



CENTRAL VERSUS PERIPHERAL FACIAL PARALYSIS

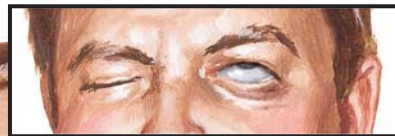


Hyperacusis

This may be an early or initial symptom of a peripheral VII nerve palsy: patient holds phone away from ear because of hyperacusis, an uncomfortable sensitivity to sound. Loss of taste also may occur on affected side.

Left peripheral VII facial weakness

Attempt to close eye results in eyeball rolling superiorly exposing sclera (Bell phenomenon) but no closure of the lid per se



Left central facial weakness



Incomplete smile with very subtle flattening of affected nasolabial fold; relative preservation of brow and forehead movement

**CRANIAL NERVE VII: FACIAL NERVE** (Continued)

involves both the upper and lower part of the face to the same degree, whereas upper motor neuron lesions typically manifest with a gradient of weakness, with relative preservation of movement in the brow and forehead (e.g., frontalis muscles). Supranuclear lesions, such as in suprabulbar palsies, may result in an absence of voluntary facial movements but retention of reflexive movements (e.g., smiling) in response to emotional stimuli.

*Intrapontine* lesions that affect the facial motor nucleus or its exiting fibers will often involve neighboring brainstem structures; for instance, a paramedian pontine reticular formation lesion causing ipsilateral conjugate gaze palsy, an associated sixth cranial nerve tract lesion with limited ipsilateral lateral rectus palsy, or contralateral hemiparesis of the arm and leg.

The facial nerve can be damaged at any level along its course (Plate 2-24). Facial musculature paralysis is the hallmark of seventh cranial nerve lesions. The presence or absence of symptoms related to the various other components of the facial nerve are important for further localization. The patient with a *peripheral facial nerve* palsy, with the exception of an early very distal branch lesion within the parotid gland, has weakness of the entire ipsilateral side of their face, with asymmetric smile, inability to close the eye (orbicularis oculi), or wrinkle the forehead (frontalis). *Intracranial, extramedullary lesions* affecting the seventh nerve typically occur within the cerebellopontine (CP) angle, most commonly caused by large acoustic neuromas, and often involve the vestibulocochlear nerve. In these cases, diminished hearing, at times initially presenting with tinnitus, usually precede the onset of peripheral facial paresis. Rarely, very large tumors may also involve the ipsilateral trigeminal cranial nerve with accompanying



Patient unable to wrinkle forehead; eyelid droops very slightly; cannot show teeth at all on affected side in attempt to smile; and lower lip droops slightly

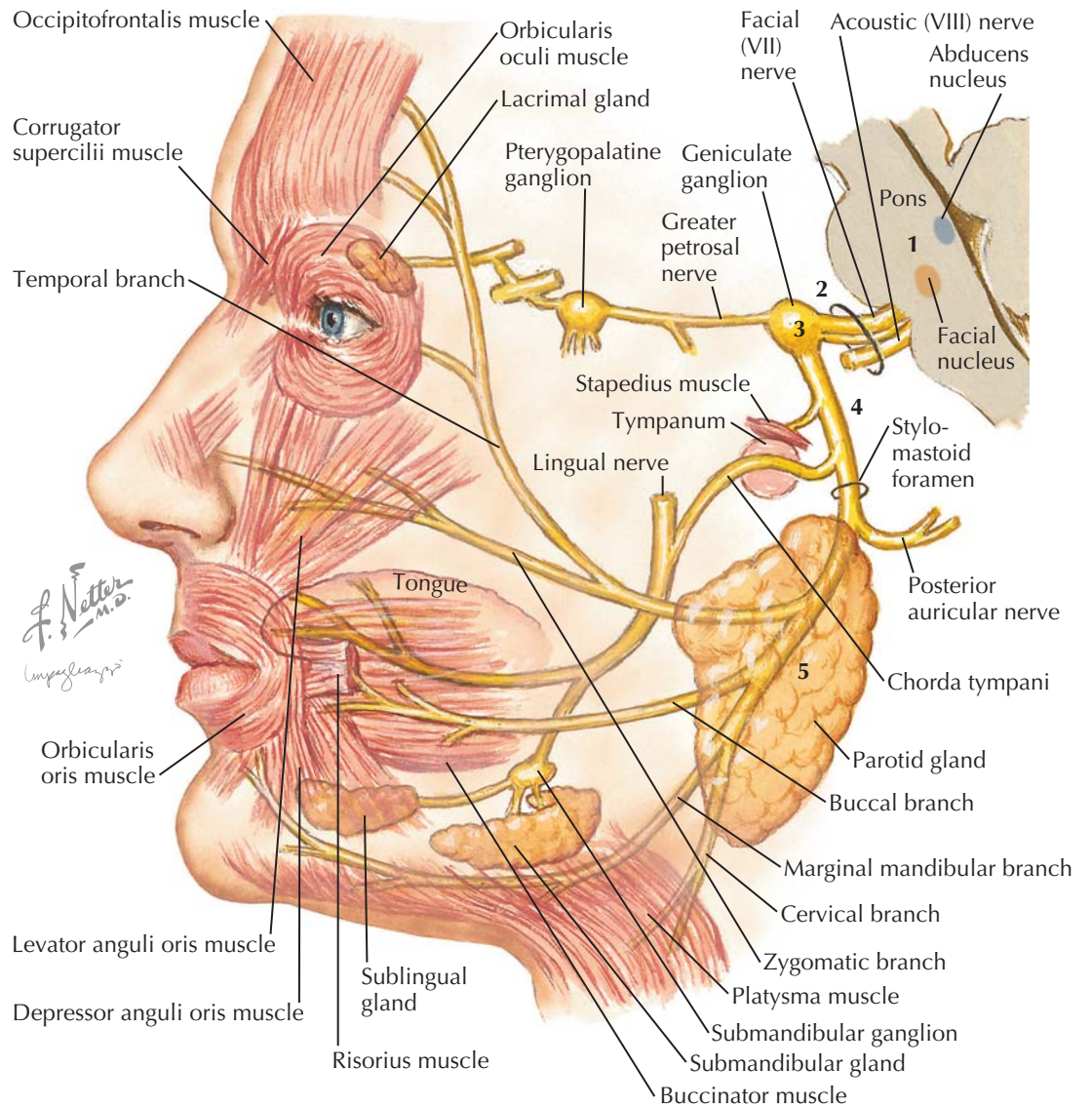
unilateral facial anesthesia and loss of corneal reflex. A *proximal preganglionic, intracranial facial nerve* lesion characteristically also causes diminished lacrimation from greater petrosal nerve involvement, as well as hyperacusis (i.e., increased sensitivity to sound) due to associated stapedius muscle paresis. These lesions also lead to diminished salivation, absent or altered taste for

the anterior two thirds of the tongue, and affected somatic sensation for the external auditory canal and mastoid area. Lesions *between the geniculate ganglion and the stapedius nerve* spare lacrimation, because the greater petrosal nerve has already exited. Damage *between the branch points of the stapedius nerve and the chorda tympani* results in hyperacusis and impaired salivation and taste,

*F. Netter M.D.*  
Impressario

FACIAL PALSY

Sites of facial (VII) nerve injury



**CRANIAL NERVE VII: FACIAL NERVE** (Continued)

but not change in lacrimation. Lesions distal to the chorda tympani branch point result in pure ipsilateral facial weakness. Distal lesions that affect individual motor branches result in weakness that may be restricted to individual facial muscles.

**BELL PALSY (“IDIOPATHIC” FACIAL PALSY)**

Bell palsy is a common cause of unilateral facial weakness. Onset of weakness is acute to subacute, evolving over hours to a few days. The lesion burden is usually proximal, with loss of total motor function on one side of the face, hyperacusis, disturbed taste, and decreased lacrimation. A preceding dull ache behind the ipsilateral ear is a common initial symptom. Nerve edema with subsequent compression and ischemia within the facial canal has been noted pathologically. The cause is believed to be reactivation of latent herpes simplex or varicella-zoster virus. A short course of corticosteroids, if given early in the course, reduces the duration of paralysis and risk of permanent impairment. The long-term prognosis is generally good, but severe cases may result in permanent partial facial paresis. Facial synkinesis, caused by aberrant regeneration of nerve, may manifest as ipsilateral eye closure occurring with smiling or ipsilateral lip and chin muscle activation during blinking. Excessive lacrimation when eating results from aberrant regeneration of salivatory fibers to the lacrimal glands (“crocodile tears”).

**OTHER ETIOLOGIES OF FACIAL NEUROPATHY**

Lyme disease is a relatively common infectious cause of an acute unilateral or bilateral facial neuropathy.

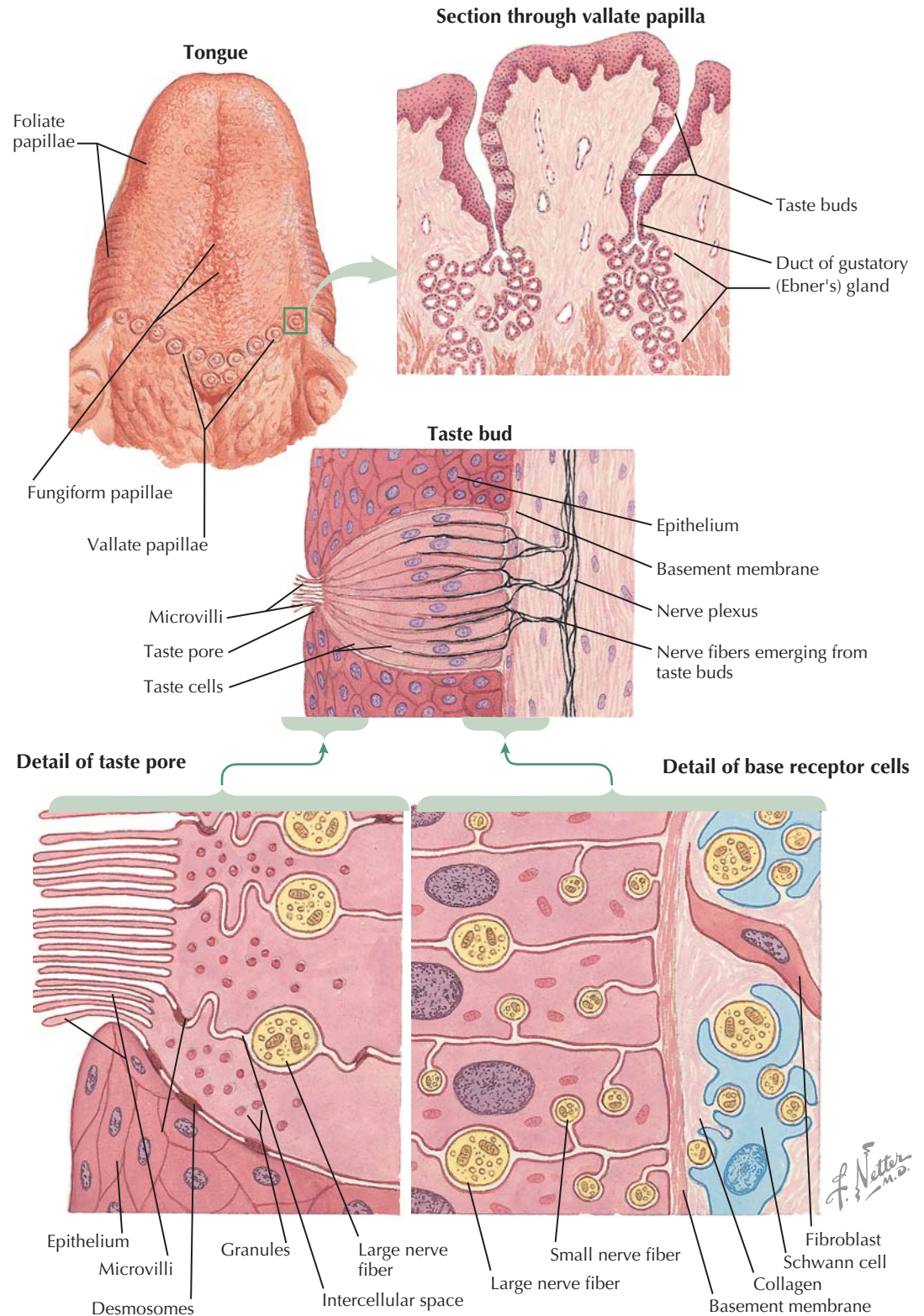
**Sites of lesions and their manifestations**

- 1. Intrapontine lesions:** Peripheral motor facial paralysis associated with eye movement abnormalities (ipsilateral abducens or horizontal gaze palsies) and contralateral motor paralysis.
- 2. Intracranial and/or internal auditory meatus:** All symptoms of 3, 4, and 5, plus deafness due to involvement of eighth cranial nerve.
- 3. Geniculate ganglion:** All symptoms of 4 and 5 with diminished lacrimation, plus pain behind ear. Herpes of tympanum and of external auditory meatus may occur.
- 4. Facial canal:** All symptoms of 5, plus loss of taste in anterior tongue and decreased salivation on affected side due to chorda tympani involvement. Hyperacusis due to effect on nerve branch to stapedius muscle.
- 5. Below stylo-mastoid foramen (parotid gland tumor, trauma):** Facial paralysis (mouth draws to opposite side) on affected side with patient unable to close eye or wrinkle forehead; food collects between teeth and cheek due to paralysis of buccinator muscle.

Symptoms typically include systemic symptoms (e.g., arthralgia, fever, rash), as well as other neurologic symptoms (e.g., headache, radiculitis, encephalopathy). Herpes zoster infection within the external auditory canal (Ramsay-Hunt syndrome), may cause facial paralysis that may precede the appearance of typical herpetic vesicles in the auditory canal. Extension of otitis media

may rarely inflame and damage the facial nerve where it travels through the petrous bone. Leprosy may lead to bilateral facial nerve lesions. Unilateral or bilateral facial neuropathy is a common neurologic manifestation of sarcoidosis. Bilateral facial weakness is common in Guillain-Barré syndrome (acute inflammatory demyelinating polyradiculopathy).

ANATOMY OF TASTE BUDS AND THEIR RECEPTORS



**TASTE RECEPTORS AND PATHWAYS**

**TASTE RECEPTORS**

*Taste buds* contain the receptors responsible for taste sensation. They are located on the upper surface of the tongue, soft palate, epiglottis, and upper esophagus. The greatest concentration of taste buds is found on the raised protuberances of the tongue called the papillae. The vallate papillae are located at the back of the tongue in front of the sulcus terminalis and are innervated by the glossopharyngeal nerve. The fungiform papillae are located at the apex of the tongue and are innervated by the facial nerve. Foliate papillae are found on the roof of the mouth and are innervated by the facial and glossopharyngeal nerve.

Each taste bud consists of up to 100 polarized neuroepithelial cells that form “islands” of columnar pseudostratified cells embedded in the epithelium. Each bud has a central taste pore through which microvilli extend from the receptor cells. Just below their apical ends, the cells are joined by desmosomes, which seal off the intracellular spaces from the taste pore. There are three types of receptor cells (types I, II, and III) and basal cells that make up the taste bud. Taste buds are constantly being renewed.

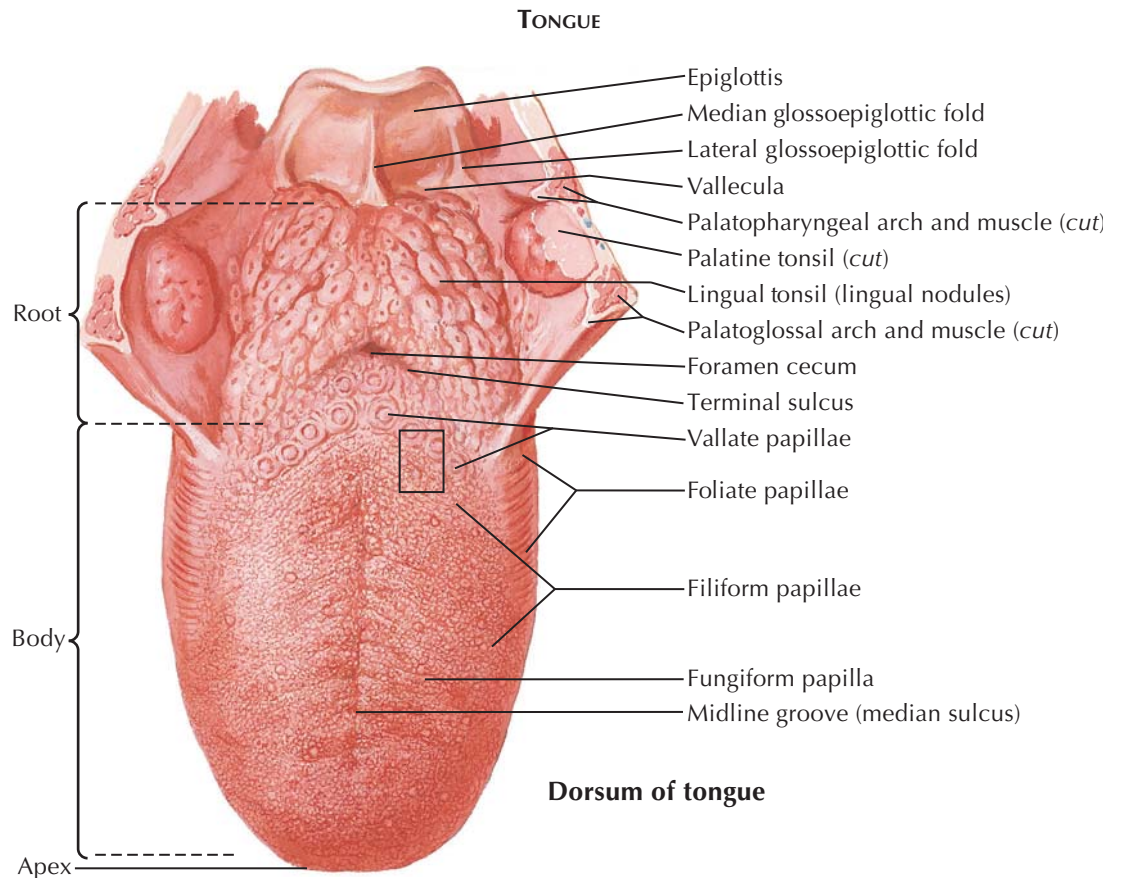
Taste buds are innervated by both large and small fibers, which emerge from a subepithelial nerve plexus and enter the bud at its base. The larger fibers run in clefts between taste cells, while the smaller fibers (possibly terminal branches derived from large fibers) tend to run in invaginations found in the basal parts of taste cells.

*The sensation of taste* can be divided into five primary qualities: sweet (sucrose), sour (hydrochloric acid), salty (sodium chloride), bitter (quinine), and umami (L-glutamate and other L-amino acids). Sweet foods signal the presence of carbohydrates, which supply energy. Sour foods signal dietary acids and are frequently aversive. Salty taste sensation helps to regulate body water balance and blood pressure. Bitter taste is aversive and guards against poison consumption.

Umami reflects food's protein content. The tip of the tongue is sensitive to all five stimuli but especially to sweet and salty substances, the sides of the tongue to sour substances, and the base of the tongue to bitter substances.

Water-soluble compounds evoke taste sensations by binding to the apical parts (microvilli) of the taste cells. Type I cells are the most abundant and function

primarily by terminating synaptic transmission and regulating neurotransmitters. In type II cells, sweet, bitter, and umami ligands bind to taste receptors, resulting in an increase of cytoplasmic calcium and depolarization of the cell membrane, ultimately resulting in adenosine triphosphate (ATP) release. Sour taste excites type III presynaptic cells. The presynaptic type III cells also form synaptic junctions with nerve



**TASTE RECEPTORS AND PATHWAYS** (*Continued*)

terminals and also express proteins involved in synapses. These cells release both serotonin and norepinephrine. Salty taste is detected by direct permeation of sodium through membrane ion channels. The cell type underlying salty taste has not been identified, although type I cells have been implicated.

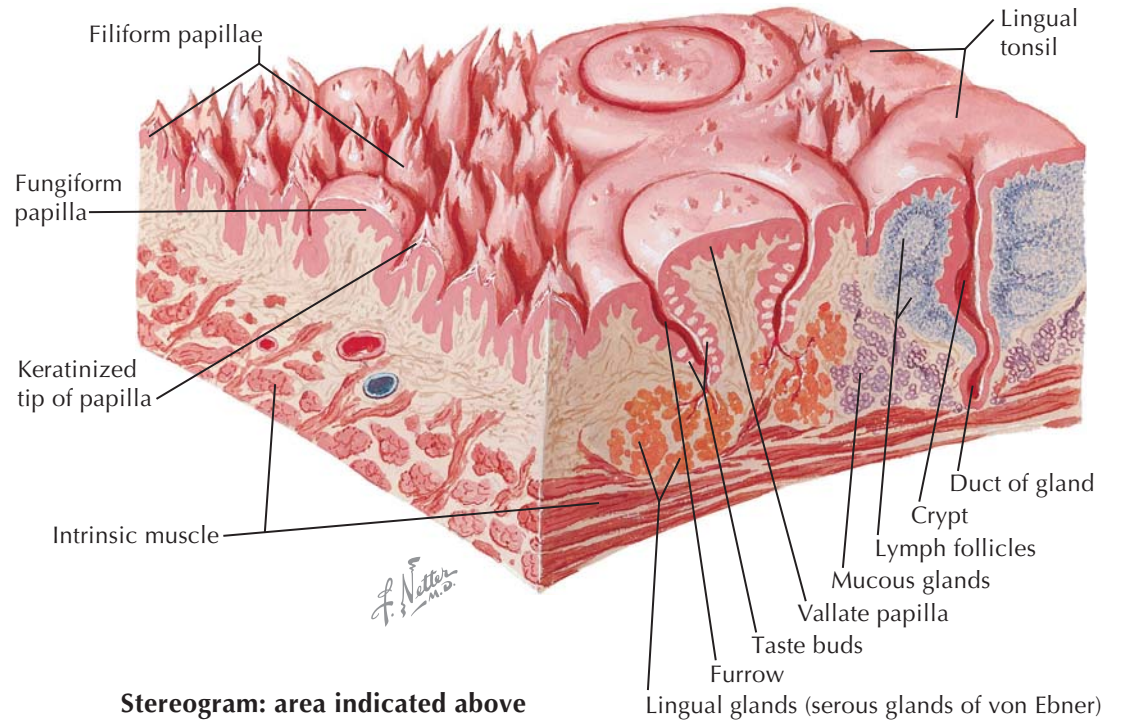
A single-taste cell responds to more than one of the five primary taste stimuli but not equally to each sensation. Similar multiple responses are observed in taste fibers, each of which synapses with several taste cells. The patterns of responses to the five taste stimuli by single fibers are not entirely random because experimental studies of large groups of fibers have revealed a tendency for certain fiber groups to respond specifically to certain sets of stimuli. For instance, a considerable number of fibers have been observed to respond well to both salt and acid stimuli, whereas fibers responding strongly to both salt and sweet stimuli are rare. Even within a given responding group, the relative sensitivity to different stimuli varies widely.

**TASTE PATHWAYS**

The chemosensitive cells found in the taste buds of the tongue, epiglottis, and larynx are innervated by three groups of sensory neurons.

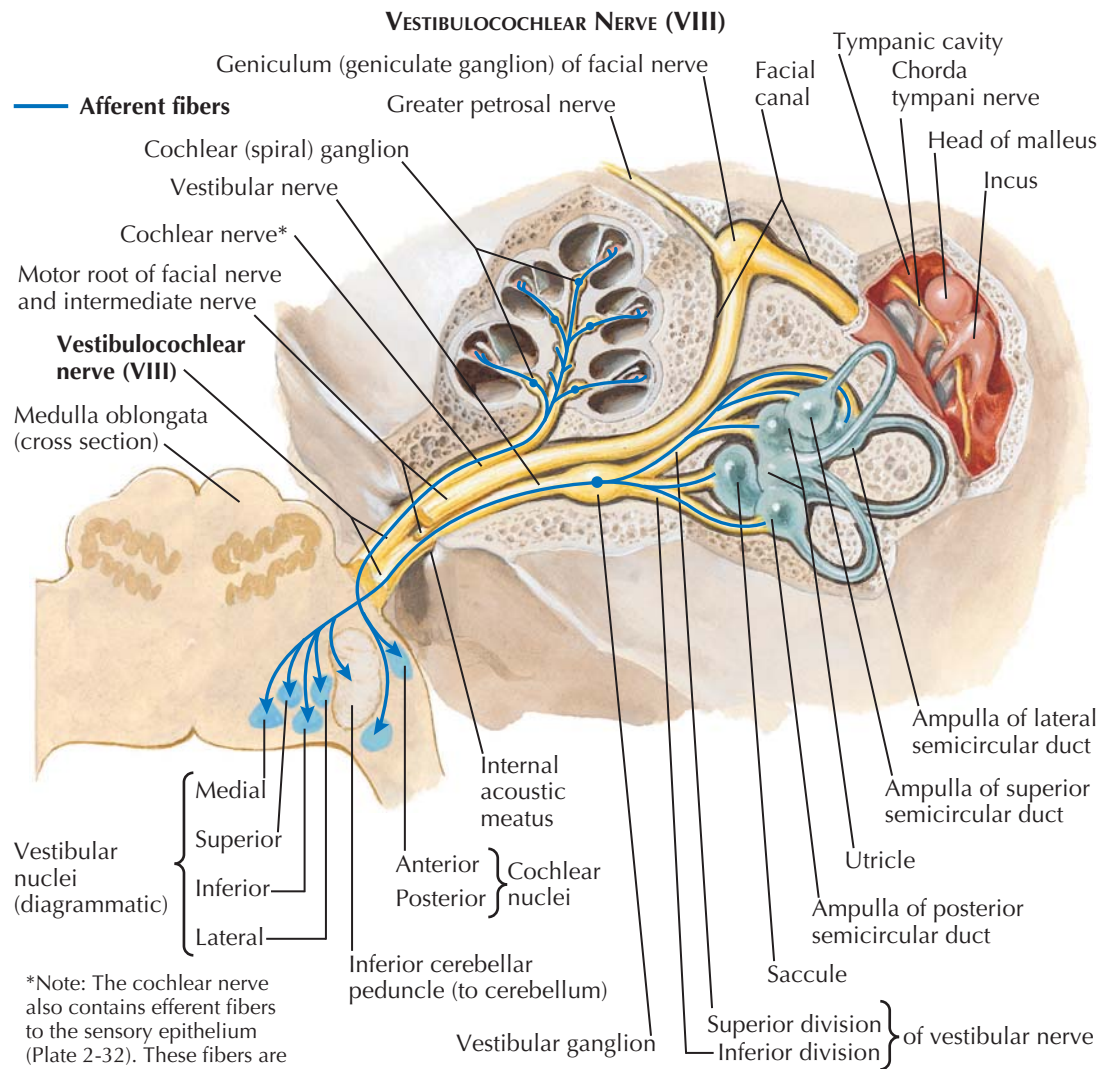
**Sensory Neurons.** Taste cells synapse with sensory axons that run in the chorda tympani and greater superficial petrosal branches of the facial nerve, which carries taste sensation via the geniculate ganglion. The lingual branch of the glossopharyngeal nerve carries taste sensation via the petrosal (inferior) ganglion of the glossopharyngeal nerve. The superior laryngeal branch of the vagus nerve passes through the nodose (inferior) ganglion. All three groups of cells terminate in the medullary nucleus of the tract of solitarius.

**Central Connections.** From the nucleus of the tract of solitarius, second-order neurons project mostly ipsilateral (some fibers may cross over in the medial lemniscus) up the solitariothalamic bundle to the ipsilateral

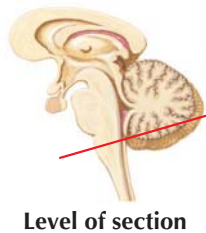


ventral posteromedial nucleus of the thalamus. Third-order neurons from the VPM nucleus pass through the posterior limb of the internal capsule to the taste region of the sensory cortex, located just below the face. The hypothalamic and amygdalar taste connections, on the other hand, appear to be primarily involved in reflex and motivational responses to taste stimuli, and thus control food intake.

The reflex-type brainstem connections between the taste nuclei and the autonomic nuclei for salivation (superior and inferior salivatory nuclei) mediate salivation reflexes that accompany taste responses to food stimuli on the tongue. "Gustation sweating," facial and forehead sweating in response to eating spicy foods, is a normal response, although it can be pathologic if profuse.

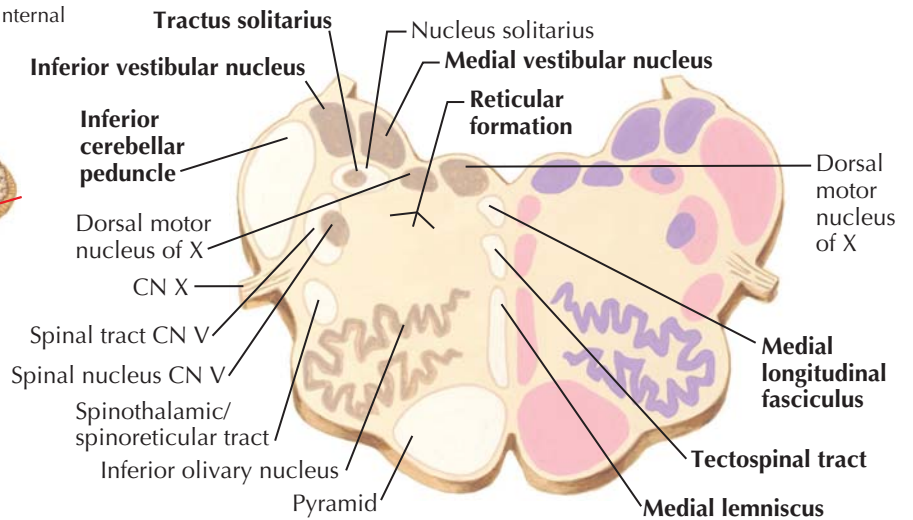


\*Note: The cochlear nerve also contains efferent fibers to the sensory epithelium (Plate 2-32). These fibers are derived from the vestibular nerve while in the internal auditory meatus.



Level of section

*F. Netter M.D.*  
JOHN A. CRAIG M.D.



## CRANIAL NERVE VIII: VESTIBULOCOCHLEAR NERVE

The vestibulocochlear nerve consists of two separate divisions, the vestibular and cochlear nerves. The vestibular labyrinth of the internal ear, including the semicircular ducts (canals) and the otolith organ (utricle and saccule), subserves equilibration, posture, and muscle tone. Linear acceleration is monitored by macules of the utricle and saccule, and angular acceleration is monitored by the cristae in the ampullae of the semicircular canals. The cochlea of the internal ear transmits auditory impulses from the spiral organ. The roots of the vestibular and cochlear nerves enter the brainstem separately and have different central connections. Sympathetic and parasympathetic fibers likely accompany both parts of the vestibulocochlear nerve. The vestibular and cochlear nerves usually unite over a variable distance and pass outward to enter the internal acoustic meatus, below the motor root of the facial nerve, with the nervus intermedius interposed.

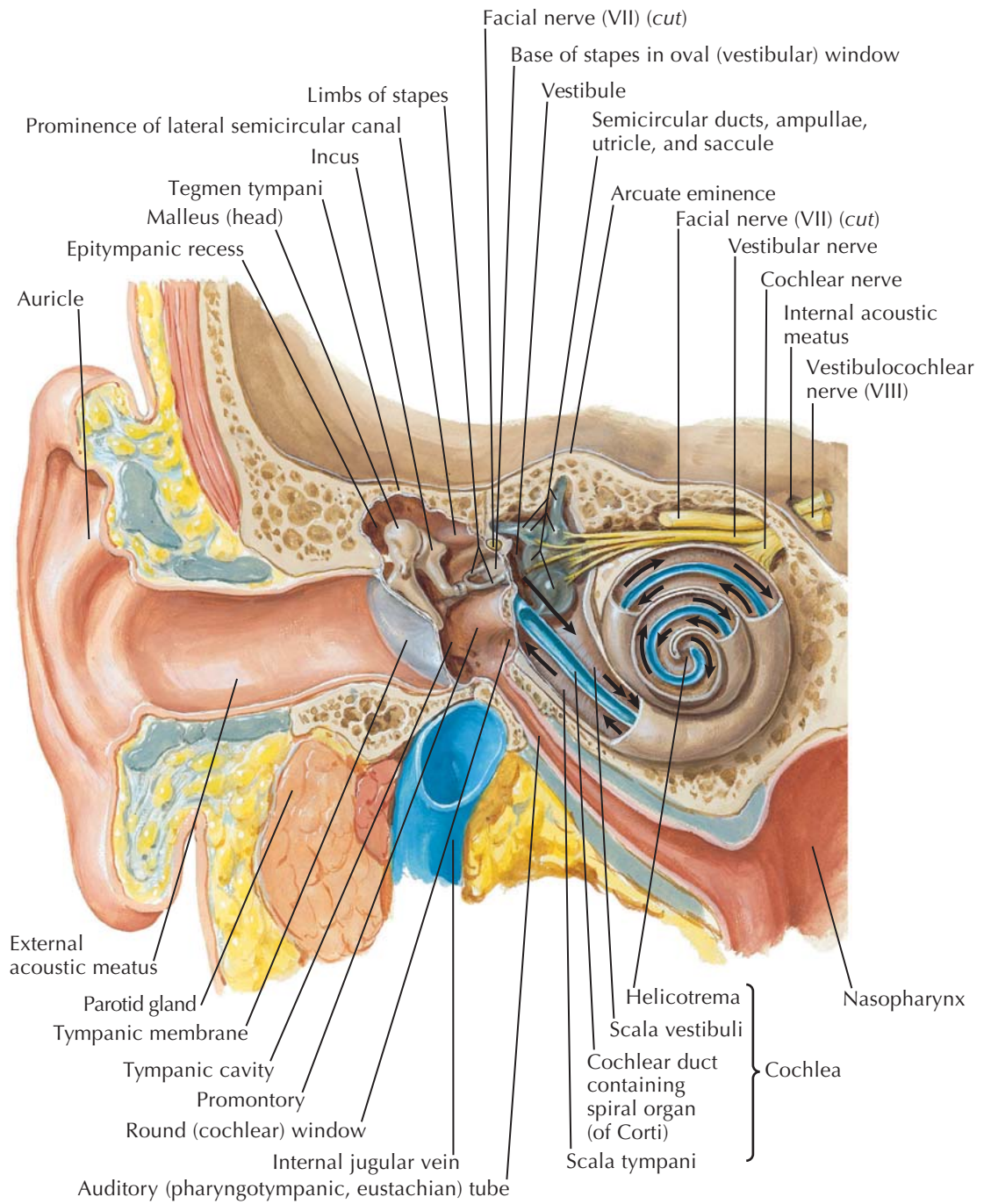
### VESTIBULAR NERVE

At the fundus of the internal acoustic meatus, the vestibular part of the vestibulocochlear nerve expands to form the vestibular ganglion before dividing into superior and inferior divisions. Both divisions contain peripheral processes of the vestibular bipolar cells, which penetrate tiny foramina in the superior and inferior vestibular areas of the fundus of the internal acoustic meatus. The peripheral processes spread to contact hair cell receptors embedded in the neuroepithelium lining the ampullae of the semicircular ducts (canals) and the maculae of the saccule and utricle. The longer central processes of the bipolar cells transmit impulses from these vestibular hair cells to the brainstem. Passing

backward in the pontomedullary junctional area, the central processes divide into ascending and descending branches, which end predominantly in the superior (cranial), inferior (caudal), medial, and lateral vestibular nuclei located in the medulla oblongata and lower pons. Other branches proceed directly through the homolateral inferior cerebellar peduncle to the flocculonodular cerebellar lobe. Fibers from the superior nucleus enter the ipsilateral medial longitudinal fasciculus and ascend

to end on cells of cranial nerves III, IV, and VI. Fibers from the inferior, medial, and lateral nuclei all terminate on the contralateral medial longitudinal fasciculus, in addition to connections with the autonomic nuclei, reticular formation, and the intermediolateral column of the cord. These connections play a crucial role in regulating posture and coordinating head, body, and eye movements. Separate vestibular-cerebellum pathways, mainly through the fastigial nuclei, also influence

Frontal section



**CRANIAL NERVE VIII:  
VESTIBULOCOCHLEAR NERVE**  
(Continued)

posture and movement coordination. Connections with the autonomic centers and the intermediolateral column likely account for the nausea and vomiting seen, at times, with overstimulation of the vestibular system.

**COCHLEAR NERVE**

The fibers in the cochlear part of the vestibulocochlear nerve traverse many small, spirally arranged foramina in the fundus of the internal acoustic meatus and enter the modiolus, the central pillar of the cochlea. The fibers run in tiny longitudinal and spiral canals into the conical central modiolus, with numerous enlargements of the spiral cochlear ganglia that contain bipolar nerve cells. The short peripheral processes of these bipolar cells end in special acoustic hair cells in the spiral organ of Corti in the cochlear duct. The hair cells located at the apex of the cochlea are stimulated by low-frequency tones, and those located at the base are stimulated by high-frequency tones. The relatively long central processes of the bipolar cells of the cochlear nerve reach the brainstem lateral to the vestibular part and end in the ventral and dorsal cochlear nuclei located on the lateral aspect of the inferior cerebellar peduncle in the superior medulla. The dorsal nuclei receive high-frequency fibers, and the ventral nuclei receive the low-frequency hair cells. Most cochlear nuclear fibers decussate through the trapezoid body before climbing in the lateral lemniscus to the inferior colliculus, while others synapse with neurons in the superior olivary nucleus. Third-order neurons from the inferior colliculus synapse in the medial geniculate body, which is the thalamic auditory relay nucleus. The fourth-order neurons proceed as the auditory radiations and courses laterally through the sublenticular portion of the internal capsule to the primary auditory cortex in the transverse temporal gyri of Heschl (Plate 2-31).

**DISORDERS OF THE VESTIBULOCOCHLEAR NERVE AND SYSTEM**

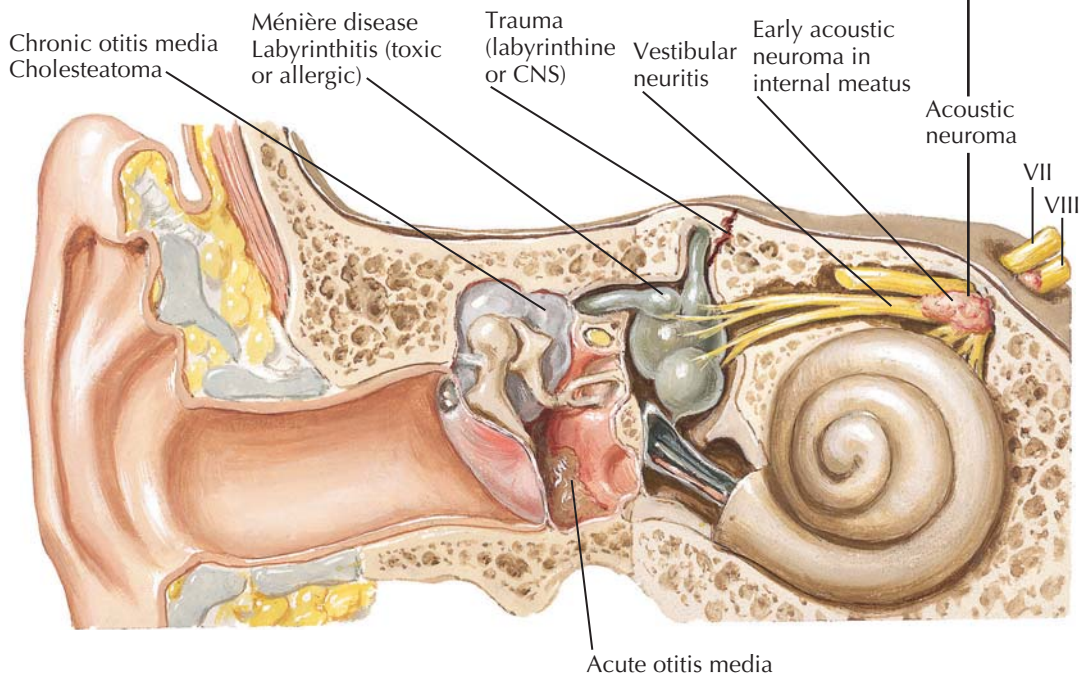
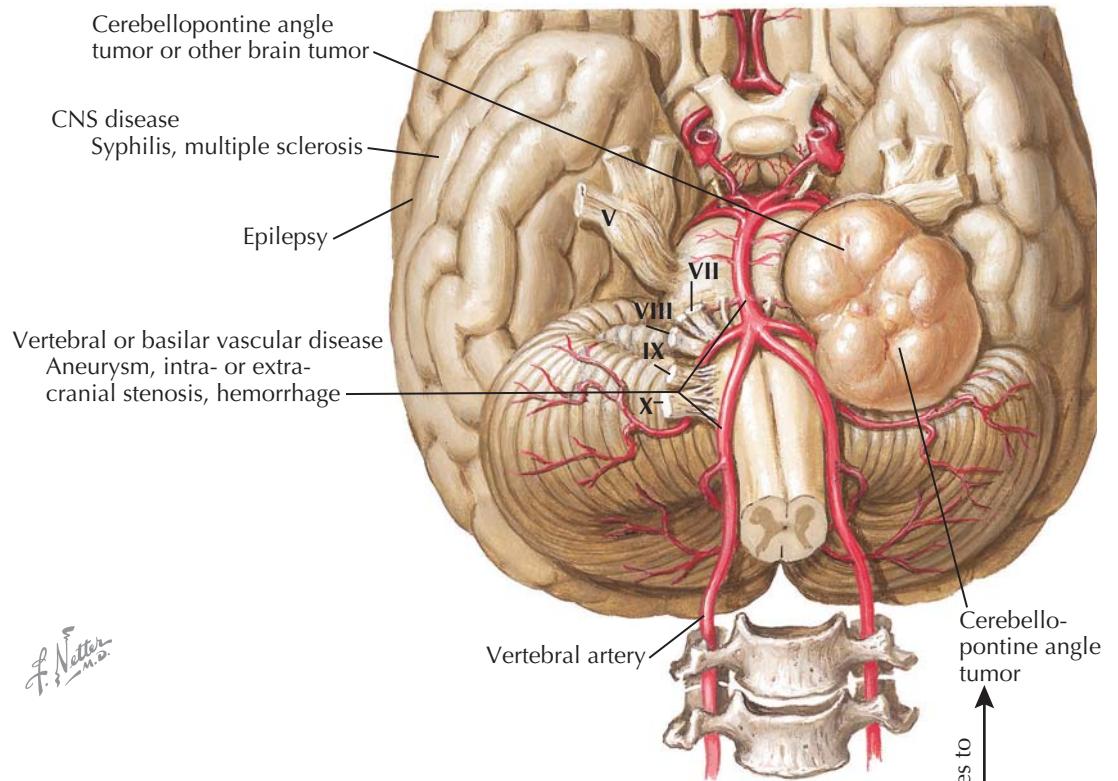
**Vestibular**

*Ménière disease* is an idiopathic process characterized by bouts of episodic vertigo, fluctuating but eventually progressive sensorineural hearing loss, tinnitus, and a sensation of aural fullness. Vestibular symptoms predominate especially early, and chronic imbalance may

eventually ensue. *Ménière disease* is felt to be secondary to an imbalance of the inner ear's endolymph. Bilateral *Ménière disease* may have an autoimmune basis. Although *Ménière disease* is often associated with hearing loss and ear fullness, vestibular neuritis in contrast is characterized by prolonged vertigo without hearing loss. *Benign paroxysmal positional vertigo (BPPV)* is caused by errant otolith debris lodging into the semicircular canals and leading to overstimulation with head

Note: Arrows indicate course of sound waves.

PATHOLOGIC CAUSES OF VERTIGO



**CRANIAL NERVE VIII:  
VESTIBULOCOCHLEAR NERVE**

(Continued)

movement. Upper respiratory and otologic infections, head trauma, and sustained unusual head postures are described triggers in many cases. Bedside maneuvers and vestibular rehabilitation help reposition errant otolith debris and reestablish equal tonic vestibular input (e.g., canalith repositioning or Epley maneuver).

Vestibular schwannoma (also known by the misnomer “acoustic neuroma”) is a benign Schwann cell tumor of the vestibular nerve that accounts for 6% of intracranial tumors. Vestibular schwannomas involve the adjacent cochlear division by compression against the walls of the internal auditory canal. Progressive hearing loss from stretching or compression of the cochlear nerve is the most common symptom, occurring in approximately 95% of patients. High-pitched unilateral tinnitus is often present, but vestibular symptoms are paradoxically infrequent as the contralateral vestibular system adjusts gradually to the imbalance. Large tumors can lead to facial or trigeminal nerve involvement and, at times, pontine compression.

The eighth cranial nerve is vulnerable to fractures involving the petrous part of the temporal bone and by tumors affecting the brainstem or cerebellum. Vertigo may be caused by central or peripheral pathology, but the distinction is not always readily clear, and thus, diagnostic circumspection is often warranted because posterior circulation strokes may manifest with the complaint of vertigo. Brainstem involvement from stroke or, at times, multiple sclerosis, may often be distinguished from a peripheral etiology by symptoms or signs indicating damage to other brainstem structures, such as dysmetria, diplopia, dysphagia, dysarthria, sensory loss, or weakness.

**Cochlear**

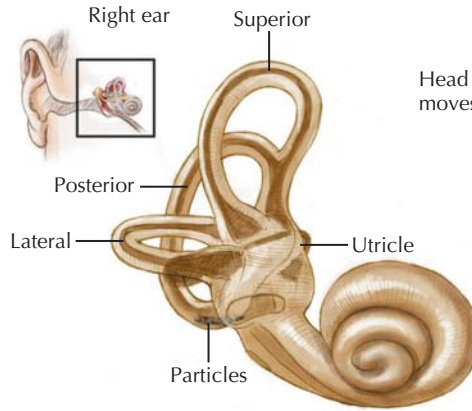
*Conductive hearing loss* refers to disrupted sound wave transmission to the cochlea from external ear canal,

tympenic membrane, or ossicular dysfunction. *Sensorineural hearing loss* relates to impairment of the cochlea (sensory), cochlear nerve, or nuclei (neural), or any part of the brain auditory pathway (central).

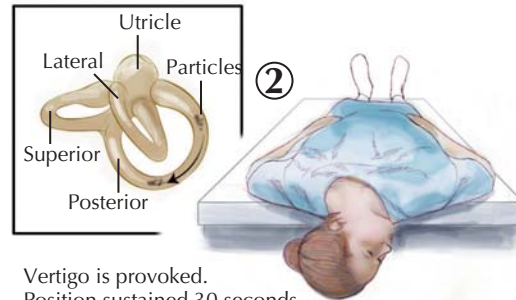
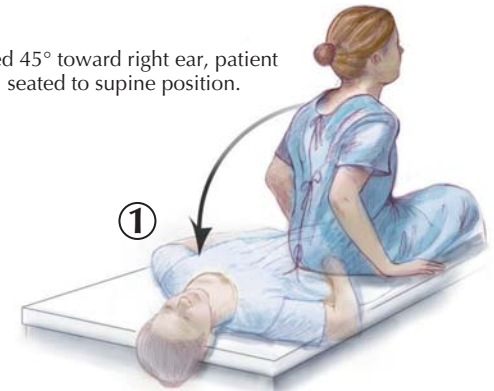
Auditory nerve dysfunction usually results in subjective tinnitus in addition to sensorineural hearing loss. Tinnitus, the sensation of ringing in the ears without

significant stimulus, is more frequently noted with peripheral than central lesions. Pulsatile tinnitus is often associated with vascular abnormalities such as arteriovenous malformations, glomus tumors, hemangiomas, meningiomas, vascular loops, high-grade carotid stenosis, intracranial aneurysm, and dural arteriovenous fistulae. Pulsatile tinnitus is also a feature of

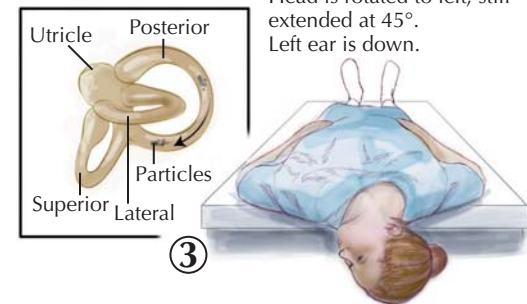
**CANALITH REPOSITIONING (EPLÉY MANEUVER)**



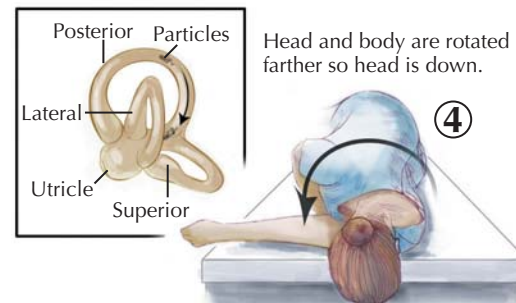
Head rotated 45° toward right ear, patient moves from seated to supine position.



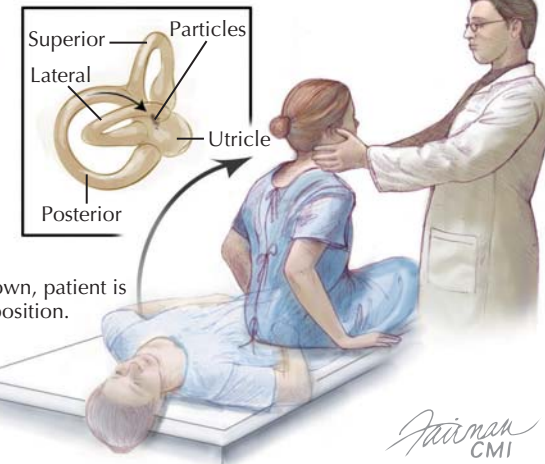
Vertigo is provoked. Position sustained 30 seconds or until vertigo subsides.



Head is rotated to left, still extended at 45°. Left ear is down.



Head and body are rotated farther so head is down.



With left shoulder down, patient is brought to a seated position.

**CRANIAL NERVE VIII:  
VESTIBULOCOCHLEAR NERVE**  
(Continued)

idiopathic intracranial hypertension. Although bilateral deficits reflect general processes such as ototoxicity (aminoglycosides, salicylates, or loop diuretics), noise exposure, and age-related hearing loss (presbycusis), unilateral hearing loss should raise concern of neoplastic, vascular, neurologic, or inflammatory etiologies. Fluctuating symptoms are seen in Ménière disease, while progressive loss may indicate tumor (e.g., vestibular schwannoma). Ménière disease typically results in low roaring tinnitus, while high-pitched tinnitus may suggest tumor or presbycusis. Sudden hearing loss occurs with viral neuritis or vascular processes that occlude the cochlear blood supply from the internal auditory artery, a terminal branch of the anterior inferior cerebellar artery or the basilar artery. This can also occur from compression by a tumor in the internal auditory canal. A stroke from occlusion of the anterior inferior cerebellar artery itself may cause infarction of the pons, with ipsilateral hearing loss, vestibular symptoms, gait ataxia, conjugate gaze palsy, ipsilateral facial paralysis, and sensory loss, as well as contralateral body loss of pain and temperature sensation. Combined symptoms of tinnitus and vertigo are inner ear symptoms and indicate involvement of the cochlea, vestibular labyrinth, auditory nerve, or a combination of structures.

**CANALITH REPOSITIONING MANEUVERS**

First-line therapy for benign paroxysmal positional vertigo (BPPV) includes canalith repositioning maneuvers such as the Epley maneuver. The maneuver uses gravity to pull the canalith debris out of the affected semicircular canal and into the utricle, where it lodges in the otolithic membrane of the macula (Plate 2-33). The maneuver requires sequential movement of the head into four positions, staying in each position for approximately 30 seconds. The Epley maneuver is most

useful for posterior canal BPPV. The patient begins in the upright sitting position with the head turned 45 degrees toward the affected side (in the figure, the right ear is affected). The patient then lies down with the affected ear facing the ground and the head in 30 degrees of neck extension (Dix-Hallpike test). Vertigo and nystagmus is elicited, and the position is

maintained until the nystagmus ceases. Then the head is rolled 180 degrees until the affected ear is facing up. The patient rolls onto their side until their nose points toward the floor. The patient then rapidly returns to the seated position, where he or she stays for 30 more seconds. The maneuver is repeated until no nystagmus is elicited.

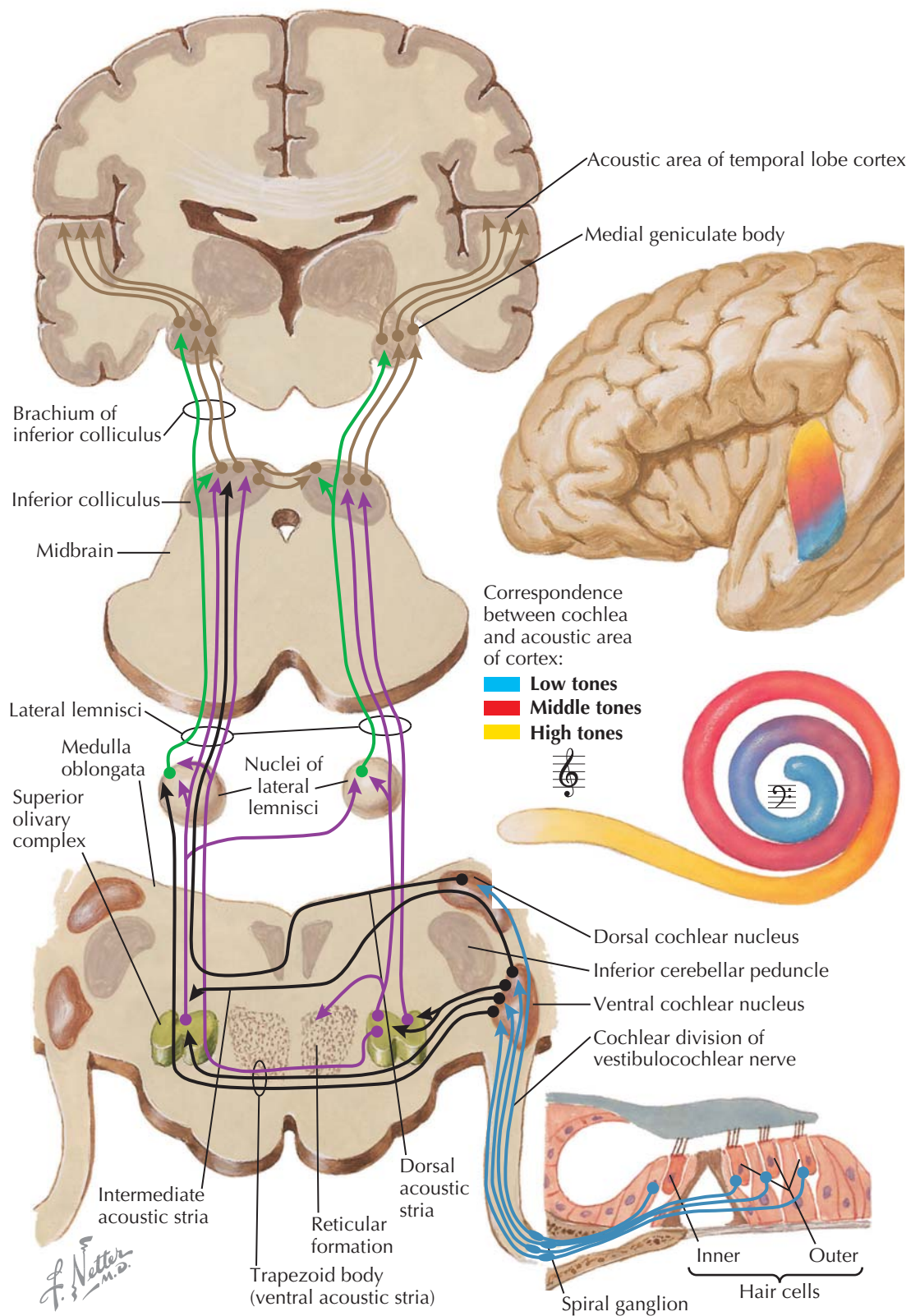


## AFFERENT AUDITORY PATHWAYS

Auditory afferent fibers enter the brainstem as the vestibulocochlear nerve and then branch to the dorsal and ventral cochlear nuclei located in the medulla. Neurons in these nuclei have similar properties: each is excited by a relatively narrow range of sound frequencies and may be inhibited by tones outside that range. Within each nucleus, neurons sensitive to different frequencies are arranged in an orderly manner, which gives rise to a tonotopic distribution within the nucleus.

The fibers of the ventral cochlear nucleus then project to the superior olive located in the medulla. The fibers then project by way of the lateral lemnisci nuclei and other relays to the inferior colliculus. The dorsal cochlear nucleus projects directly to the inferior colliculus via the lateral lemniscus. Fibers from both the ventral and dorsal cochlear nucleus project from the inferior colliculus to the medial geniculate nucleus of the thalamus. Within the colliculi signals from both ears interact on their way toward the cerebral cortex. From the medial geniculate nucleus, the auditory signals travel to the primary auditory cortex, which is located in the temporal lobe and is Brodmann's area 41. Despite the extensive intermixing among afferent fibers, the bulk of the neural activity reaching the auditory cortex originates in the contralateral ear. Tonotopic ordering is preserved throughout the ascending pathway so that individual cortical regions are sensitive to specific frequencies. The width of the band of frequencies to which an individual neuron responds is approximately the same in area 41 as at the level of the cochlear nuclei.

In the analysis of acoustic information, relatively little is known about the function of the various stages along the auditory pathway. Neurons within the superior olivary complex are specifically adapted for analyzing the location of a sound in space. Olivary neurons receive excitatory input from the contralateral cochlear nuclei and inhibitory input from the ipsilateral cochlear nuclei. In the medial portion of the complex, where neurons are sensitive to sounds of low frequency, these opposing inputs result in individual neurons becoming attuned to a fixed time delay between the arrival of sound at each ear. In the lateral portion of the complex, where neurons are sensitive to higher frequencies, the opposing inputs result in neurons becoming sensitive to differences in the intensity of sound reaching each ear. The entire auditory pathway, including the auditory cortex, must be intact for sound localization to take place. Similarly, auditory structures as far as the level of the inferior colliculus are required for frequency discrimination, even though neurons at all levels of the auditory pathway are frequency selective.



Intensity discriminations, on the other hand, can be made following the destruction of the inferior colliculus and higher centers. Such discrimination may involve the collateral pathways that relay auditory signals to the brainstem reticular formation. These pathways are probably also involved in the reflex reaction to a sudden sound.

**Disorders.** A common auditory pathway deficit is vestibular schwannoma. The patient suffers loss of sound

localization, diminished speech discrimination, tinnitus, imbalance, and diminution of the stapedius reflex. Nerve-type deafness can be caused by toxins (e.g., arsenic, lead, quinine) and by antibiotics such as streptomycin, which can also damage the cochlea directly. Because of the multisynaptic and highly complex system of crossed pathways, damage to auditory brainstem tracts and nuclei by trauma, tumors, or vascular disorders results in only slight hearing impairment.

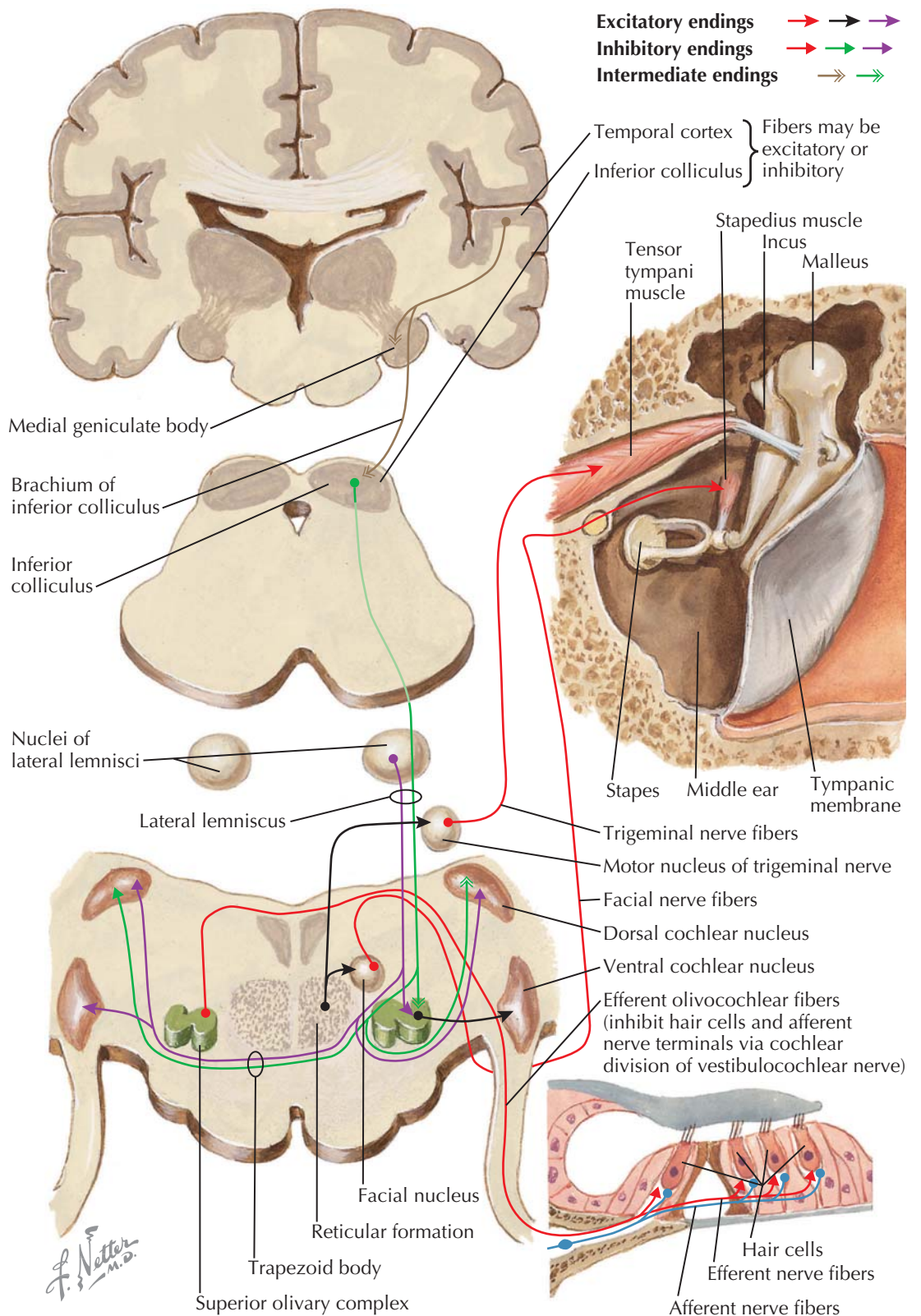
## CENTRIFUGAL AUDITORY PATHWAYS

In addition to the afferent neural pathways that carry auditory information from the cochlea to the higher centers, there is a parallel, descending efferent pathway named the centrifugal pathway. Within the brain, such connections arise from each of the areas involved in the auditory system, including the primary auditory cortex, and project to nuclei one or two levels below their point of origin. Individual connections may be either excitatory or inhibitory, but the centrifugal pathways appear to be activated by the inhibition of transmission of auditory signals through the ascending auditory pathways.

Centrifugal auditory pathways also include efferent projections to the sensory hair cells of the cochlea and to the muscles of the middle ear. The cochlear efferent fibers originate from a group of neurons on the medial side of the contralateral superior olive and pass to the cochlea via the crossed olivocochlear bundle and the cochlear division of the vestibulocochlear nerve. They are joined by a smaller number of fibers, which originate in the ipsilateral superior olive. The olivocochlear efferent pathway comprises the medial olivocochlear system (MOCS) and the lateral olivocochlear system (LOCS). The MOCS has large cell bodies in the medial and anterior olivary regions and innervate the outer hair cells of the cochlea. The LOCS has small cell bodies in and around the lateral superior olive and innervate the afferent dendrites beneath the inner hair cells of the ipsilateral cochlea. The large outer hair cell endings are primarily cholinergic, whereas the axodendritic synapses beneath the inner hair cells contain acetylcholine, dopamine, enkephalins, and other peptides. The efferent fibers produce hyperpolarization in the cochlear hair cells and afferent nerve terminals, thereby decreasing the afferent response produced when sound reaches the cochlea. Fibers innervating the muscles of the middle ear originate in the trigeminal motor nucleus and the facial nucleus (the tensor tympani muscle and the stapedius muscle). By contracting, these muscles decrease the transmission of sound vibrations from the eardrum to the oval window by way of the ossicles (incus, malleus, and stapes).

Several functions have been proposed for the centrifugal auditory pathways. One possibility is that efferent impulses can suppress the auditory nerve afferent responses to sound, thus preventing damage from too strong a stimulus. The middle ear muscles contract during loud noises and self-initiated vocalization, thereby helping to prevent saturation or damage of the cochlear receptors. Sound-activated efferent fibers in the olivocochlear bundle may additionally contribute to the suppression of sensory input that could saturate the central nervous pathways. A related mechanism, possibly also mediated by olivocochlear fibers, is improved auditory discrimination by the attenuation of loud background noise.

The phenomenon of selective attention to auditory signals is likely also to be an effect of the centrifugal auditory pathways. This "attentional filter" is absent in



de-efferented humans. Evidence also shows that habituation to repeated auditory stimuli occurs with inhibition of the cochlear nuclei.

Finally, efferent olivocochlear pathways participate in auditory discrimination. Neurons at higher levels of the auditory pathway tend to respond to transient changes in auditory input rather than to steady signals.

Centrifugal inhibition may be a factor in eliminating responses to steady signals, thus accentuating sensitivity to transient ones. Together with the inhibition that takes place within each level of the auditory system, it may also contribute to the processes that sharpen neuronal responses by restricting the ranges of the frequencies to which each neuron responds.

## VESTIBULAR RECEPTORS

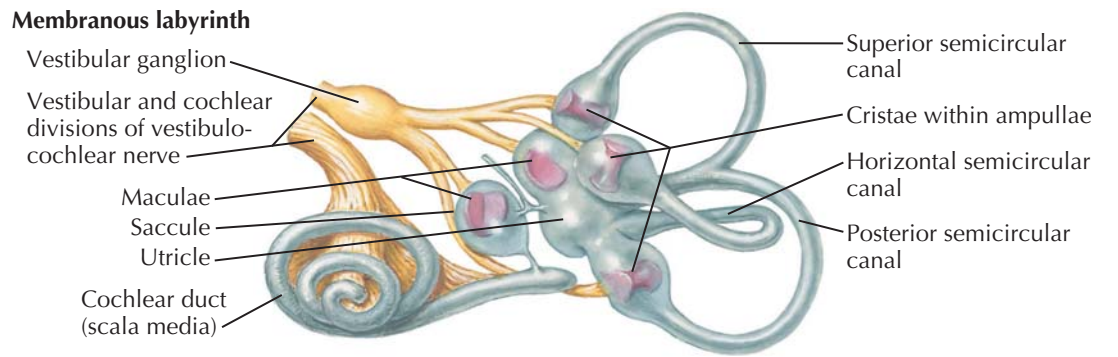
The *membranous labyrinth* is a specialized structure that converts angular and linear accelerations of the head into neuronal signals. This labyrinth is filled with potassium-rich endolymph and is a system of thin-walled intercommunicating tubes and ducts situated within the petrous part of the temporal bone at the base of the skull. The membranous labyrinth consists of the otolith organ (utricle and saccule) and three semicircular canals. The utricle and saccule contain specialized receptors called maculae that specifically respond to linear acceleration. Connected to the utricle are the three semicircular canals oriented at right angles to each other, which respond to angular acceleration. Within swellings of the canals, called ampullae, are the specialized receptors, the cristae.

The vestibular labyrinth receives dual innervation. The distal axonal processes of the bipolar vestibular afferent neurons have cell bodies housed in the vestibular ganglion of the internal acoustic meatus. The afferent axons terminate on the mechanoreceptive vestibular hair cells that serve as the sensory transducers. The vestibular efferent fibers originate in the brainstem.

*Hair cells* are specialized epithelial cells that have ciliary tufts protruding from their apical surface. Type I cells are goblet shaped and are enclosed in a nerve chalice. Synaptic terminals packed with vesicles are in contact with the base of the chalice and are likely presynaptic terminals. Type II hair cells are more common and have small terminal synaptic boutons. They are innervated by thin nerve branches that form synaptic contact with the bottom of the cell. The efferent endings are presynaptic to the hair cell and filled with vesicles. Type I hair cells are thought to be more sensitive than those of type II. Efferent fibers form typical chemical synapses with hair cells or with afferent terminals, which act to increase the discharge rate of afferent fibers and to modulate their response to mechanical stimuli.

The apical ends of both types of hair cells bear a tuft of 40 or more sensory hairs, or stereocilia, whose bases are embedded in a stiff cuticle, and a single, lower kinocilium, which originates from a basal body and has a structure similar to that of a motile cilium. The entire group of hairs is joined together at its free end. The stimulus for the sensory hair cells is shearing displacement of the hair cells. Displacement of the sensory hair bundle in the direction in of the kinocilium is excitatory and results in depolarization of the hair cell and increased firing of the vestibular nerve fibers. In the opposite direction, the response is inhibitory and results in hyperpolarization of the hair cell and reduced firing of the vestibular nerve. Signal transduction in hair cells occurs via a direct gating mechanism in which the hair bundle deflection puts tension on membrane-bound, cation-selective ion channels located near the tip of the hair bundle. This increased tension opens the channel and allows calcium to enter the cell. The increased intracellular calcium promotes adaptation, which may activate molecular motors that adjust the tension of the transduction apparatus.

The *cristae and maculae* are especially sensitive to angular and linear acceleration and convert head movements to bending forces on the sensory hairs. The hair



### Section of crista

Opposite wall of ampulla

Gelatinous cupula

Hair tufts

Hair cells

Nerve fibers

Basement membrane

### Section of macula

Otoconia

Gelatinous otolithic membrane

Hair tuft

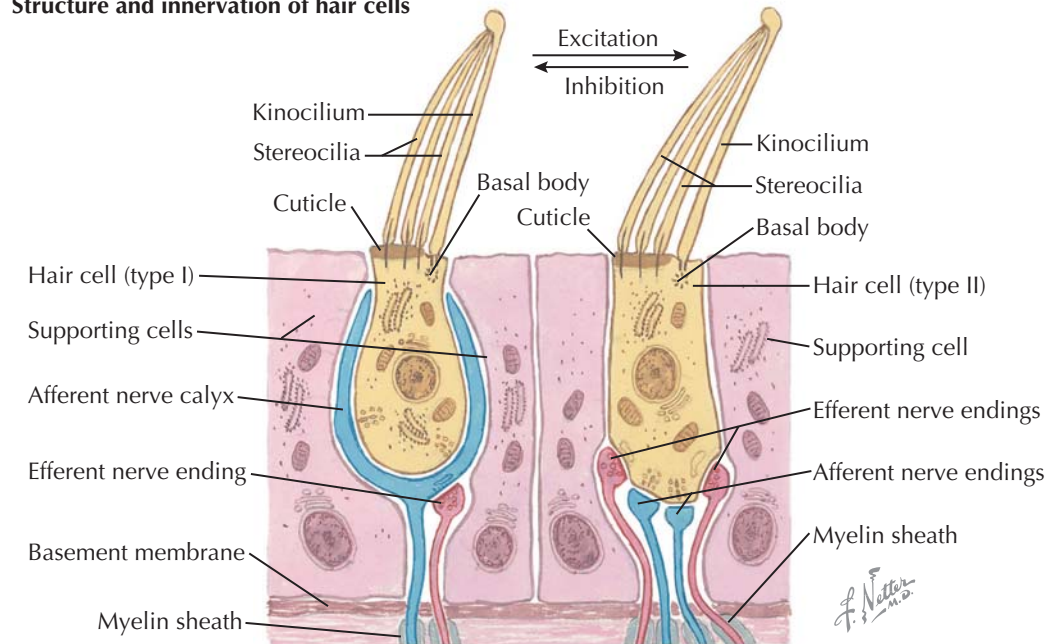
Hair cells

Supporting cells

Basement membrane

Nerve fibers

### Structure and innervation of hair cells



cells, the mechanoreceptors in the cristae, are embedded in a gelatinous mass called the cupula, which extends across the ampulla. During angular acceleration, there is displacement of the cupula and resultant bending of the sensory hairs. Because all hair cells in the cristae are oriented in the same direction as their kinocilia, this bending either increases or decreases the discharge rate of all the afferent fibers.

The hairs of the sensory cells found in the maculae of the saccule and utricle are embedded in a gelatinous otolithic membrane, which contains concretions of calcium carbonate called otoconia or otoliths. Because the otoconia are denser than the surrounding fluid, the otolithic membrane tends to move under the influence of linear acceleration. For instance, when the normally

horizontal utricular macula is tilted, the pull of gravity tends to make the otolithic membrane slide downward, thus bending the sensory hairs. Because the macula contains hair cells that have two different orientations, this bending increases the discharge rate of some utricular afferent fibers and slows the discharge rate of others. These signals are analyzed by the central nervous system (CNS) for information on the position of the head. The macula of the saccule is in a vertical position and is therefore sensitive to vertical acceleration. The saccule may also contribute to the sensing of head position when the head is oriented with one ear down.

The *vestibulospinal tracts* are discussed in the *spinal cord section*.

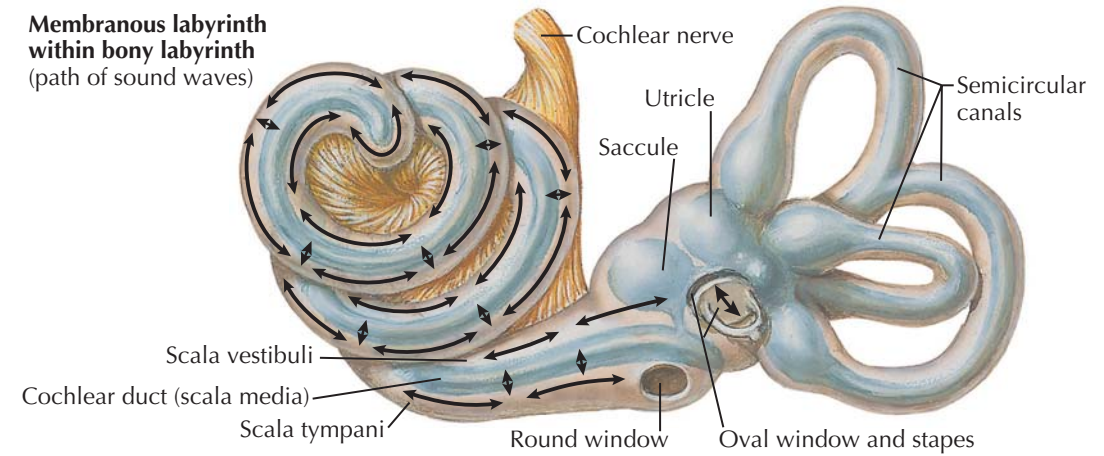
## COCHLEAR RECEPTORS

The human cochlea is a spiral channel located within the petrous portion of the temporal bone at the base of the skull. There are three fluid-filled chambers or *scala*e: the *scala vestibuli*, *scala media*, and *scala tympani*. The *scala media* is separated from the *scala vestibuli* by the vestibular (Reissner's) membrane and from the *scala tympani* by the stria vascularis. The *scala media* is filled with potassium-rich endolymph and is continuous with the vestibular labyrinth. The two remaining spaces, the *scala vestibuli* and the *scala tympani*, are external to the membranous labyrinth and are filled with perilymph. At the basal end of the *scala vestibuli* is the oval window, which is connected to the auditory ossicles that transmit vibration from the eardrum. At the basal end of the *scala tympani* is the membrane-covered round window, whose movements provide a compensatory release of the vibratory pressures at the oval window.

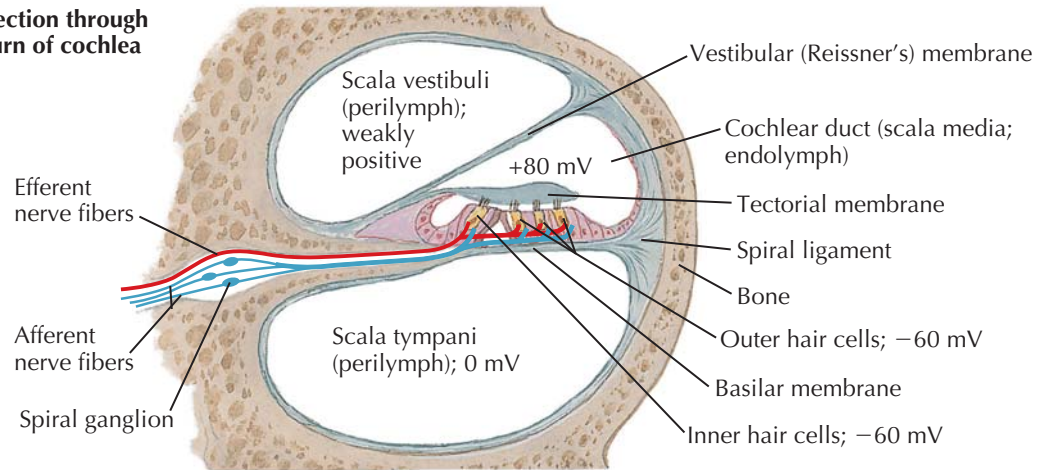
The cochlea receives dual innervation: afferent fibers, which originate from cell bodies in the adjacent spiral ganglion efferent fibers, which originate in the brainstem. Both types of fibers form synapses with sensory hair cells in the spiral organ of Corti (experimental studies have shown that activity in the efferent fibers can inhibit the discharge of cochlear afferent fibers). At the center of the organ of Corti is the tunnel of Corti, flanked by two sets of supporting rods of Corti (pillar cells). When hair cells are activated, impulse transmission is triggered in fibers of the spiral ganglion. The fibers then enter the brainstem as the cochlear nerve.

**Hearing.** The stapes ossicle bone transmits vibrations to the oval window on the outside of the cochlea. The perilymph vibrates in the *scala vestibuli* toward the helicotrema. Within the *scala media* is the receptor organ, the organ of Corti, which rests on top of the basilar membrane. The vibrations spread through the cochlea and induce vibrations in the basilar membrane, which are then transduced into afferent nerve excitation by the hair cells. The hair cells are arranged in inner and outer groups, and each cell is capped with 50 to 100 hairlike stereocilia that are imbedded in the tectorial membrane. The inner hair cells, about 3,500 in number, are arranged in a single row on the inner side of the inner rods of Corti; the 12,000 outer hair cells are longer and are arranged in three rows in the basal coil of the cochlea, and in four or five rows in the apical coil. Physiologic studies suggest that cochlear hair cells behave like their vestibular counterparts; bending of stereocilia in one direction leads to a depolarization of hair cells and an accelerated rate of nerve discharge, while bending in the opposite direction produces hyperpolarization and a slowing of discharge.

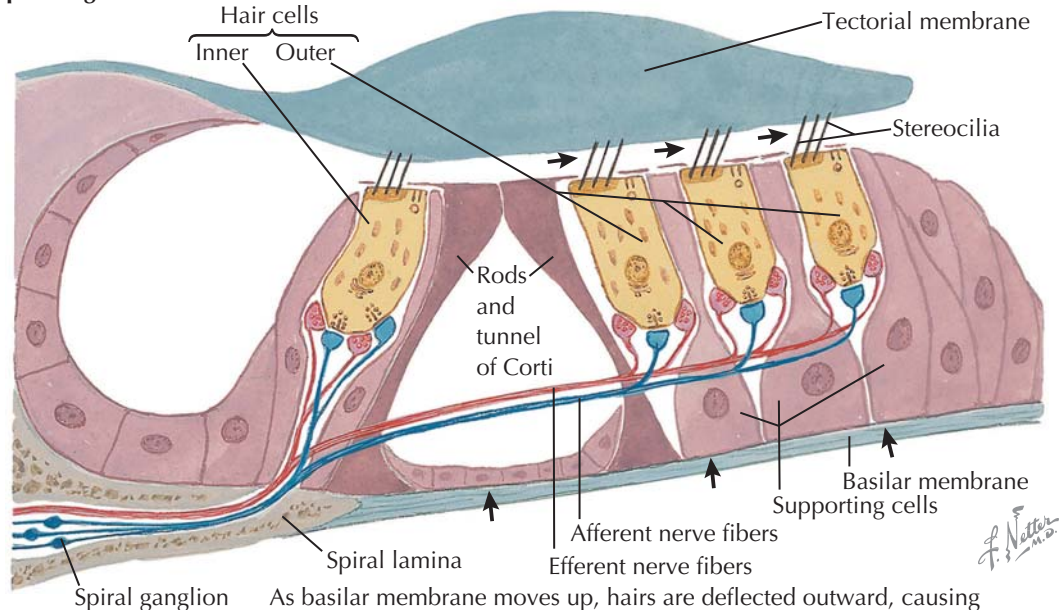
Another type of frequency analysis is based on the differences in the shape and stiffness of the basilar membrane located between the base and the apex of the cochlea. The basilar membrane vibrates to high frequencies at the base of the cochlea, where the basilar membrane is thinner and narrower, and to low frequencies at the apex. The dimensions of the basilar membrane gradually changes, so that for each vibration frequency between the two extremes, a somewhat



### Section through turn of cochlea



### Spiral organ of Corti



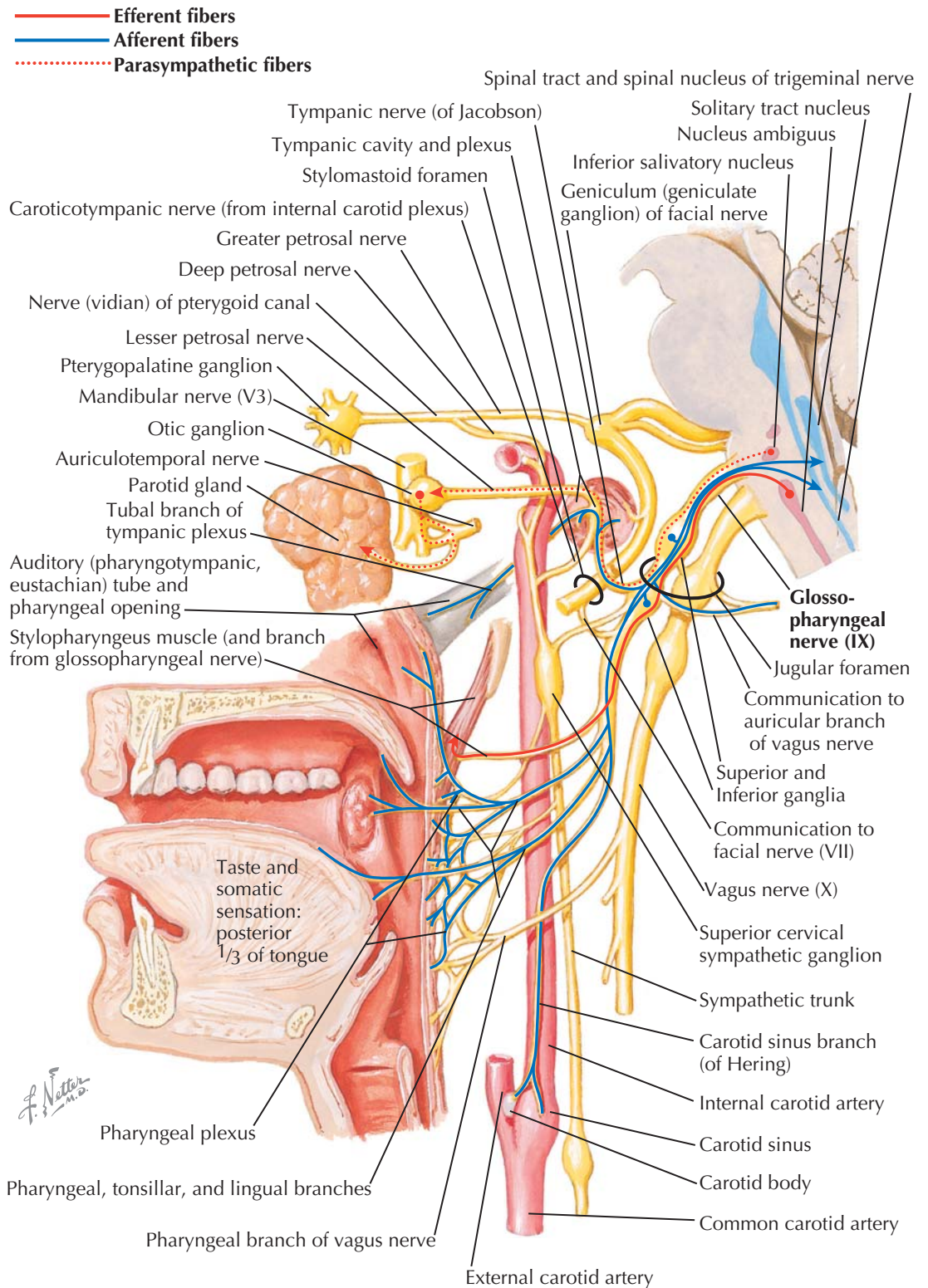
As basilar membrane moves up, hairs are deflected outward, causing depolarization of hair cells and increased firing of afferent nerve fibers

restricted region of the membrane, and hence a certain group of afferent fibers, responds most vigorously. The cochlea is therefore said to be tonotopically organized: each afferent fiber will respond to some extent to a range of frequencies, while within the range is one frequency to which it will respond most readily.

**Deafness.** The cochlea is often the source of deafness, either to a specific pitch or to a broad range of

frequencies. Head trauma can produce transient deafness, but severe injury involving a fracture of the petrous part of the temporal bone can cause permanent spiral ganglion or cochlear damage. Intense noise can cause temporary deafness; if it is sustained, permanent cochlear damage will result. The most common cause of deafness in adult life is otosclerosis, a non-neural process that results in the fixation of the stapes to the oval window.

GLOSSOPHARYNGEAL NERVE (IX)



**CRANIAL NERVE IX:  
 GLOSSOPHARYNGEAL NERVE  
 AND OTIC GANGLION**

The glossopharyngeal nerve is closely related functionally and anatomically to the vagus nerve. The two share common nuclei of origin and terminate in the ambiguus and dorsal vagal nuclei. The glossopharyngeal nerve also carries secretomotor fibers from the inferior salivatory nuclei, which are scattered in the reticular formation. As its name implies, the glossopharyngeal nerve contains sensory, motor, and parasympathetic fibers that supply parts of the tongue and pharynx. Its rootlets emerge from the dorsolateral sulcus of the medulla oblongata, rostral to those of the vagus nerve. The rootlets unite, and the nerve joins the vagus nerve and spinal accessory nerve to leave the skull through the central part of the jugular foramen between the inferior petrosal and sigmoid sinuses. Two ganglia, a small superior ganglion and a larger inferior ganglion, are situated on the nerve. The pseudounipolar nerve cells contained in both ganglia transmit multiple afferent impulses: special visceral sensation (taste) from the posterior third of the tongue and part of the soft palate; general visceral sensation (touch, pain, temperature) from the posterior third and adjacent areas of the tongue, fauces and pharynx soft palate, nasopharynx, and tragus of the ear; general somatic afferent impulses, via the tympanic branch of the glossopharyngeal nerve, from small areas of postauricular skin and from the meninges in the posterior cranial fossa; and visceral afferent impulses from the carotid sinus and body. The central cell processes concerned with taste end in the nucleus of the solitary tract; those concerned with visceral sensation end in the combined dorsal glossopharyngeal-vagal nucleus, and those concerned with general somatic afferents likely end in the spinal tract and nucleus of the trigeminal nerve.

From the jugular foramen, the nerve arches forward between the internal jugular vein and internal carotid artery, then passes deep to the styloid process, and curves behind the stylopharyngeus muscle (which it supplies) to the side of the pharynx. It pierces the superior constrictor muscle (or passes between this muscle and the middle constrictor) to enter the base of the tongue. It finally divides into branches that supply the mucous membrane over the posterior third of the tongue, fauces, palatine tonsil, and adjacent part of the pharynx and glands and vessels in these areas.

The lingual branches convey special and general sensations from the vallate papillae and the tongue behind

the sulcus terminalis. These branches are associated with small lingual ganglia. The ganglia act as relay centers for the preganglionic and postganglionic vaso-motor and secretomotor neurons. Another glossopharyngeal branch is the tympanic nerve (or Jacobson's nerve), which arises from the inferior (petrous) ganglion and ascends through the tympanic canaliculus to the middle ear (tympanic cavity), where it contributes to the tympanic plexus and gives off the lesser petrosal

nerve. The tympanic nerve contains sensory fibers that supply the middle ear, parasympathetic secretory fibers that serve the parotid gland, and sympathetic fibers that communicate with the carotid sinus. There are also communications with the auricular vagal branch, the superior vagal ganglion, the superior cervical sympathetic trunk ganglion, and the facial nerve. There is also a carotid sinus branch, a branch to supply the stylopharyngeus muscle, and several pharyngeal branches,



# CRANIAL NERVE X: VAGUS NERVE

## VAGAL NUCLEI

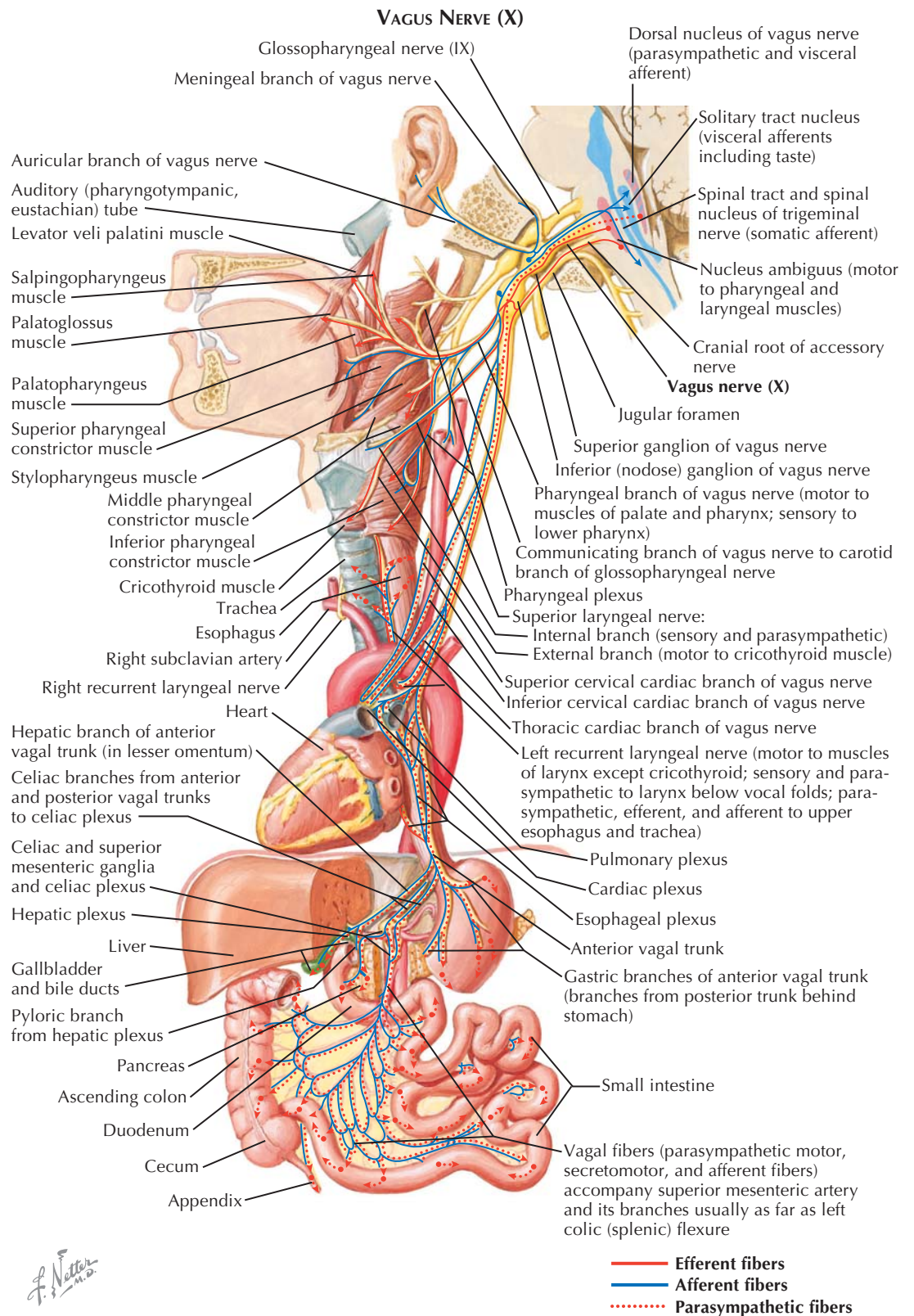
The glossopharyngeal nerve, vagus nerve, and cranial parts of accessory nerves may be considered as a single nerve complex because all have central connections with the dorsal vagal nucleus, solitary tract nucleus, and nucleus ambiguus.

The dorsal vagal nucleus is a mixed nucleus that represents fused visceral afferent and efferent columns of neurons. It consists of a longitudinal column of cells lying beneath the vagal trigone in the fourth ventricle floor, lateral to the hypoglossal nucleus, extending nearly the length of the medulla oblongata. The special and general visceral afferent fibers ending in the nucleus are the central processes of pseudounipolar sensory cells in the inferior vagal ganglion (or nodose ganglion); peripheral processes of the sensory cells convey impulses from the heart, aorta, trachea, bronchi, lungs, most of the alimentary tract (from the lower pharynx almost to the left colic flexure), liver, pancreas, and possibly from the kidneys. Sensory fibers that carry taste sensation from the epiglottis, pharynx, and hard and soft palates are also located in the nodose ganglion. Preganglionic efferent fibers carrying impulses for the same structures originate in the dorsal vagal nuclei and are distributed through direct vagal branches to the viscera or through branches of the cardiac, celiac, and abdominal plexuses (anterior and posterior vagal trunks). Vagal preganglionic fibers synapse in ganglia located near or within the viscera they innervate. Because of this arrangement, vagal parasympathetic postganglionic fibers are relatively short and more limited in their distribution than their sympathetic counterparts. The general somatic afferent fibers are the pseudounipolar cells of the superior vagal ganglia (or jugular ganglia) involved with sensory impulses conducted through the auricular and meningeal vagal branches, although the fibers in the latter branches may be derived from interconnections between ganglia and upper cervical spinal nerves. Central processes of the superior vagal ganglion cells probably end in the spinal nuclei of the trigeminal nerves.

The solitary tract nucleus receives afferent special sensory taste fibers, traveling in the superior laryngeal vagal branches from the mucous membrane of the epiglottis and the epiglottic valleculae. In addition, general visceral sensations from the larynx, oropharynx, linings of the thorax, and abdominal viscera also project to the solitary tract nucleus. The nucleus ambiguus develops from special visceral efferent columns and forms a row of discrete, multipolar neurons located deeply in the reticular formation of the medulla oblongata. Its axons emerge in the glossopharyngeal and vagal nerves and in the cranial parts of the accessory nerves. The glossopharyngeal and vagal fibers distribute mainly to the intrinsic laryngeal and pharyngeal muscles (except tensor veli palatine [CN V] and stylopharyngeus [CN IX]), while the accessory fibers serve mainly the sternocleidomastoid and the trapezius muscles. The lower precentral gyrus controls vagal motor function.

## VAGUS NERVE

The vagus nerve contains both afferent and efferent parasympathetic fibers that are widely distributed to visceral and vascular structures in the neck, thorax and abdomen, somatic sensory fibers in the auricular and meningeal branches, some special sensory fibers (taste)



*F. Netter M.D.*

of the superior laryngeal branch, and special visceral efferent fibers that arise in the nucleus ambiguus and are distributed mainly to laryngeal and pharyngeal muscles. Each vagus nerve emerges from the lateral medulla oblongata along the posterior sulcus as 8 to 10 rootlets above the rootlets of the glossopharyngeal nerve and cranial parts of the accessory nerve. The rootlets coalesce to form a nerve that exits the skull through the jugular foramen, together with the glossopharyngeal and accessory nerves, the sigmoid sinus, and several

other blood vessels. Within or inferior to the jugular foramen, the vagus nerve expands into superior and inferior ganglia. The superior vagal ganglion (jugular ganglion) communicates with the nearby superior cervical sympathetic trunk ganglion and the facial, glossopharyngeal and accessory nerves. It gives off a recurrent branch to the meninges of the posterior cranial fossa, an auricular branch that carries somatic sensory impulses from parts of the tympanic membrane and the external acoustic

**CRANIAL NERVE X: VAGUS NERVE** (Continued)

meatus, and a pharyngeal branch that, along with the glossopharyngeal nerve, forms the pharyngeal plexus and sends motor fibers to the muscles of the soft palate and pharynx.

The inferior vagal ganglion (nodose ganglion) is connected with the cranial part of the accessory nerve. It communicates with the superior cervical sympathetic trunk ganglion, the hypoglossal nerve, and the loop between the first and second cervical spinal nerves. It gives off pharyngeal and superior laryngeal branches (which divide into a motor external ramus to the cricothyroid muscle and an internal ramus that pierces the thyrohyoid and sends sensory fibers to the larynx) and inconstant carotid rami, which assist the glossopharyngeal nerve in innervating the carotid sinus and body.

Below its inferior ganglion, the vagus nerve descends within a homolateral carotid sheath, shared with the internal jugular vein and carotid artery, to the thoracic inlet. The vagus nerve intercommunicates with filaments from the cervical sympathetic trunks or branches so that it is a mixed parasymphathetic-symphathetic nerve from the neck downward. Within the neck, the vagus gives off the cardiac rami; these branches join the sympathetic fibers via the cardiac plexus of the heart.

**VAGAL NERVE BRANCHES IN THE THORAX**

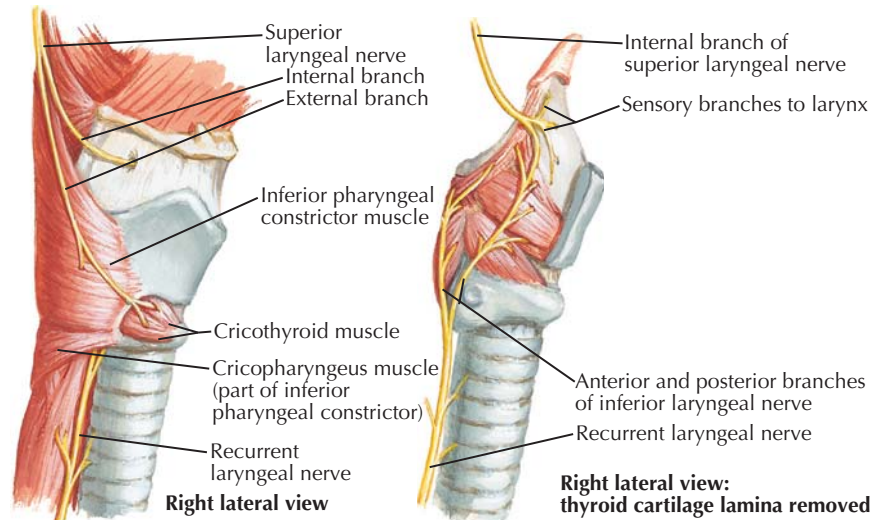
The right vagus nerve enters the thorax behind the internal jugular vein and in front of the first part of the subclavian artery. Here it gives off the right recurrent laryngeal nerve, which hooks under the artery before ascending to the larynx. The recurrent laryngeal nerves divide into anterior and posterior rami and supply the larynx. The main nerve climbs posteromedially, behind the right brachiocephalic vein and the superior vena cava, and runs medial to the azygos vein to reach the root of the right lung, where it splits into smaller anterior and larger posterior branches, both of which contribute rami to the anterior and posterior pulmonary plexuses.

The left vagus nerve enters the thorax between the left common carotid and left subclavian arteries, behind the left brachiocephalic vein. It crosses the left side of the aortic arch, giving off the left recurrent laryngeal nerve; thereafter, as on the right side, it participates in the formation of the pulmonary and esophageal plexuses. The left recurrent laryngeal nerve passes underneath the aorta on the outer side of the ligamentum arteriosum and then ascends to the larynx. The left recurrent laryngeal nerve, with the right recurrent laryngeal nerve, innervates the laryngeal muscles (all except the cricothyroids, which are supplied by the external ramus of the superior laryngeal nerve).

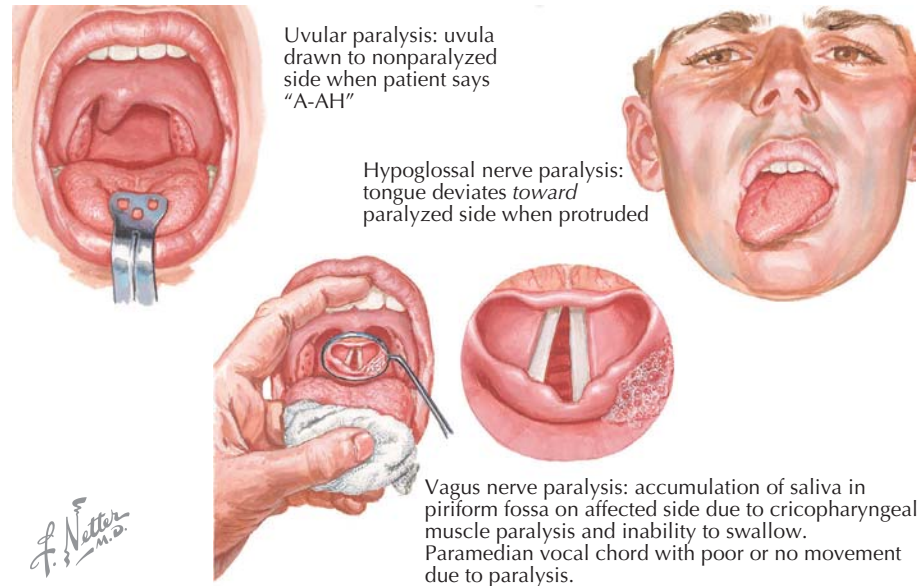
The vagal pulmonary branches, along with filaments derived from the second to fifth or sixth thoracic sympathetic trunk ganglia, form anterior and posterior pulmonary plexuses. The pulmonary plexuses become dispersed around the vascular and bronchial structures, and some of their terminal filaments reach the peripheral portion of the lungs. Along the course of the larger bronchi, small ganglia provide relay stations for the preganglionic parasympathetic (vagal) fibers. The sympathetic fibers relay outside the organs, primarily in the sympathetic trunk ganglia. Sympathetic and parasympathetic pulmonary afferent fibers are also present.

The esophageal plexus forms below the lung roots as the vagus nerves break up into two to four parts and travel on the esophagus as it descends through the posterior mediastinum, then divide and reunite to form the

**Motor and sensory branches from the vagus nerve**



**Neurogenic disorders of mouth and pharynx (X and XII)**



esophageal plexus. Filaments from the thoracic parts of the sympathetic trunks and from the thoracic splanchnic nerves then join the esophageal plexus. Most of the branches of the right vagus incline posteriorly, while most of those from the left vagus incline anteriorly. Above the esophageal hiatus in the diaphragm, the meshes of the esophageal plexus become reconstituted into two or more vagal trunks, which travel by way of the esophageal diaphragm to innervate the abdominal viscera.

**VAGAL NERVE DISORDERS**

Bilateral supranuclear lesions may result in dysphagia, spastic dysarthria, emotional incontinence, pharyngeal and laryngeal incoordination, and altered sensation with an increased risk of aspiration. Unilateral supranuclear lesions rarely cause vagal dysfunction because the supranuclear control is bilateral. Dysphagia rarely occurs with unilateral precentral gyrus lesions.

Isolated proximal vagus nerve injuries are rare because lesions at or around the jugular foramen, such as those caused by trauma or tumors (glomus vagale paragangliomas), usually also injure the glossopharyngeal and accessory nerves. Unilateral vagus neuropathy may cause ipsilateral pharyngeal (e.g., dysphagia) and laryngeal

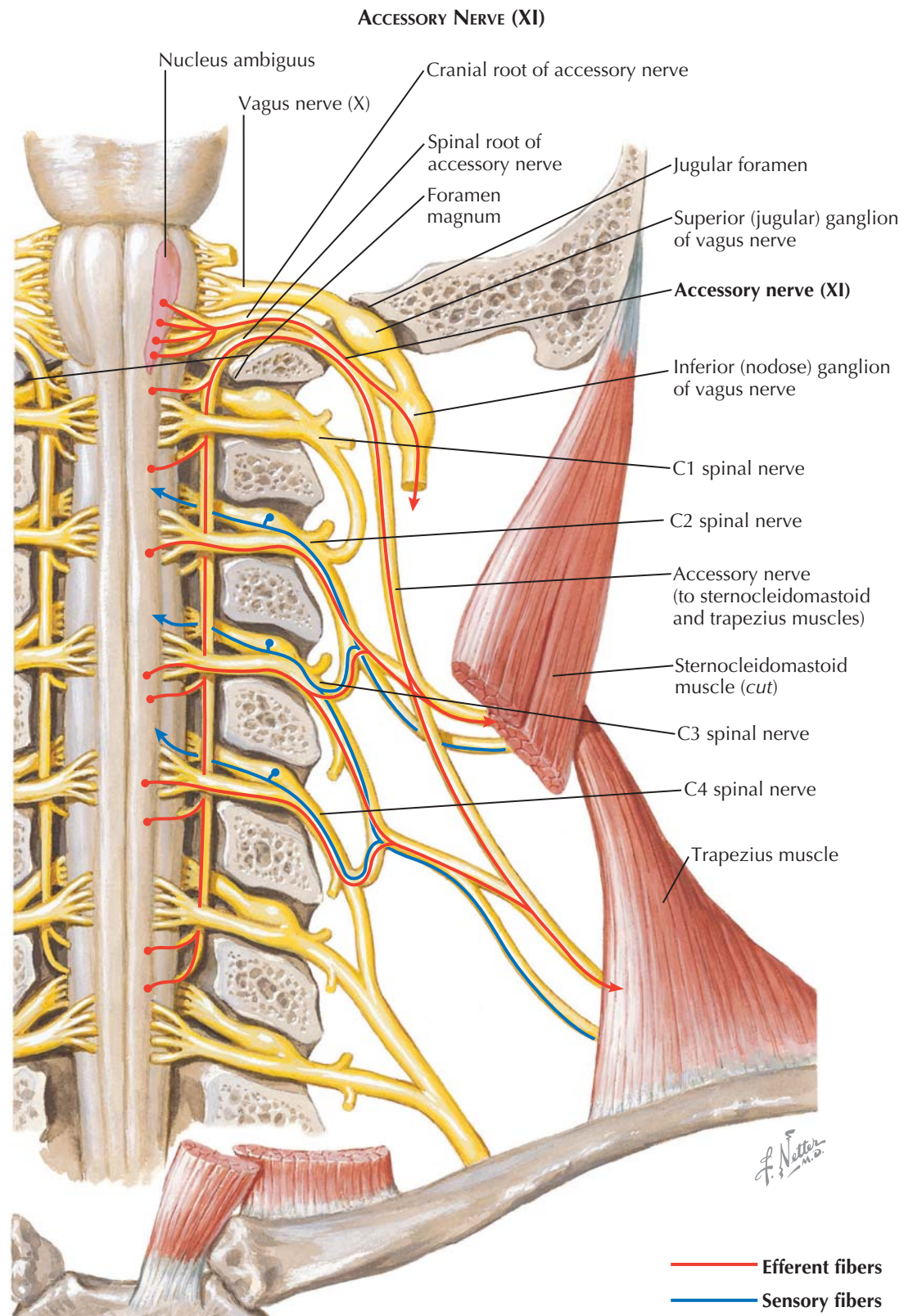
(e.g., change in voice) weakness and impaired sensation with inadequate airway protection. Ipsilateral soft palate weakness may manifest as nasal regurgitation and nasal speech. Ipsilateral vocal cord paralysis may be the result of superior laryngeal nerve injury (cricothyroid muscle for vocal cord lengthening and laryngeal sensation) or more distal recurrent laryngeal neuropathy (cricoaarytenoids and thyroarytenoid muscles for adduction, abduction, and shortening of vocal cords). Recurrent laryngeal nerve lesions affect all laryngeal muscles, with the exception of the cricothyroid, which is innervated by the superior laryngeal nerve. Superior laryngeal neuropathy leads to loss of high vocal pitches, a weak voice, and aspiration due to altered laryngeal sensation. The causes include thyroiditis, local neck infections, or surgery; however, a good proportion of cases are idiopathic. Recurrent laryngeal nerve lesions cause variable symptoms, from slight voice fatigue and breathiness to significantly altered speech, hoarseness, and ineffective cough. When unilateral, they typically cause transient hoarseness. Common causes include thyroid, neck, and lung tumors; thoracic surgery; and, rarely, thyroiditis. Diabetes, amyloidosis, and other acquired etiologies of polyneuropathy may cause vagal neuropathy, usually accompanied by symptoms and signs of more widespread sensorimotor polyneuropathy.



## CRANIAL NERVE XI: ACCESSORY NERVE

The *spinal root* fibers arise from an elongated strand of motor neurons, the *spinal nucleus of the accessory nerve*, which is a special visceral efferent column that extends from the lower medulla oblongata to the dorsolateral part of the ventral gray column of the upper five or six cervical cord segments. The fibers emerge as a series of rootlets from the side of the spinal cord via the lateral funiculus, about midway between the anterior and posterior rootlets of the upper five or six cervical spinal nerves, and coalesce as they ascend behind the denticulate ligament in the subarachnoid space to form the spinal root which enters the skull through the *foramen magnum* behind the vertebral artery. Arching upward and outward, the spinal root unites over a short distance with the cranial root to leave the skull through the *jugular foramen* in the same dural sheath as the vagus nerve.

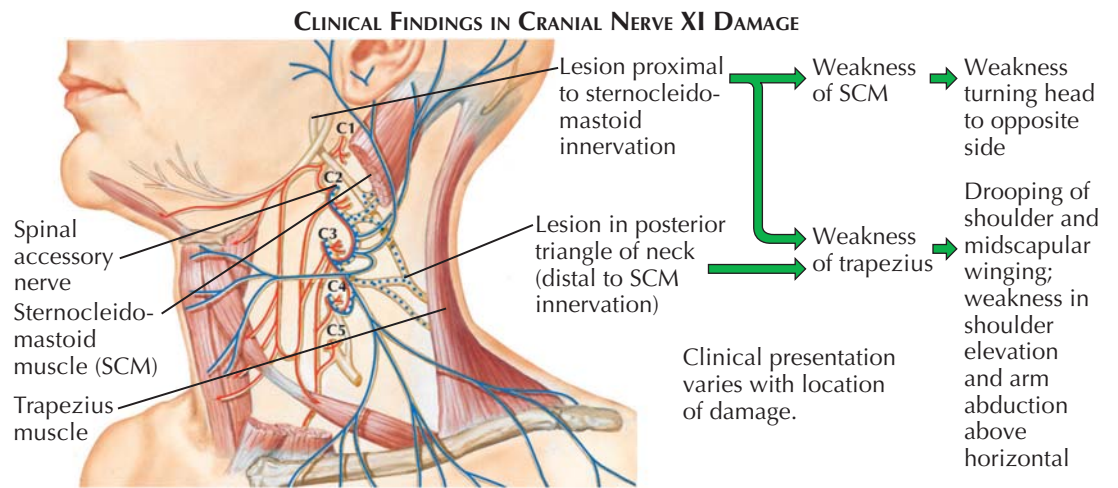
The cranial root is the smaller of the two portions of the accessory nerve. Although it is discussed in this section, it is often considered as a part of the vagus nerve rather than the accessory nerve proper because the cranial component rapidly joins the vagus nerve and serves the same function as other vagal nerve fibers. The cranial nerve root fibers, classified as special visceral efferent, arise mainly from neurons in the caudal half of the *nucleus ambiguus* of the medulla, with probable minor contributions from the *dorsal vagal nucleus*. The fibers of the cranial root emerge as four to six rootlets from the dorsolateral sulcus, posterior to the olive, below the roots of the vagus nerve. The cranial root runs laterally to briefly join the larger spinal root before passing through the *jugular foramen* in the same dural and arachnoid sheath as the vagus nerve. The cranial root communicates by one or two filaments with the superior vagal ganglion; however, most of its fibers continue as the *internal branch of the accessory nerve*, which joins the vagus nerve at or near its inferior ganglion and provides most of the motor fibers to the



pharynx and larynx. The *pharyngeal branches* supply the muscles of the soft palate (except the tensor veli palatini) and contribute motor fibers to the pharyngeal plexus. The fibers in the *recurrent laryngeal vagal branches* supply all the intrinsic laryngeal muscles except the cricothyroid.

**Course of Accessory Nerve.** The cranial and spinal root fibers separate distal to the jugular foramen to form the *internal* and *external branches* of the accessory

nerve. The internal branch joins the vagus nerve as described above. The external accessory branch innervates the sternocleidomastoid and trapezius muscles. The external branch of the accessory nerve usually passes between the internal carotid artery and the internal jugular vein and runs obliquely downward and backward over the transverse process of the atlas and deep to the styloid process, occipital artery, and posterior belly of the digastric muscle before piercing the deep



**Clinical findings in CN XI nerve damage**

**CRANIAL NERVE XI: ACCESSORY NERVE (Continued)**

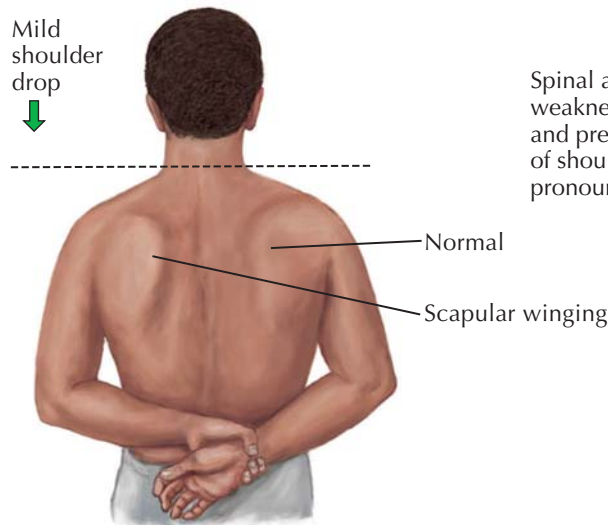
surface of the *sternocleidomastoid muscle*. It passes through and supplies this muscle and emerges from the midpoint of the posterior sternocleidomastoid border. The external branch then descends across the posterior cervical triangle and crosses over the levator scapulae muscle to disappear under the trapezius muscle about 2 cm above the clavicle. Along its course, the external branch receives branches from the second, third, and fourth cervical nerves.

**Supranuclear Innervation.** The trapezius and sternocleidomastoid muscles receive supranuclear innervation from the lower precentral gyrus. The corticobulbar fibers supplying the trapezius are primarily crossed. The corticobulbar fibers controlling the sternocleidomastoid muscle are thought to terminate mainly in the ipsilateral nuclei.

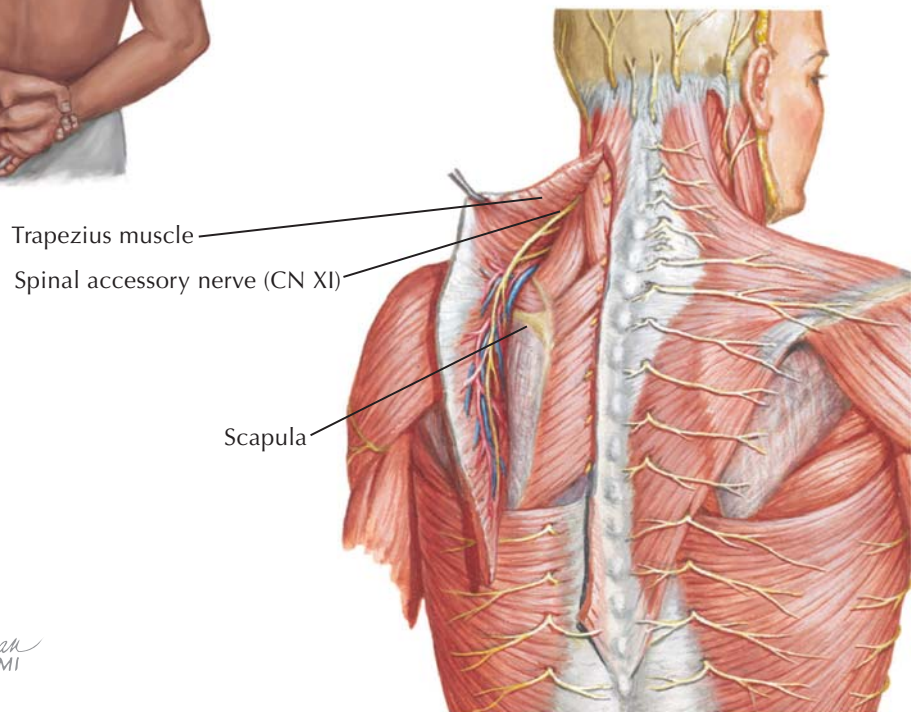
**DISORDERS**

Proximal spinal accessory nerve lesions cause weakness of the sternocleidomastoid and the trapezius muscles. Damage within the posterior triangle of the neck spares the sternocleidomastoid, resulting in trapezius weakness. With sternocleidomastoid weakness, there is weakness of turning the head to the opposite side. Involvement of the trapezius muscle manifests as drooping of the shoulder and mild upper scapular winging away from the chest wall, with slight lateral displacement. Weakness in shoulder elevation and arm abduction above horizontal is typical. Most individuals with accessory neuropathies also present with shoulder and neck pain.

The most common site of isolated accessory neuropathy is in the neck. The close association of the accessory nerve with the superficial cervical lymph nodes makes it vulnerable to iatrogenic damage during lymph node biopsy or radical neck dissection. The accessory nerve can also be directly compressed by swollen lymph nodes or other solid tumors. Rarely, accessory neuropathy occurs after blunt or penetrating



Spinal accessory (CN XI) nerve lesions cause weakness of trapezius muscle on involved side and present with mild shoulder droop. Weakness of shoulder elevation and scapular winging most pronounced on arm abduction.



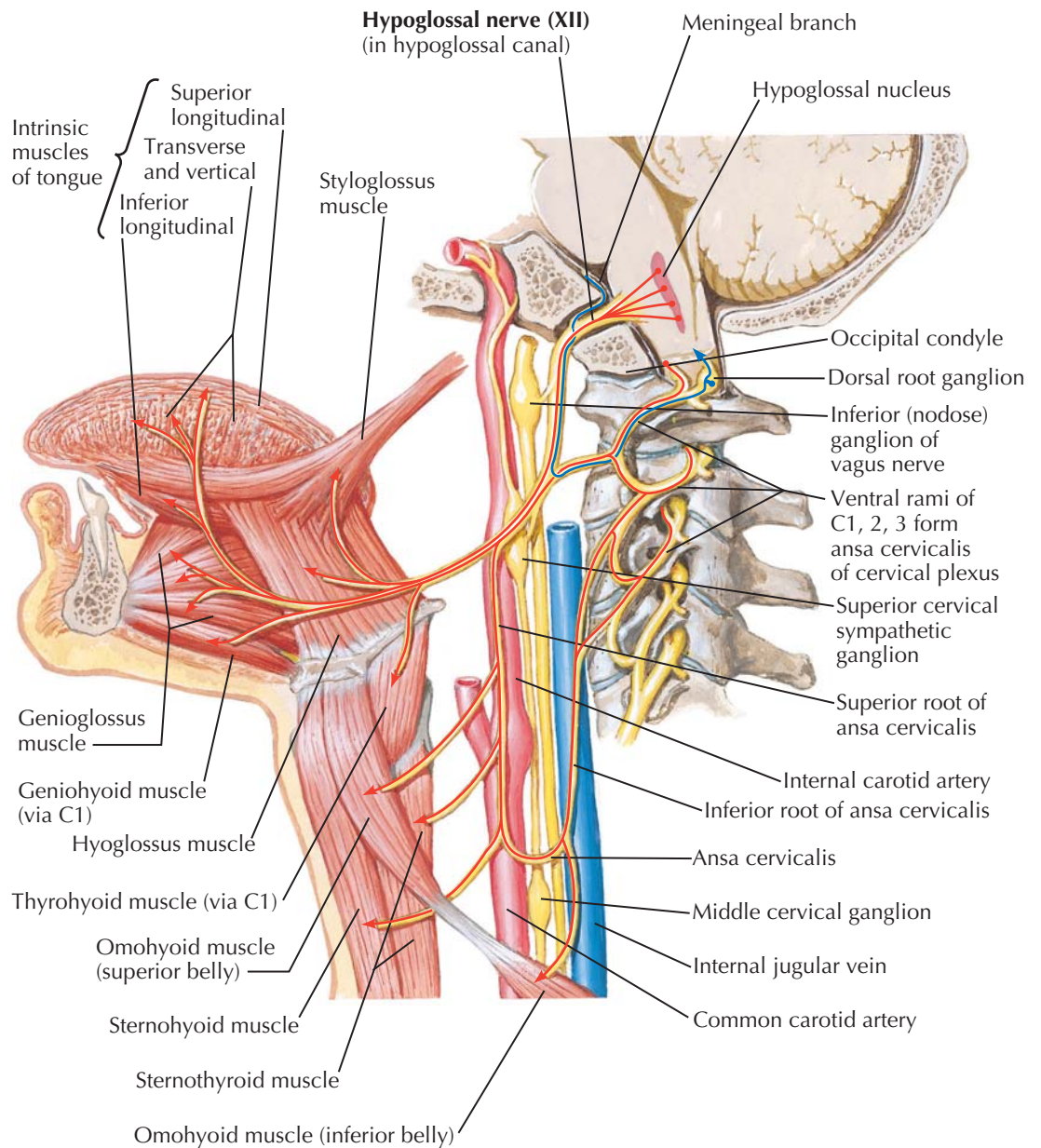
*F. Netter M.D. J. Moore CMI K. Marziani*

neck trauma, or it is due to radiation injury with treatment of neck tumors. Damage can occur after carotid endarterectomy or jugular vein cannulation because of the nerve's proximity to large neck vessels. Accessory neuropathy is sometimes seen as part of brachial plexitis or Parsonage-Turner syndrome.

Intrinsic spinal cord lesions, posterior fossa meningiomas, or metastases near the jugular foramen or foramen magnum may injure the intraspinal and

intracranial portions of the accessory nerve but usually also affect the glossopharyngeal and vagal nerves. At times, the hypoglossal nerve exiting through the adjacent hypoglossal foramen is involved, as well as the adjacent sympathetic chain fibers, resulting in an associated Horner syndrome. Disorders of the anterior horn cell, including motor neuron disease, syringomyelia, and poliomyelitis, may involve the nuclei of the accessory nerve.

**HYPOGLOSSAL NERVE (XII)**



*F. Netter M.D.*

— Efferent fibers  
— Afferent fibers

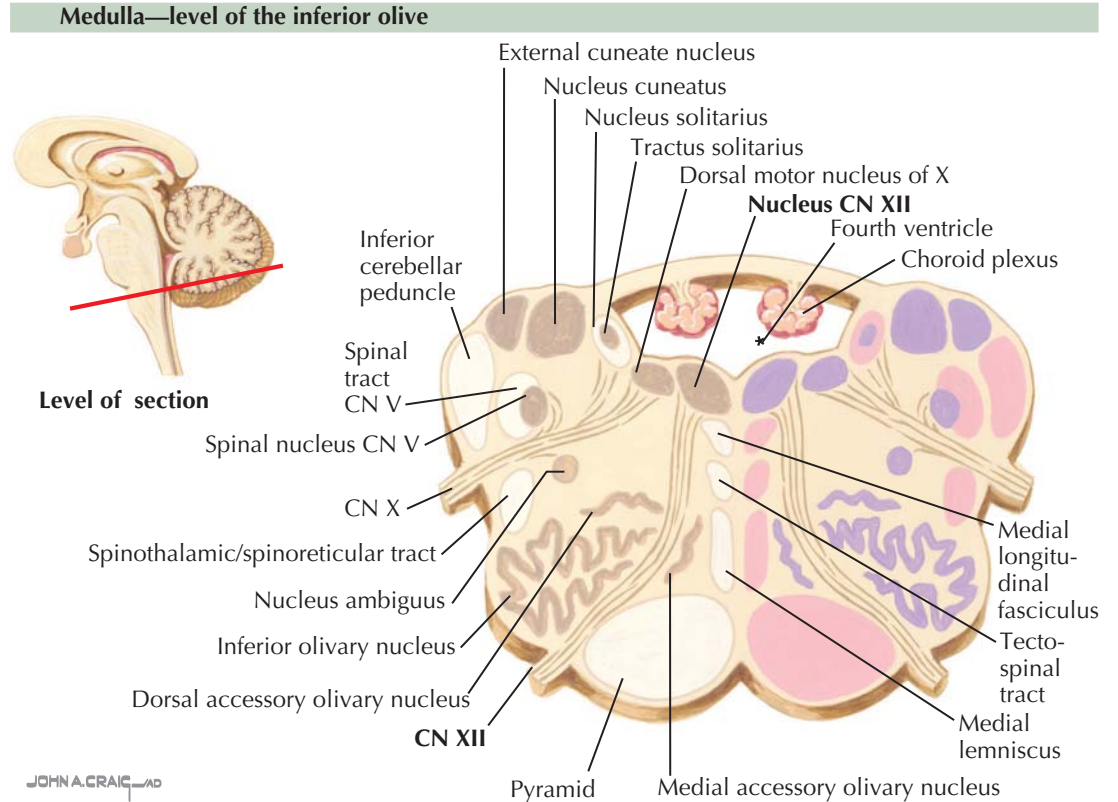
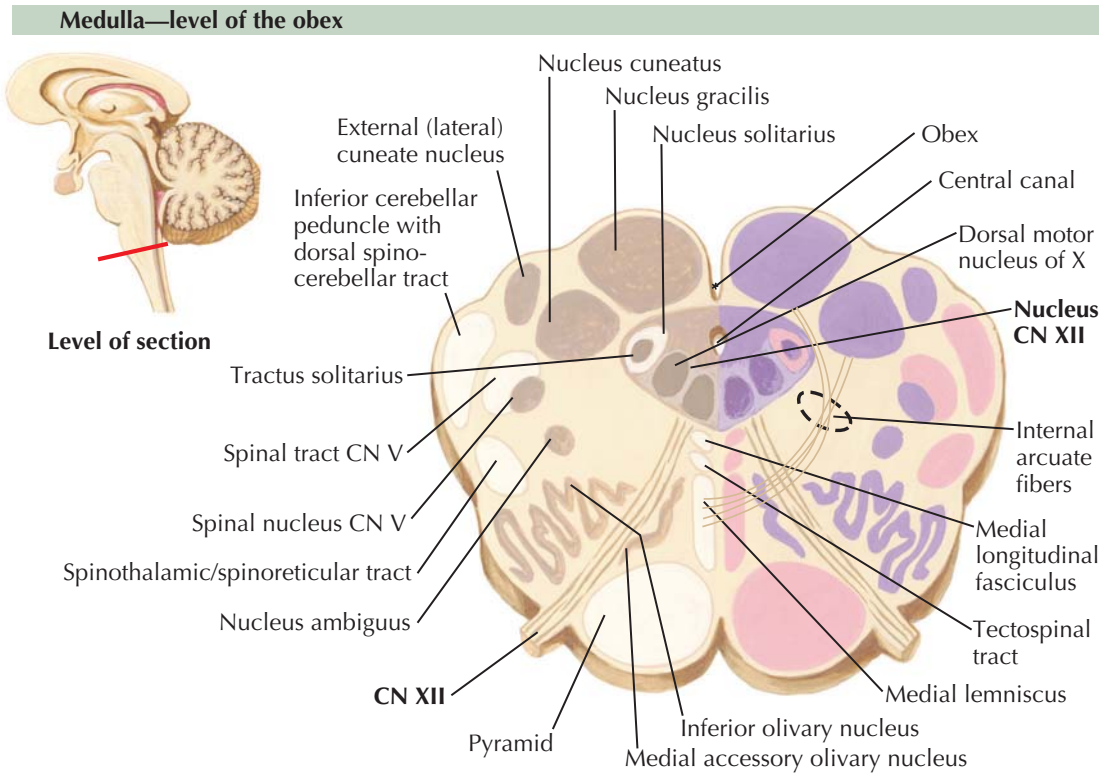
**CRANIAL NERVE XII:  
HYPOGLOSSAL NERVE**

The hypoglossal nerve is the motor nerve of the tongue. The fibers of the hypoglossal nerve arise from the hypoglossal nucleus. This nucleus is a column of cells that lies beneath the hypoglossal trigone of the fourth ventricle floor in the medulla oblongata. It extends from the pontomedullary junction to the caudal most medulla oblongata. The main nucleus comprises subnuclei that are likely associated with the individual muscles they innervate. The fibers leave the hypoglossal nucleus and travel anterolaterally through the medullary reticular formation and the medial portion of the inferior olive and then course laterally to the medial longitudinal fasciculus, medial lemniscus, and pyramid. The hypoglossal nerve fibers leave the medulla between the inferior olivary complex and the pyramid. The fibers are positioned medial to cranial nerves IX, X, and XI. The rootlets fuse into two and then pass through the dura mater and hypoglossal canal of the skull. As the nerve roots exit into the upper neck, the two roots join to form a single nerve that runs near the internal carotid artery, internal jugular vein, and cranial nerves IX, X, and XI before passing over

the internal and external carotid arteries and beneath the stylohyoid, mylohyoid, and digastric muscles. After passing between the mylohyoid and hypoglossal muscles, the nerve divides into many branches. These lingual branches convey general somatic efferent fiber to the tongue and supply most of the extrinsic (hyoglossus, styloglossus, genioglossus, and chondroglossus) and all the intrinsic muscles of the tongue (the transverse and vertical lingual muscles, as well as the

superior and inferior longitudinal muscles). The other branches are derived from the cervical plexus and are not connected with the hypoglossal nuclei. These include the superior root of the ansa cervicalis, the meningeal branch, and nerves to the thyrohyoid and geniohyoid muscles. These are derived from the anterior rami of the first and second cervical nerves. The inferior root of the ansa cervicalis gives off branches to the omohyoid, sternothyroid, and sternohyoid muscles

**HYPGLOSSAL NERVE INTERMEDULLARY COURSE**



**CRANIAL NERVE XII:  
HYPOGLOSSAL NERVE (Continued)**

and is derived from the anterior rami of the second and third cervical nerves.

Supranuclear control of the tongue is mediated by the corticobulbar fibers, which originate in the lower portion of the precentral gyrus. The fibers controlling the genioglossus muscles are crossed, but other tongue muscles have bilateral supranuclear control.

**DISORDERS OF THE HYPOGLOSSAL NUCLEUS AND NERVE**

Supranuclear lesions affecting the corticobulbar fibers above their decussation result in weakness of the contralateral half of the tongue. Bilateral upper motor neuron lesions affecting the corticobulbar tracts cause significant tongue dysfunction and spastic dysarthria. Dorsal medullary lesions causing bilateral lower motor neuron lesions of the tongue are extremely rare but are seen on occasion with tumors or syringobulbia. The medial medullary syndrome (Dejerine anterior bulbar

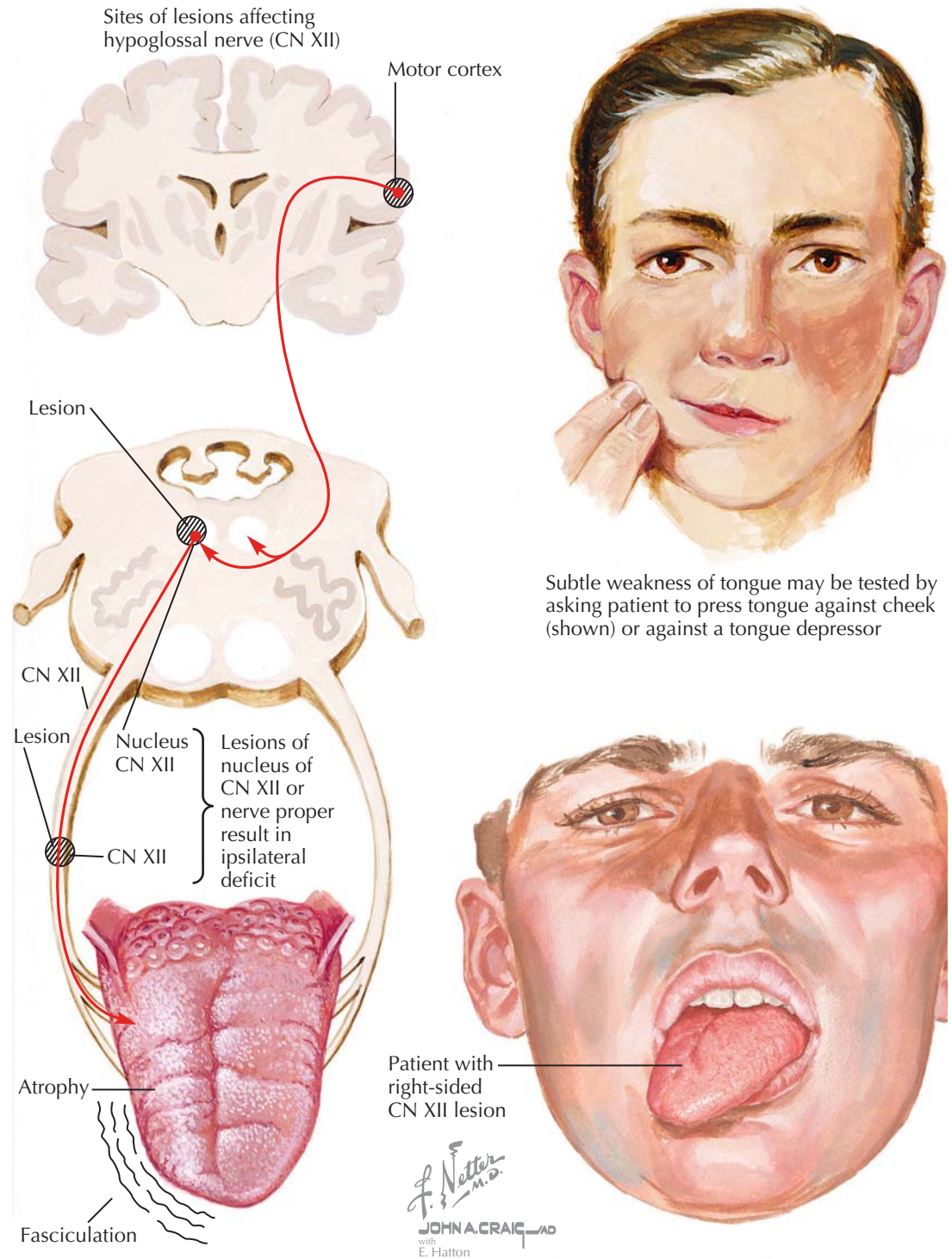
syndrome) is caused by occlusion of the anterior spinal artery supplying the medial lemniscus, hypoglossal nerve, and ipsilateral pyramids. Intramedullary lesions may also result from cavernomas, multiple sclerosis, syringobulbia, and intramedullary tumors. These lesions may present with ipsilateral paresis, atrophy, and fasciculations of the tongue, often accompanied by contralateral hemiplegia and contralateral loss of position and vibratory sensation. Anterior horn cell disorders,

such as amyotrophic lateral sclerosis, frequently affect the hypoglossal nucleus.

Peripheral nerve lesions of the hypoglossal nerve result in tongue deviation to the side of the lesion. Atrophy, fasciculations, and increased furrowing may be observed on the side of the lesion. It is best to allow the tongue to rest on the floor of the mouth when assessing for fasciculations. Because of the close proximity to cranial nerves IX, X, and XI in the hypoglossal canal,

JOHN A. CRAIG, MD

DISORDERS OF HYPOGLOSSAL NUCLEUS AND NERVE



**CRANIAL NERVE XII:  
HYPOGLOSSAL NERVE** (Continued)

basilar skull lesions in this area may damage all four of these cranial nerves, resulting in weakness of the sternocleidomastoid, trapezius, tongue, pharyngeal and laryngeal muscles, accompanied by loss of taste on the posterior third of the tongue and hemianesthesia of the palate, pharynx, and larynx (Collard-Sicard syndrome). Occipital pain and ipsilateral hypoglossal nerve injury may occur with occipital condyle syndrome, which is usually the result of tumors or chronic inflammatory lesions. Isolated hypoglossal neuropathy may also occur as the result of carotid aneurysm, vascular entrapment, dissection, local infection, rheumatologic disease, neck radiation, or tumors.

Extra-axial intracranial lesions of the hypoglossal nerve are typically caused by neoplasm at the basal meninges or skull base. Examples of neoplasms that cause hypoglossal neuropathy include metastatic bronchial or breast carcinomas, lymphoma, meningiomas, chordoma, and cholesteatomas. The proximity of the

When hypoglossal nerve or its nucleus is damaged, atrophy and fasciculation of the tongue are noted on evaluation

hypoglossal and jugular foramina explains the frequent co-involvement of other lower cranial nerves (CN IX, X, XI) in cases caused by neoplasm. Jugular foramen lesions, such as glomus jugulare tumor (a rare hyper-vascular malignancy that arises from the paraganglionic tissue), can compress the hypoglossal nerve. Infectious or granulomatous lesions, such as tuberculosis and sarcoidosis, causing basal meningitis, may affect multiple cranial nerves, including the hypoglossal nerve. Primary

If hypoglossal nerve is affected on one side, the tongue often deviates toward the side of the lesion on protrusion (due to imbalance of genioglossus contraction)

bony processes (e.g., platybasia and Paget disease) have rarely been reported to affect the hypoglossal nerve. The close spatial relation between the hypoglossal nerve and the carotid artery makes this nerve vulnerable to primary carotid pathology within the neck and is occasionally seen with internal carotid artery dissection, neck surgery or carotid endarterectomy. Nasopharyngeal cancer and radiation therapy may damage the hypoglossal nerve in the neck.

# ILLUSTRATED CROSS SECTIONS OF THE HEAD SHOWING THE CRANIAL NERVES

Excerpted from Lee TC, Mukundan S. *Netter's Correlative Imaging: Neuroanatomy*. Philadelphia: Elsevier, 2015, pp 175-271.

For more from this publication visit <http://www.us.elsevierhealth.com/netter-clinical-science/netter-s-correlative-imaging-neuroanatomy-hardcover/9781437704150/>

### **OLFACTORY NERVE (CN I)**

*Axial*  
*Coronal*

### **OPTIC NERVE (CN II)**

*Axial*  
*Coronal*  
*Sagittal*

### **OCULOMOTOR NERVE (CN III)**

*Axial*  
*Coronal*

### **TROCHLEAR NERVE (CN IV)**

*Axial*  
*Coronal*

### **TRIGEMINAL NERVE (CN V)**

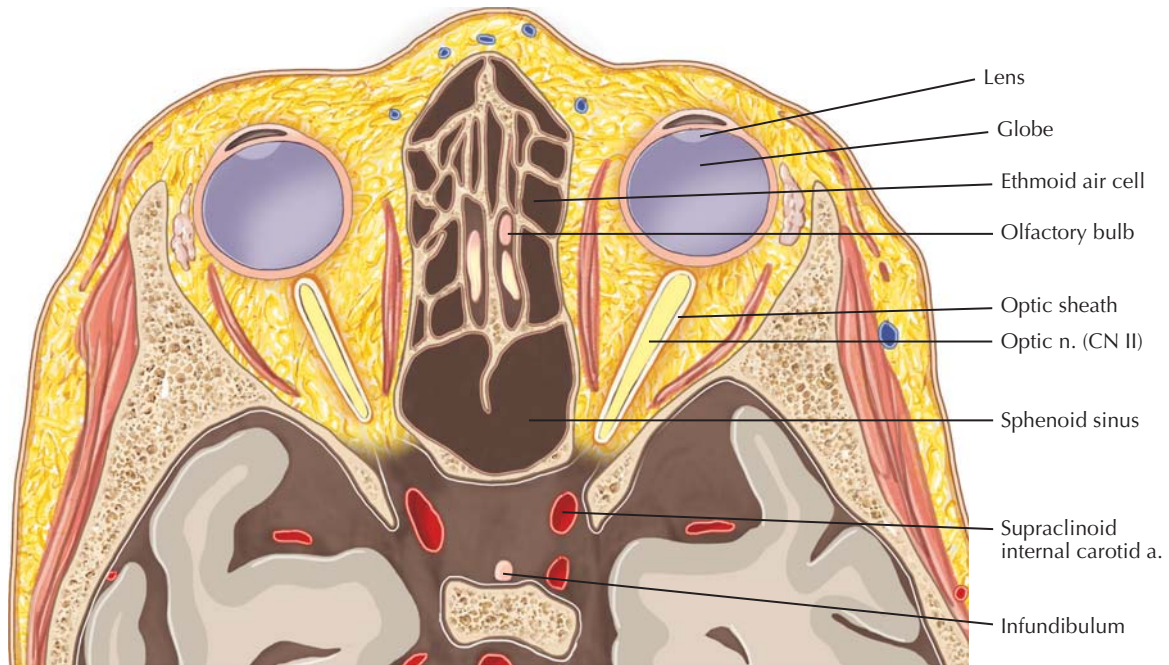
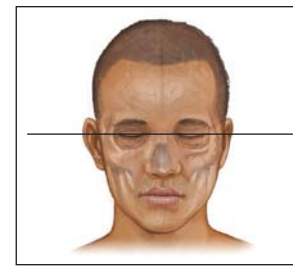
*Axial*  
*Sagittal*  
*Coronal*

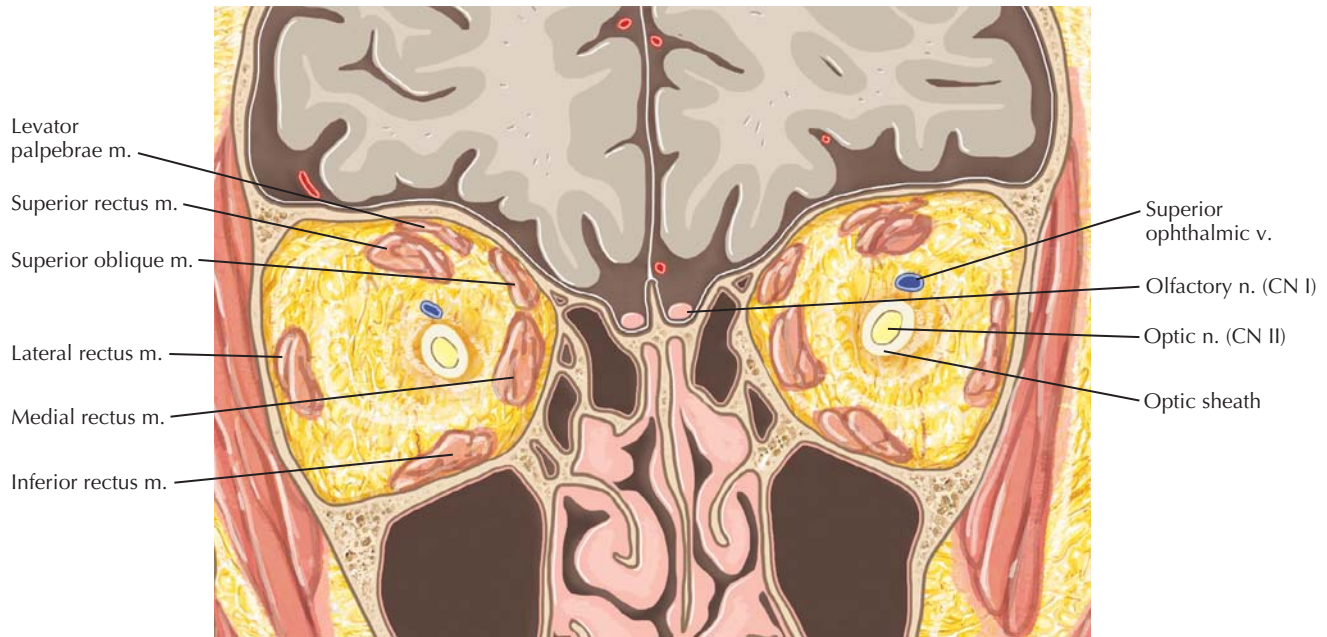
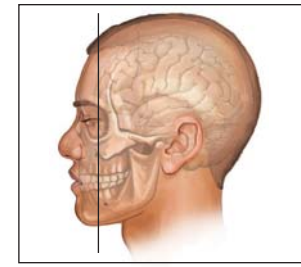
### **ABDUCENS NERVE (CN VI), FACIAL NERVE (CN VII), AND VESTIBULOCOCHLEAR NERVE (VIII)**

*Axial*  
*Sagittal*

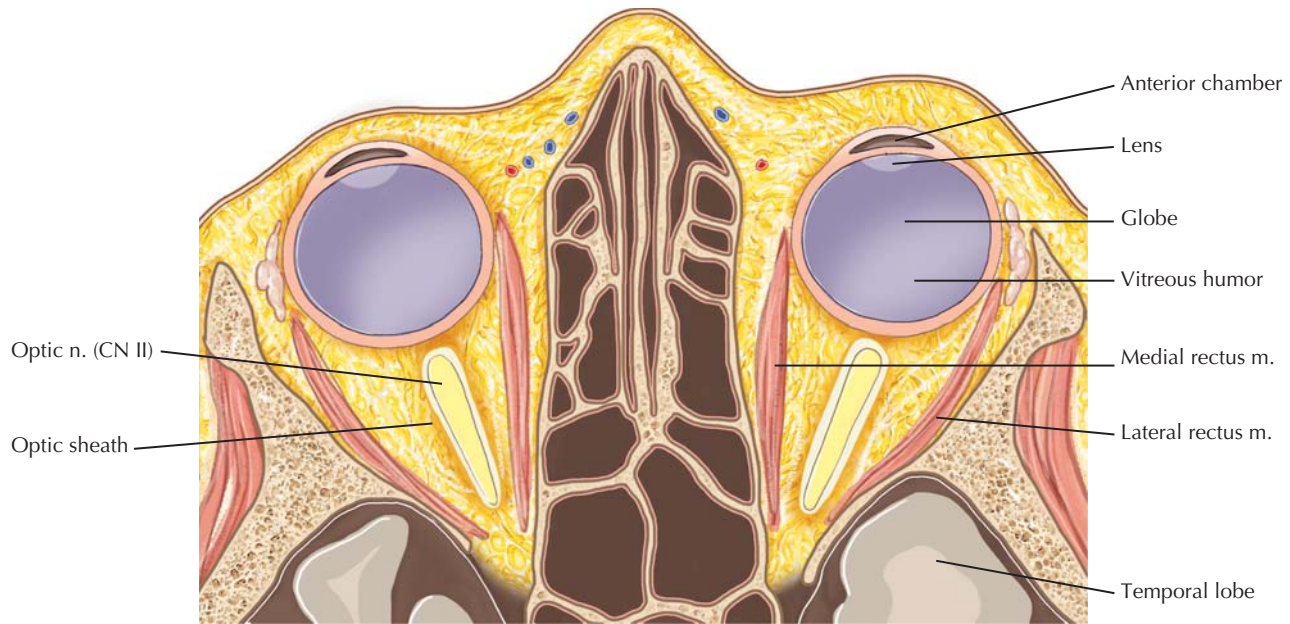
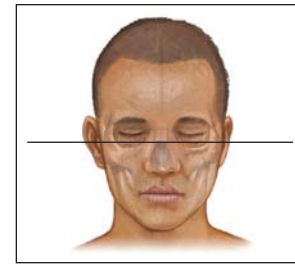
### **GLOSSOPHARYNGEAL NERVE (CN IX), VAGUS NERVE (CN X), ACCESSORY NERVE (CN XI), HYPOGLOSSAL NERVE (CN XII)**

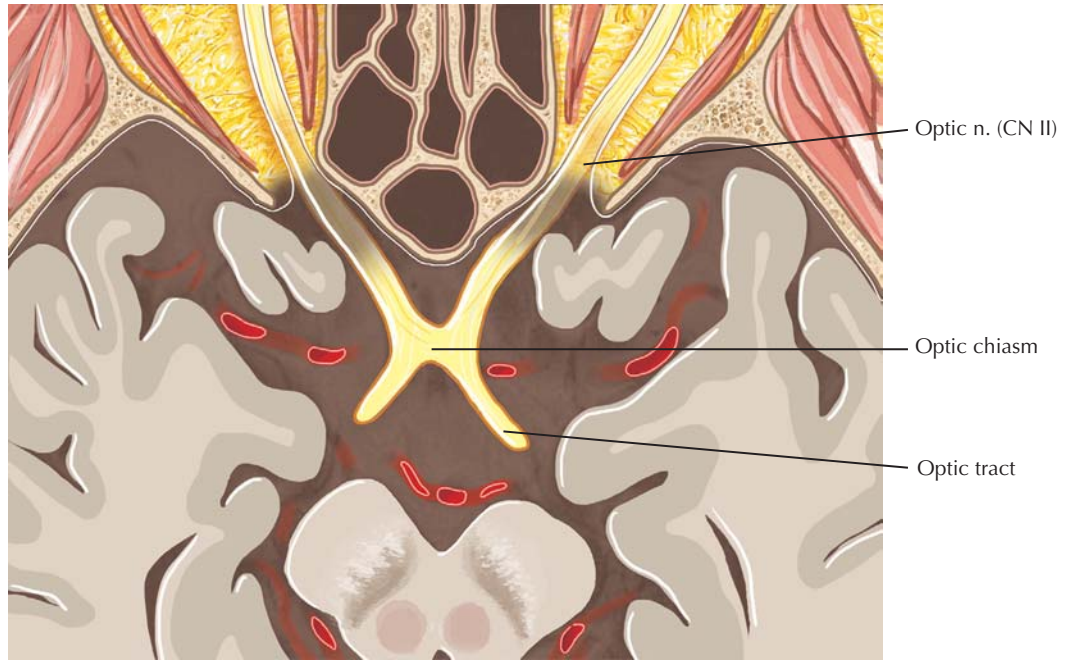
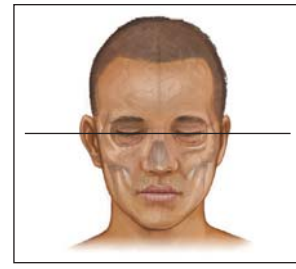
*Axial*

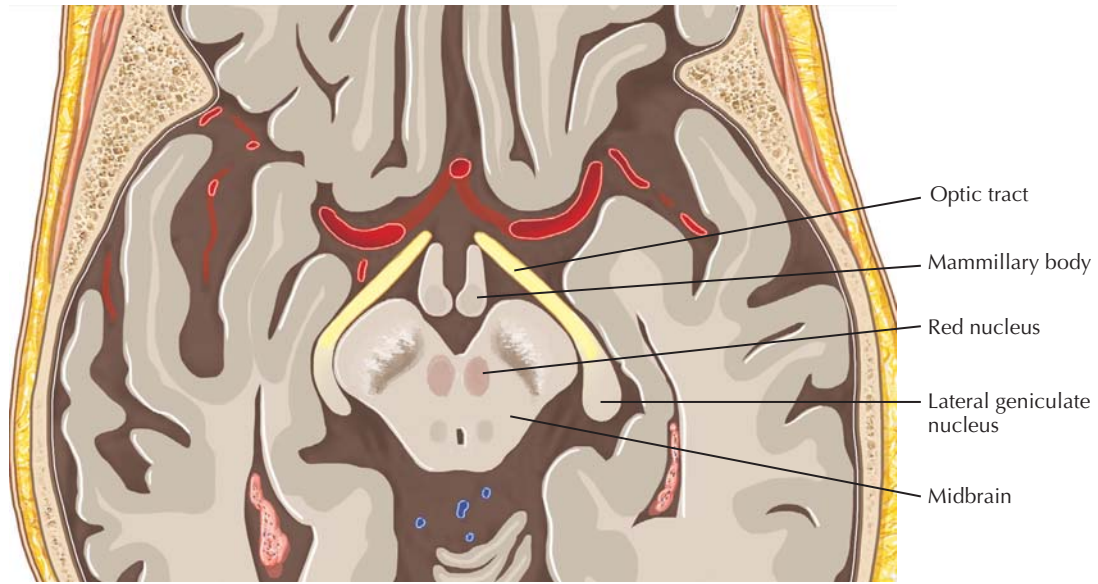
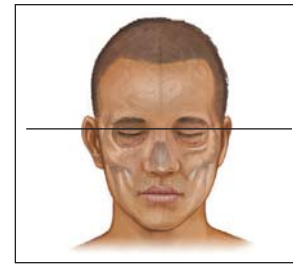


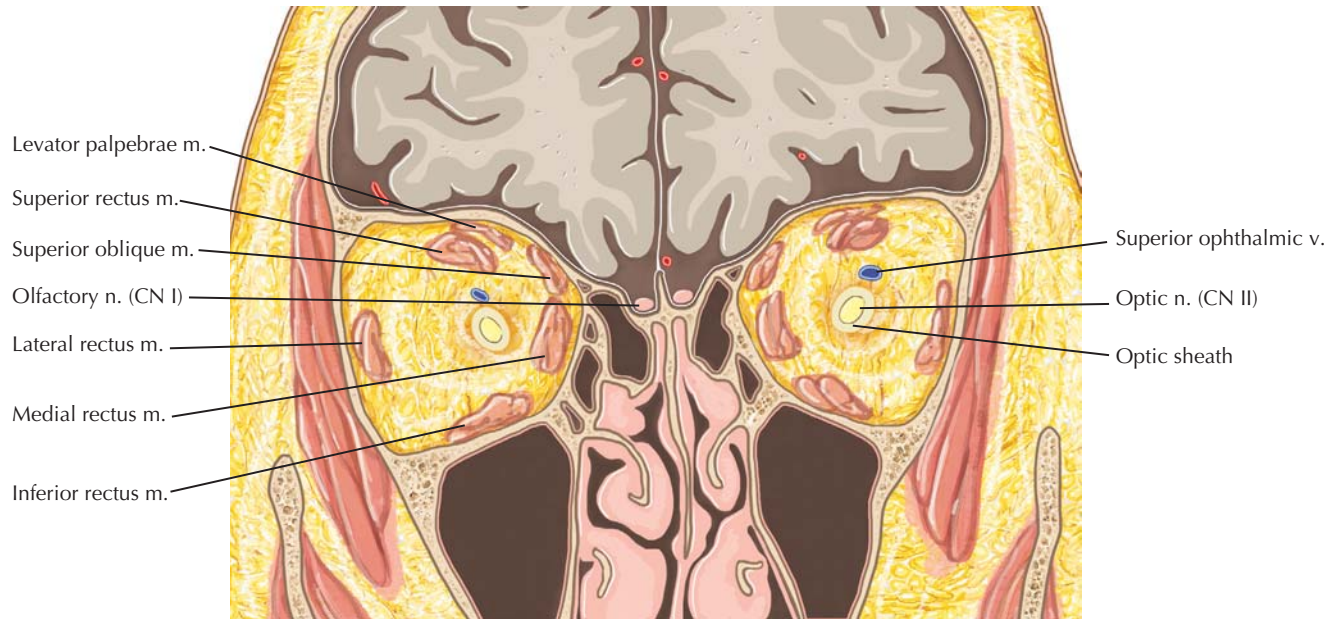
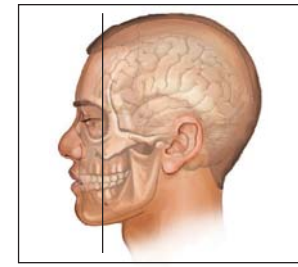


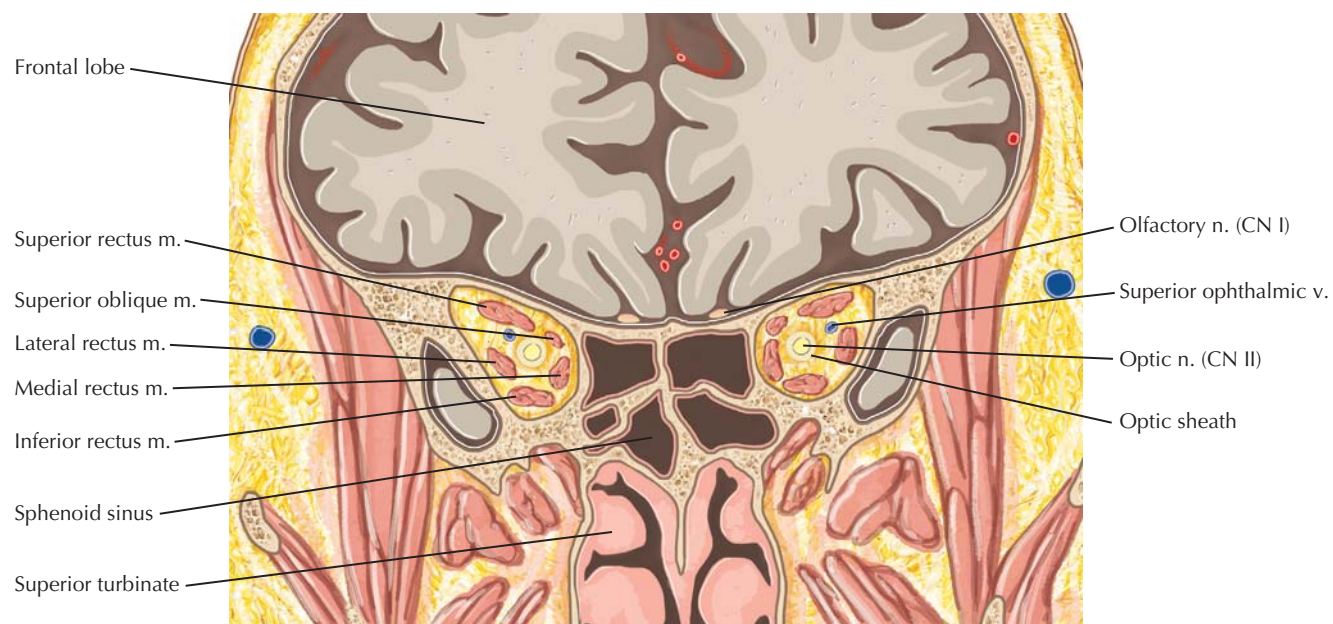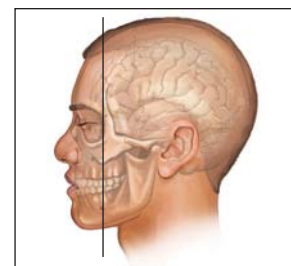


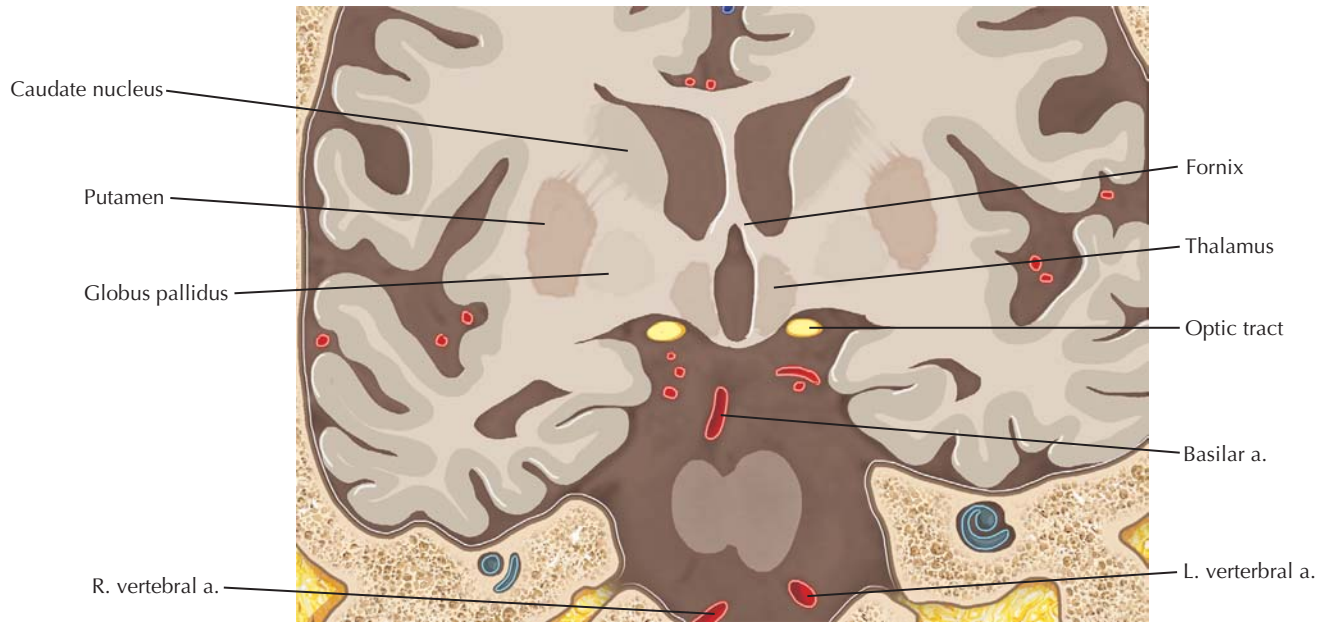
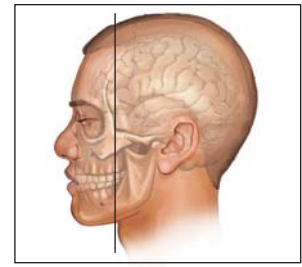


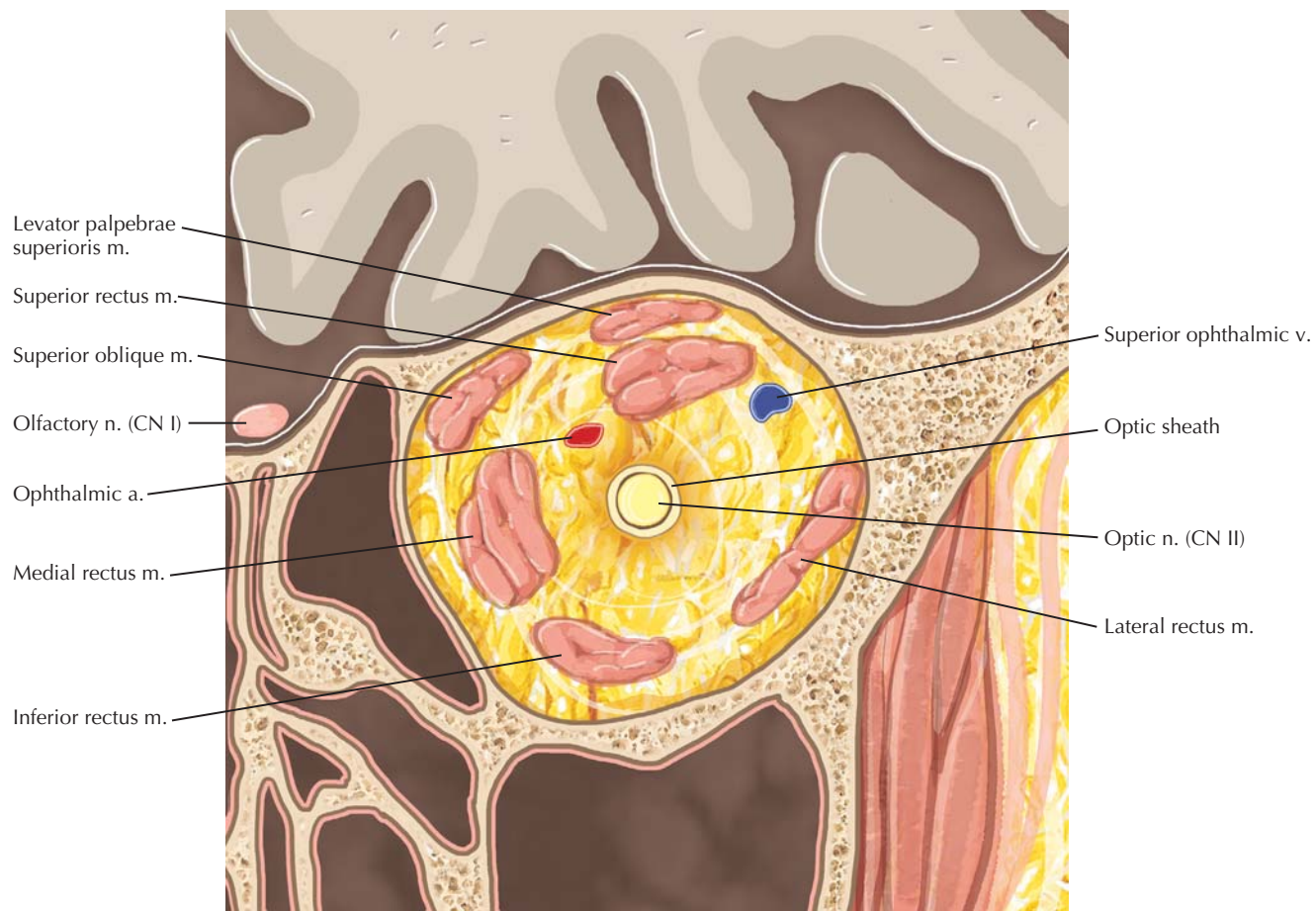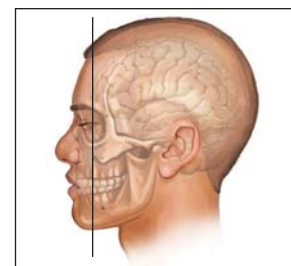


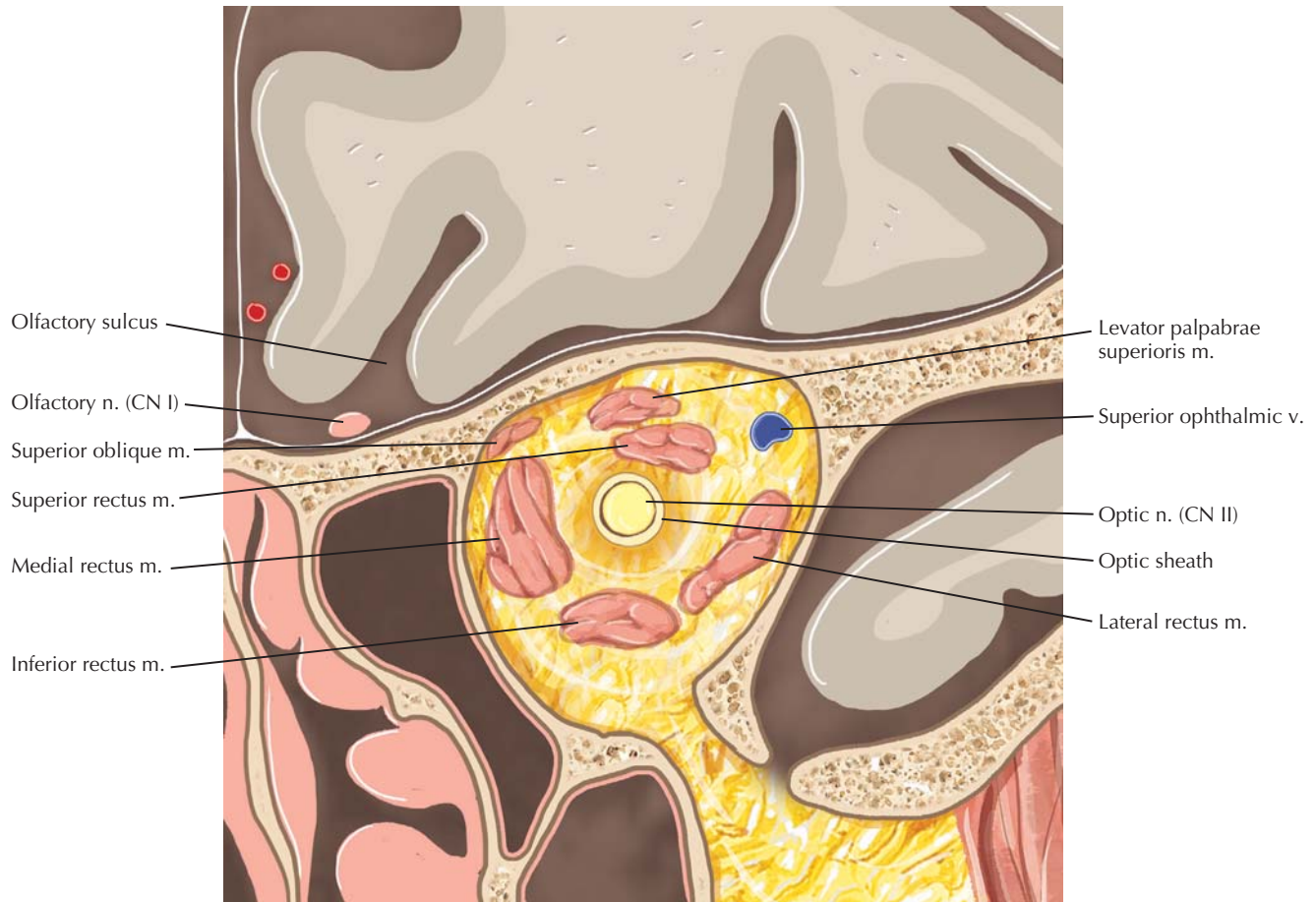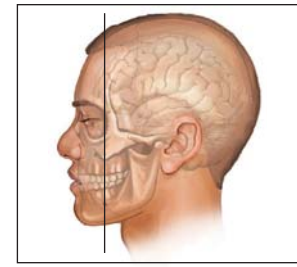








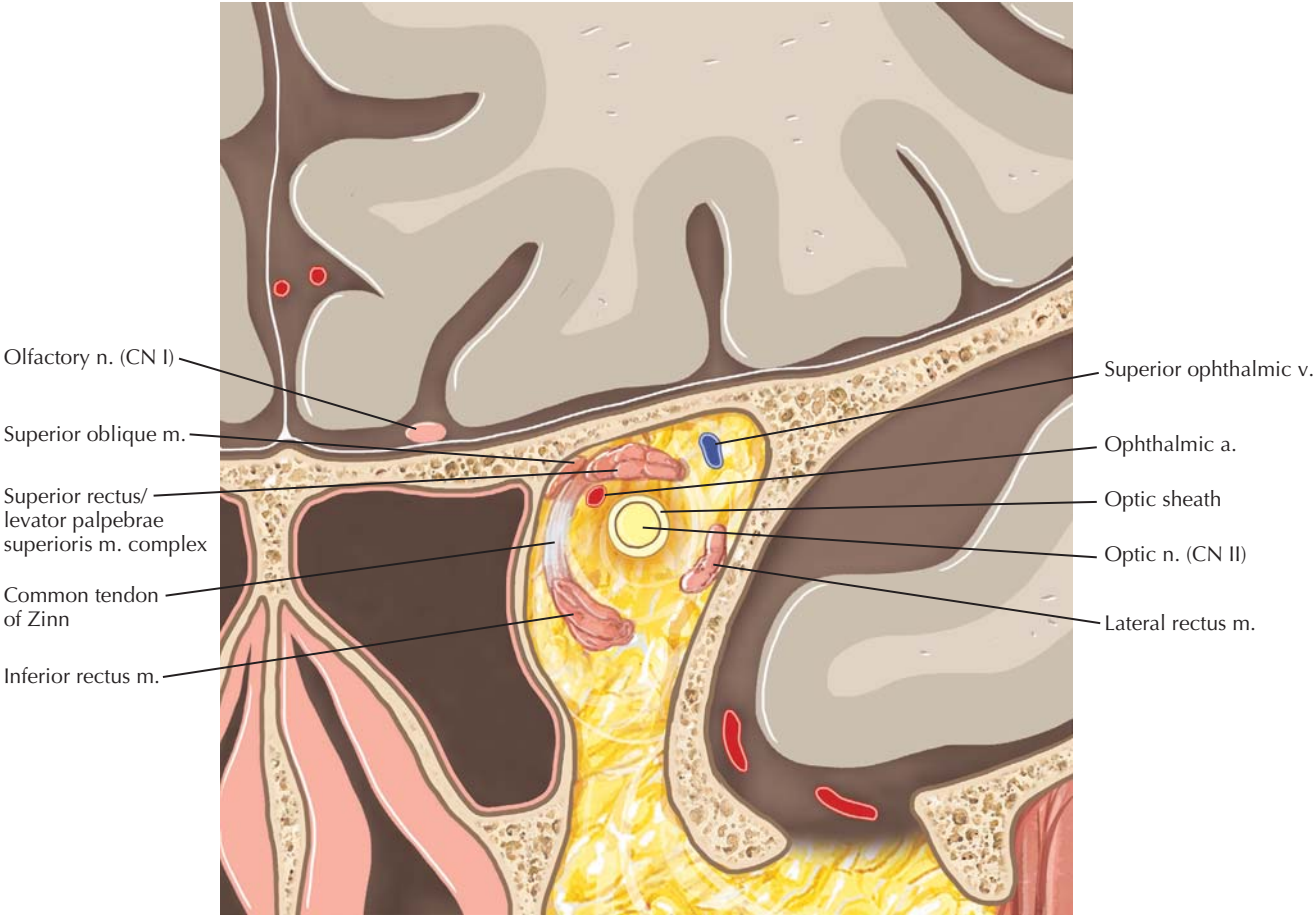
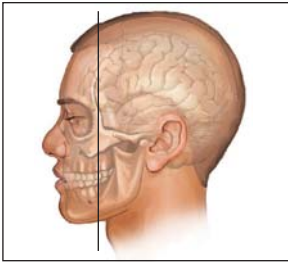


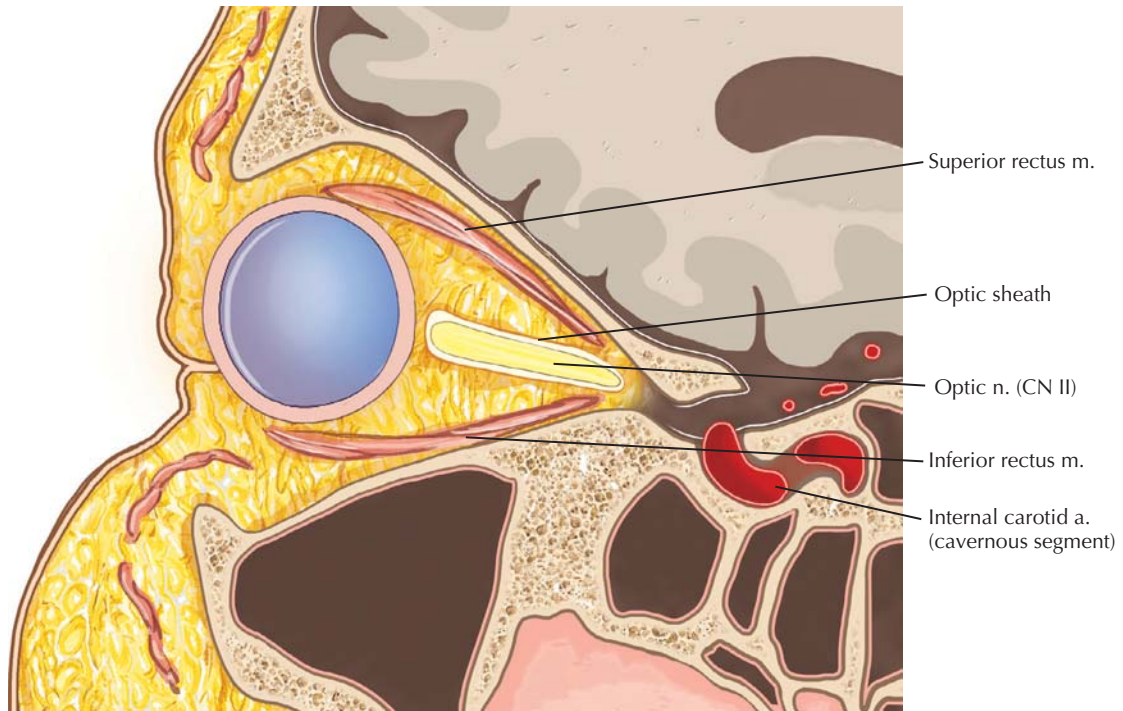
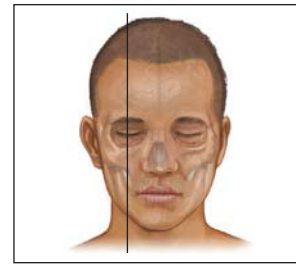


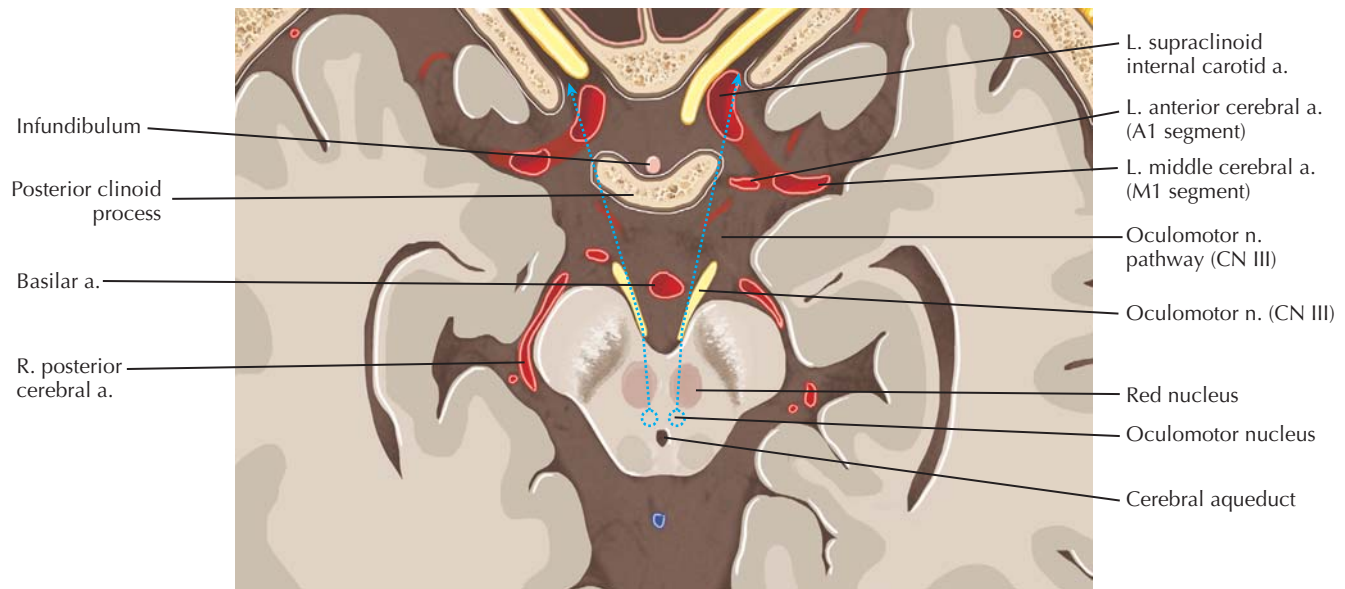
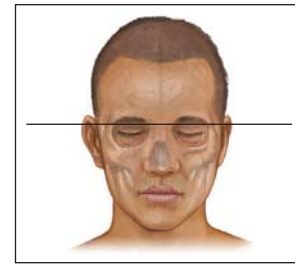
Olfactory sulcus  
Olfactory n. (CN I)  
Superior oblique m.  
Superior rectus m.  
Medial rectus m.  
Inferior rectus m.

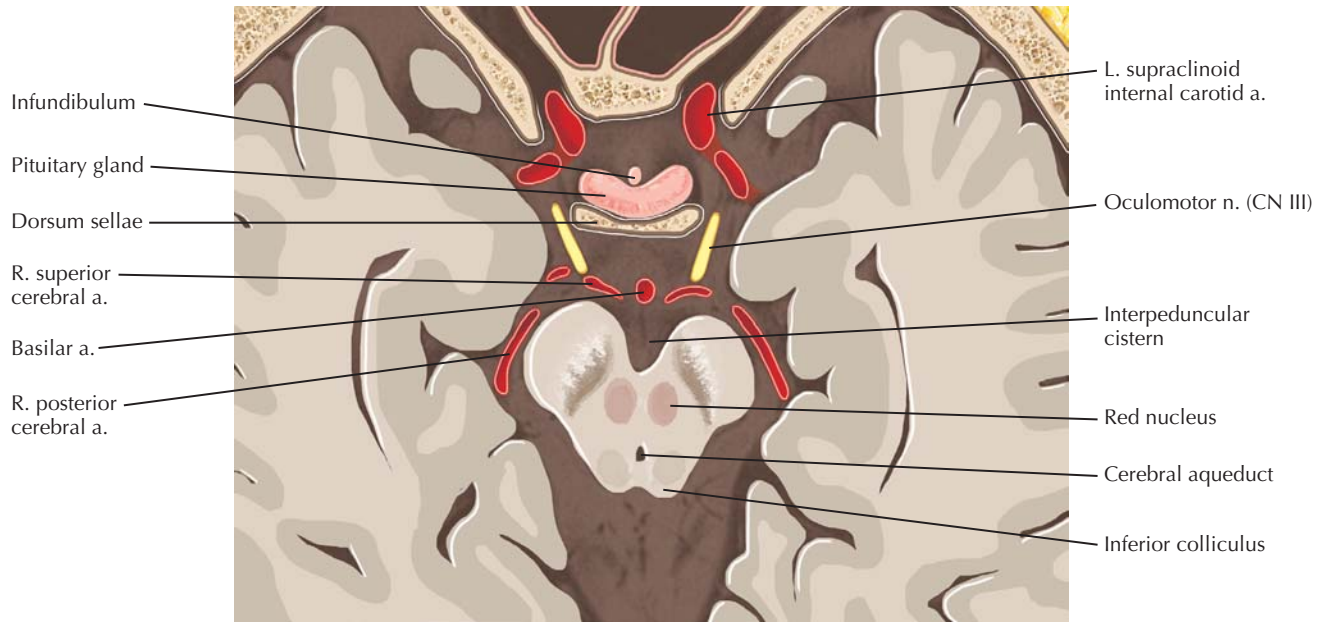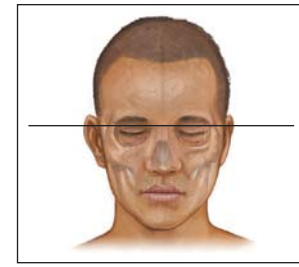
Levator palpabrae superioris m.  
Superior ophthalmic v.  
Optic n. (CN II)  
Optic sheath  
Lateral rectus m.

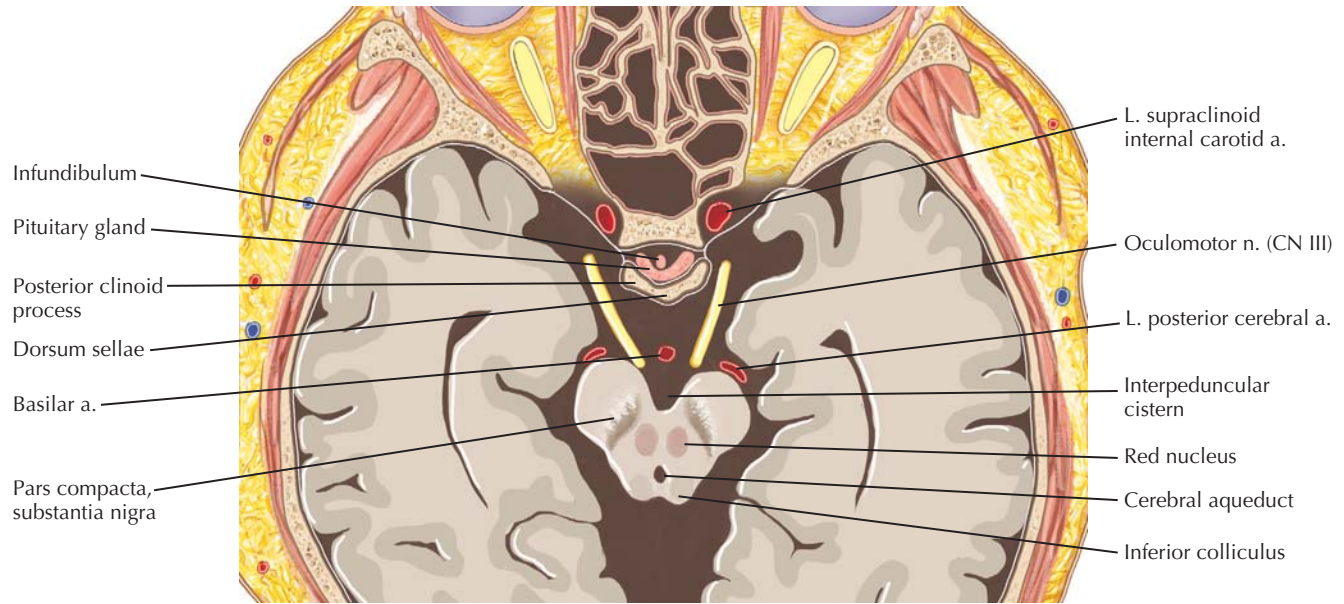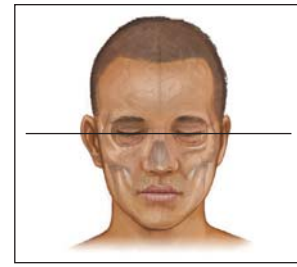


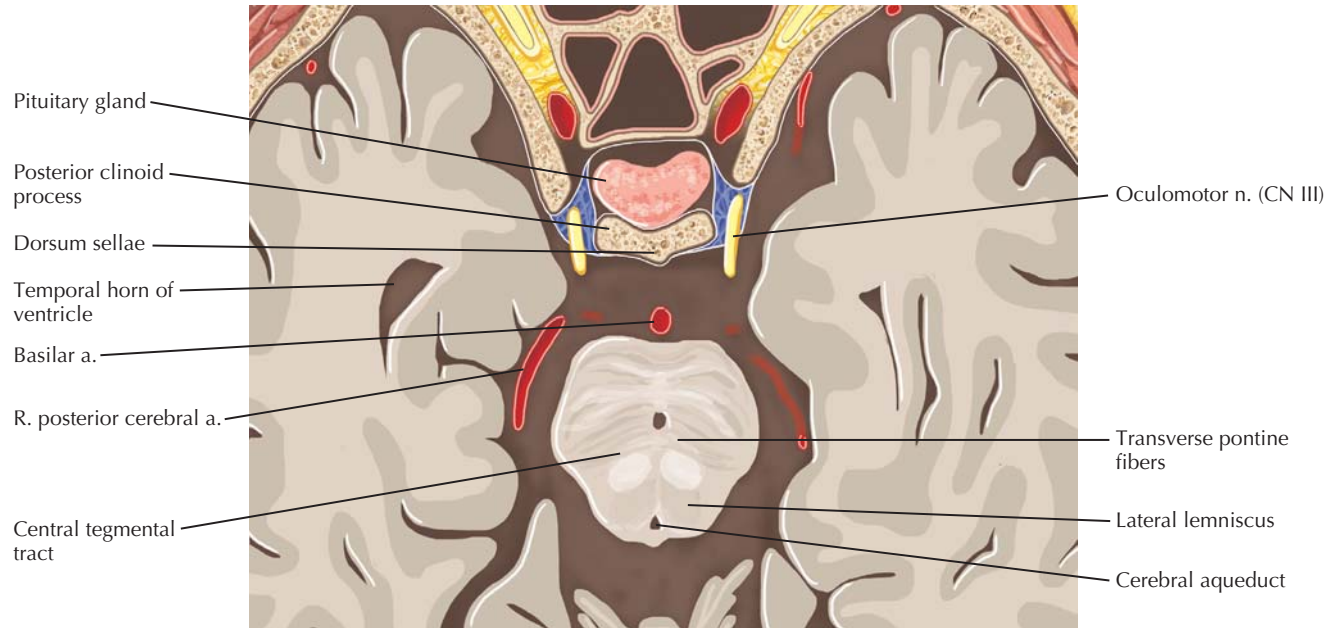
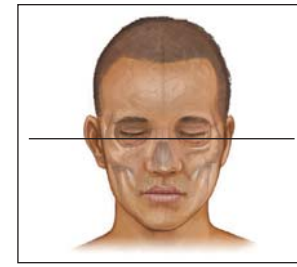


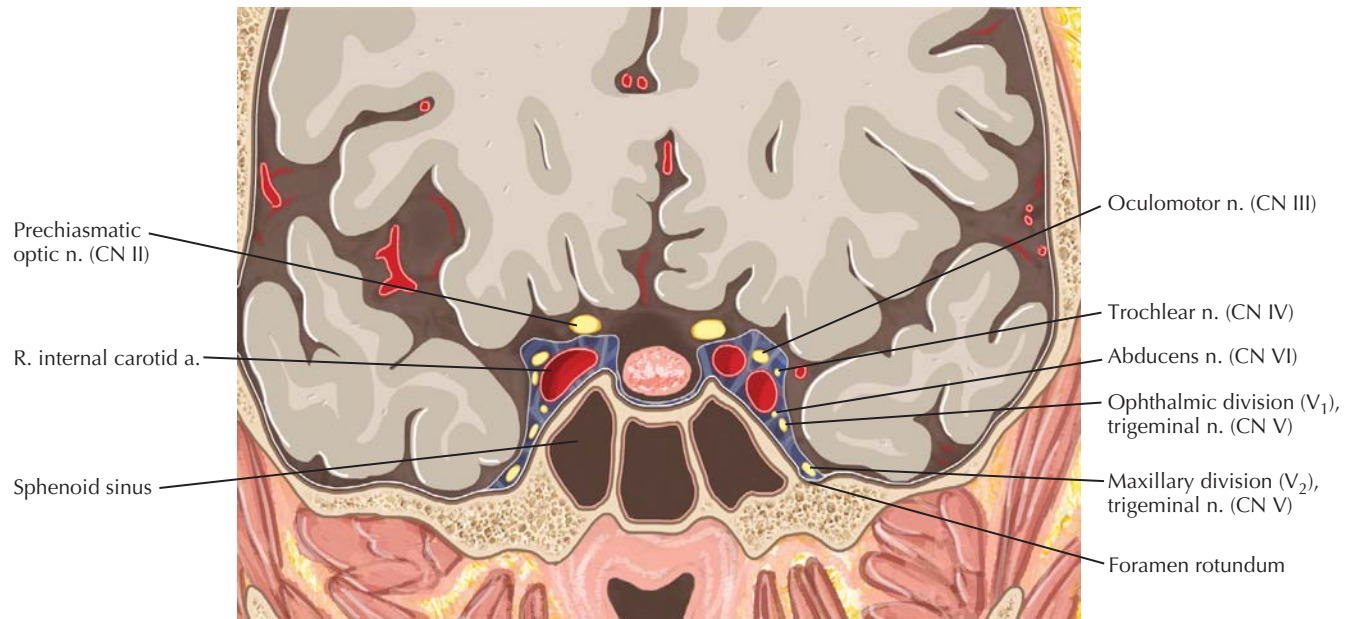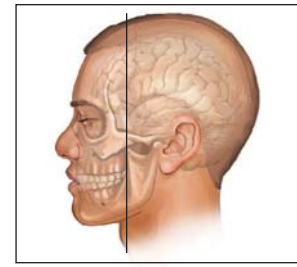


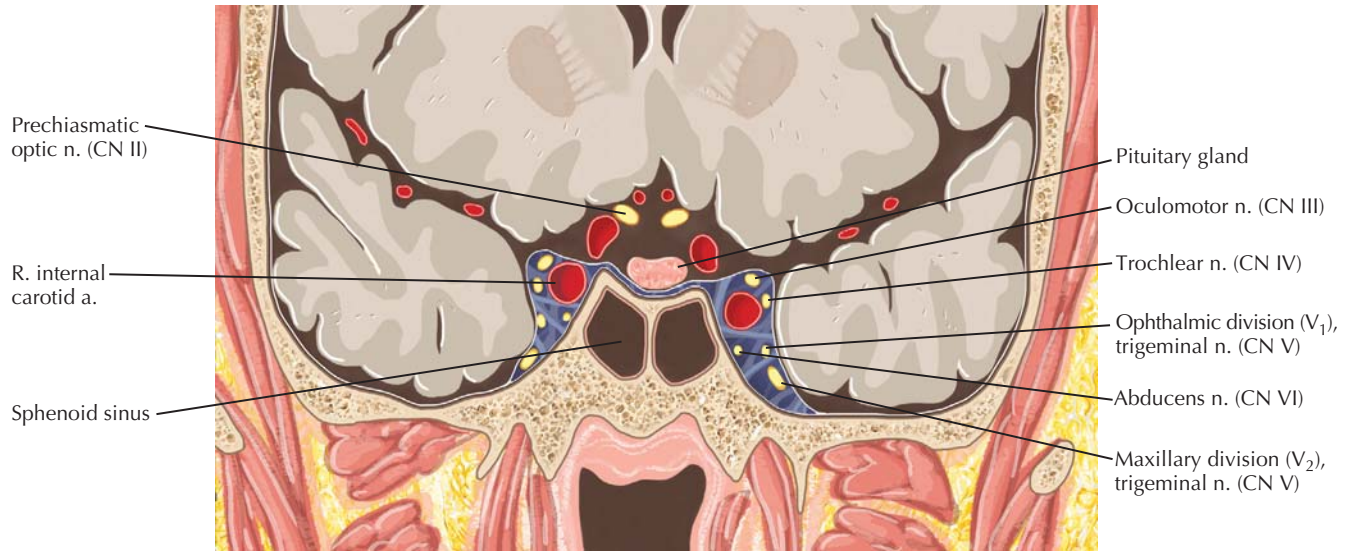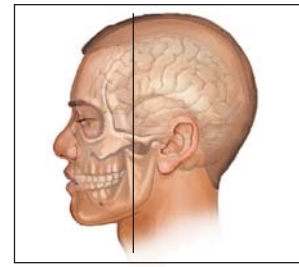




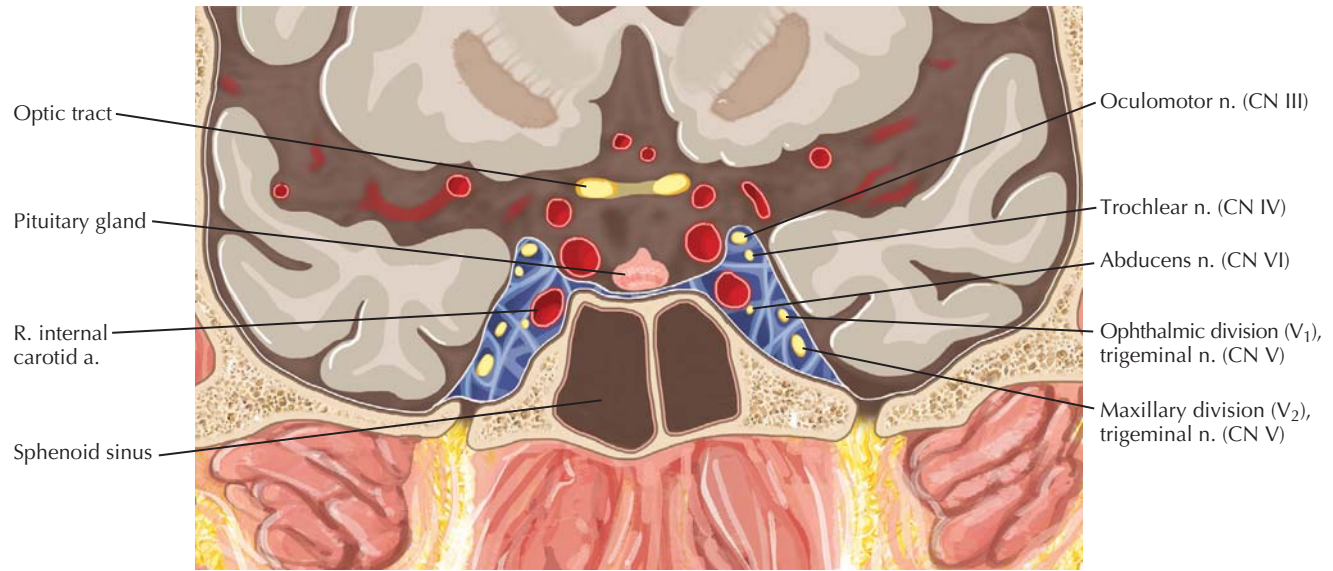
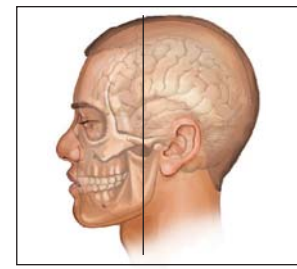


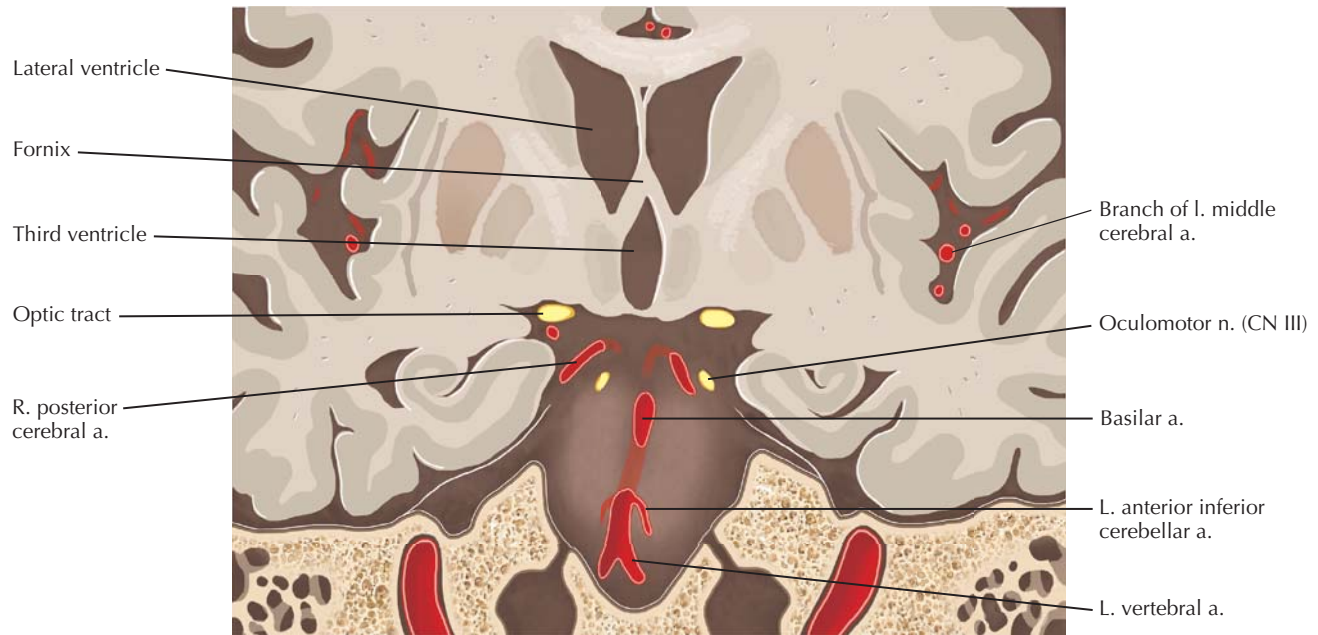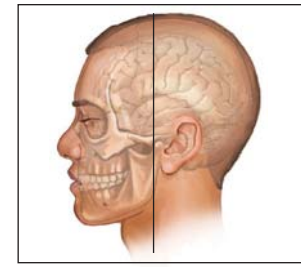


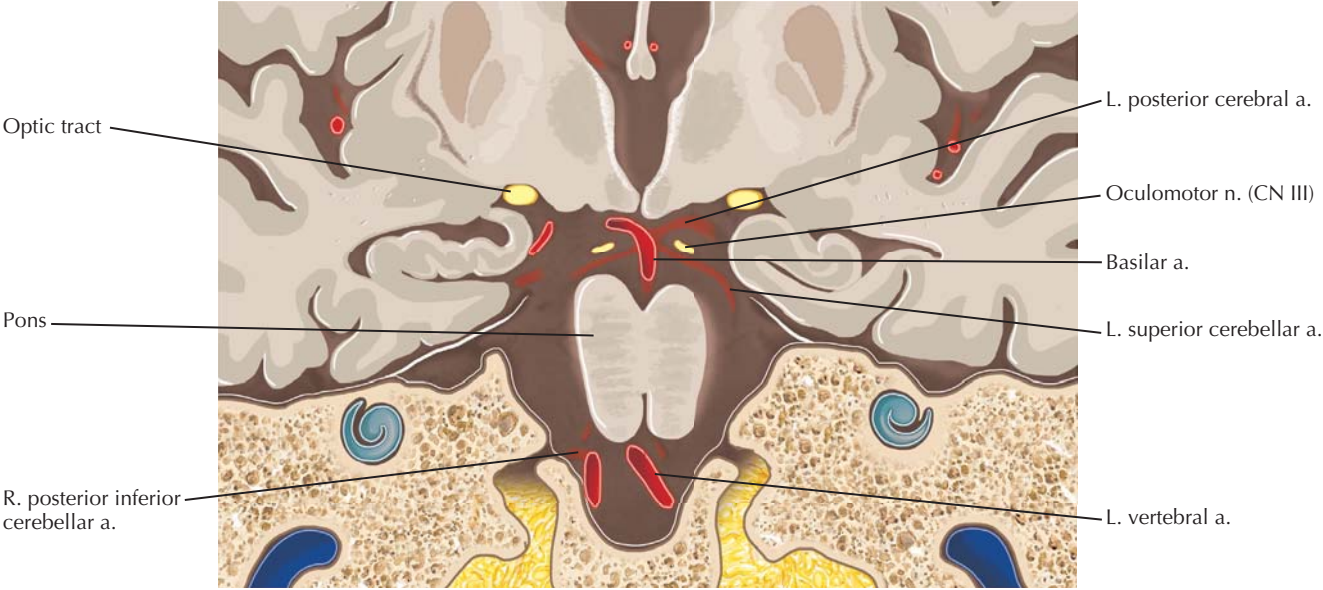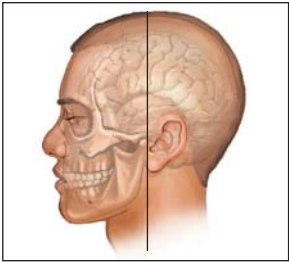


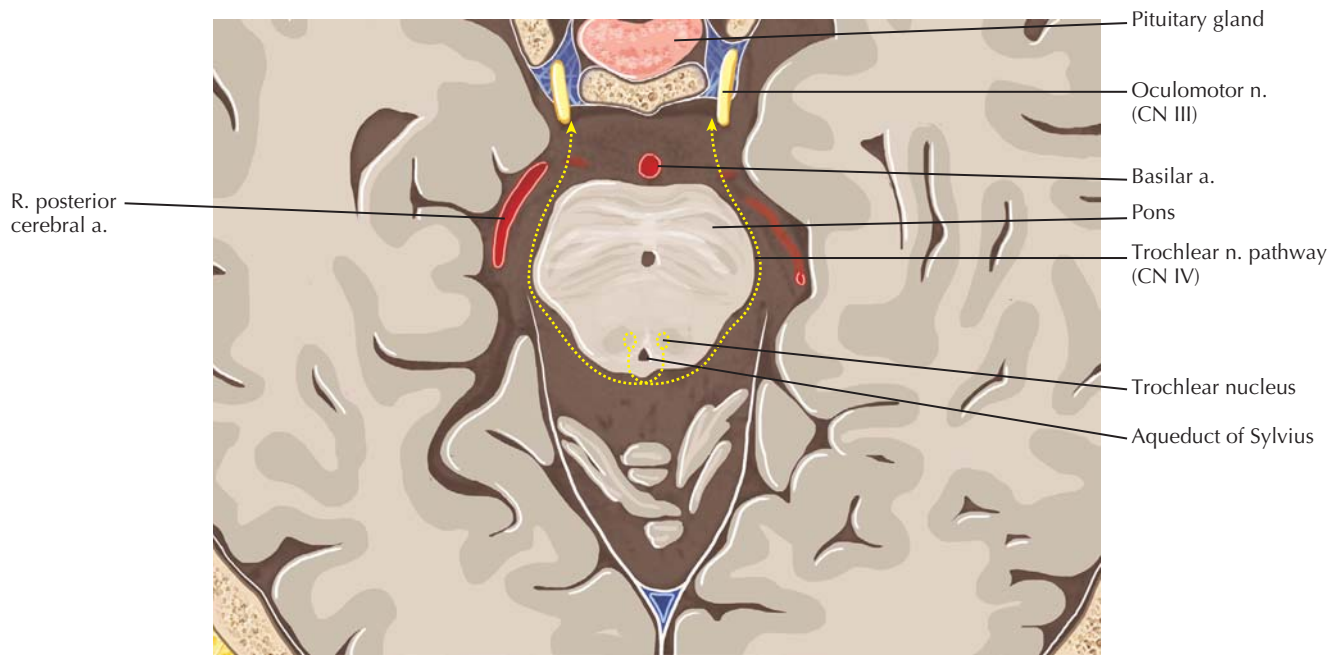
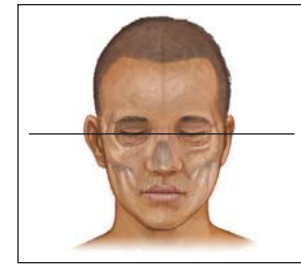


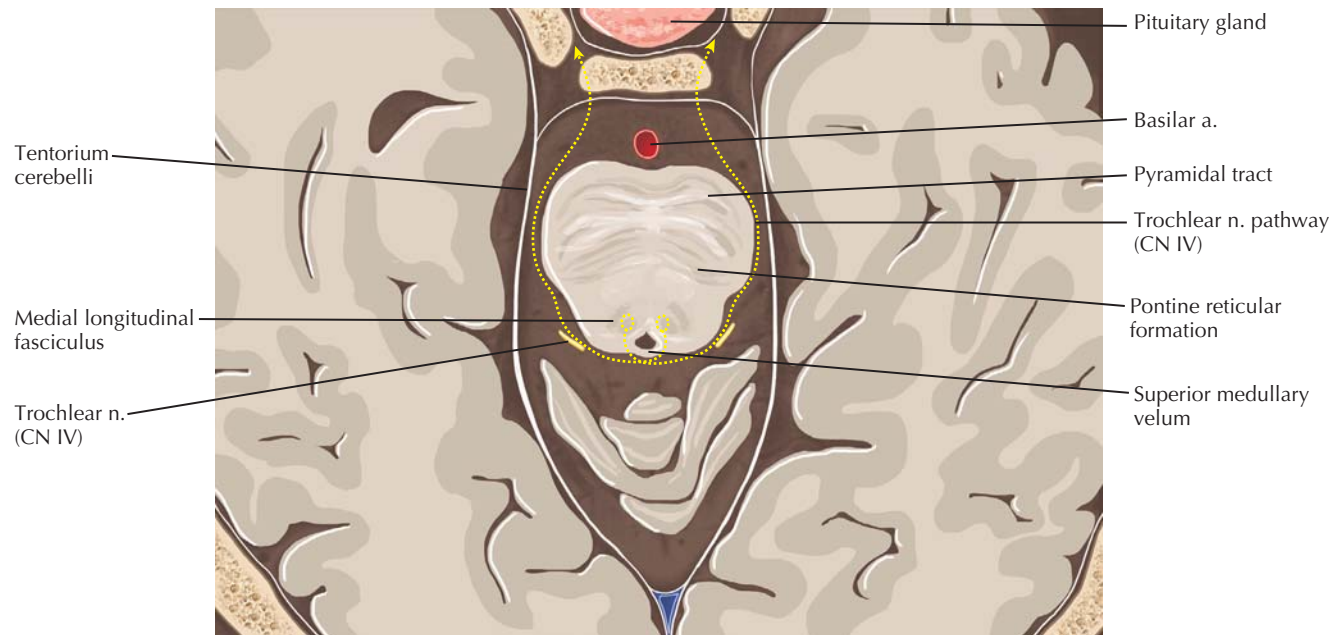
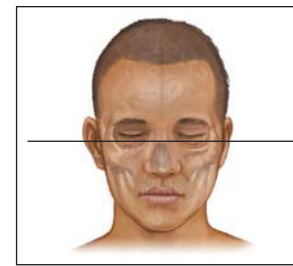


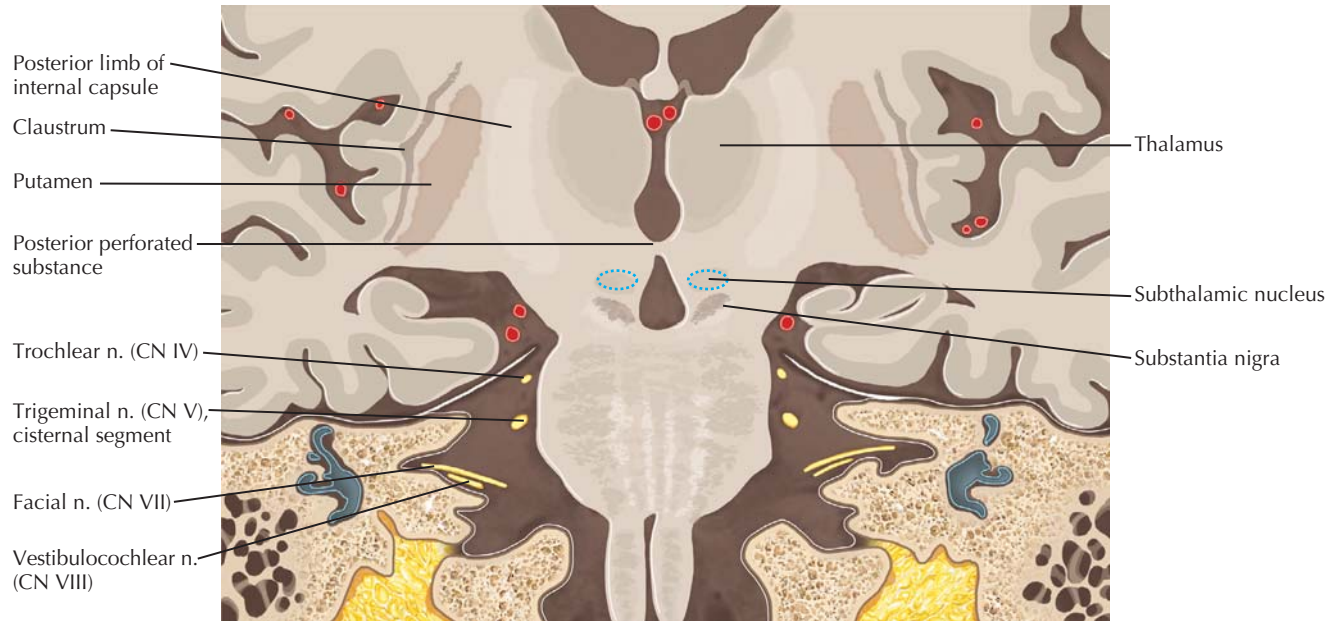
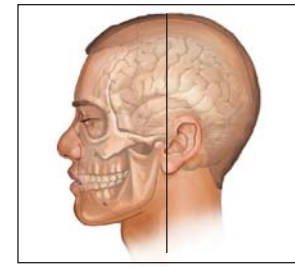


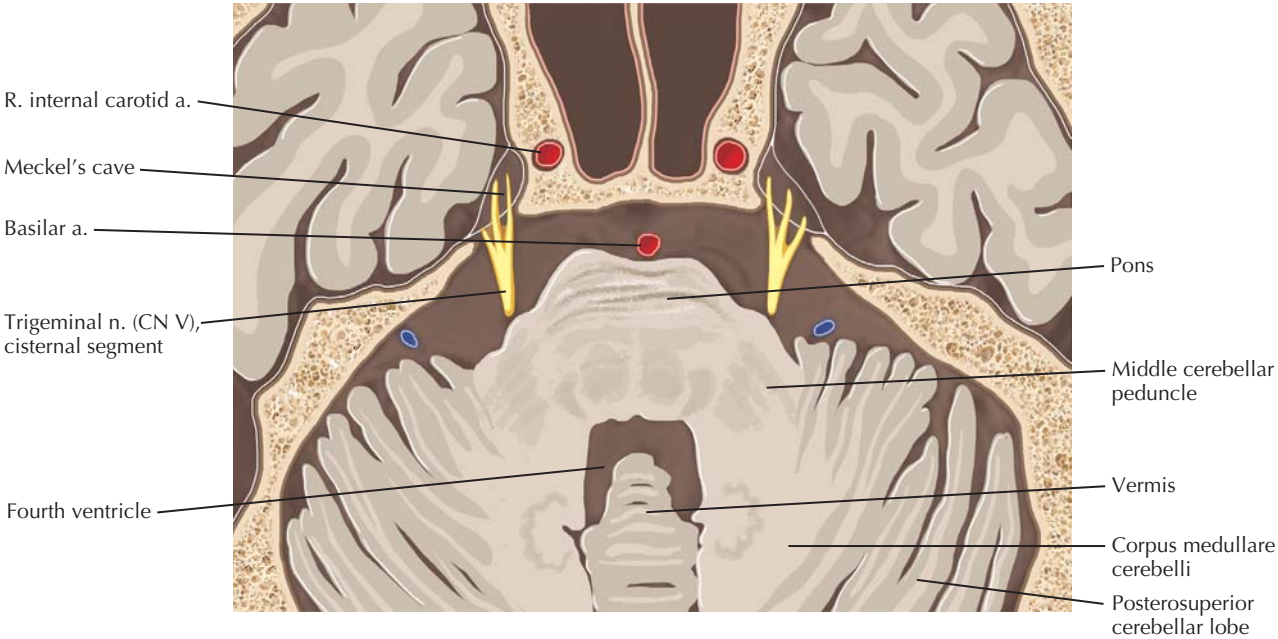
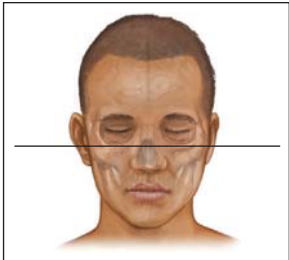


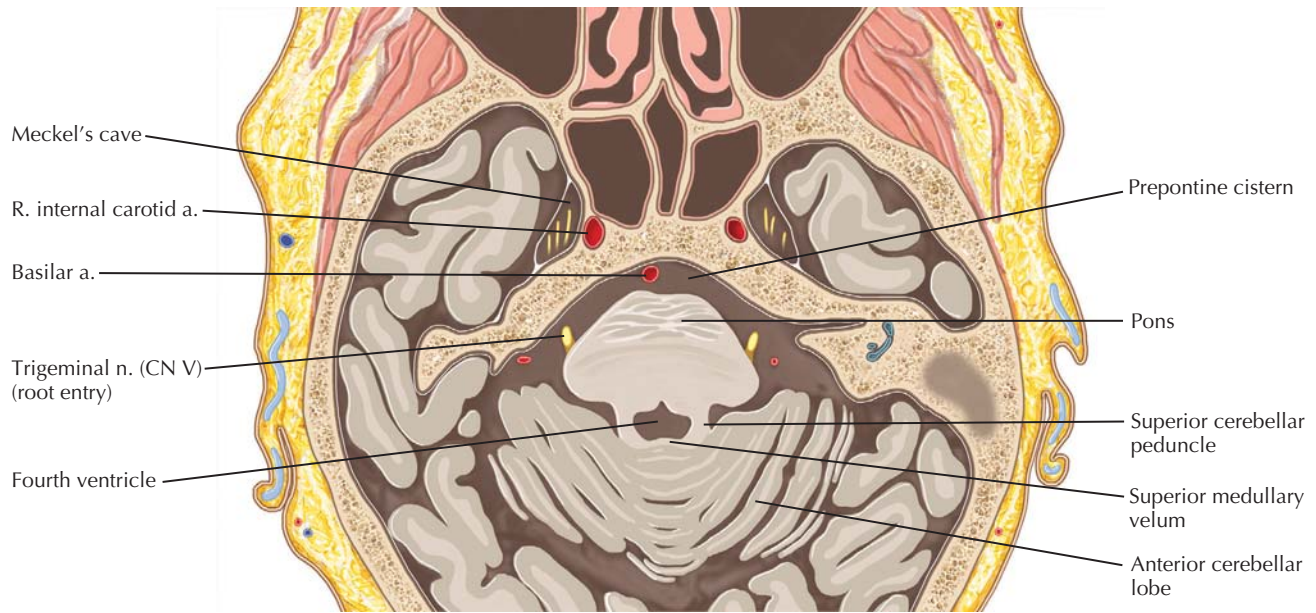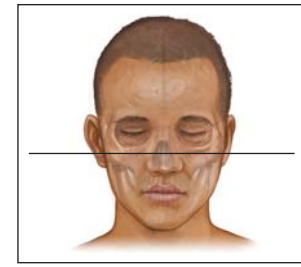




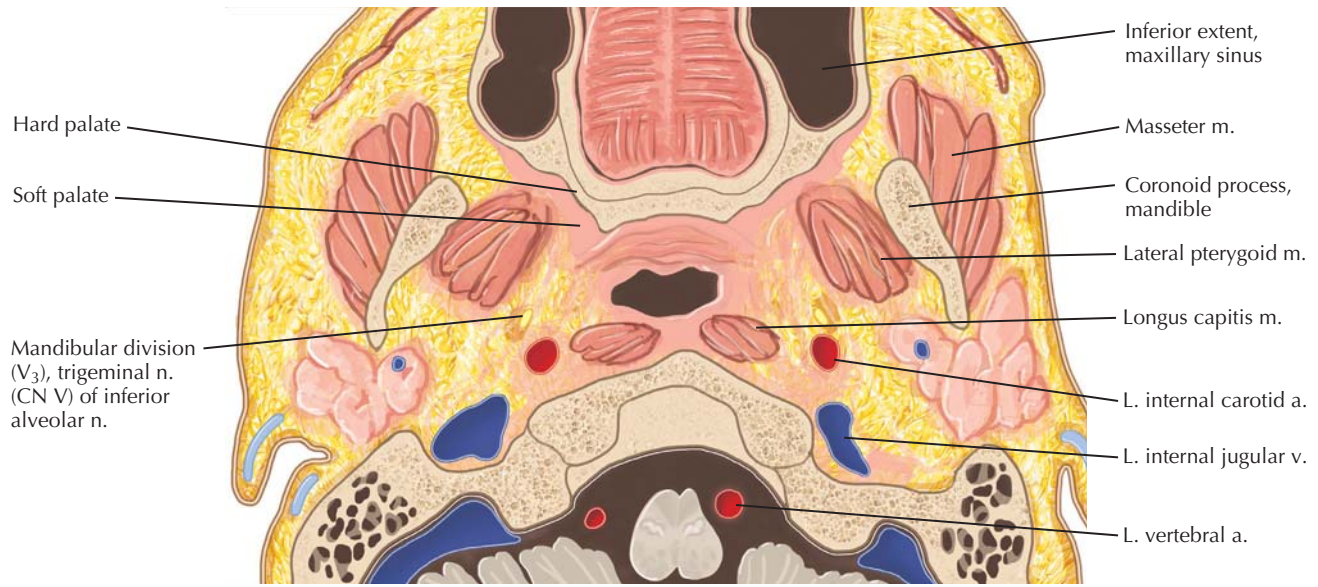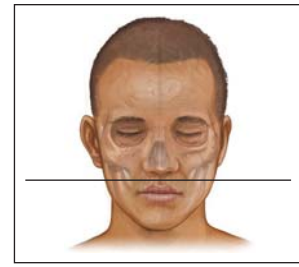


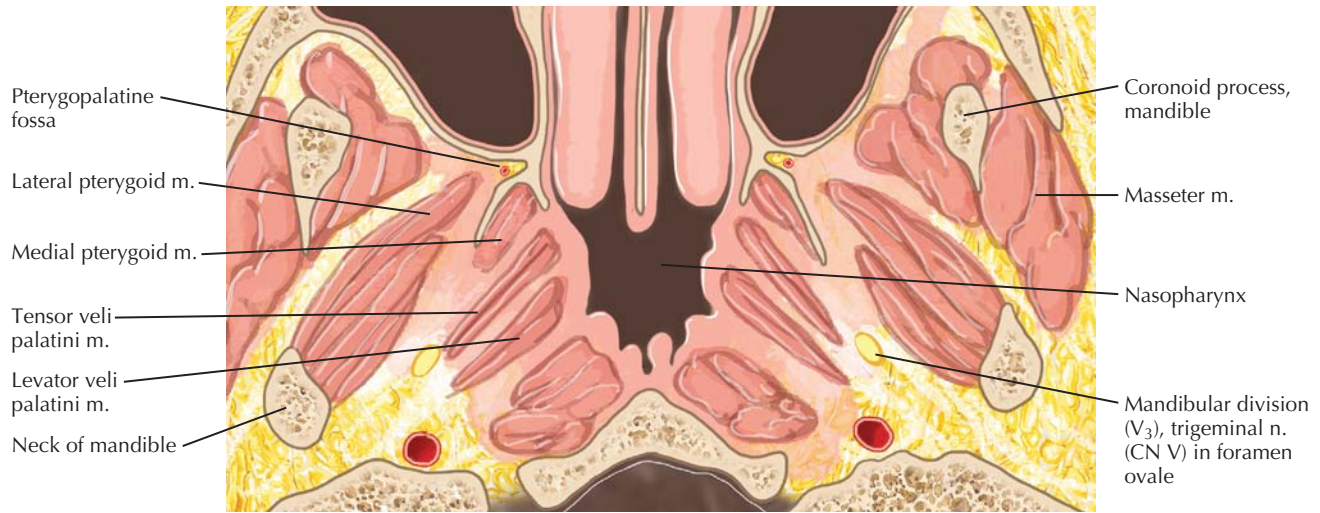
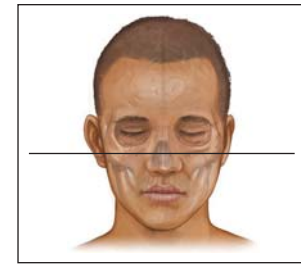


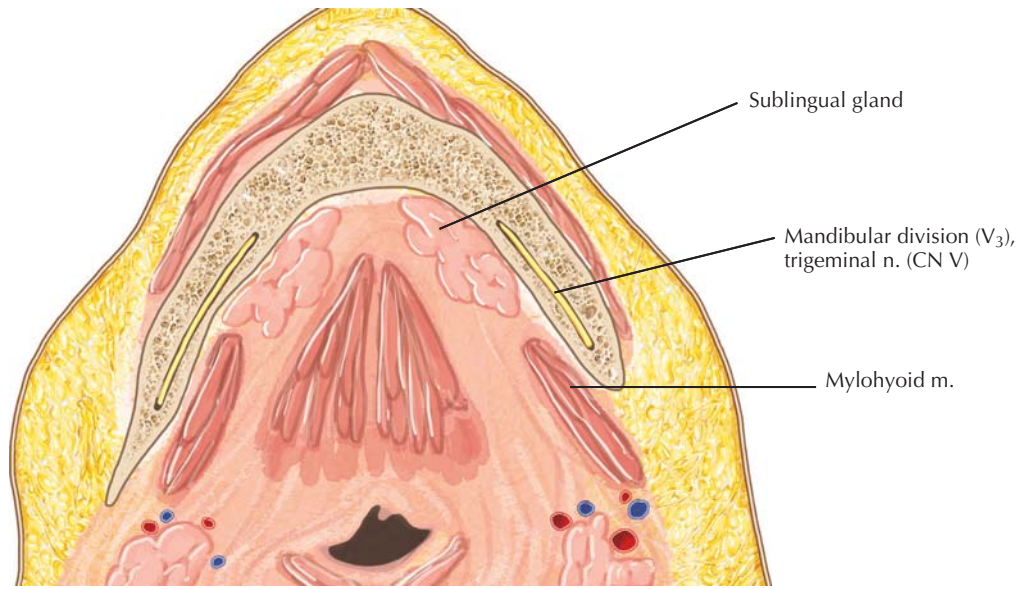
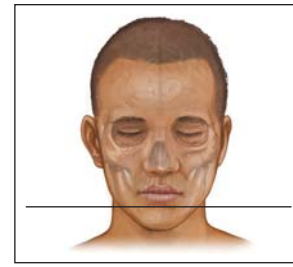


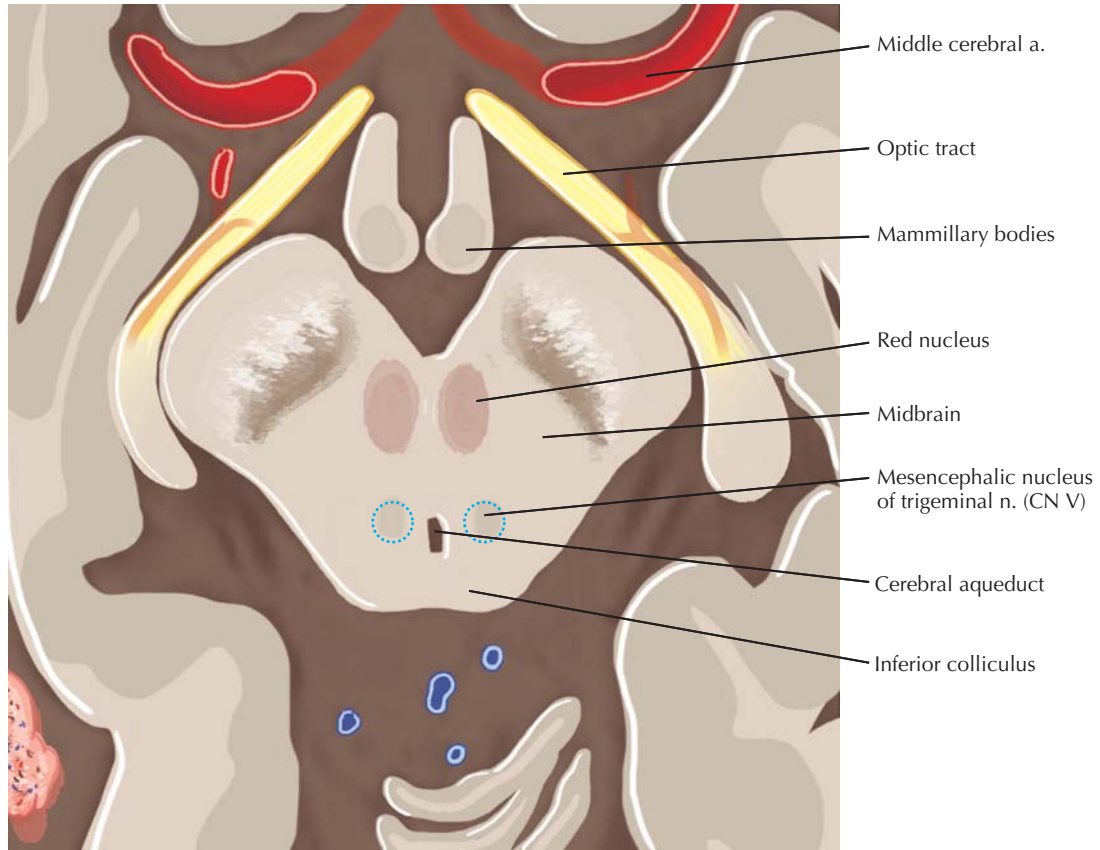
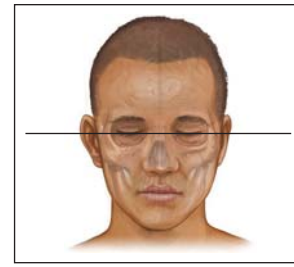


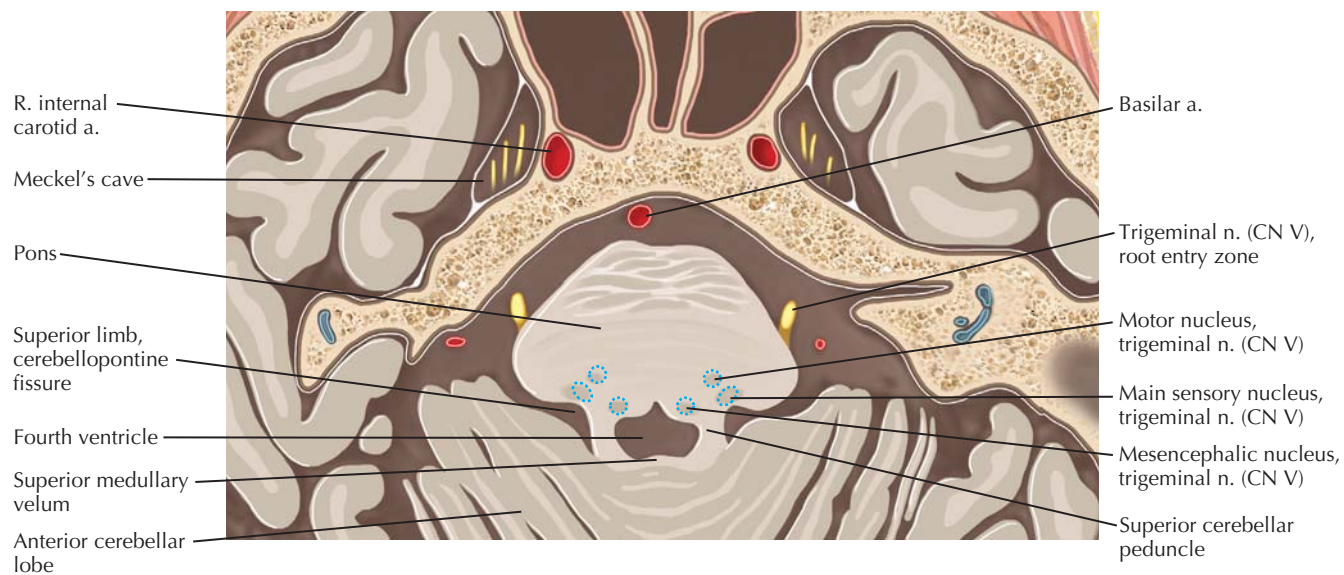
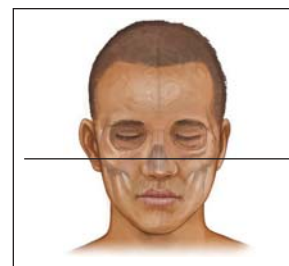


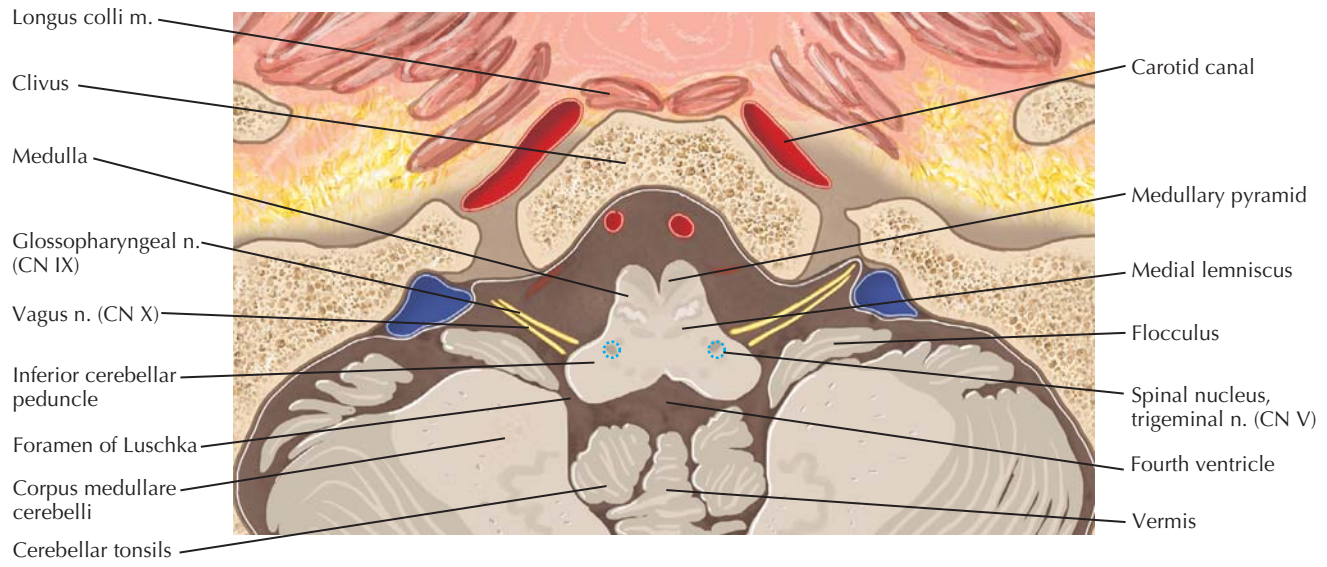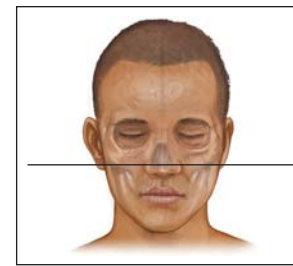


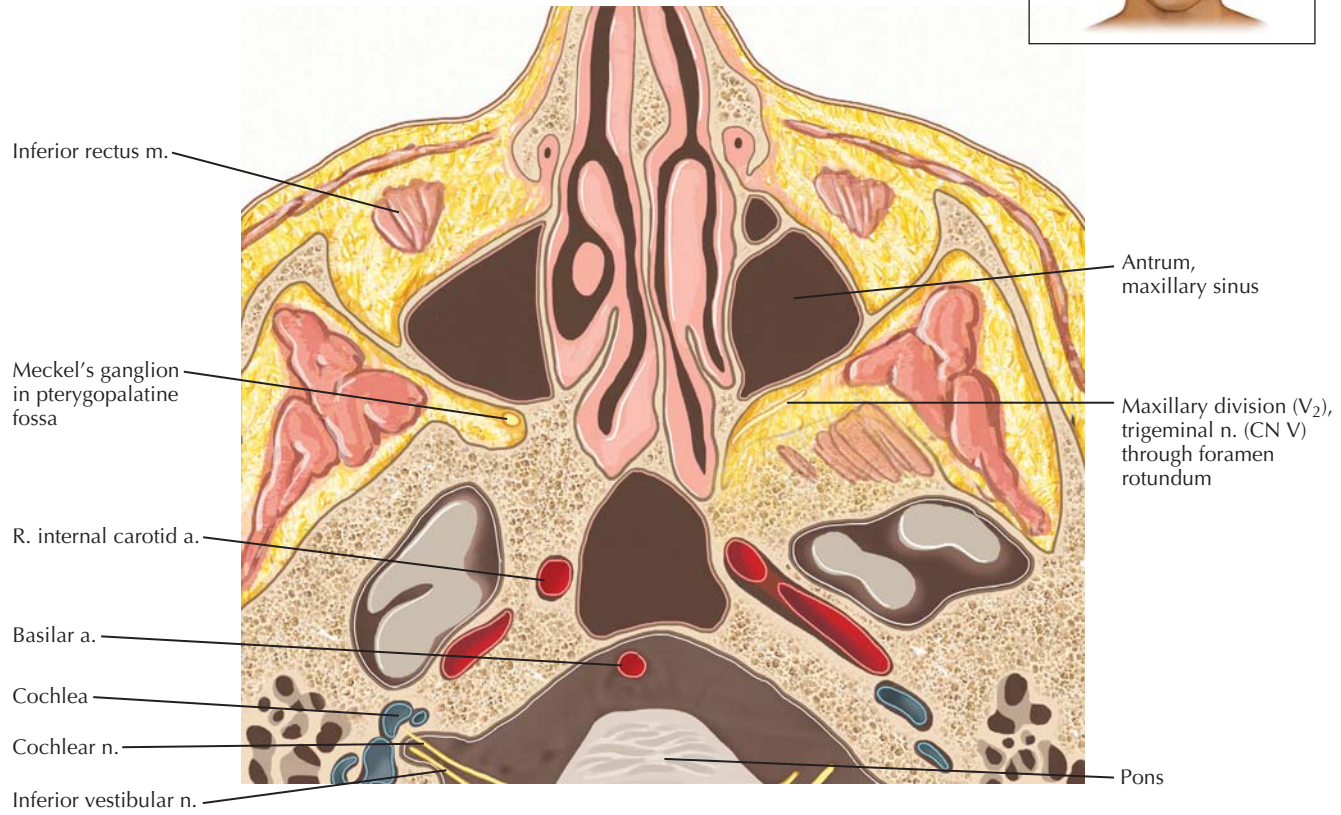
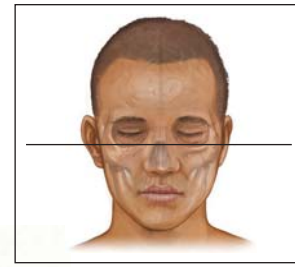


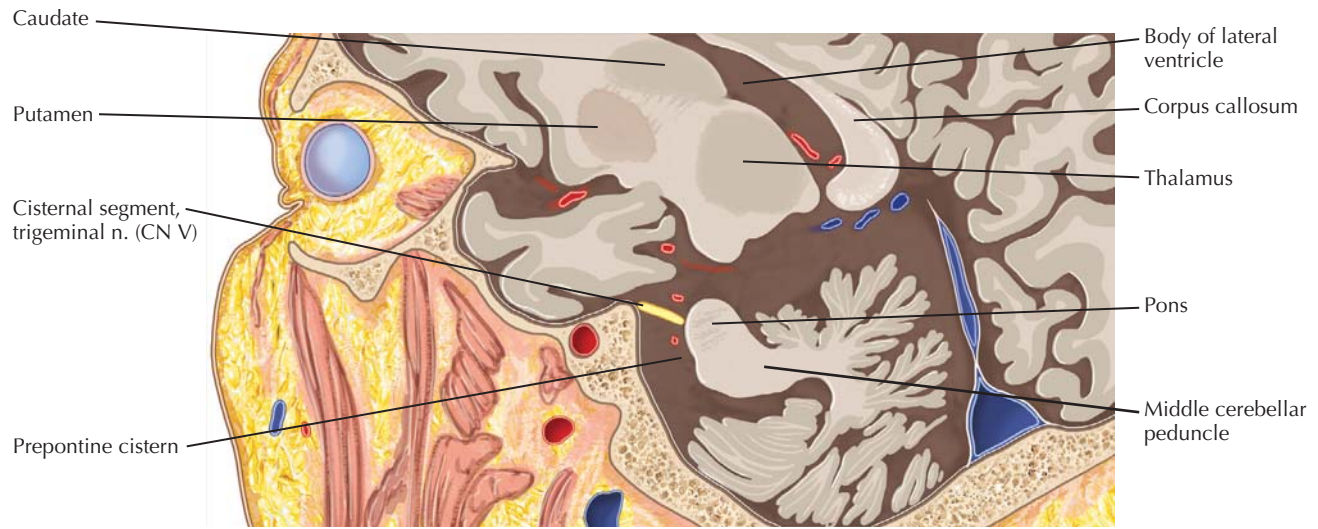
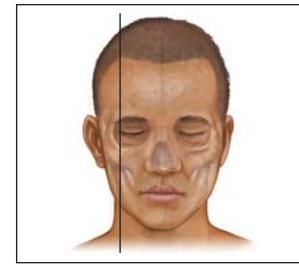




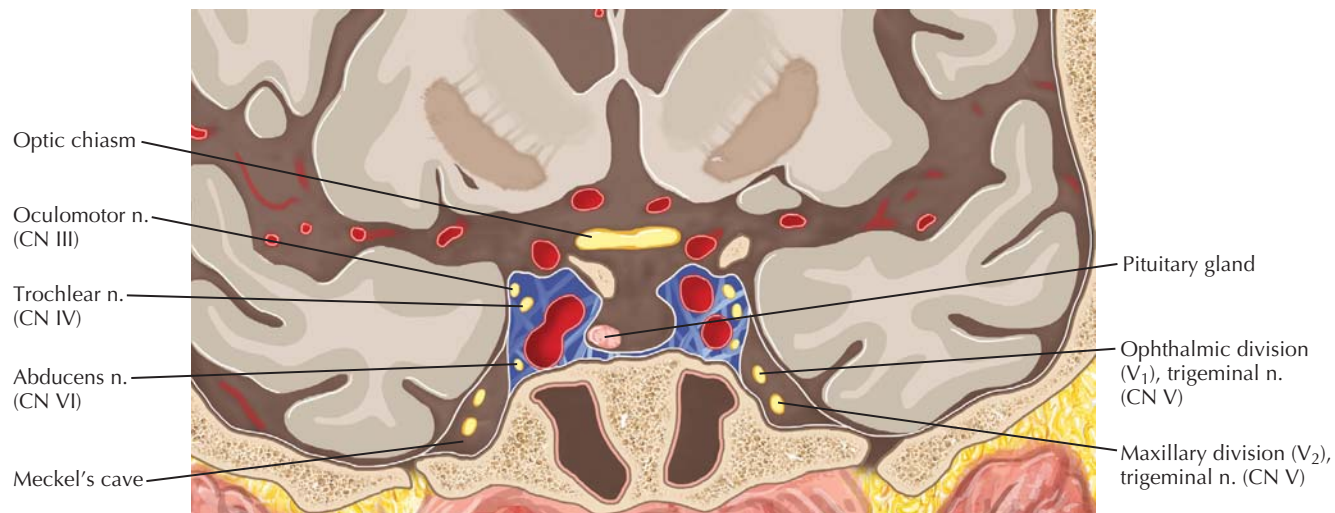
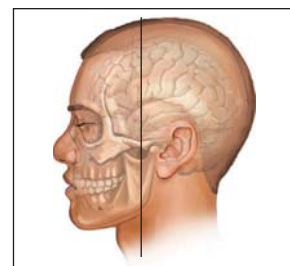


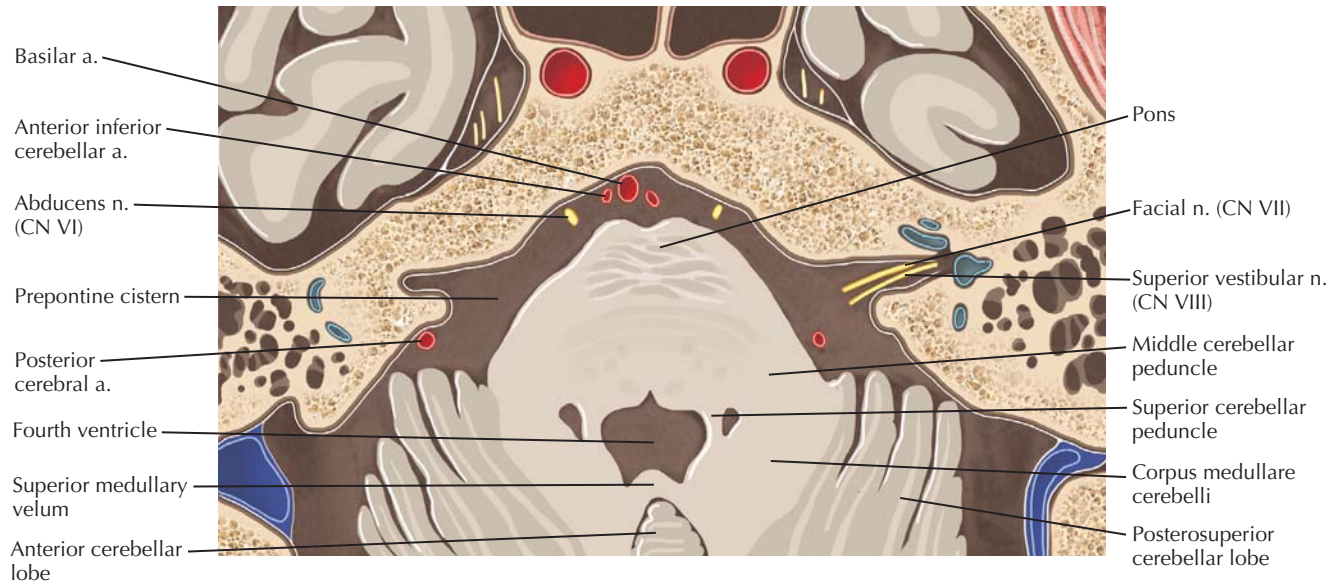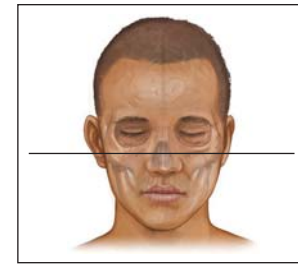


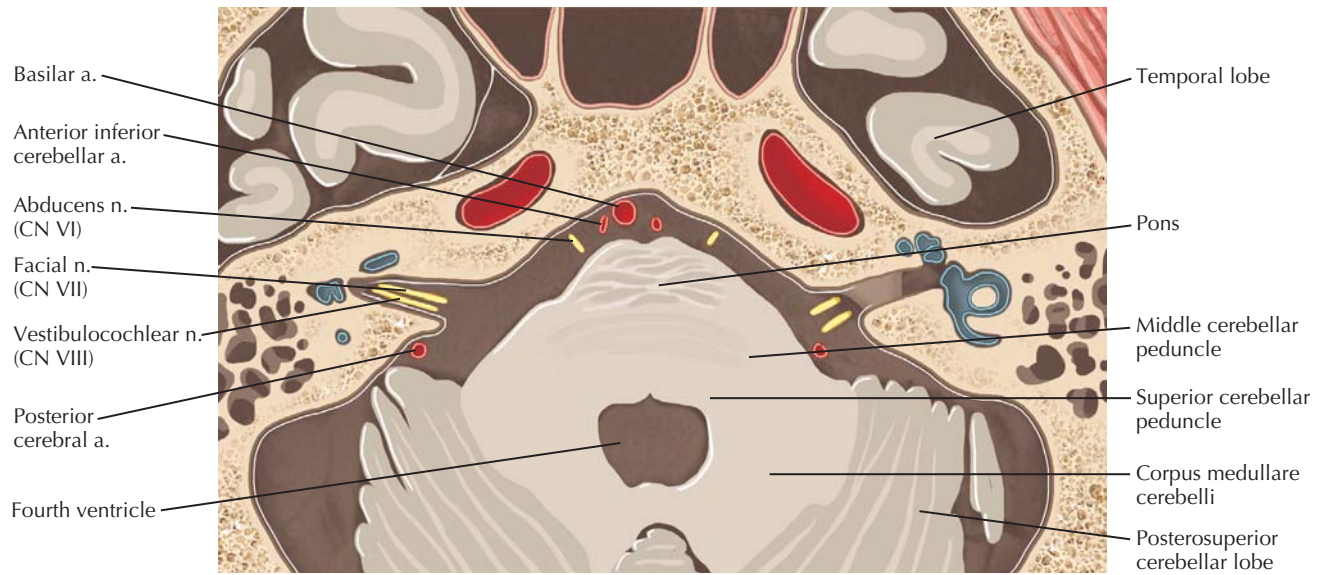
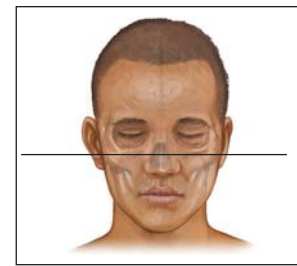


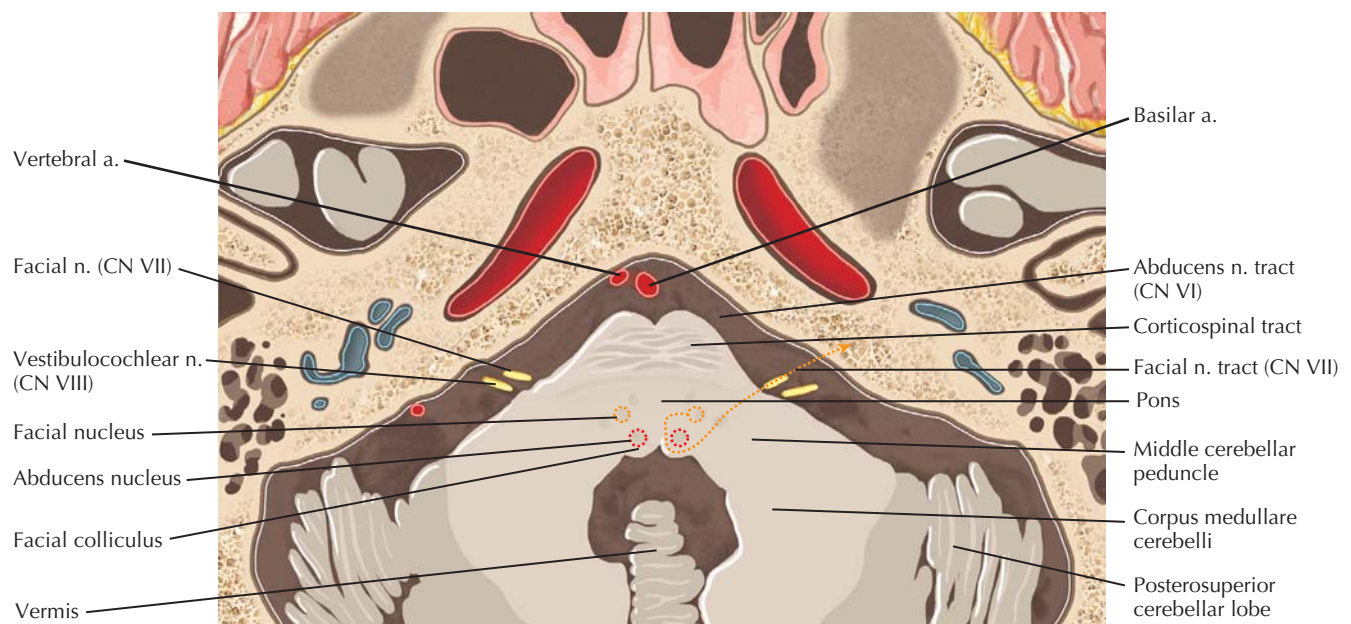
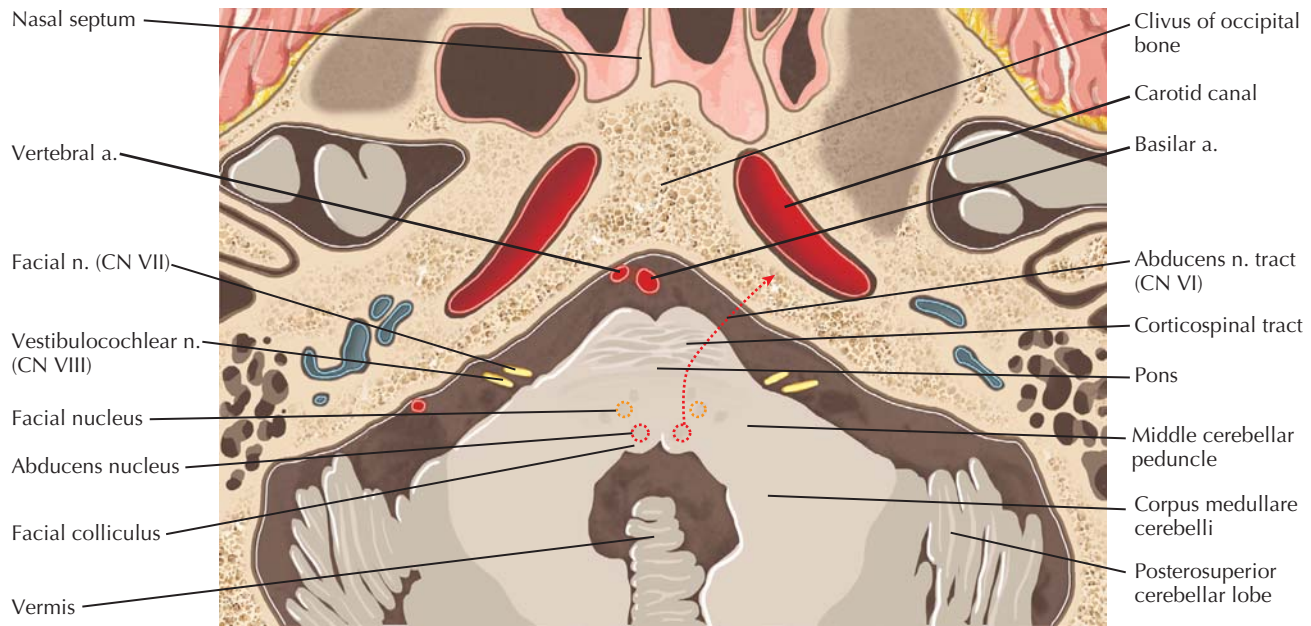
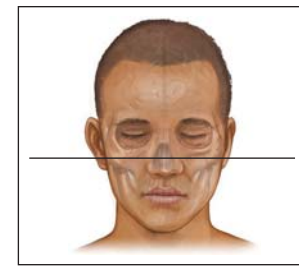


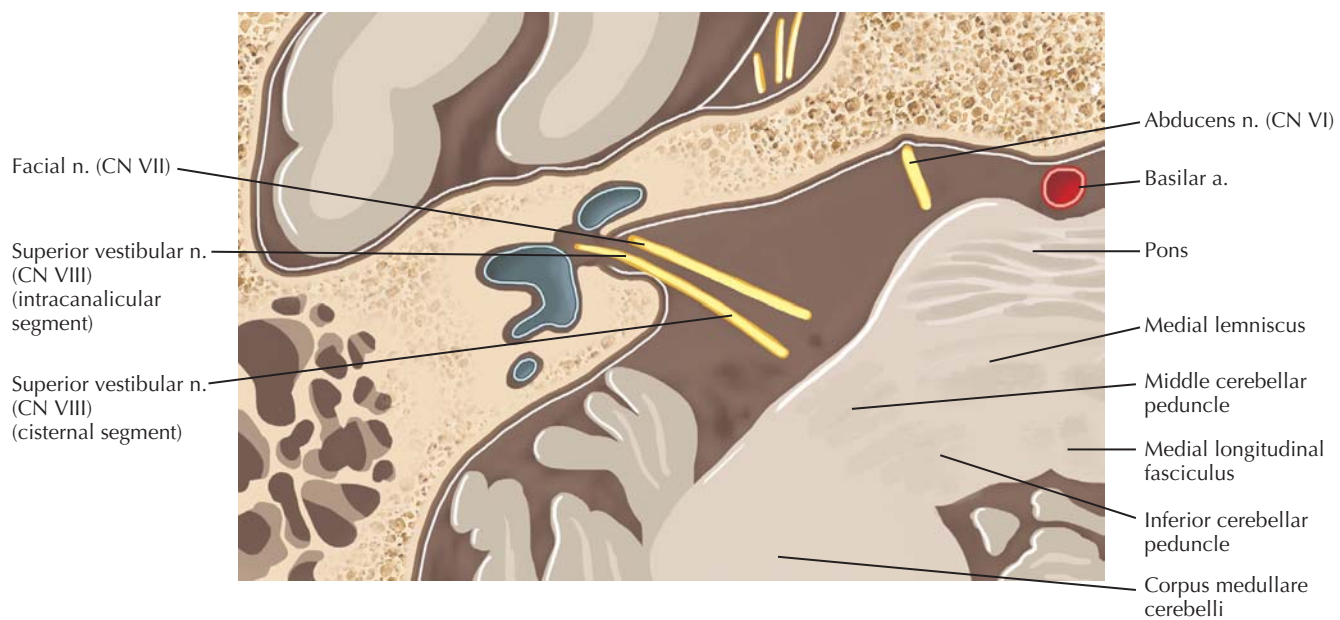
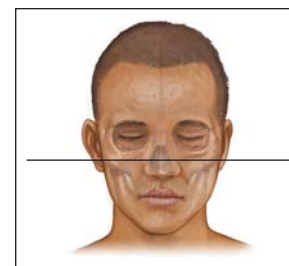


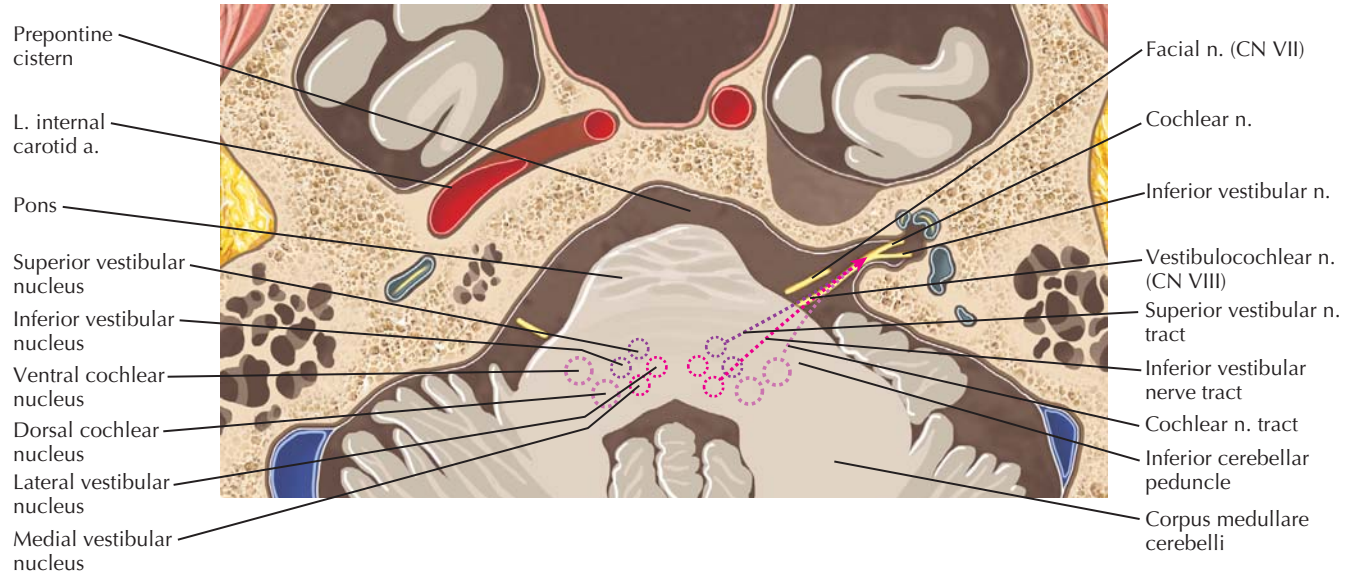
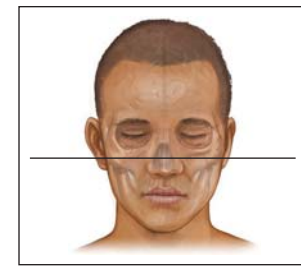


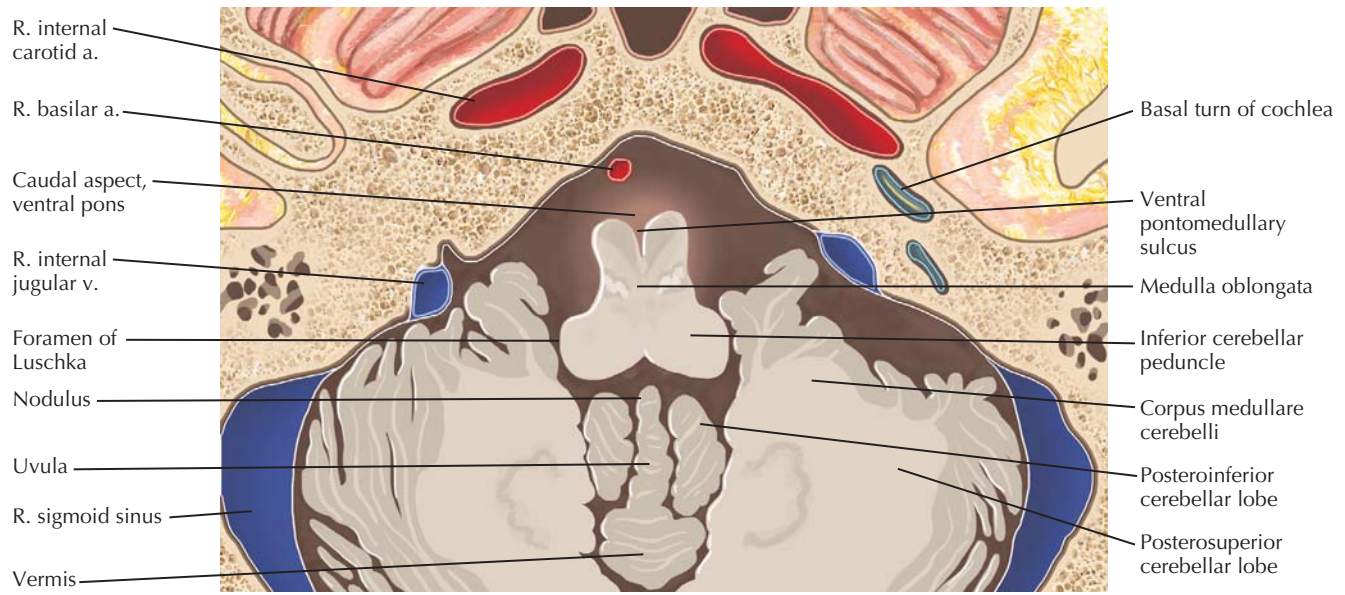
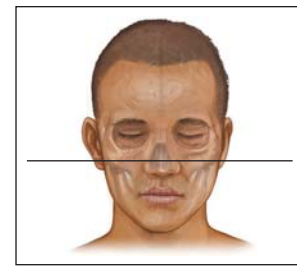


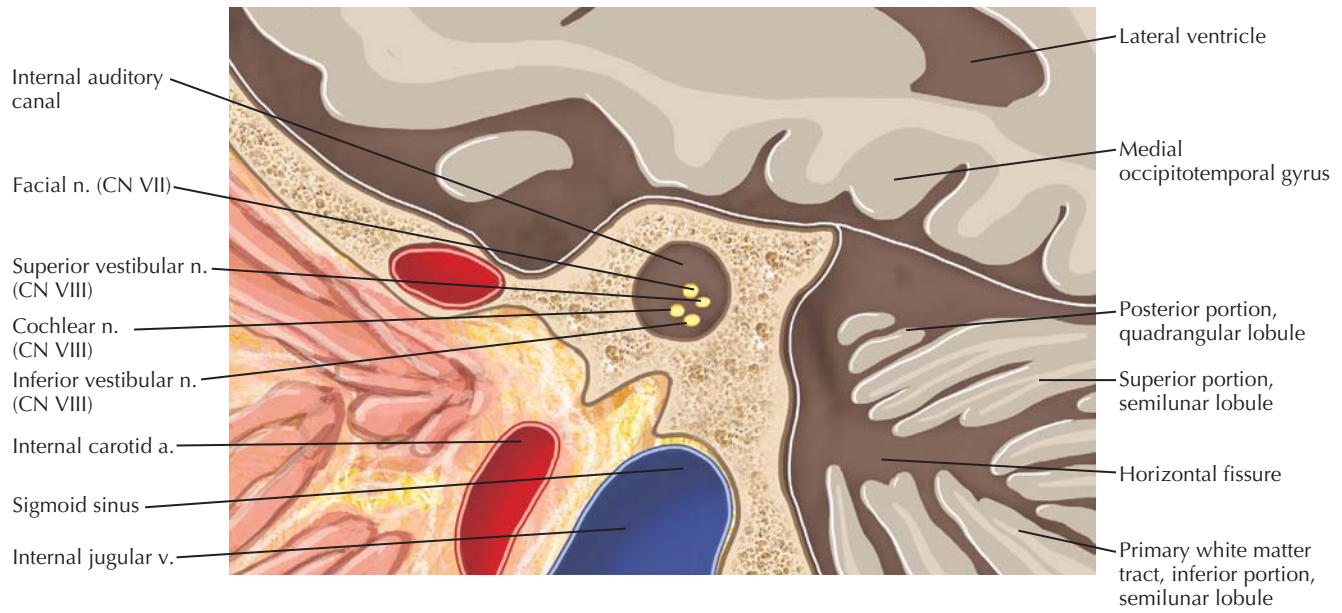
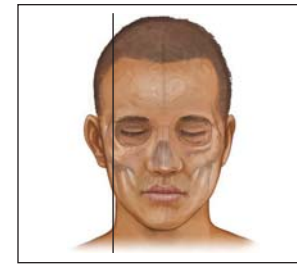




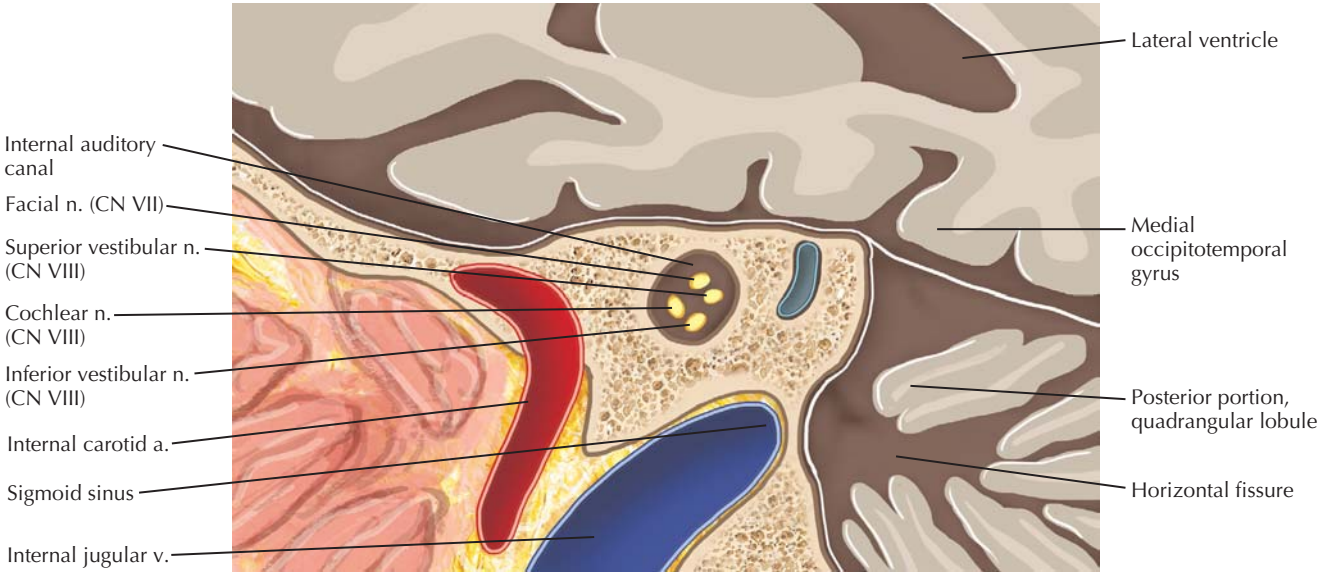
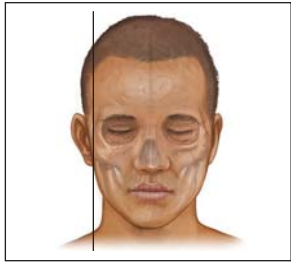


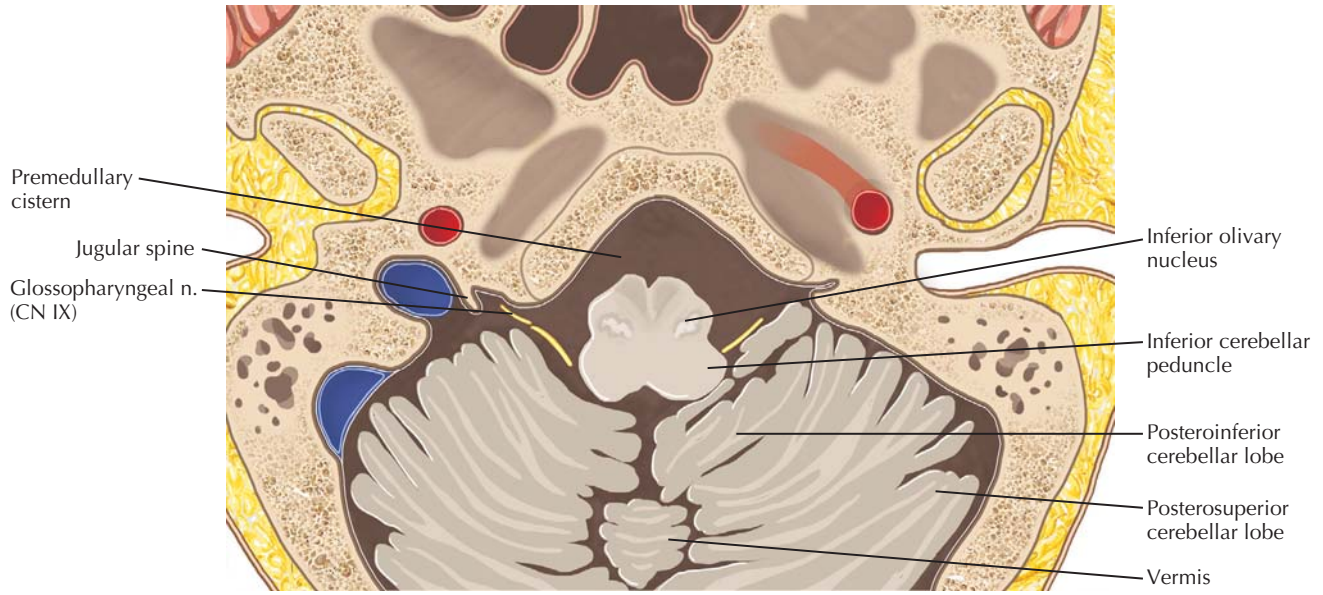
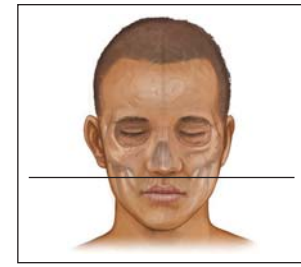


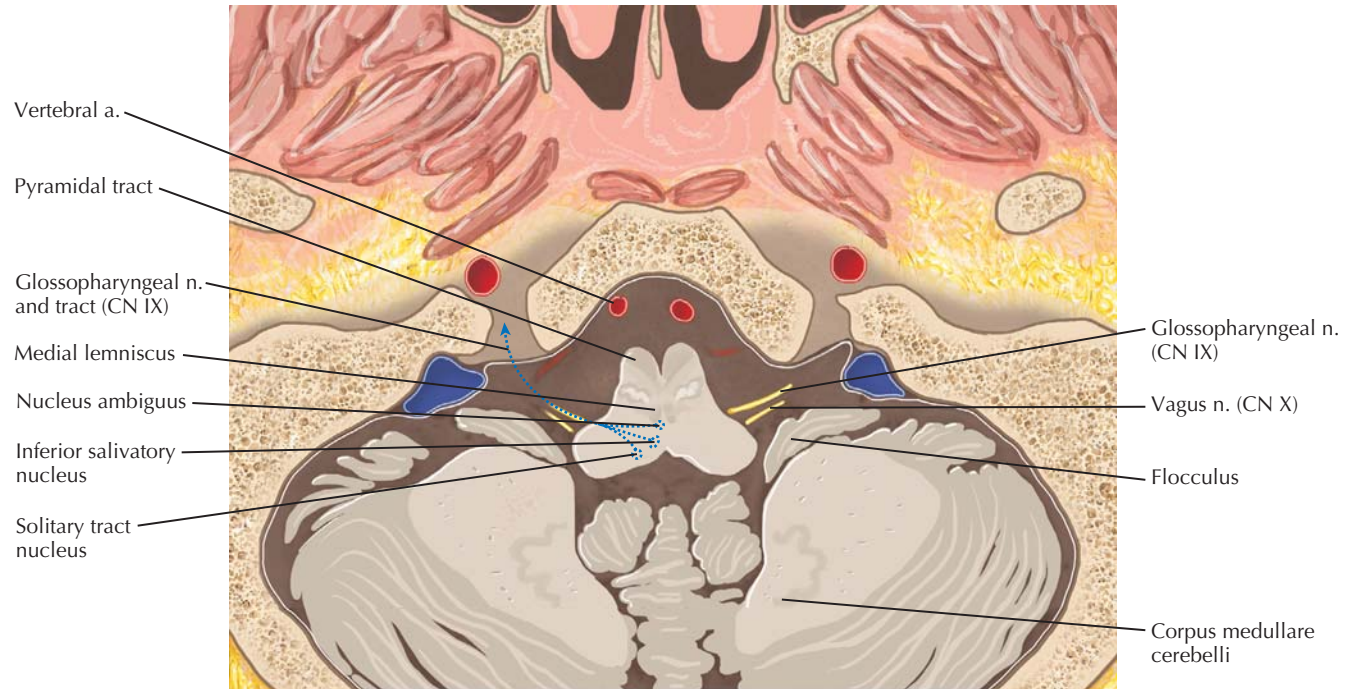
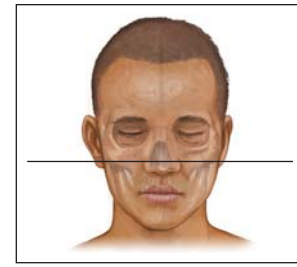


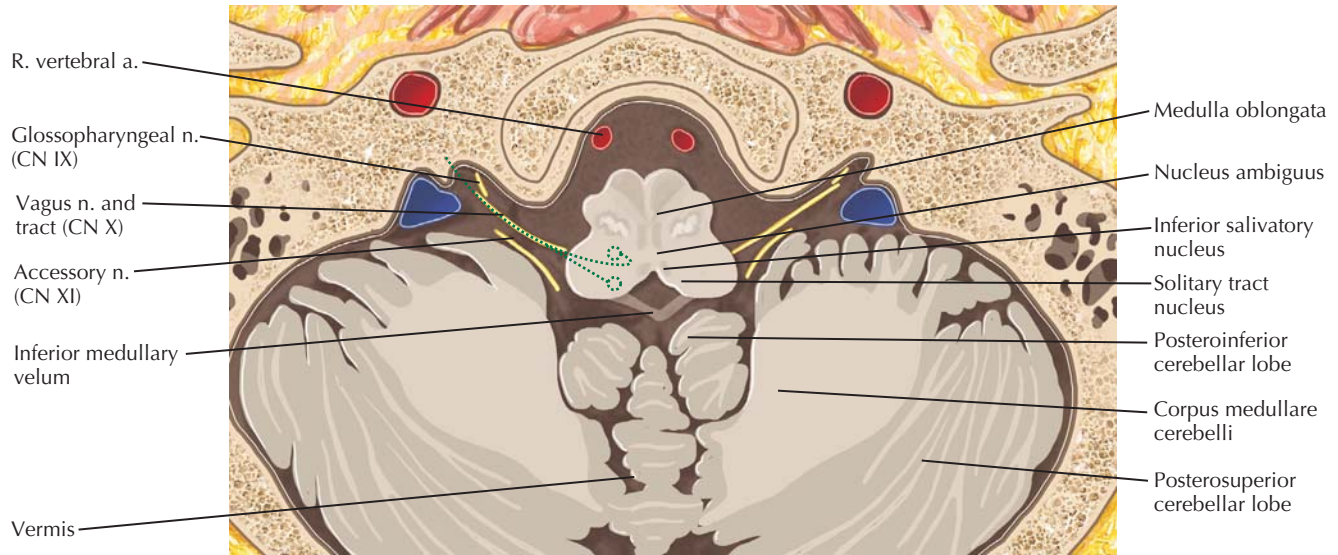
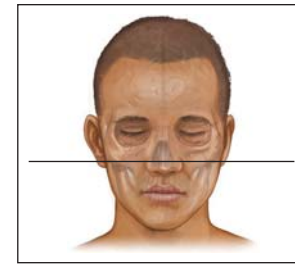


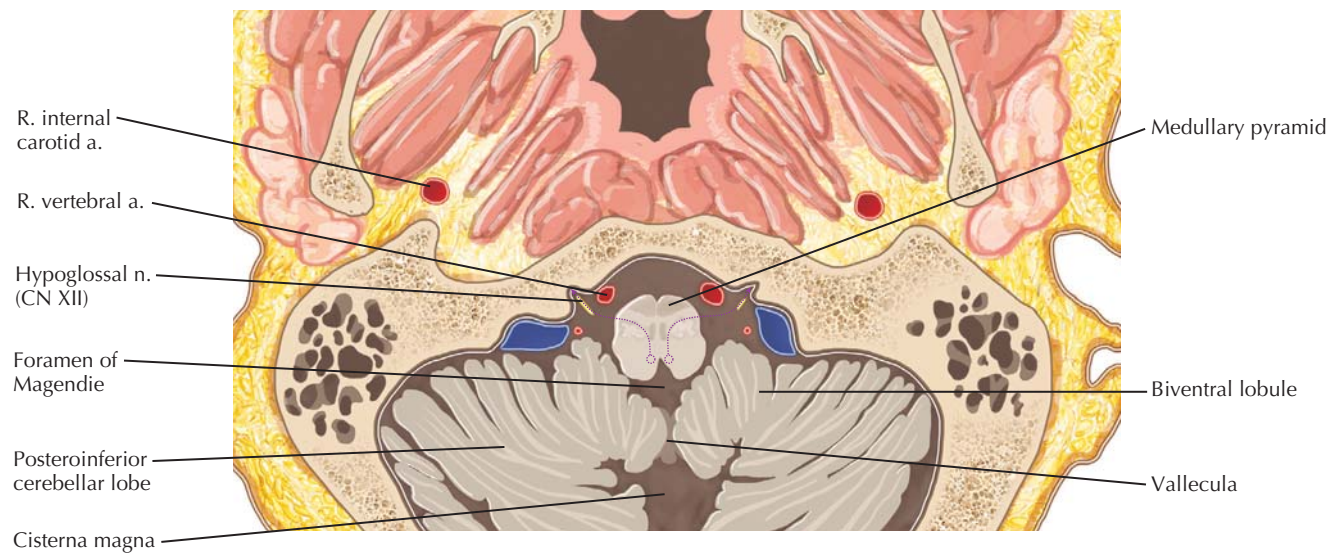
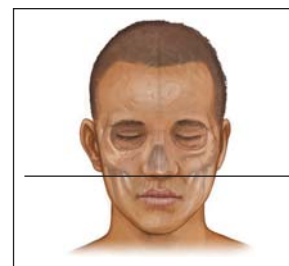












# VIDEO DISSECTIONS OF THE CRANIAL NERVES

Videos from **Netter's Dissection Video Modules** adapted from *Netter's Online Dissection Modules* by University of North Carolina, Chapel Hill.

For more information or to purchase more videos visit [https://studentconsult.inkling.com/store/book/netter-dissection-modules-henson-1/?ia\\_search\\_q=netter&ia\\_view\\_type=book&ia\\_result\\_type=book](https://studentconsult.inkling.com/store/book/netter-dissection-modules-henson-1/?ia_search_q=netter&ia_view_type=book&ia_result_type=book)

Videos available on **Student Consult**. Please see **Instruction for online access** in the Table of Contents

Video 4-1	Transection of cranial nerves and vessels in the anterior and middle cranial fossae	Video 4-7	Superior oblique muscle; trochlear and lacrimal nerves	Video 4-13	Internal acoustic meatus; labyrinthine artery; facial and vestibulocochlear nerves
Video 4-2	Transection of additional cranial nerves in the middle cranial fossa	Video 4-8	Extraocular muscles and superior division of the oculomotor nerve	Video 4-14	Branches of the external carotid artery; hypoglossal nerve
Video 4-3	Transection of nerves in the posterior cranial fossa	Video 4-9	Optic canal and its contents; common tendinous ring; oculomotor and trochlear nerves	Video 4-15	Exposure of spinal cord and roots of accessory nerve
Video 4-4	Parotid gland and facial nerve	Video 4-10	Exposure of the optic nerve; ocular branches of the ophthalmic artery; ciliary ganglion and short ciliary nerves	Video 4-16	Vagus nerve; left recurrent laryngeal nerve
Video 4-5	CN III, V, and VI in the floor of the cranial cavity; trigeminal cave and ganglion; mandibular division of CN V	Video 4-11	Inferior division of the oculomotor nerve	Video 4-17	Hypoglossal nerve; superior cervical ganglion; structures emerging from the jugular foramen
Video 4-6	Nerves, vessels, and foramina of the nasal cavity (skull)	Video 4-12	Branches of the mandibular division of the trigeminal nerve		