

# An Atlas of Surgical Anatomy

A detailed pencil drawing of a hand holding a surgical instrument, possibly a scalpel or forceps, over an anatomical dissection. The drawing is rendered in a classic, detailed style, showing the texture of the skin and the underlying structures of the hand and forearm. The background is a solid dark red color.

*Surgical Commentary  
by Alain C Masquelet*

*Illustrations by Léon Dorn*

 Taylor & Francis  
Taylor & Francis Group

with  
CD-ROM

# An Atlas of Surgical Anatomy



An Atlas of  
**Surgical Anatomy**

Surgical commentary by

**Alain C Masquelet**, MD

**Illustrations by Léon Dorn**

© 2005 Taylor & Francis, an imprint of the Taylor & Francis Group

First published in the United Kingdom in 2005  
by Taylor & Francis, an imprint of the Taylor & Francis Group,  
2 Park Square, Milton Park, Abingdon, Oxon OX14 4RN

Tel.: +44 (0) 1235 828600  
Fax.: +44 (0) 1235 829000  
E-mail: [info@dunitz.co.uk](mailto:info@dunitz.co.uk)  
Website: <http://www.dunitz.co.uk>

All rights reserved. No part of this publication may be reproduced, stored in a retrieval system, or transmitted, in any form or by any means, electronic, mechanical, photocopying, recording, or otherwise, without the prior permission of the publisher or in accordance with the provisions of the Copyright, Designs and Patents Act 1988 or under the terms of any licence permitting limited copying issued by the Copyright Licensing Agency, 90 Tottenham Court Road, London W1P 0LP.

Although every effort has been made to ensure that all owners of copyright material have been acknowledged in this publication, we would be glad to acknowledge in subsequent reprints or editions any omissions brought to our attention.

Although every effort has been made to ensure that drug doses and other information are presented accurately in this publication, the ultimate responsibility rests with the prescribing physician. Neither the publishers nor the authors can be held responsible for errors or for any consequences arising from the use of information contained herein. For detailed prescribing information or instructions on the use of any product or procedure discussed herein, please consult the prescribing information or instructional material issued by the manufacturer.

A CIP record for this book is available from the British Library.

Library of Congress Cataloging-in-Publication Data  
Data available on application

ISBN 1 84184 000 0

Distributed in North and South America by  
Taylor & Francis  
2000 NW Corporate Blvd  
Boca Raton, FL 33431, USA

Within Continental USA  
Tel.: 800 272 7737; Fax.: 800 374 3401  
Outside Continental USA  
Tel.: 561 994 0555; Fax.: 561 361 6018  
E-mail: [orders@crcpress.com](mailto:orders@crcpress.com)

Distributed in the rest of the world by  
Thomson Publishing Services  
Cheriton House  
North Way  
Andover, Hampshire SP10 5BE, UK  
Tel.: +44 (0)1264 332424  
E-mail: [salesorder.tandf@thomsonpublishingservices.co.uk](mailto:salesorder.tandf@thomsonpublishingservices.co.uk)

Typeset by Scribe Design, Ashford, Kent  
Printed and bound by

# Contents

---

Preface vii

Léon Dorn: A biographical note viii

Léon Dorn: Notes on method ix

## 1 Reconstructive surgery

The tree of flaps for the upper limb 2

Flap from the lateral head of  
gastrocnemius 3

Soleus muscle flaps 5

Sural skin flap 8

Vascularised osteoperiosteal flap from the  
femur 10

Vascularised fibula transfer 11

Lateral brachial flap 14

Forearm radial flap 16

Posterior interosseous flap 18

Pronator quadratus muscle flap 20

## 2 Hand and peripheral nerve surgery

Anatomy of the hand 24

The trapezium: volar approach 27

The 'boutonnière' deformity 31

Arthrolysis of the PIP joint 34

Protective flaps for the median nerve at the  
wrist 36

Flexor digitorum superficialis transfer to the  
thumb 38

Vascularised bone transfer from the metaphysis  
of the second metacarpal 39

Dupuytren's disease 40

Surgery of the wrist 44

Pollicisation of the index finger 45

Brachial plexus 49

Exposure of the interosseous nerve 54

Exposure of the radial nerve at the  
elbow 57

## 3 Gynaecological surgery

The lower approach of the prolapse and  
the separation of the vagina and the  
bladder 60

Treatment of genital prolapse after  
hysterectomy 65

Surgical treatment of elythrocele 70

## 4 Urological surgery

Allotransplantation of the kidney 74

Surgery of renal lithiasis 79

Extrophy of the bladder in a young boy 81

Hypospadias surgery 86

Prosthesis for erectile function of penis 90

Amputation of the penis for sexual ambiguity:  
feminisation 97

## 5 Abdominal surgery

Reconstruction of a urinary bladder 106

Gastrectomy 110

The liver 115

## 6 Surgery of the vertebral column

Transpleural approach to the dorsal rachis by  
thoracotomy 120

Treatment of lumbar spondylolisthesis 122

Surgical treatment of scoliosis 126

Treatment of lumbar disc hernia: anterior  
approach 129

## 7 Upper limb surgery

Sternoclavicular dislocation 134

Stabilisation of a shoulder prosthetic  
implant 136

Cleidectomy 137

Osteosynthesis of a fracture of the  
forearm 139

Anterior approach to the subacromial  
space 141

# Contents

---

- Anterior approach to the glenohumeral joint 143
- Axillary approach to the glenohumeral joint 147
- Subdeltoid approach to the proximal metaphysis of the humerus 150
- Anterior approach to the proximal third of the radius 151

## 8 Lower limb surgery

- Anatomy of the posterior approach to the femoral shaft 154
- Extended medial approach to the popliteal vessels 157
- Anatomy of the knee 160
- Anatomy of the lumbosacral plexus 162
- Prosthesis of the patella 163
- Repair of a rupture of the anterior cruciate ligament 167
- Posterior approach to the posterior cruciate ligament 171

- Allograft of patella and patellar ligament 173
- Cross-section through the hip joint 176
- Posterior approach to the acetabulum 177
- Inguinal approach to the acetabulum 181
- Extended iliofemoral approach to the acetabulum 186
- Posteromedial approach to the ankle 190
- Lateral approach to the subtalar and midtarsal joint 193

## 9 Miscellaneous

- Muscular studies 195
- Surgery of the ear: neurosurgery 199
- Surgery of the middle ear 202
- Tympanic graft 204
- Paediatrics: Pavlick's harness 207
- Congenital malformations 208
- Detection of fetal anomalies 216
- Dissection of the left heart 217
- Dissection of the right heart 221

Index 225

# Preface

---

Léon Dorn is one of the most famous medical illustrators in the world. Even today, at 80 years of age, he continues to pursue his work with the same enthusiasm. His work coincides with his great passion: the representation of the human body. Anatomy holds no secrets for him. He has spent countless hours in operating theatres, dissecting rooms and with himself; when Léon Dorn is drawing hands, he is drawing his own hands ...

Until recently, medical illustration was an undervalued job. The illustrators were basically artists, attracted to the human body. Many of them were self-trained people. Most of the time they were not well considered and some publishers even refused to mention their names in books.

Today, medical illustration has gained its 'letters patent of nobility'. Léon Dorn has witnessed the emergence, the development and the now well recognised state of the medical illustration.

Dorn is specially involved in the illustration of surgical techniques, which is probably the most difficult part of the art of medical illustration since the illustrator must attend surgical operations to understand what exactly is being done and then distil a long procedure into a few drawings. Usually, no more than five to seven drawings are needed to illustrate a surgical technique. The skill and possibly the genius of the artist lies in their ability to condense multiple operating stages into a limited number of drawings.

From a didactic point of view, it reveals the superiority of drawings over film. A film (movie or video sequence) delivers a linear succession of snap shots whereas a single drawing illustrates an entire sequence of a technical procedure.

For learning a technique, human understanding proceeds more by intuitive discerning of whole stages rather than separate elementary actions. This is the reason why the medical illustration based on drawings is superior to one based on videos. In spite of the recent advances in techniques of communi-

cation, the illustrated book will always be valid for the learning process.

I would like just to comment upon Léon Dorn's manner of working. Some illustrators work at home, trying to restore a surgical technique from a draft prepared by the surgeon. Dorn's method is quite different. For him, the illustrator is like a reporter, an eye witness and a field worker; he has to perceive the intensity of an acute stage to express it through the drawing. This book is an attempt to communicate this particular state of mind. With Léon Dorn we have selected over 300 drawings from among a collection of several thousands.

These selected drawings do not constitute a treatise of surgical techniques. Their function is to highlight one of the main stages of the illustrator's work, which is the 'almost finished rough sketch'. For that reason the drawings are still outlines in lead pencil, in black and white. We have included a few definitive drawings in colour to show the contrast between what is actually published and what is the most important stage of the artist's work. Thus we present isolated drawings or several associated drawings, taken from different surgical fields, which do not constitute the complete description of a surgical technique.

The drawings are succinctly explained, just for understanding what they show. Where they are present, we have kept the legends written by the artist as an aid for the definitive drawing. On the other hand, we have not added new legends that could impede the serene contemplation of the drawings. What is important for the readers is to open their eyes for pleasure; the secret is not in the text but in the illustrations. Léon Dorn has rejuvenated the tradition of the medical illustrators who were initially artists admiring the human body, such as Calcar, the pupil of Le Titian, who immortalised the dissections of Vesalius, or Jacob, the pupil of David, who drew the anatomical preparations of Bourguery.

*AC Masquelet*



# Léon Dorn

---

## A biographical note

Léon Dorn was born in Paris in 1920. He lived in Israel from 1932 to 1965, where he worked in a kibbutz. This long stay in Israel was interrupted for two years (1953–1954) during which he studied at the Academy of Arts in Florence (Italy). In 1961, he was named general secretary of the Organisation of Painters and Sculptors of Kibboutzim.

He began to work as a medical illustrator when he came back to France in 1965. He was mostly commissioned by Masson Publishers and, in 1989, was invited by Professor Tubiana to illustrate surgi-

cal books for Martin Dunitz. His illustrations for *An Atlas of Flaps in Limb Reconstruction* (published by Martin Dunitz) won the Royal Society of Medicine Atlas award in 1995.

Léon Dorn is a pioneer of modern medical illustration in France. He actively participated in the efforts of the European Association of Medical and Scientific Illustrators to promote special schools devoted to medical illustration. A department was opened at the Ecole Estienne of Paris in 1992.

# Léon Dorn

---

## Notes on method

What is the method of Léon Dorn? Another form of this fascinating question could be: How is the genesis of a definitive drawing?

The secret of Léon Dorn is based on two principles:

1. An excellent knowledge of anatomy. As Léon Dorn has worked with many surgeons from different specialties, he has indepth knowledge of the anatomy of the human body. Moreover, he has contributed to several books on anatomy. It can be said that during his entire professional life Dorn has continued to compare anatomy as described and taught in books with real-life anatomy as encountered in operating rooms and theatres.
2. The second principle issues from the first. Léon Dorn draws 'live'. In his professional life he is permanently on the move to attend surgical operations and dissections. The vast majority of his illustrations have not been drawn from photographs or rough sketches made by surgeons but from what he has seen and observed.

The realisation of a definitive drawing as it will be published in a book has three important stages. It has been difficult to retrieve all the stages for one drawing from Dorn's archives. He has lost many drawings, and the first stage of a drawing is generally destroyed.

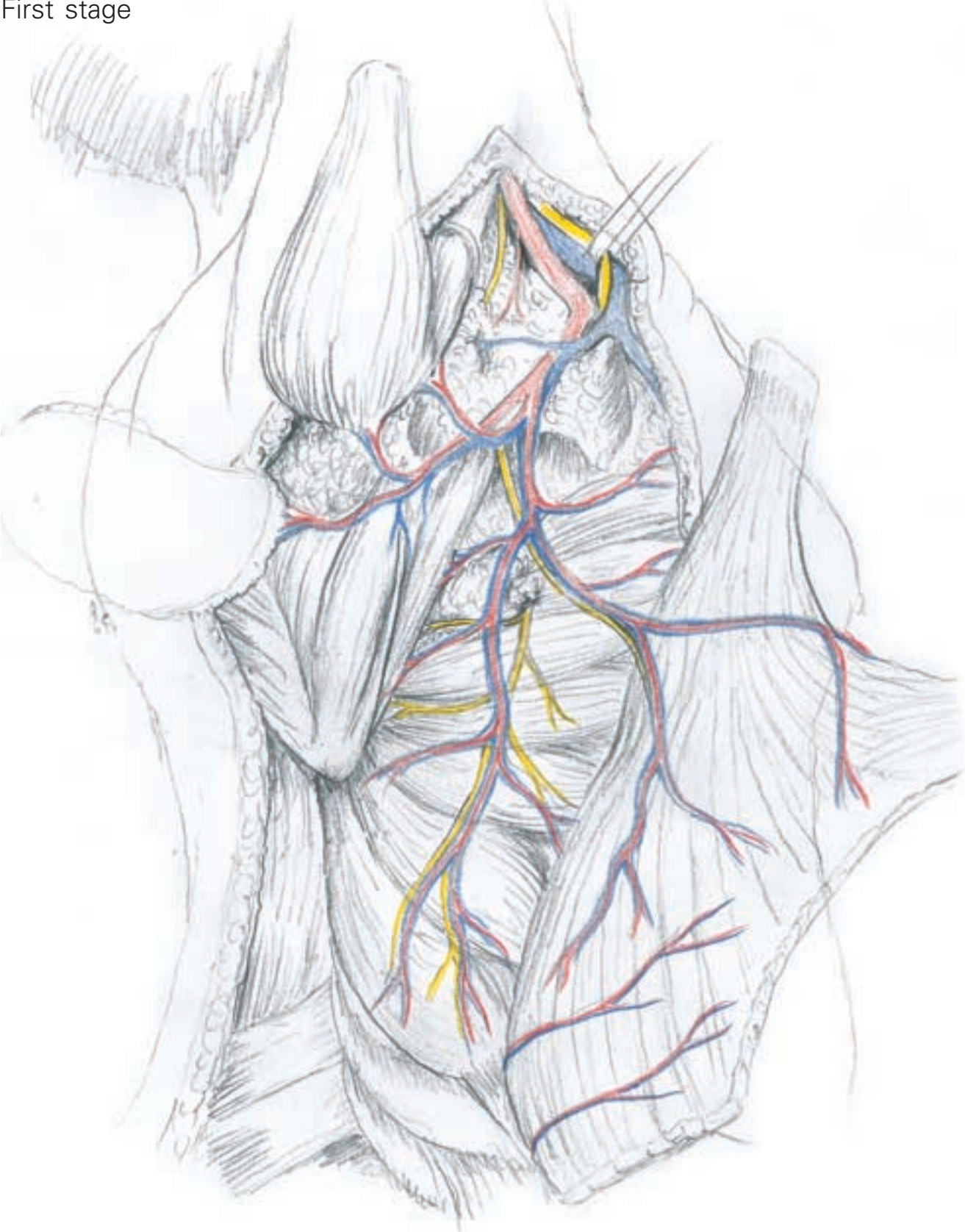
We have only one example of a complete series.

- a) The first drawing is done in the operating room or in a theatre of anatomy. It can be called a sketch, but it is a very precise sketch. All the proportions are good, and all the structures are set in place: the nerves are coloured yellow, veins blue and arteries red. Some legends are added to remember exactly what has been drawn.
- b) The second stage is drawn 'at home'. It is the intermediate stage between the sketch and the definitive drawing. It can be called the 'rough drawing'. Details are precisely drawn, for example the representation of the arteries and the thickness of the subcutaneous tissue. In this stage, primarily the shadows are applied to increase the impression of volume for the muscles and the perspective for the deep structures. The rough drawing is given to the surgeon who can then modify any detail on a tracing paper firmly attached to the drawing.
- c) The definitive drawing is made once the rough drawing has been corrected. The structures are coloured or underlined in black ink and with paint.

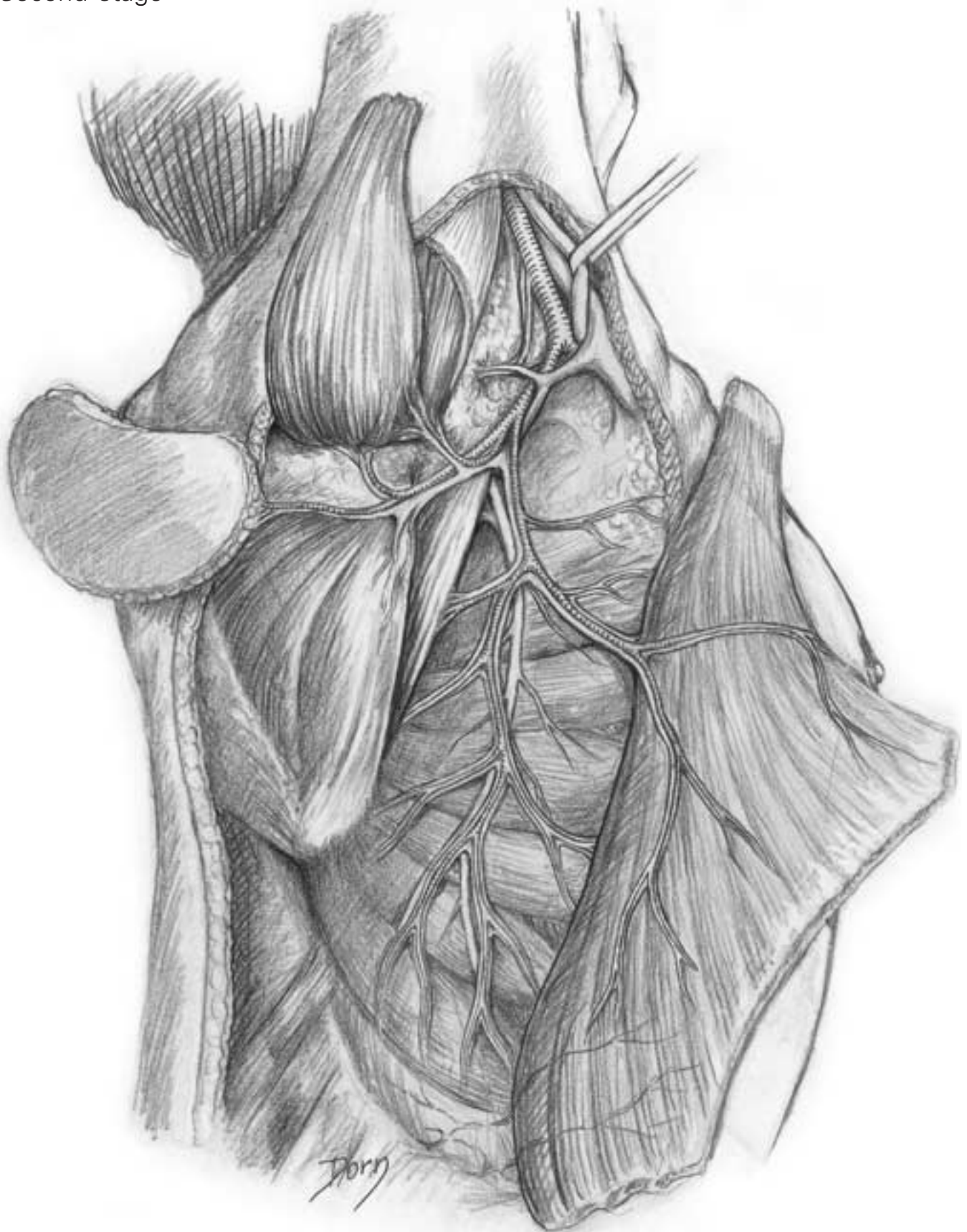
The destiny of each stage is quite different:

- The sketches are generally destroyed or lost.
- The definitive drawing is given to the publisher and becomes their property.
- The intermediate stage - the rough drawing - which is, in fact, the most beautiful stage because it is the most realistic, remains the property of Léon Dorn.

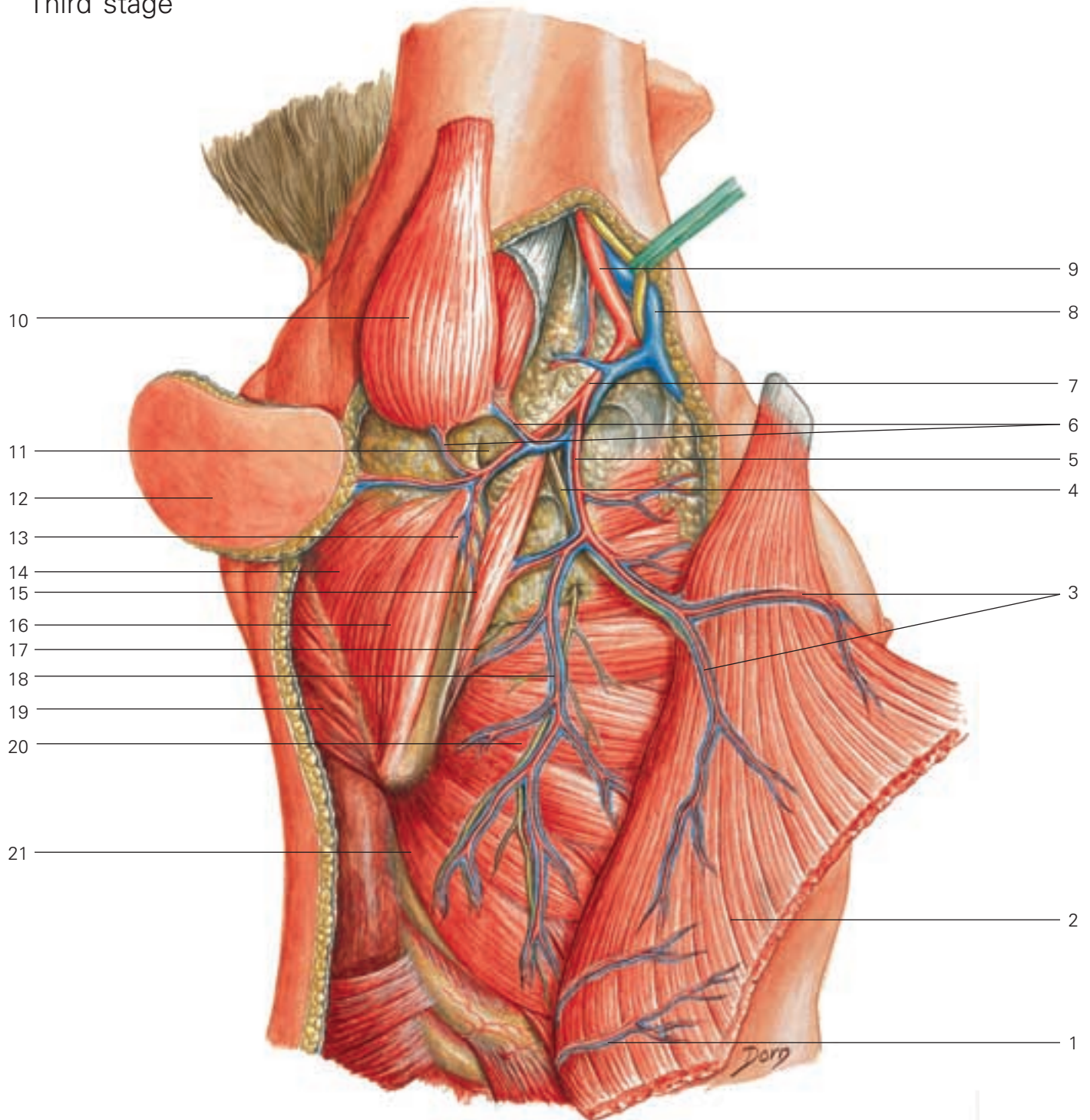
First stage



Second stage



Third stage



**D**

- |  |  |  |
|--|--|--|
| 1 intramuscular pedicle issuing from intercostal arteries                | 7 subscapular artery                             | 15 subscapular muscle  |
| 2 latissimus dorsi muscle  | 8 axillary vein                                  | 16 teres minor muscle  |
| 3 intramuscular divisions of vascular pedicle supplying latissimus dorsi | 9 axillary artery                                | 17 bony angular branch to scapula (anastomoses with vascular pedicle supplying rim of scapula) |
| 4 nerve to latissimus dorsi  | 10 teres major muscle                            | 18 thoracic vessels  |
| 5 thoracodorsal pedicle  | 11 circumflex scapular artery and vein           | 19 trapezius and rhomboid muscles  |
| 6 pedicles to teres major muscle   | 12 scapular flap                                 | 20 long thoracic nerve   |
|  | 13 vascular pedicle supplying rim of the scapula | 21 serratus anterior muscle  |
|  | 14 infraspinatus muscle                          |  |

# Reconstructive surgery

During the past 30 years, reconstructive surgery has undergone incredible development. One of the main factors is microsurgical techniques which have permitted transfer of all kinds of tissue. There has been a renewed interest in anatomy, especially for the description of nutritive sources and vascular pedicles.

Recent advances in immunosuppressive treatment have allowed allotransplantation of functional organs, such as the hand.

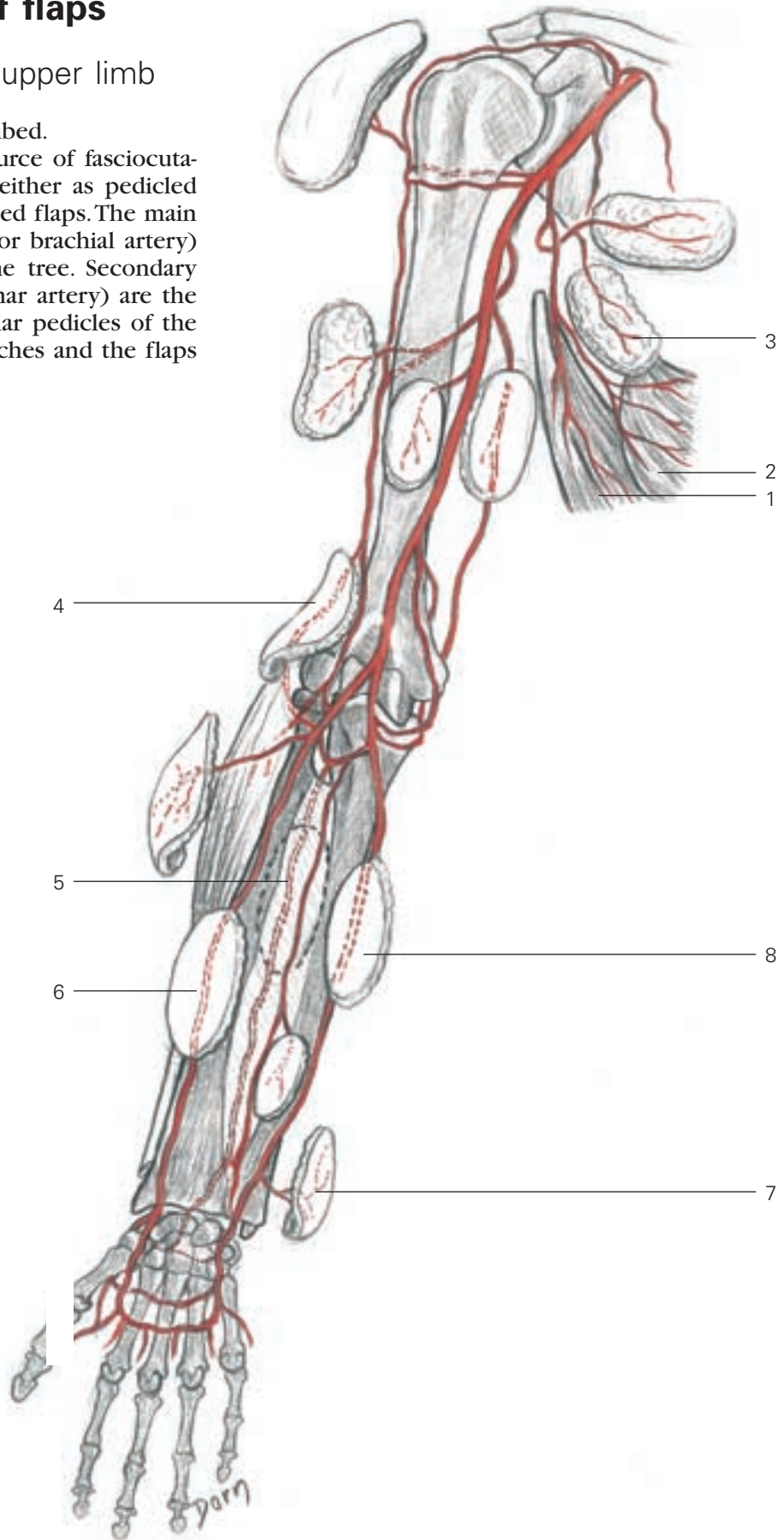
*An Atlas of Flaps of the Musculoskeletal System* is the latest book illustrated by Léon Dorn. All the drawings are based on anatomical dissections and every detail is authentic.

## Anatomy: the tree of flaps

The tree of flaps for the upper limb

Numerous flaps have been described.

The upper extremity is the source of fasciocutaneous flaps which can be used either as pedicled island flaps or as free revascularised flaps. The main vascular axis (the axillary artery or brachial artery) is considered as the trunk of the tree. Secondary arteries (such as the radial or ulnar artery) are the divisions of the trunk. The vascular pedicles of the flaps are formed from small branches and the flaps are the leaves.

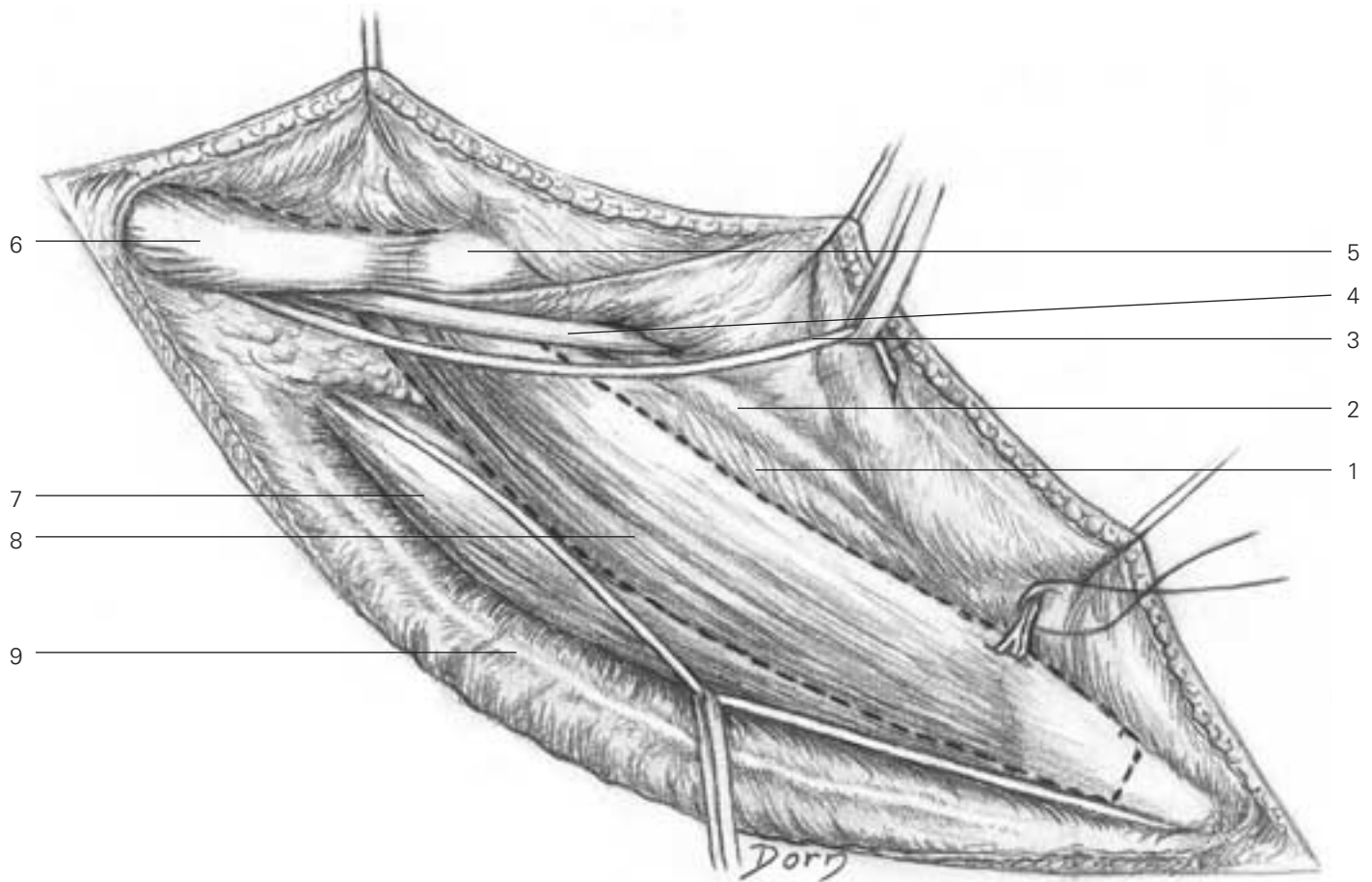


- 1 latissimus dorsi flap
- 2 serratus anterior flap
- 3 scapular flaps
- 4 lateral arm flap
- 5 posterior intraosseous flap
- 6 radial forearm flap
- 7 distal ulnar flap
- 8 ulnar forearm flap

## Flaps from the lower limb

Flap from the lateral head of the gastrocnemius

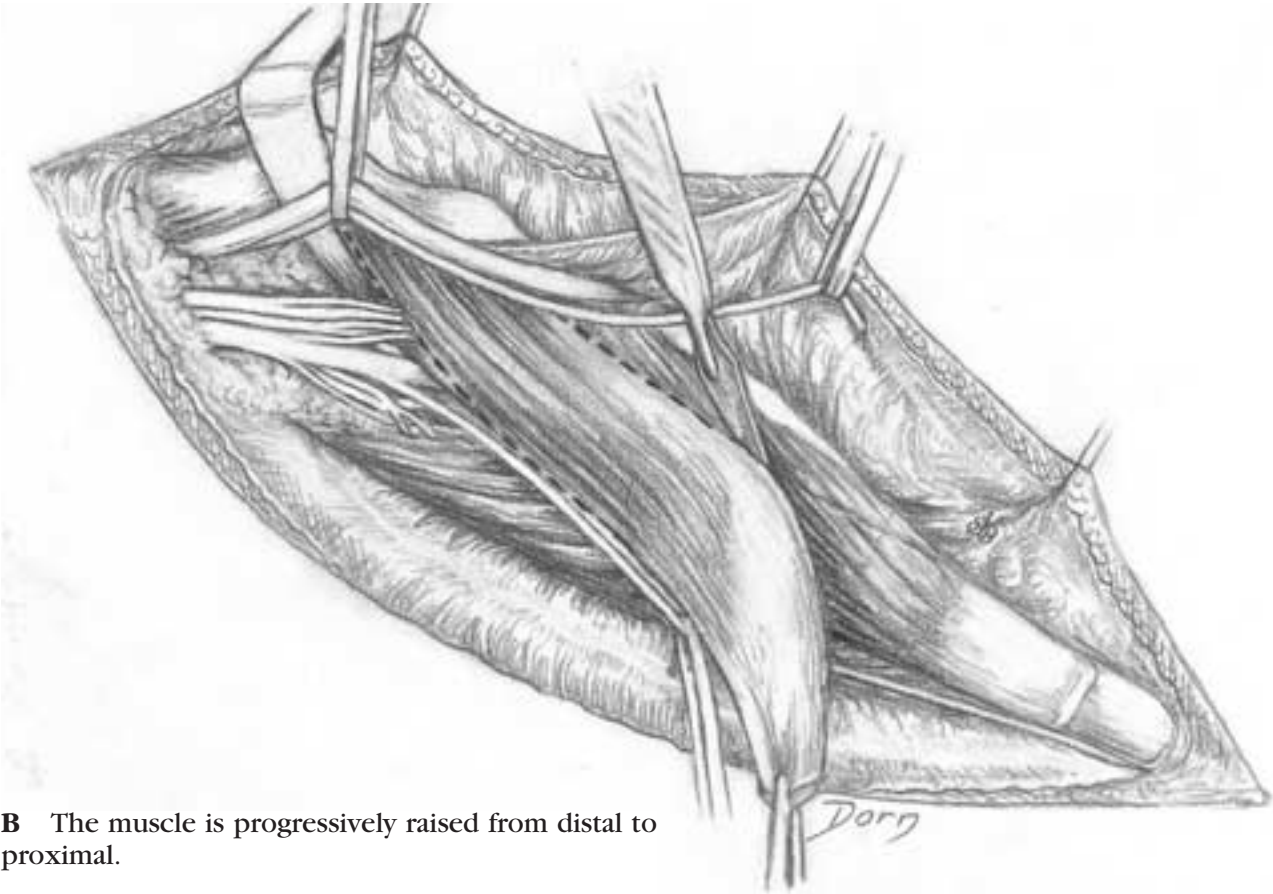
**A** The muscle is exposed with all the surrounding structures.



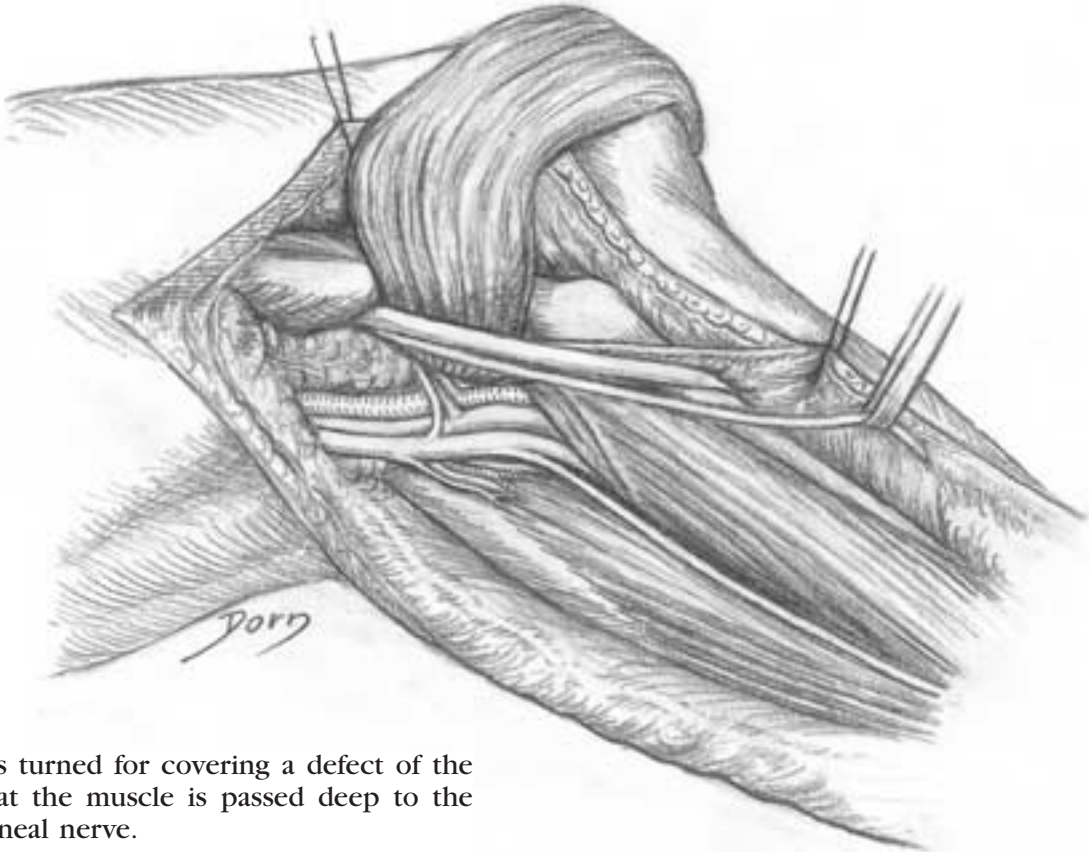
### **A**

- 1 soleus
- 2 fibula
- 3 lateral sural cutaneous nerve
- 4 common peroneal nerve
- 5 head of fibula
- 6 biceps femoris
- 7 gastrocnemius (medial head)
- 8 gastrocnemius (lateral head)
- 9 lesser saphenous vein





**B** The muscle is progressively raised from distal to proximal.

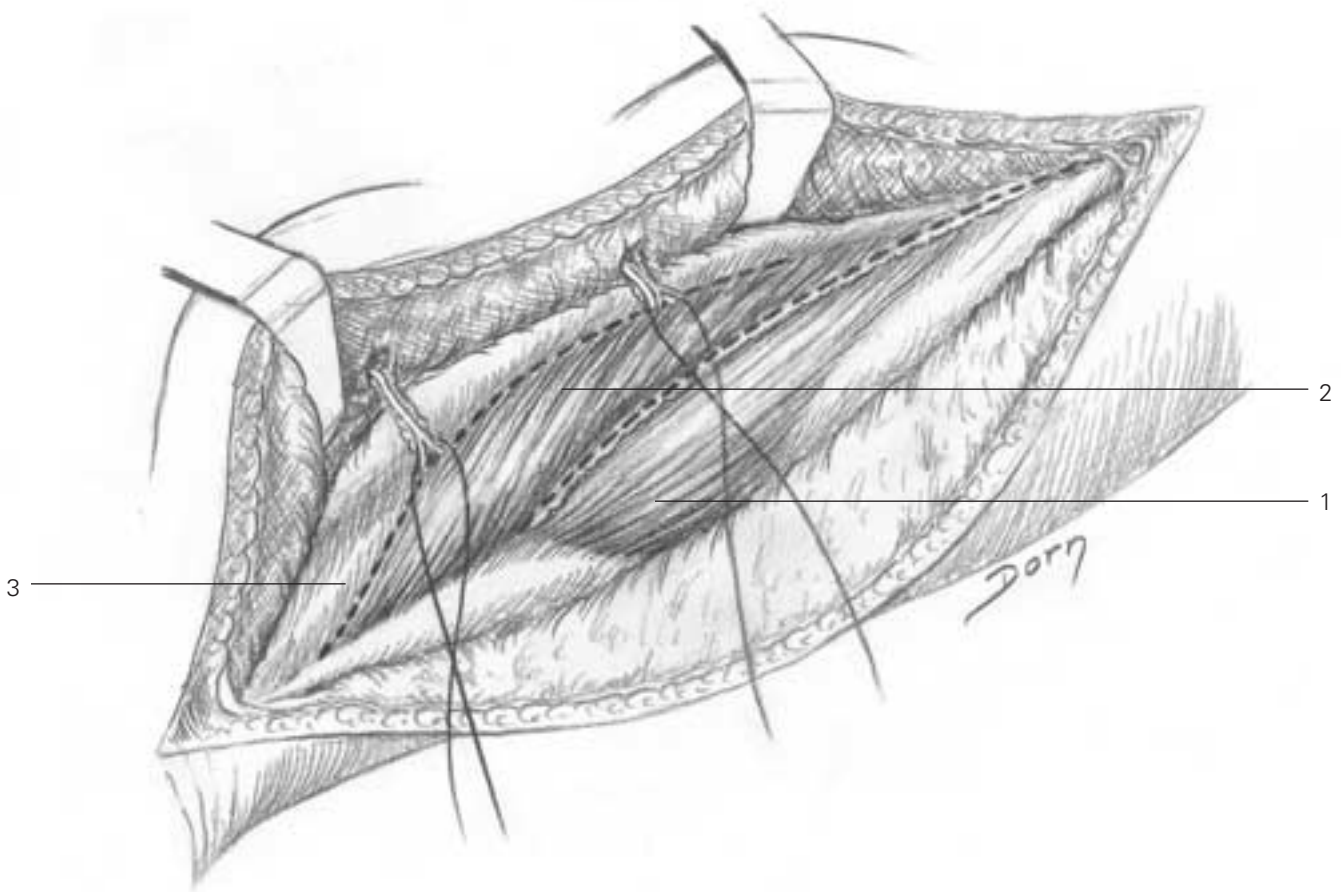


**C** The flap is turned for covering a defect of the knee. Note that the muscle is passed deep to the common peroneal nerve.

## Soleus muscle flaps

This flap is suitable for covering a defect of the middle third of the leg.

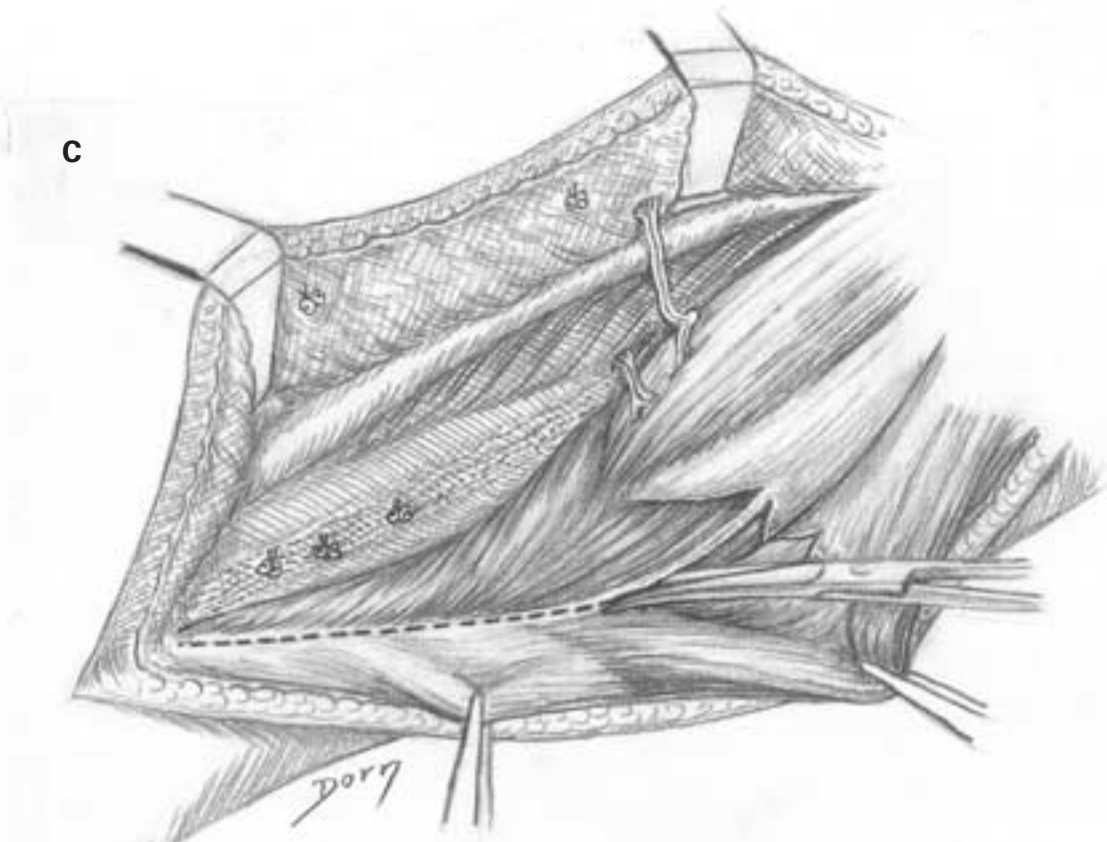
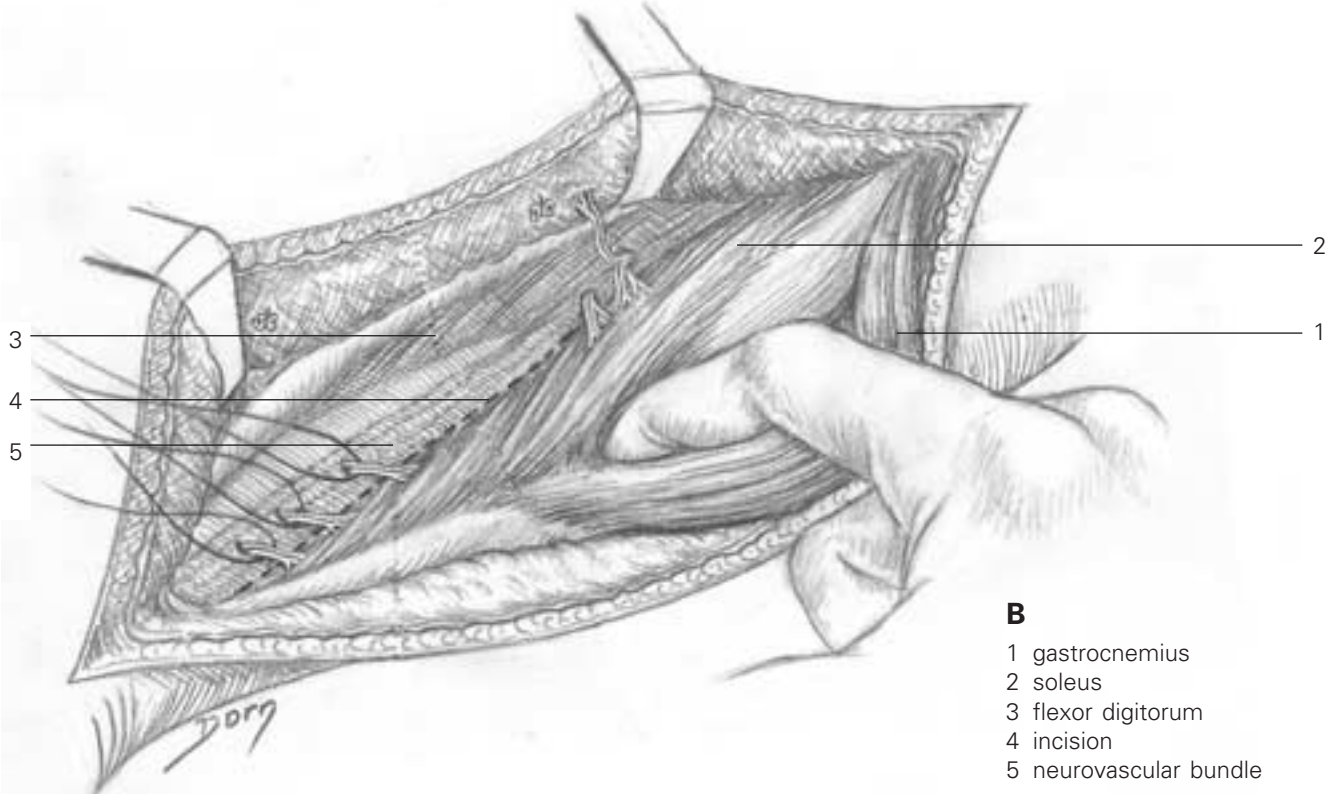
**A** The muscle is exposed on the medial aspect of the leg. Two planes of dissection are developed: (i) between the soleus and the medial head of the gastrocnemius and (ii) between the soleus and the deep posterior compartment of the leg.



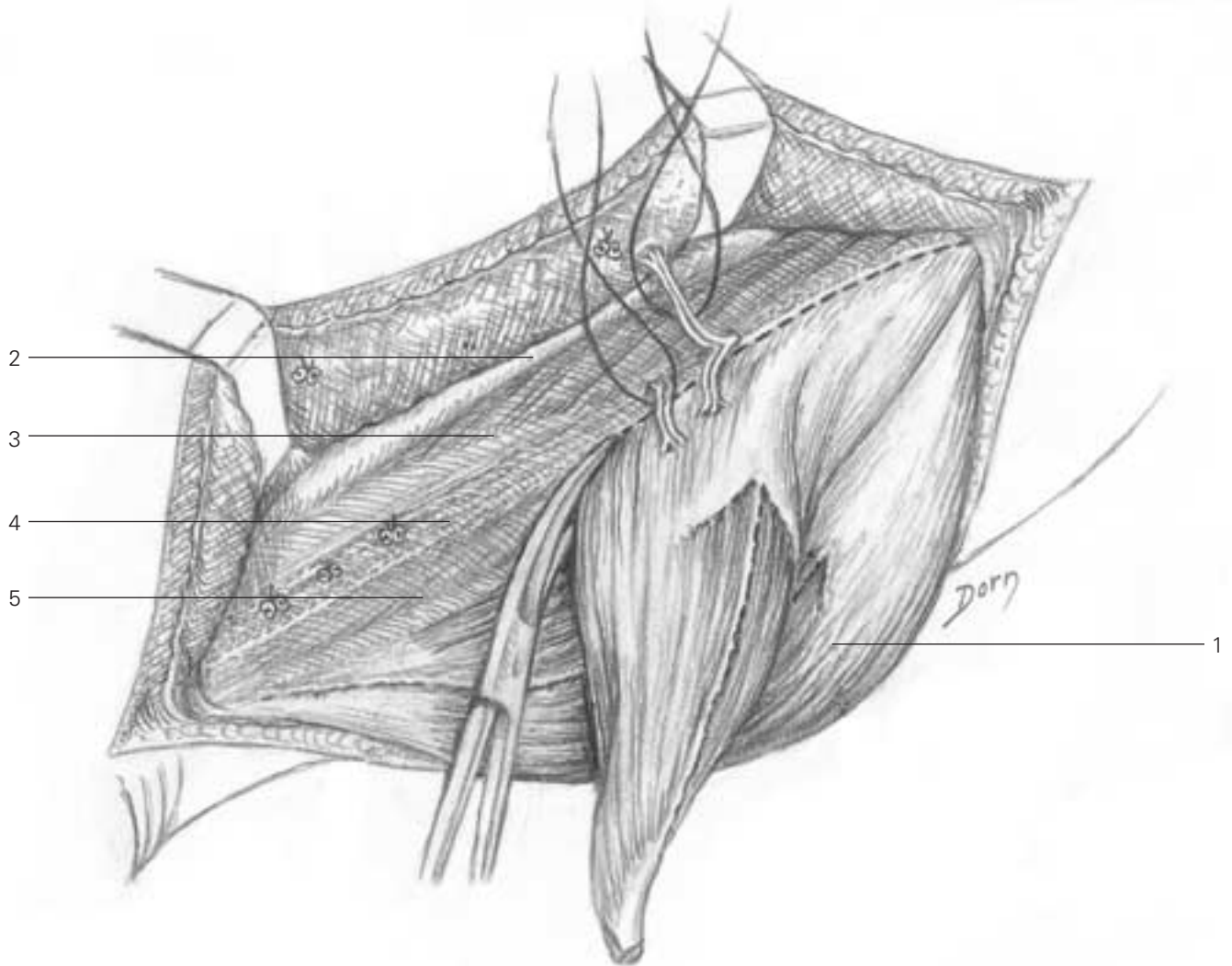
- 1 gastrocnemius (medial head)
- 2 soleus
- 3 deep posterior compartment

# Reconstructive surgery

**B, C** The distal portion of the soleus is isolated and separated from Achilles' tendon.



**D** The distal extremity of the muscle has been freed and the flap is raised from distal to proximal.



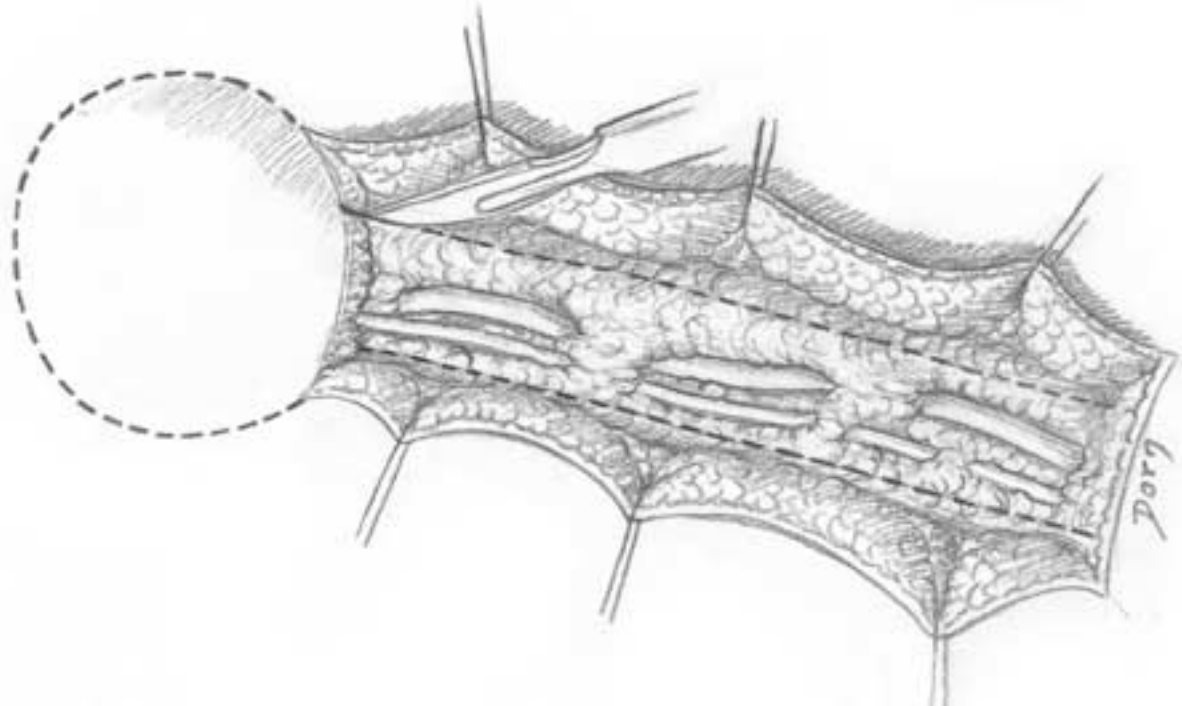
- D**
- 1 gastrocnemius
  - 2 tibia
  - 3 flexor digitorum longus
  - 4 nerve and vessels
  - 5 flexor hallucis longus

# Reconstructive surgery

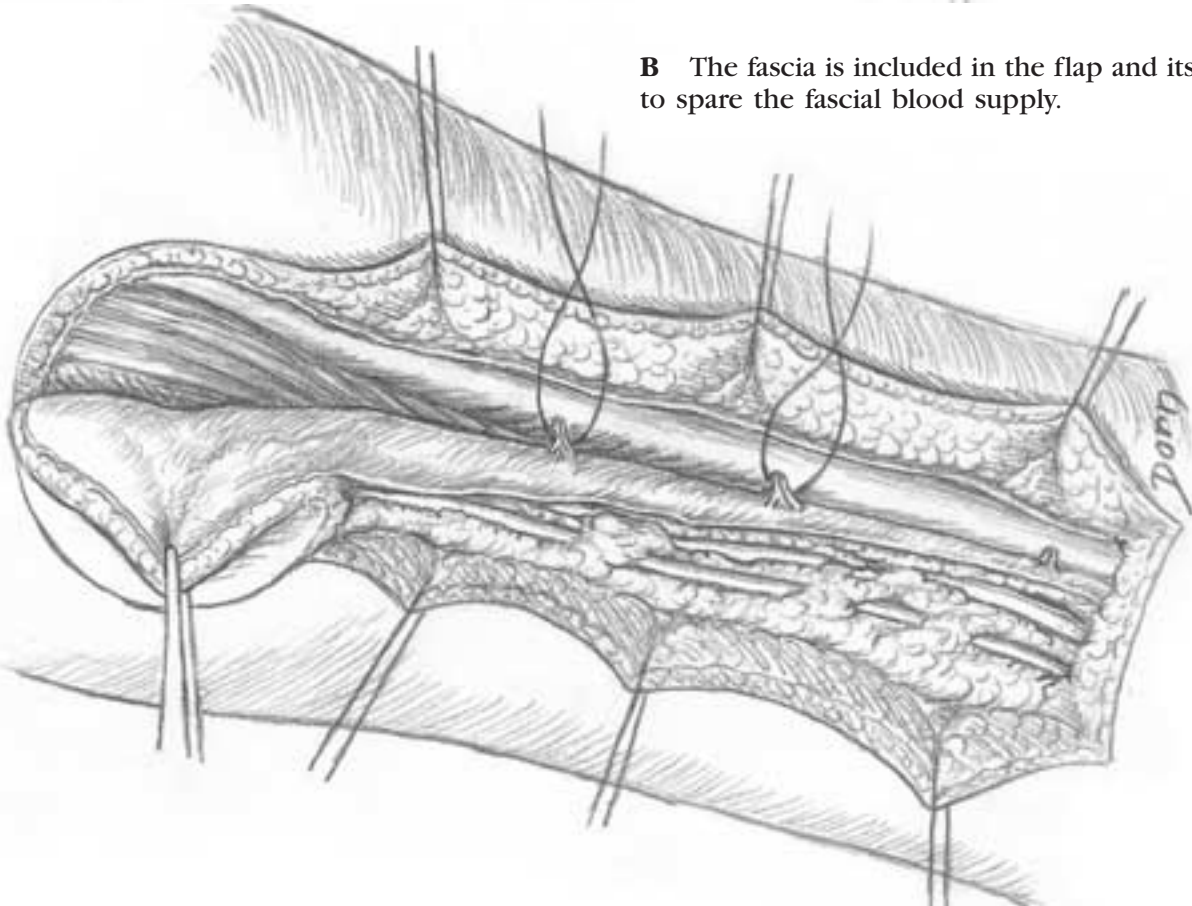
## Sural skin flap

The sural skin flap is a neurocutaneous flap which is raised on the posterior aspect of the calf.

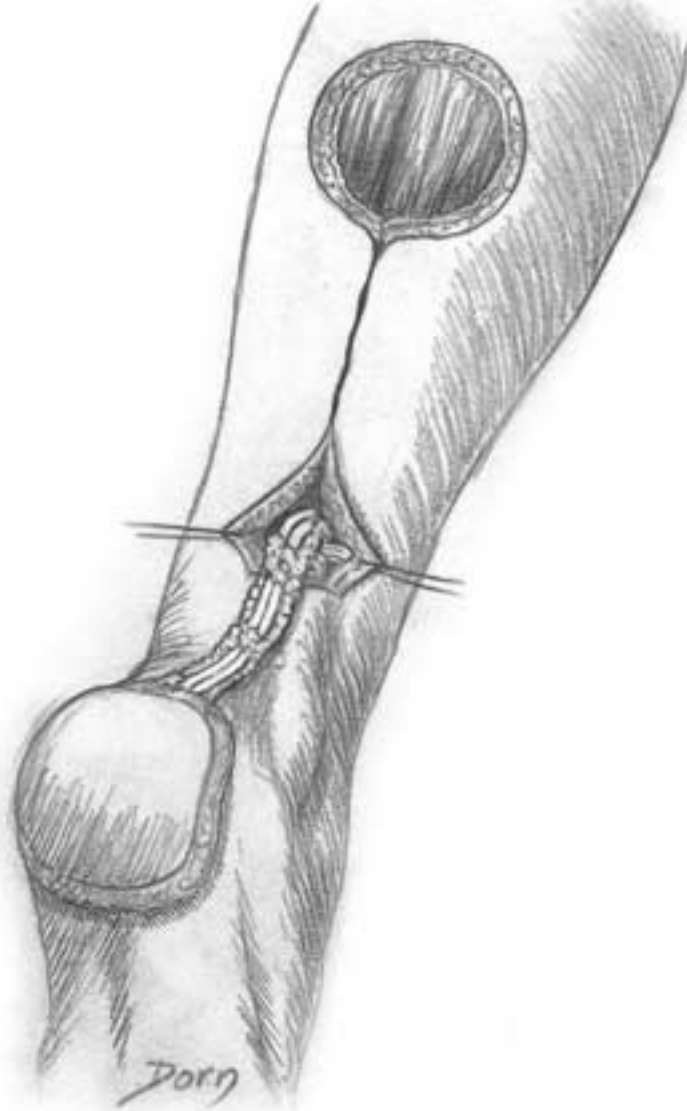
**A** The skin paddle is isolated on an adipofascial pedicle which contains a vein, superficial nerve and arterial network.



**B** The fascia is included in the flap and its pedicle to spare the fascial blood supply.



**C** This flap is indicated for covering a defect over the posterior heel. It is supplied by a perforating vessel issued from the peroneal artery.



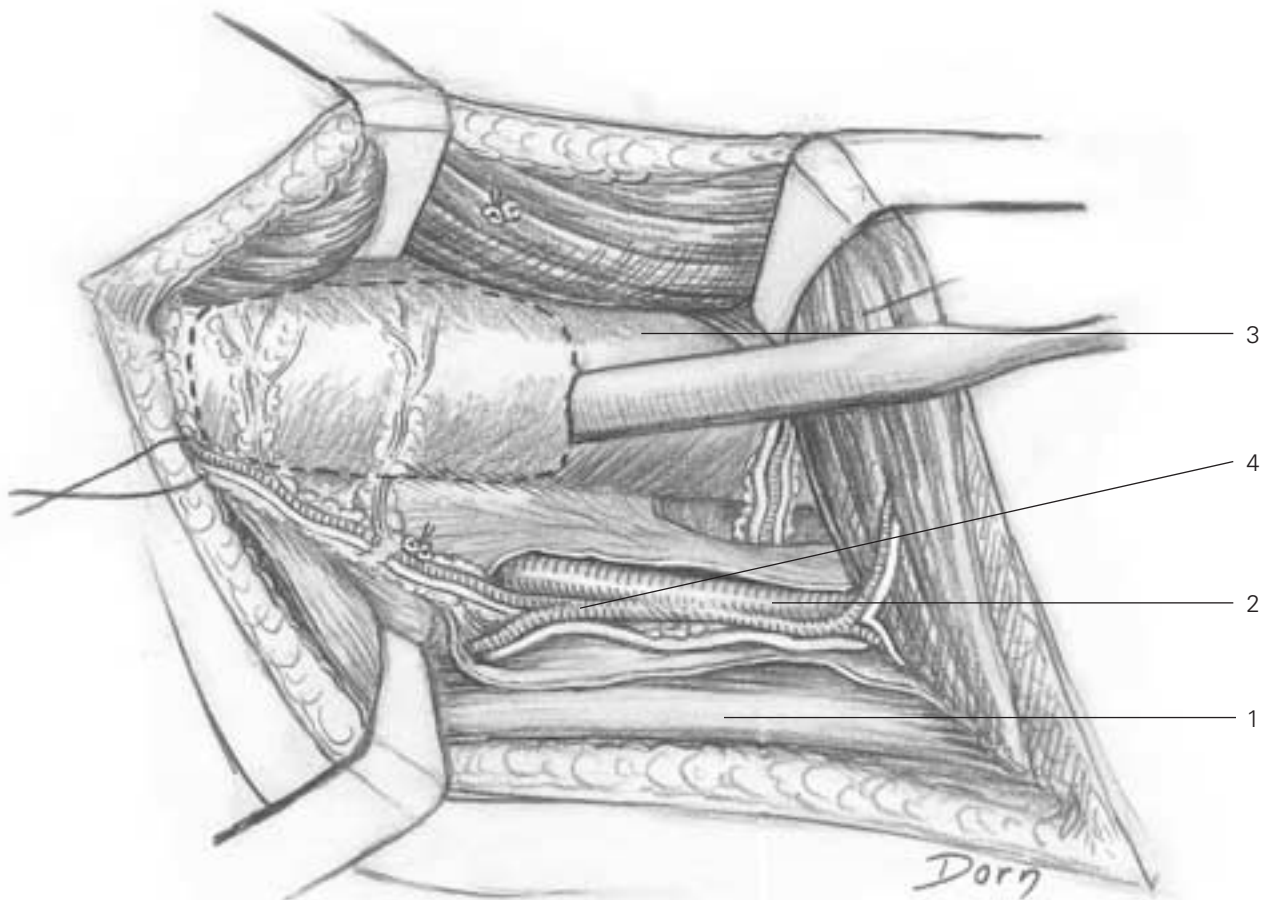
## Vascularised bone transfers

Vascularised bone transfers have dramatically improved the treatment of bone defects. Healing occurs quickly avoiding the state of 'creeping substitution' specific to the revascularisation of conventional bone grafts.

Vascularised osteoperiosteal flap from the femur

This transfer is chiefly indicated in craniofacial surgery. It can also be used as a pedicled island flap to promote bone healing in a recalcitrant non-union of the femur.

The flap is detached from the medial aspect of the distal metaphysis of the femur. It is supplied by the descending genicular artery that issues from the lower femoral artery.

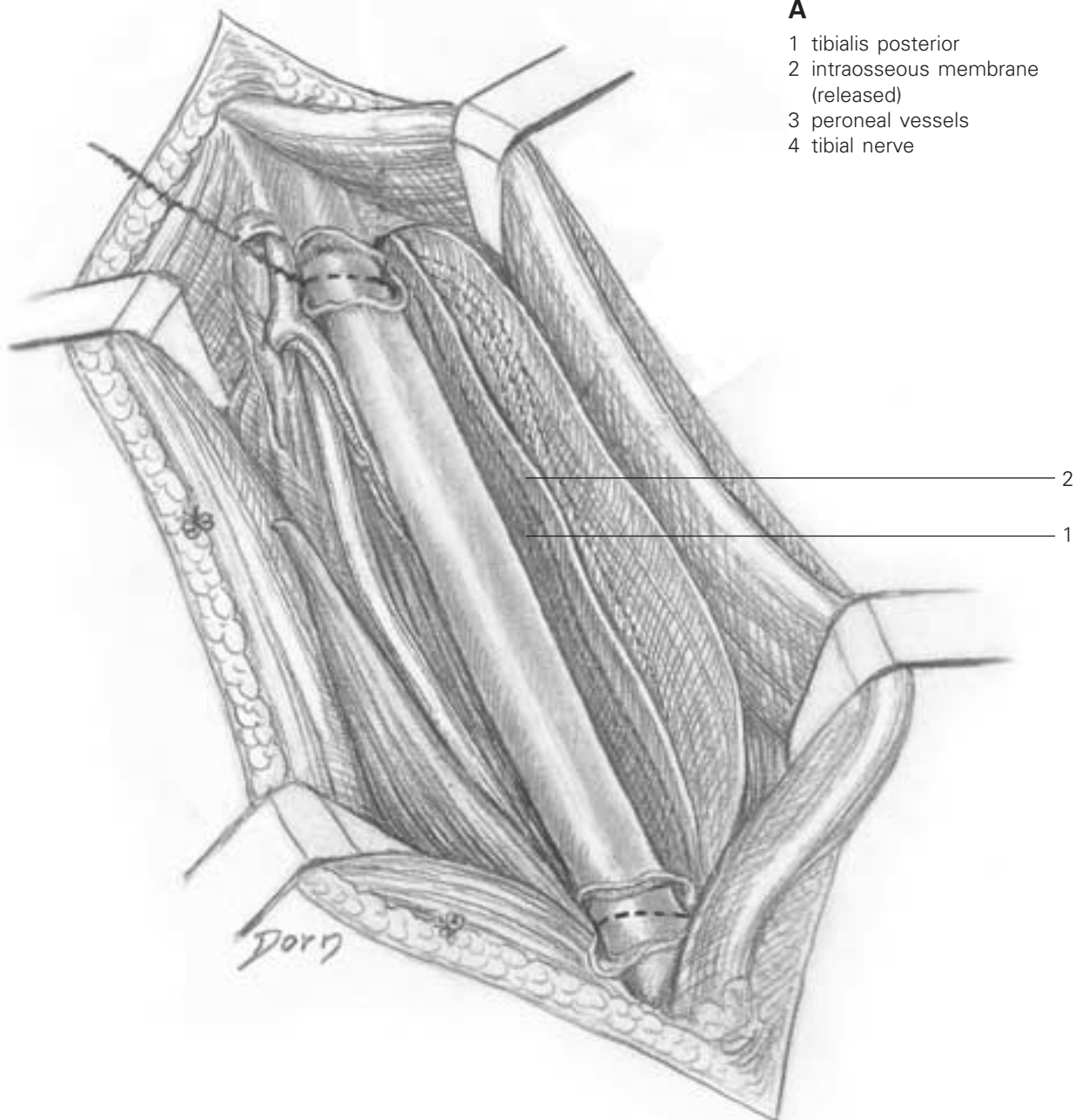


- 1 adductor magnus tendon
- 2 lower femoral artery
- 3 femur
- 4 descending genicular artery

## Vascularised fibula transfer

The vascularised fibula is now of much interest in reconstructive surgery of long bone defects.

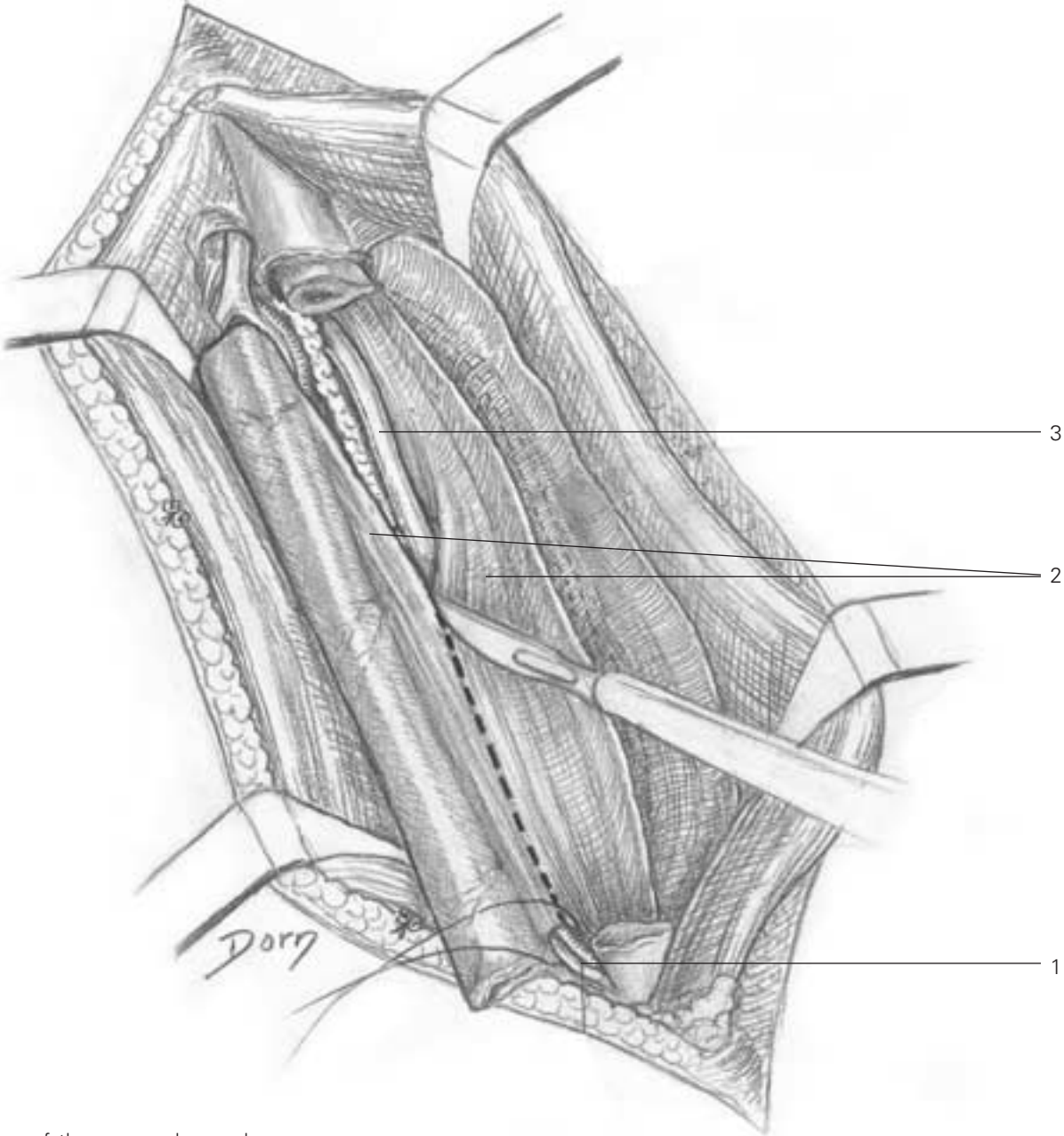
**A** The fibula has been isolated with the peroneal vessels remaining protected by a portion of the tibialis posterior or the flexor hallucis longus muscles. The transfer is severed at both extremities, sparing a cuff of periosteum.





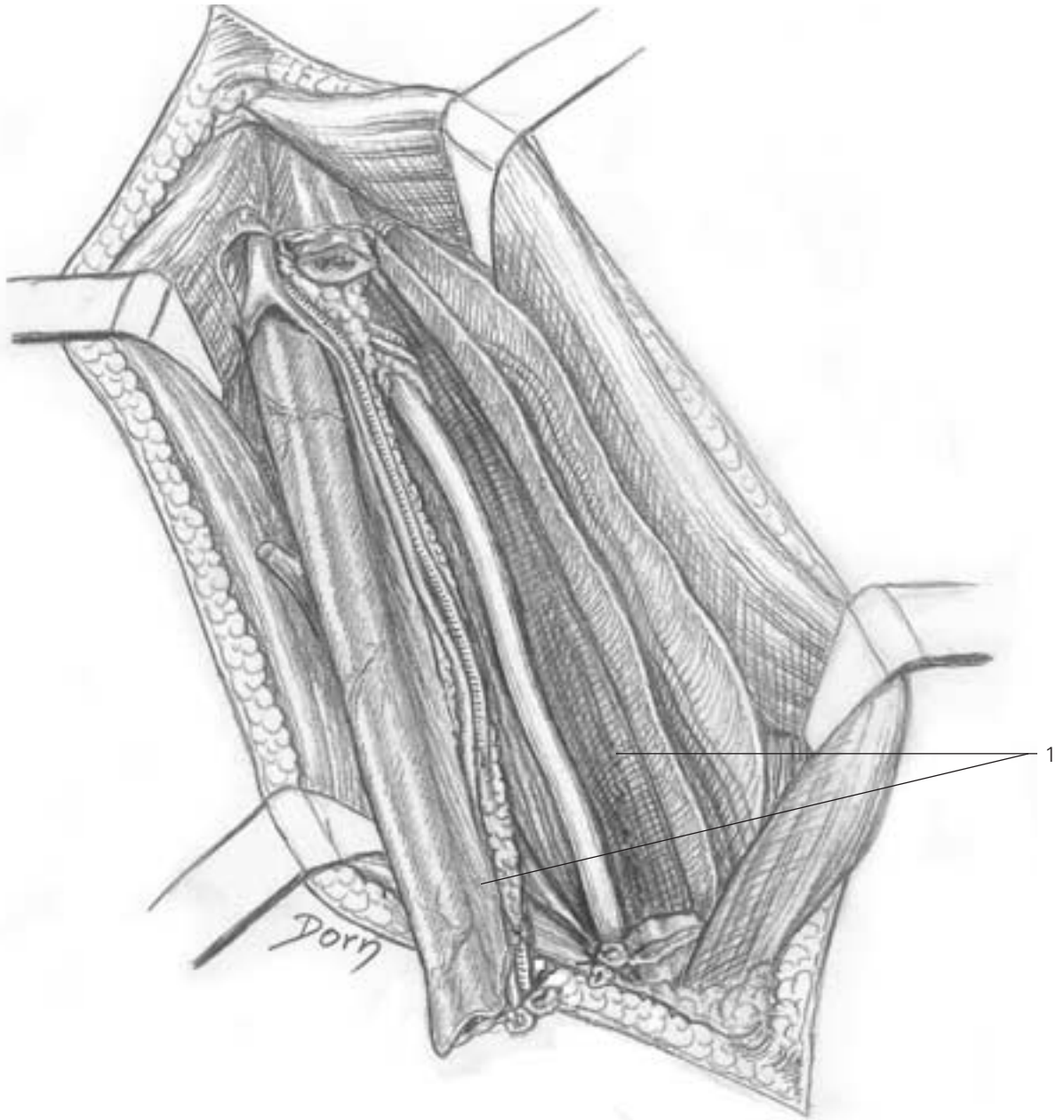
# Reconstructive surgery

**B** A portion of tibialis posterior muscle remains attached to the fibula to protect the peroneal vessels which supply the bone.



- B**
- 1 distal ligation of the peroneal vessels
- 2 tibialis posterior (split)
- 3 tibial nerve

C The transfer is completely isolated on its pedicle.



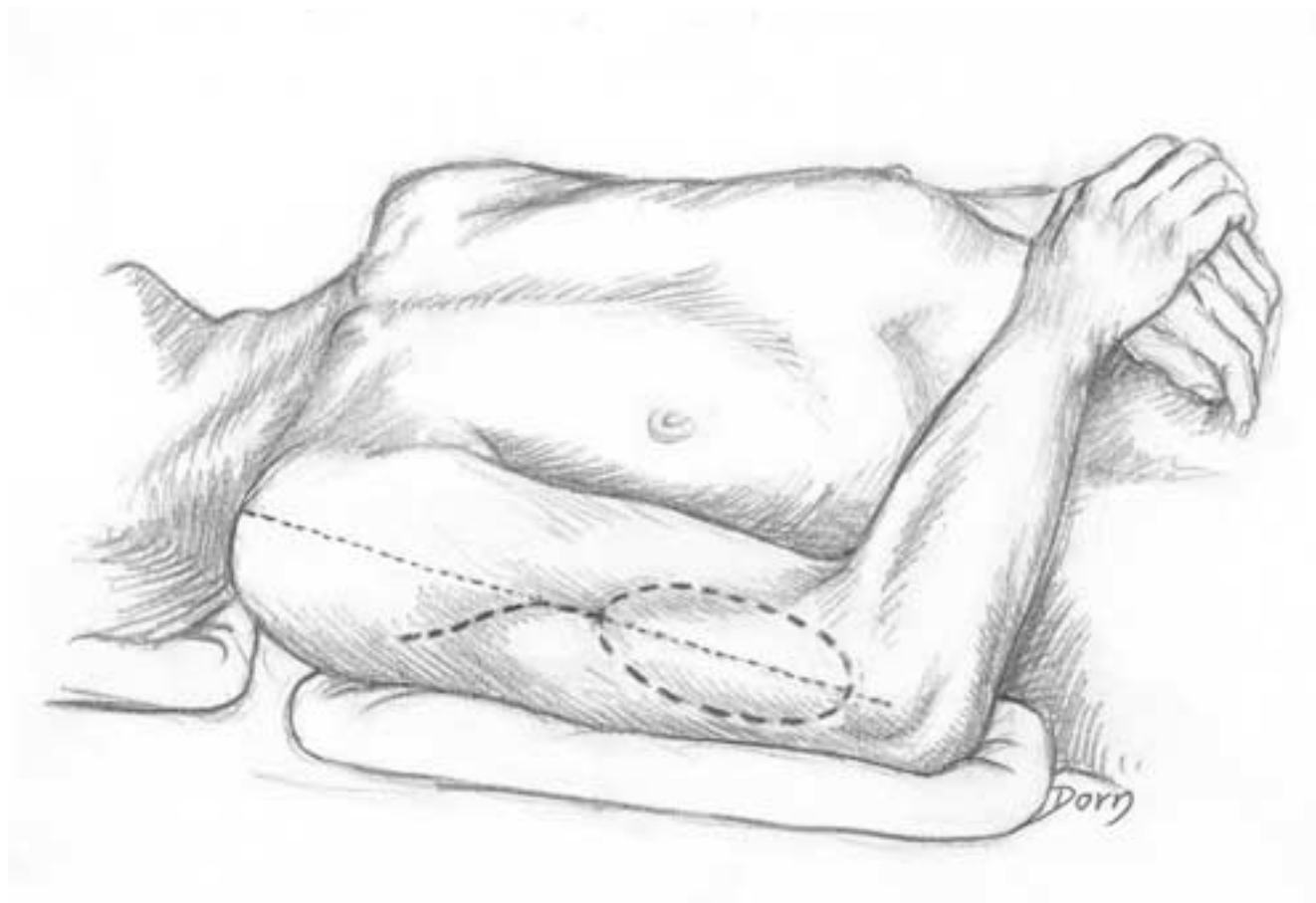
**C**  
1 tibialis posterior (split)

## Flaps from the upper limb

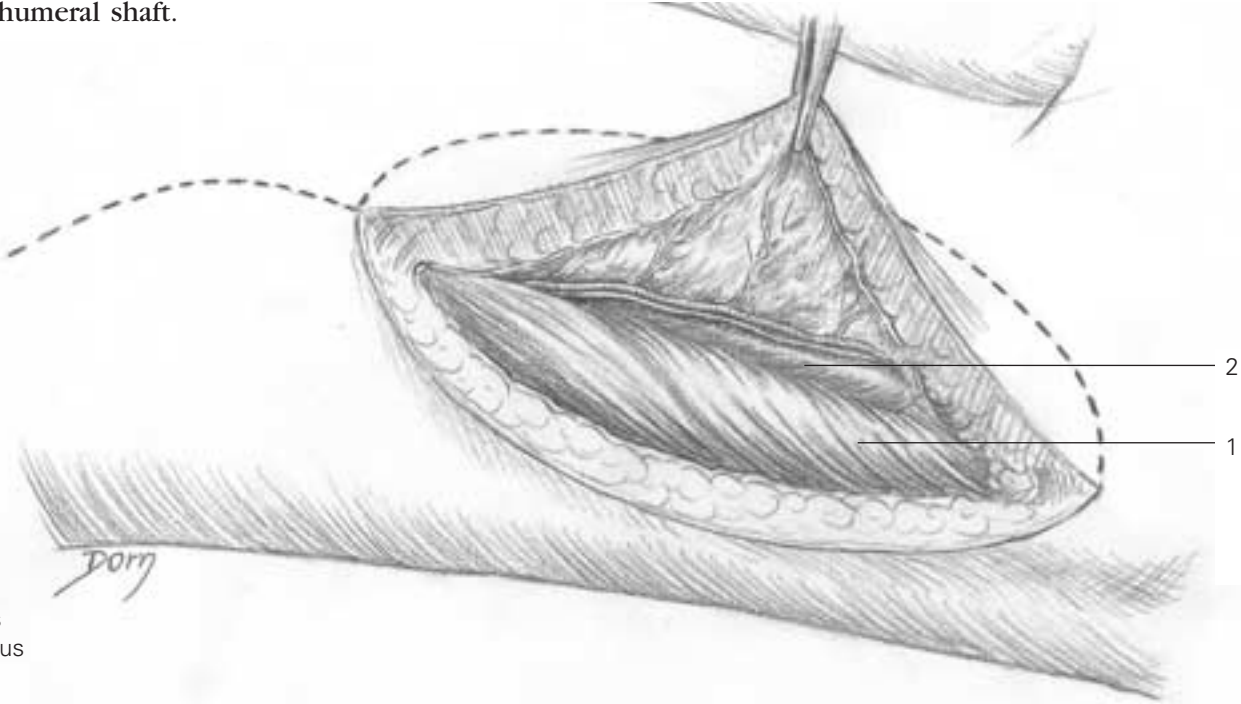
### Lateral brachial flap

The lateral brachial flap is raised on the lateral aspect of the arm and is available as a pedicled flap or a free flap. It can be combined with a piece of bone from the humerus.

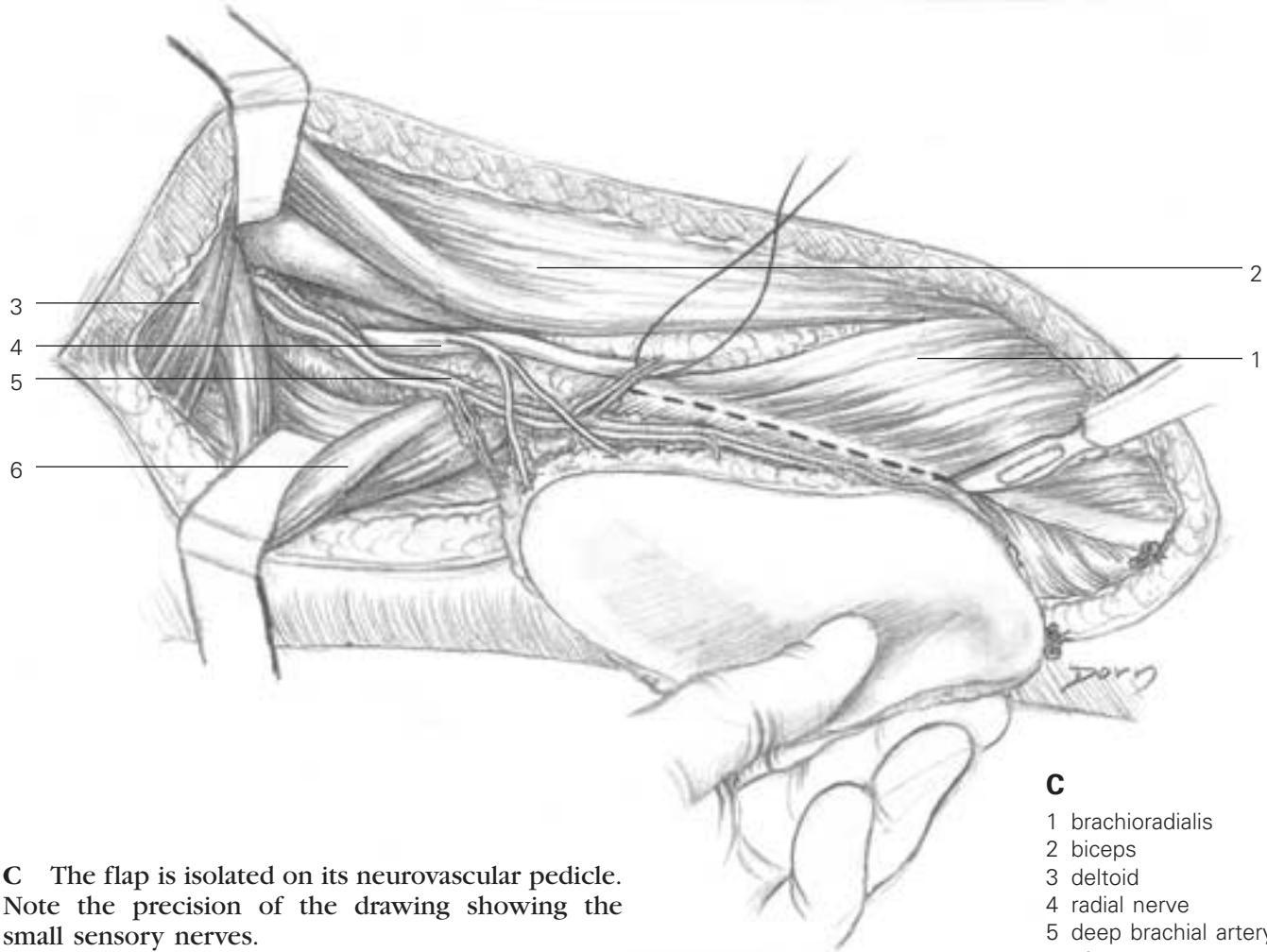
**A** Incision - the blood supply comes from the posterior branch of the brachial artery.



**B** The vessels are seen within the septum inserted on the humeral shaft.



**B**  
1 triceps  
2 humerus



**C** The flap is isolated on its neurovascular pedicle. Note the precision of the drawing showing the small sensory nerves.

**C**  
1 brachioradialis  
2 biceps  
3 deltoid  
4 radial nerve  
5 deep brachial artery  
6 triceps

# Reconstructive surgery

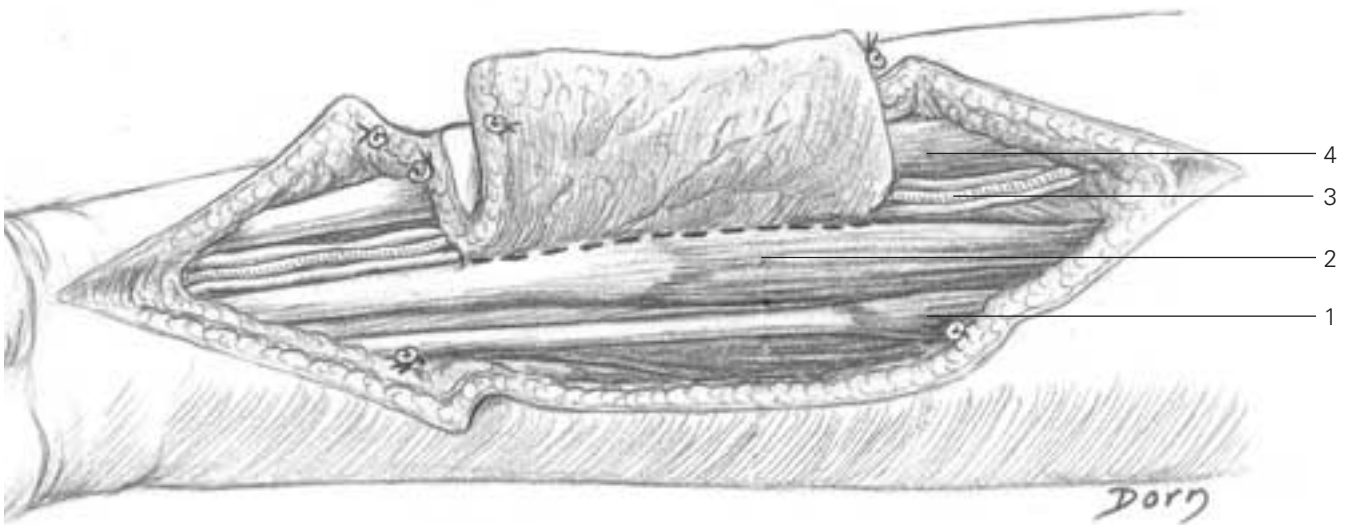
## Forearm radial flap

This flap was the origin of a true revolution in 1980. Described by Chinese authors it is supplied by the radial artery and started the era of distally based pedicled island flaps, with retrograde blood flow, which were initially considered difficult to achieve.

**A, B** The flap is raised progressively on its vascular axis which is maintained in continuity during the first step of the dissection.

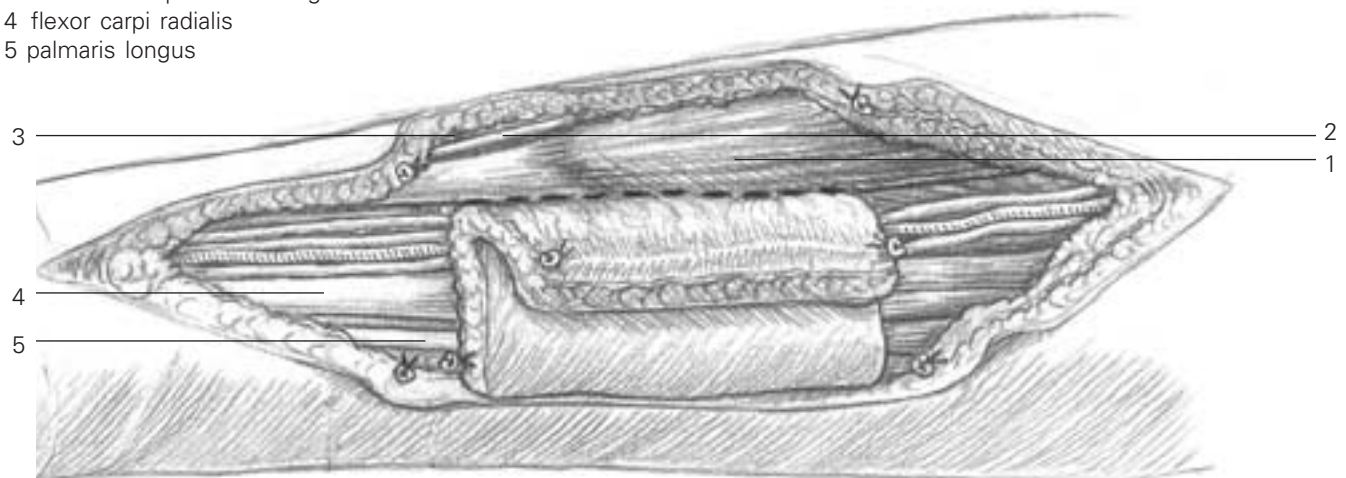
**A**

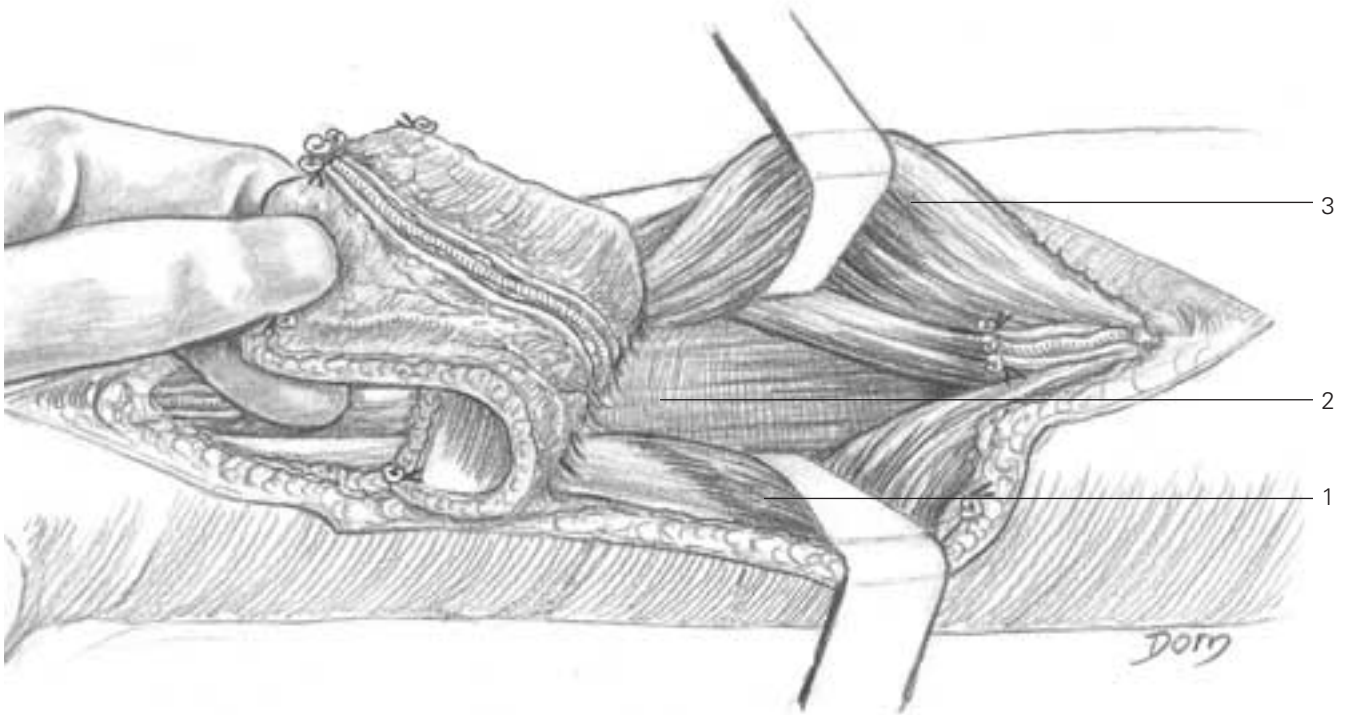
- 1 palmaris longus
- 2 flexor carpi radialis
- 3 radial artery
- 4 brachioradialis



**B**

- 1 brachioradialis
- 2 radial nerve (sensitive branch)
- 3 extensor carpi radialis longus
- 4 flexor carpi radialis
- 5 palmaris longus





**C** The radial artery has been severed proximal to the flap. The pivot point of the pedicle is at the level of the wrist. The flap is convenient for covering any defect of the hand.

- C**
- 1 flexor carpi radialis
  - 2 flexor digitorum superficialis
  - 3 brachioradialis

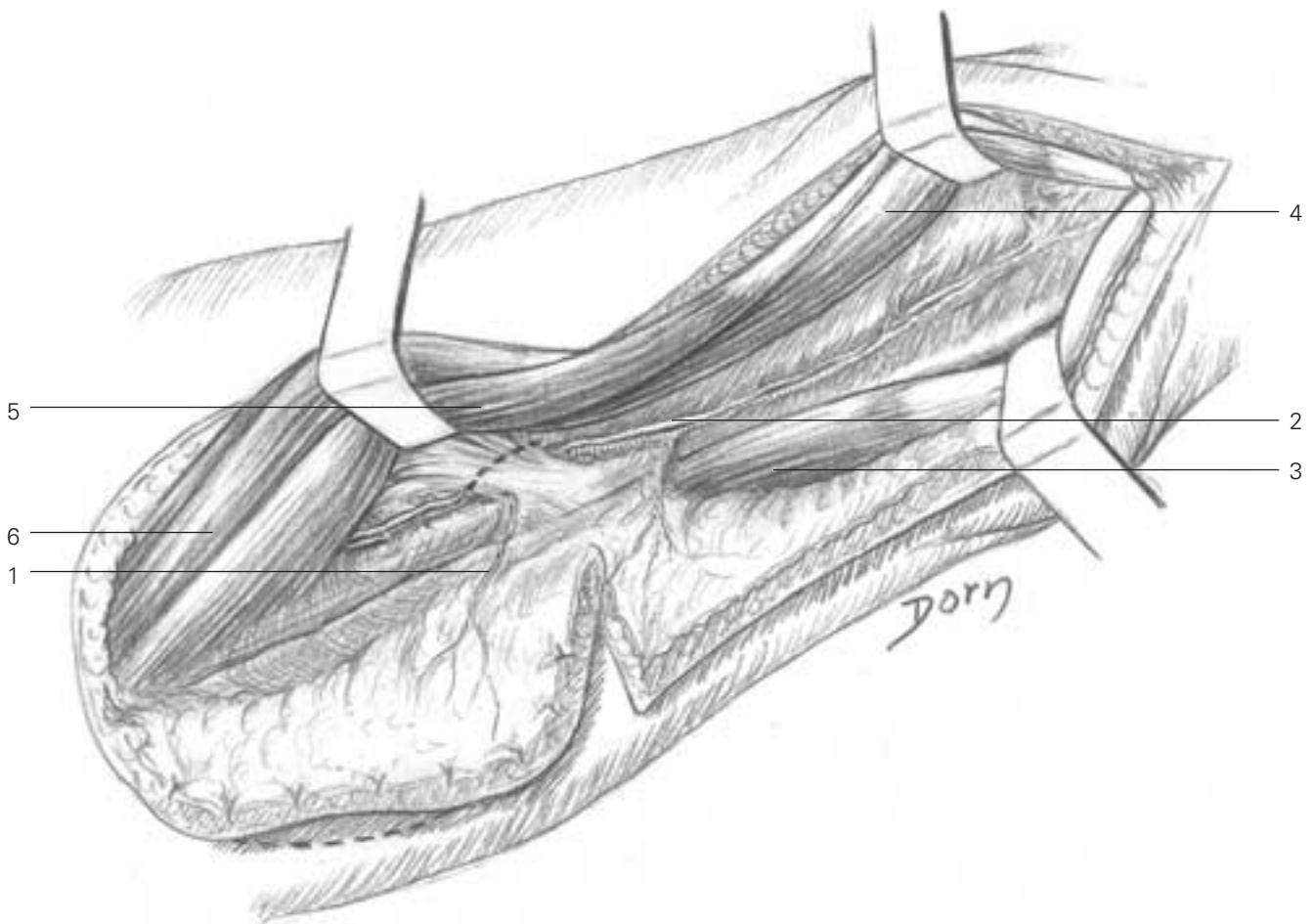
# Reconstructive surgery

---

## Posterior interosseous flap

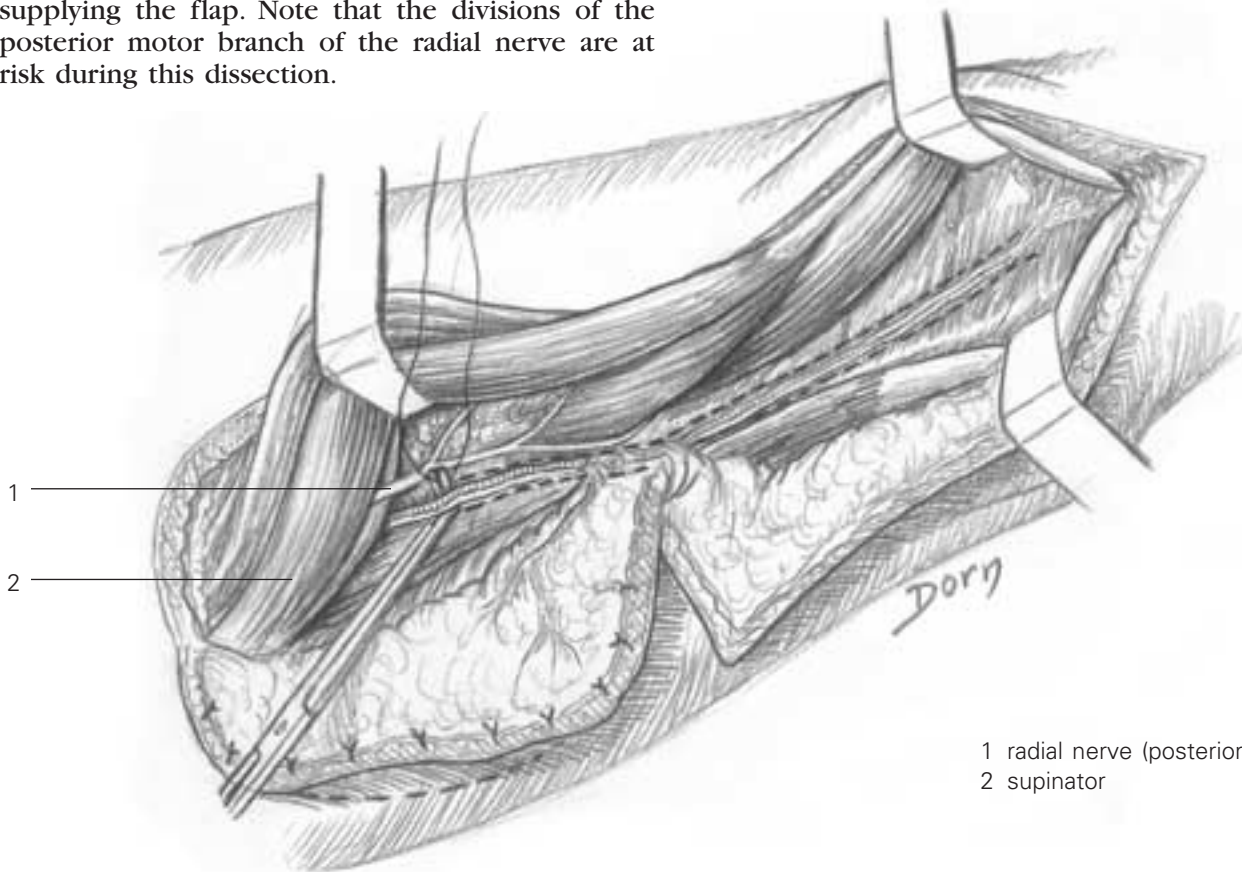
The flap is raised on the posterior aspect of the forearm. The advantage of this flap is the absence of sacrifice of a main vascular axis, since it is supplied by a small artery called the posterior interosseous artery. The technique is not easy and it is difficult to represent by drawings because of the different planes of perspective in depth.

**A** The flap is partially raised; a posterior hinge is maintained while exploring the vessels.



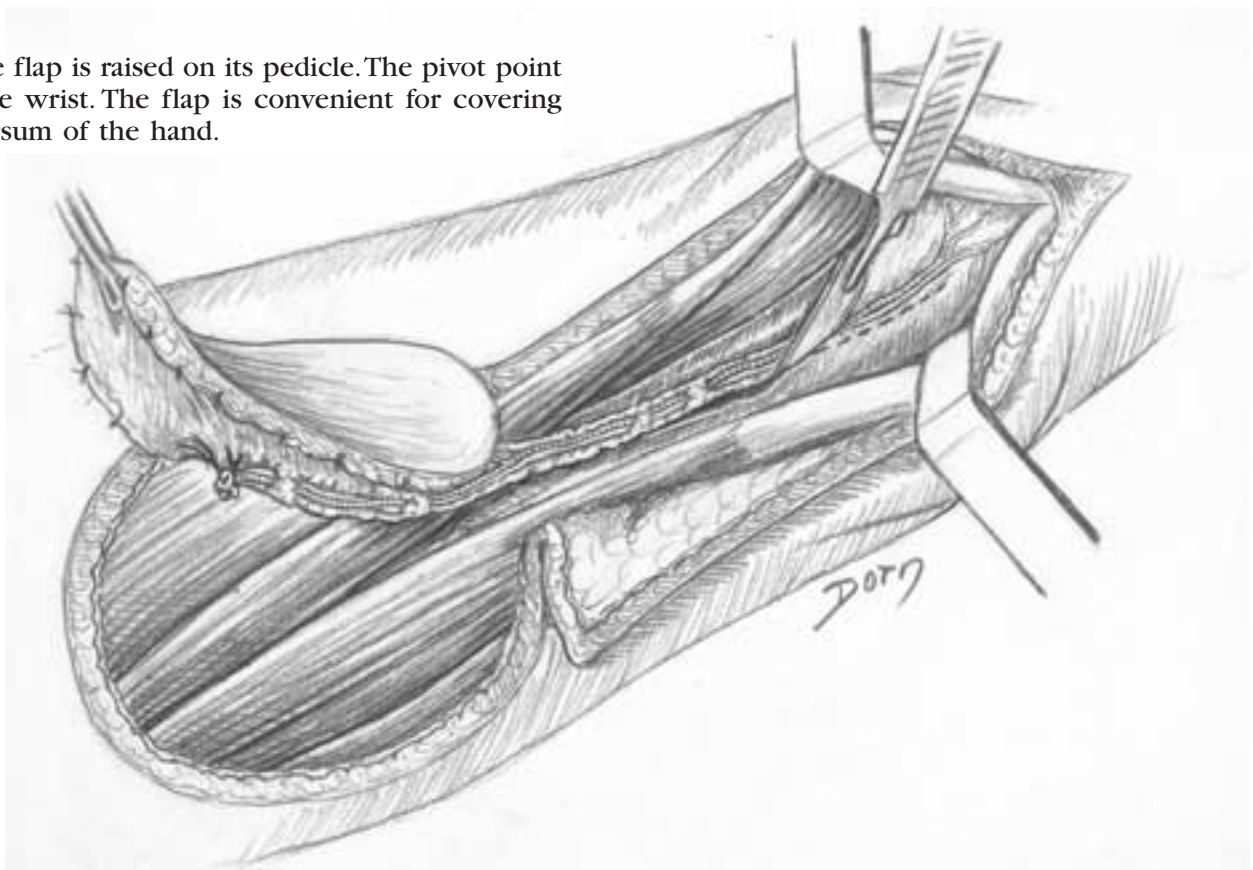
- 1 arterial branch to the flap
- 2 posterior interosseous artery
- 3 extensor carpi ulnaris
- 4 extensor indicis proprius
- 5 extensor digiti quinti
- 6 extensor digitorum

**B** The artery is severed proximal to the branch supplying the flap. Note that the divisions of the posterior motor branch of the radial nerve are at risk during this dissection.



- 1 radial nerve (posterior branch)
- 2 supinator

**C** The flap is raised on its pedicle. The pivot point is at the wrist. The flap is convenient for covering the dorsum of the hand.



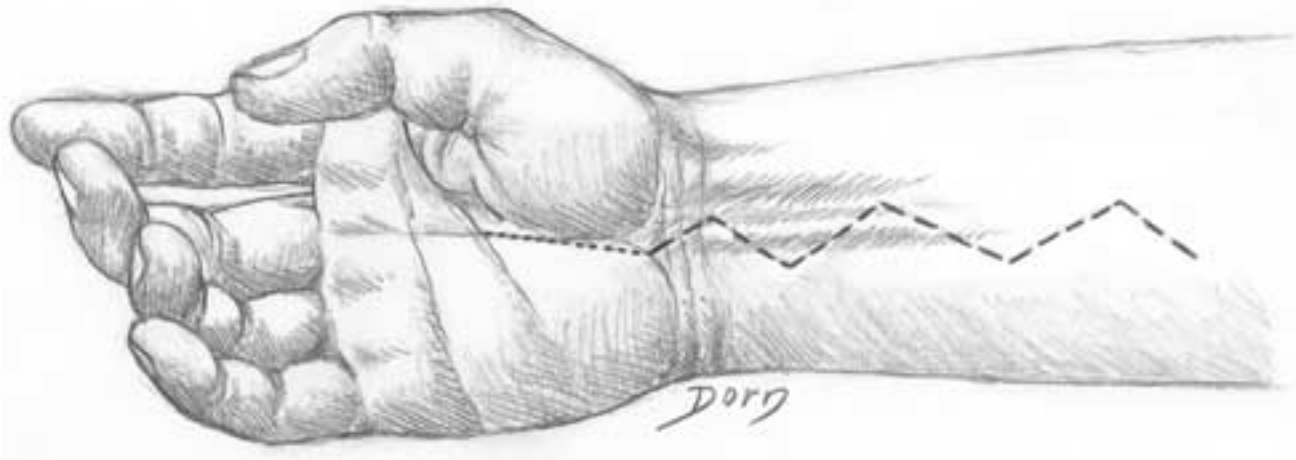


# Reconstructive surgery

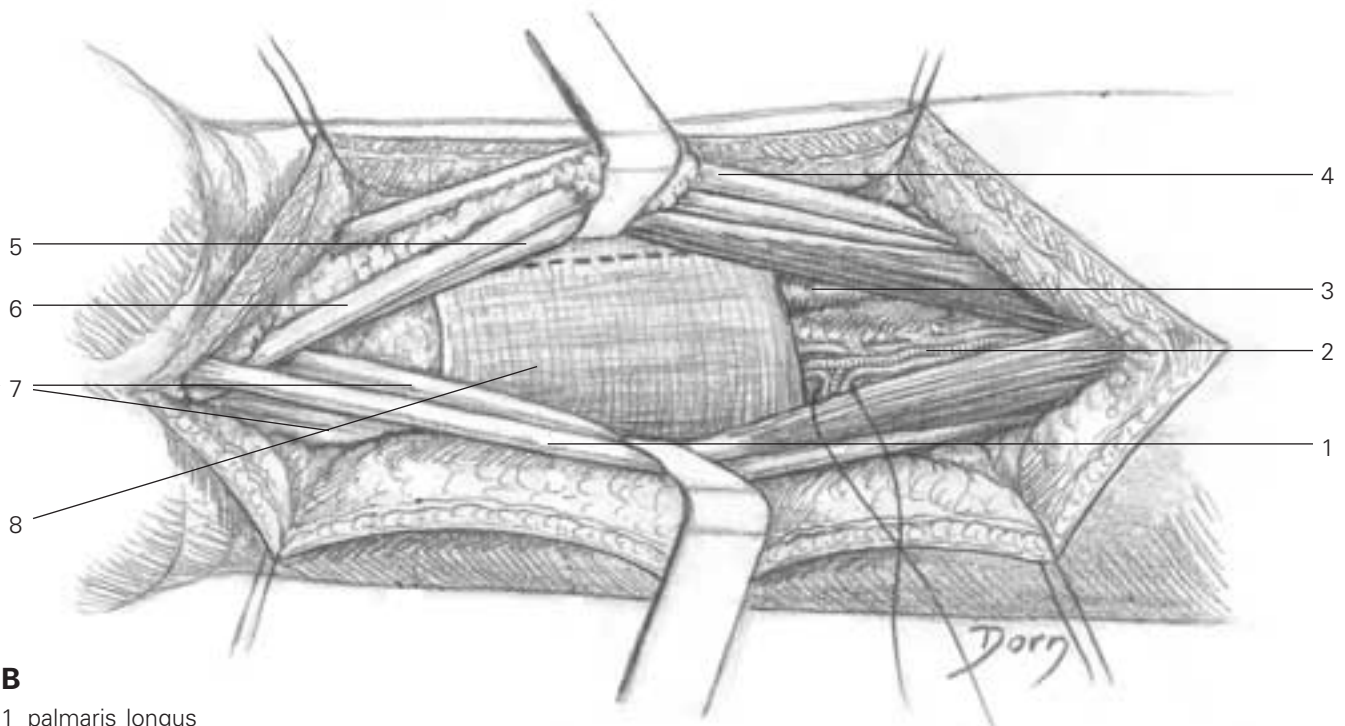
## Pronator quadratus muscle flap

This flap is rarely used. However, the dissection is very fine and so are the drawings.

### A Skin incision.

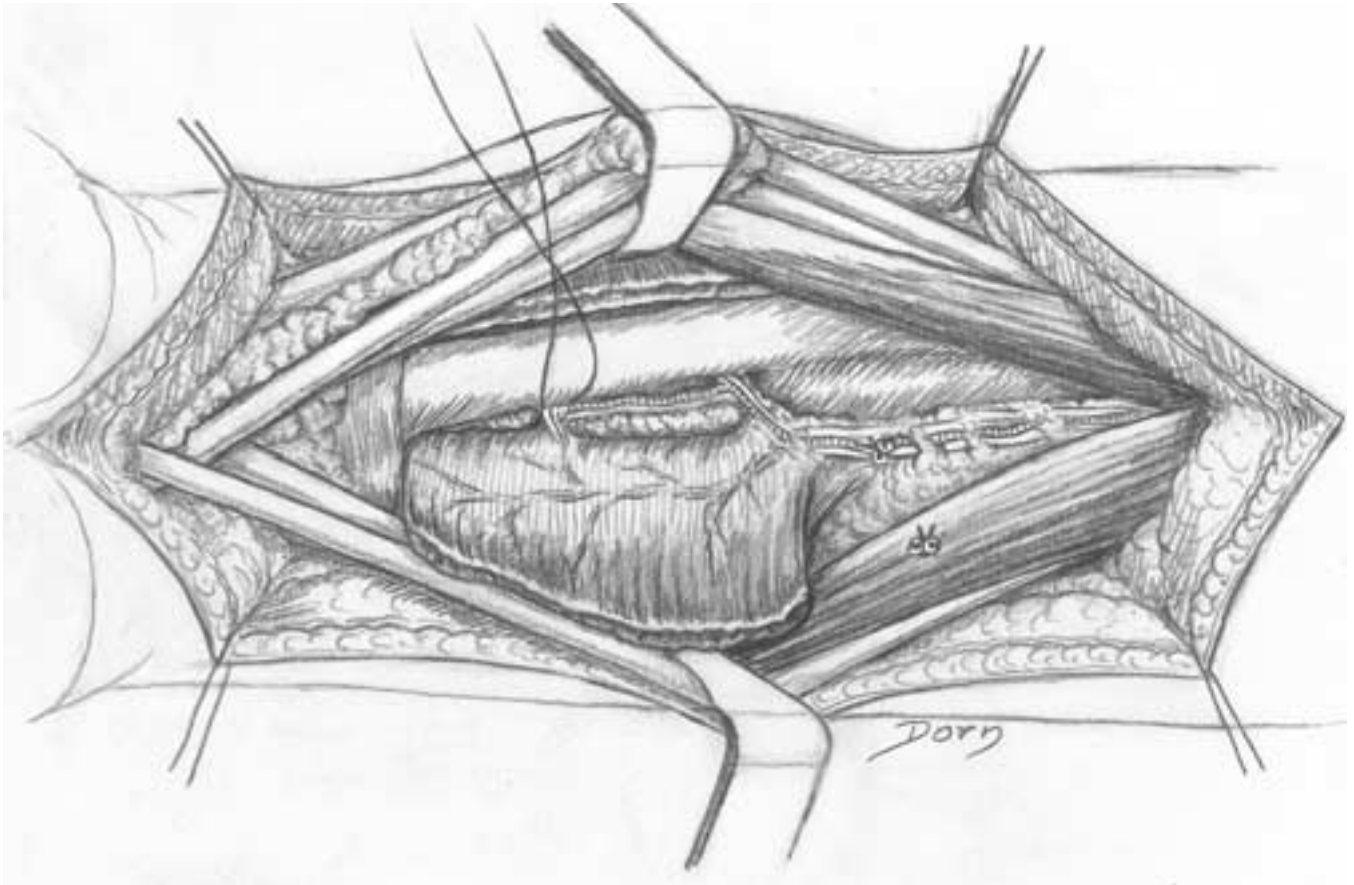


### B Exposure of the pronator quadratus muscle.



- B**
- 1 palmaris longus
  - 2 anterior interosseous vessels
  - 3 radius
  - 4 flexor carpi radialis
  - 5 flexor hallucis longus
  - 6 median nerve
  - 7 flexor digitorum superficialis
  - 8 pronator quadratus

C The flap is raised on the anterior interosseous artery.





# Hand and peripheral nerve surgery

The hand is probably a field of predilection for Léon Dorn. He has worked very hard as the hand is not easy to depict. Dorn was the renowned collaborator of Raoul Tubiana for the monumental book *Chirurgie de la Main*.

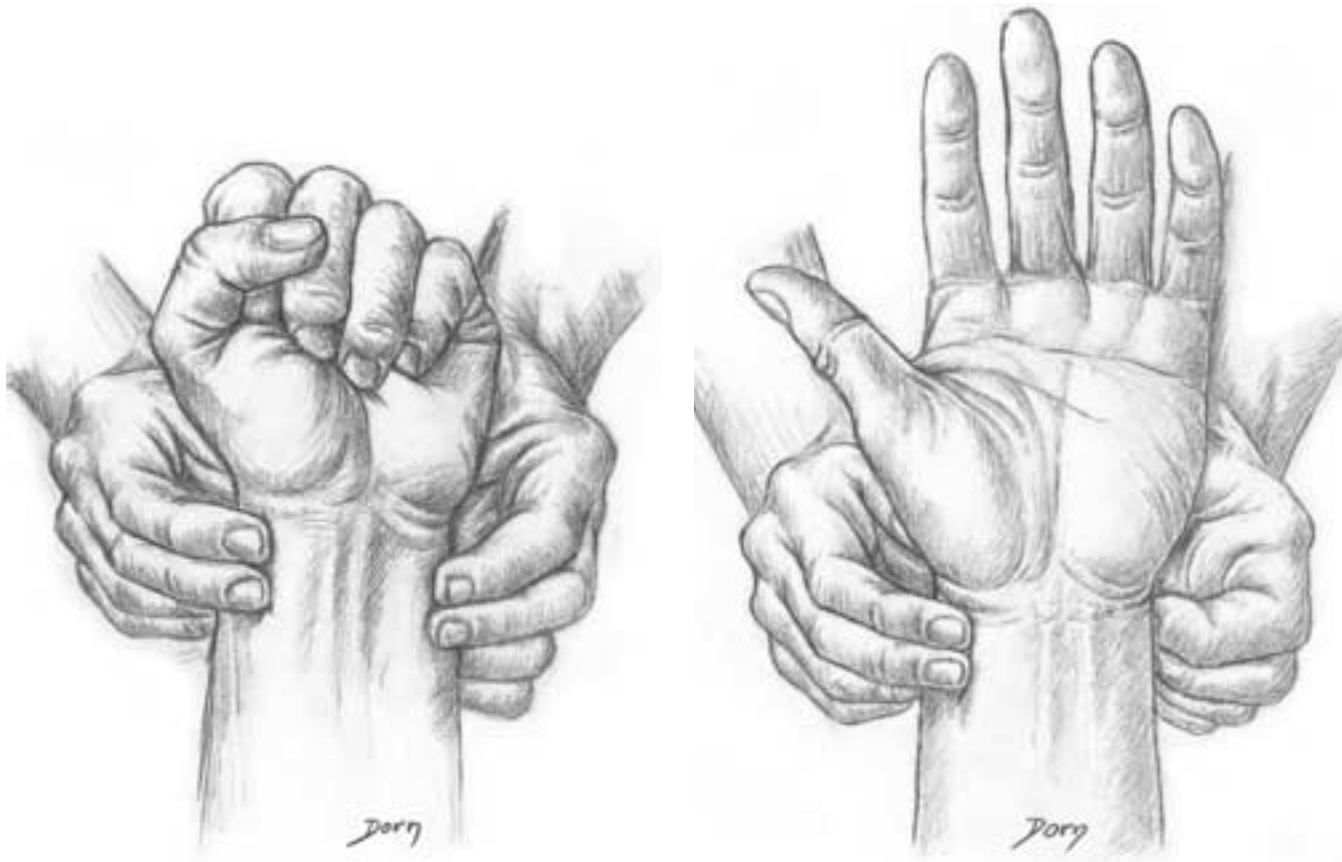
Among Dorn's vast production of illustrations of the hand can be seen some which truly demonstrate the true skill of the artist.

# Hand and peripheral nerve surgery

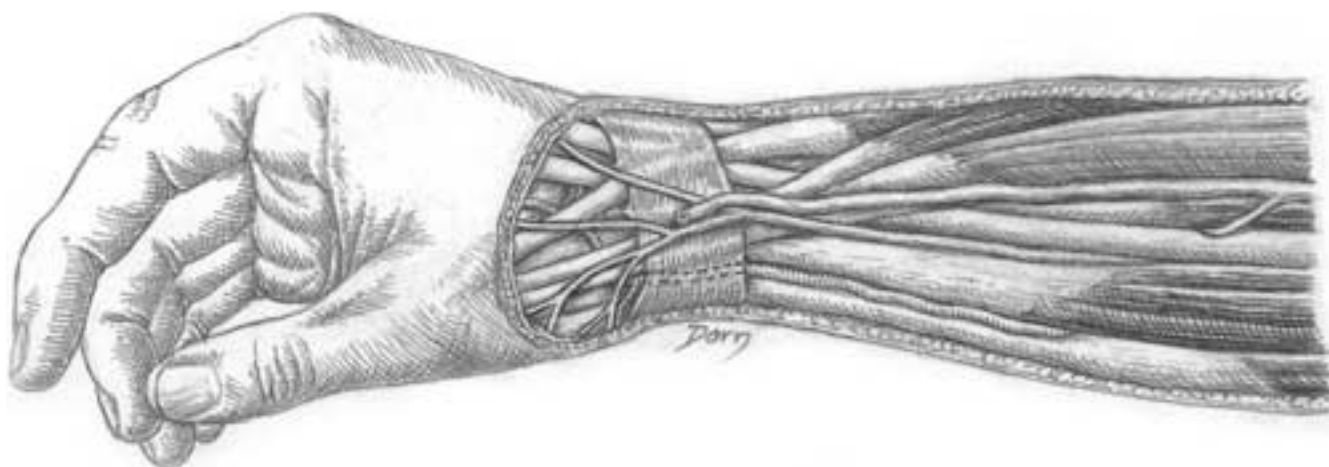
---

## Anatomy of the hand

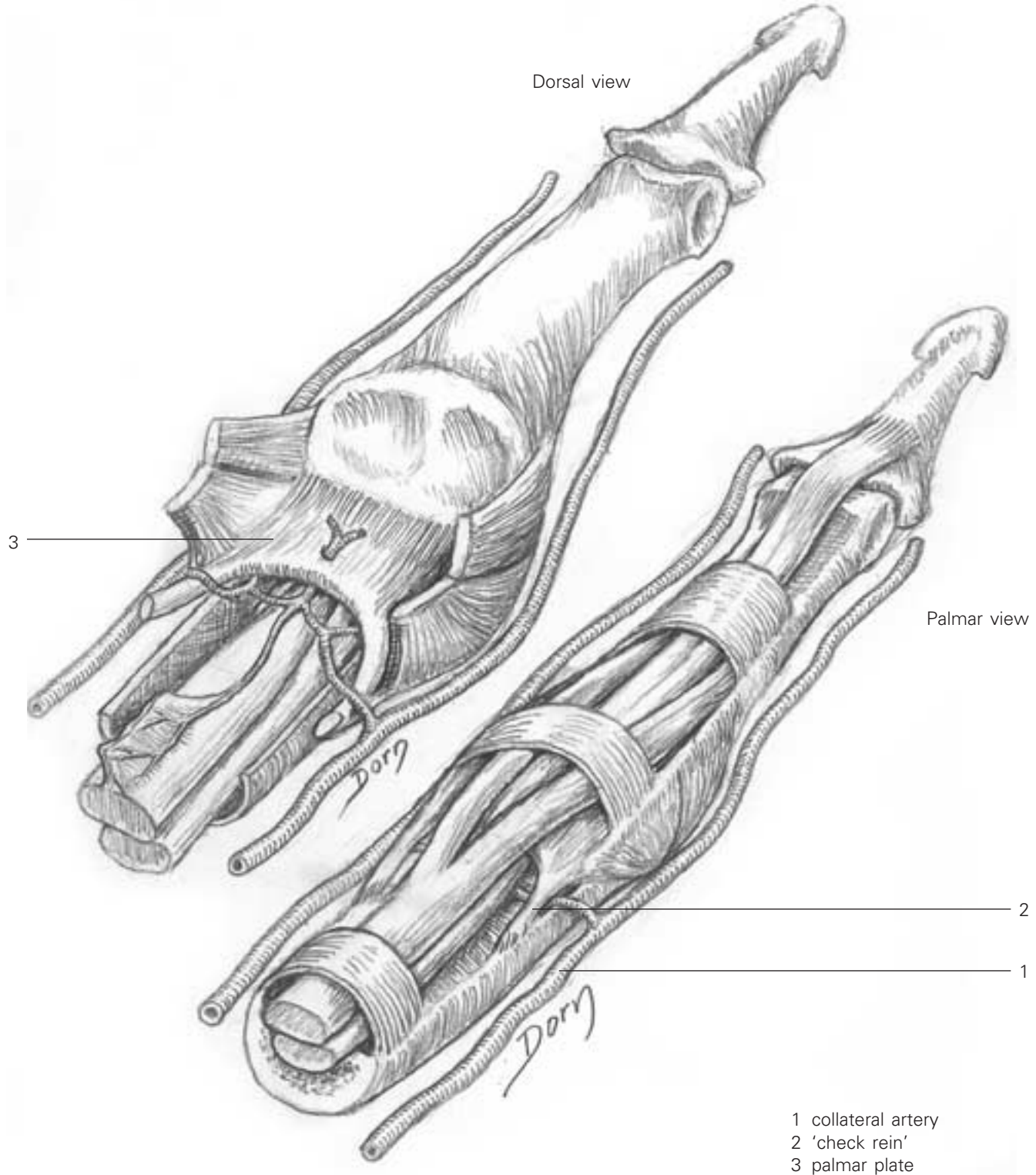
**A** Allen's test - the principle is to assess the permeability (patency test) of each artery of the hand.



**B** The radial aspect of the wrist and forearm. Note the divisions of the sensory branch of the radial nerve.



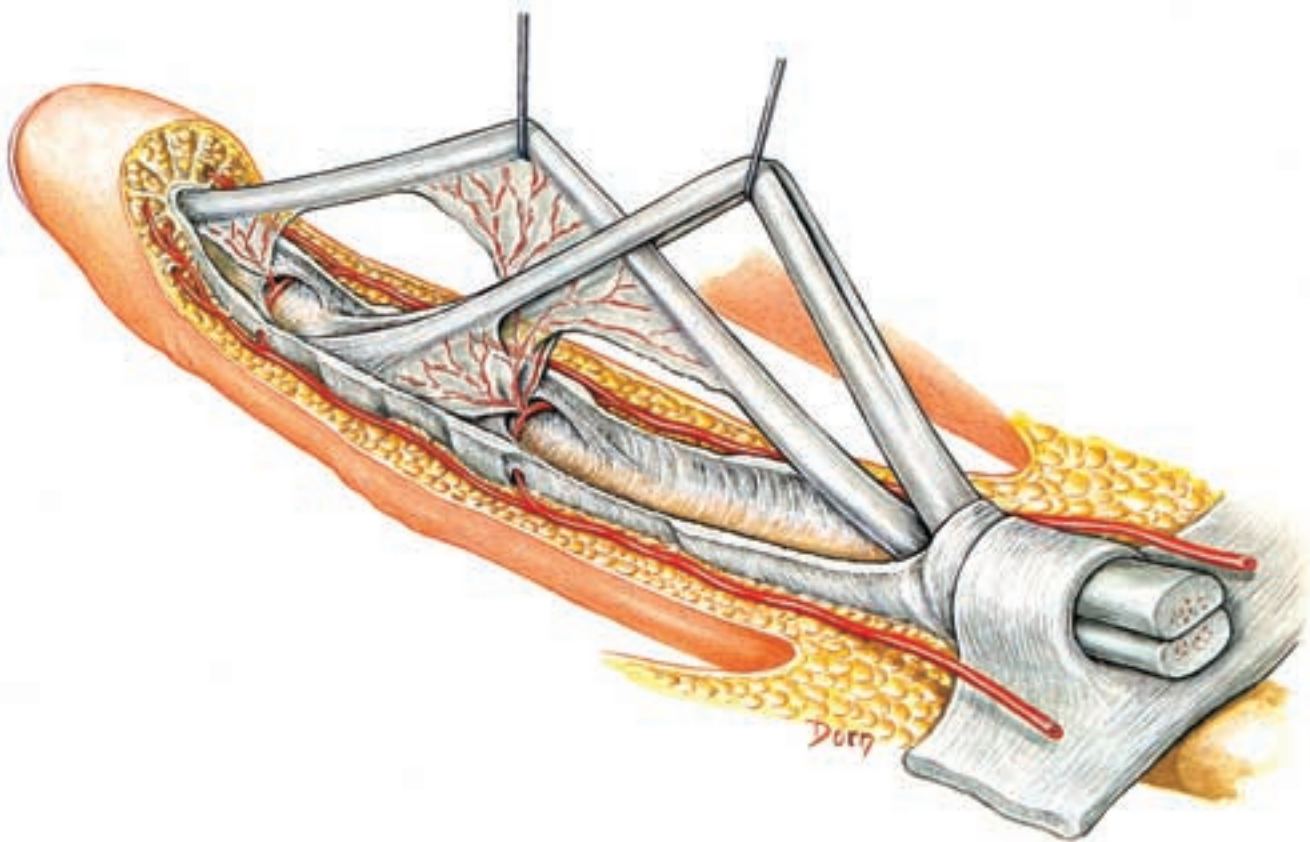
C Blood supply to the flexor tendons of the fingers. Note the small pedicles issuing from the collateral artery. They pass beneath the 'check reins' of the capsule of the PIP joint and divide into several branches. One branch is devoted to the vinculum.



# Hand and peripheral nerve surgery

---

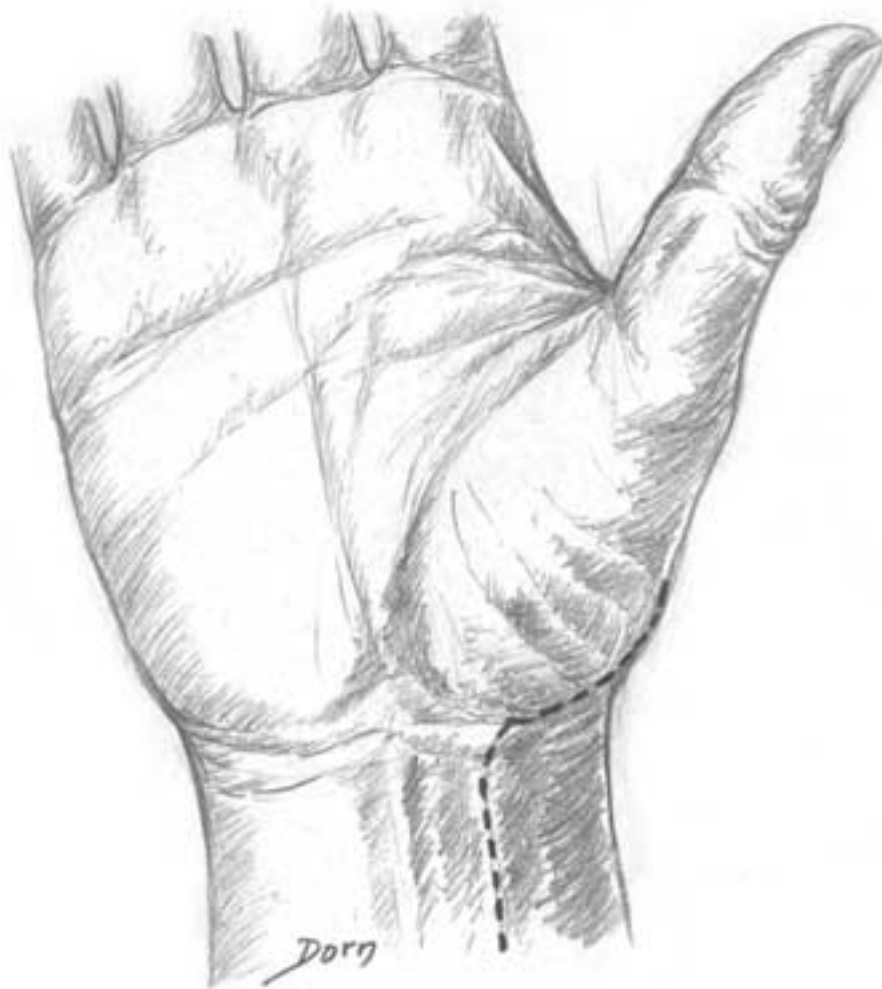**D** The blood supply to the profundus tendon comes from the vinculum of the superficialis tendon. Hence the superficialis tendon should not be excised when both tendons are divided; rather both tendons should be repaired.



## The trapezium: volar approach

The indications of this procedure are trapeziectomy (for osteoarthritis) and internal fixation of intra-articular fractures.

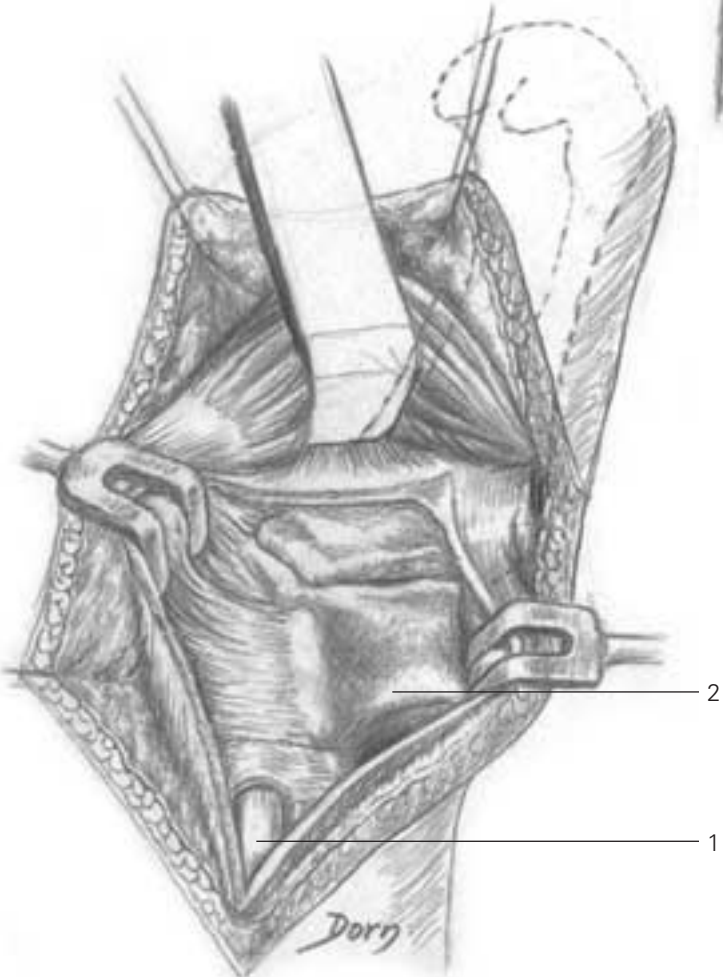
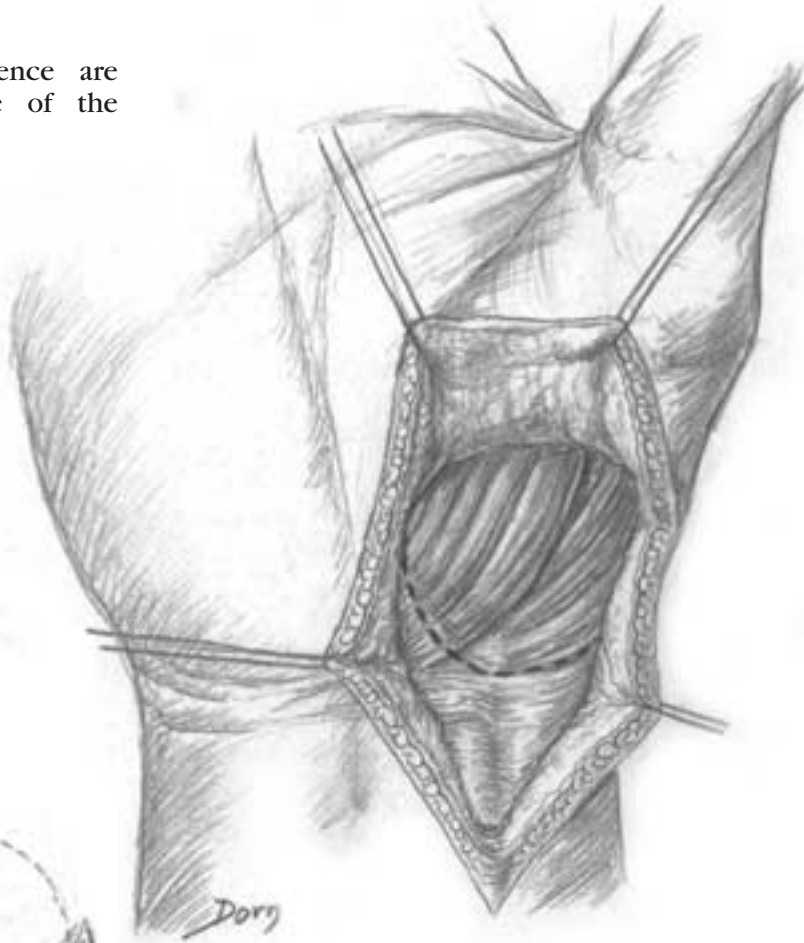
### A Skin incision.





# Hand and peripheral nerve surgery

**B** The muscles of the thenar eminence are reflected from the underlying capsule of the trapeziometacarpal joint.

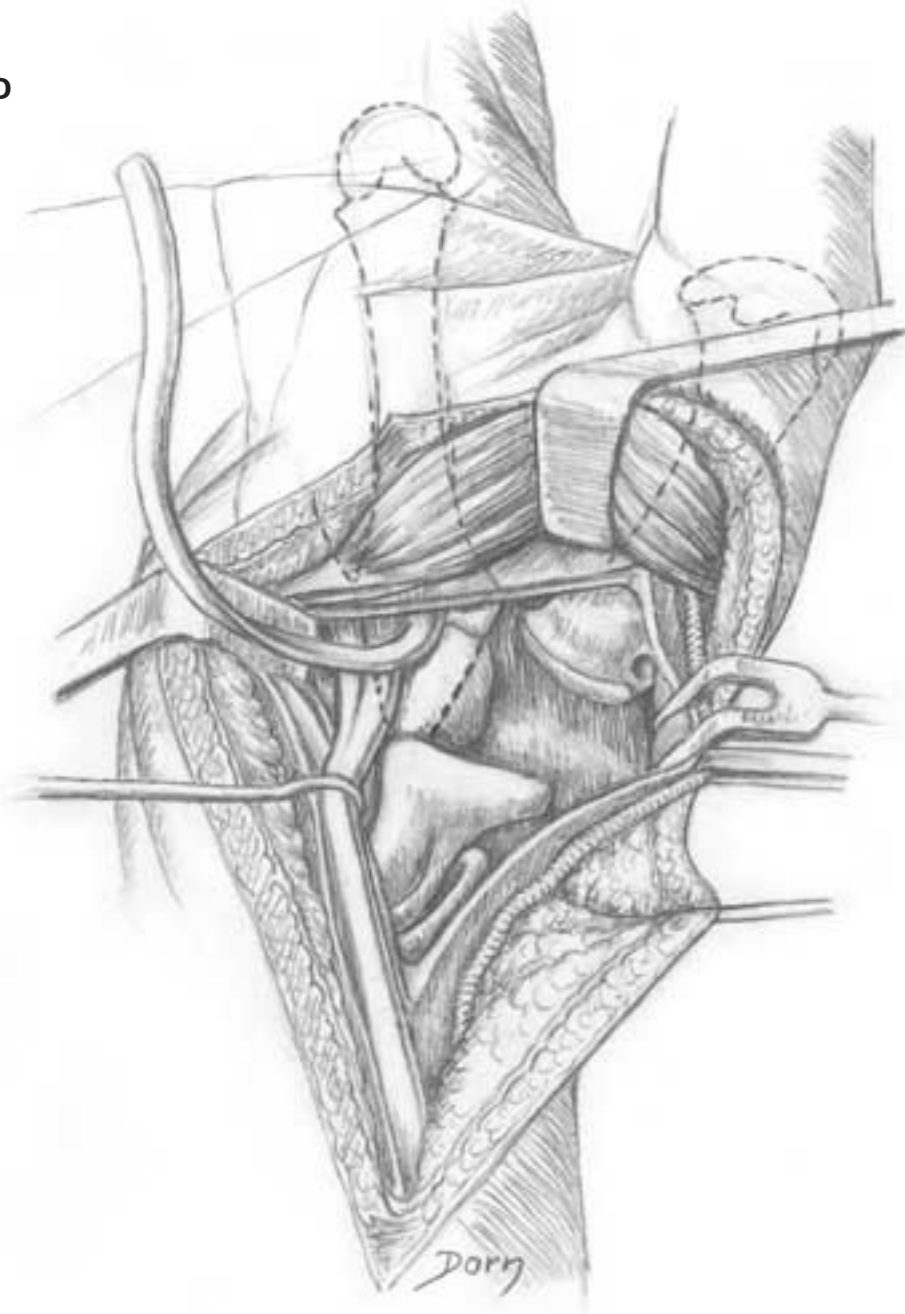


**C** The capsule is incised, giving access to the trapezium and the base of the first metacarpal.

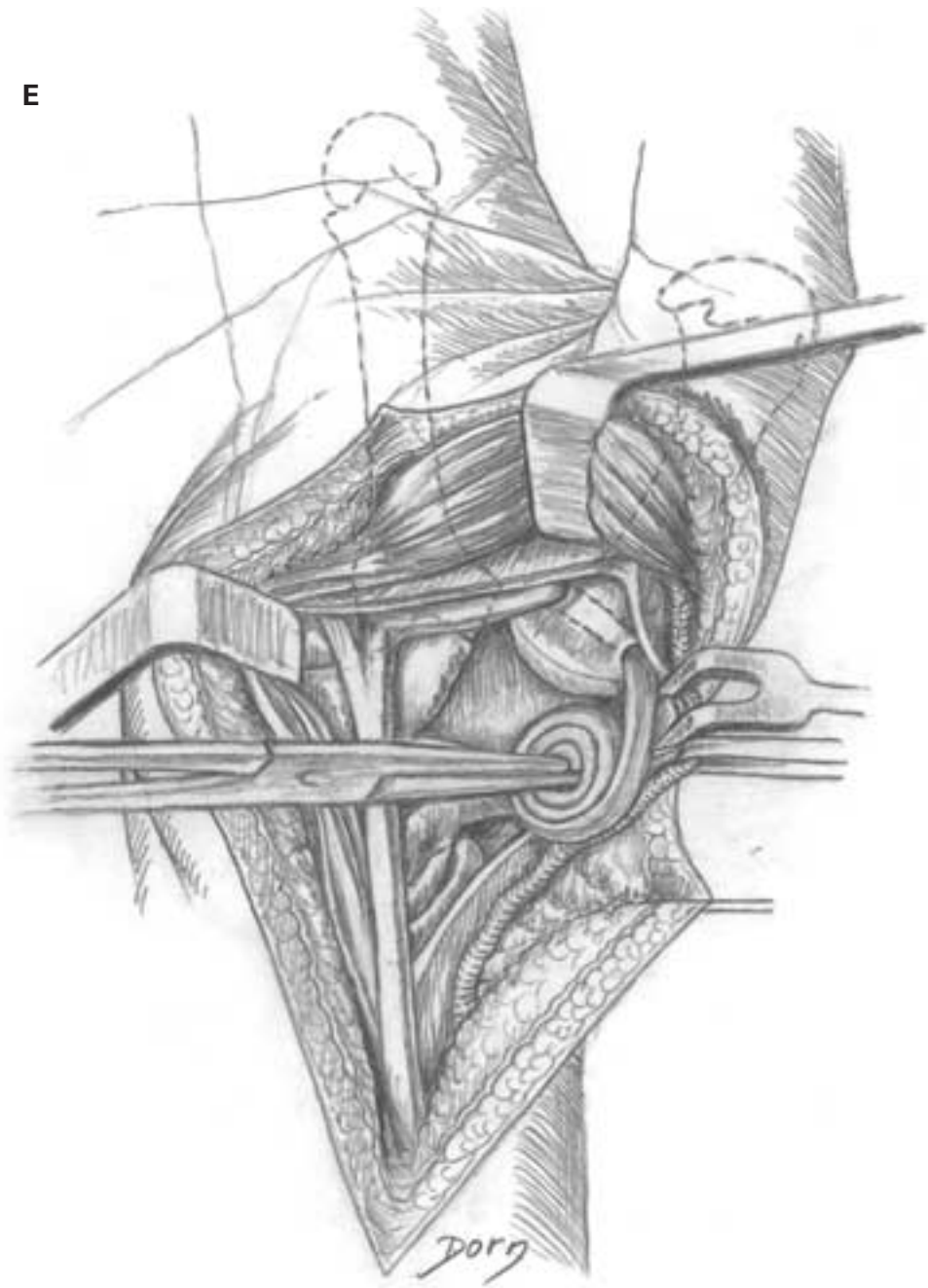
- 1 flexor carpi radialis
- 2 trapezium

**D, E** The trapezium has been removed. A band of tendon from the flexor carpi radialis is prepared to stabilise the first metacarpal bone and to fill the cavity.

**D**



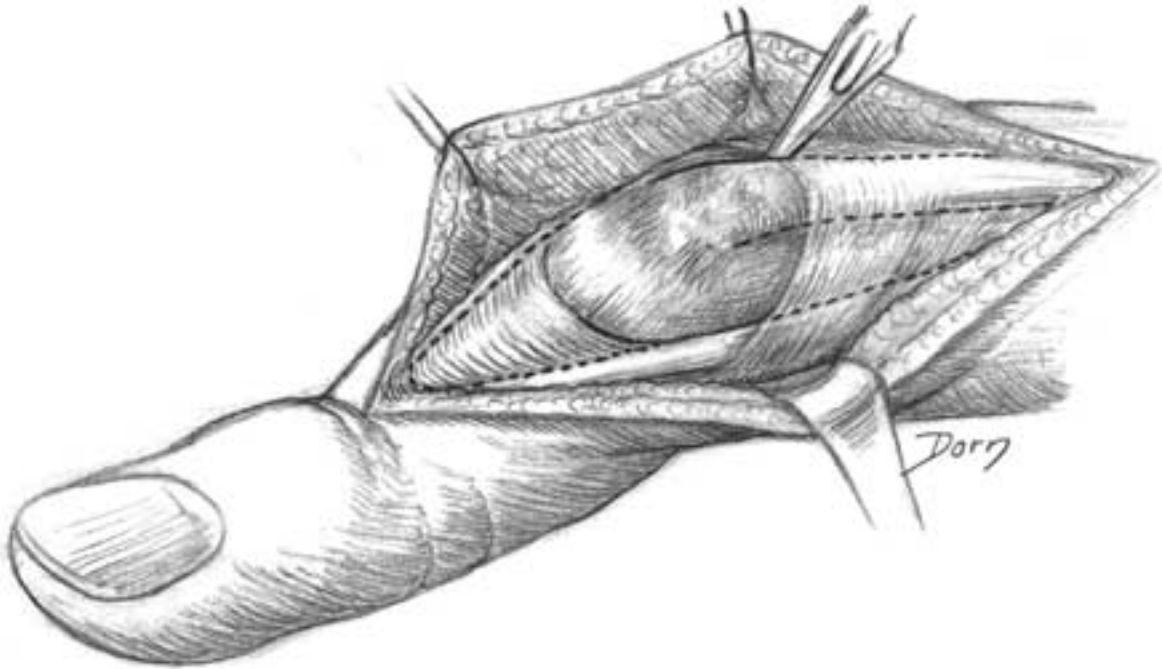
E



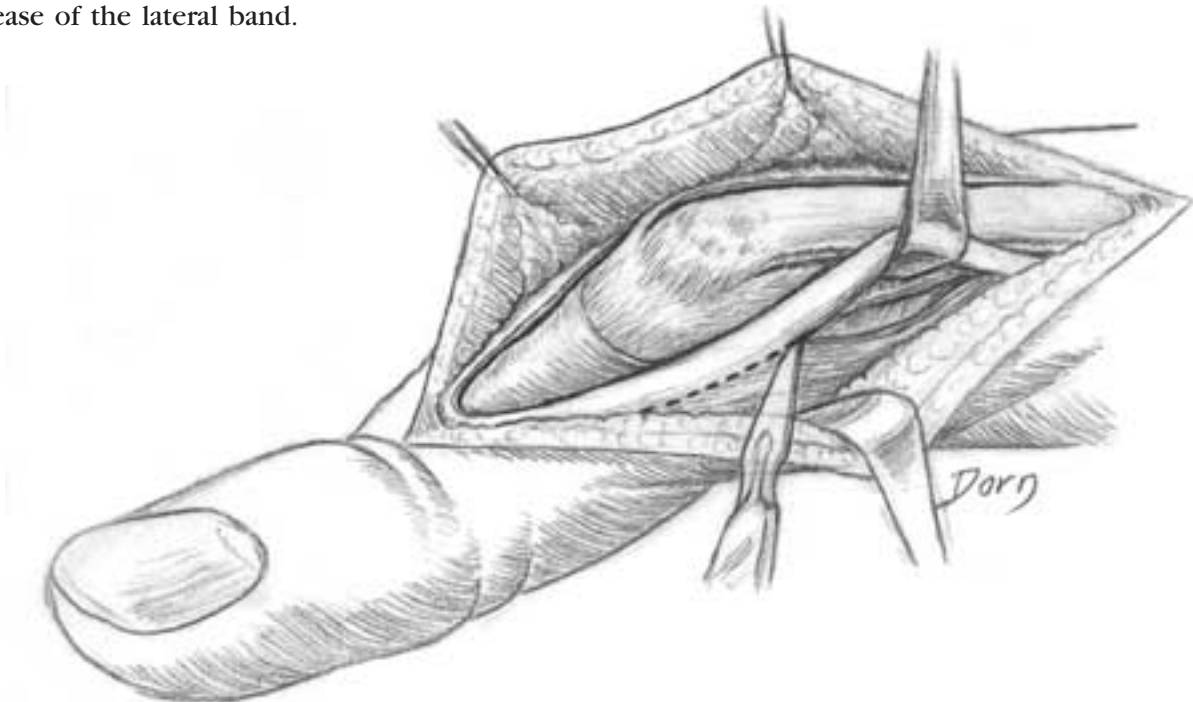
## The 'boutonnière' deformity

The 'boutonnière' deformity associates flexion of the PIP joint with hyperextension of the DIP joint. It is caused by the rupture of the central band of the extensor tendon and the luxation of the lateral bands.

### A Exposure of the lesions.

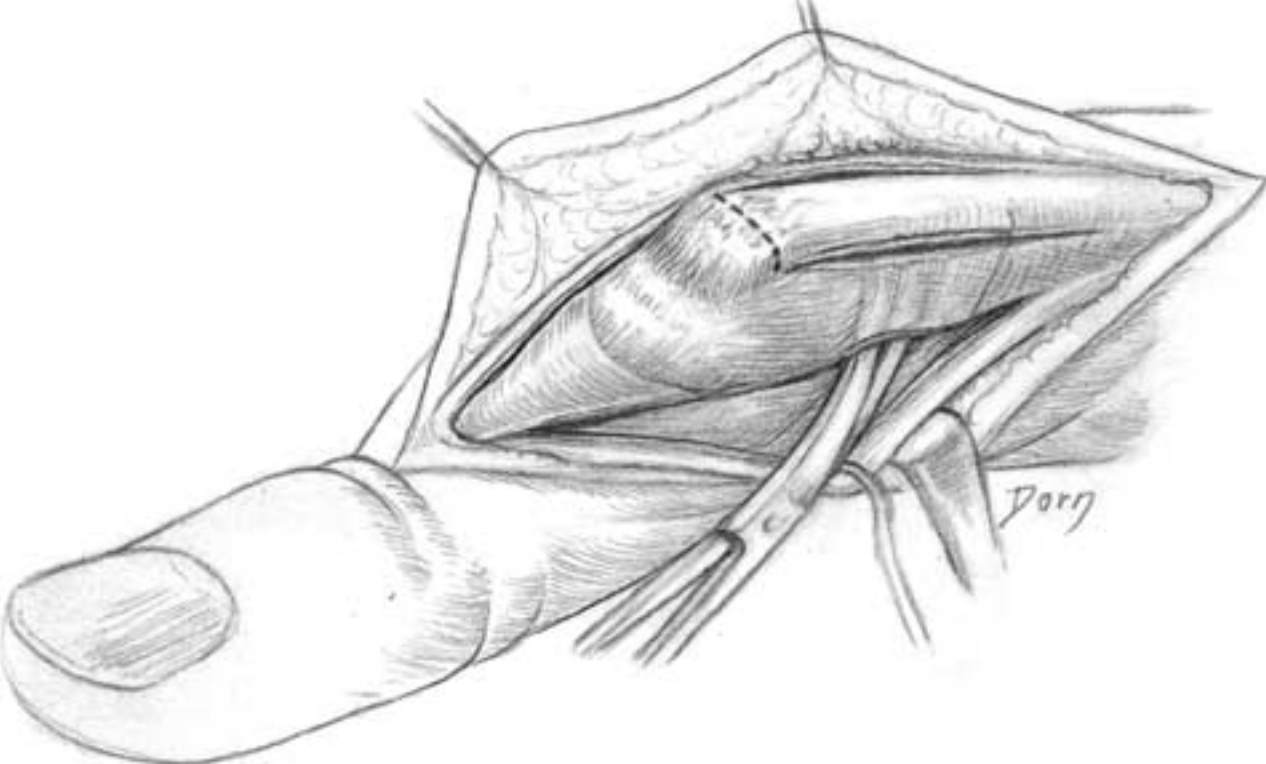


### B Release of the lateral band.

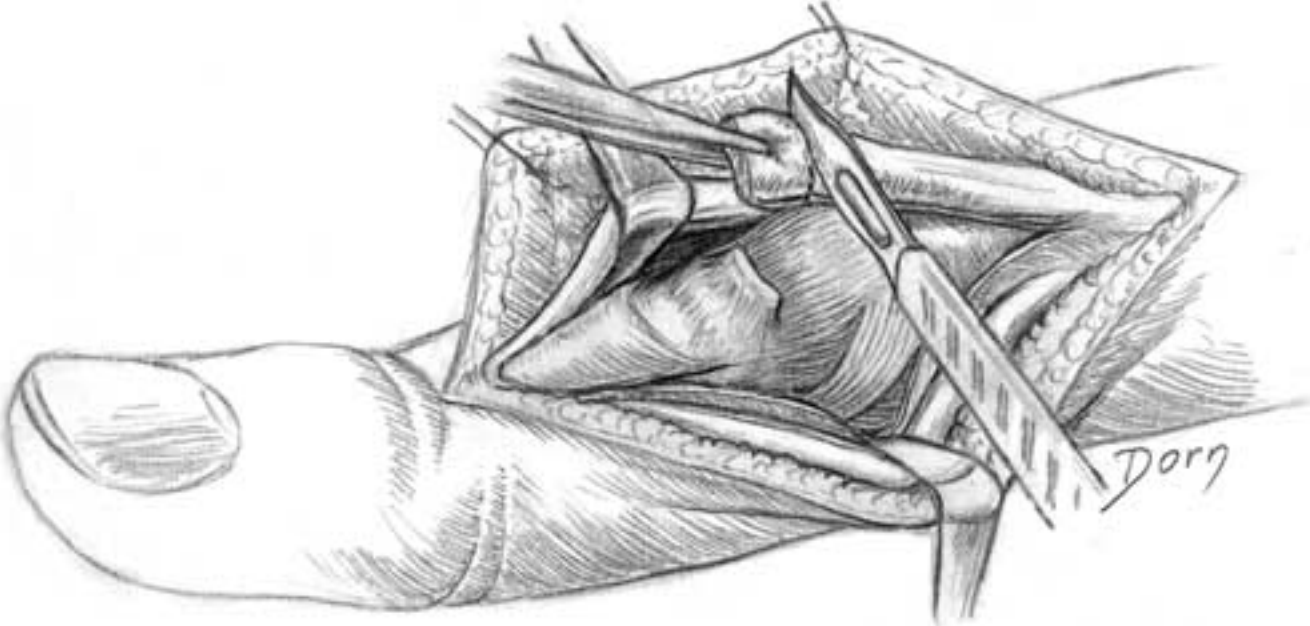


# Hand and peripheral nerve surgery

C Release of the central band.

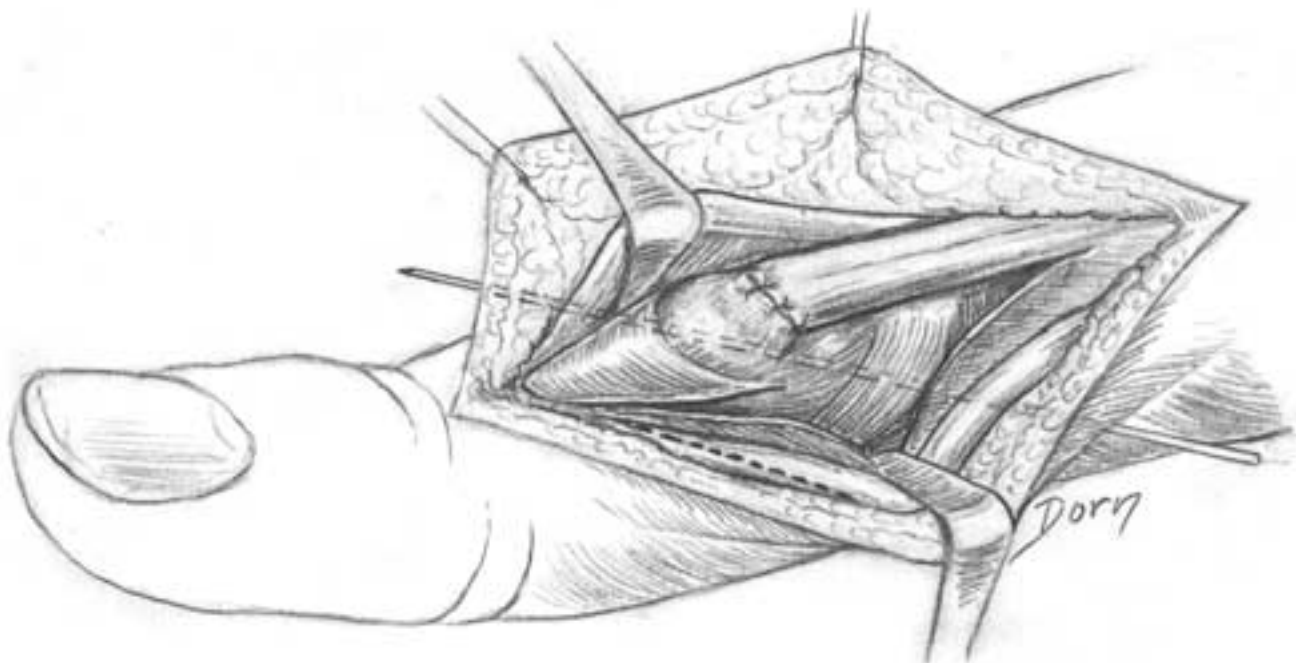


D The fibrous tissue of healing is resected to shorten the central band.

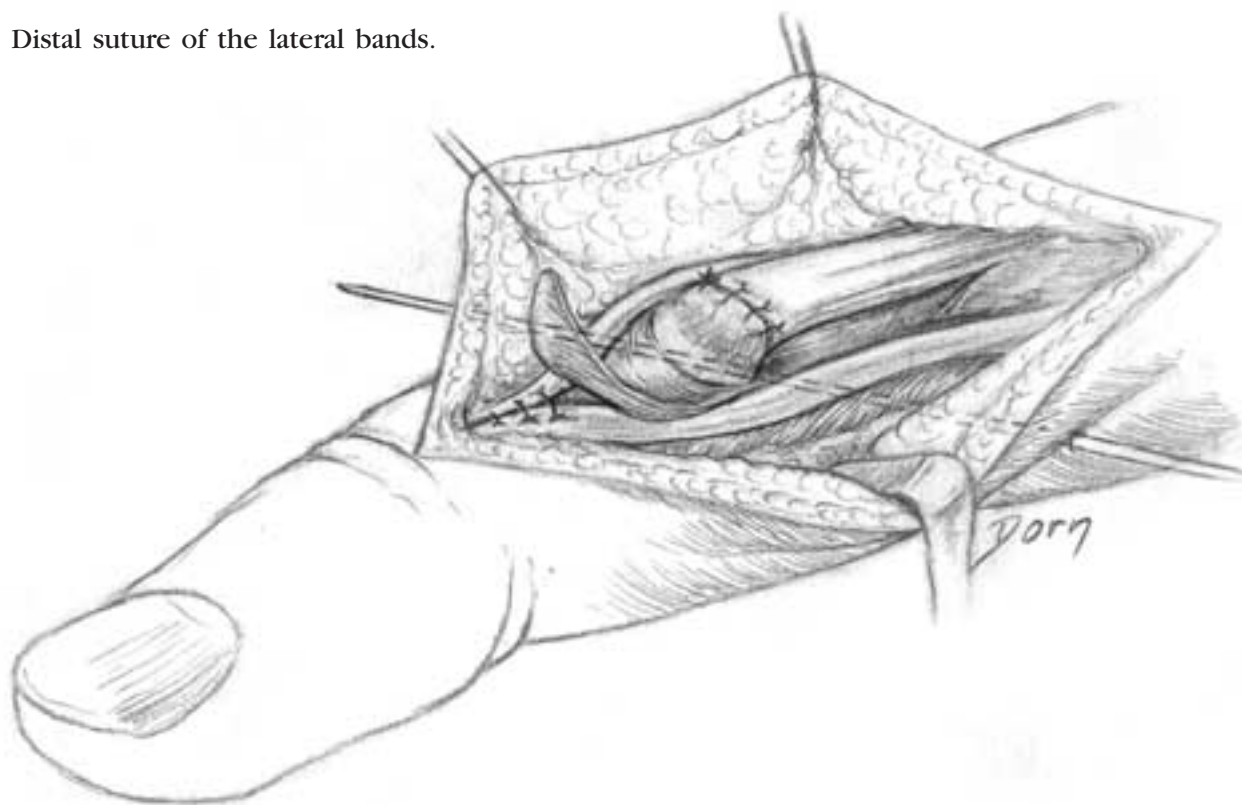


## The 'boutonnière' deformity

**E** The PIP joint is immobilised in extension with a wire. The central band of the tendon is sutured.



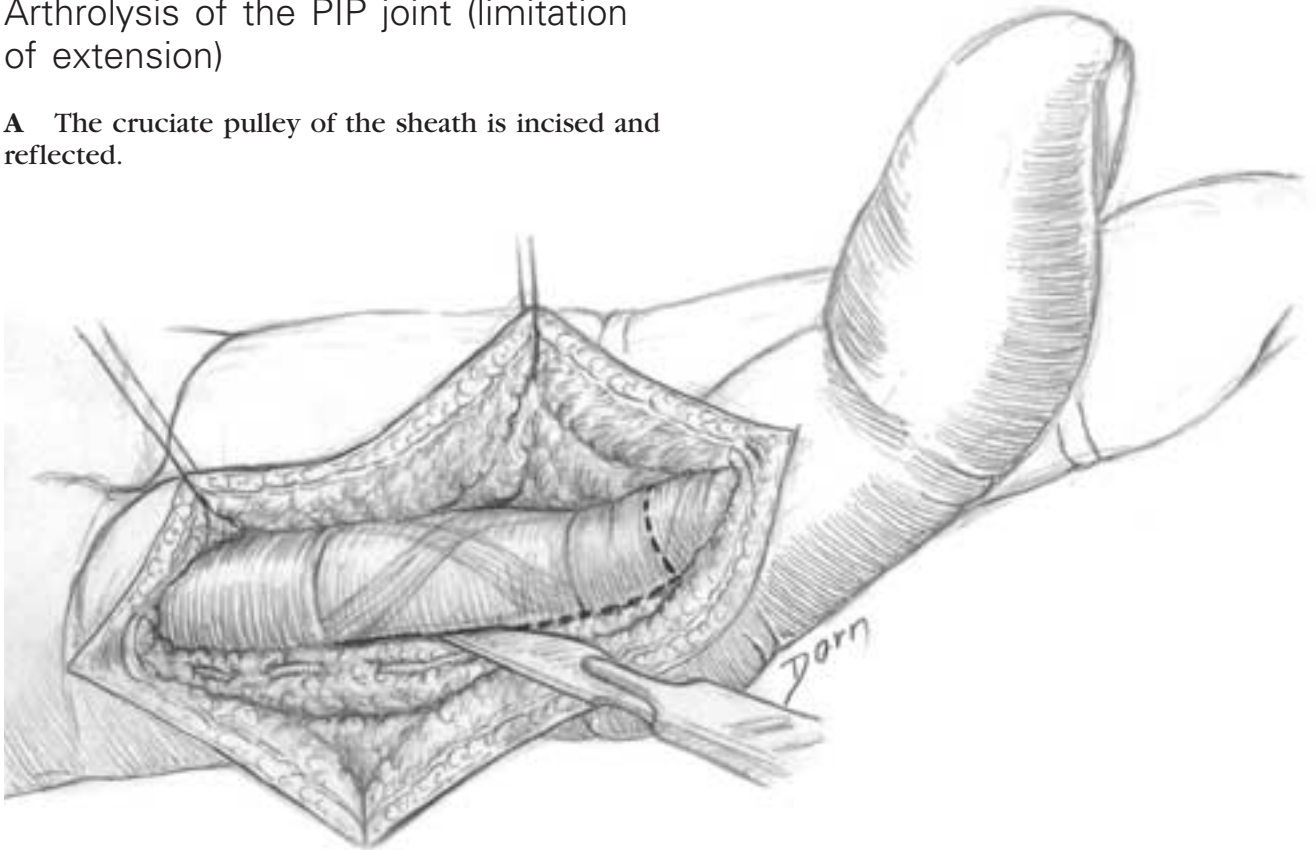
**F** Distal suture of the lateral bands.



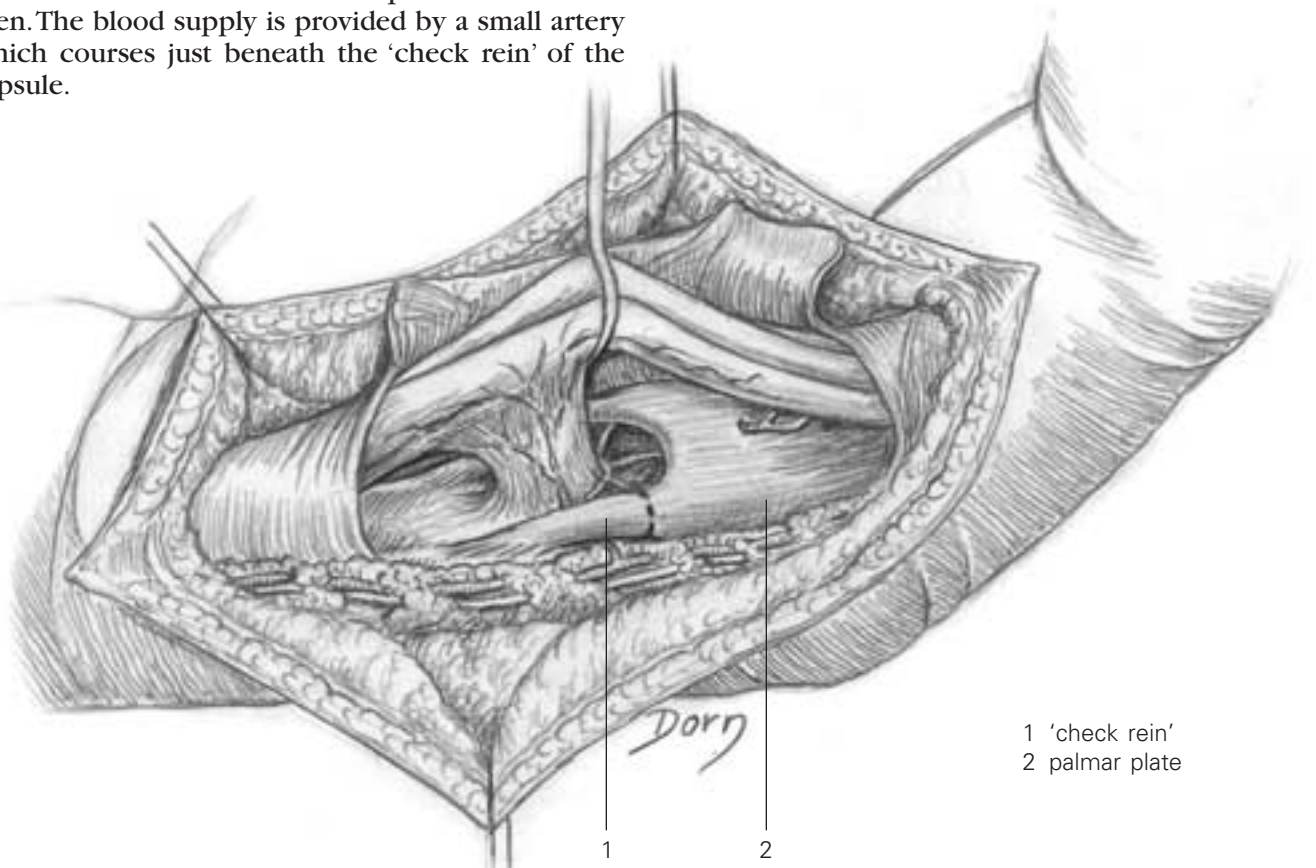
# Hand and peripheral nerve surgery

Arthrolysis of the PIP joint (limitation of extension)

**A** The cruciate pulley of the sheath is incised and reflected.



**B** The vincula of the flexor superficialis are well seen. The blood supply is provided by a small artery which courses just beneath the 'check rein' of the capsule.

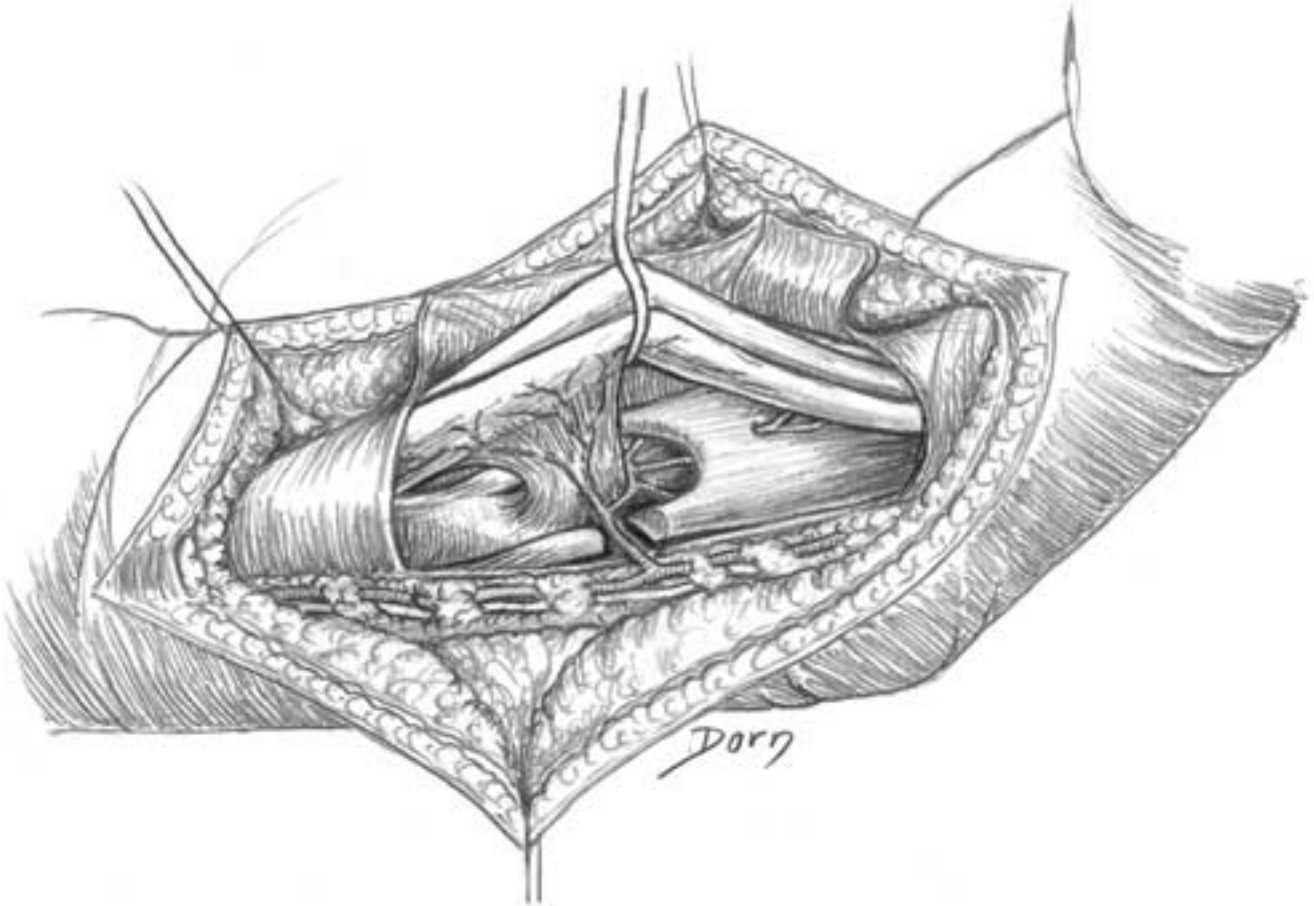


- 1 'check rein'
- 2 palmar plate

## Arthrolysis of the PIP joint (limitation of extension)

---

**C** The check rein is divided, taking care of the small artery. This constitutes the first step of the arthrolysis, and most of the time this is sufficient. If it is not, the capsule is released.



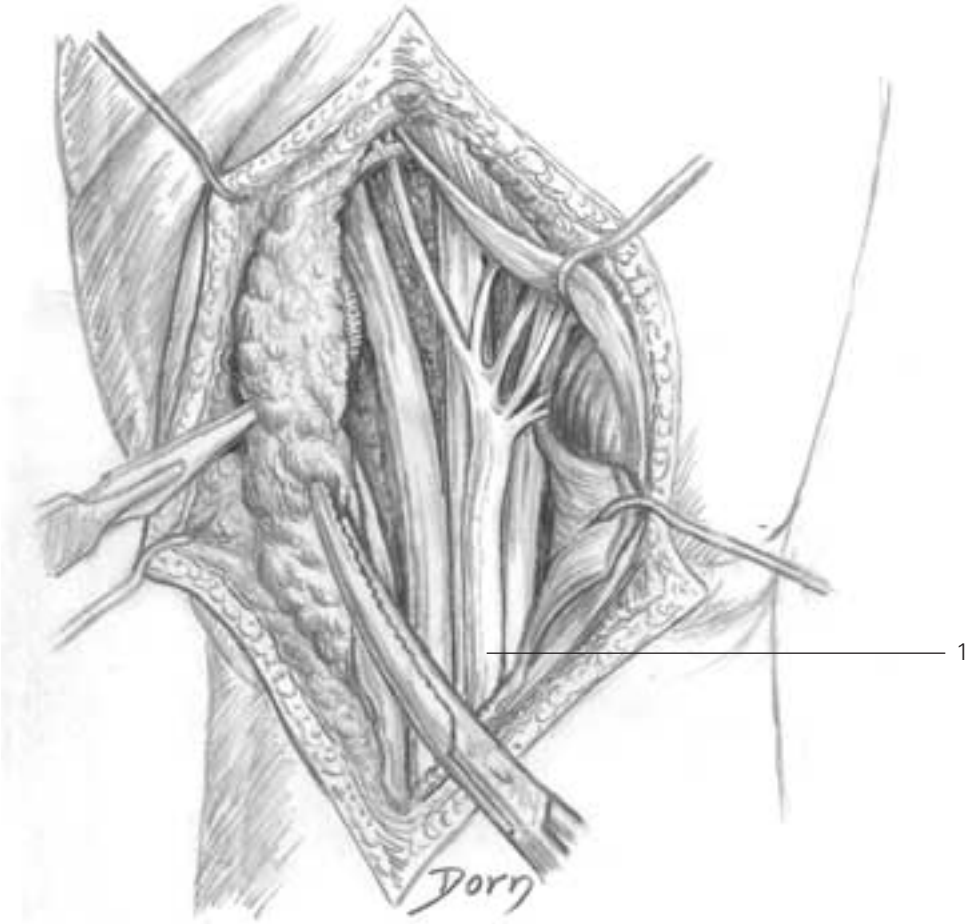


# Hand and peripheral nerve surgery

## Protective flap for the median nerve at the wrist

This procedure is indicated in iterative release of the median nerve in carpal tunnel syndrome.

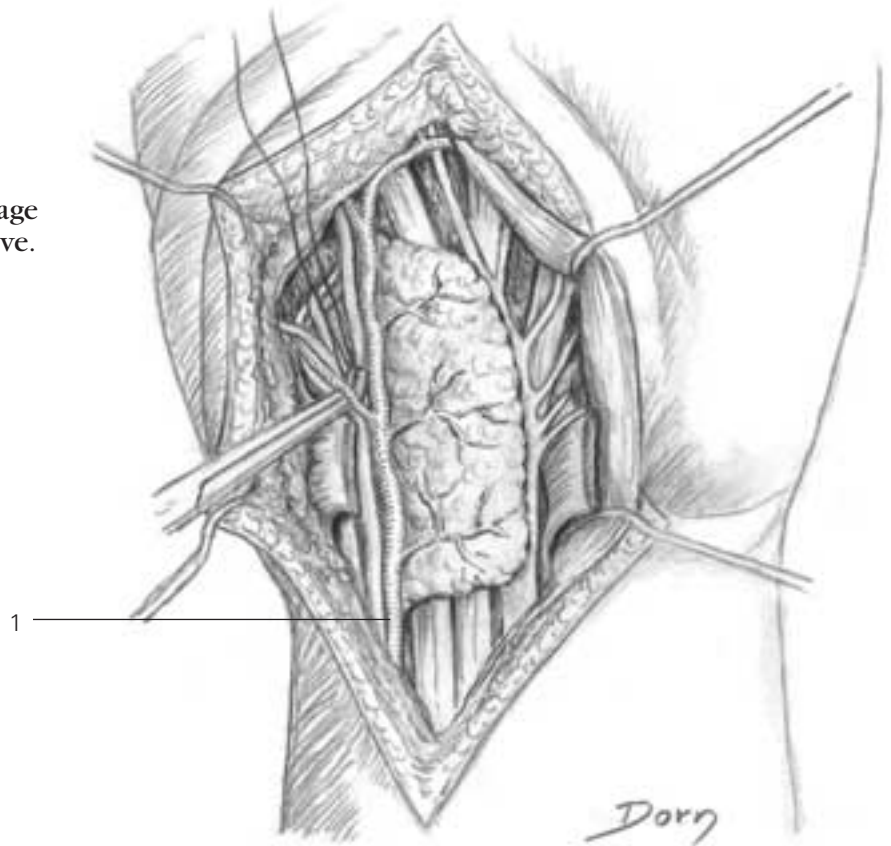
**A** The fat pad of Guyon's compartment is mobilised. It is supplied by the ulnar artery.



1 median nerve

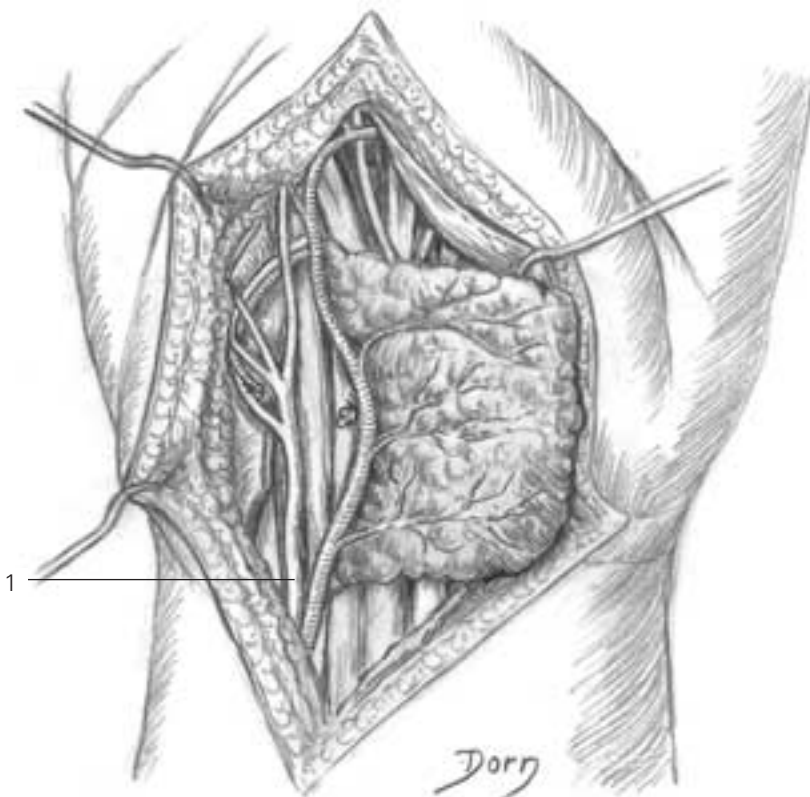
# Protective flap for the median nerve at the wrist

**B** The fat flap is turned like a page of a book to cover the median nerve.



1 ulnar artery

**C** If necessary, the ulnar vessels are mobilised to increase the arc of rotation of the flap.



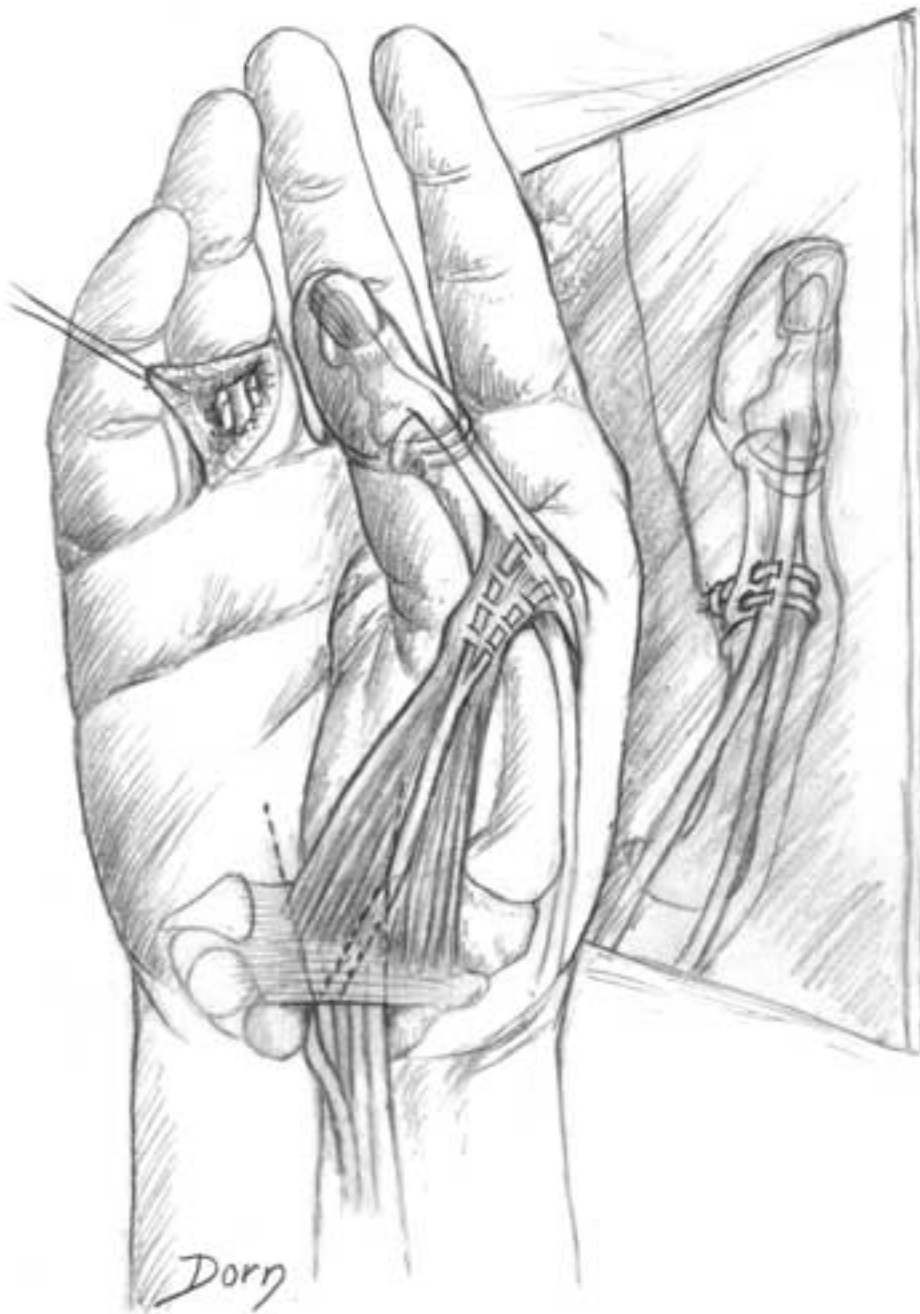
1 ulnar nerve

# Hand and peripheral nerve surgery

## Flexor digitorum superficialis transfer to the thumb

This procedure allows, in a single drawing, to see the opposite side of the base of the thumb. Therefore, we can see the fixation of the tendon transfer on the ulnar side of the thumb.

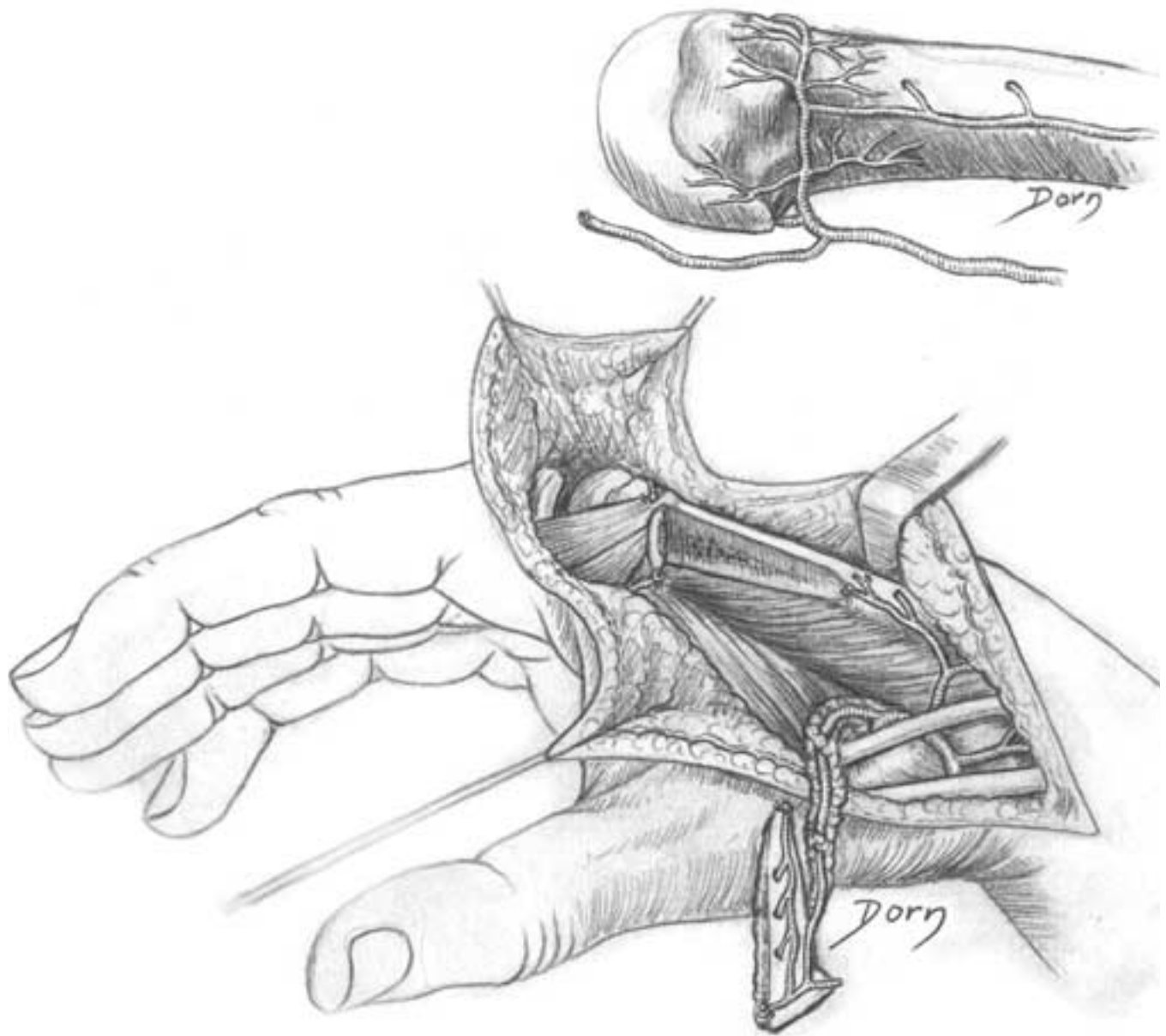
Paralysis of all intrinsic muscles of the thumb. FDS transfer to the thumb. The best site for the pulley is at the proximal pole of the pisiform. The simplest procedure consists of passing the transfer around the tendon of the FCU. However, if this muscle is paralysed, its tendon stretches and the direction of the transfer will not be maintained. In this event it is advisable to perform a tenodesis of the paralysed FCU tendon to the ulna proximal to the pulley.



# Vascularised bone transfer from the second metacarpal

Vascularised bone transfer from the metaphysis of the second metacarpal

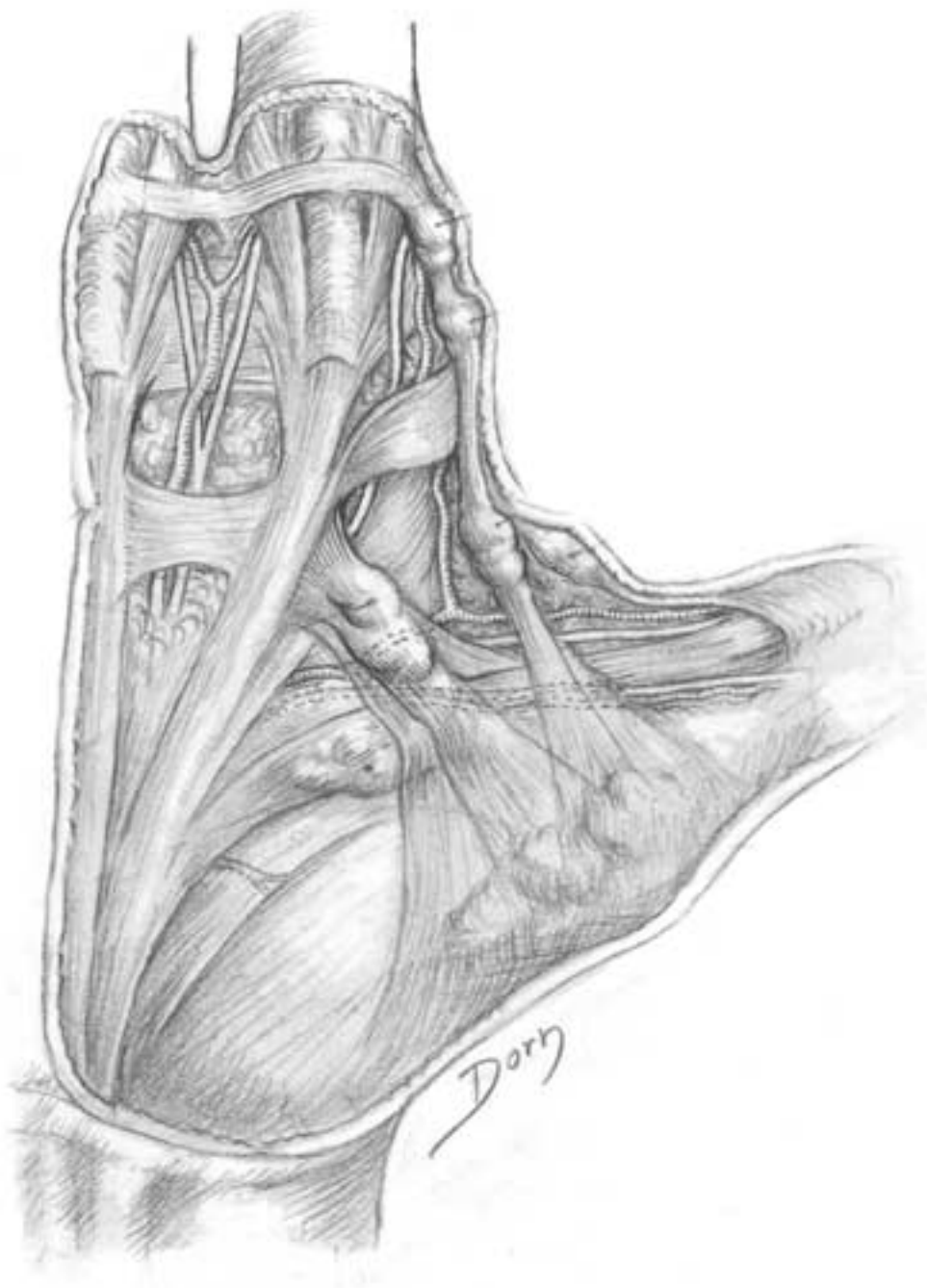
The bone block is pedicled on the first dorsal interosseous artery. This transfer can be used for atrophic non-union of the scaphoid.



## Dupuytren's disease

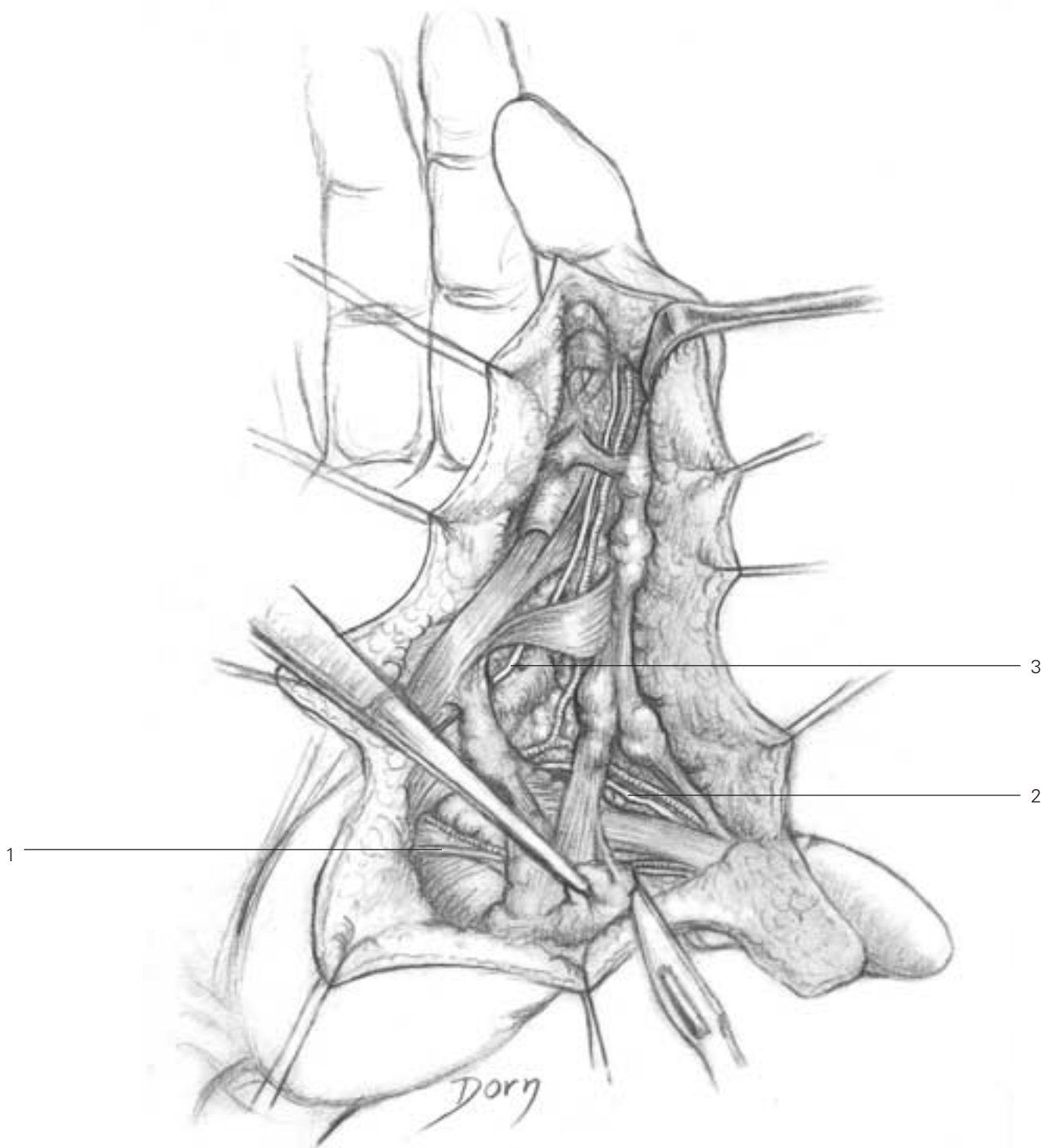
This series of illustrations is probably one of the most beautiful of all of Léon Dorn's drawings. The amount of work needed for representing the lesions is impressive. The drawings are based on the vast experience of Raoul Tubiana, and the fibrous bands are not a product of imagination.

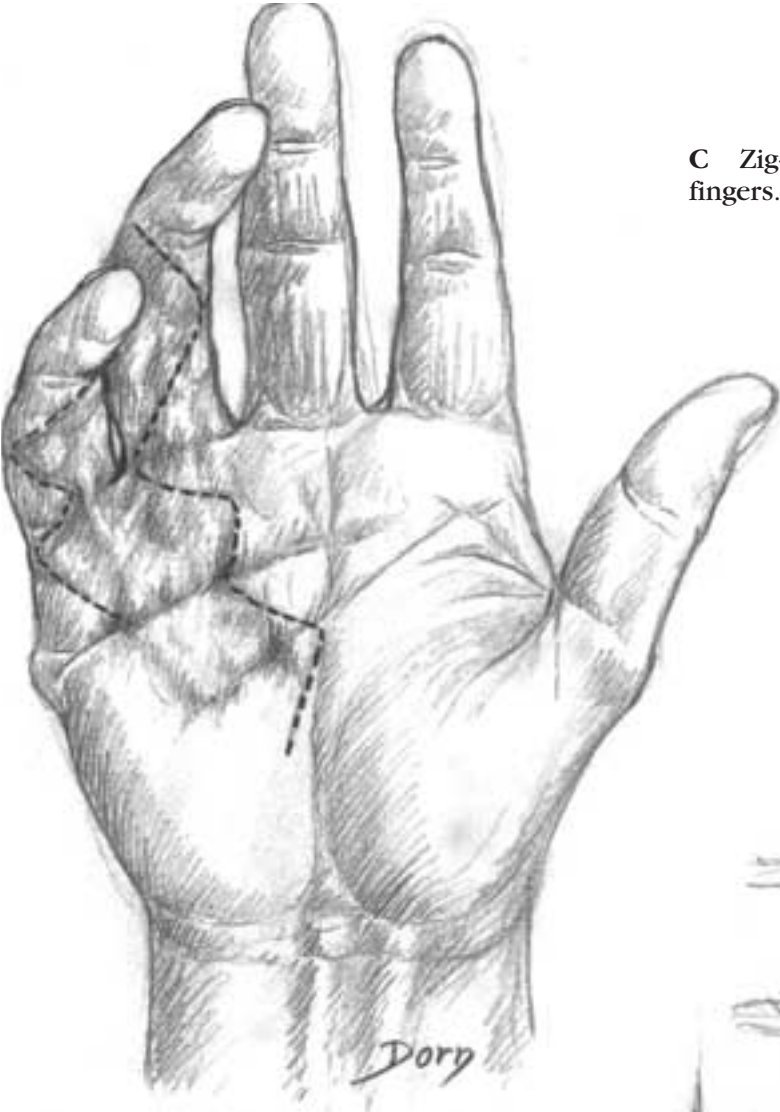
A Radial side lesions.



**B** At the digitopalmar junction and in the finger, pathological tissue is often very thick. It is necessary to identify the arteries and nerves at the level of the finger.

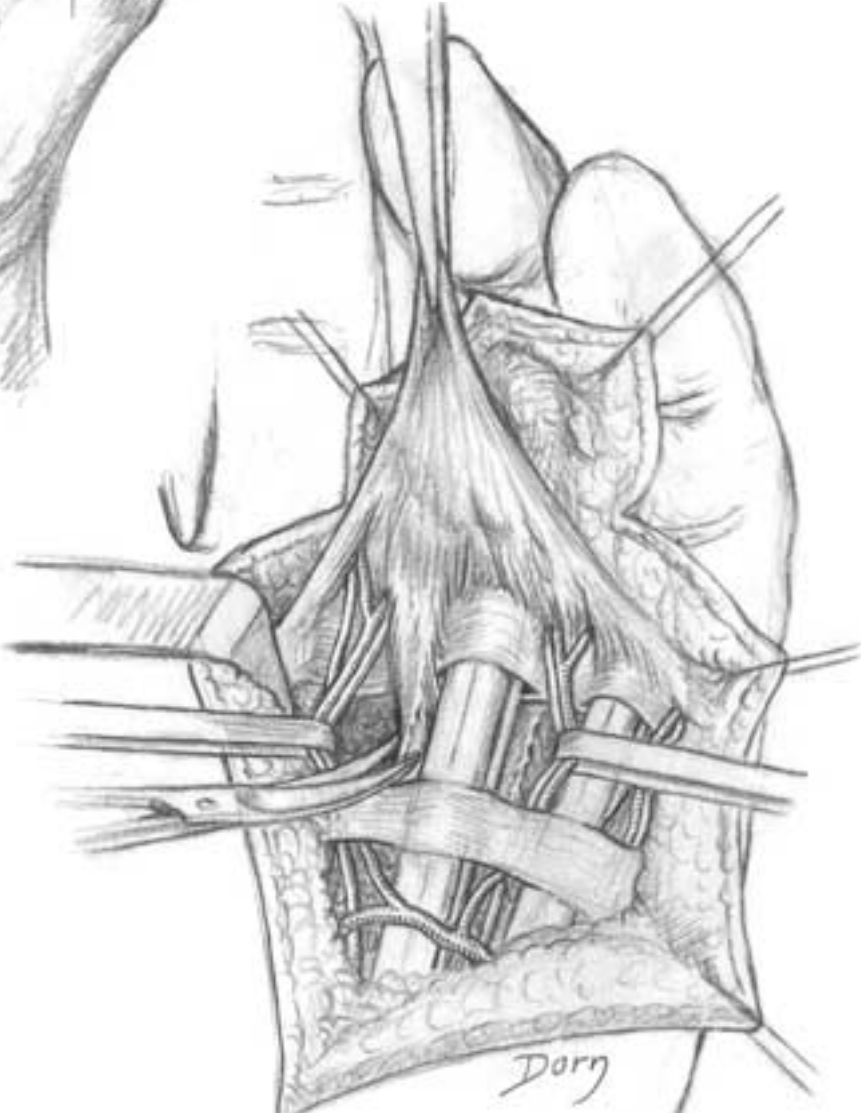
- 1 radial collateral nerve of the thumb
- 2 ulnar vascular bundle of the thumb
- 3 radial collateral nerve of the index finger



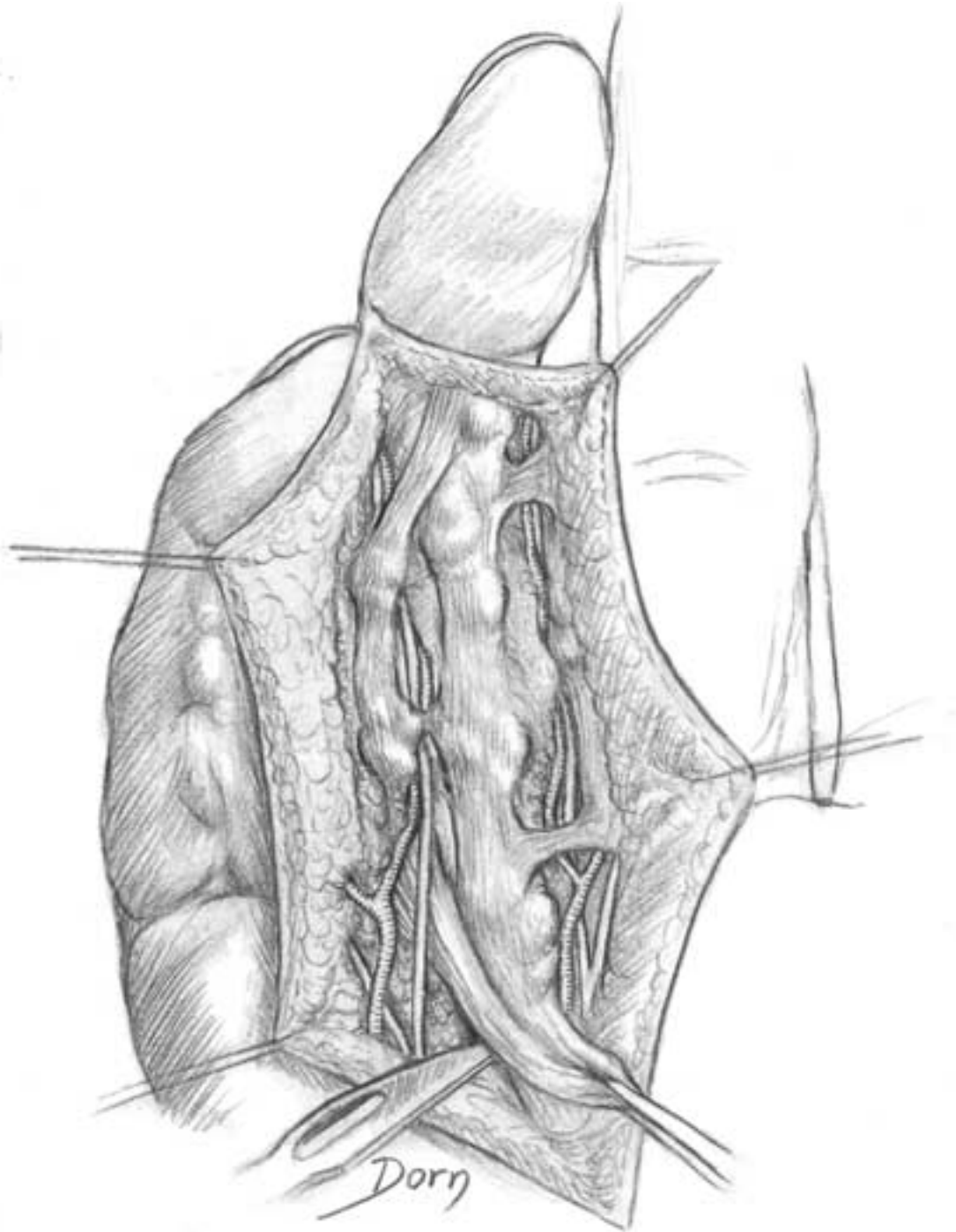


C Zig-zag digitopalmar incisions on two adjacent fingers.

D At the digitopalmar junction and in the finger, pathological tissue is often very thick. It is necessary to identify the arteries and nerves at the level of the finger.



E Division of the vertical septae.



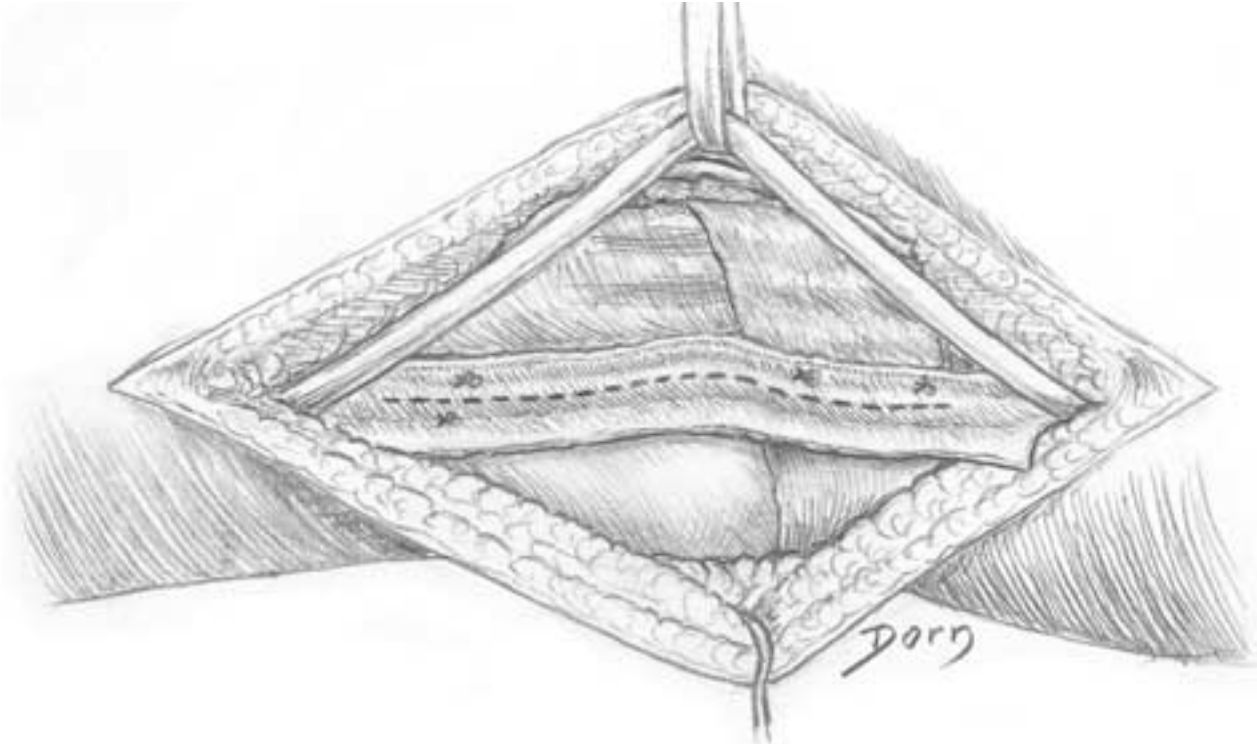


# Hand and peripheral nerve surgery

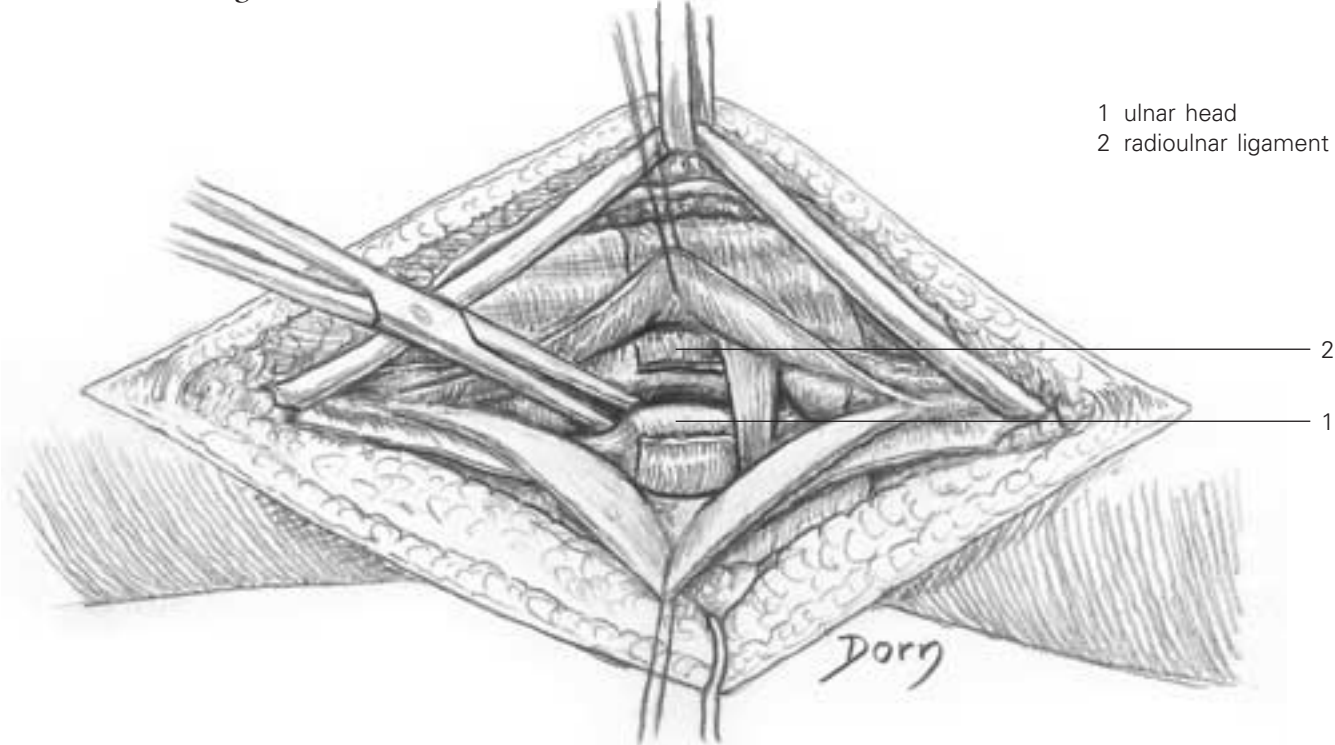
## Surgery of the wrist

Approach to the distal radioulnar joint.

**A** The fifth compartment of extensor tendons has been opened. The tendon of extensor digiti minimi is retracted and the floor of the sheath is incised.



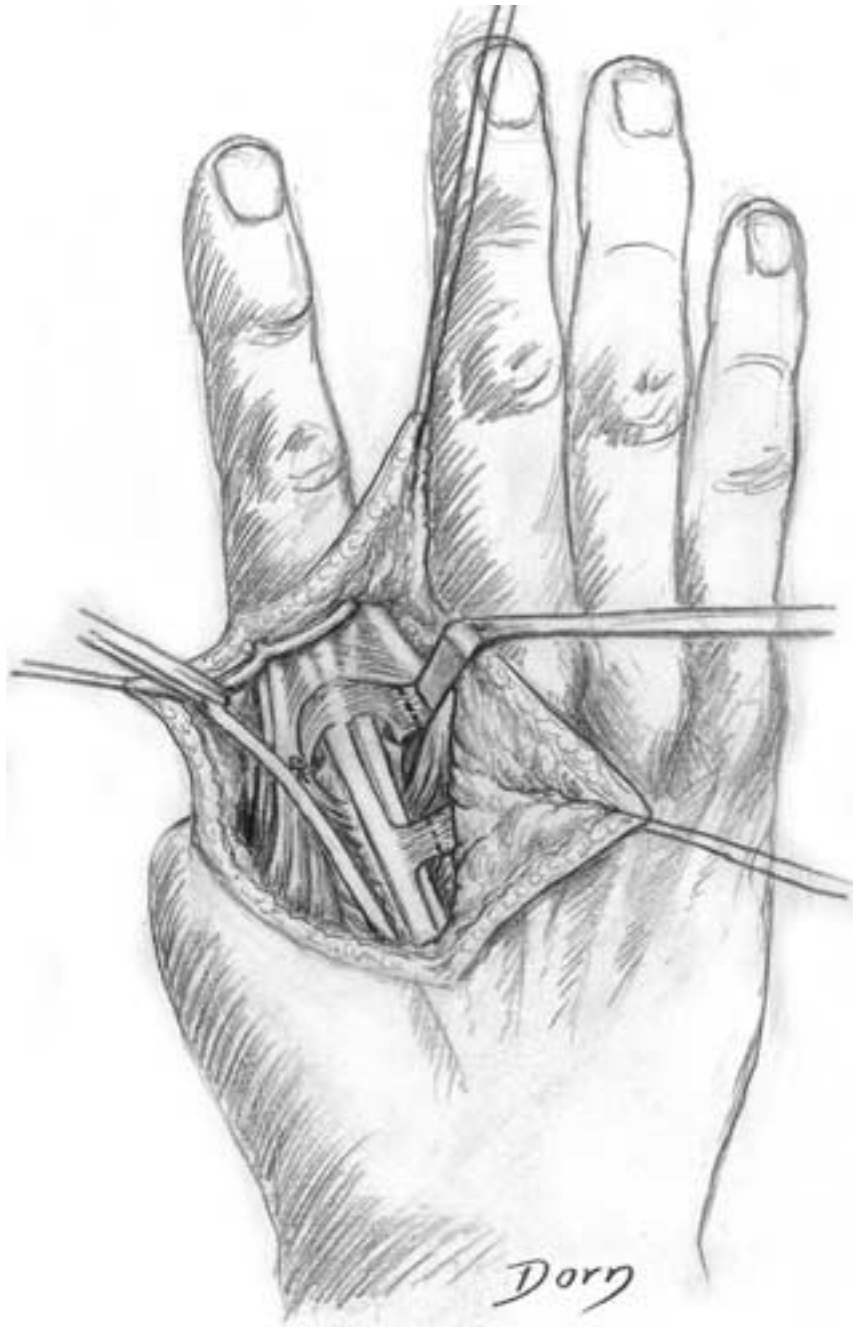
**B** The joint is exposed. Note rupture of the posterior radioulnar ligament.



## Pollicisation of the index finger

The procedure of pollicisation consists of transferring a finger to replace a missing thumb. It is one of the most difficult techniques in surgery of the hand. The skin incision should be precisely designed, dissection must be accurate and cautious and the result should be assessed cosmetically and functionally. The series of drawings shows pollicisation of the index finger, which is the most frequently performed.

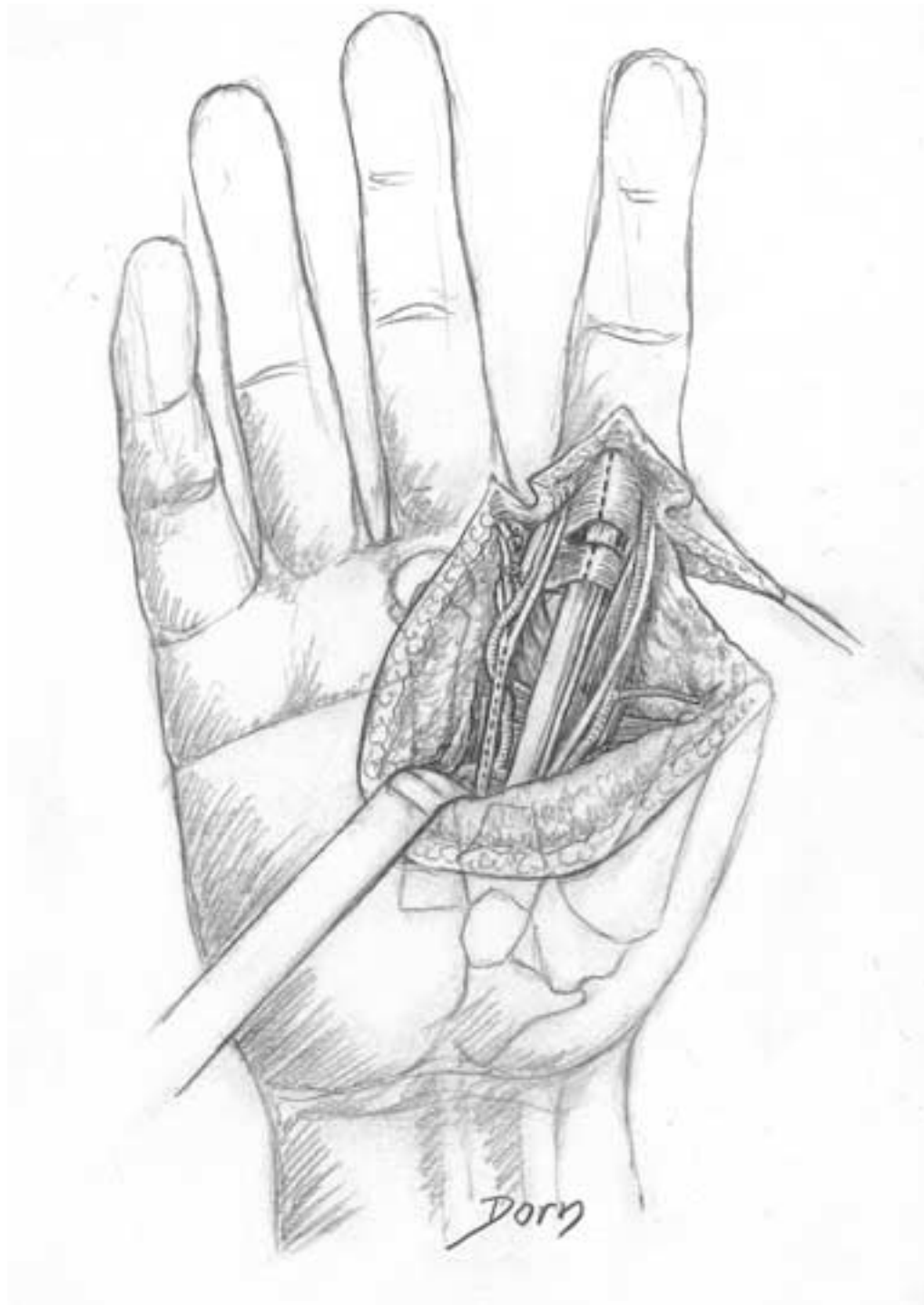
**A** Dissection of the dorsal aspect, skin flaps being reflected.



# Hand and peripheral nerve surgery

---

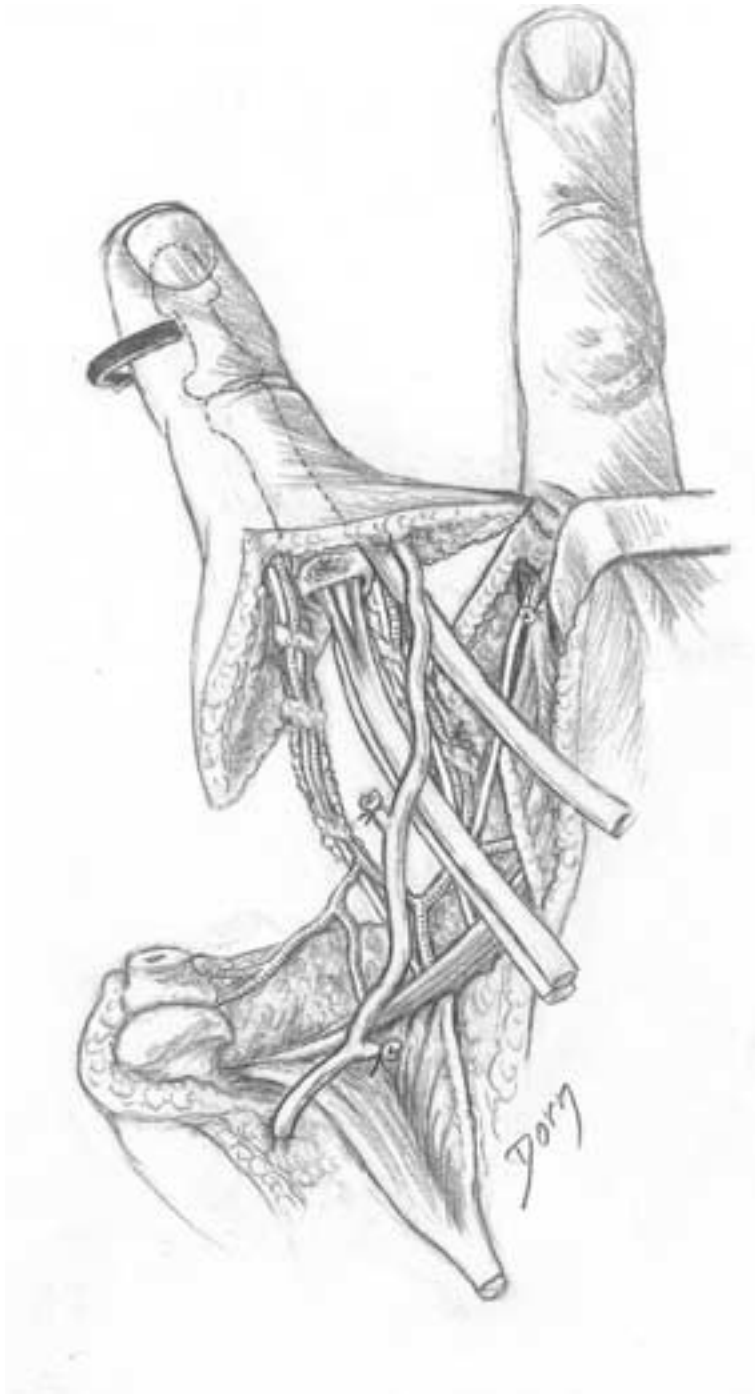
**B** Dissection of the palmar structures. Care should be taken to spare the neurovascular pedicles. Note that the common digital nerve should be split (by intraneural dissection) to allow the mobilisation of the finger.



## Pollicisation of the index finger

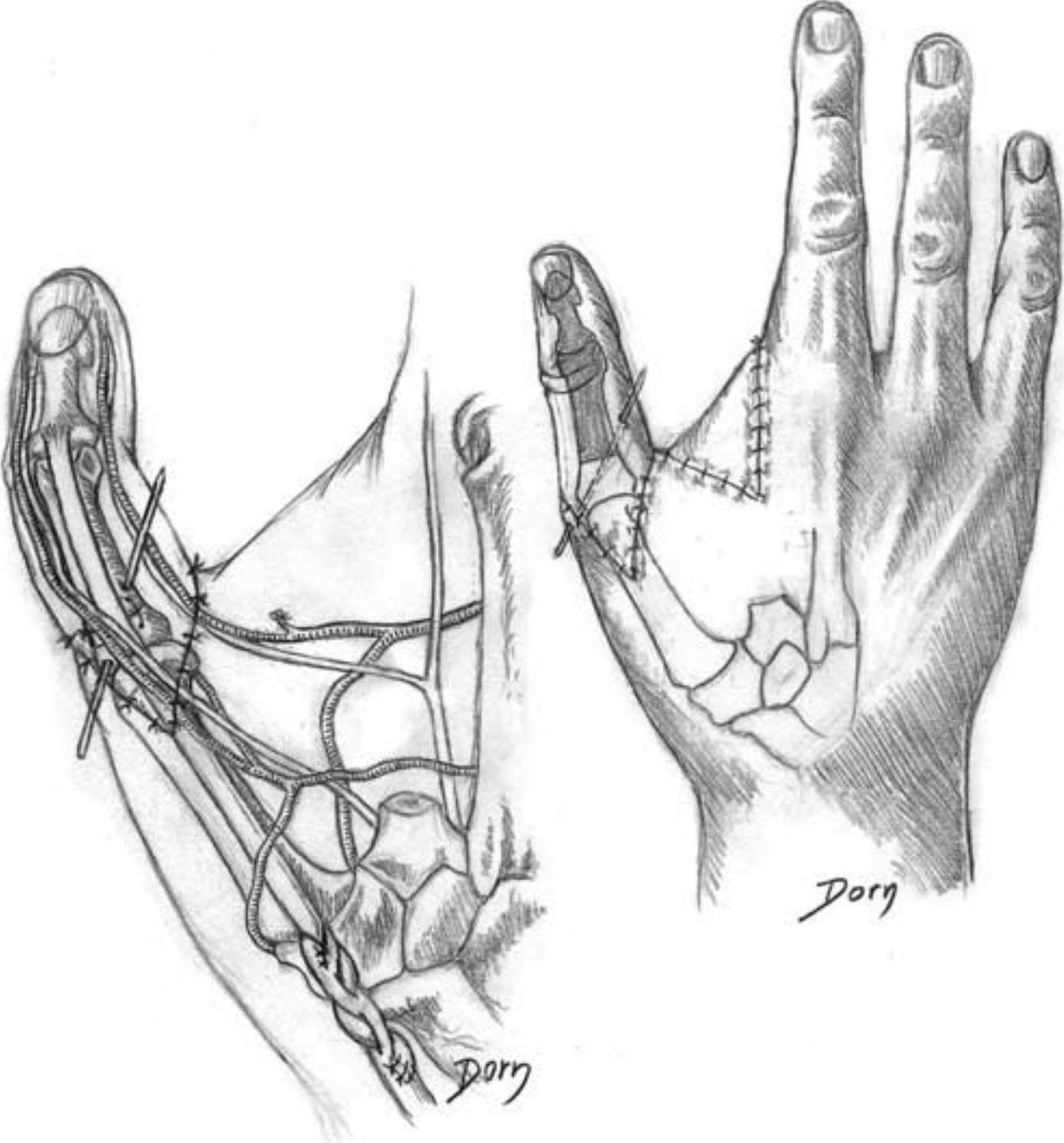
---

C The finger remains pedicled only on its neurovascular bundles: palmar pedicles and dorsal vein. The tendons are severed to be sutured on the recipient site. The index finger should be rotated without twisting the pedicles. Note that the first phalanx has been removed.



# Hand and peripheral nerve surgery

**D** Fixation of bone and sutures of the tendons. The second metacarpal has been excised to increase the width of the first web.

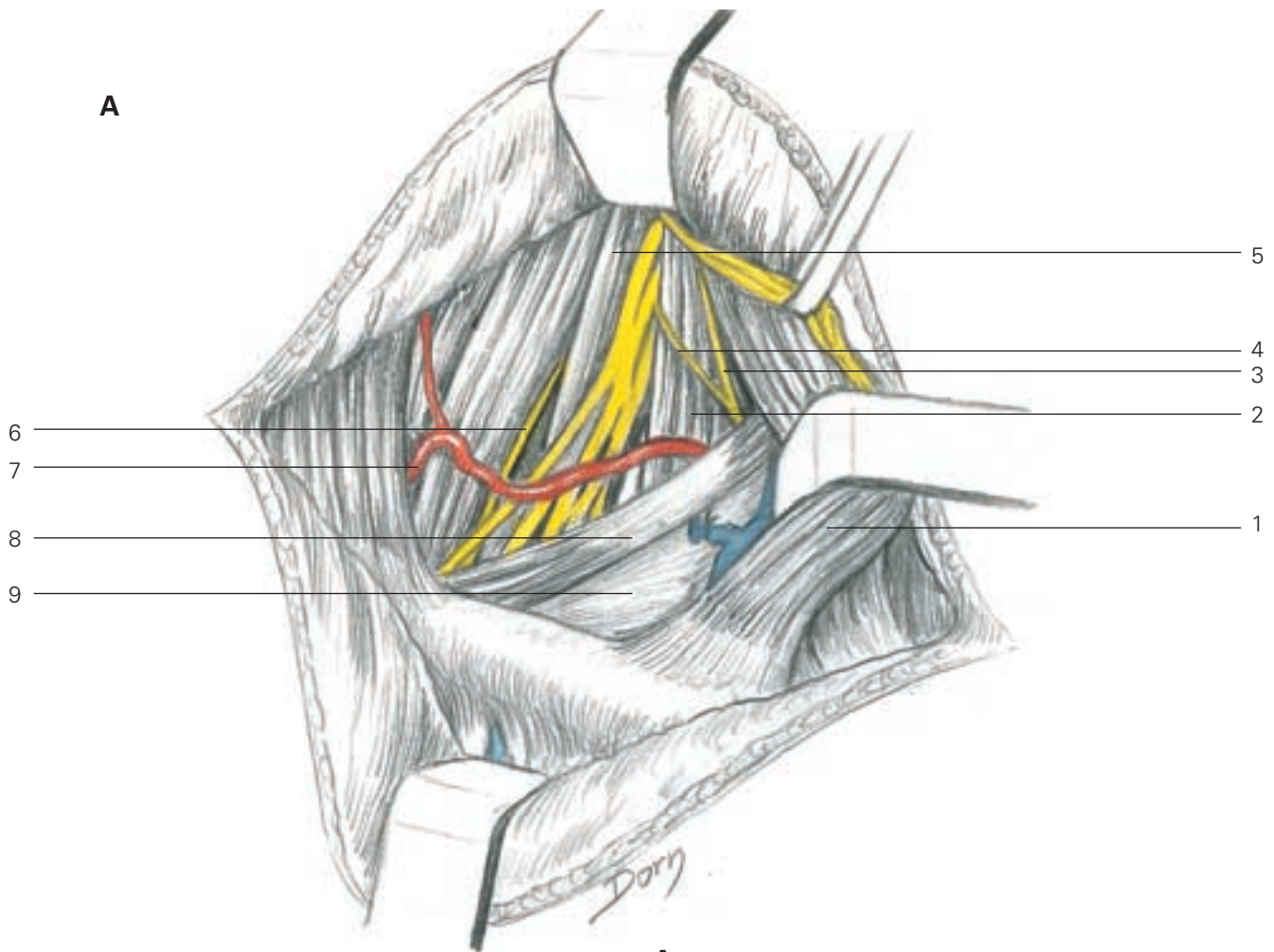


## Surgery of the peripheral nerves

Nerve surgery is particularly important in the upper limb, as the ultimate purpose of the upper extremity is the function of the hand. Tunnel syndromes are frequent (median nerve at the wrist, ulnar nerve at the elbow, etc) and cause pain and disability. Traumatic lesions require exploration and repair either by direct suturing or by nerve grafts. One of the most dramatic lesions is the partial or total paralysis of the brachial plexus as a result of trauma. The first figure shows the exposure of the brachial plexus.

## Brachial plexus

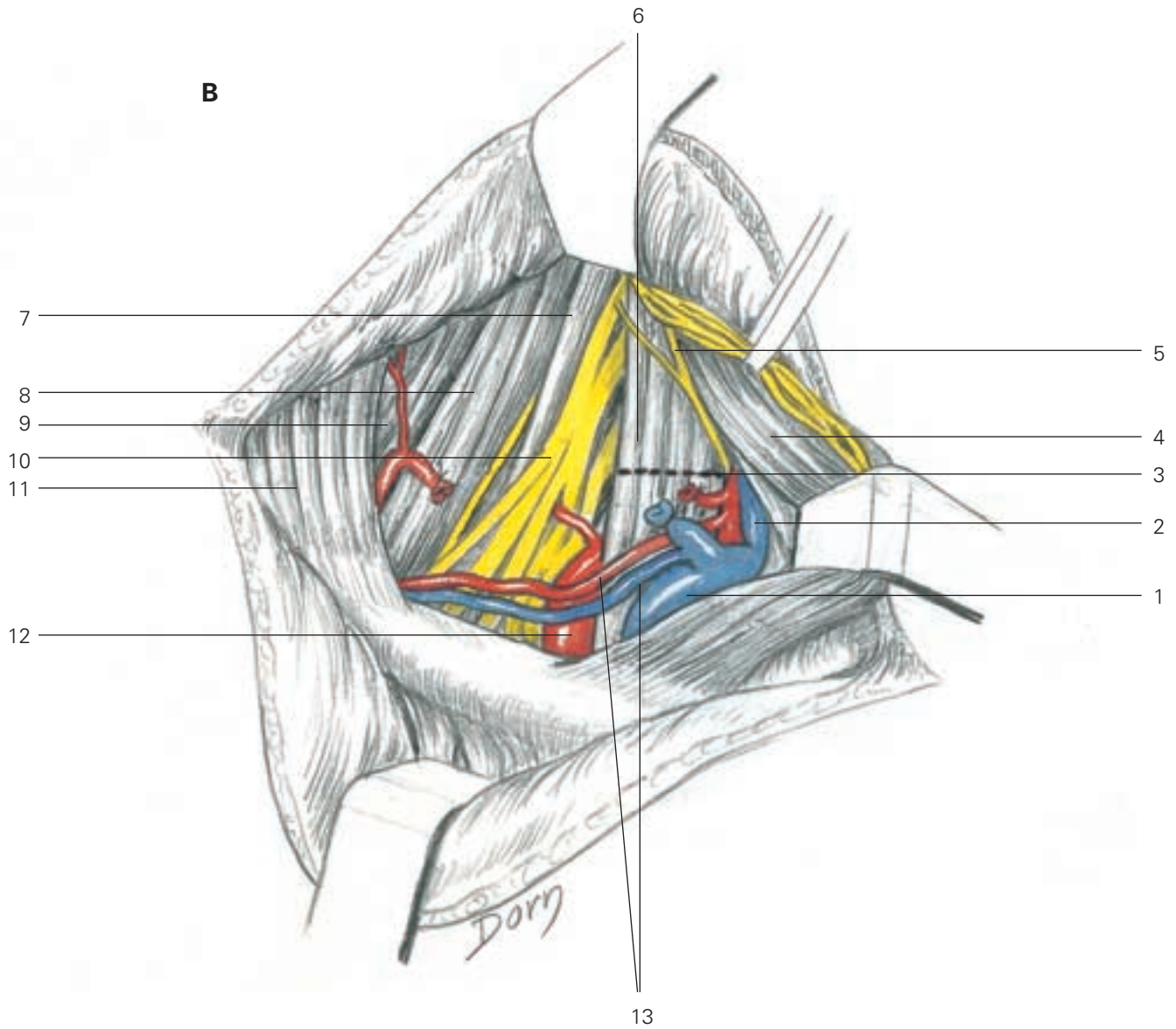
**A, B** Supraclavicular approach. The two drawings show the progressive dissection to the plexus, severing the omohyoideus (a) and then the scalenus anterior (b). Note the coloured neurovascular structures which form a key point for the rough drawings.



### A

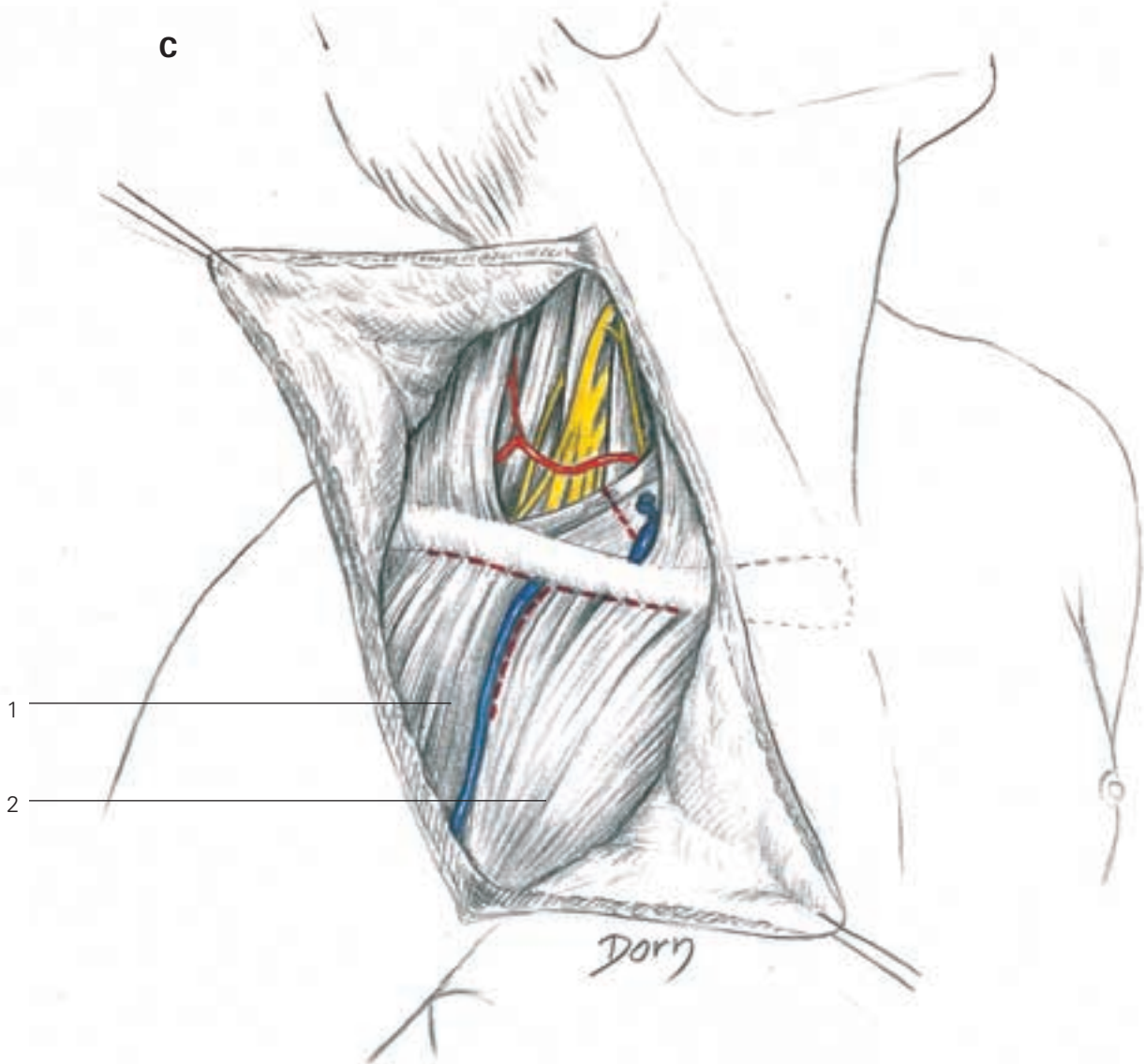
- 1 retracted sternocleidomastoid
- 2 scalenus anterior
- 3 phrenic nerve
- 4 accessory phrenic nerve
- 5 scalenus medius
- 6 branch to rhomboid and levator scapular
- 7 superficial cervical artery
- 8 omohyoideus
- 9 omohyoideus fascia

# Hand and peripheral nerve surgery



- B**
- 1 subclavian vein
  - 2 int. jugular vein
  - 3 line of division of scalenus ant.
  - 4 sterno-cleidomastoid retracted
  - 5 phrenic nerve retracted
  - 6 scalenus anterior
  - 7 scalenus medius
  - 8 levator scapula
  - 9 splenius capitis
  - 10 brachial plexus
  - 11 trapezius
  - 12 subclavian artery
  - 13 supra-scapular artery and vein

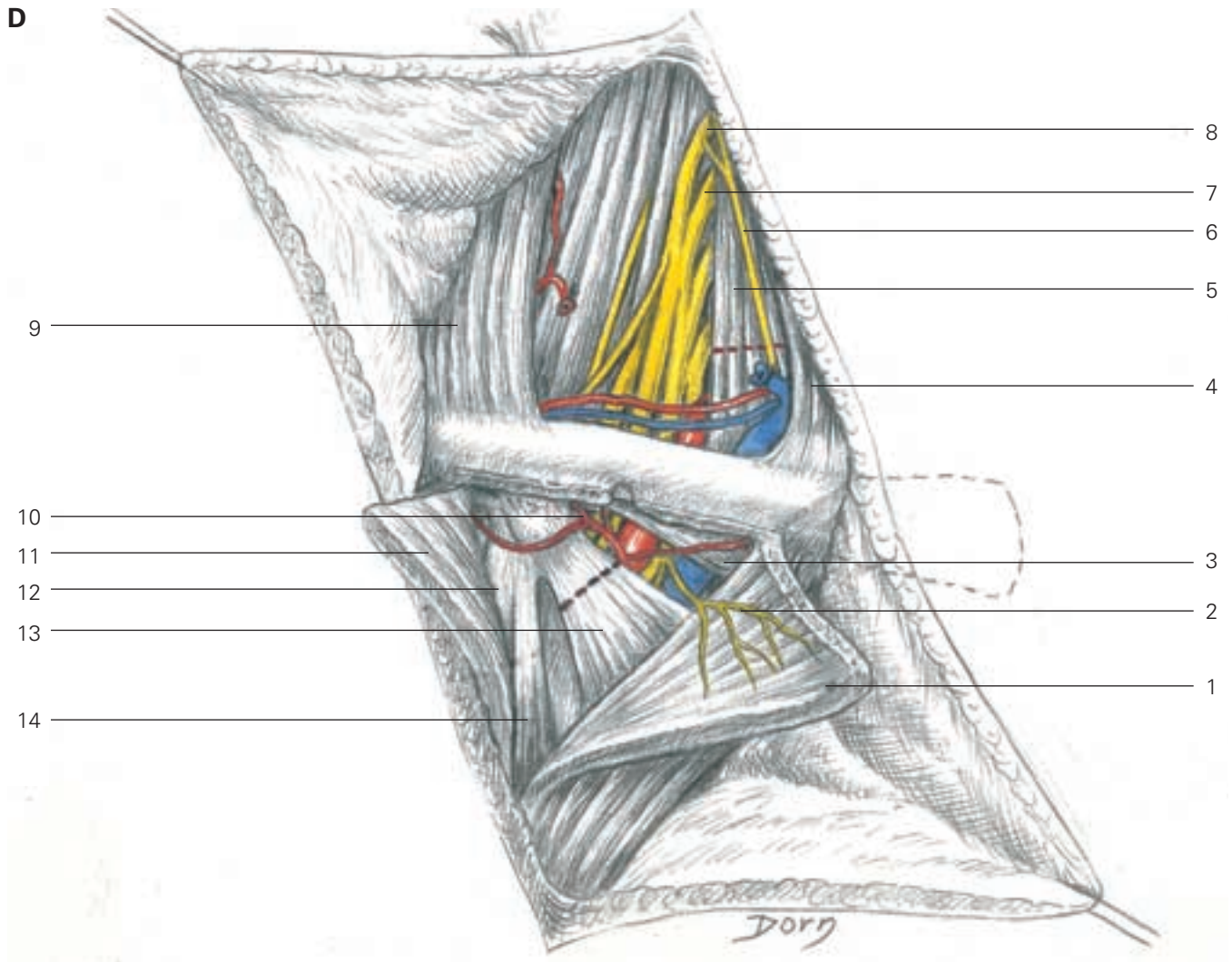
**C, D** Supraclavicular and infraclavicular approach. Pectoralis minor is severed to expose the divisions of the plexus. If necessary the clavicle can also be osteotomised.



- 1 deltoid
- 2 pectoralis major



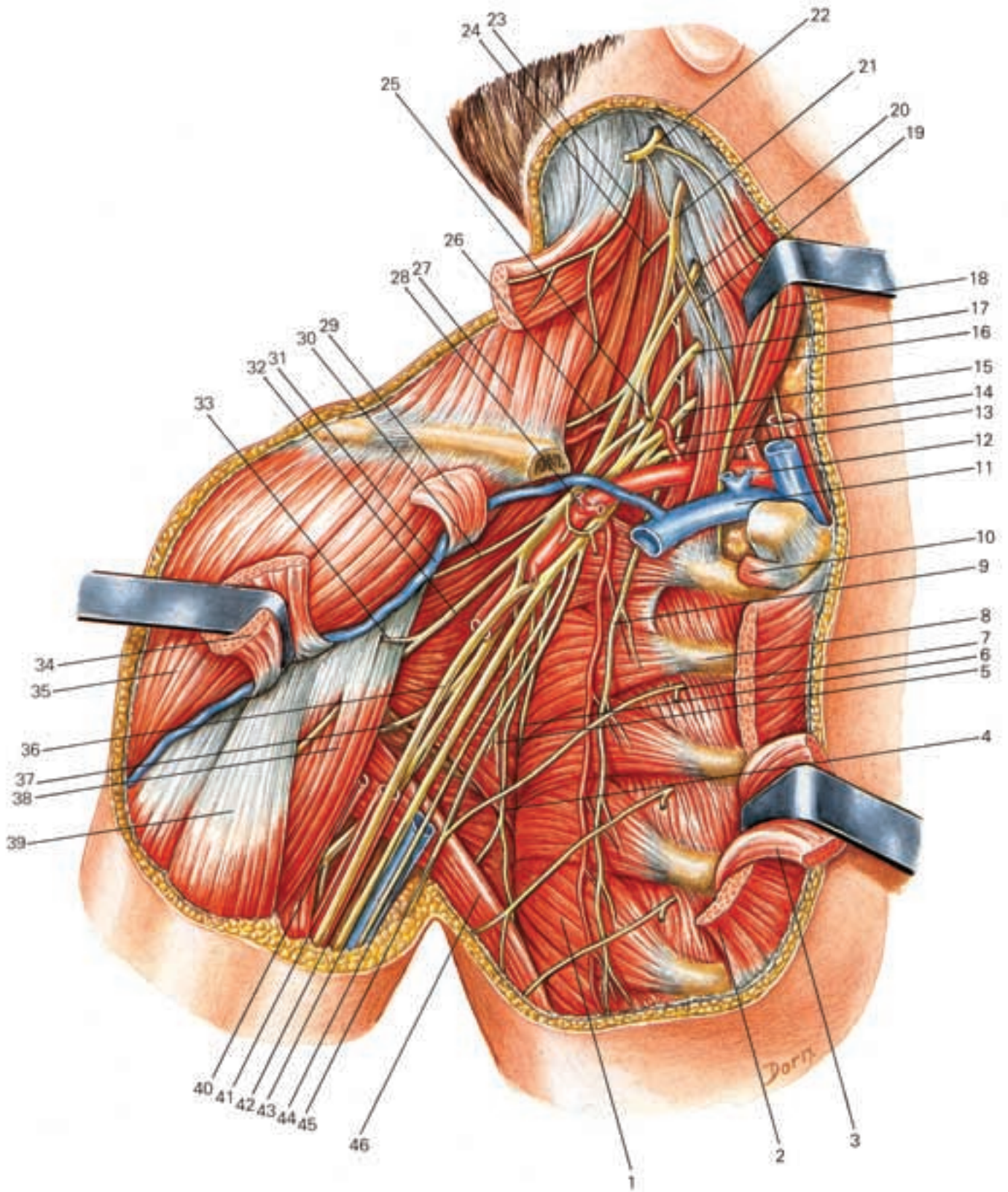
# Hand and peripheral nerve surgery



- D**
- |                        |                     |                            |
|------------------------|---------------------|----------------------------|
| 1 pectoralis major     | 5 scalenus anterior | 10 thoraco-acromial artery |
| 2 lat. pectoral nerve  | 6 phrenic nerve     | 11 deltoid                 |
| 3 subclavius           | 7 C6                | 12 short head biceps       |
| 4 sterno-cleidomastoid | 8 C5                | 13 pectoralis minor        |
|                        | 9 trapezius         | 14 coraco brachial         |
- 
- E**
- |                              |                            |   |
|------------------------------|----------------------------|---|
| 1 serratus anterior          | 17 C7                      | 33 nerve to coracobrachialis              |
| 2 pectoralis major           | 18 phrenic nerve           | 34 pectoralis major                       |
| 3 pectoralis minor           | 19 branch to phrenic nerve | 35 deltoid                                |
| 4 thoracodorsal nerve        | 20 C6                      | 36 median nerve                           |
| 5 inferior subscapular nerve | 21 C5                      | 37 axillary nerve                         |
| 6 superior subscapular nerve | 22 C4                      | 38 coracobrachialis                       |
| 7 second intercostal nerve   | 23 accessory nerve         | 39 biceps brachii                         |
| 8 second rib                 | 24 branch to rhomboids     | 40 profunda brachii                       |
| 9 long thoracic nerve        | 25 subclavius nerve        | 41 axillary artery                        |
| 10 subclavius muscle         | 26 suprascapular nerve     | 42 radial nerve                           |
| 11 subclavian vein           | 27 trapezius               | 43 ulnar nerve                            |
| 12 subclavian artery         | 28 acromiothoracic artery  | 44 axillary vein                          |
| 13 T1                        | 29 pectoralis minor        | 45 medial brachial cutaneous nerve of arm |
| 14 suprascapular artery      | 30 upper subscapular nerve | 46 latissimus dorsi                       |
| 15 C8                        | 31 cephalic vein           |   |
| 16 scalenus anterior         | 32 musculocutaneous nerve  |   |

# Surgery of the peripheral nerves

E Anatomical view of all structures.

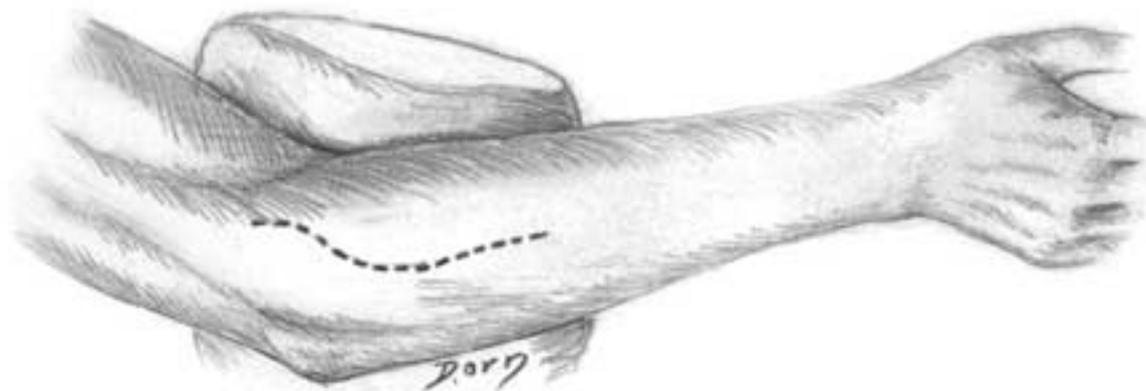


# Hand and peripheral nerve surgery

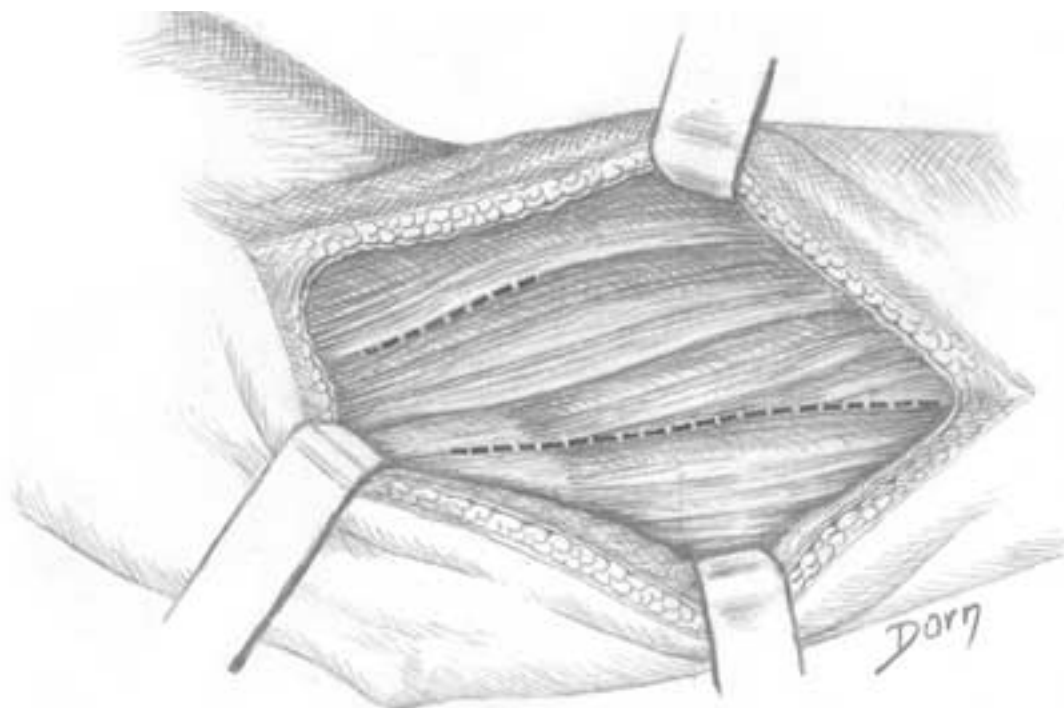
---

Exposure of the interosseous nerve  
(posterior motor branch of the radial  
nerve)

**A** Skin incision on the posterolateral aspect of the  
forearm.

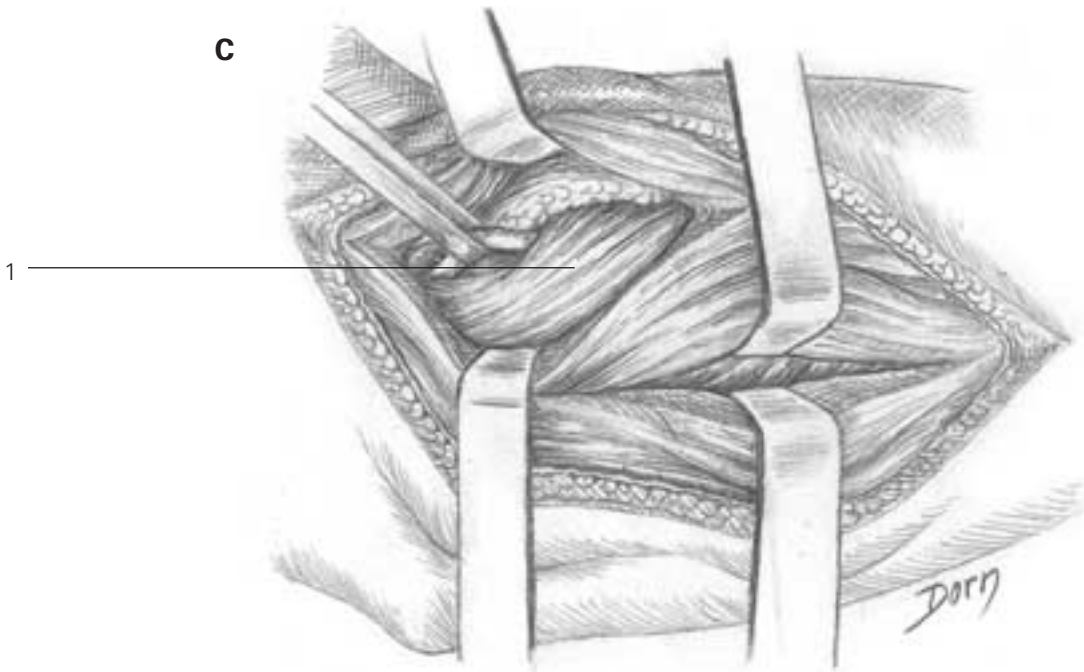


**B** Muscles are exposed. Two approaches are  
mandatory: the first one between the extensors of  
the carpus and the extensor digitorum communis  
and the second one between the extensors of the  
fingers and extensor carpi ulnaris.



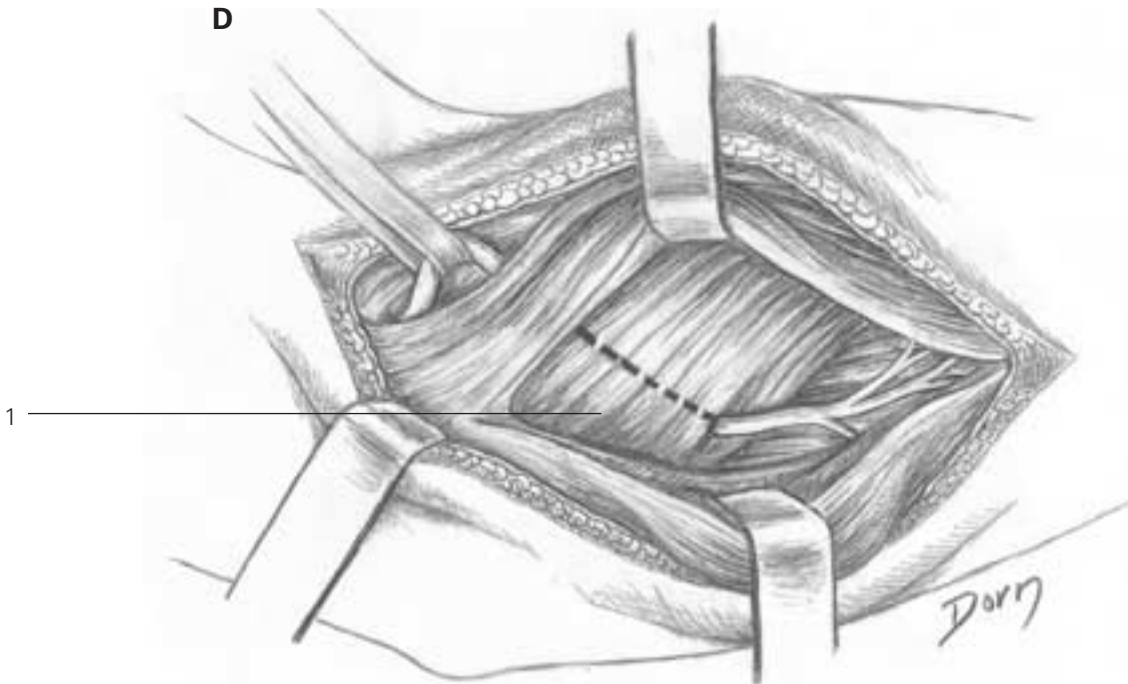
**C, D** The posterior radial nerve is identified proximally and distally to the supinator muscle.

**C**



1 supinator

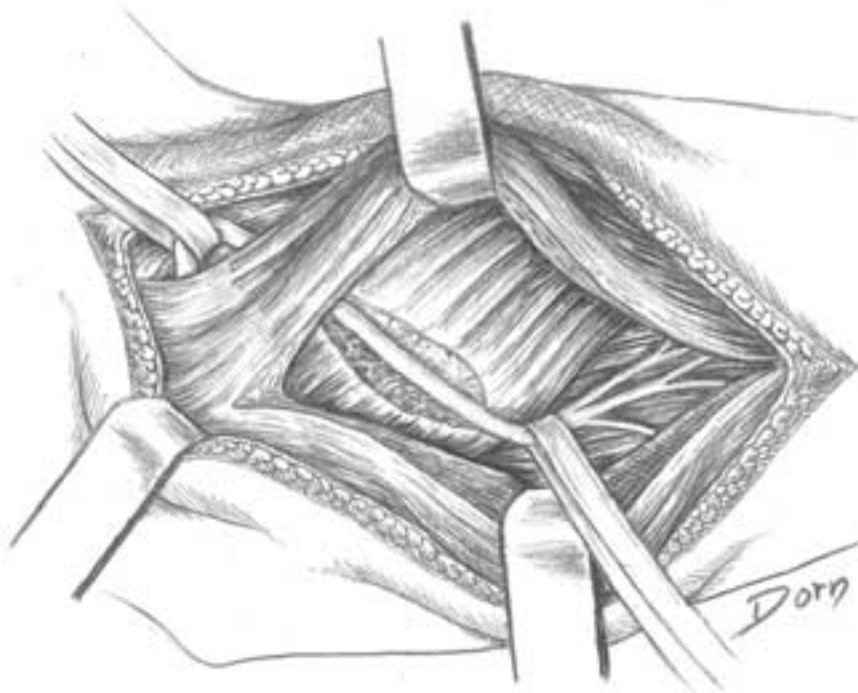
**D**



# Hand and peripheral nerve surgery

---

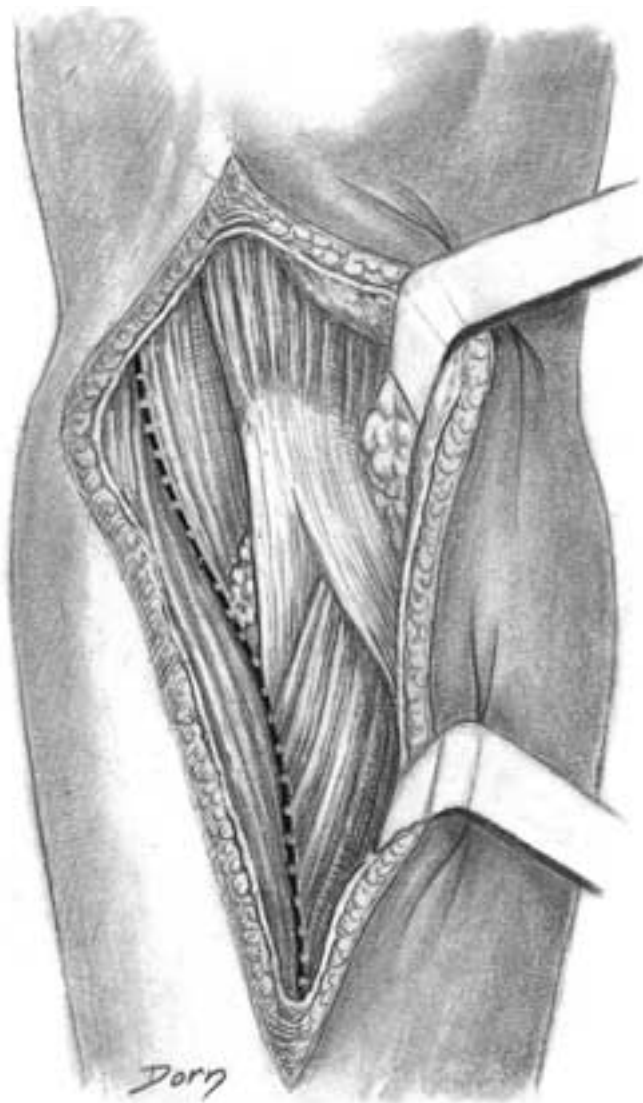**E** Superficial head of the supinator has been severed to release the nerve.



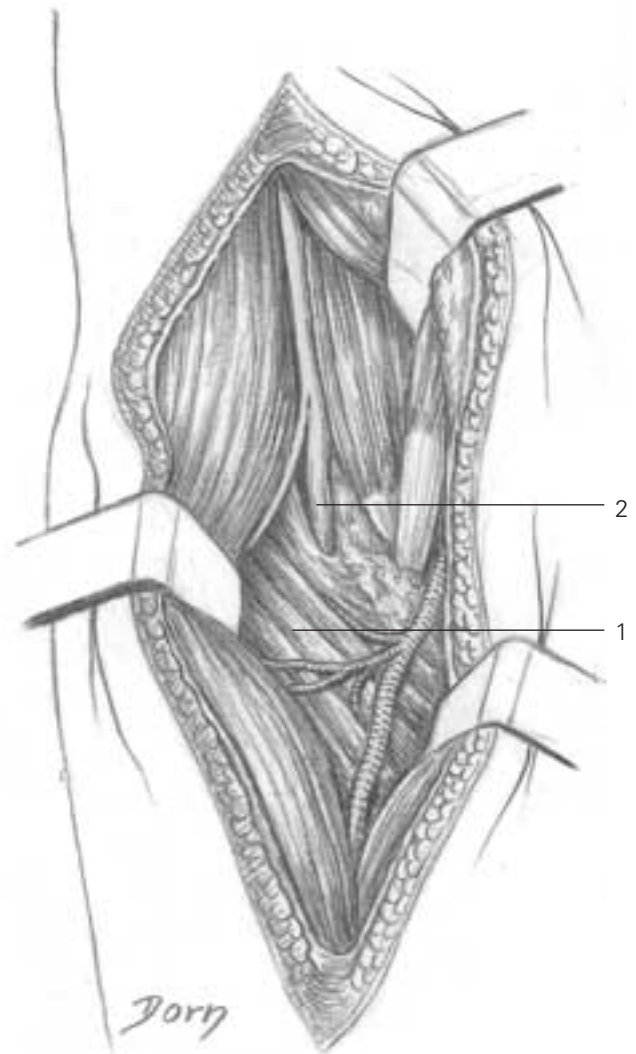
# Surgery of the peripheral nerves

Exposure of the radial nerve at the elbow (common trunk and its division into anterior and posterior branches)

**A** The plane between the brachioradialis and brachialis is developed.



**B** Medially the biceps and the pronator teres muscles are retracted. The radial nerve and its division are exposed. The posterior branch courses beneath the superficial head of the supinator muscle.

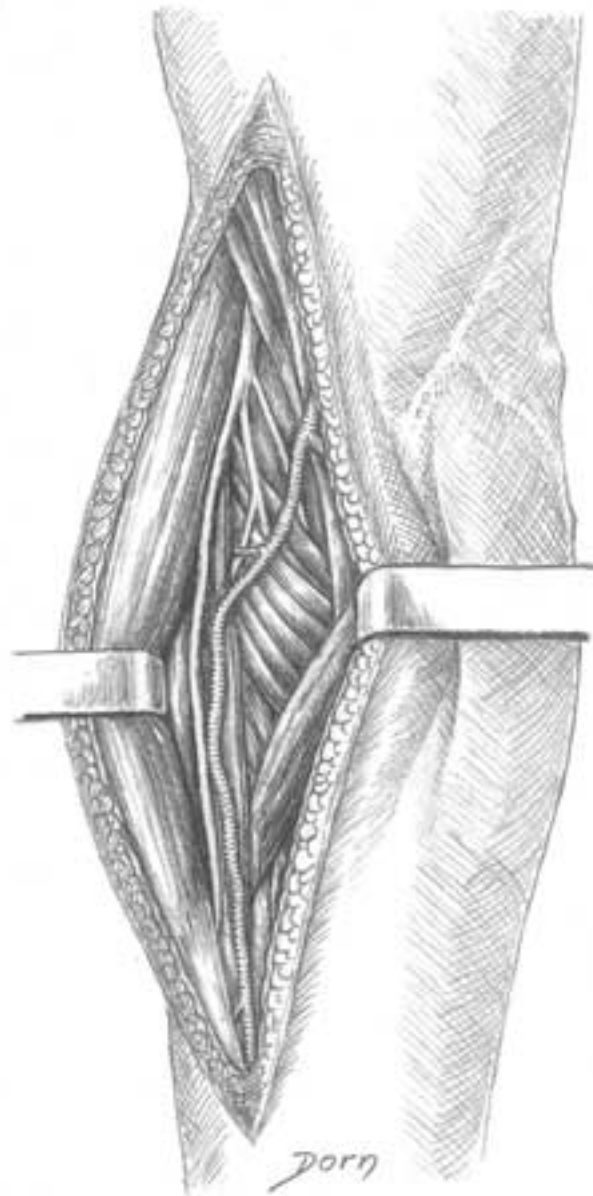


- 1 supinator
- 2 radial nerve

# Hand and peripheral nerve surgery

---

C By reflecting the brachioradialis muscle, the anterior branch is exposed. It courses near the radial artery.



# Gynaecological surgery

Some of these drawings have been made from rough sketches made in the operating theatre. They illustrate the numerous techniques for treating genital prolapse.

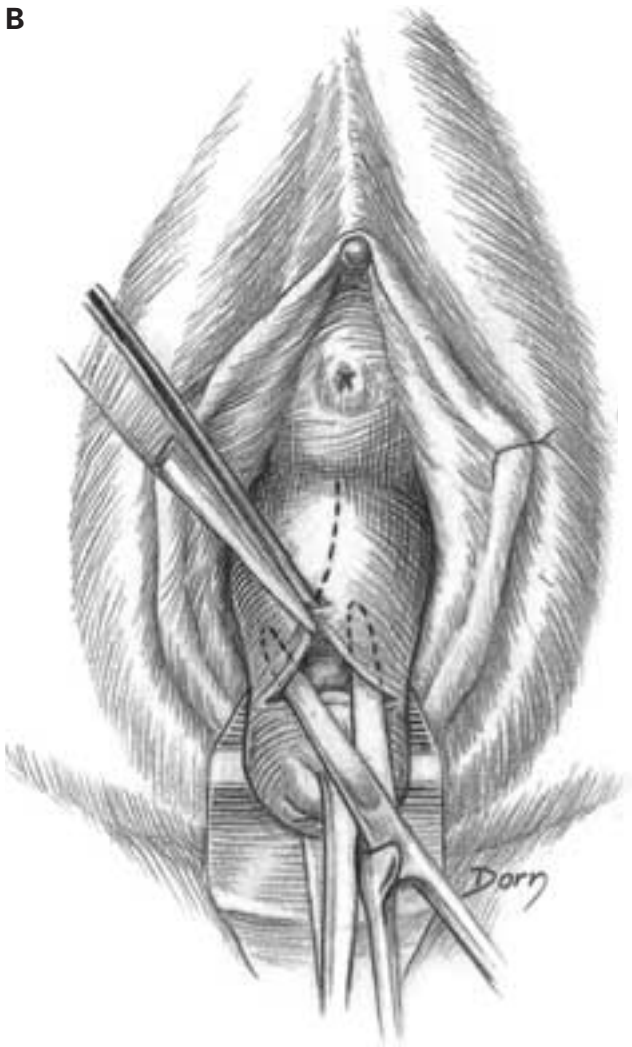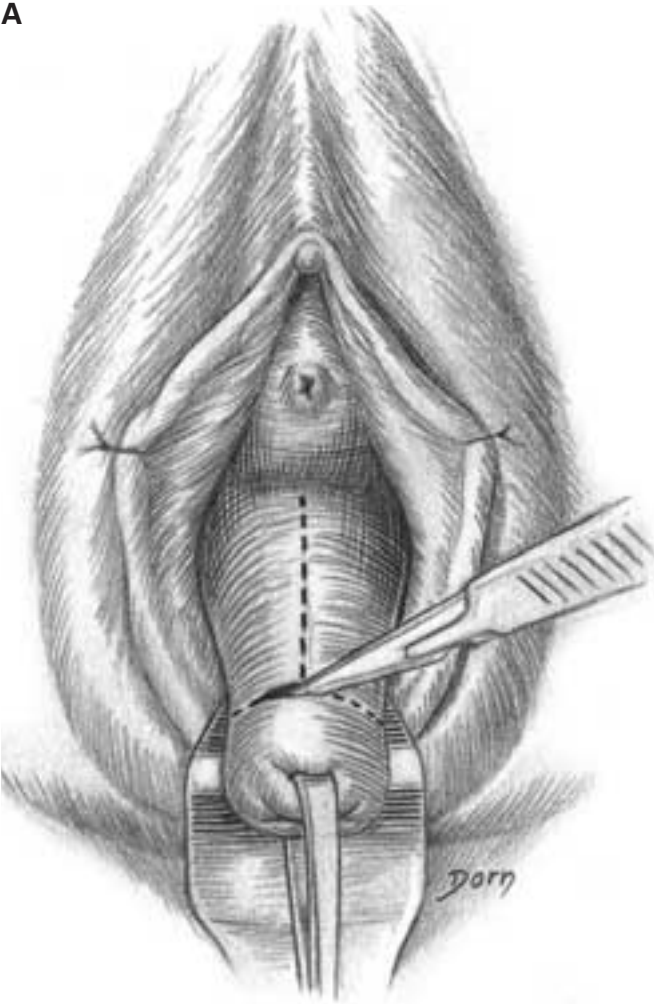


# Gynaecological surgery

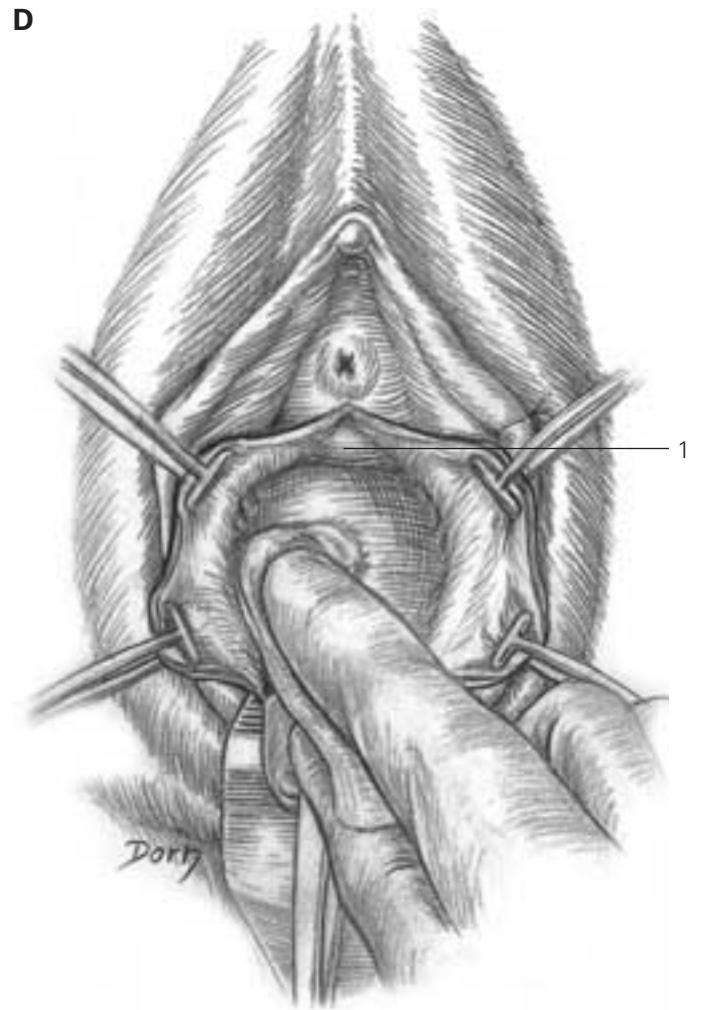
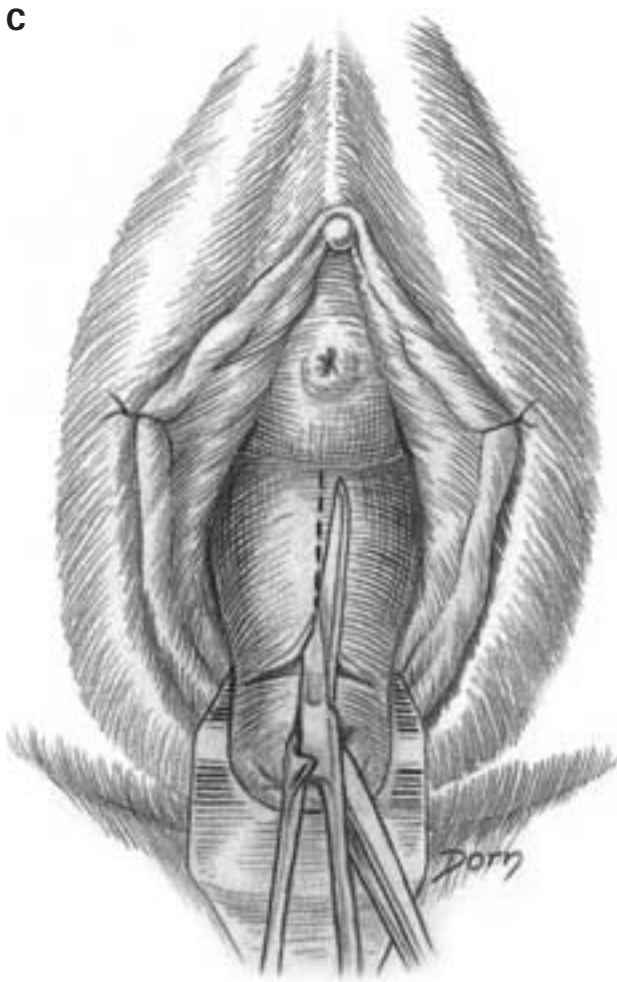
---

The lower approach of the genital prolapse and the separation of the vagina and the bladder

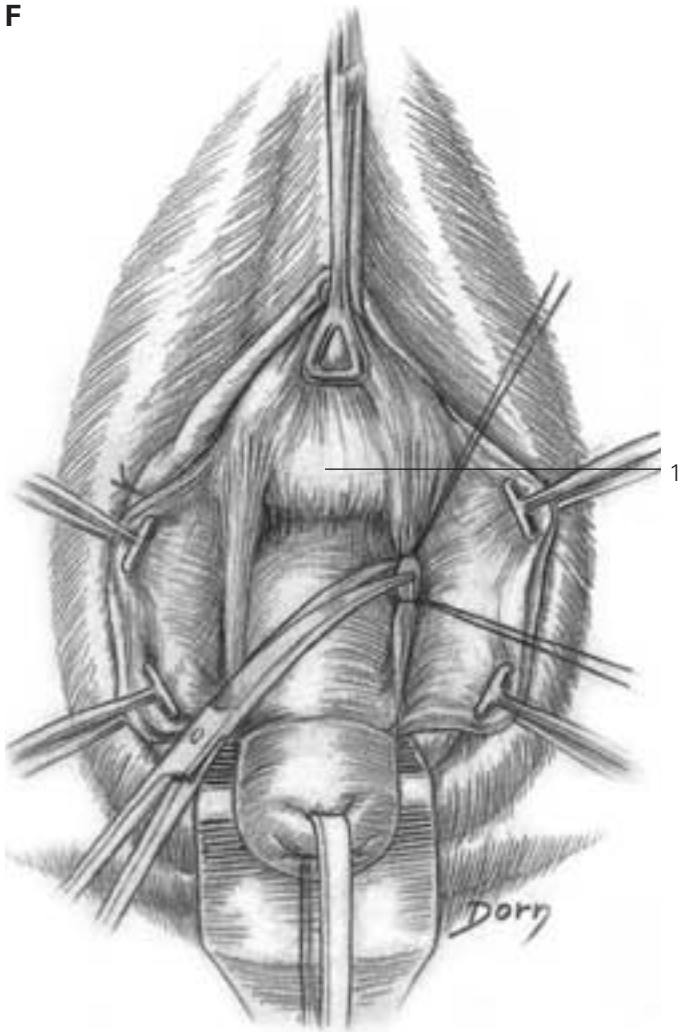
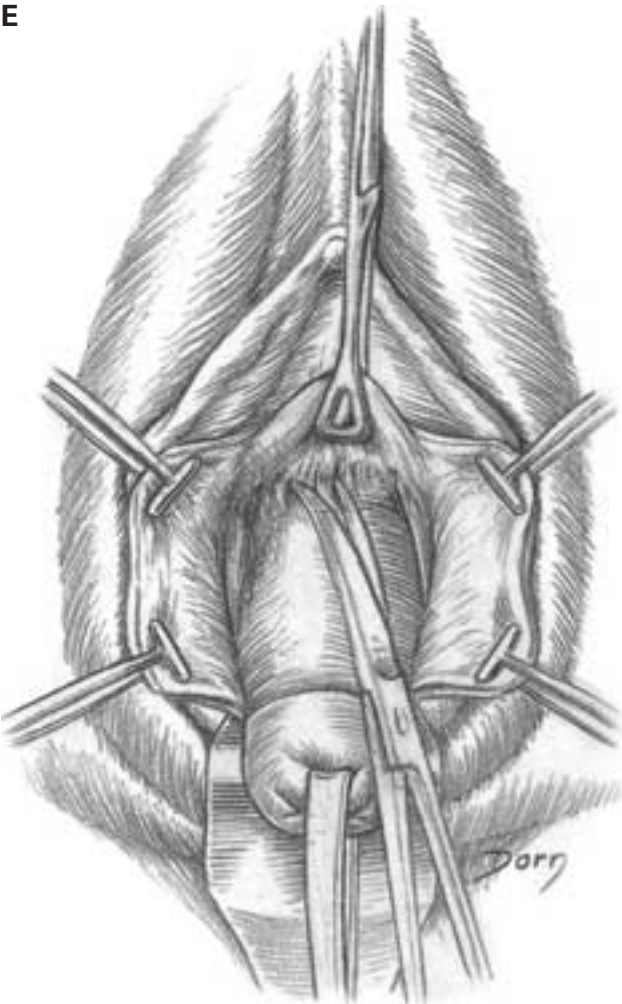
**A–C** The anterior aspect of the vagina is incised and the plane of dissection between the vagina and the bladder is developed.



**D-F** The separation between the vagina and the bladder is pursued; the long forceps holds the bladder.



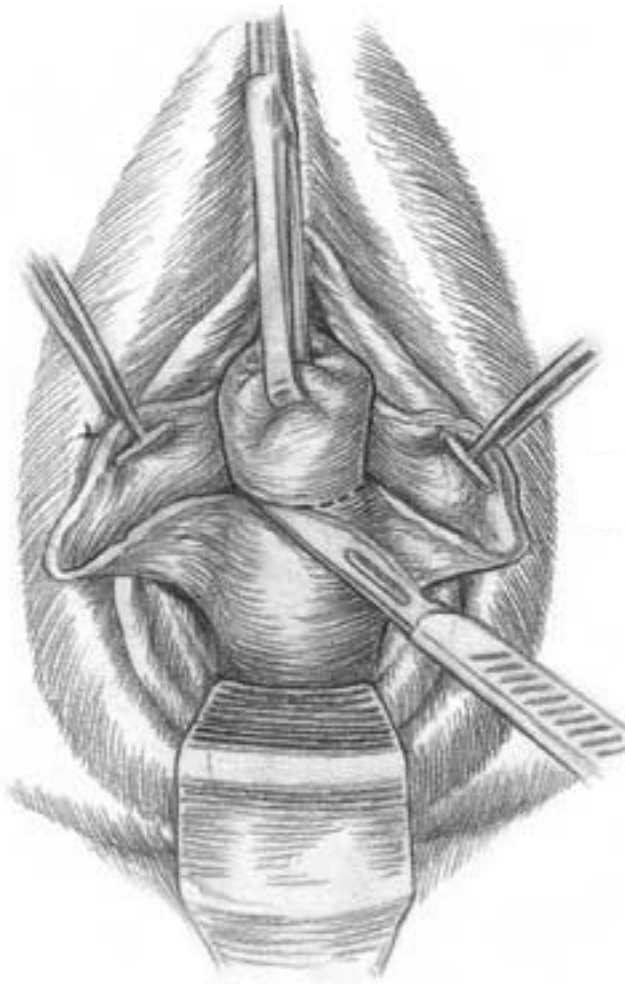
1 bladder



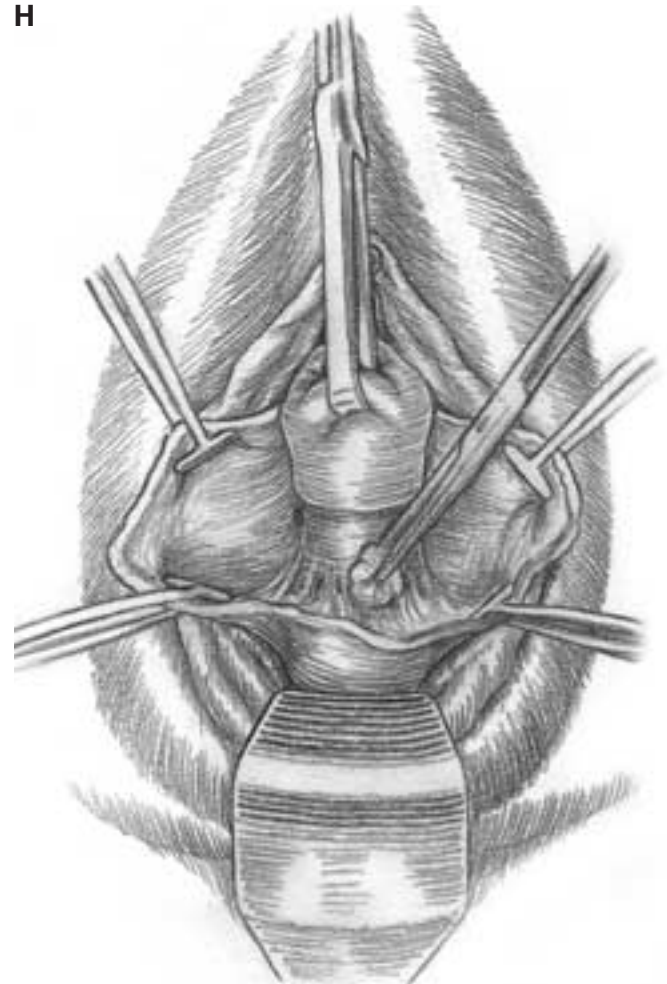
1 bladder

**G, H** Separation of the posterior aspect of the vagina.

**G**

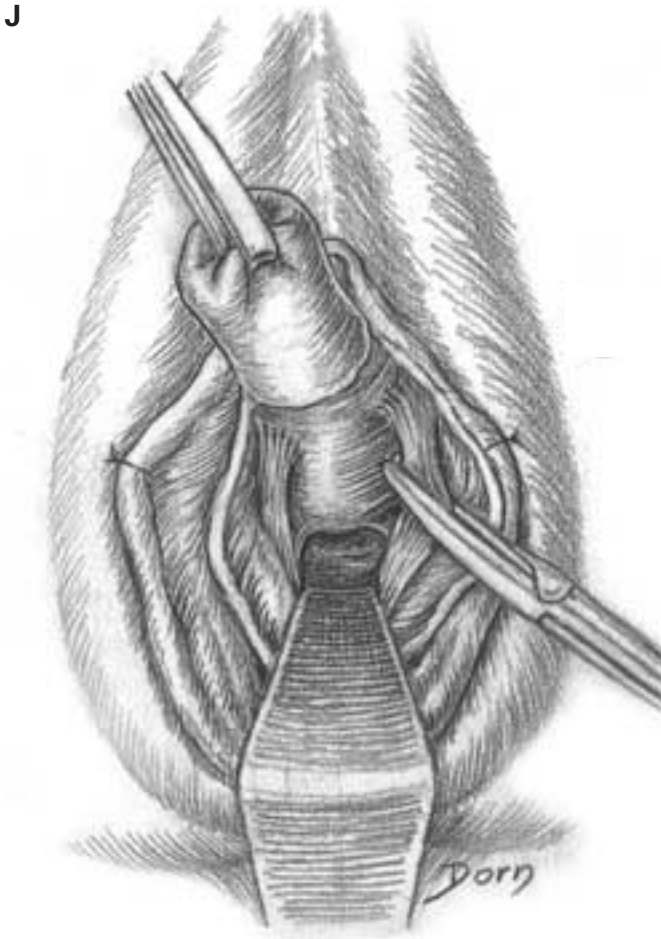
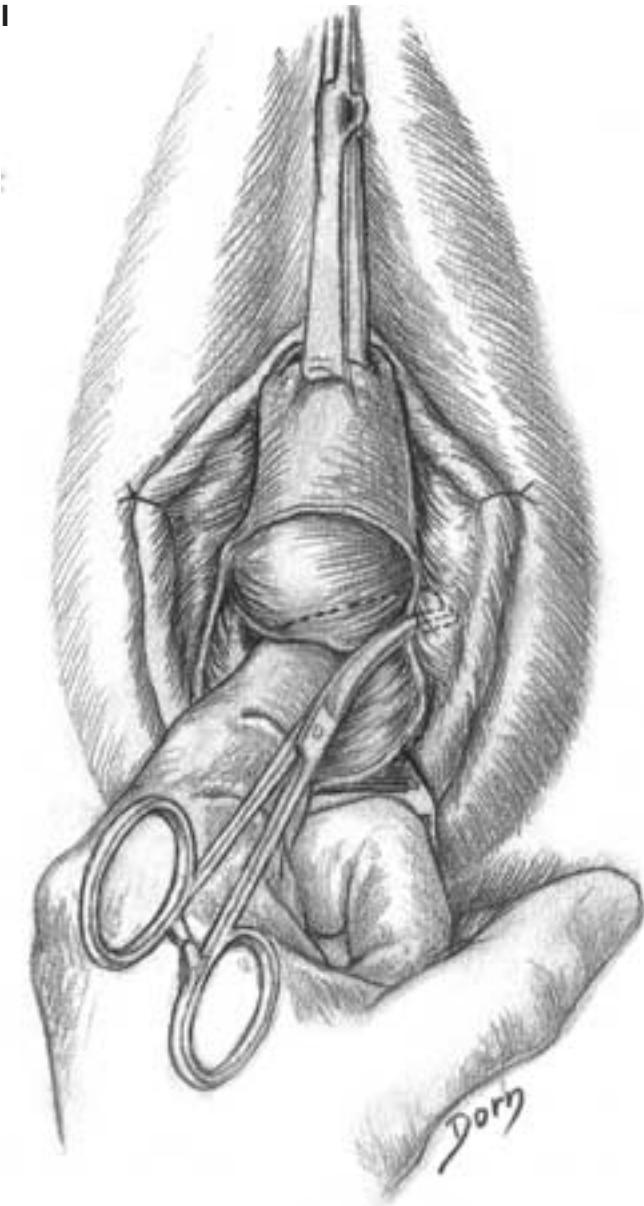

**H**



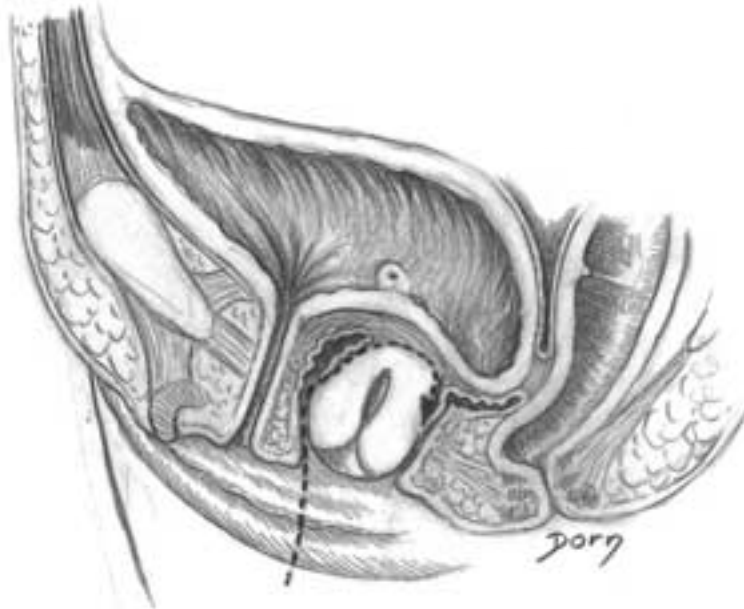
# Gynaecological surgery

I, J The cul-de-sac of Douglas is opened and the uterosacral ligaments are ligated and cut.

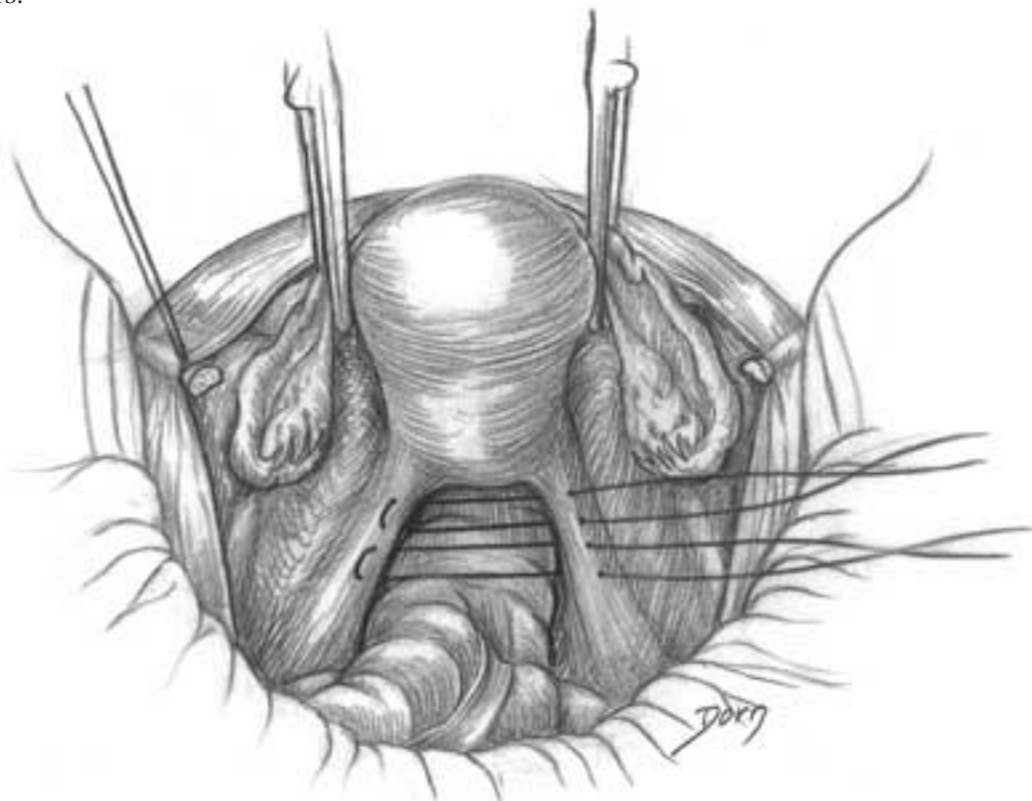


Treatment of genital prolapse after hysterectomy

**A** In this procedure care should be taken of the bladder which can overlap behind the cervix of the uterus (after a hysterectomy).



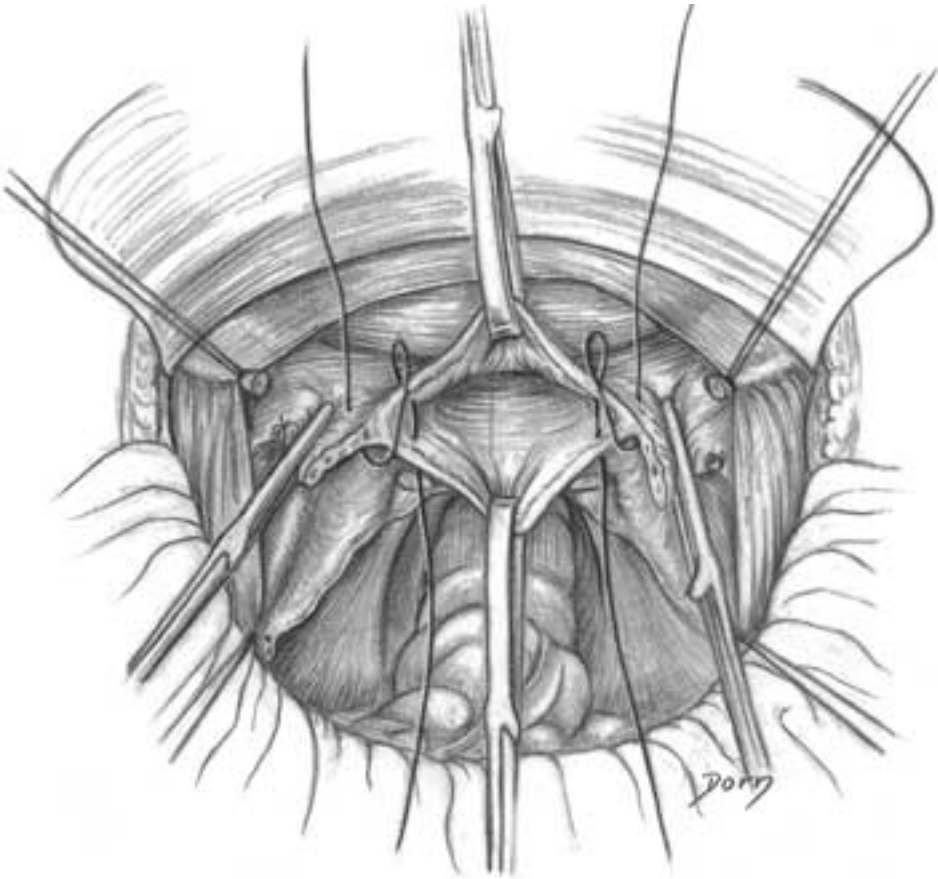
**B** Just before the hysterectomy, the threads are passed through the uterosacral ligaments, taking care of the ureters.



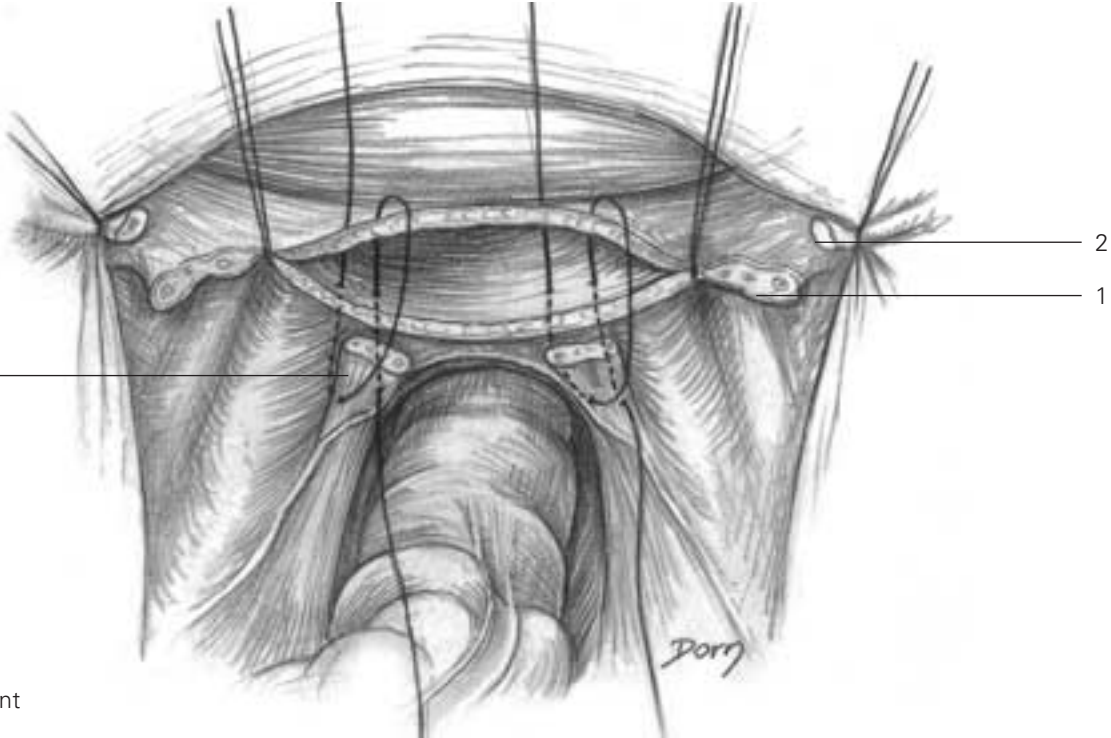
# Gynaecological surgery

C-E The hysterectomy is completed by an upper approach.

C

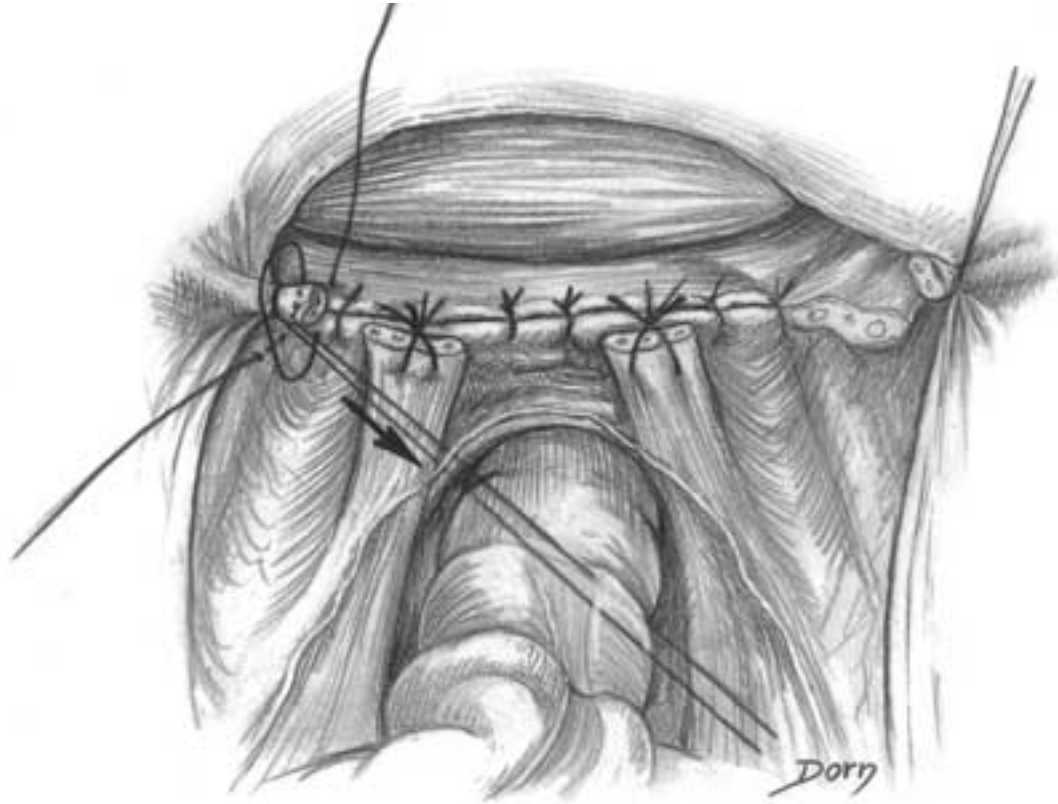


D

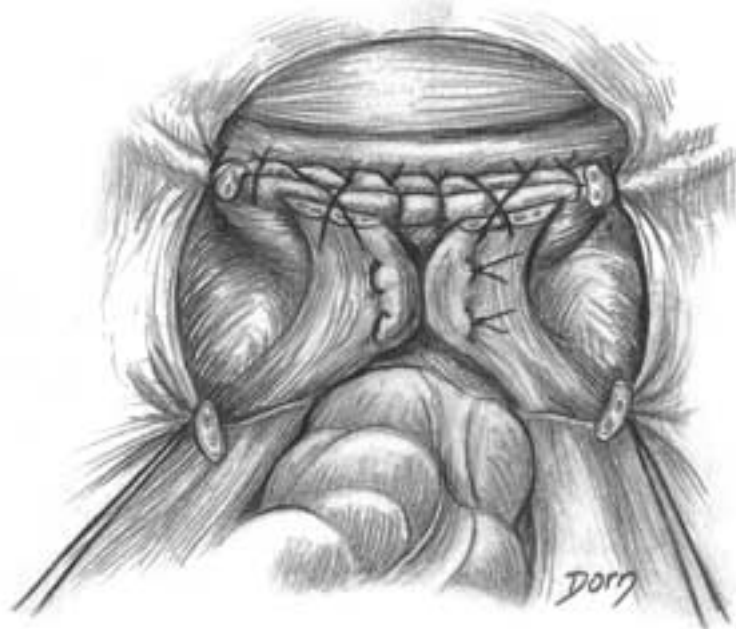

- 1 cardinal ligament
- 2 round ligament
- 3 uterosacral ligament

E



F The vagina is sutured and the uterosacral ligaments are sutured to the vagina.



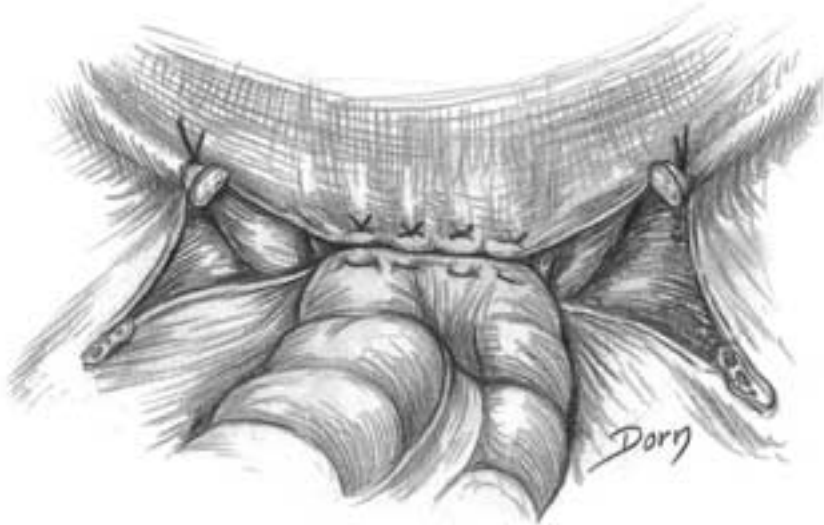


# Gynaecological surgery

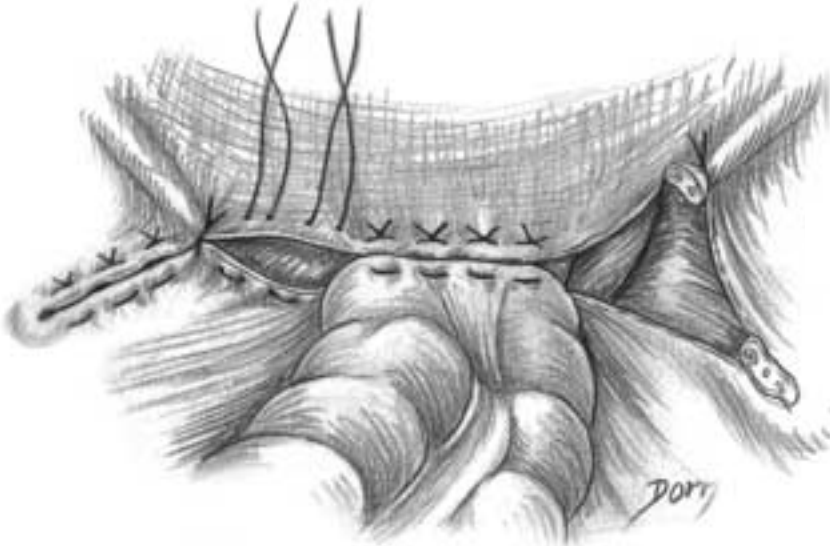
---

**G-J** The closure of the cul-de-sac of Douglas to prevent an ehytrocele.

**G**

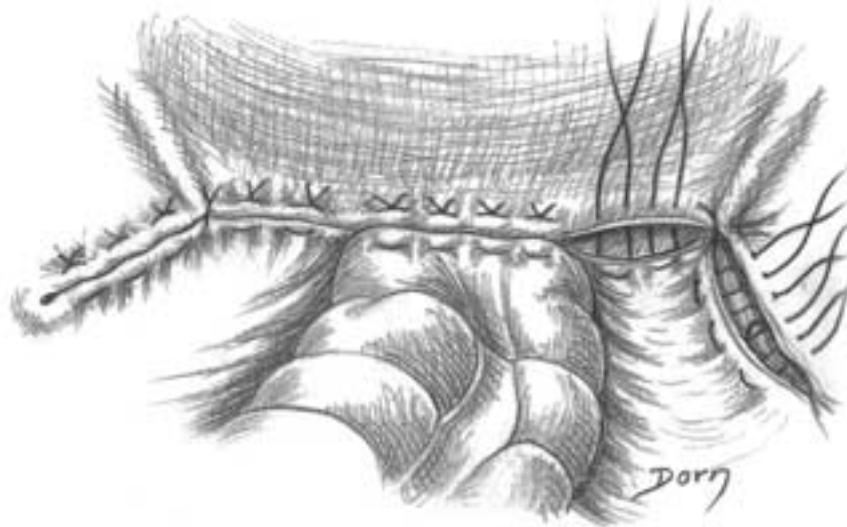


**H**

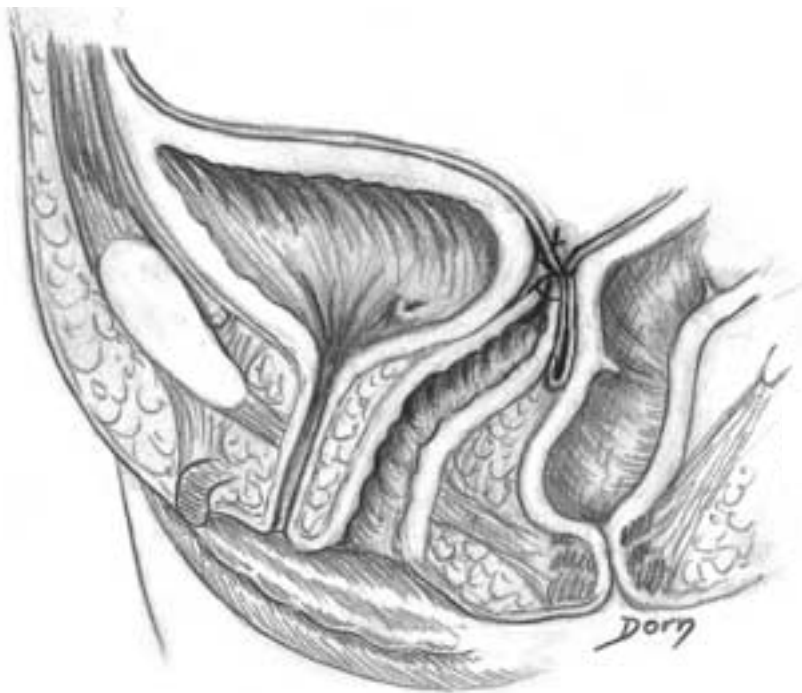


The perineum is sutured.

I



J

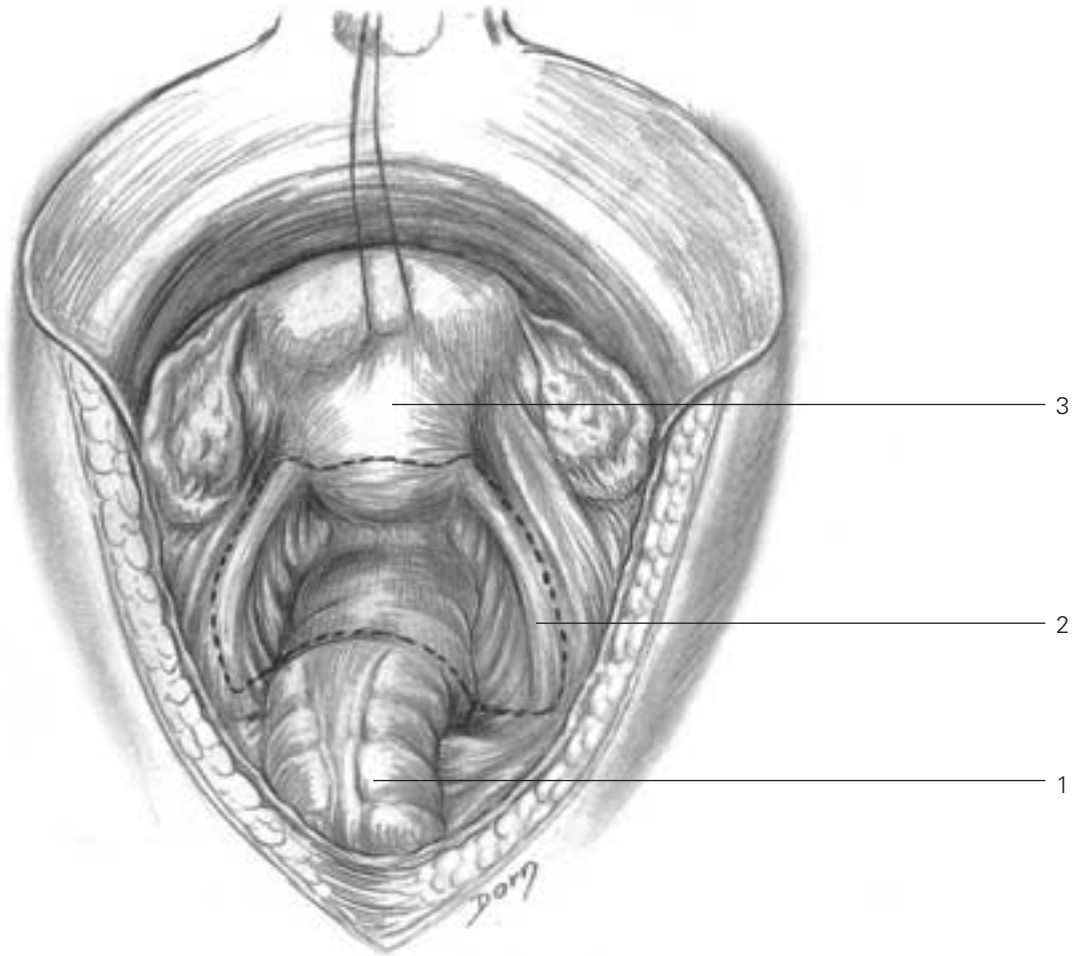


# Gynaecological surgery

## Surgical treatment of the elythrocele

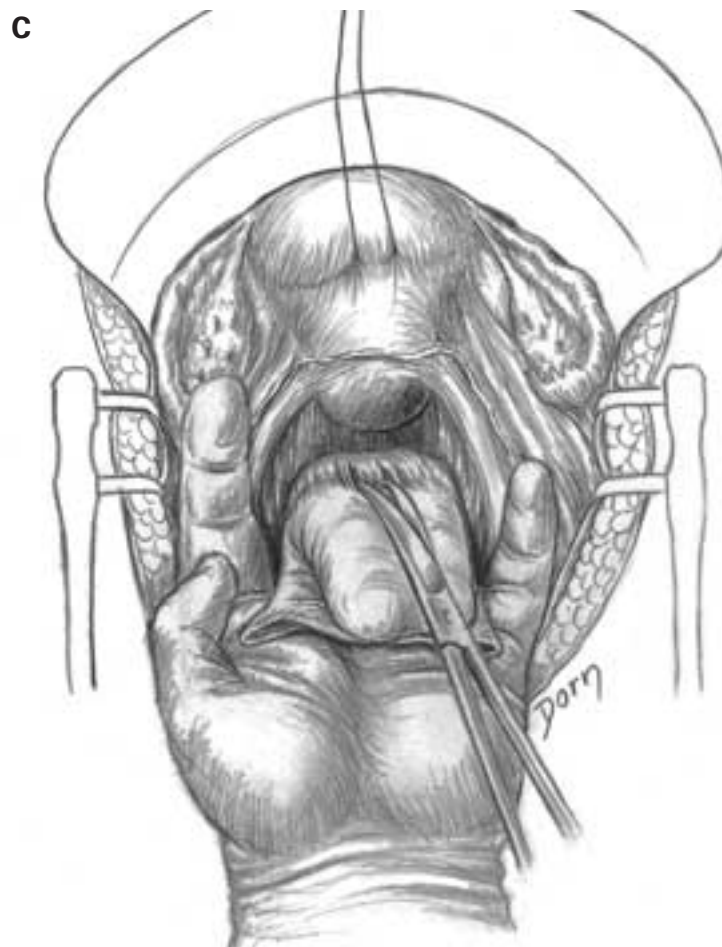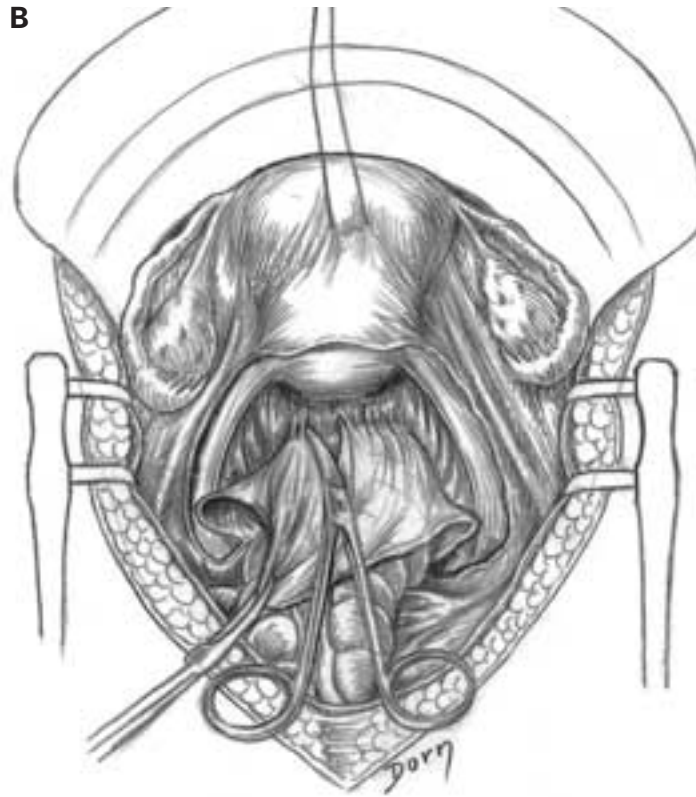
The elythrocele is the interposition of the cul-de-sac of Douglas between the vagina and the rectum. The surgery is performed by the abdominal approach.

**A** The uterus is held by threads; the dotted line is the landmark for the dissection. Care should be taken to spare the ureters.

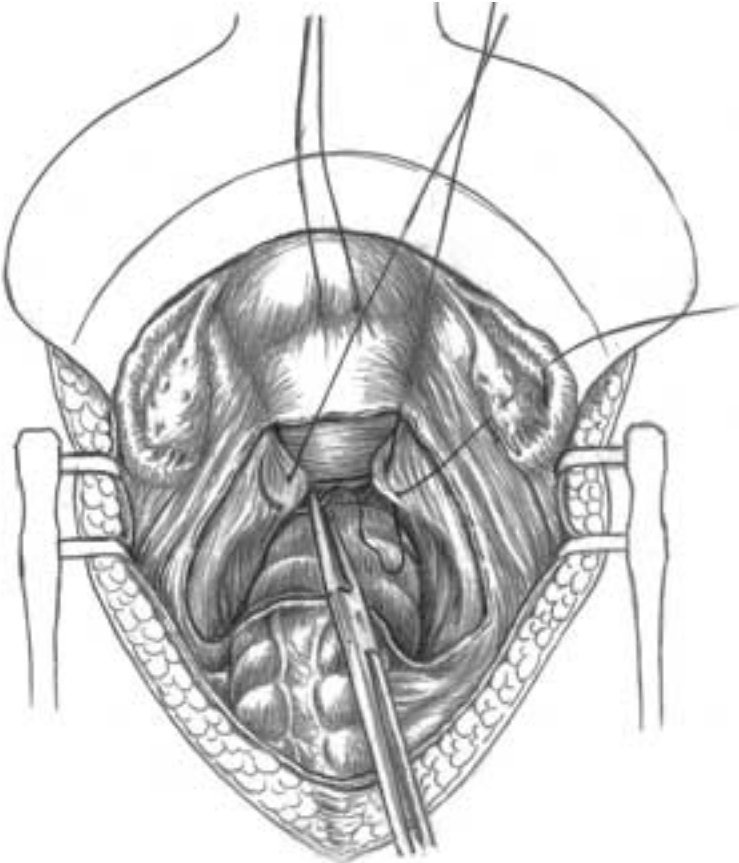


- 1 rectum
- 2 uterosacral ligament
- 3 uterus

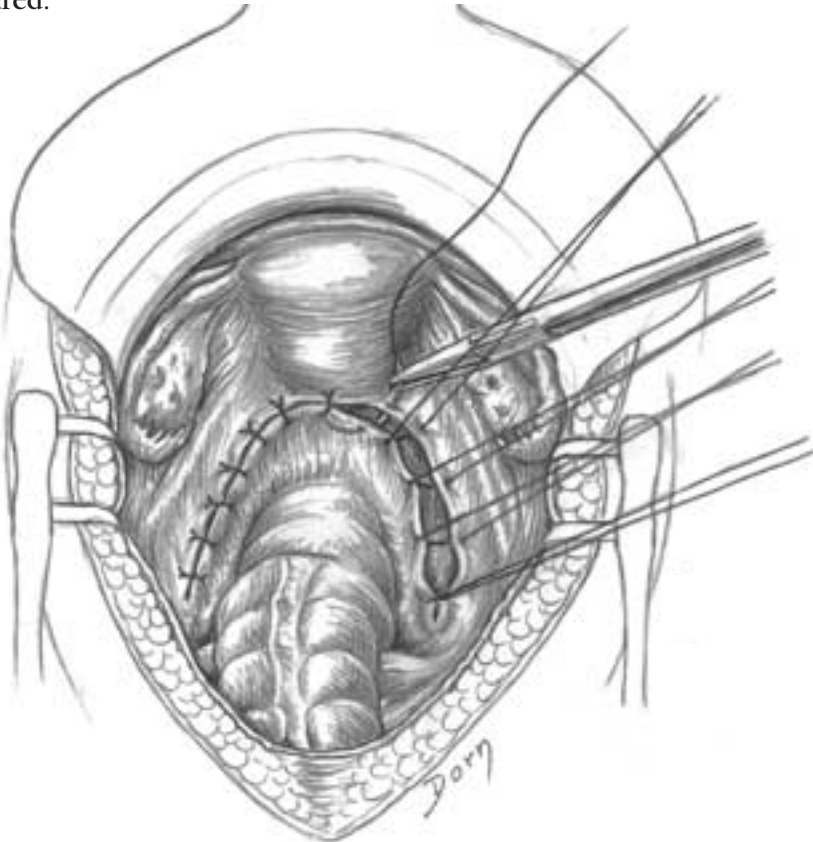
**B, C** The plane of dissection is developed between the posterior aspect of the uterus and the rectum.



D The uterosacral ligaments are sutured together.



E The peritoneum is sutured.



# Urological surgery

Urology is a surgical specialty covering a large number of indications and procedures.

Transplantation of the kidney was the first successful allotransplantation to be performed a short time after the Second World War. This extraordinary achievement marked the start of the modern era of organ transplantation aided by the

advances in immunology. Urology is also concerned with reconstructive procedures involving loss of substance irrespective of the aetiology: tumour, congenital, traumatic, etc.

The last section of this chapter covers surgery of the sexual organs in sex modification.

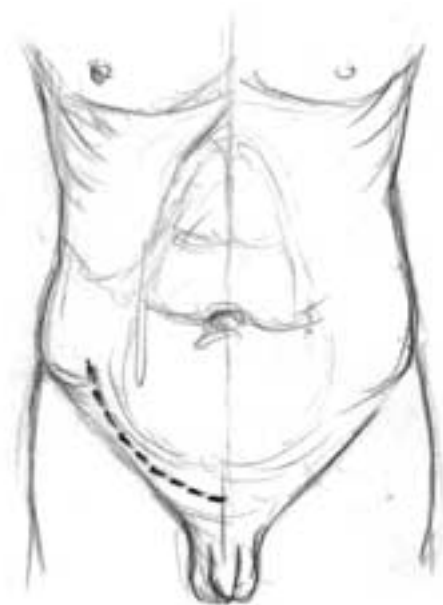
# Urological surgery

---

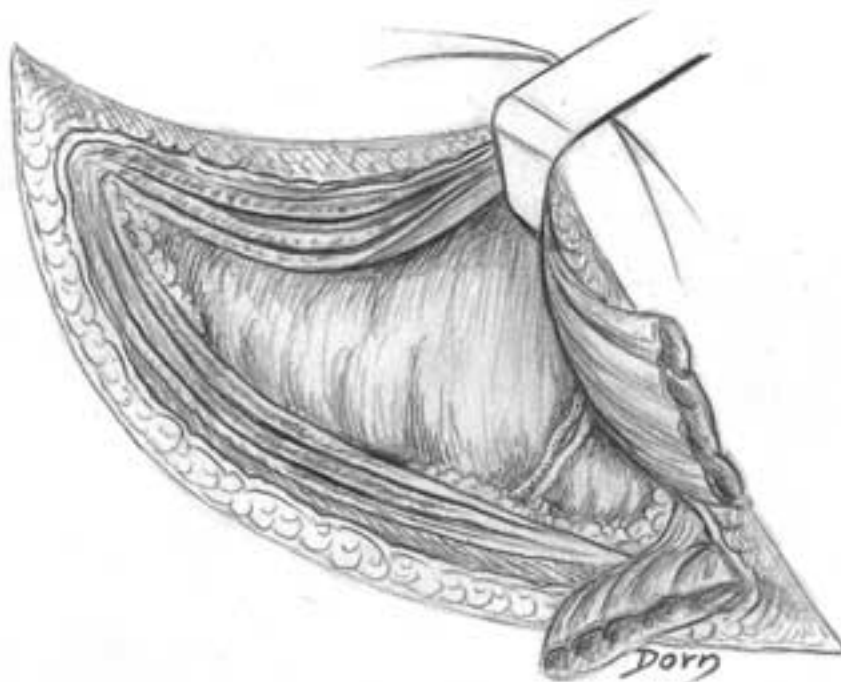
## Allotransplantation of the kidney

The various steps are shown in the drawings: surgical approach, preparation of the vessels and vascular anastomoses.

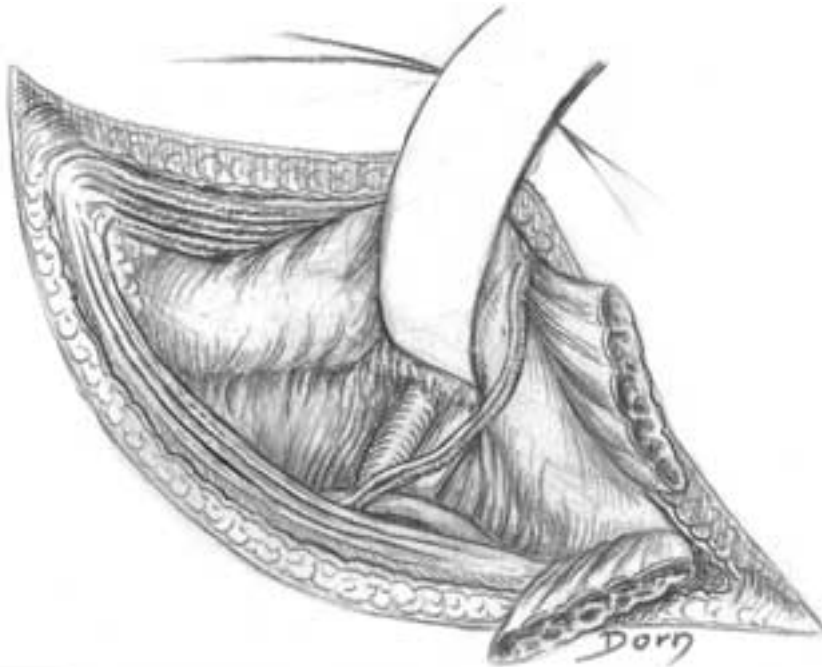**A** Skin incision.



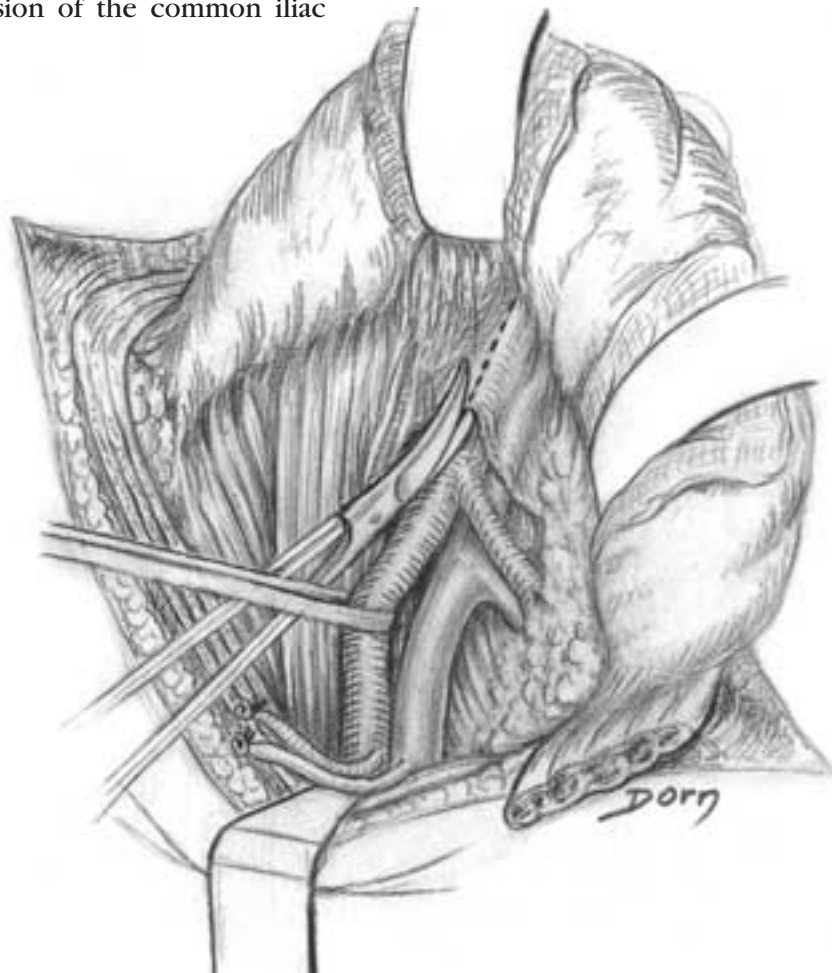
**B** The abdominal muscular wall is incised.



**C** The peritoneum is retracted which allows the dissection of the internal iliac vessels.

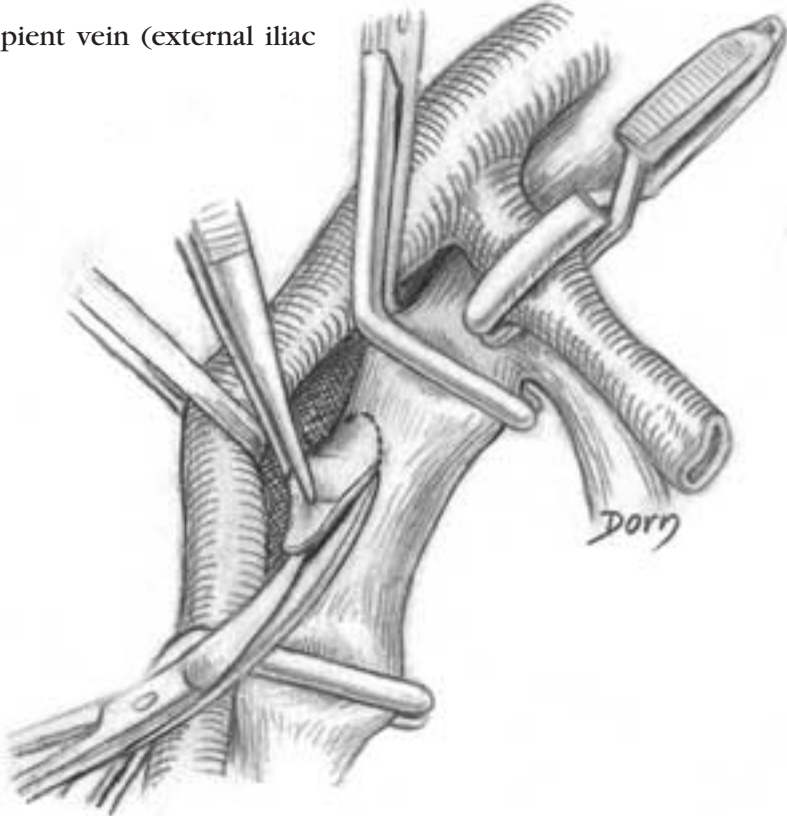


**D** Exposure of the division of the common iliac artery.

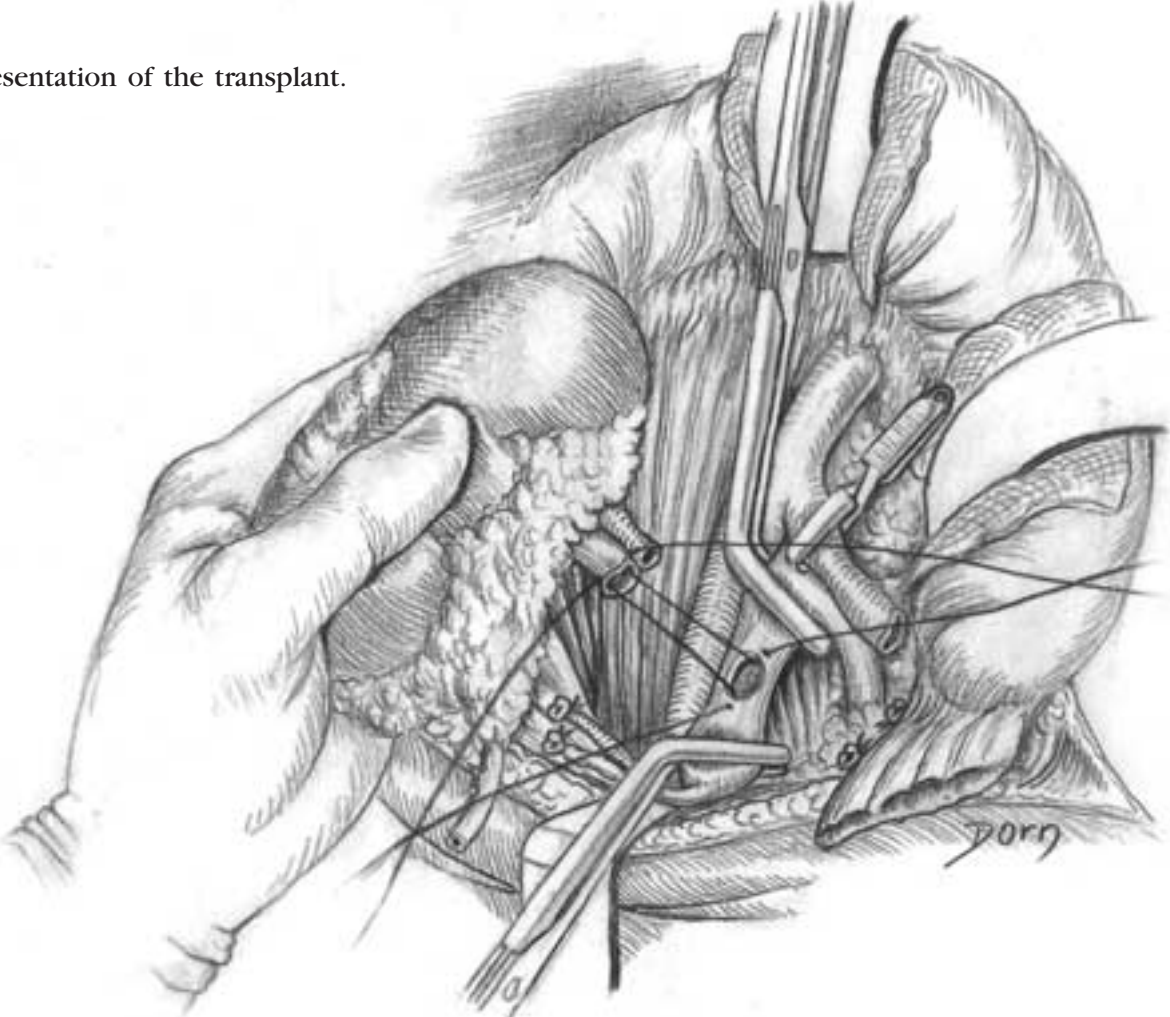




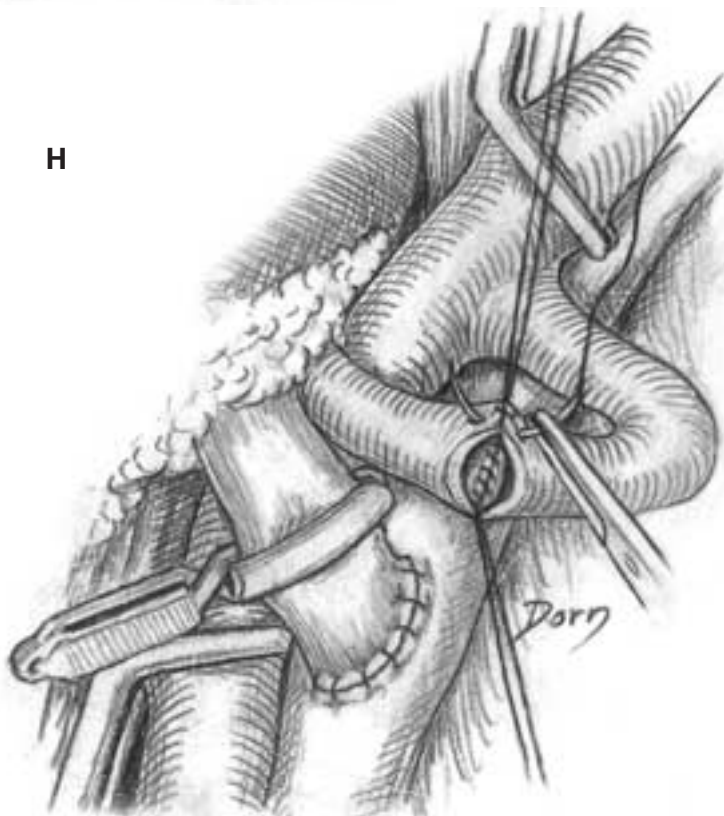
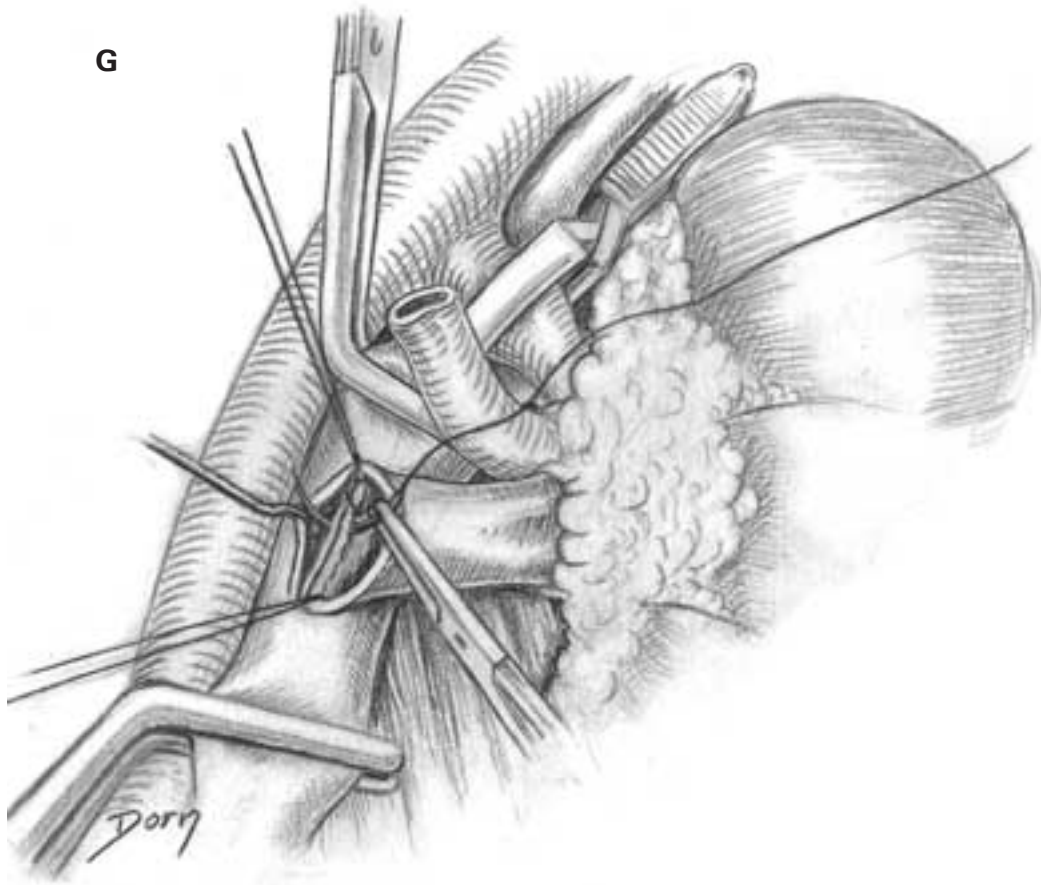
E Preparation of the recipient vein (external iliac vein).



F Presentation of the transplant.



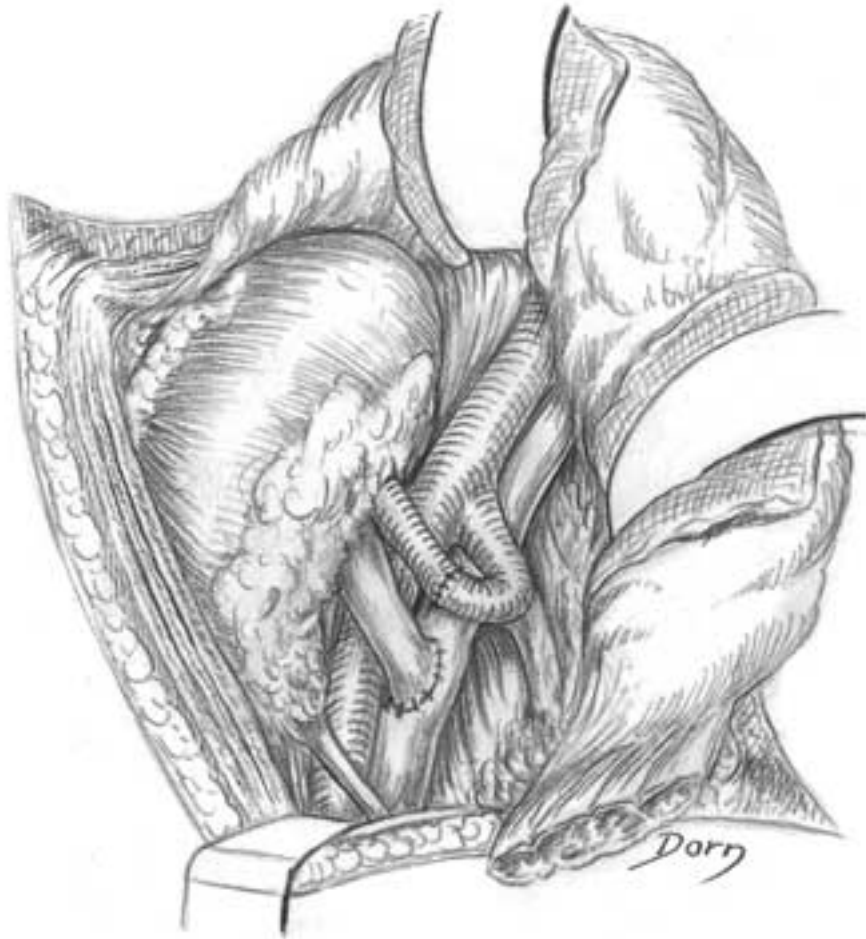
**G, H** Suturing the vessels. The first to be done is the anastomosis of the veins.



# Urological surgery

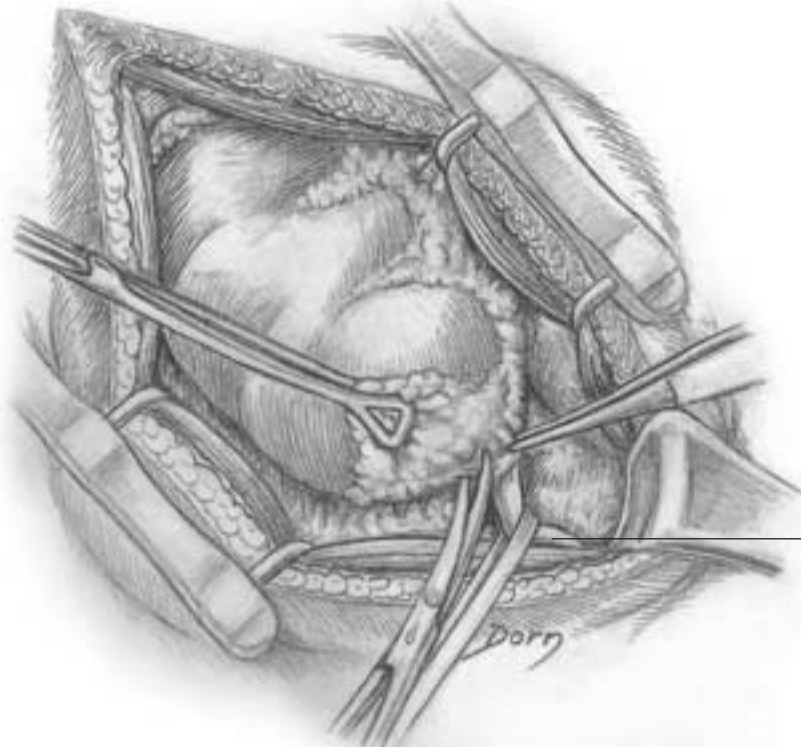
---

I The final aspect of the vascular sutures. Then the ureter is reimplanted in the bladder.



Surgery of renal lithiasis

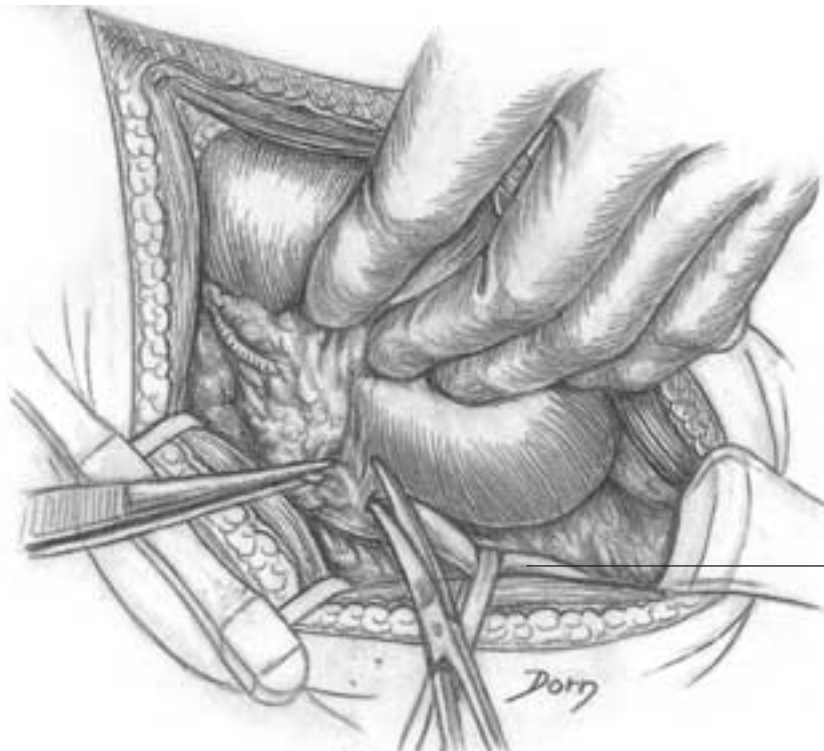
**A** The compartment of the kidney has been opened. The ureter is identified.



1

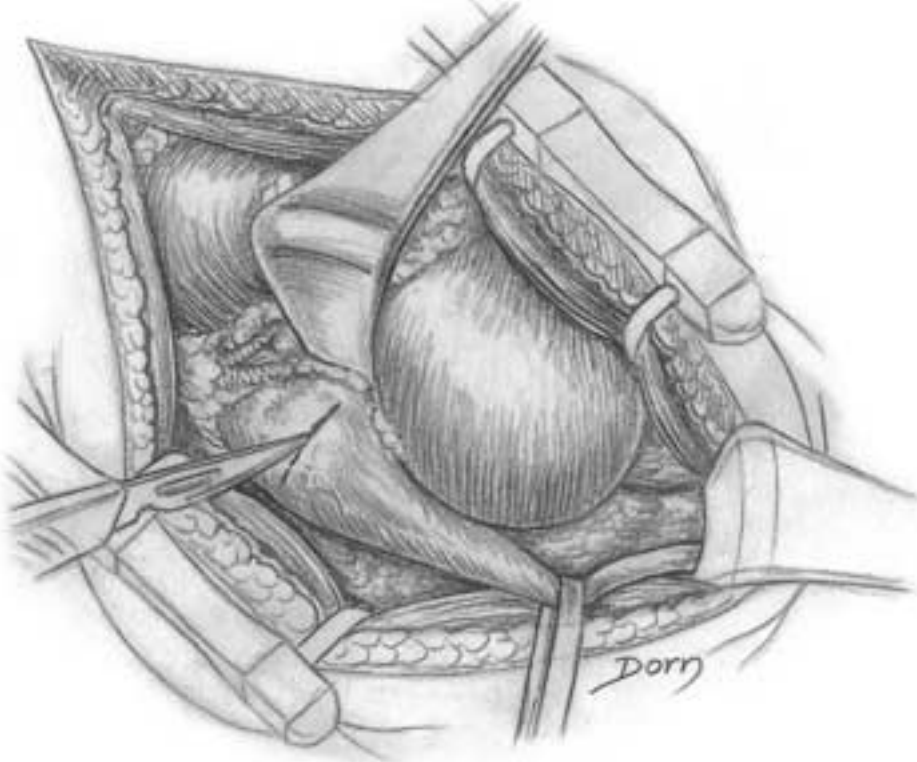
**B** Dissection of the ureter allows access to the renal pelvis.

1 ureter

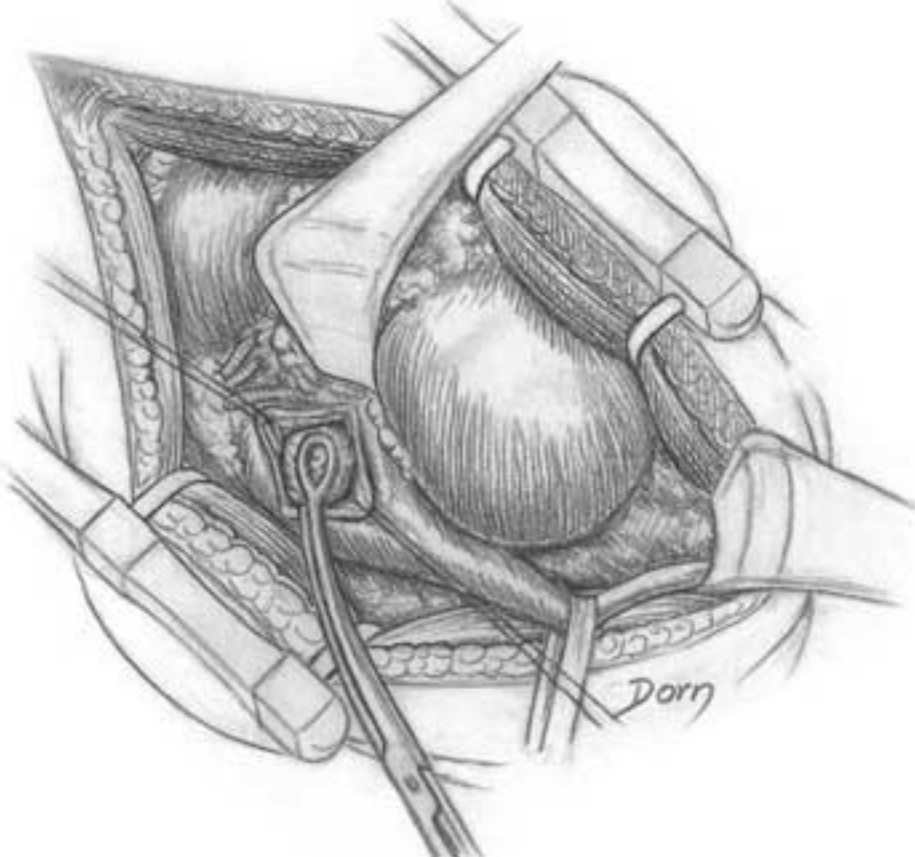


1

C Incision of the renal pelvis.

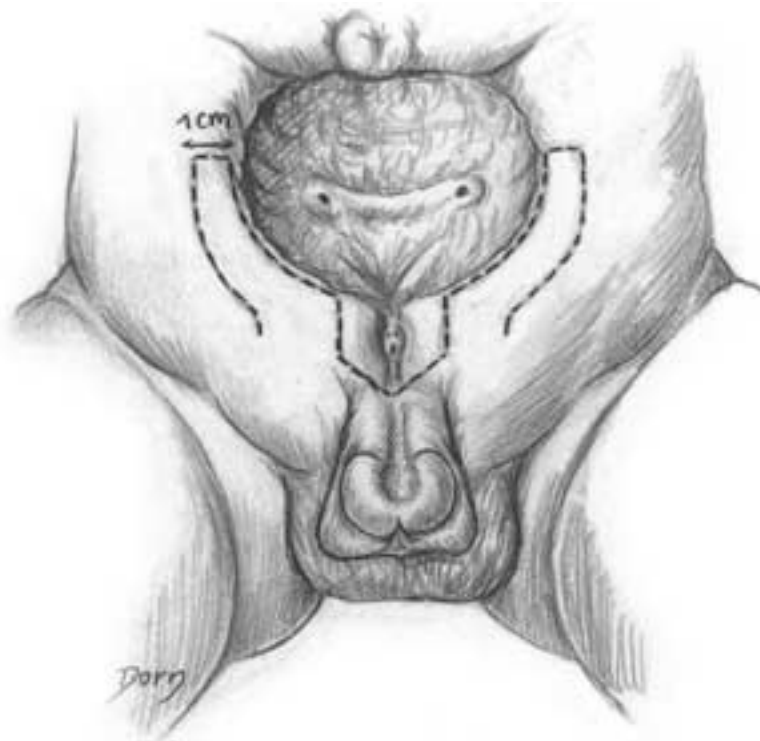


D Removing the lithiasis.

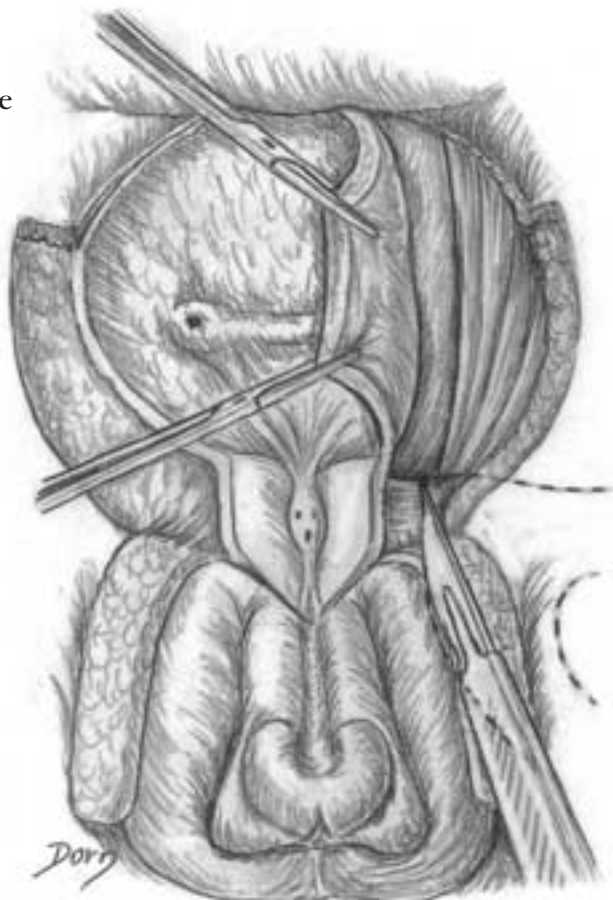

Extrophy of the bladder in a young boy

**A** The incisions. Two skin flaps are delineated.

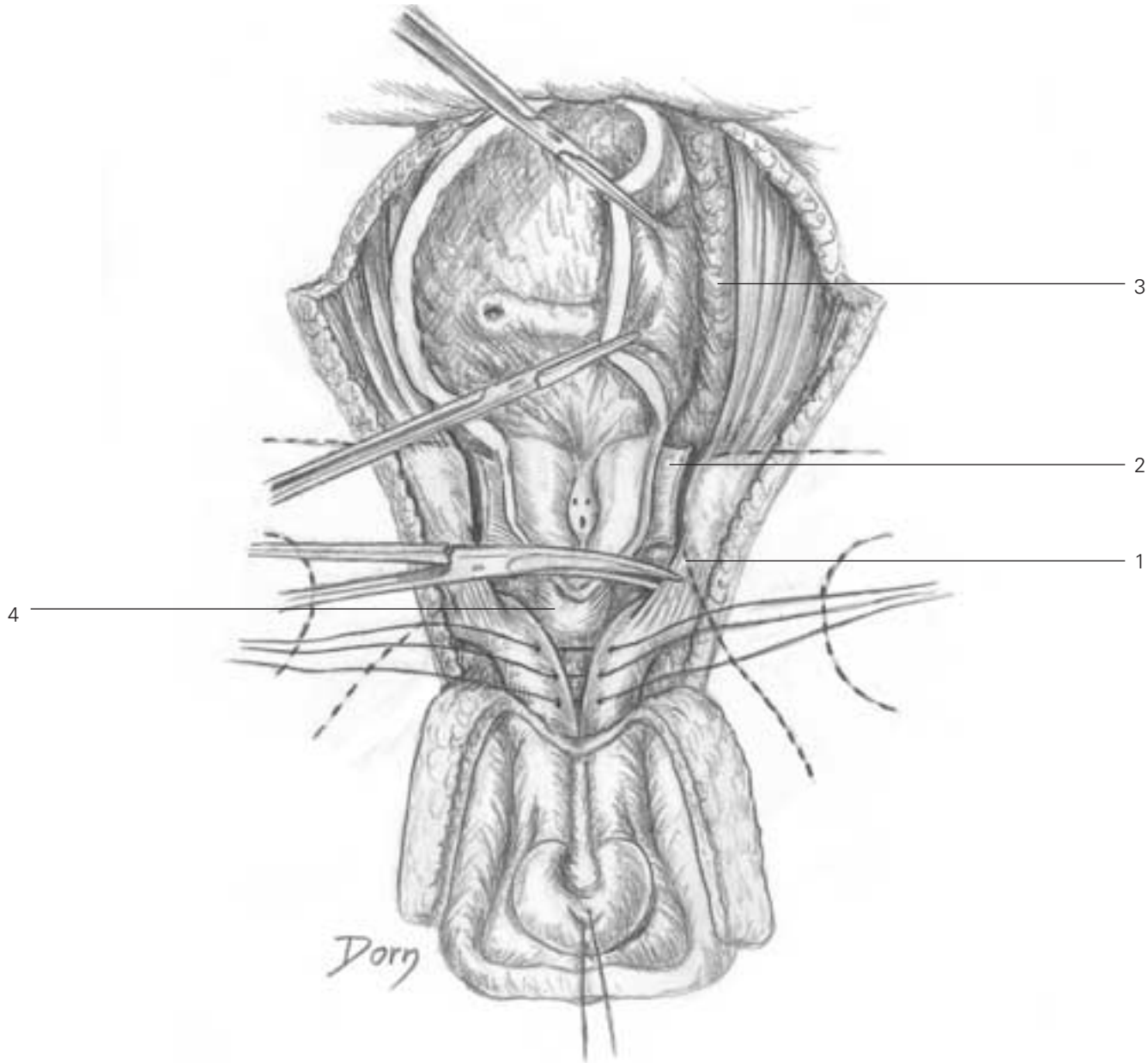


**B** The lateral aspects of the bladder are released.



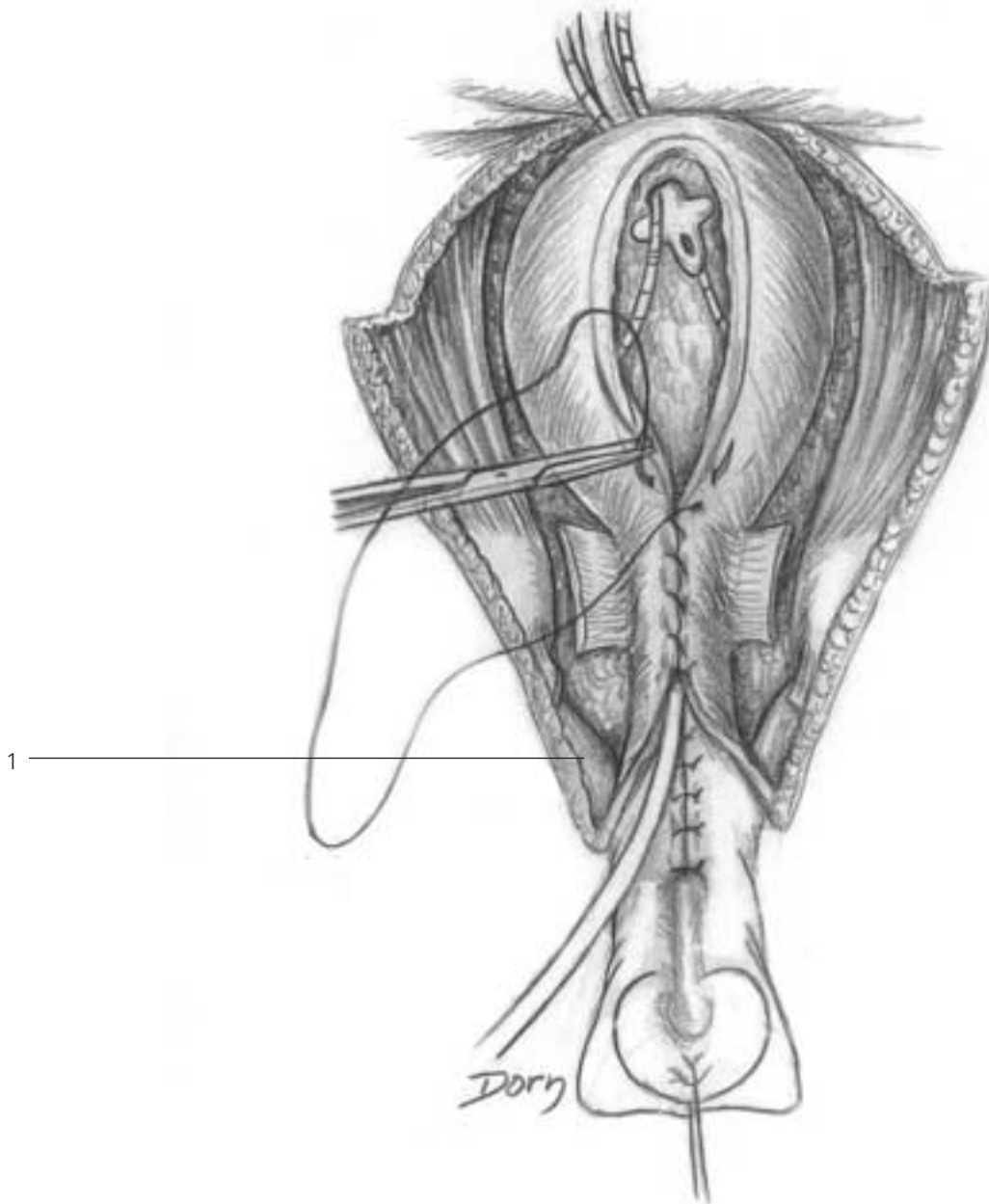
# Urological surgery

C The penis is lengthened. The ischiocavernosus muscles are released.



- C**
- 1 ischiocavernosus muscle
  - 2 transverse perineal ligament
  - 3 release of the posterior aspect of the bladder
  - 4 bulbospongiosus

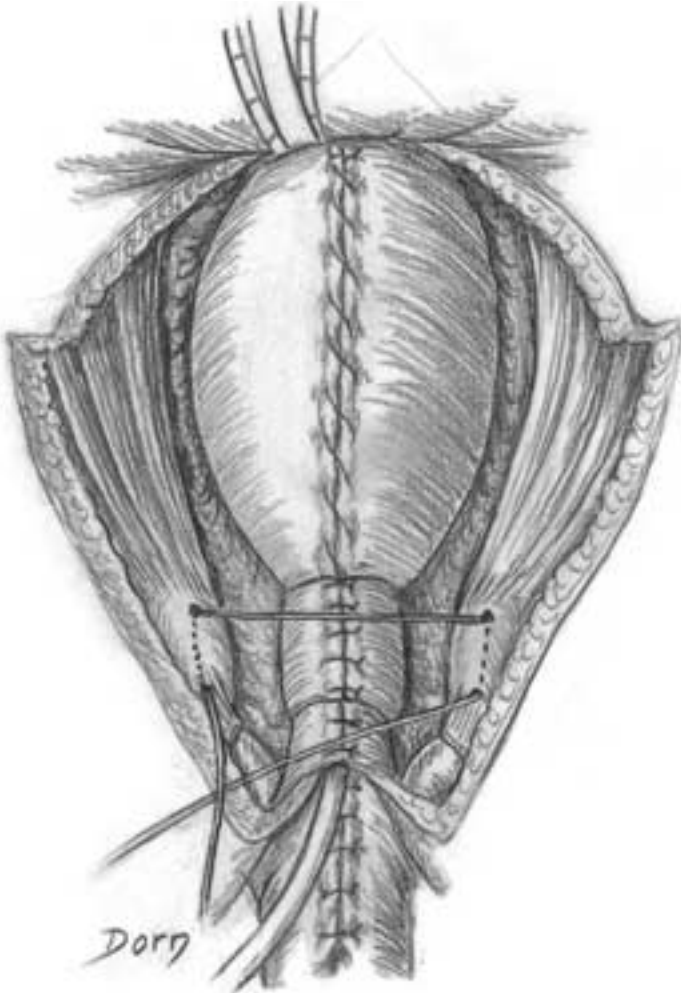
**D** The urethra is lengthened by joining the two skin flaps and the bladder is sutured.



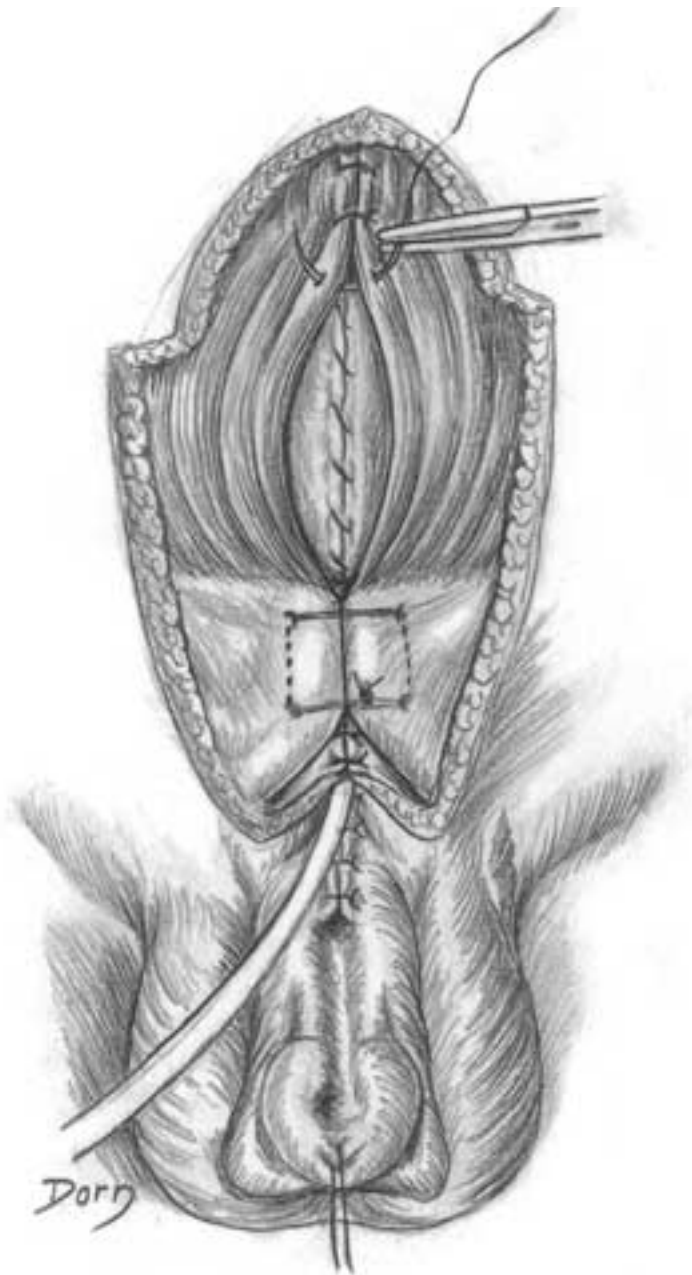
**D**  
1 corpus cavernosus



E Closure of the bone frame.



F Closure of the muscular wall.



# Urological surgery

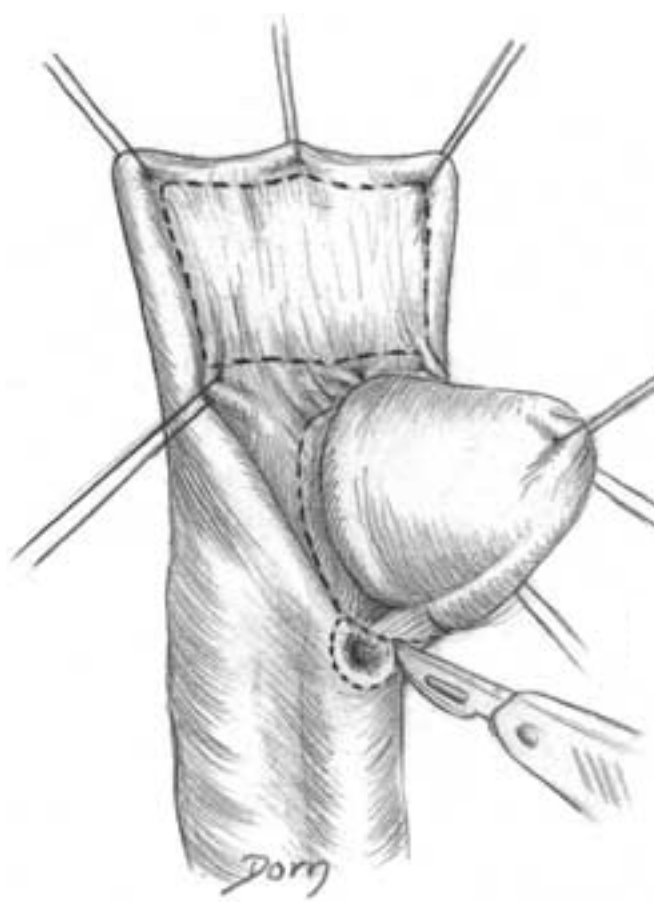
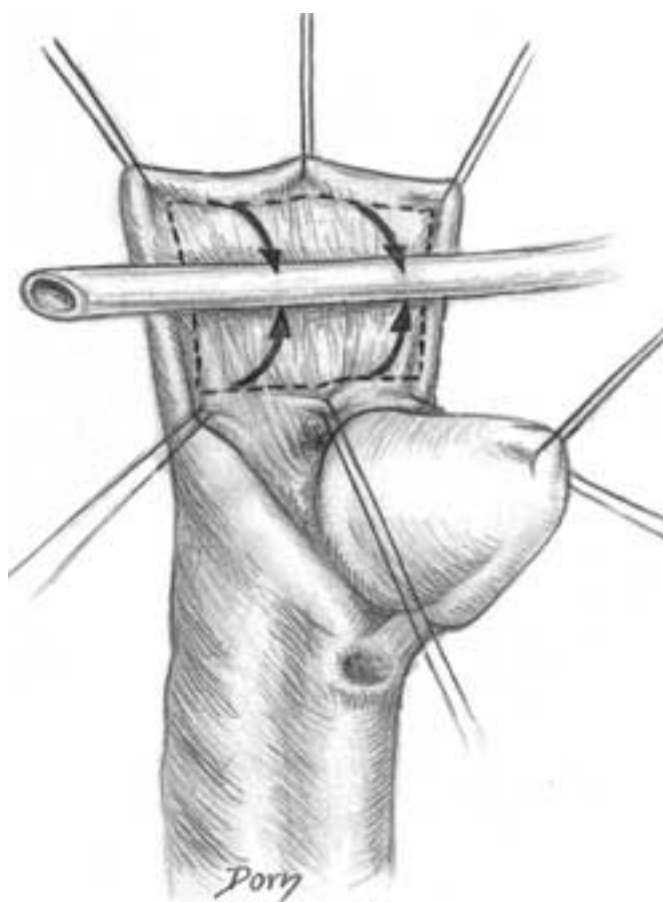
## Hypospadias surgery

Hypospadias is a congenital malformation in which the external urethral meatus is not contained in the glans penis.

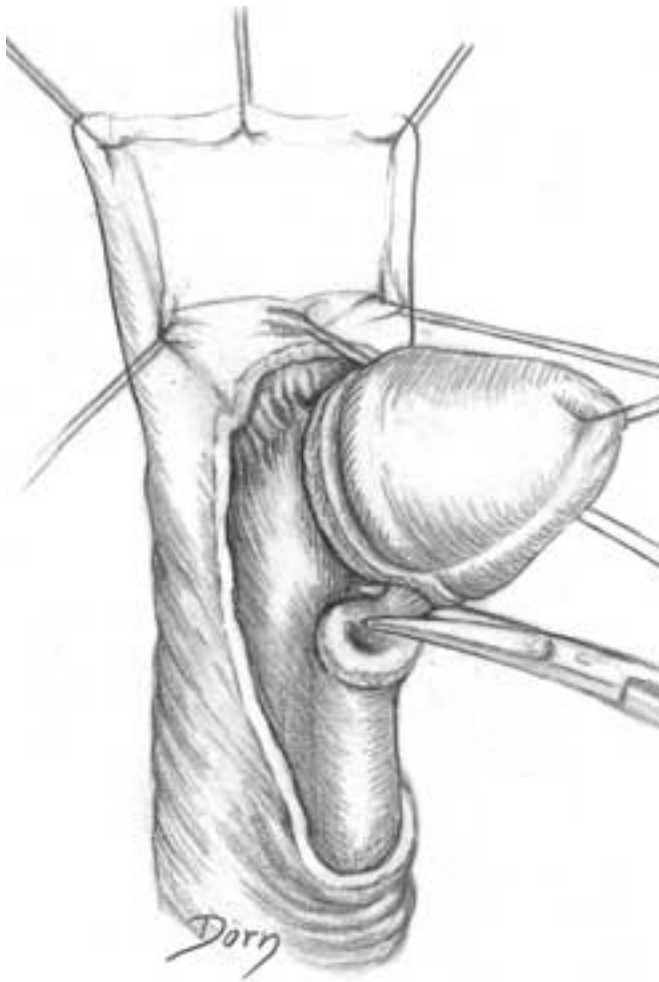
The aim of the operation is to reconstruct the distal portion of the urethra.

**A** The urethral canal will be reconstructed with a tubularised and pedicled preputial flap (mucosal aspect). Design of the incisions.

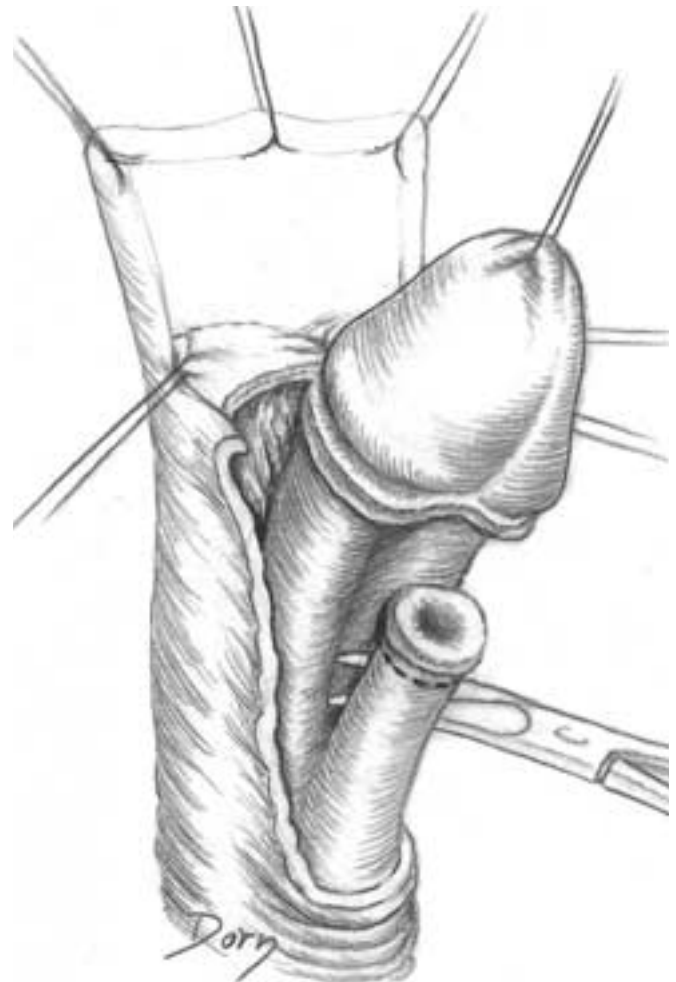
**B** Incision around the urethral meatus.



**C** Section of the retractile band responsible for the curvature of the penis.



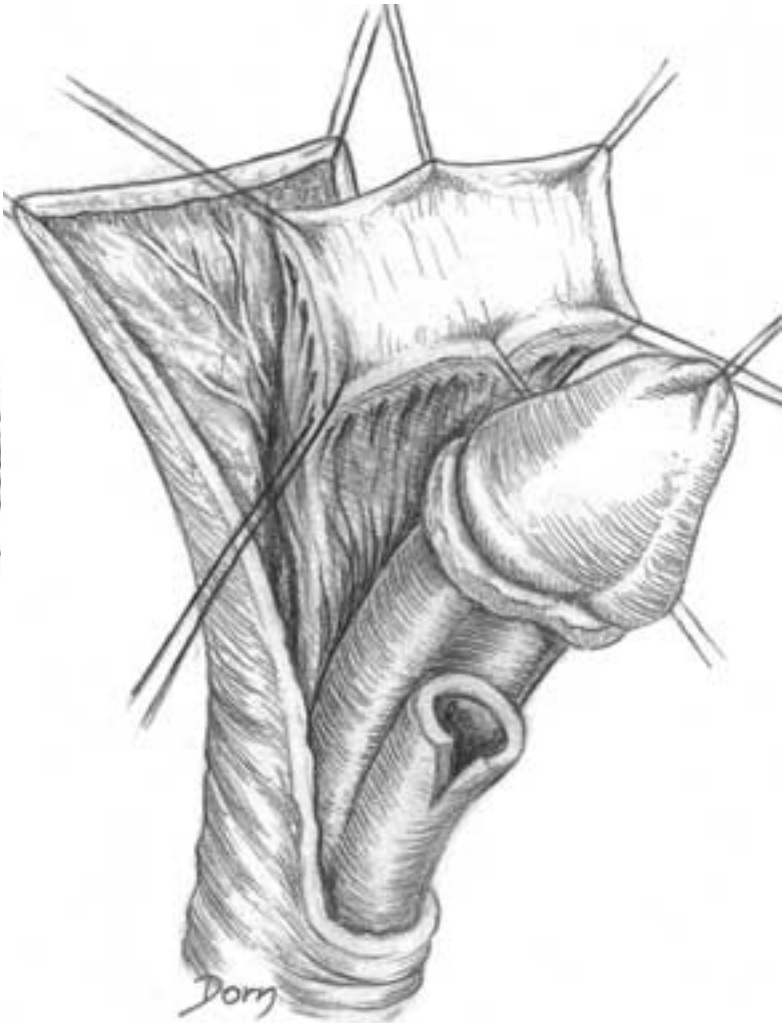
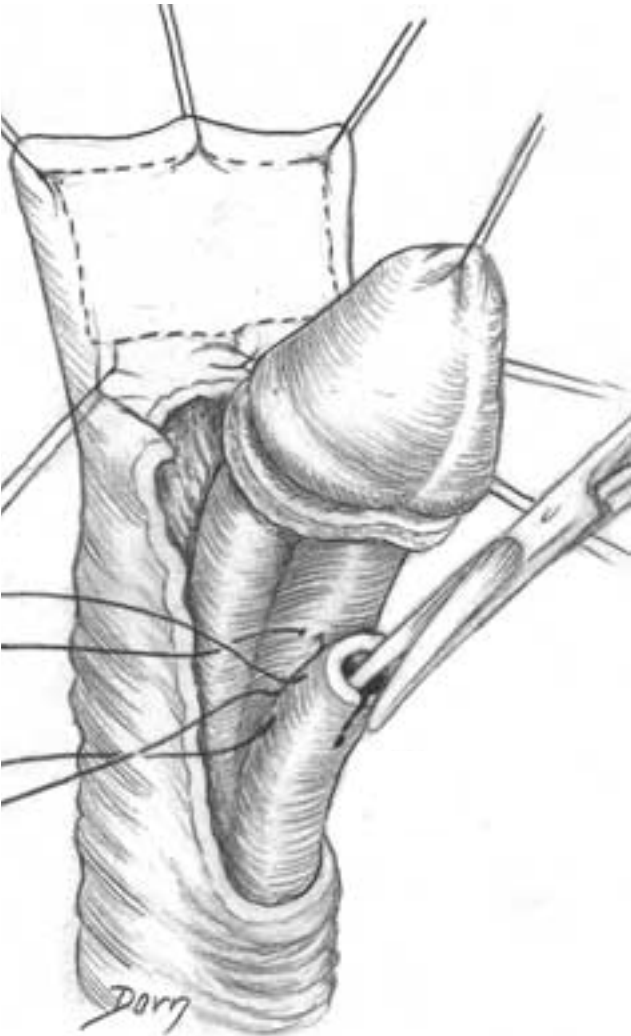
**D** Release of the urethra between the corpora cavernosa and the corpus spongiosum.



# Urological surgery

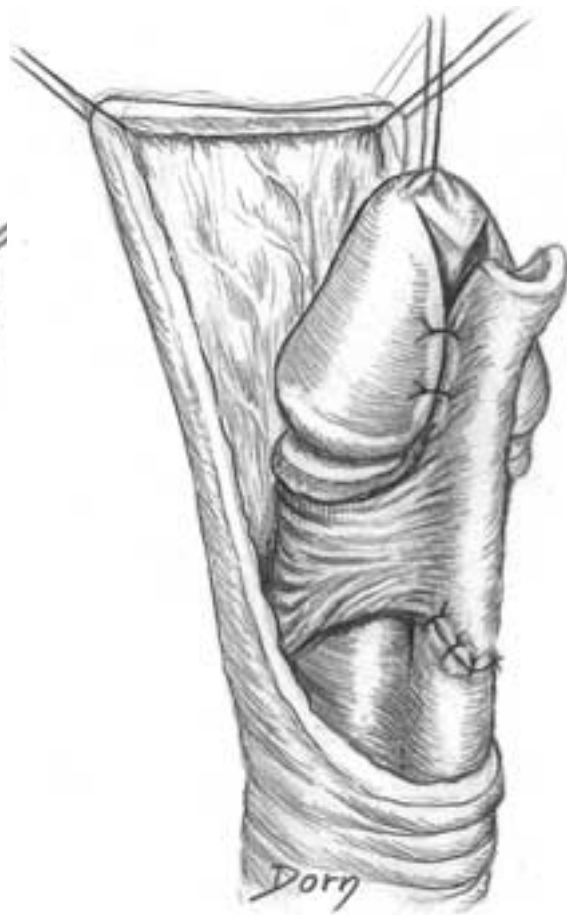
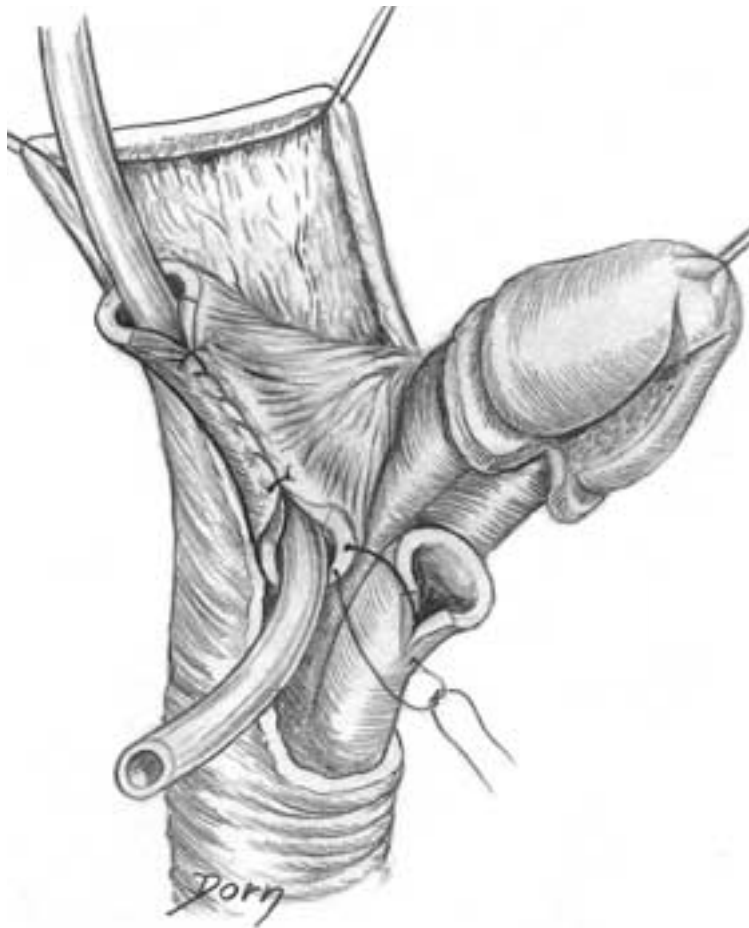
**E** Preparation of the urethra: excision of the meatus and the distal hypoplastic portion of the urethra; incision of the inferior aspect of the urethra and fixation of the dorsal aspect of the corpus spongiosum to the corpora cavernosa.

**F** The mucosal flap is isolated on its pedicle.



**G** Tubularisation of the flap. Note the trough in the glans to implant the neo-urethra.

**H** The reconstruction is covered by a skin flap.



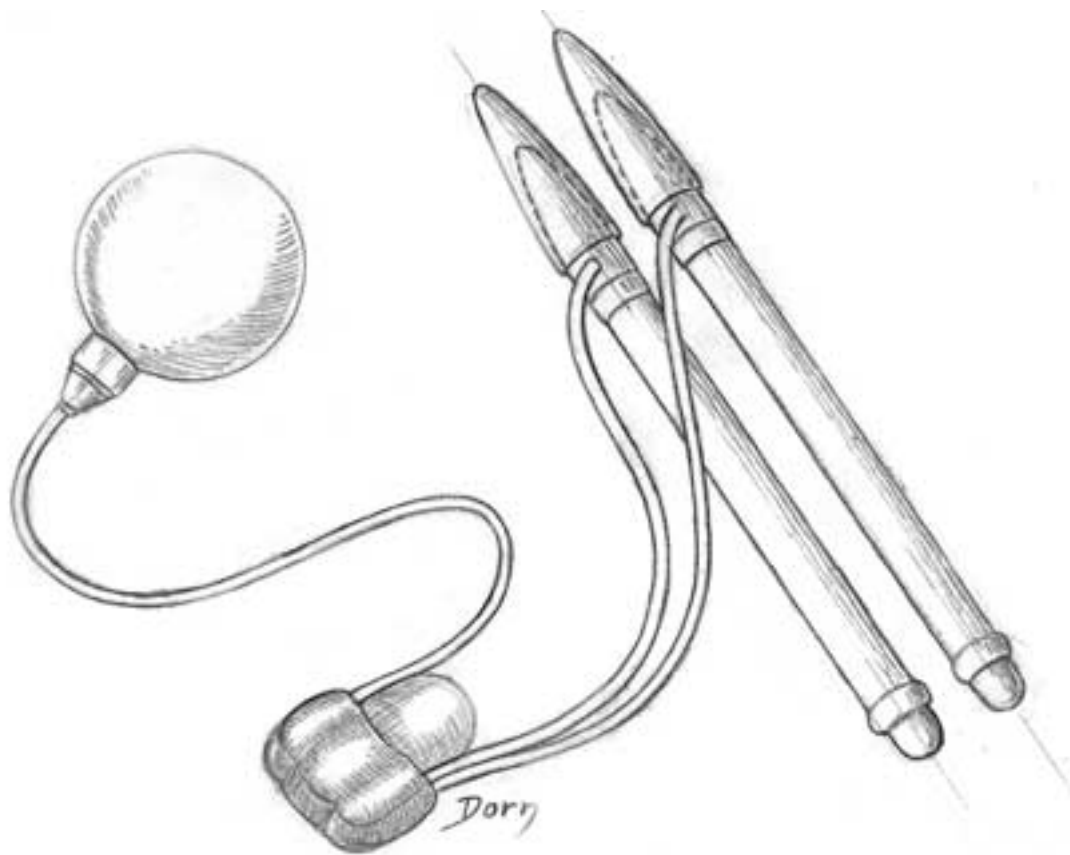
# Urological surgery

---

## Prosthesis for erectile function of penis

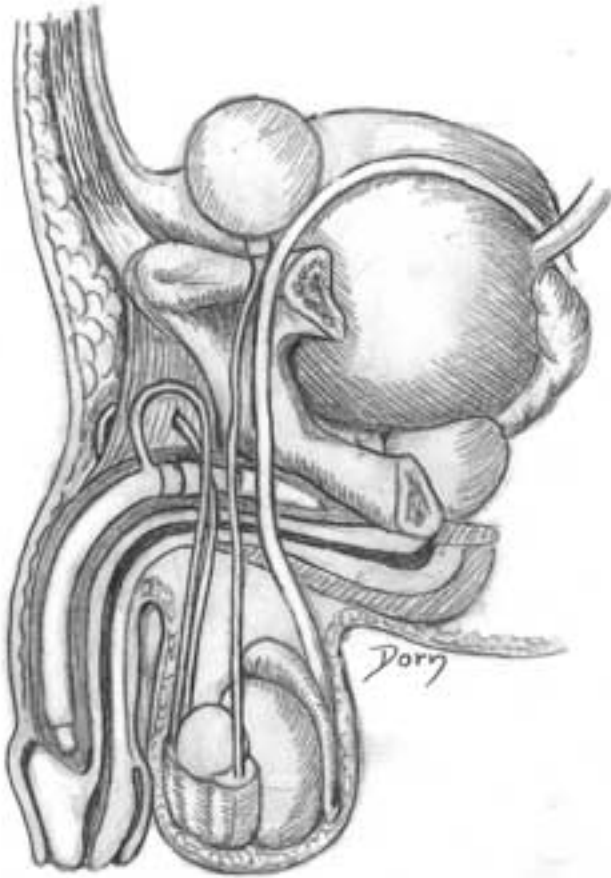
The principle is to obtain an artificial erection by inflating the corpora cavernosa of the penis. The glans penis cannot be erected by this prosthesis.

**A** Prosthesis of penis. It comprises a tank, a pump and two inflatable cylinders which will be placed in the corpora cavernosa.

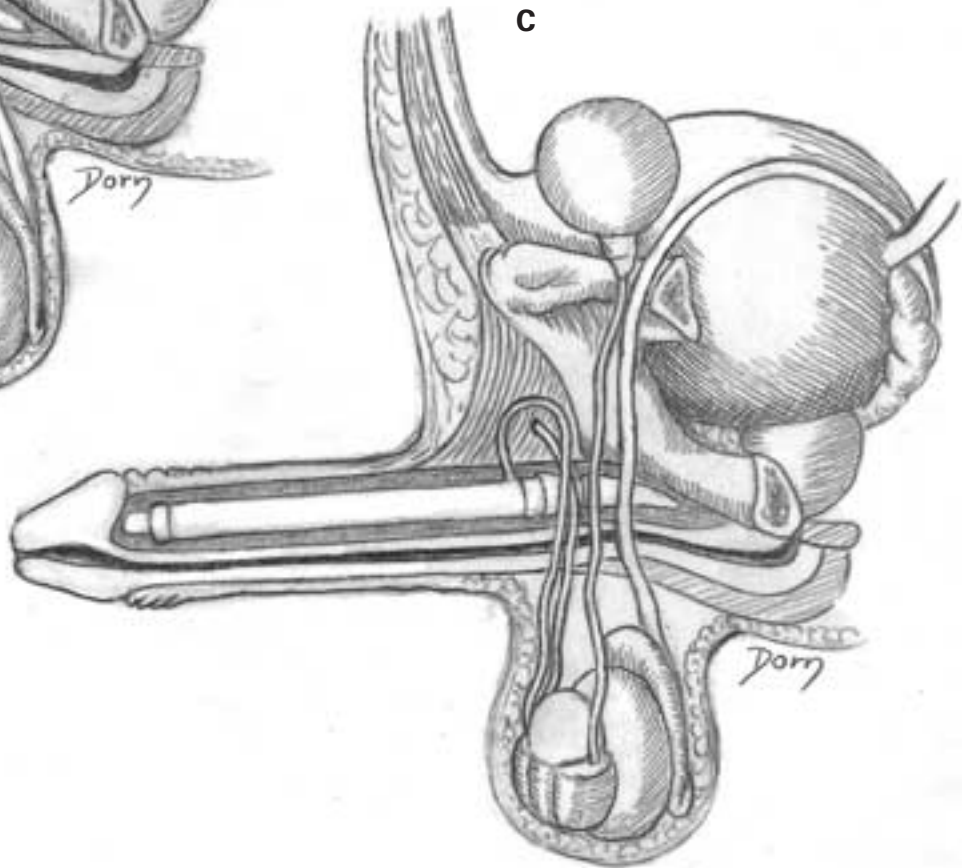


**B, C** The prosthesis in the flaccid state and in erection. The tank is placed in Retzius' space while the pump is in the scrotum.

**B**



**C**

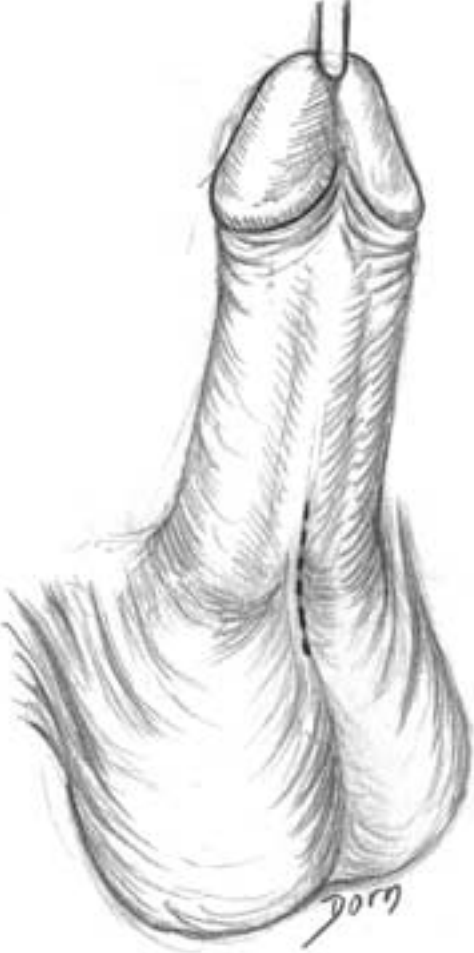



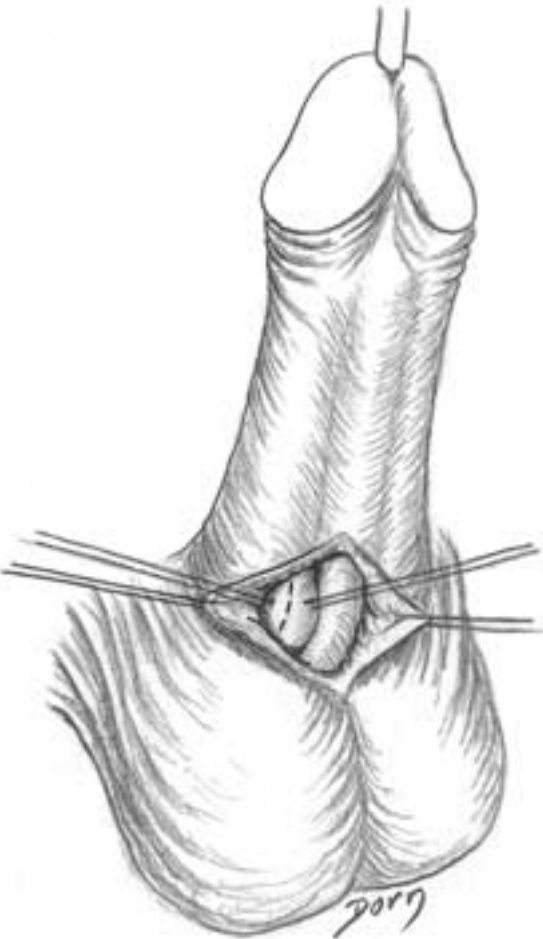
# Urological surgery

**D-G** Surgical procedure. Incision of the corpus cavernosum and dilation.

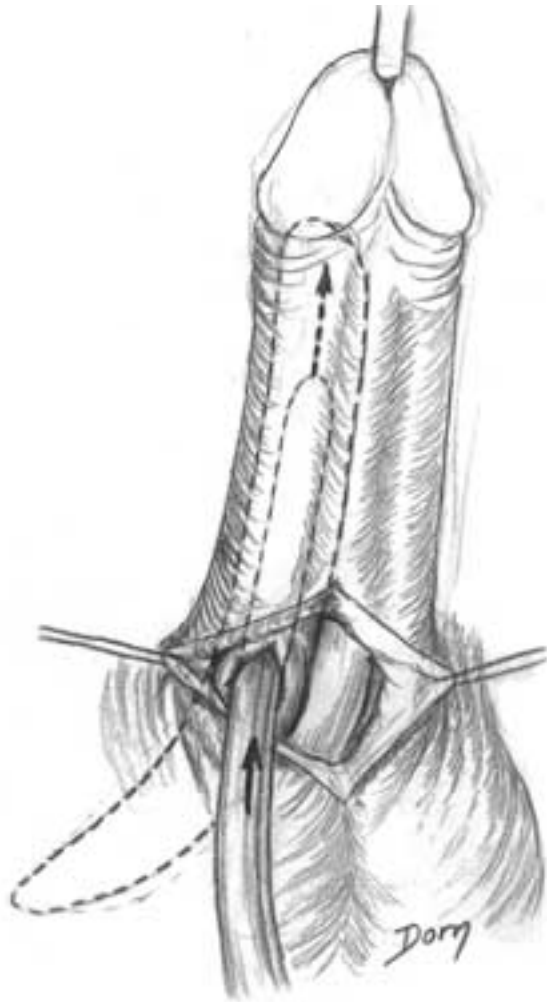
**D**



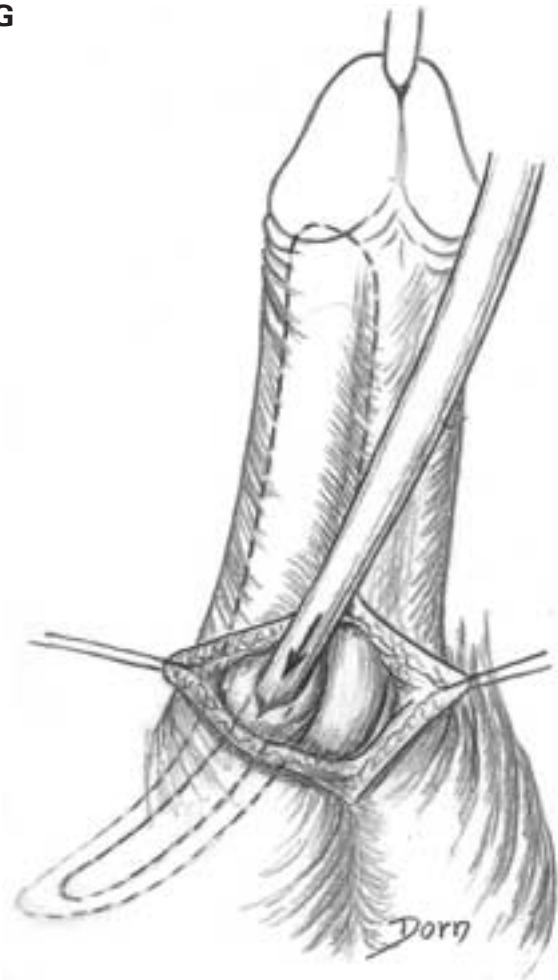
**E**



F



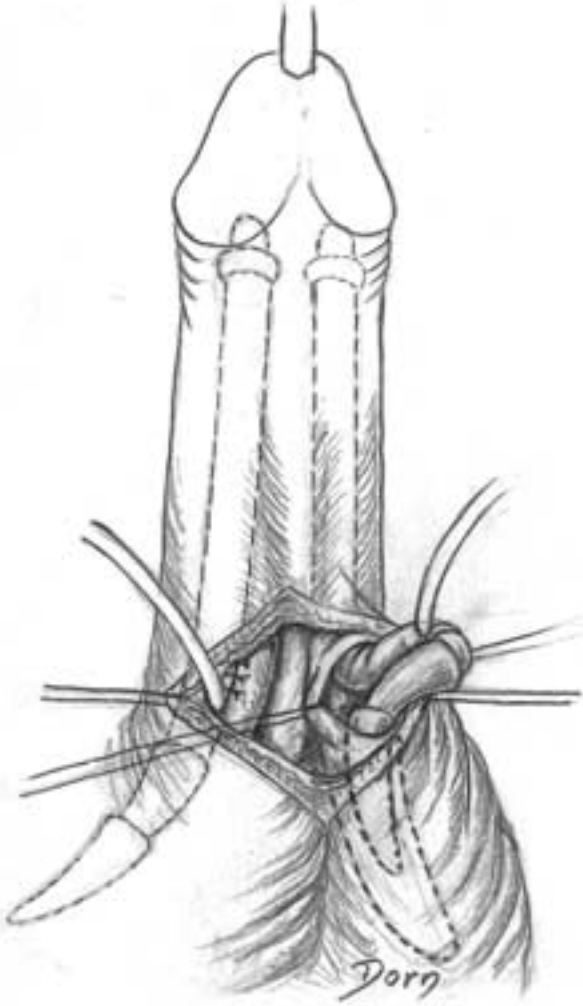
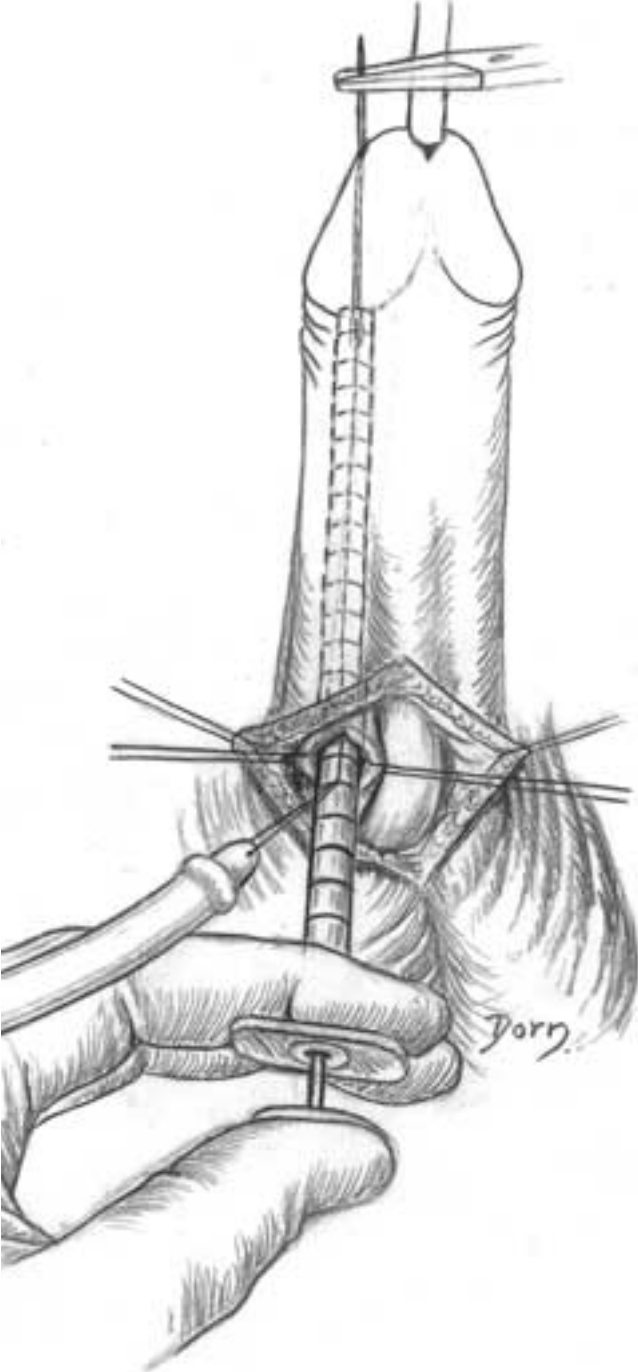
G



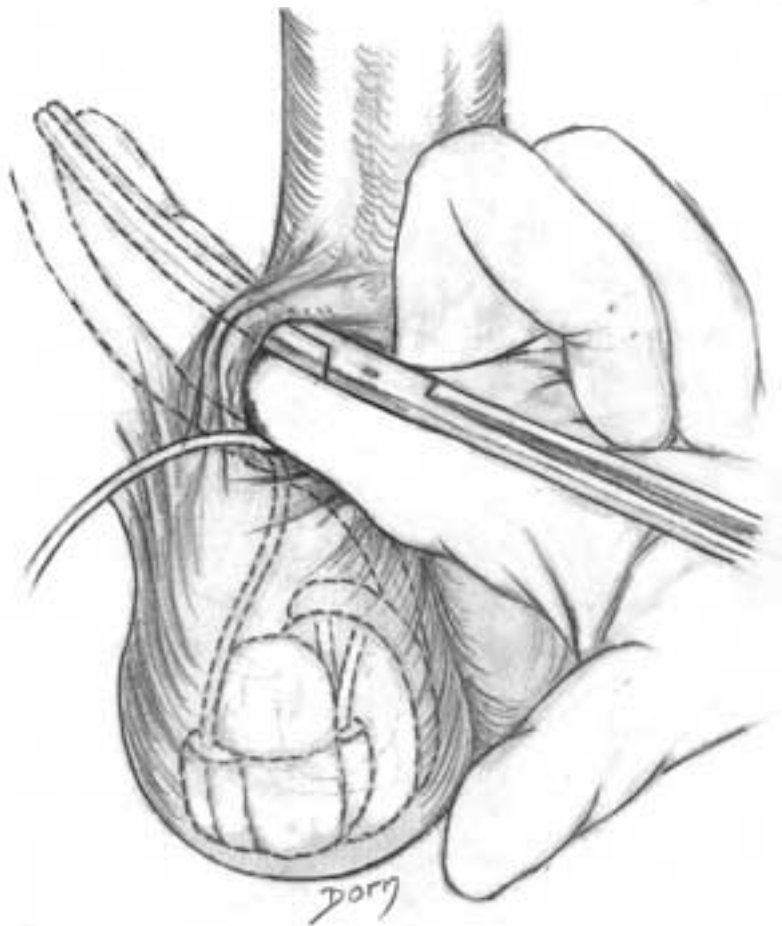
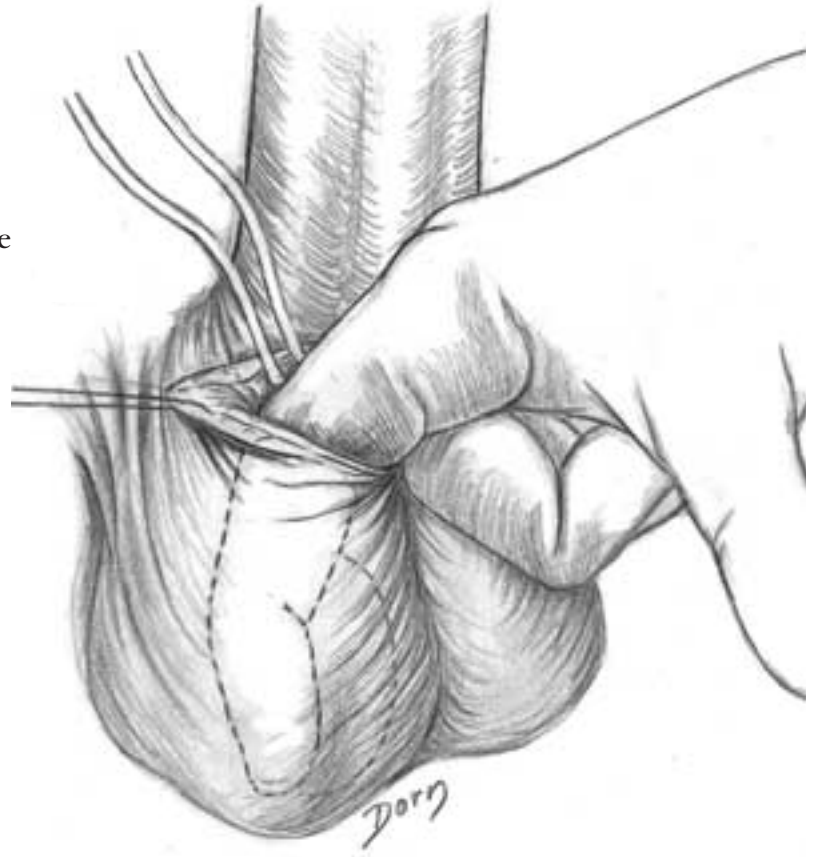
# Urological surgery

**H** A needle with a thread is passed through the glans, which permits lifting up the cylinder to put it in right place.

**I** The same procedure is performed on the other corpus cavernosum.



**J** A tunnel is made in the scrotum to place the pump.

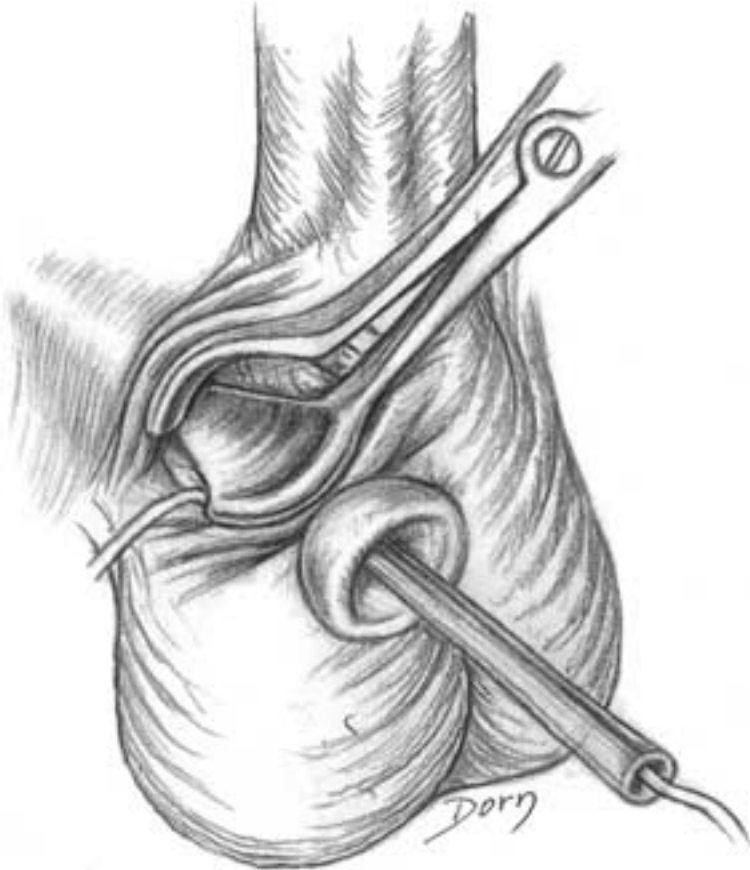


**K** A tunnel is made to give access to Retzius' space (for the tank).

# Urological surgery

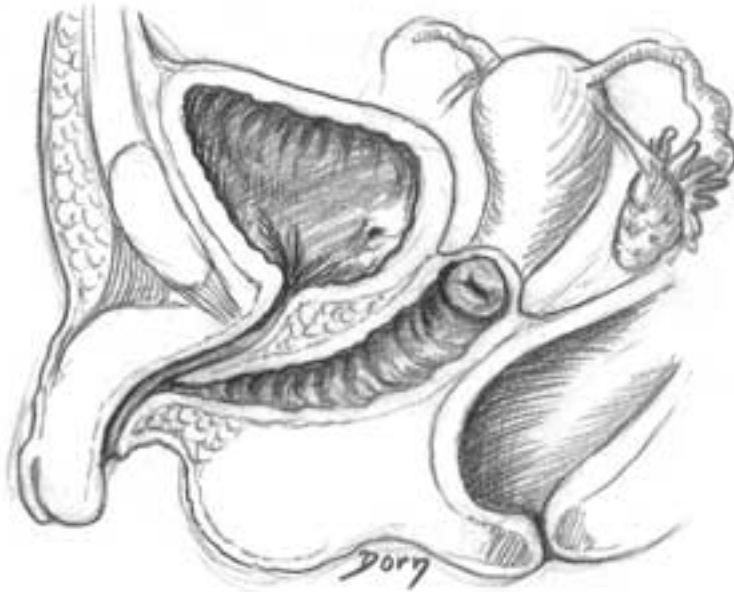
---

L The tank is introduced with a small speculum.

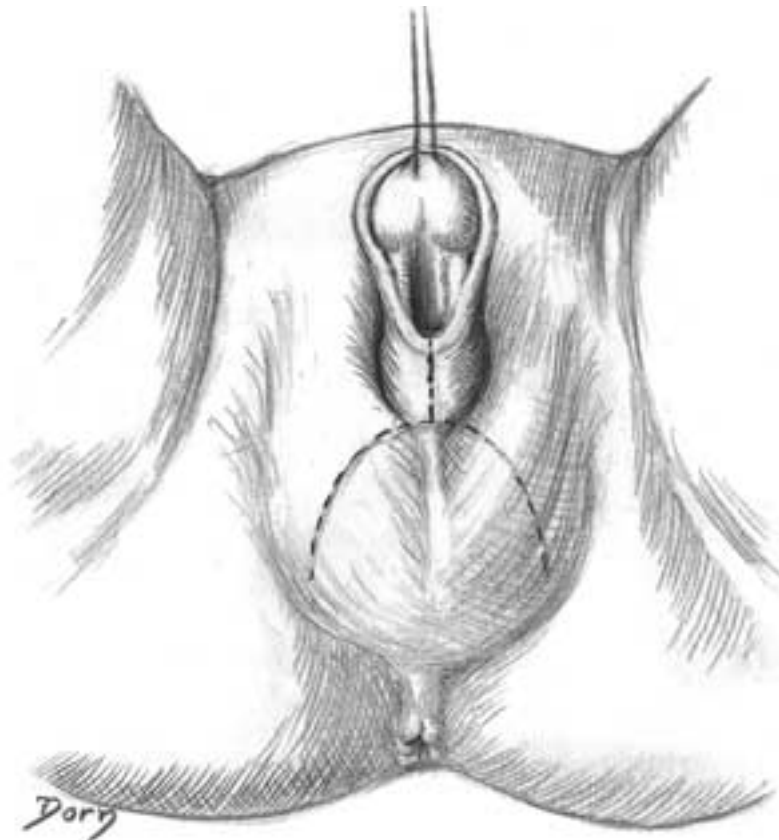


Amputation of the penis for sexual ambiguity: feminisation

**A** Diagrammatic representation of sexual ambiguity. Note the short urogenital sinus.

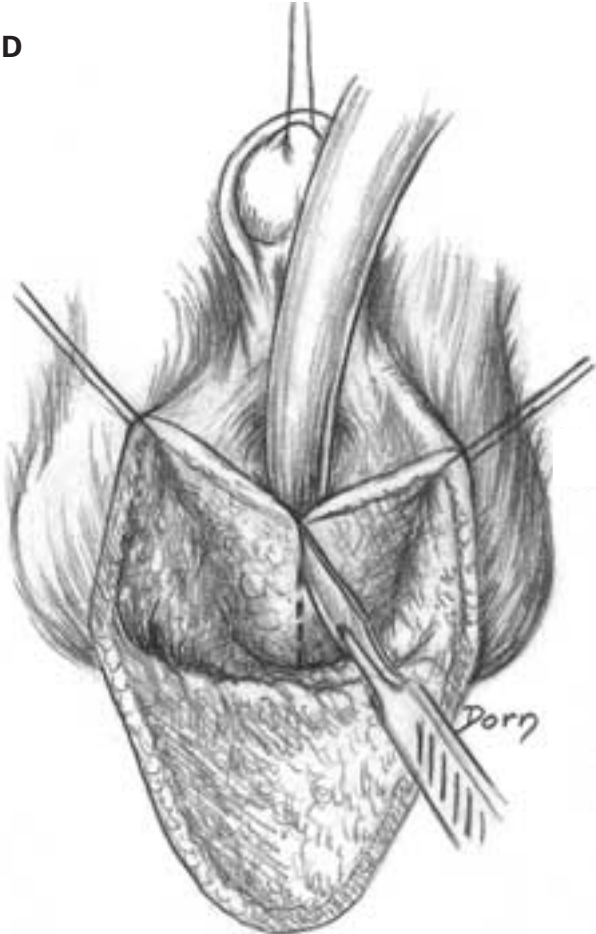
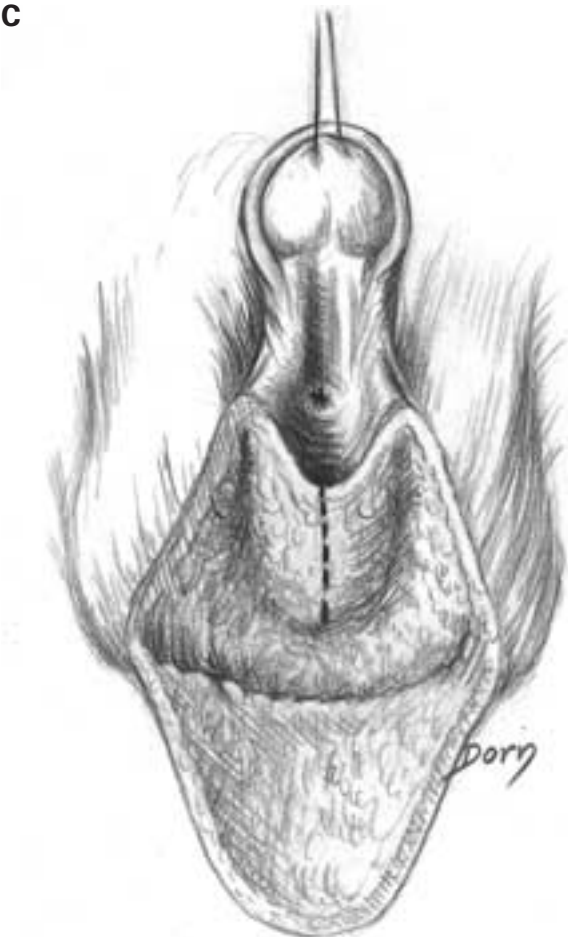

**B** Vagina plasty and plasty of the labia. The skin incision permits raising a large flap with a posterior hinge.



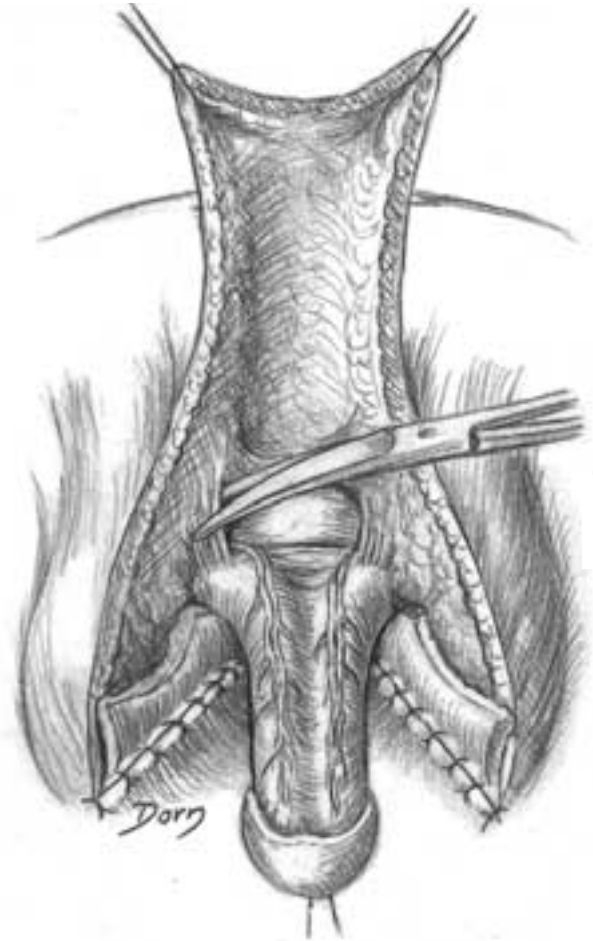
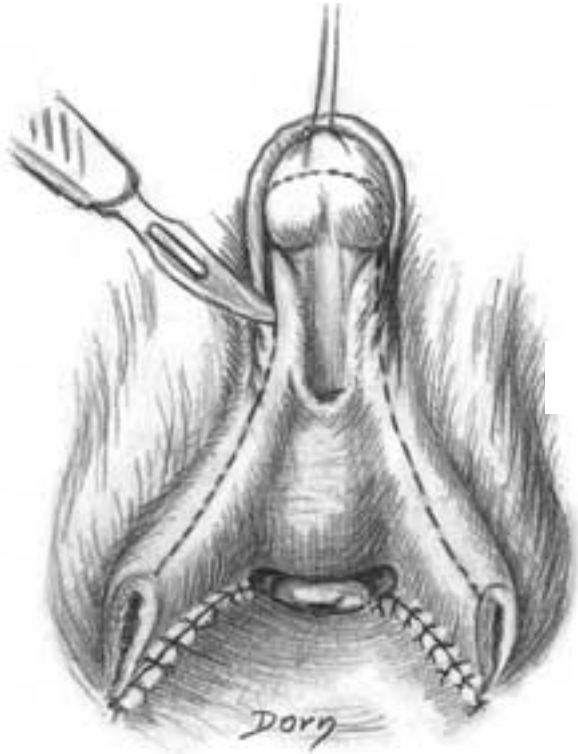# Urological surgery

C, D Incision in the posterior aspect of the urogenital sinus.



**E** The skin flap is inserted in the posterior aspect of the urogenital sinus (which has been incised). Incisions to prepare the plasty of the labia, the clitoris and the prepuce of the clitoris.

**F** Complete release of the penis; which will become the clitoris organ.

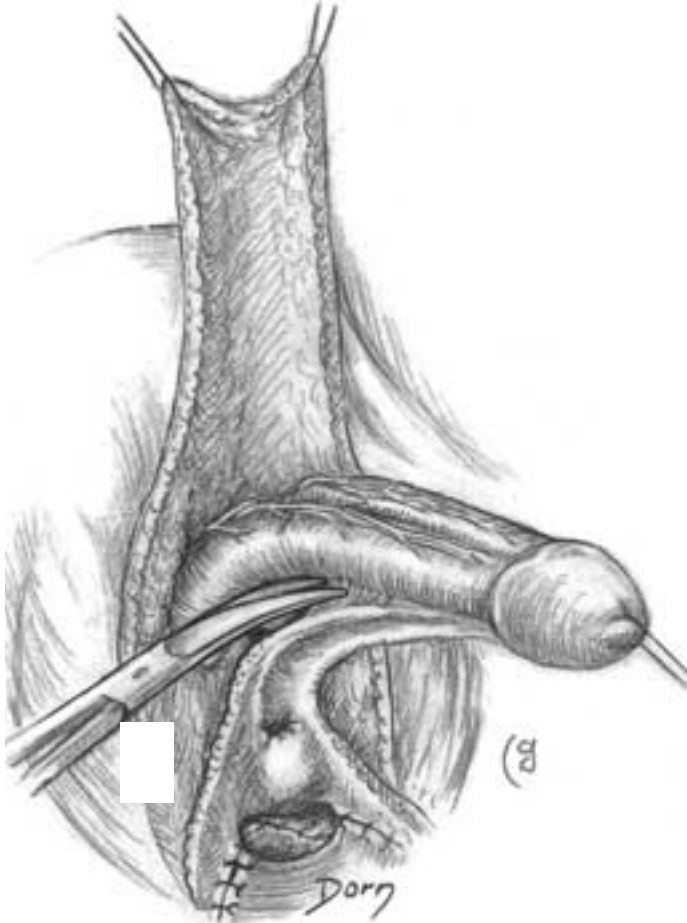




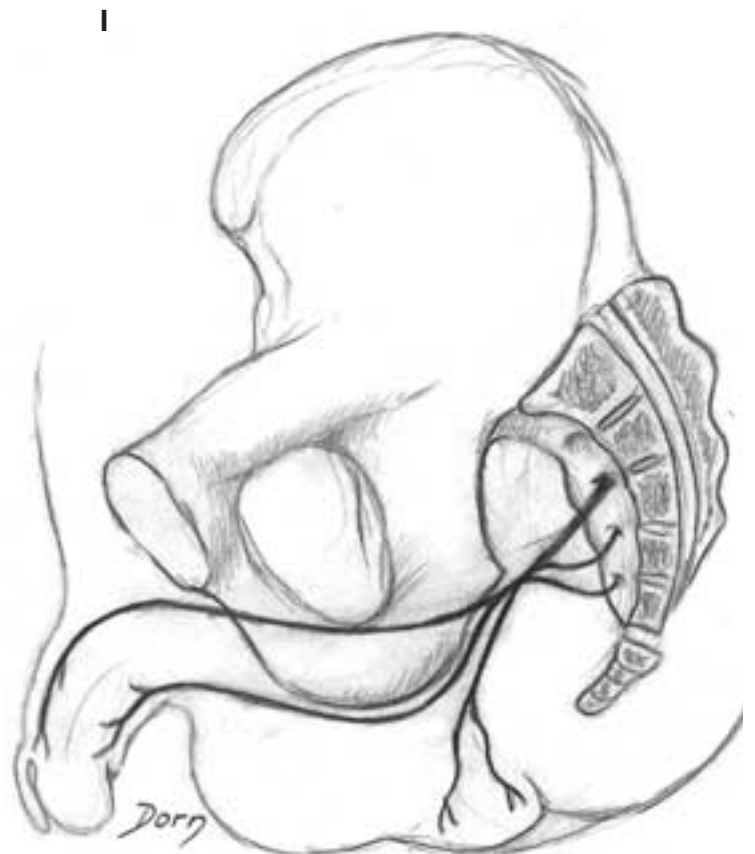
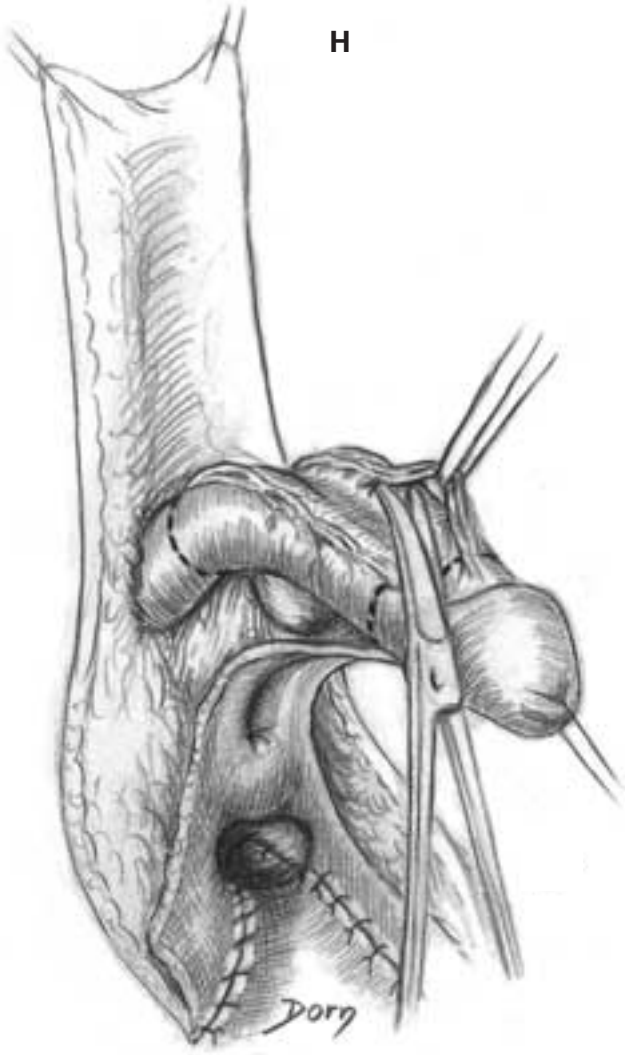
# Urological surgery

---

**G** Release of the ventral aspects of the corpora cavernosa.



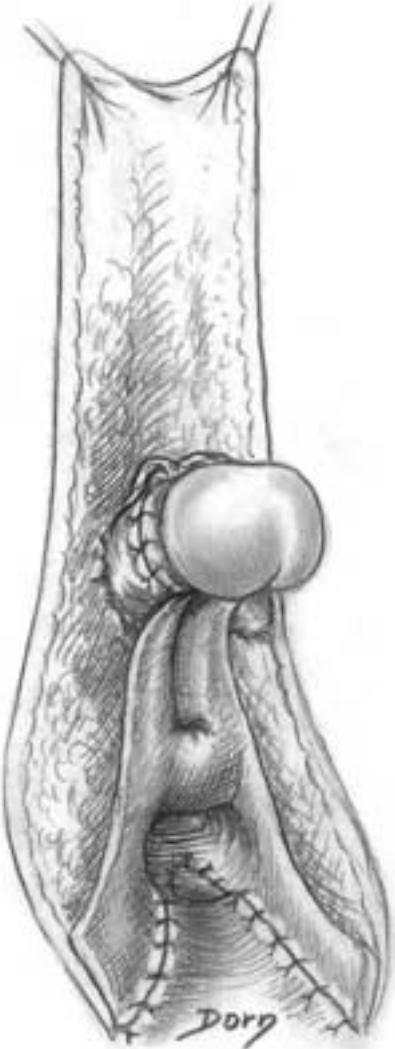
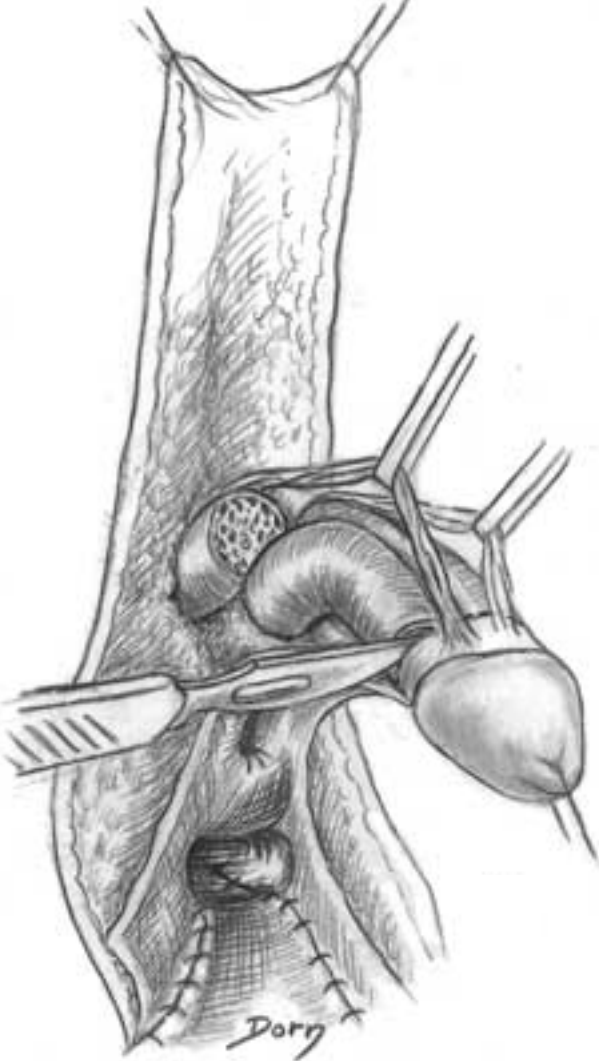
**H** Plasty of the clitoris. Dissection of the dorsal neurovascular pedicle for the (future) clitoris. **I** Origin of the nerves.



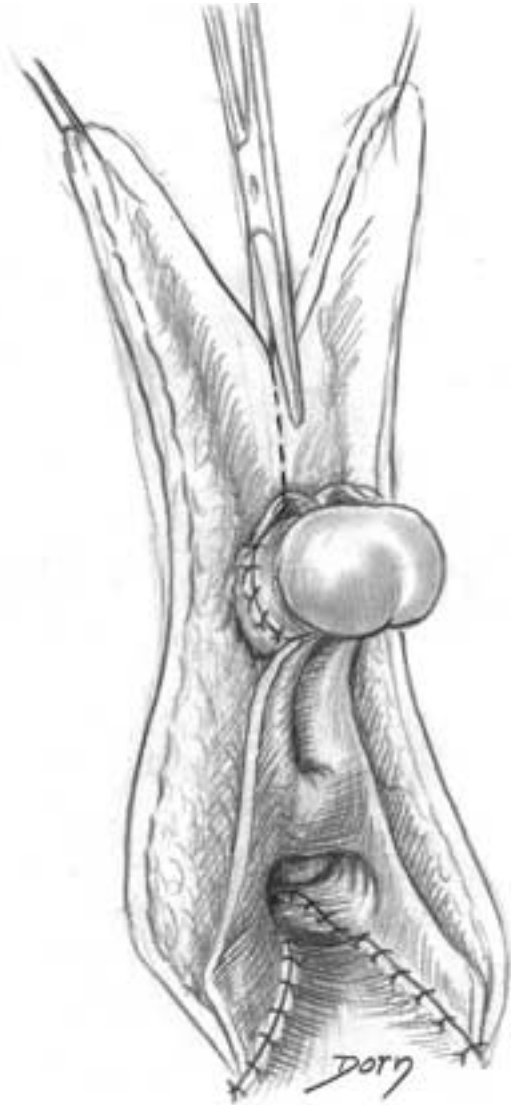
# Urological surgery

**J** Excision of the major portions of the corpora cavernosa, taking care of the neurovascular pedicles which supply the glans.

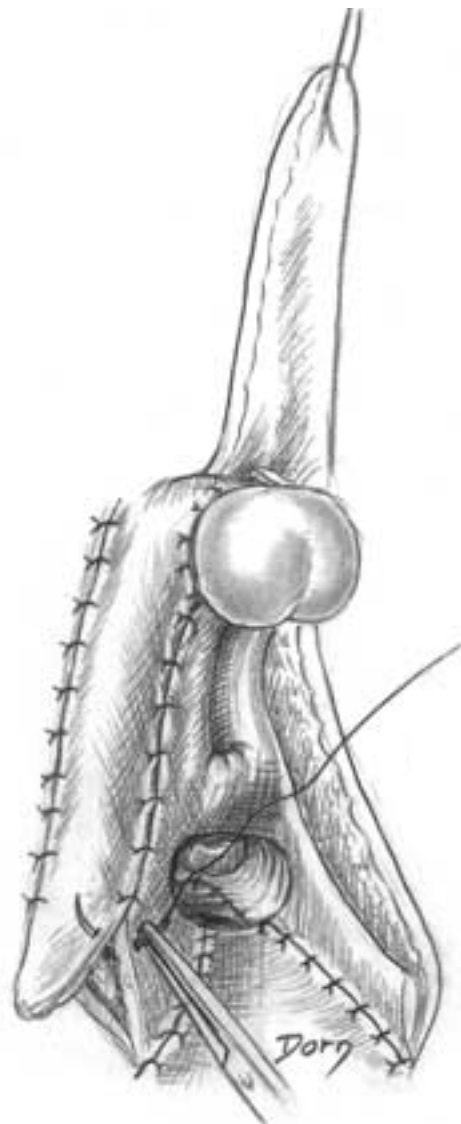
**K** Suture. The penis is shortened to obtain a clitoris.



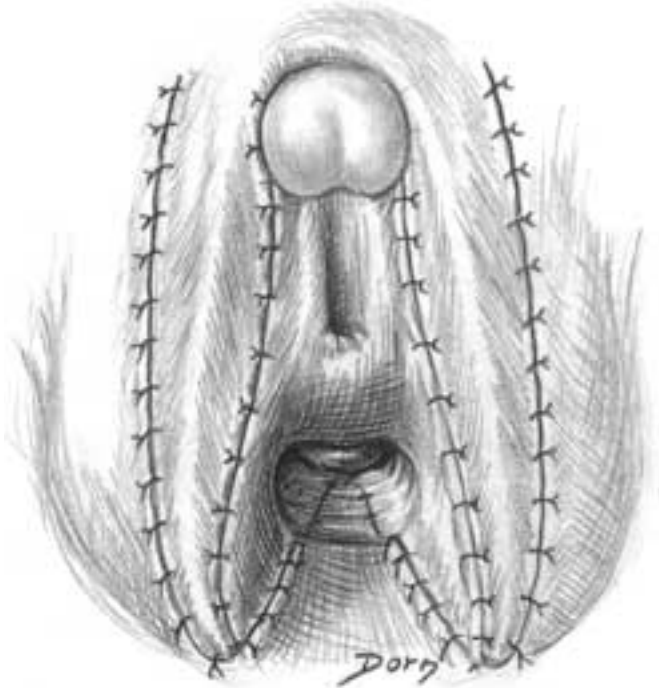
**L** Plasty of the labium minus.



**M** Reconstruction of the labium majus and labium minus.



N Final aspect.



# Abdominal surgery

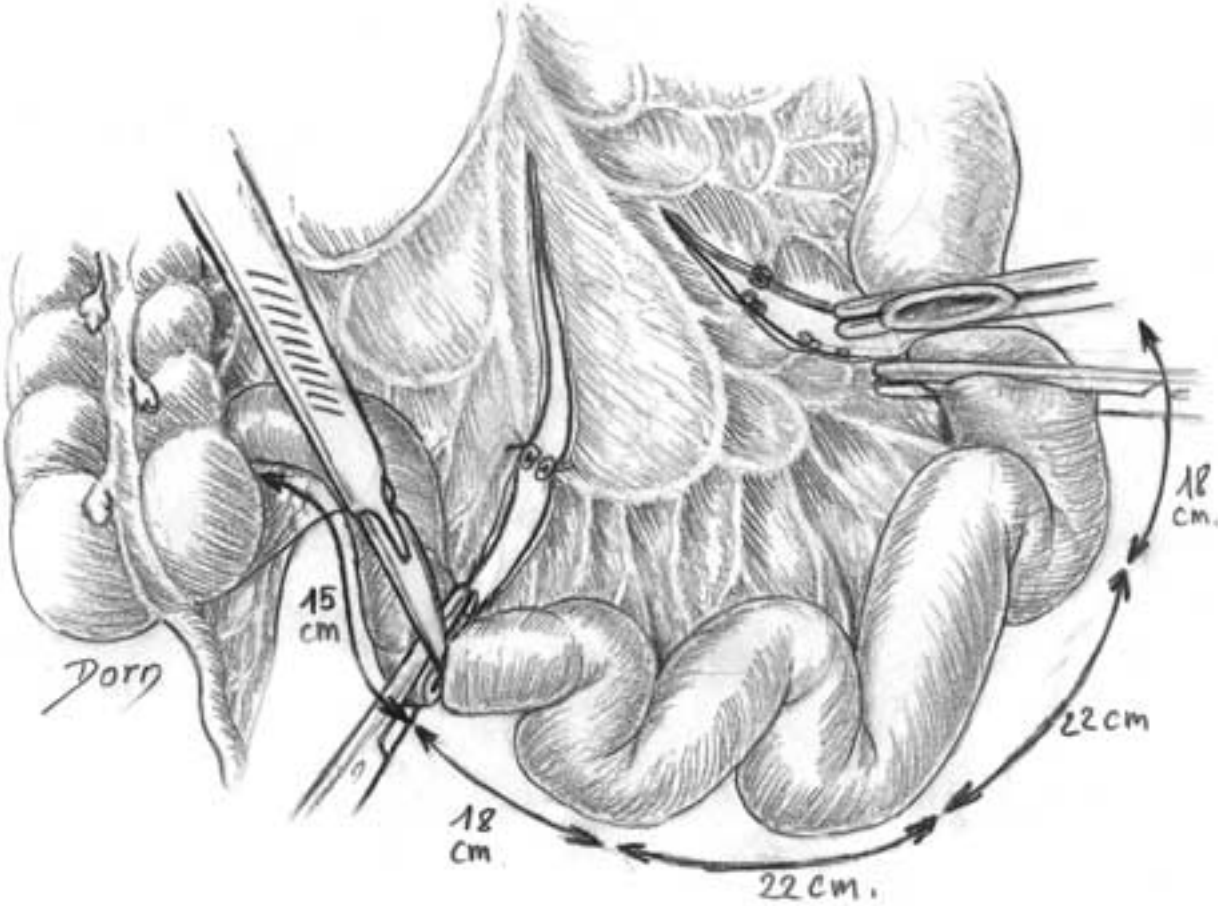
The following series of illustrations is devoted to surgery of the abdominal viscera. The organs of the abdomen can be removed in case of tumour-like cancer; they can also be used in palliative procedures to reconstruct another organ which has been removed. The ileum, which is the distal portion of the small intestine, is not absolutely indispensable for normal physiology; it is routinely employed to replace a missing bladder.

Great advances have been made in liver surgery recently, particularly in the field of transplantation. The division of the liver into segments is based upon ramification of bile ducts and hepatic vessels and does not entirely correspond with division into lobes. Segmental resections are of major interest in traumatology and surgery of liver tumours. One of the main recent advances is the possibility of transferring a lobe from the liver of a living donor to replace an entire liver in a recipient patient.

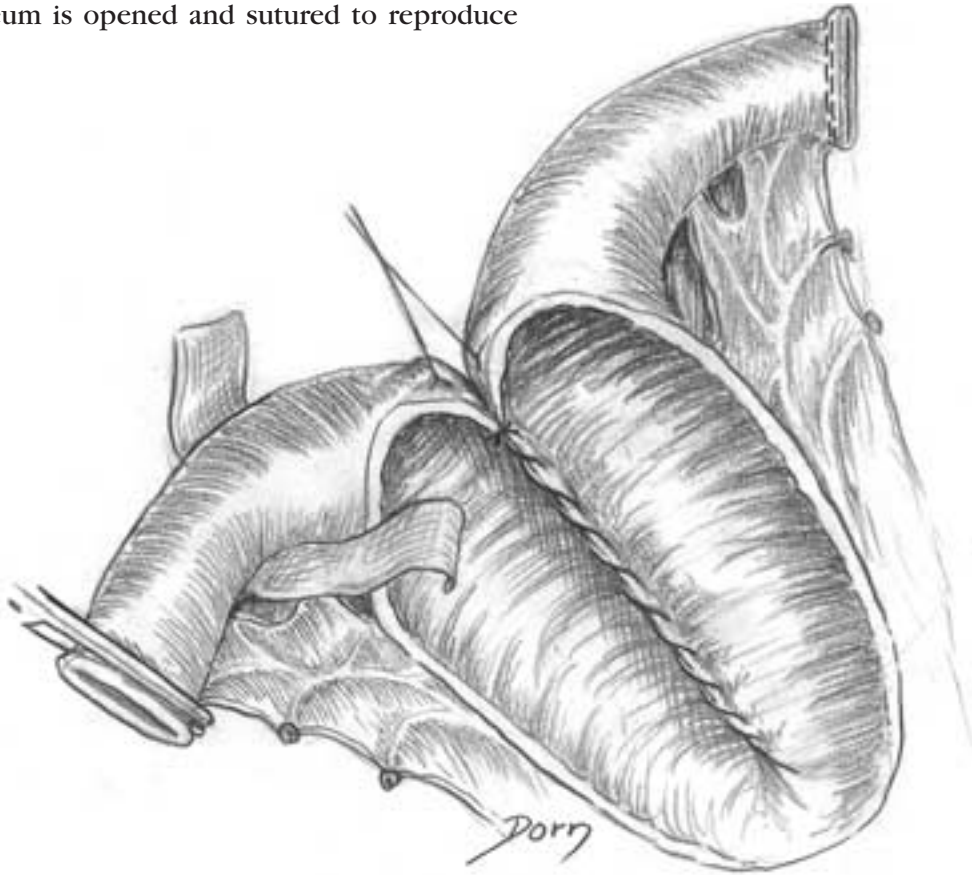
# Abdominal surgery

## Reconstruction of a urinary bladder

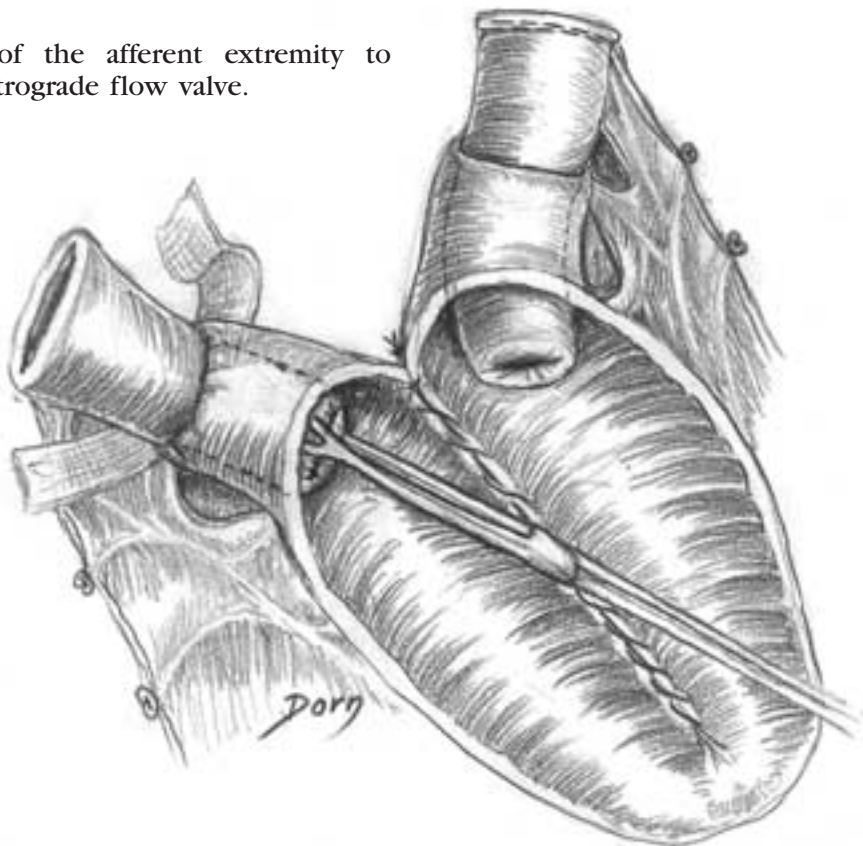
A The distal portion of the ileum is isolated with the corresponding part of mesentery.



**B** The ileum is opened and sutured to reproduce a bladder.



**C** Invagination of the afferent extremity to perform an antiretrograde flow valve.

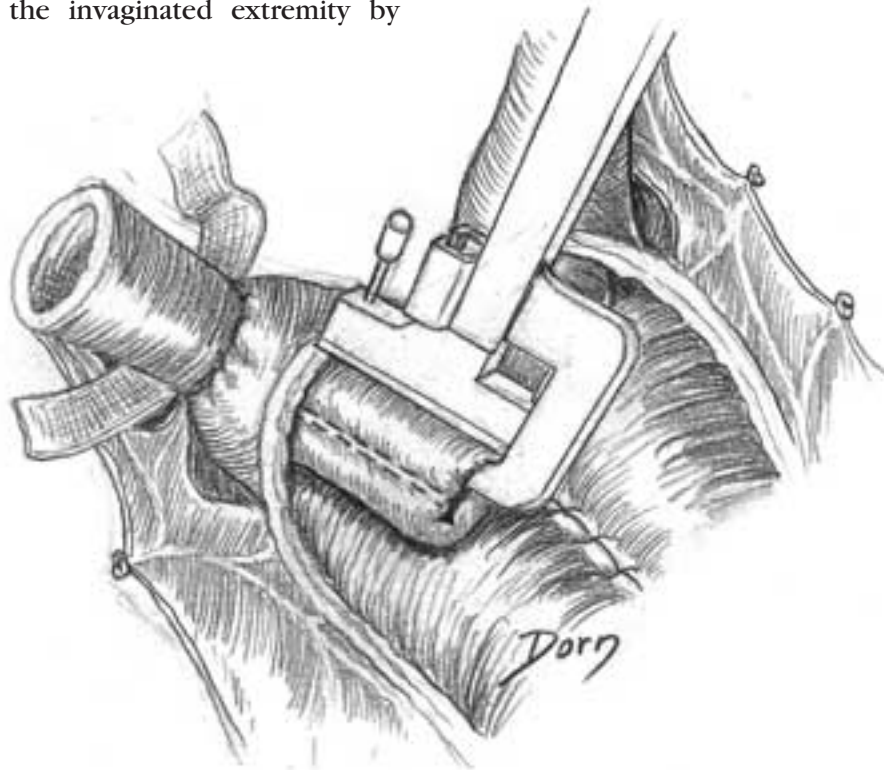




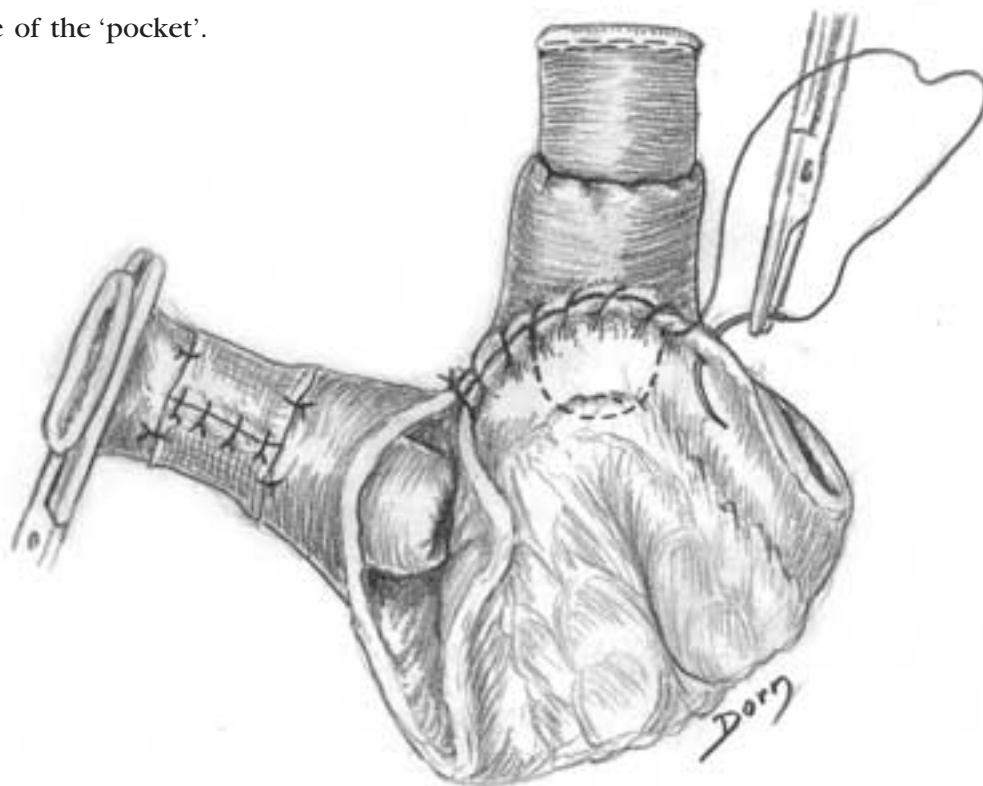
# Abdominal surgery

---

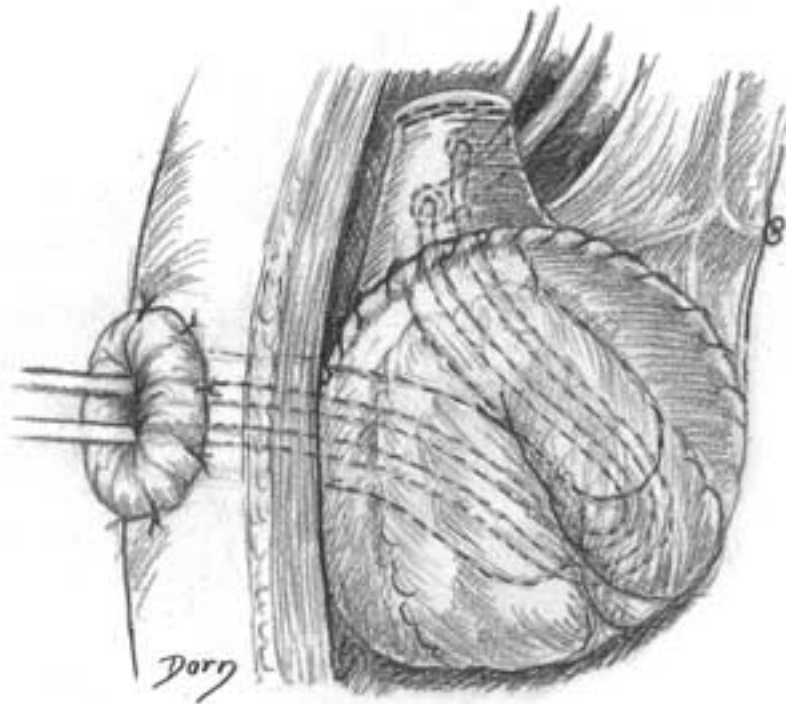
**D** Stabilisation of the invaginated extremity by staples.



**E** Suture of the 'pocket'.



**F** The two ureters are implanted in the afferent extremity. The efferent extremity is passed through the abdominal wall to constitute a stomy.



# Abdominal surgery

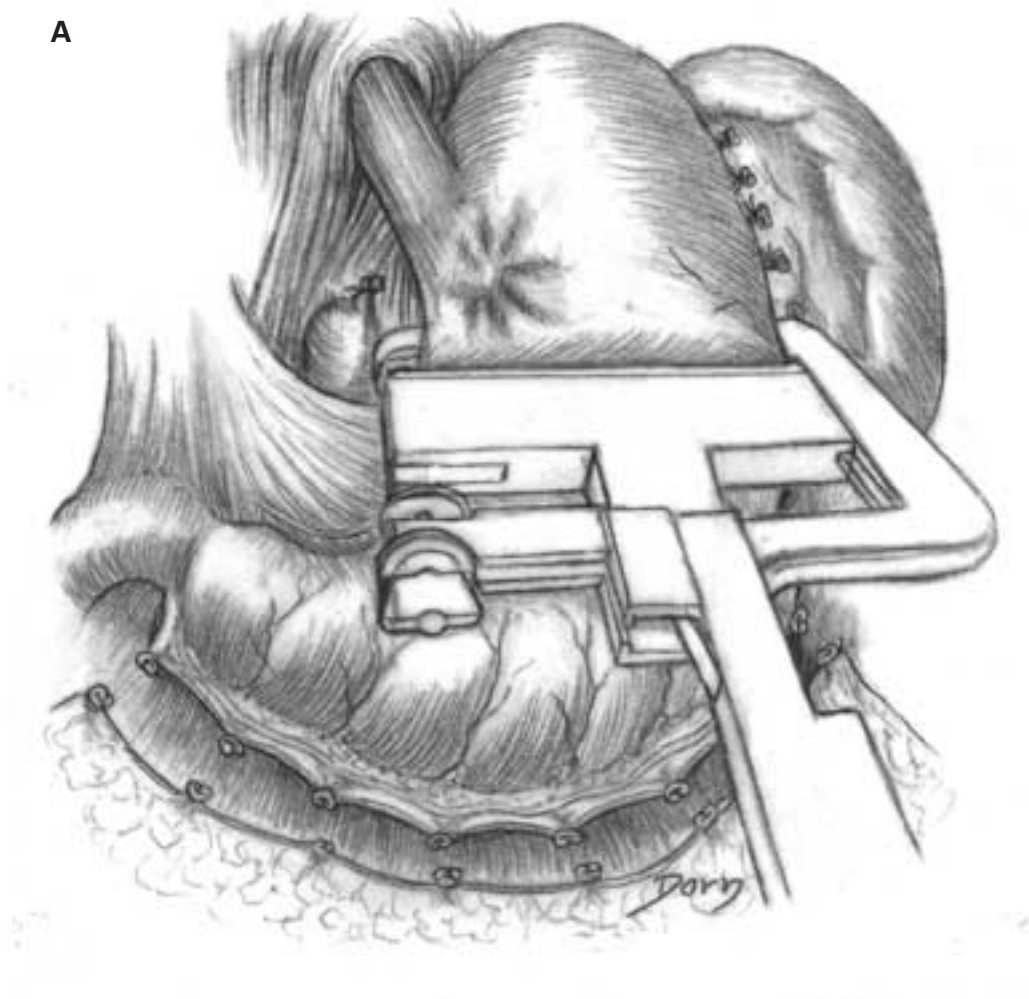
---

## Gastrectomy

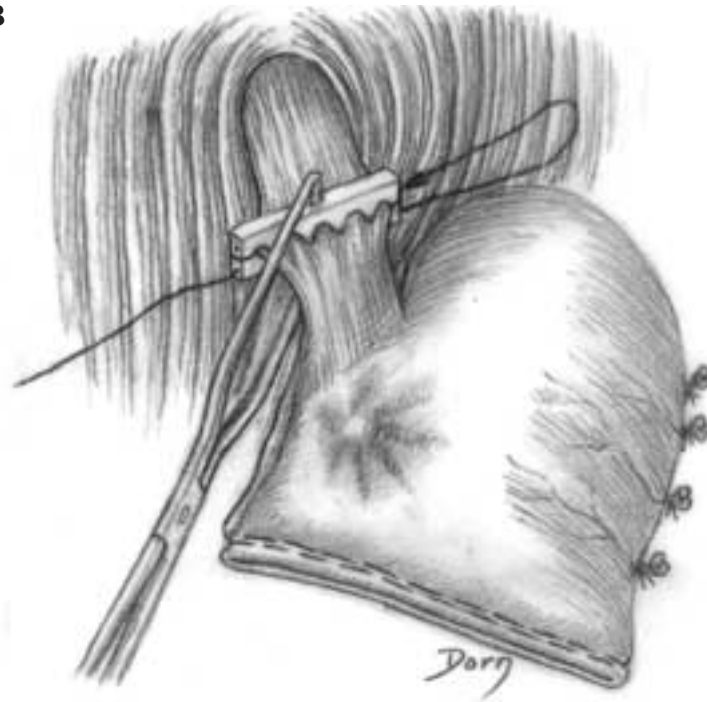
- Oesogastrectomy for cancer.

The tumour is located near the cardia.

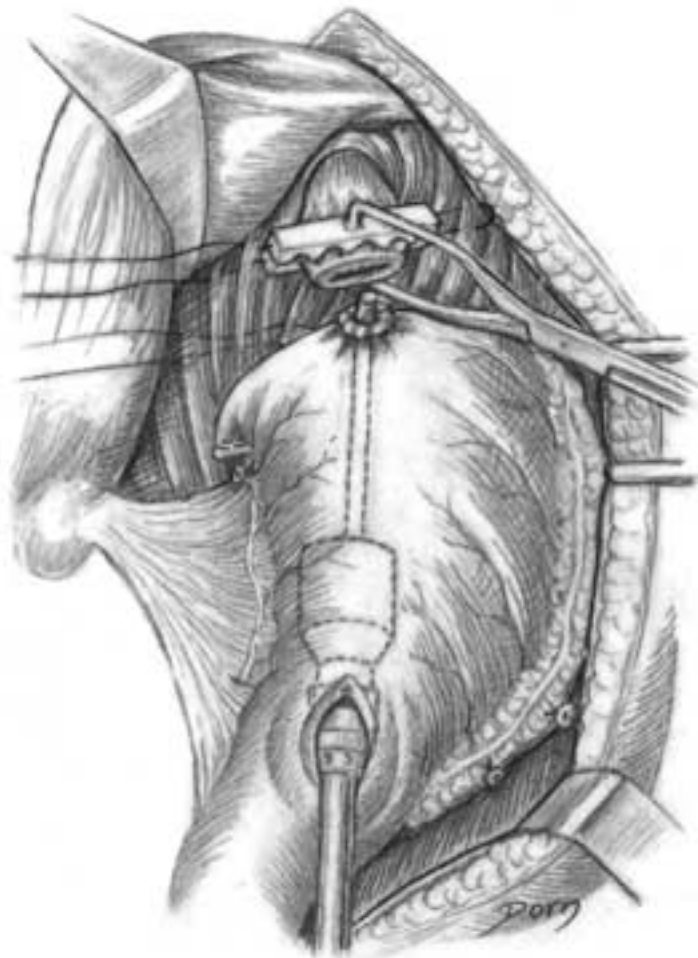
**A, B** Excision of the proximal two-thirds of the stomach and the distal part of the oesophagus.



B



C The distal portion of the stomach is lifted up and anastomosed with the oesophagus.

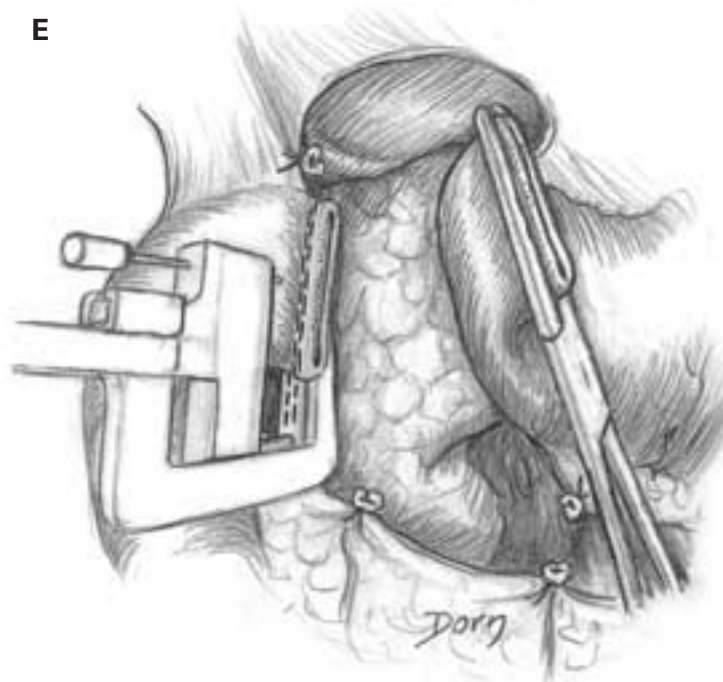
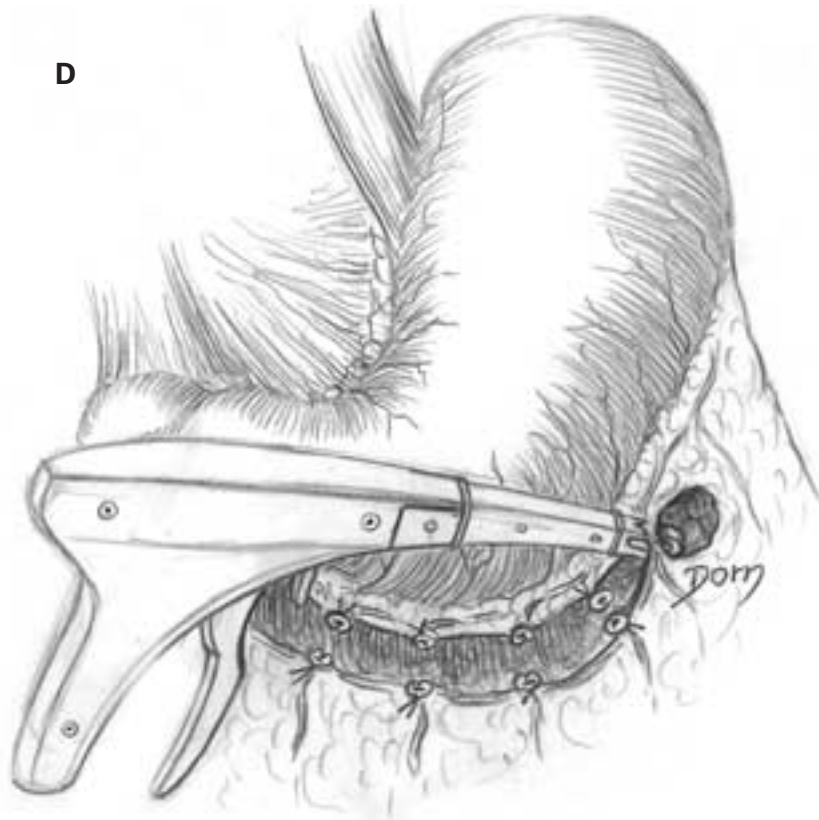


# Abdominal surgery

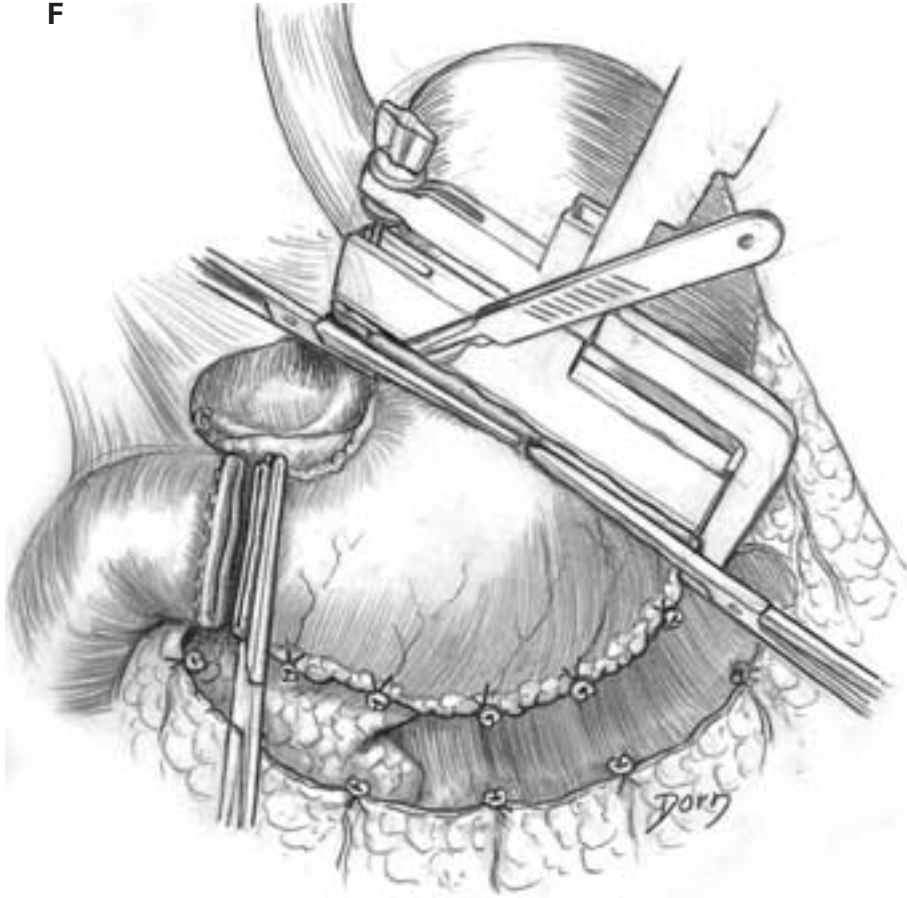
---

- gastrectomy and anastomoses with the jejunum.

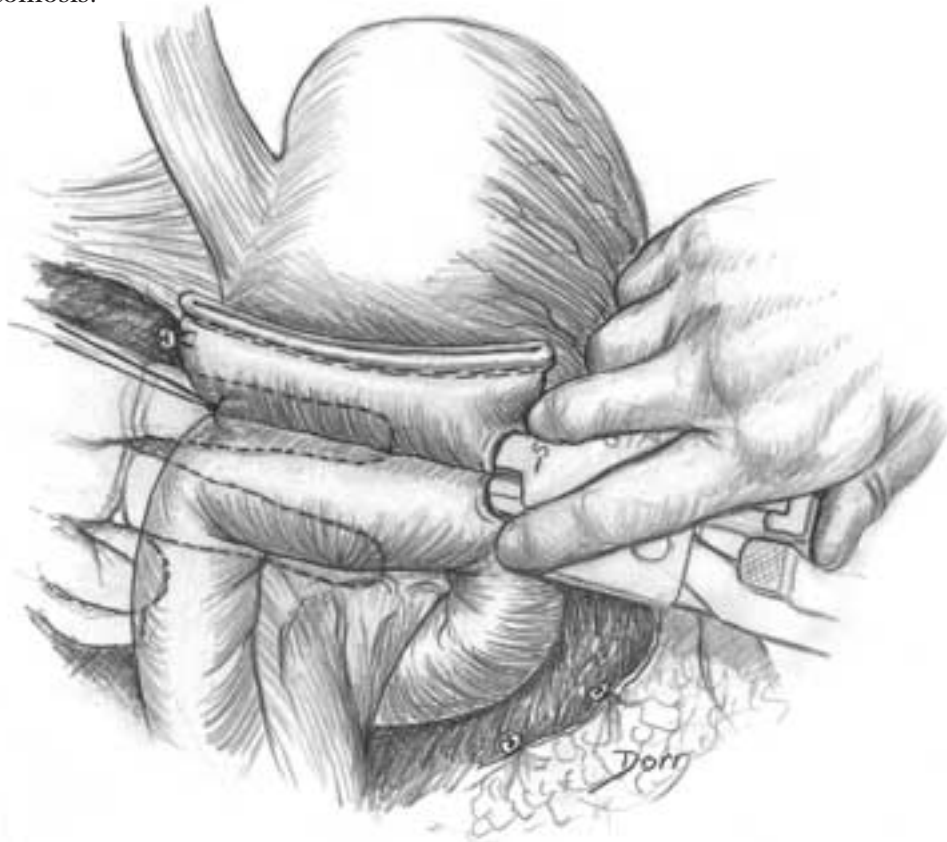**D–F** The distal two-thirds of the stomach is isolated and removed. The extremities of the remaining portion of the stomach and of the jejunum are closed with mechanical staples.



F



G The jejunum is prepared for the end-to-side anastomosis.

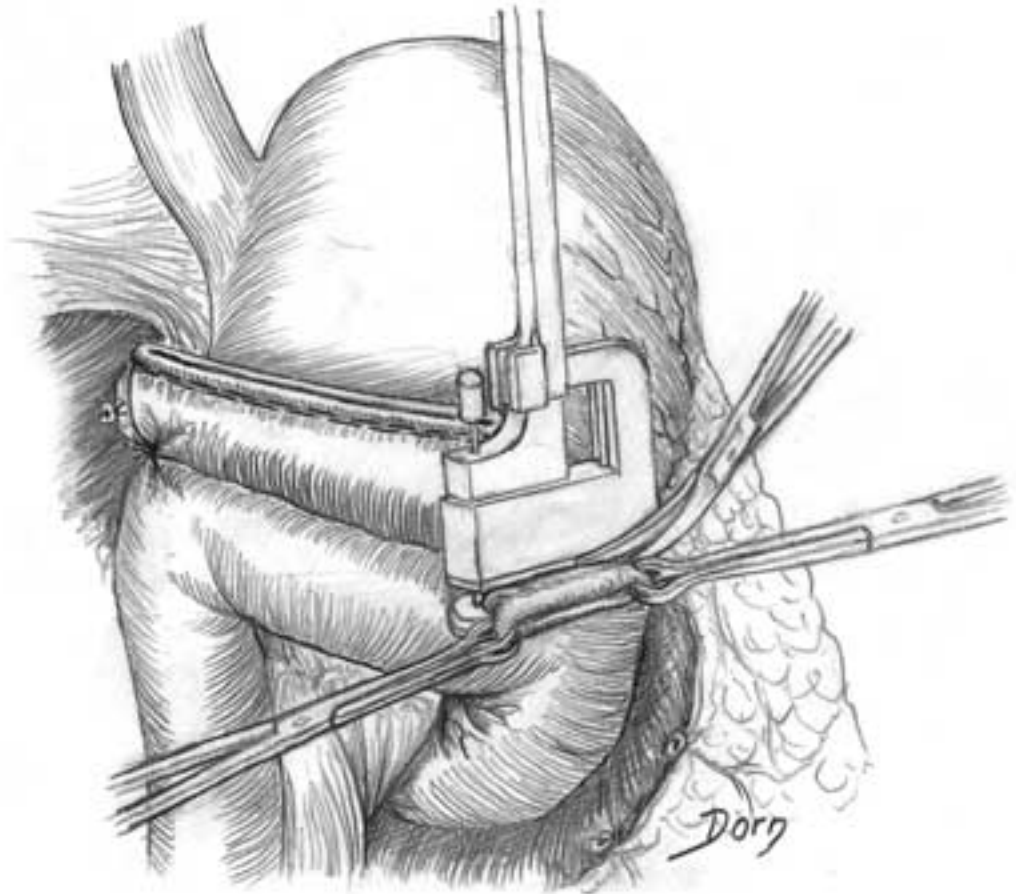


# Abdominal surgery

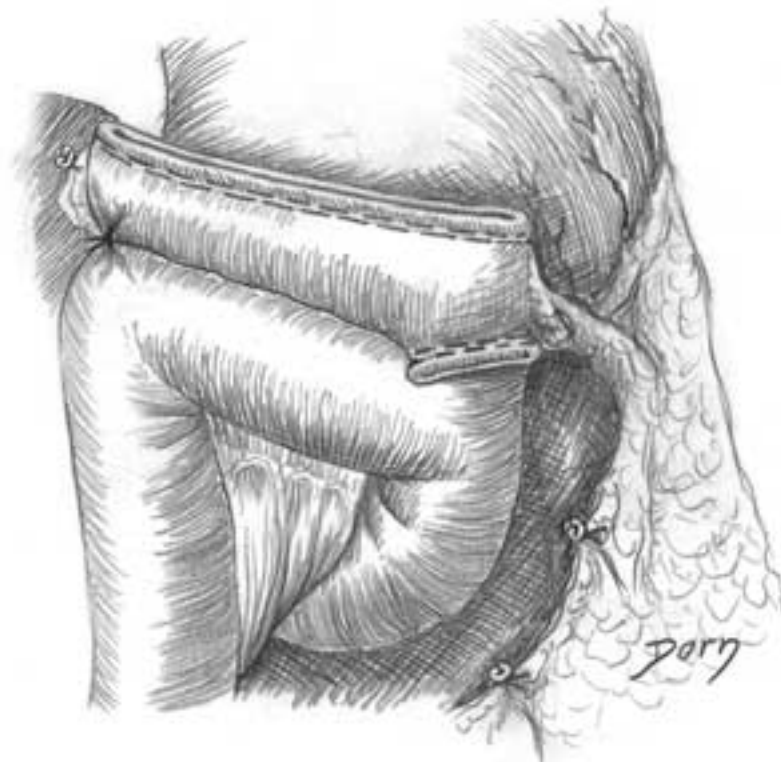
---

**H, I** Final view of the procedure.

**H**

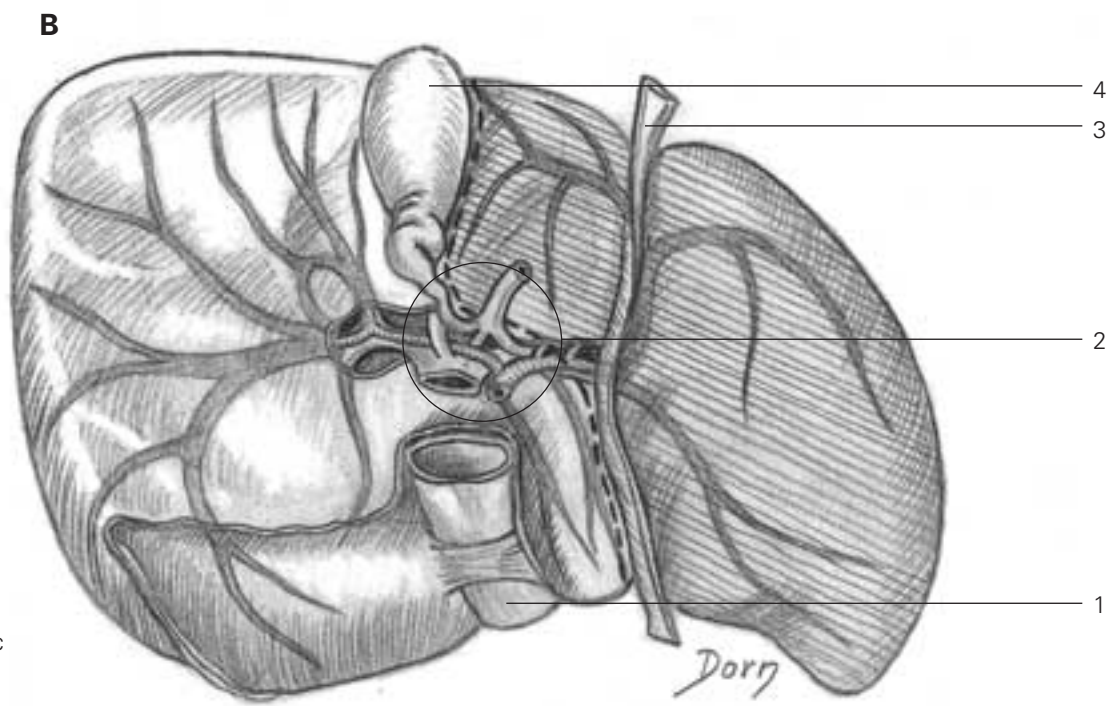
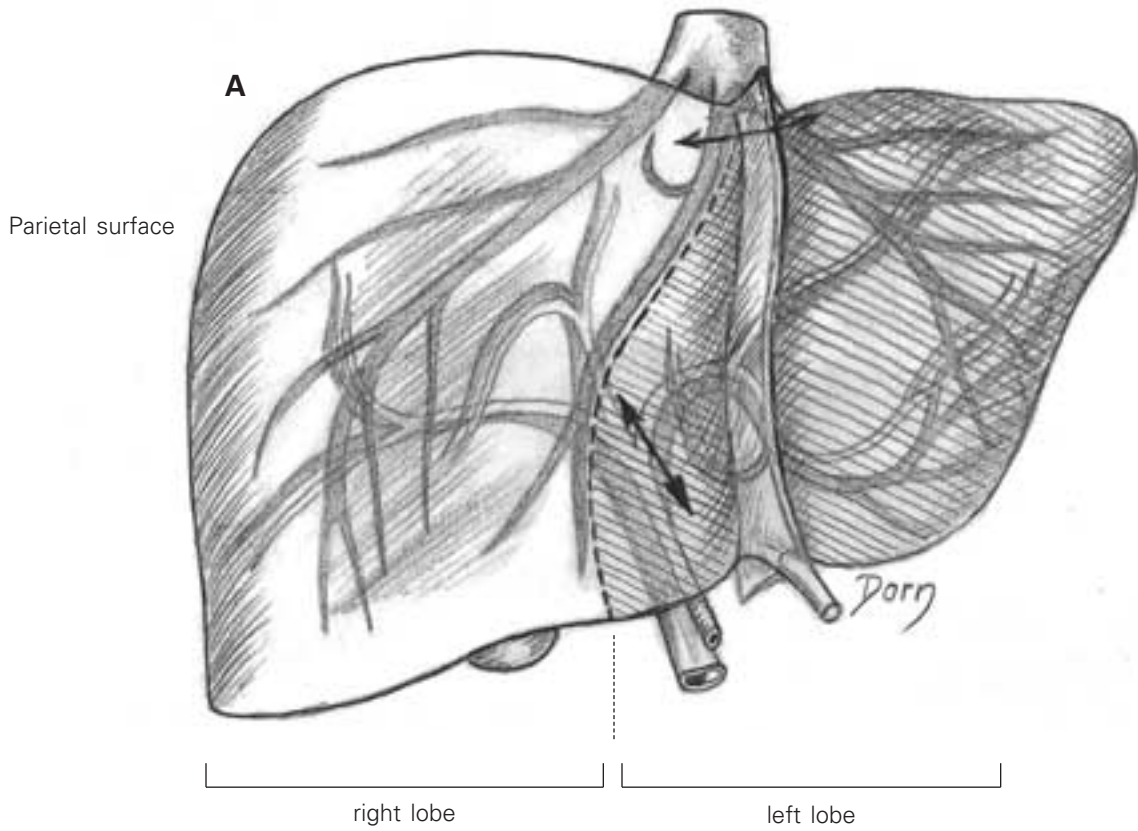


**I**



The liver

**A-B** The two lobes of the liver. Distribution of vessels and cuts.



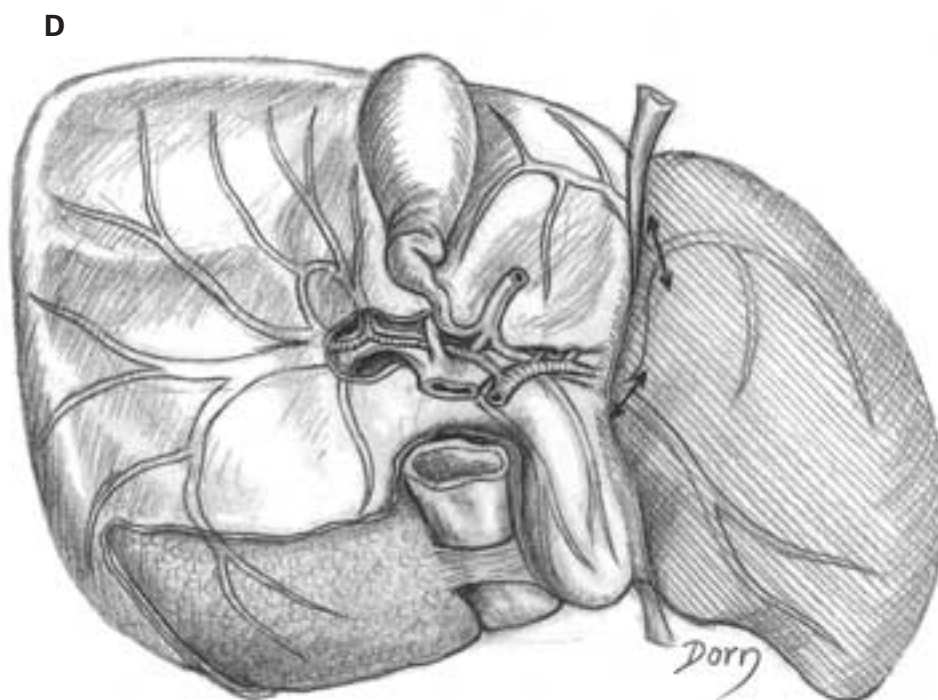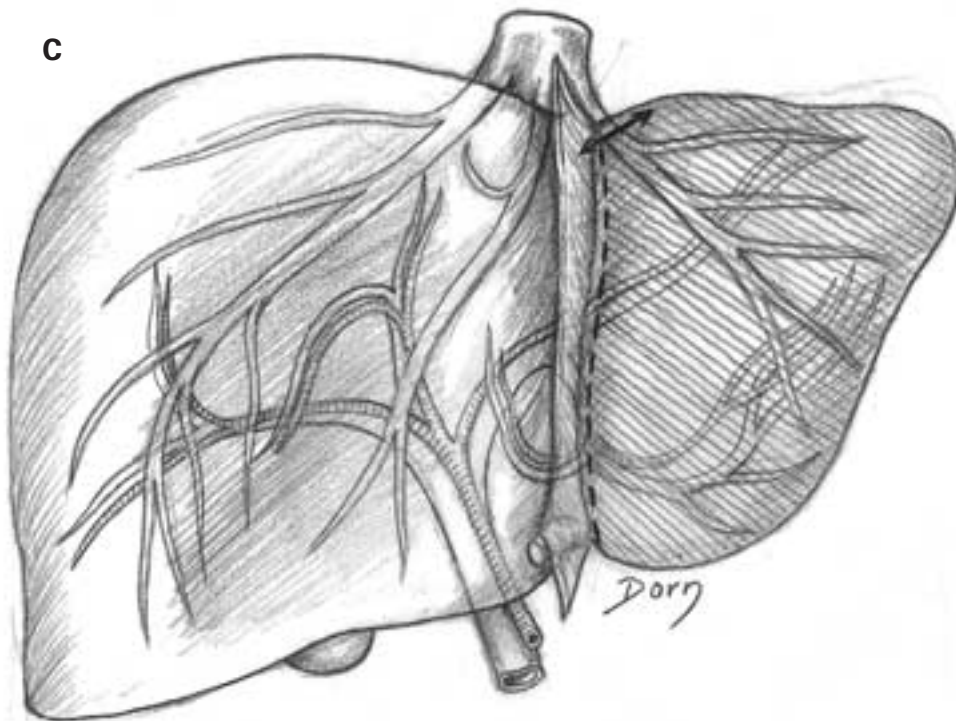
- 1 inferior vena cava
- 2 common hepatic duct, portal vein and proper hepatic artery
- 3 round ligament
- 4 gall bladder



# Abdominal surgery

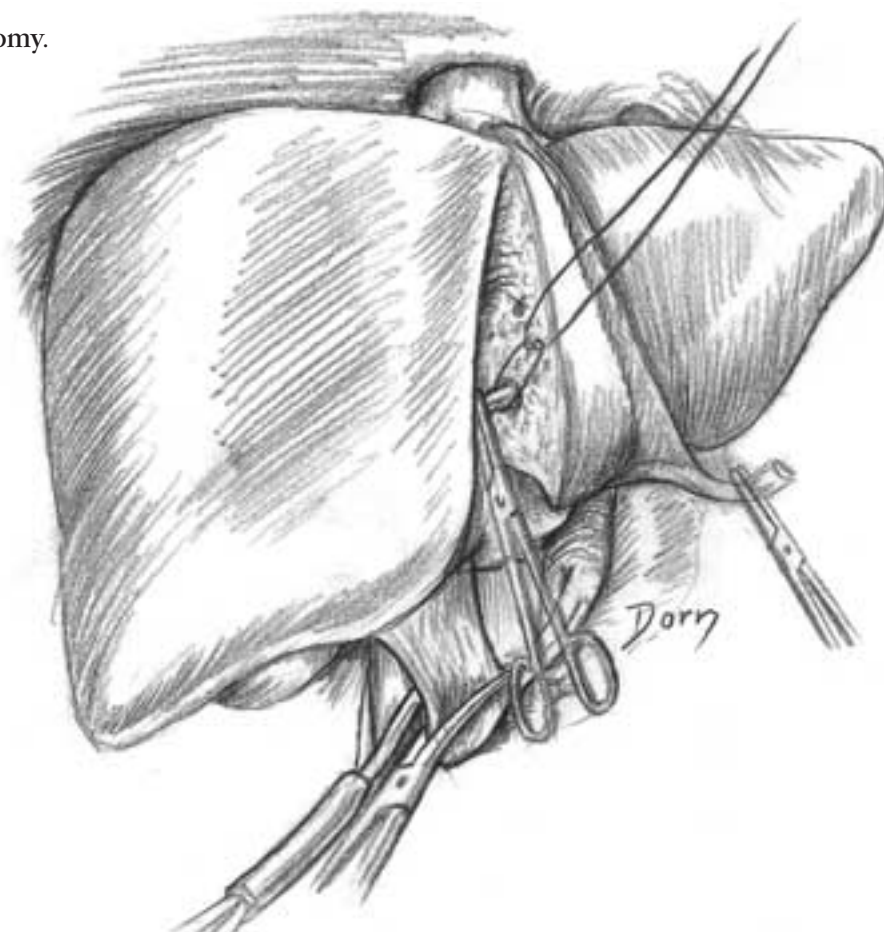
---

**C, D** Anatomic variation of the distribution. The left lobe is less developed.

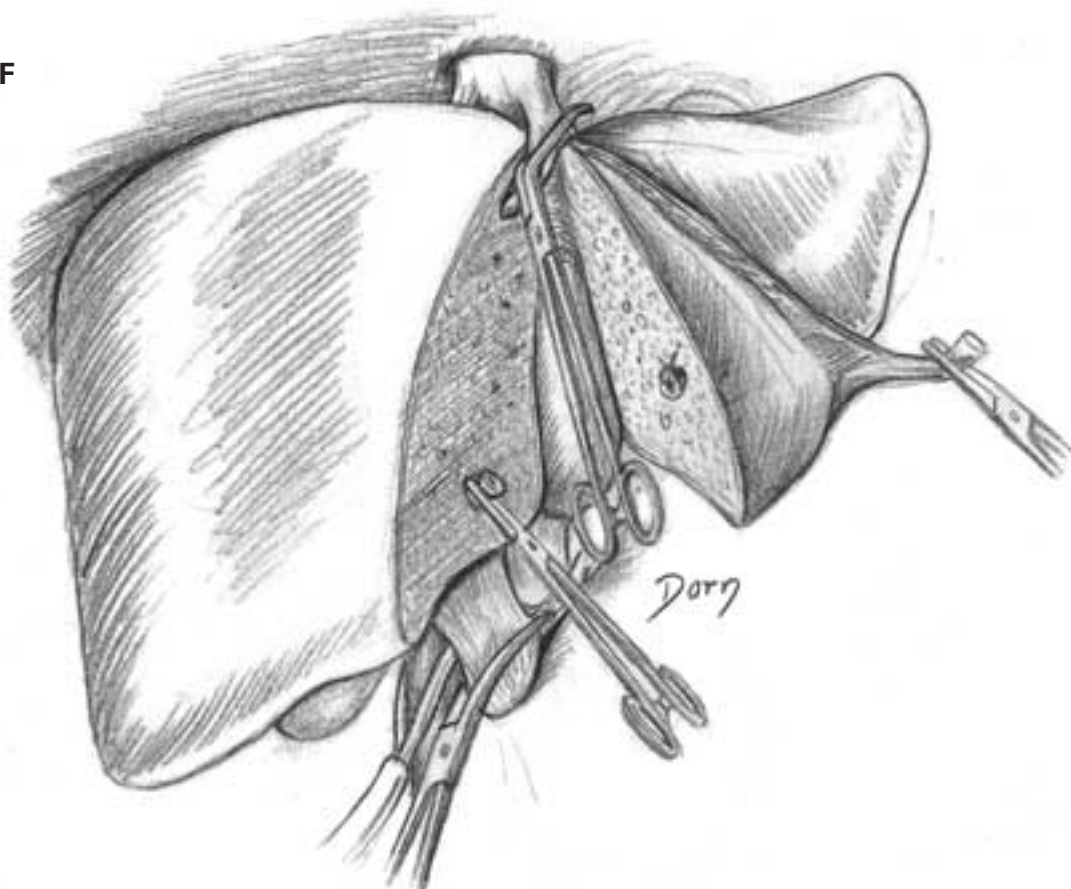


E, F Left hepatectomy.

E



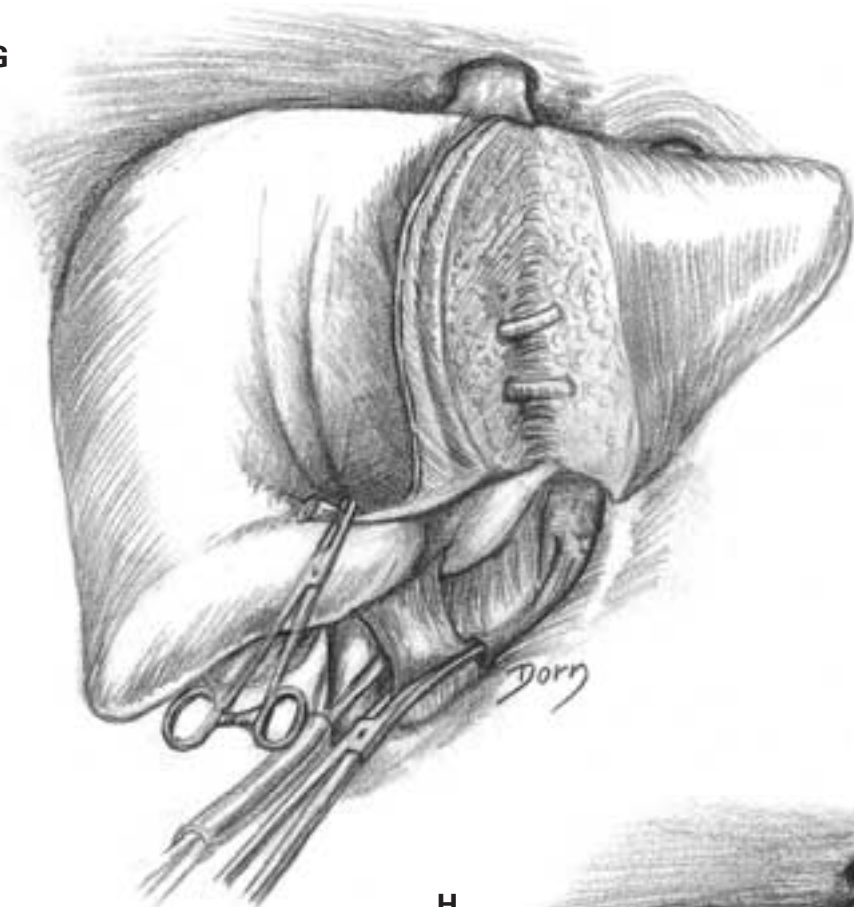
F



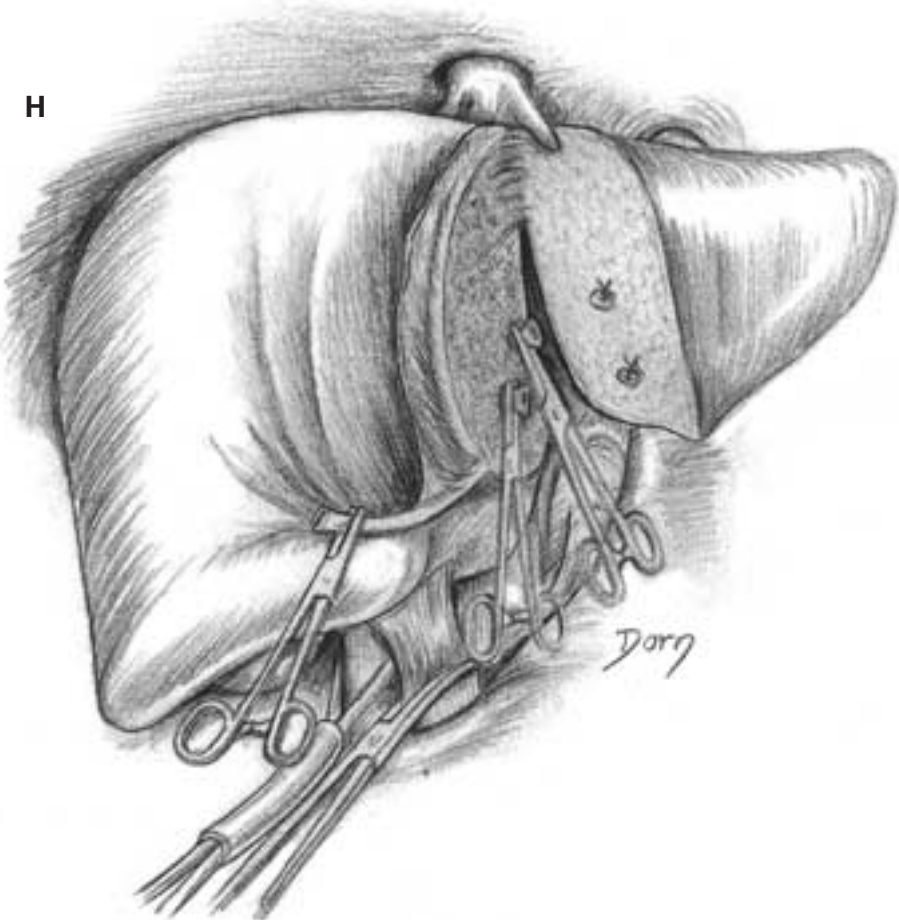
# Abdominal surgery

G, H Partial left hepatectomy.

G



H



# Surgery of the vertebral column

The following chapter is in a less complete or definitive fashion since the drawings were made a long time ago and many sketches were lost. However, this

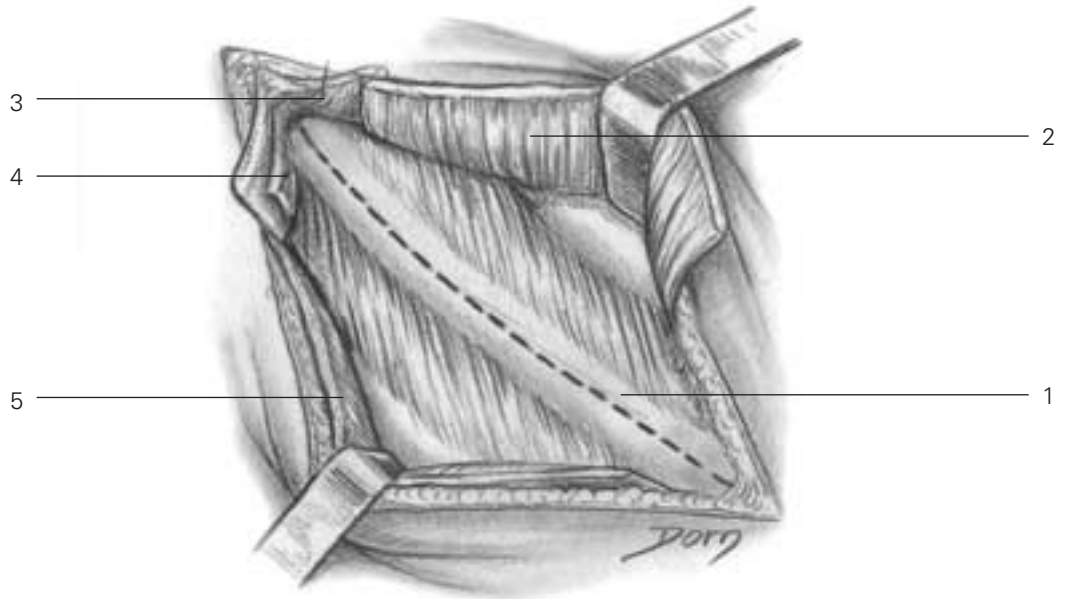
presentation allows us to appreciate the artistic skills of Léon Dorn, whatever the field of anatomy or surgery.

# Surgery of the vertebral column

## Transpleural approach to the dorsal rachis by thoracotomy

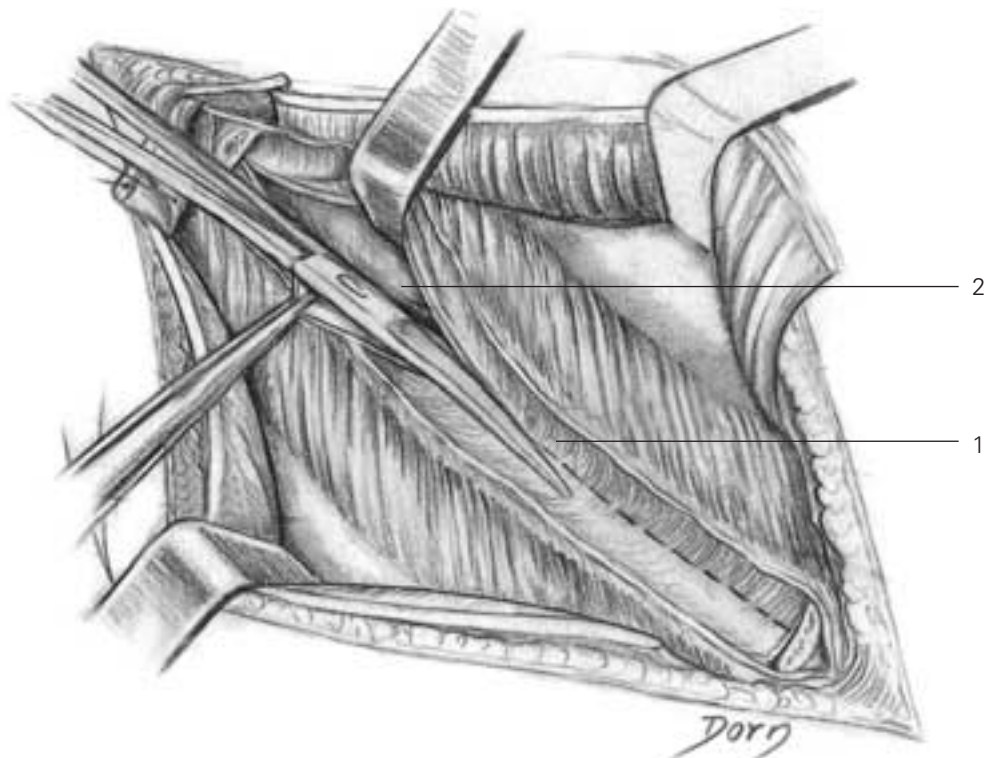
**A** The posterolateral incision is at the level of the sixth rib. The latissimus dorsi muscle is severed.

- A**
- 1 sixth rib
  - 2 latissimus dorsi
  - 3 trapezius
  - 4 rhomboid
  - 5 latissimus dorsi

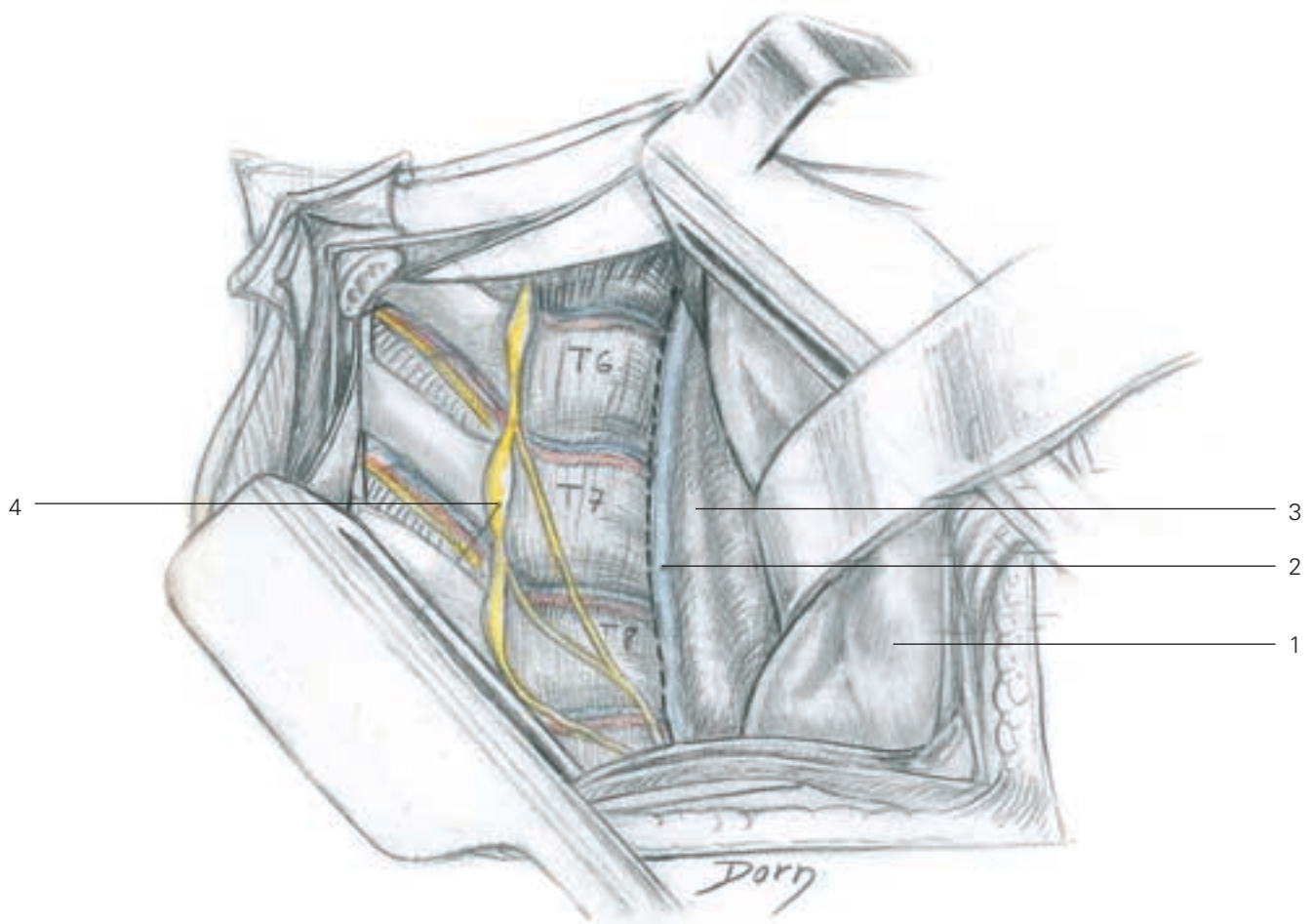


**B** A segment of rib has been removed. The pleura is incised.

- B**
- 1 incision of the periosteum
  - 2 parietal pleura



**C** Exposure of the dorsal rachis; the oesophagus, azygos vein and lung are gently retracted.



- C**
- 1 pleura and lung retracted
  - 2 azygos vein
  - 3 oesophagus
  - 4 sympathetic trunk and ganglia

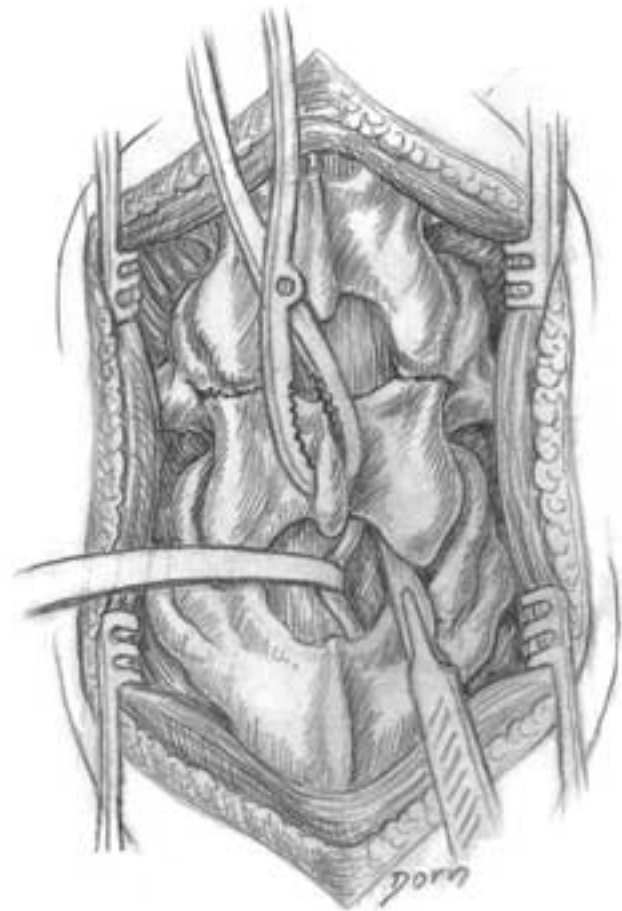
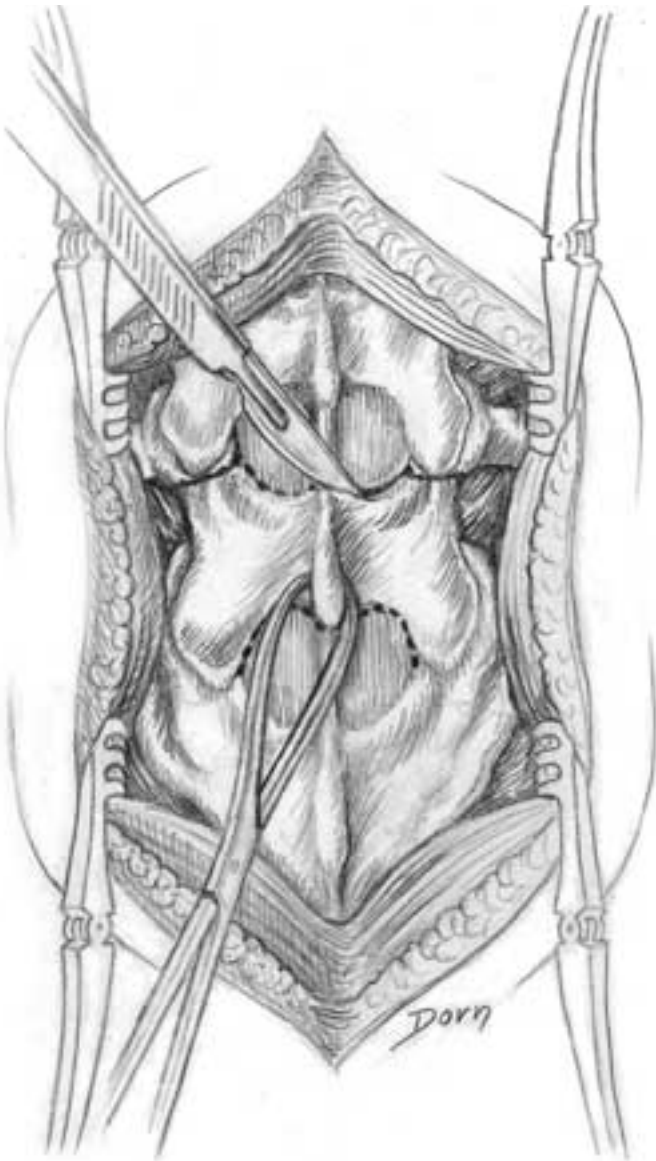
# Surgery of the vertebral column

## Treatment of lumbar spondylolisthesis

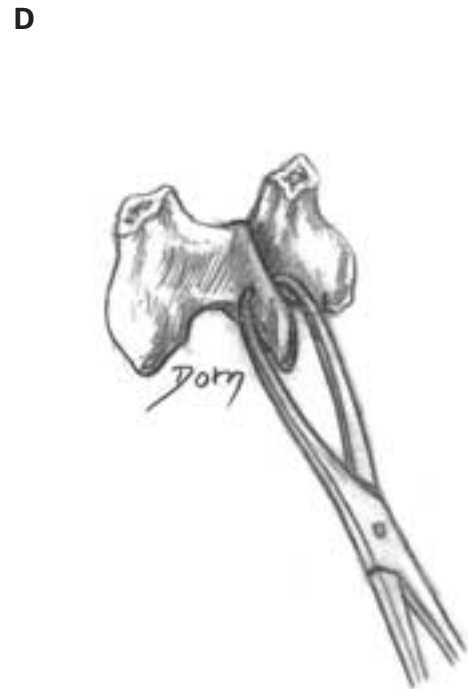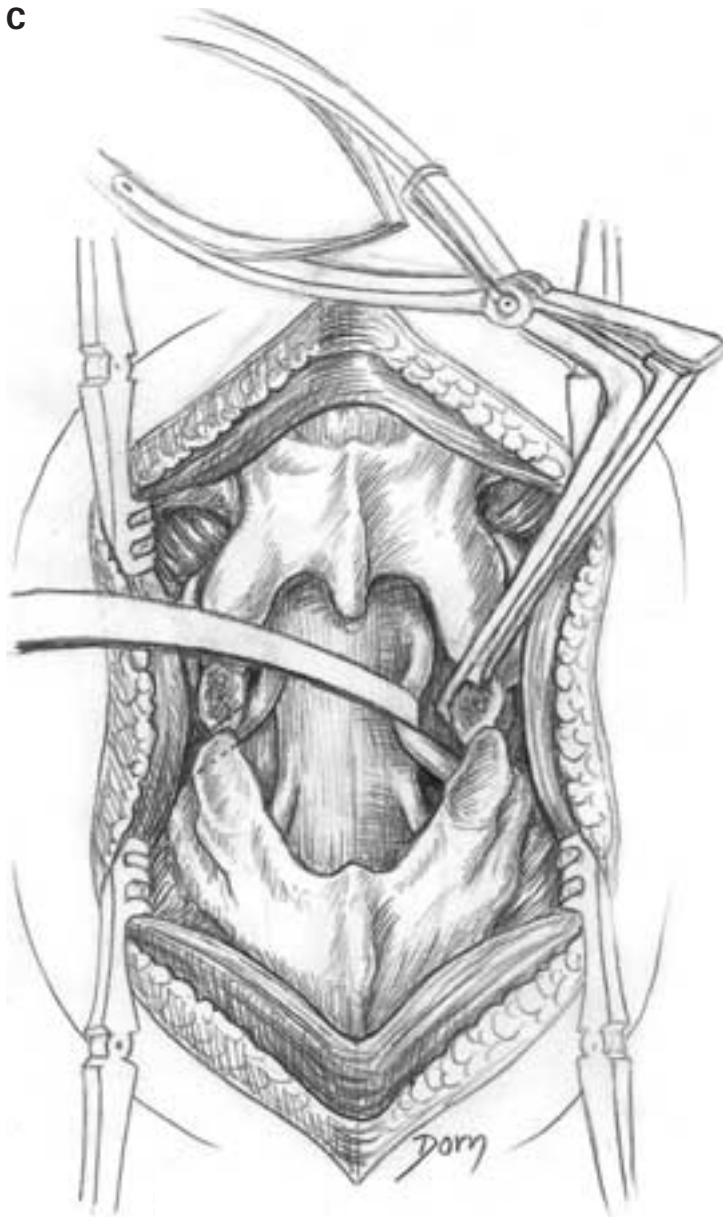
The surgical technique consists of the resection of the posterior segment of a vertebra and corporeal fusion with the underlying vertebra.

**A** After exposure of the affected vertebra the ligamentum flavum is excised.

**B** The inferior joints are opened and the capsule is excised. The superior articular facets are osteotomised.



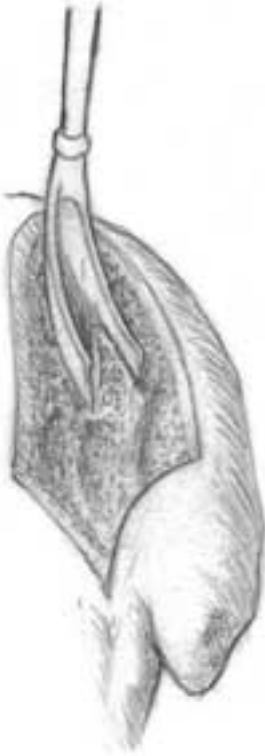**C, D** The whole of the posterior portion of the vertebra is removed. The spinal cord is freed.



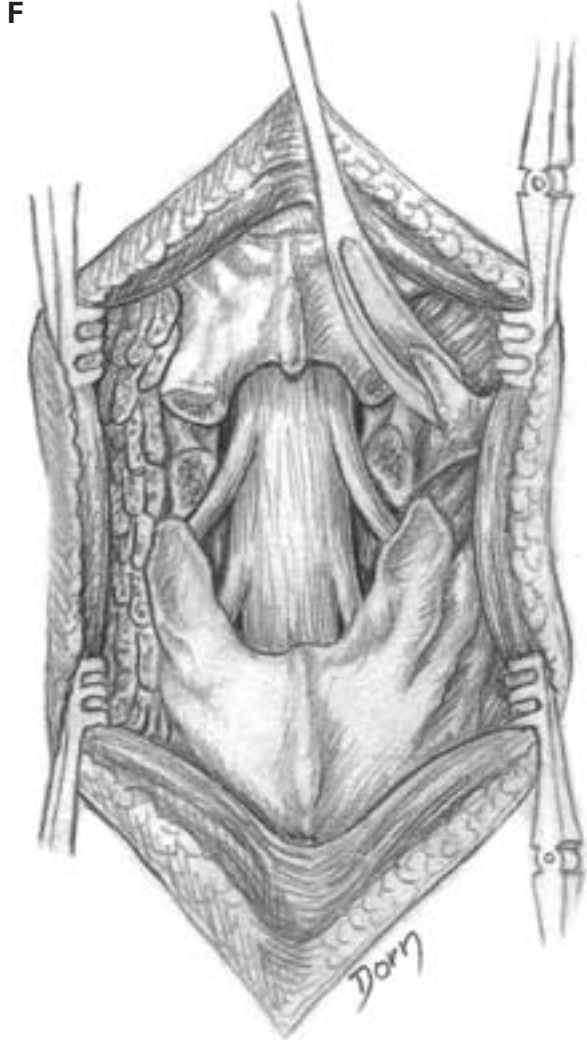


# Surgery of the vertebral column

**E** Harvesting cancellous bone from the posterior iliac crest.

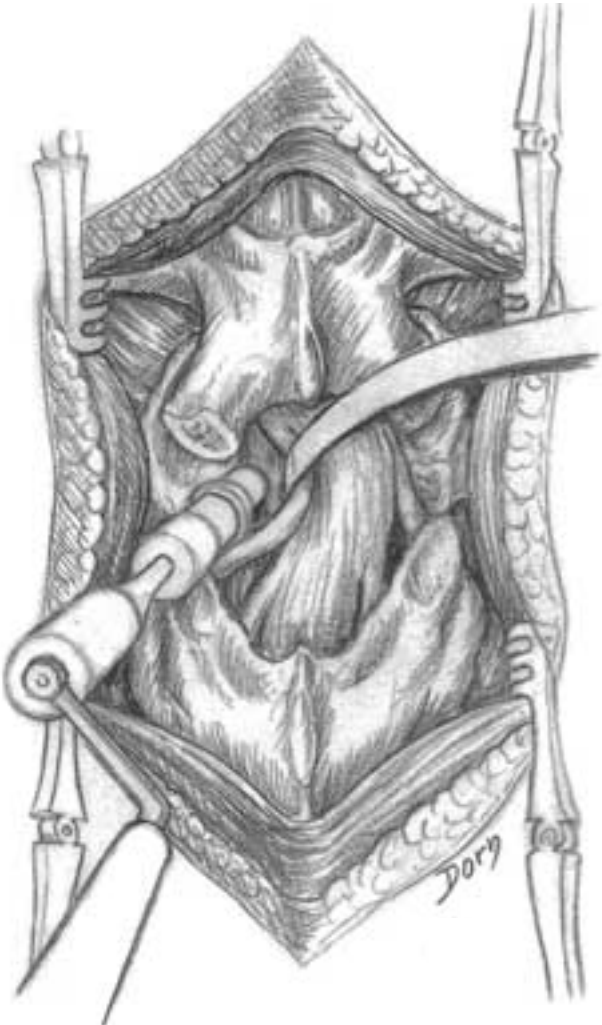

**F** A posterolateral fusion is prepared by putting small chips of cancellous bone on the transverse processes.

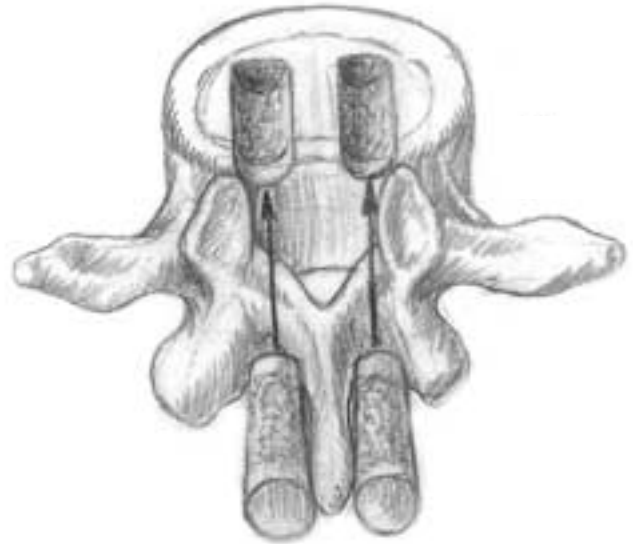


**G, H** An intersomatic fusion by the same posterior approach can be combined with the posterolateral fusion or it can be performed as an alternative by the anterior approach.

**G**



**H**

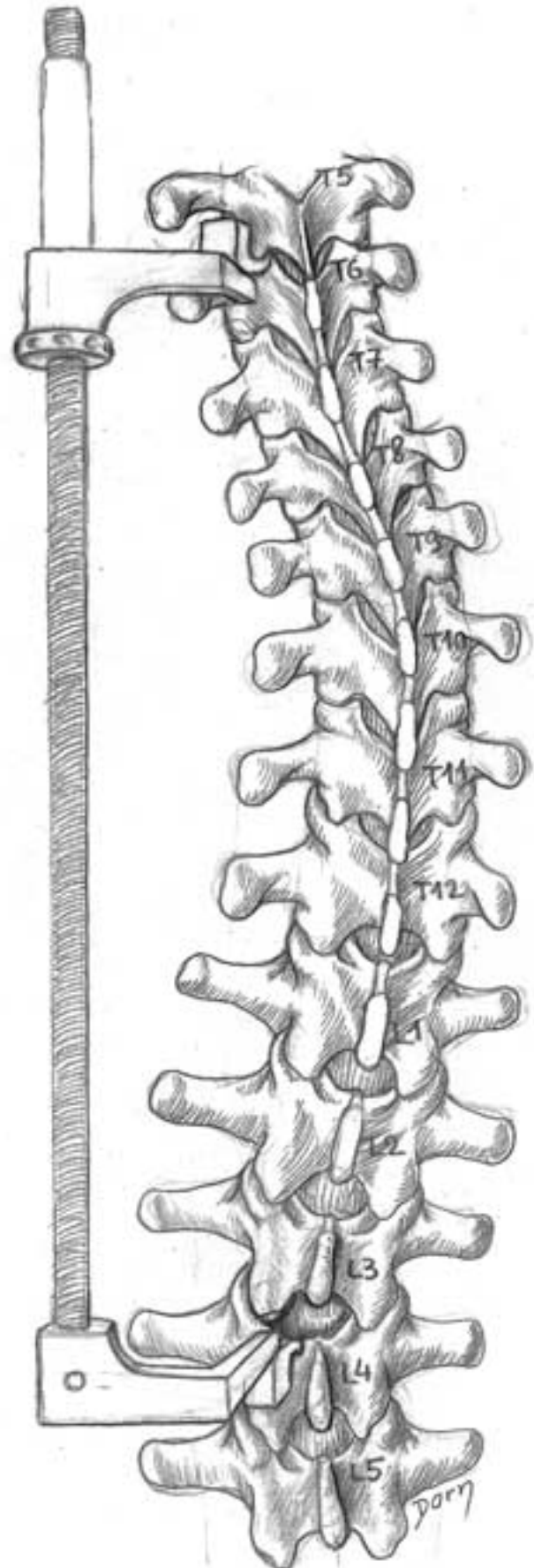


# Surgery of the vertebral column

## Surgical treatment of scoliosis

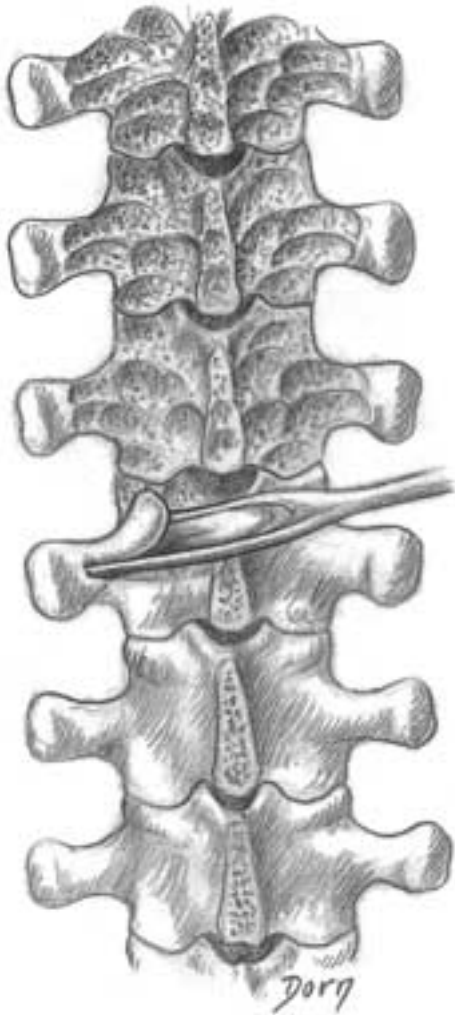Different devices have been described for correction of scoliosis. This series of illustrations presents Harrington's rod, which is now considered obsolete.

**A** The principle of Harrington's procedure. The rod is used in distraction to correct the curvature; the extremities of the rod are fixed by hooks which are applied on the laminae of the vertebrae.

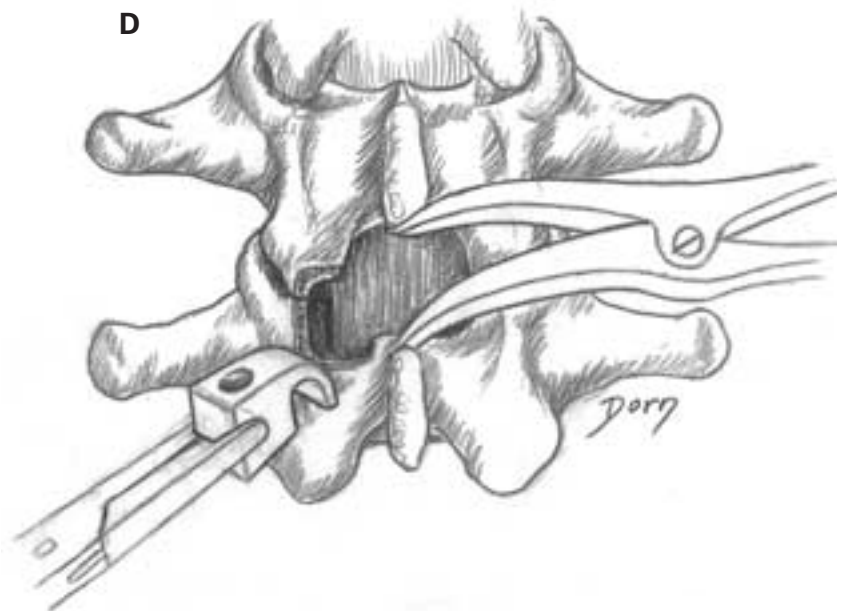
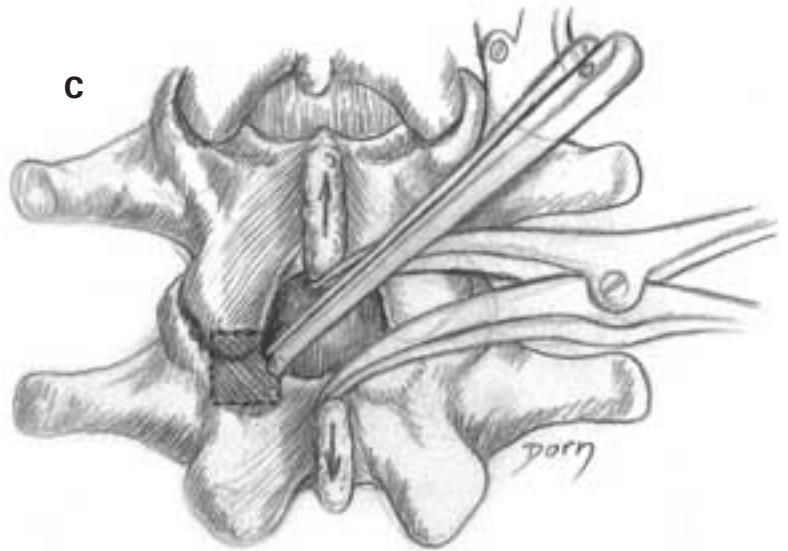


# Surgery of the vertebral column

**B** Small bone chips of the posterior segments of the vertebrae are removed to prepare the posterior fusion.



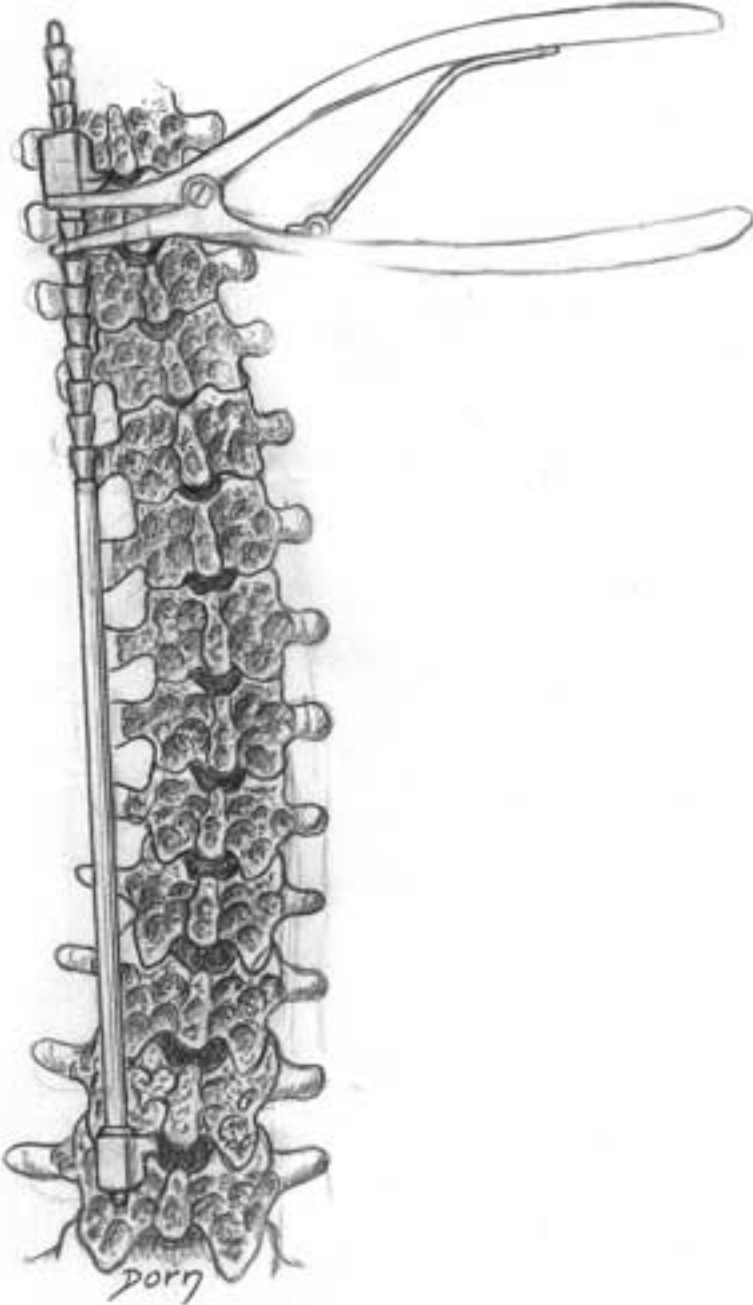
**C, D** The inferior hook is put in place; partial bone resection is needed.



# Surgery of the vertebral column

---

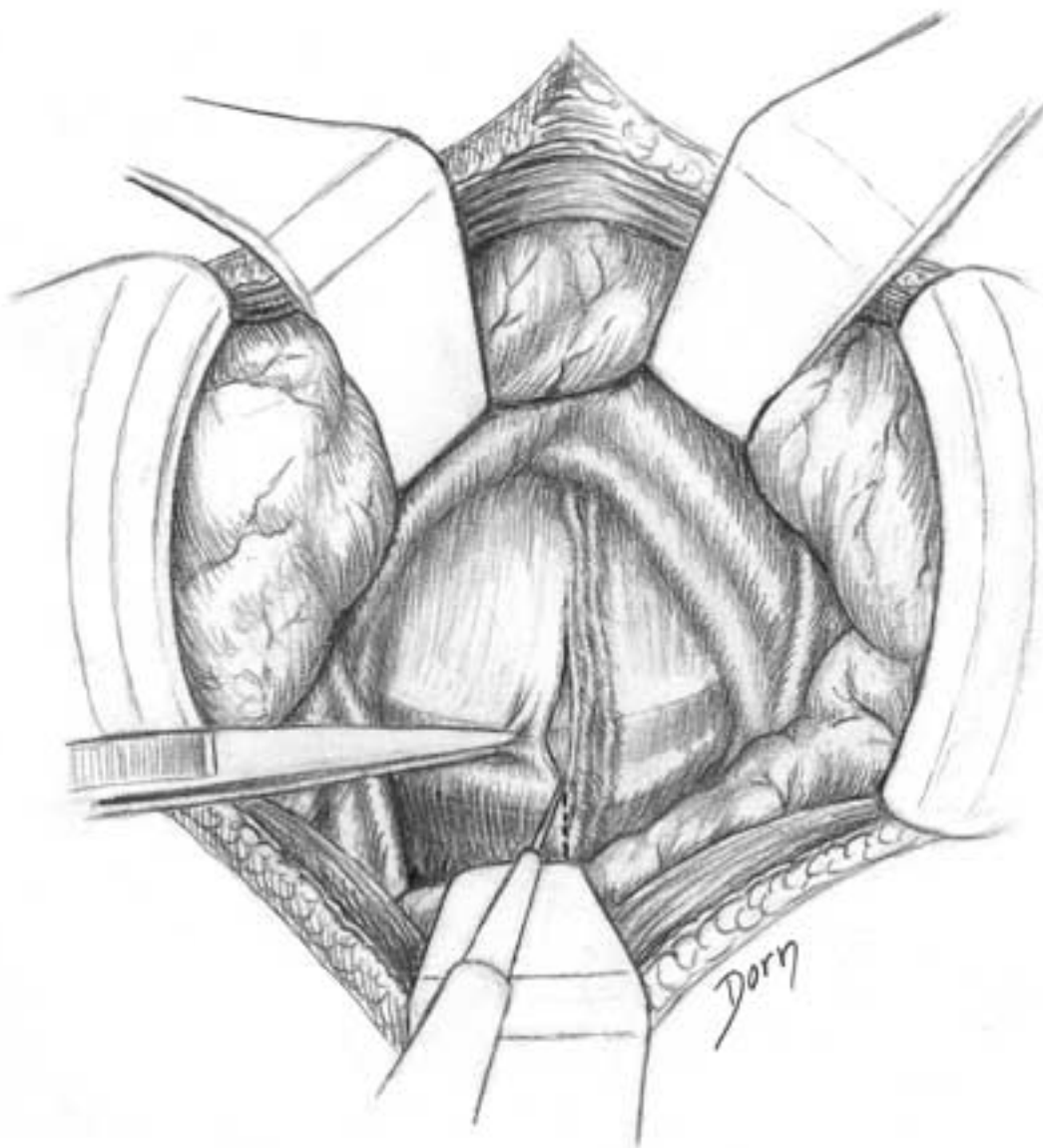E Setting Harrington's rod and distraction to correct the curvature.



## Treatment of lumbar disc hernia: anterior approach

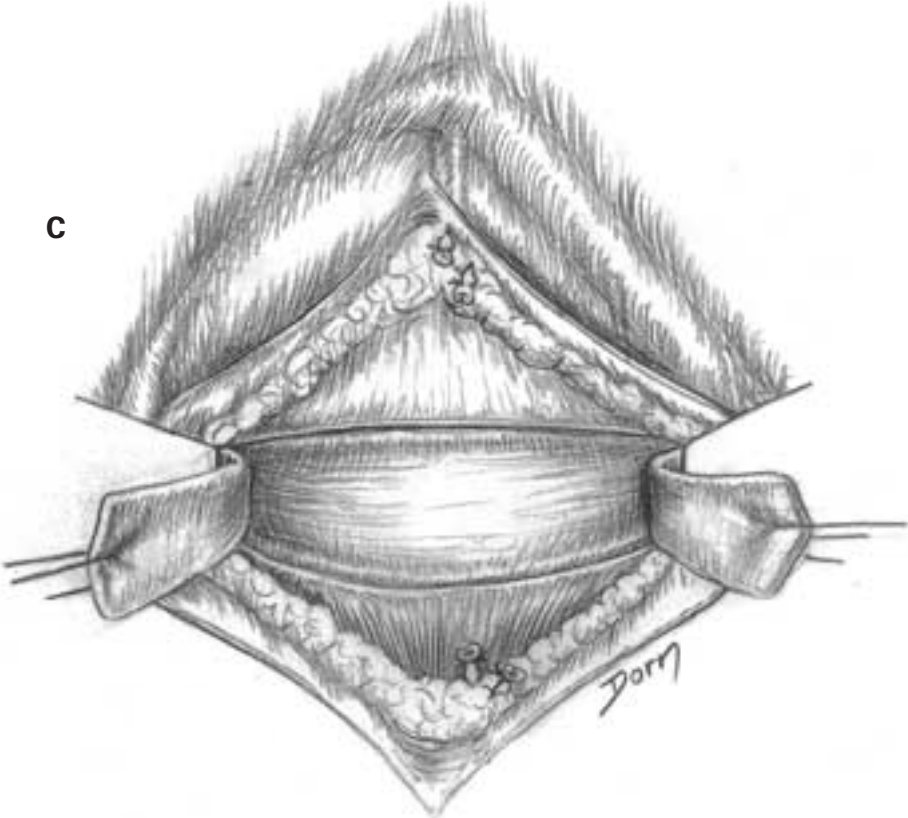
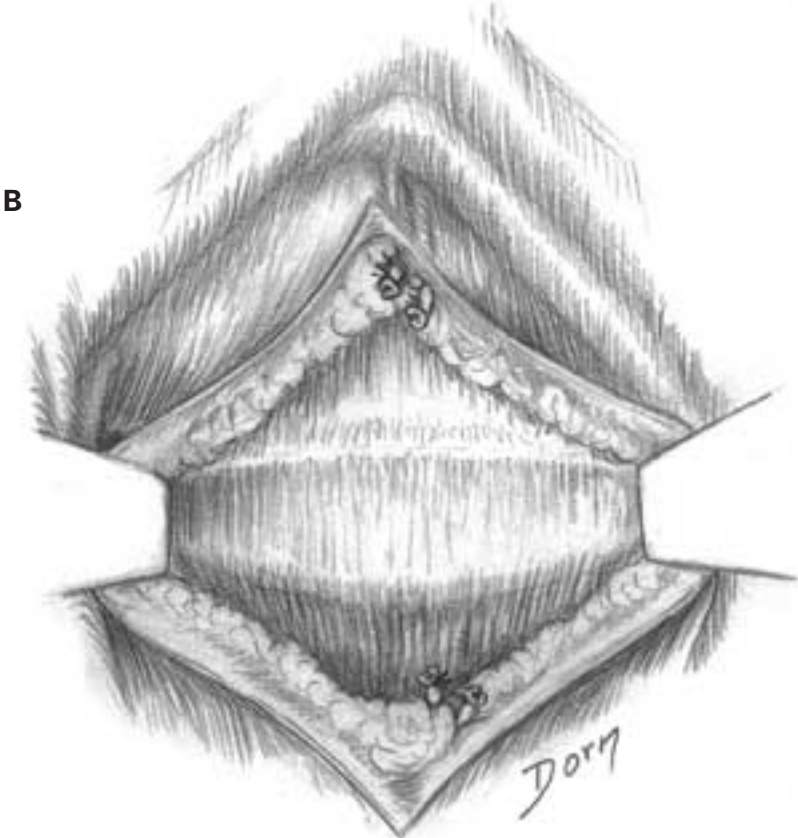
The anterior approach to remove a disc hernia at the lumbosacral level is usually not used. It is only indicated when an intersomatic fusion is performed in the same operation; the risk is a lesion of the superior hypogastric plexus.

**A** A transperitoneal approach is made. The organs are retracted. The sacral promontory is exposed and the posterior peritoneum is incised.

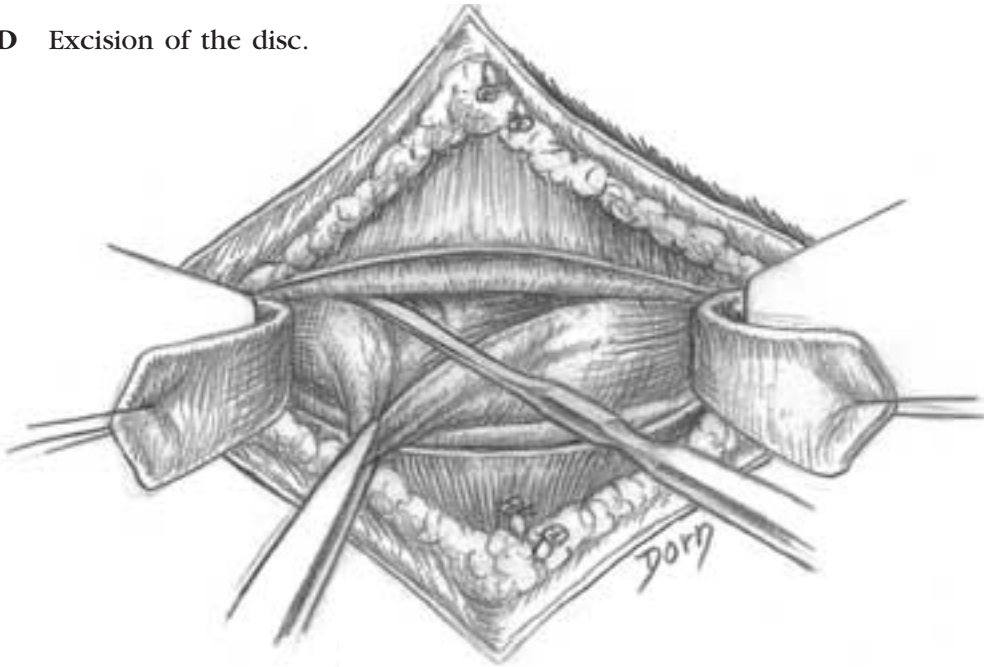


# Surgery of the vertebral column

**B, C** The disc is exposed and the anterior longitudinal ligament is opened.

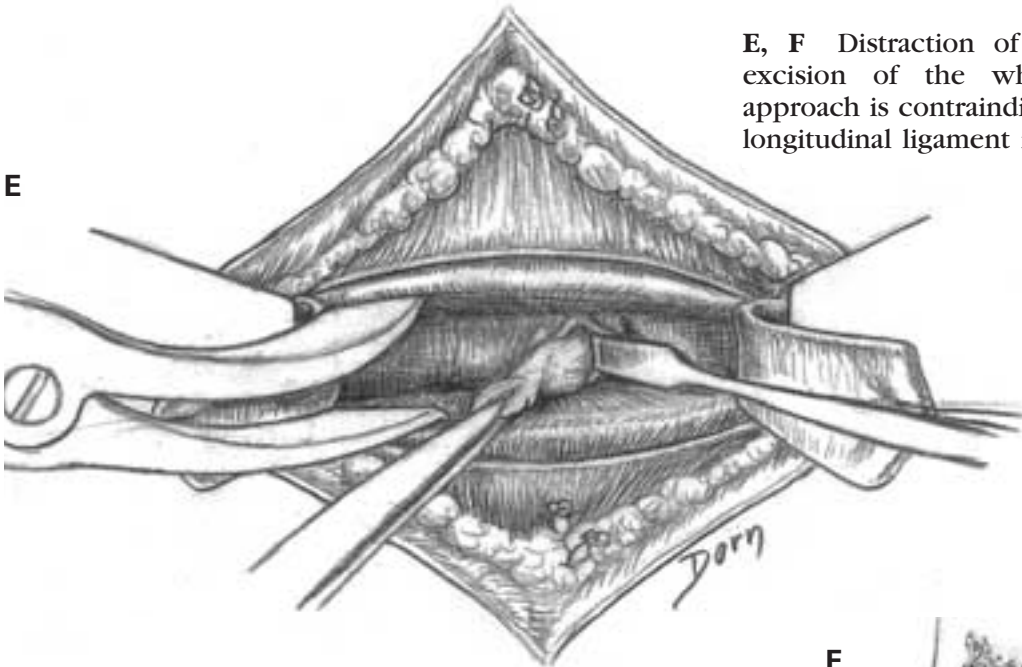


**D** Excision of the disc.

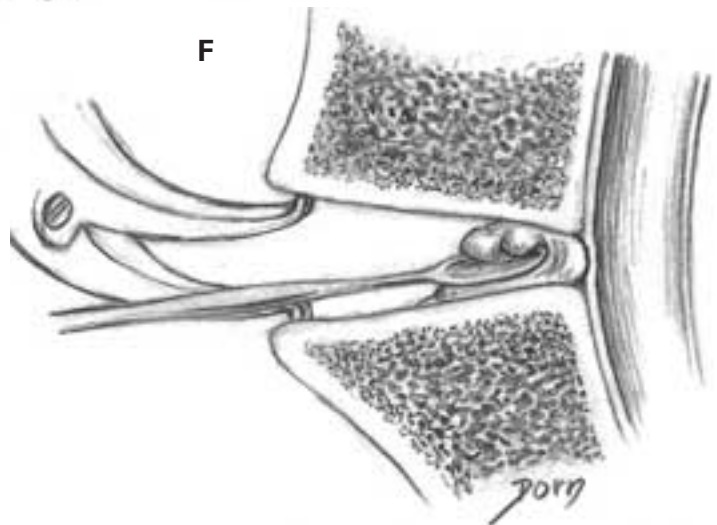


**E, F** Distraction of vertebral bodies allows excision of the whole disc. The anterior approach is contraindicated when the posterior longitudinal ligament is ruptured.

**E**



**F**







# Upper limb surgery

Surgery of the upper limb has increasingly gained interest over the past 20 years. This is due to the major development of the surgery of the hand, which is equally performed by orthopaedic and plastic surgeons. Moreover many recent advances have been made in the field of surgery of the shoul-

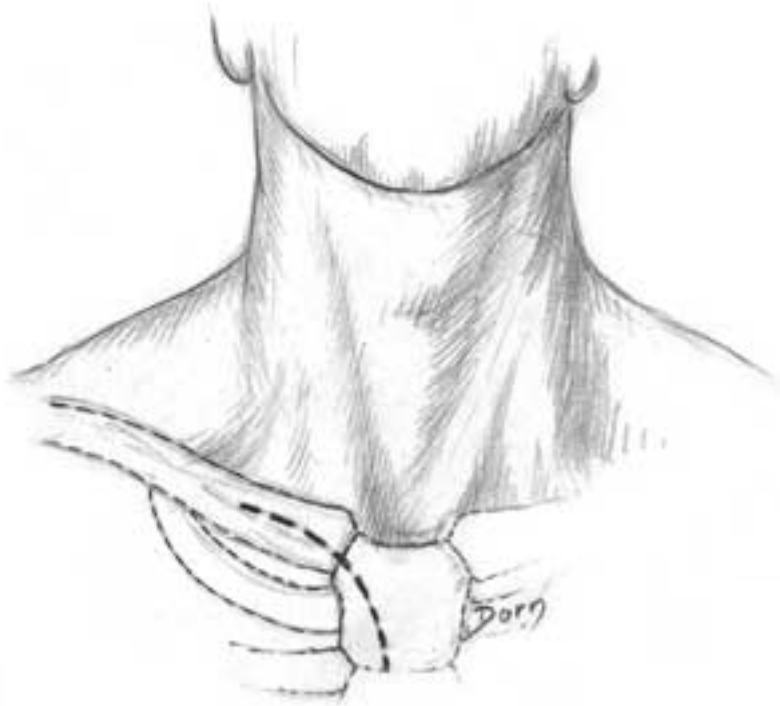
der and elbow, chiefly in relation to the possibilities offered by arthroscopy and prosthetic replacements. Thus, we have given some examples of surgery of the upper limb in a separate section instead of including them in the chapter on surgery of the hand and wrist.

# Upper limb surgery

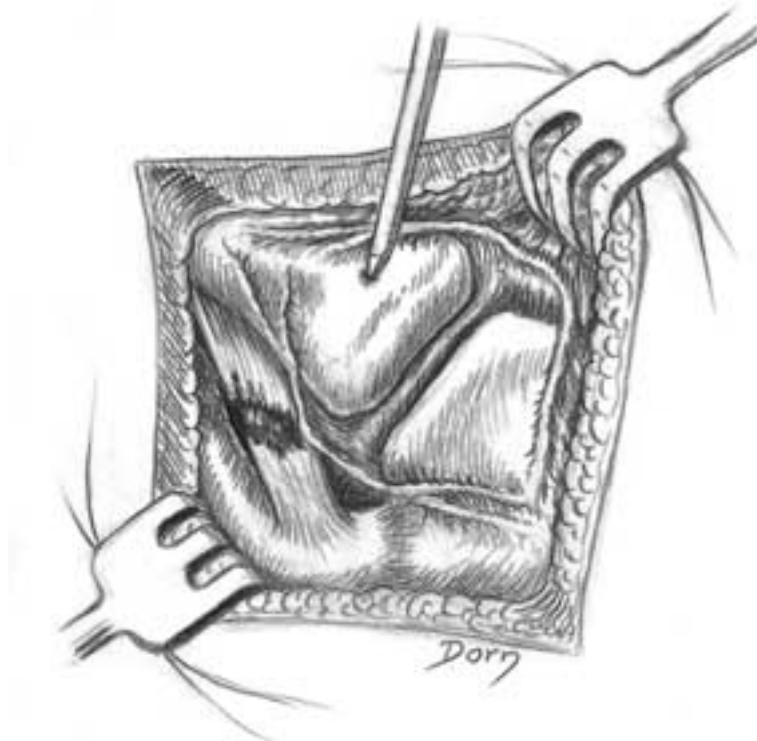---

## Sternoclavicular dislocation

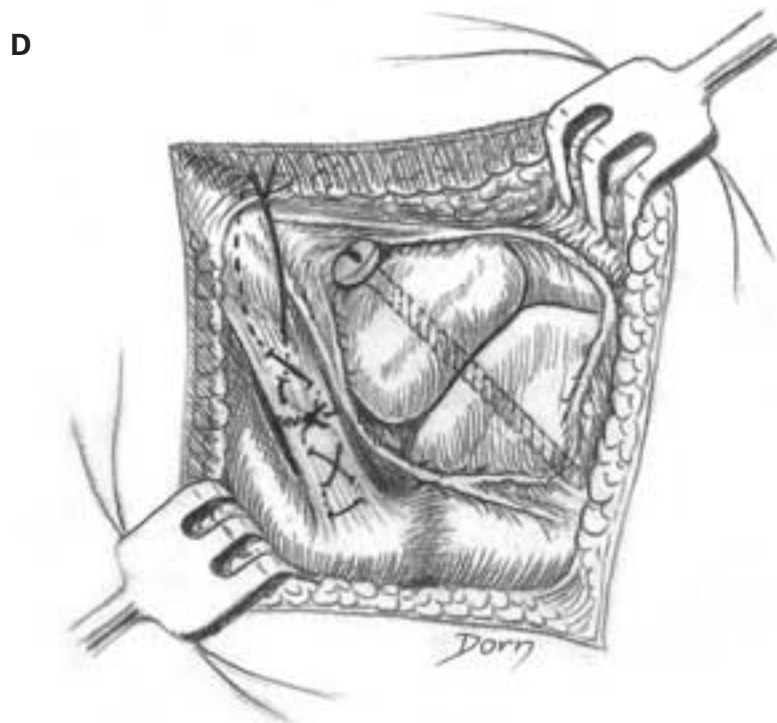
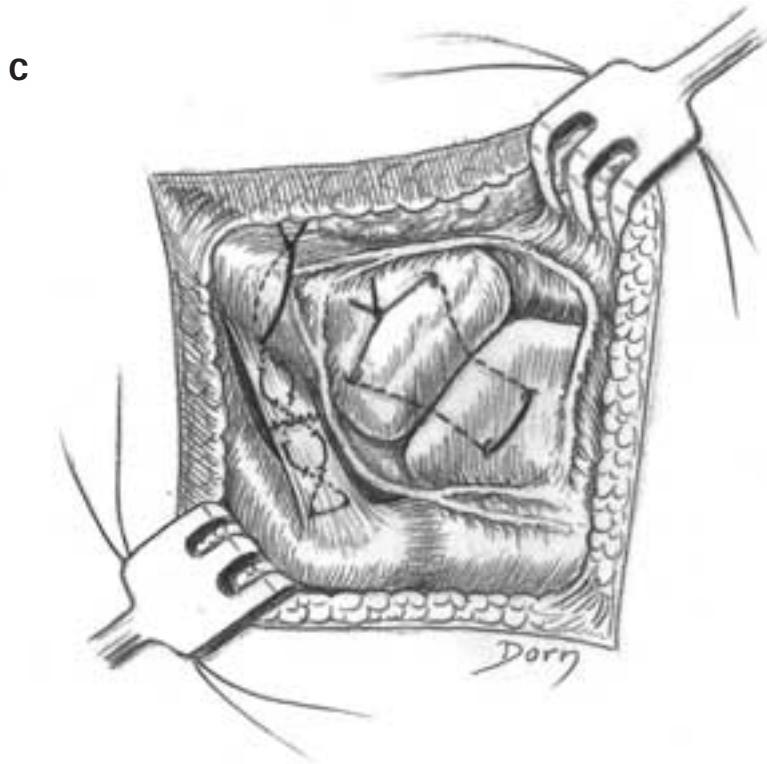
**A** Skin incision.



**B** The exposure of the sternoclavicular joint. Note the rupture of the costoclavicular ligament.



C, D Repair of the costoclavicular ligament and stabilisation by a frame or a screw.



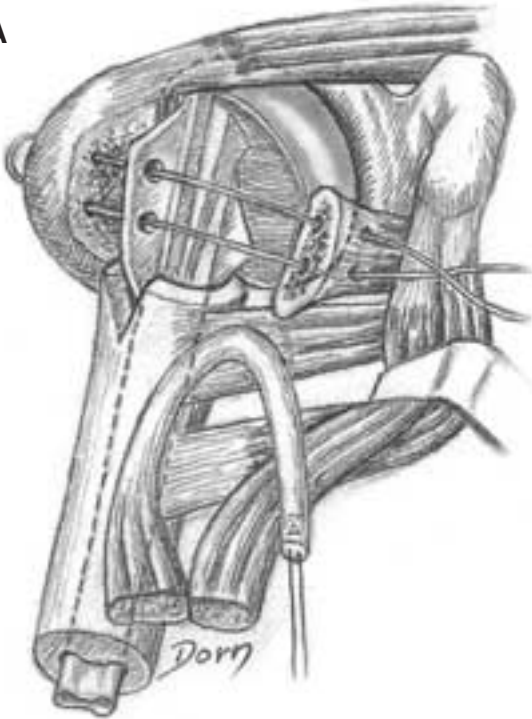
# Upper limb surgery

## Stabilisation of a shoulder prosthetic implant

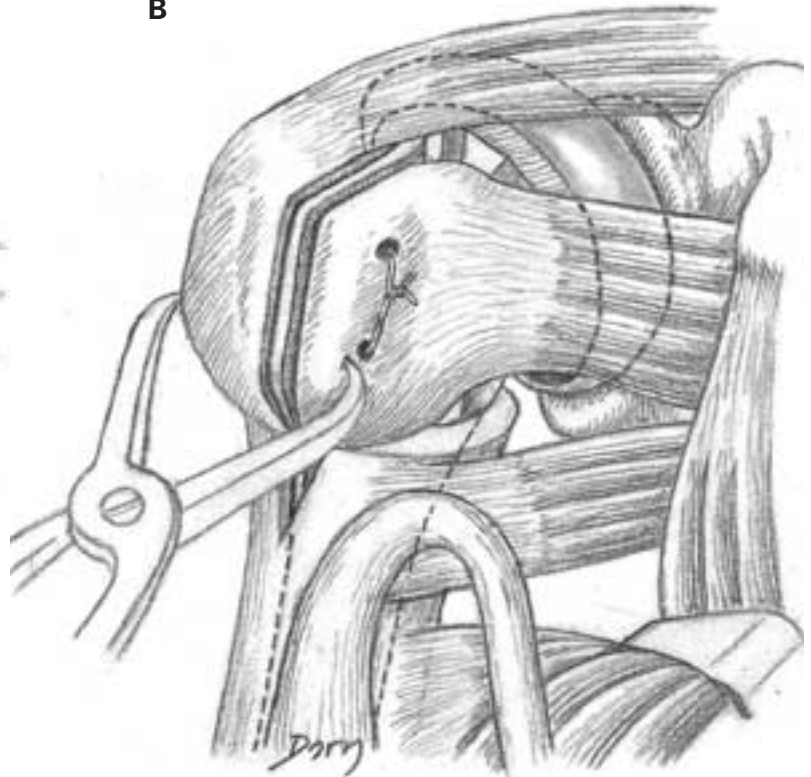
This type of implant is employed in comminutive fractures of the proximal extremity of the humerus.

**A, B** The prosthesis is put in place. The greater and the lesser tubercles are reduced on the prosthesis and firmly fixed.

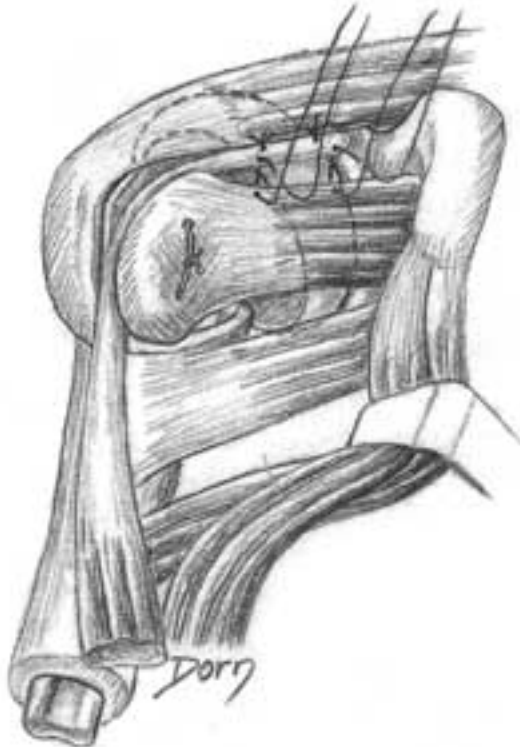
**A**



**B**



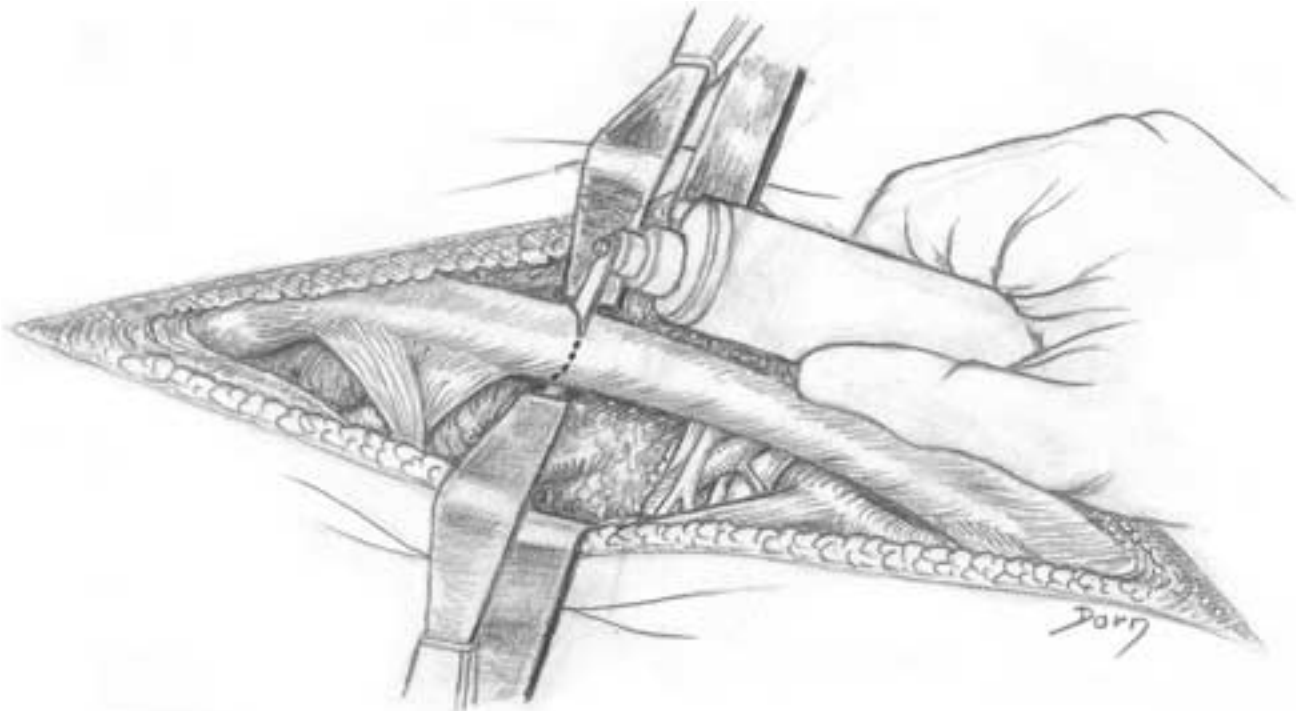
**C** The stability of the prosthesis is reinforced by the suture of the biceps tendon on the rotator cuff interval.



## Cleidectomy

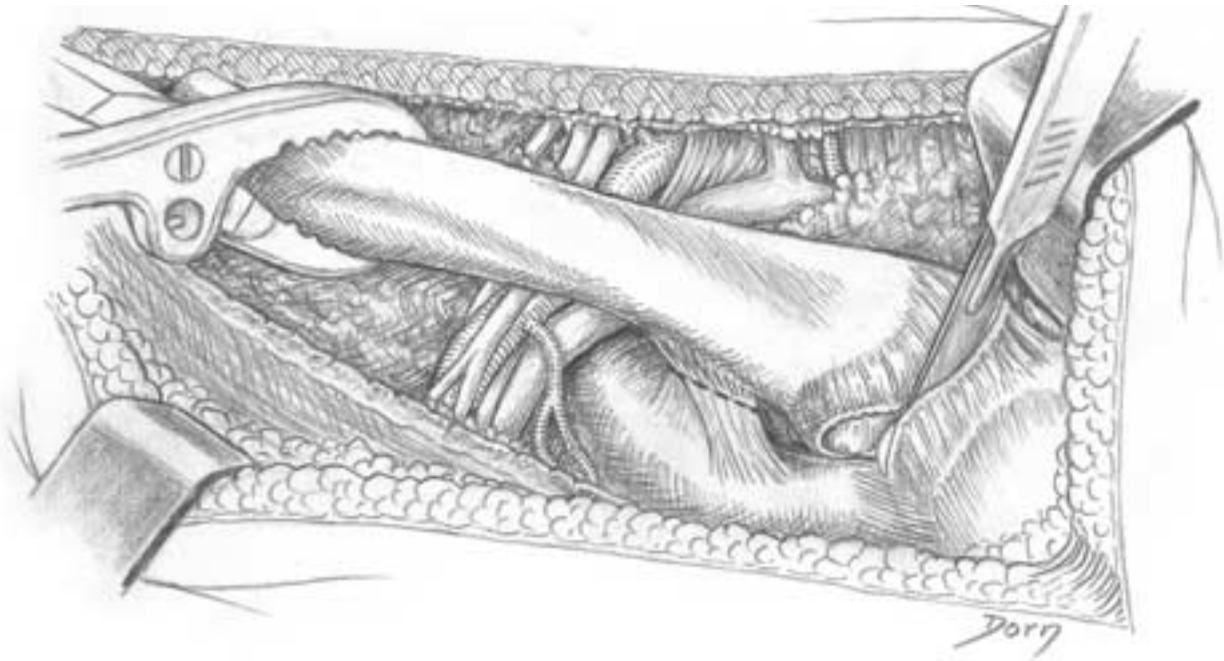
Excision of the clavicle is an uncommon procedure. It can be indicated in case of tumour.

**A** It is easier to remove the clavicle in two parts and the procedure begins by severing the clavicle. First all the muscle insertions are released.

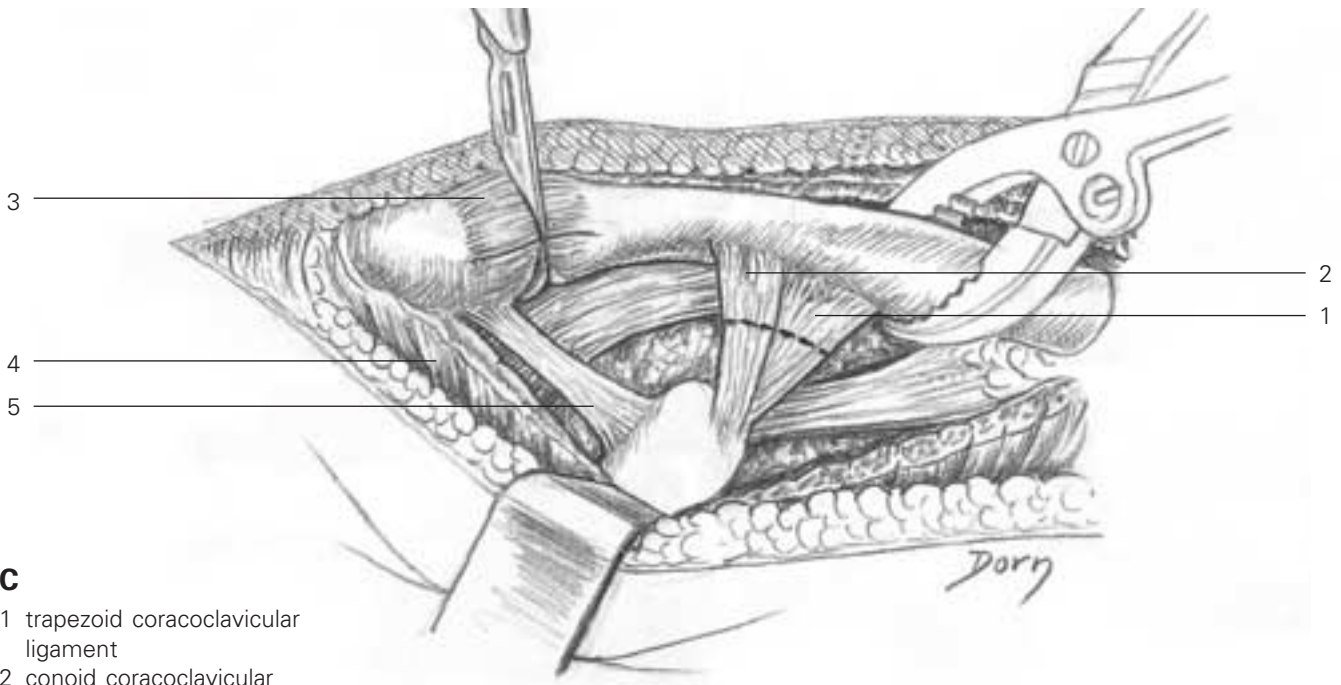


# Upper limb surgery

**B** Then the medial portion is removed by cutting the costoclavicular ligament and opening the sternoclavicular joint.



**C** The lateral part is removed by cutting the coracoclavicular ligament and opening the acromioclavicular joint.

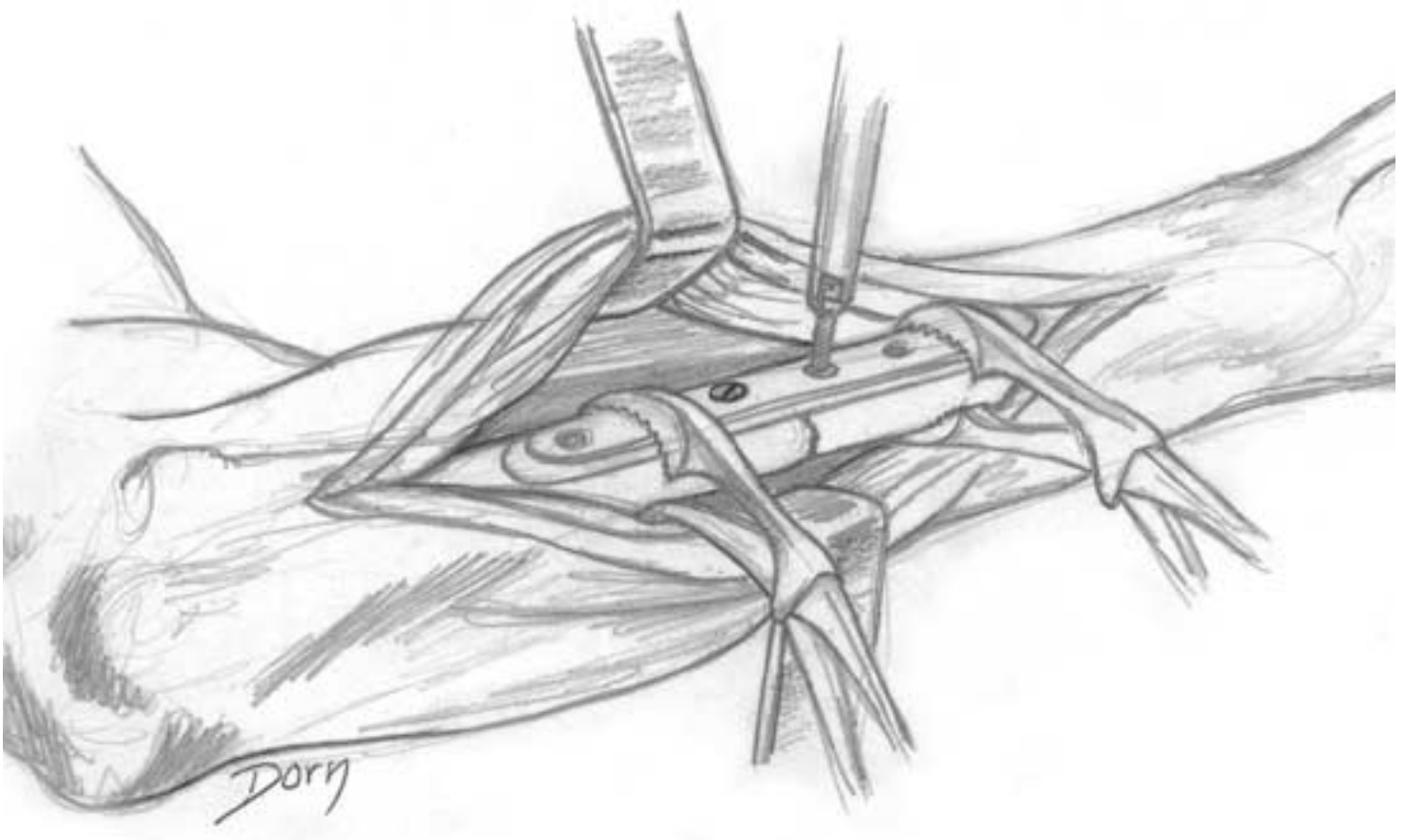


- C**
- 1 trapezoid coracoclavicular ligament
  - 2 conoid coracoclavicular ligament
  - 3 acromioclavicular capsule
  - 4 deltoid muscle
  - 5 coracoacromial ligament

Osteosynthesis of a fracture of the forearm

The following early series of drawings allows us to assess the evolution of Dorn's style. As a matter of fact, this technique was designed in 1970 for Merle d'Aubigné. Very few details are visible in the soft tissues and the shape of the bones is approximate.

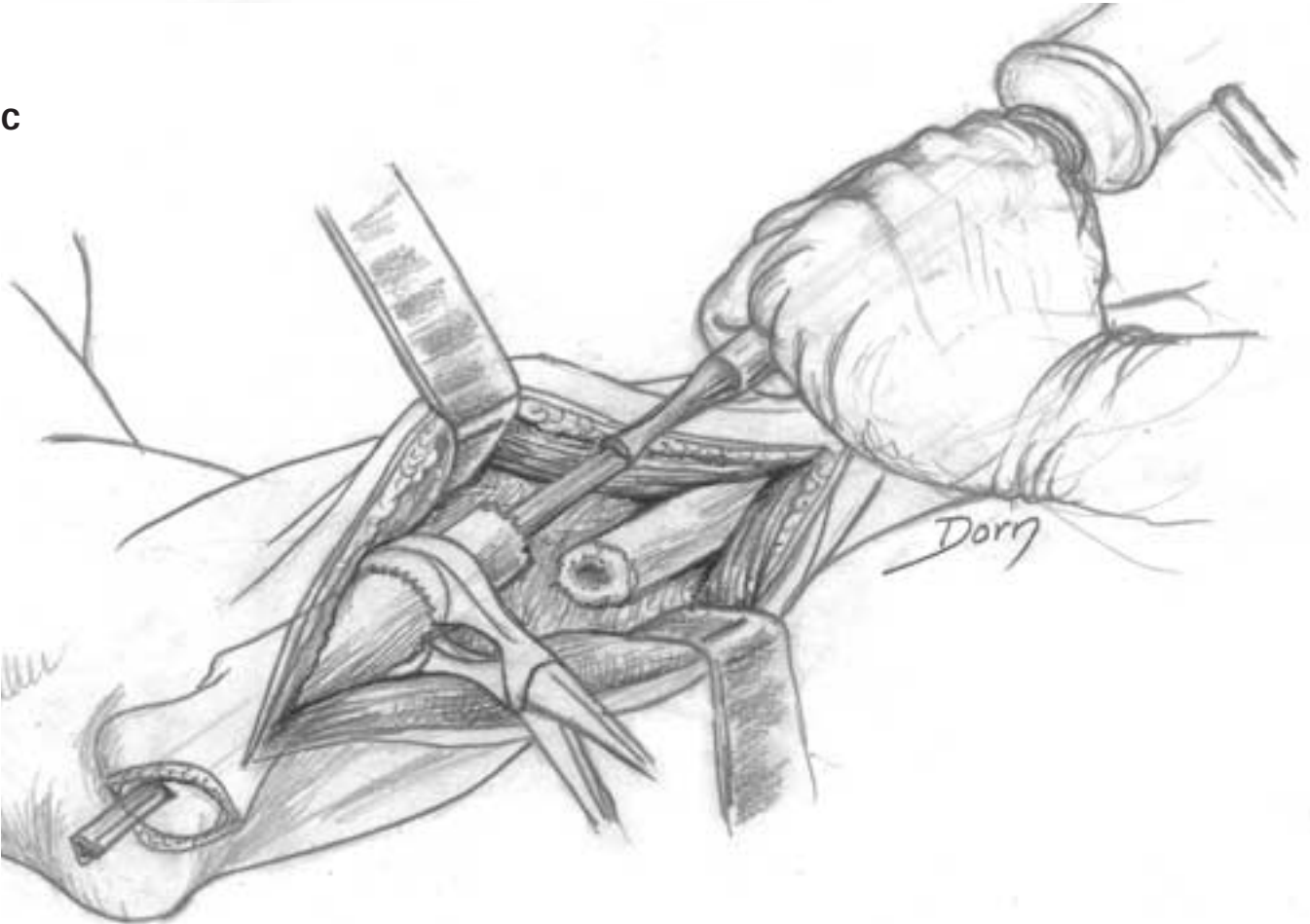
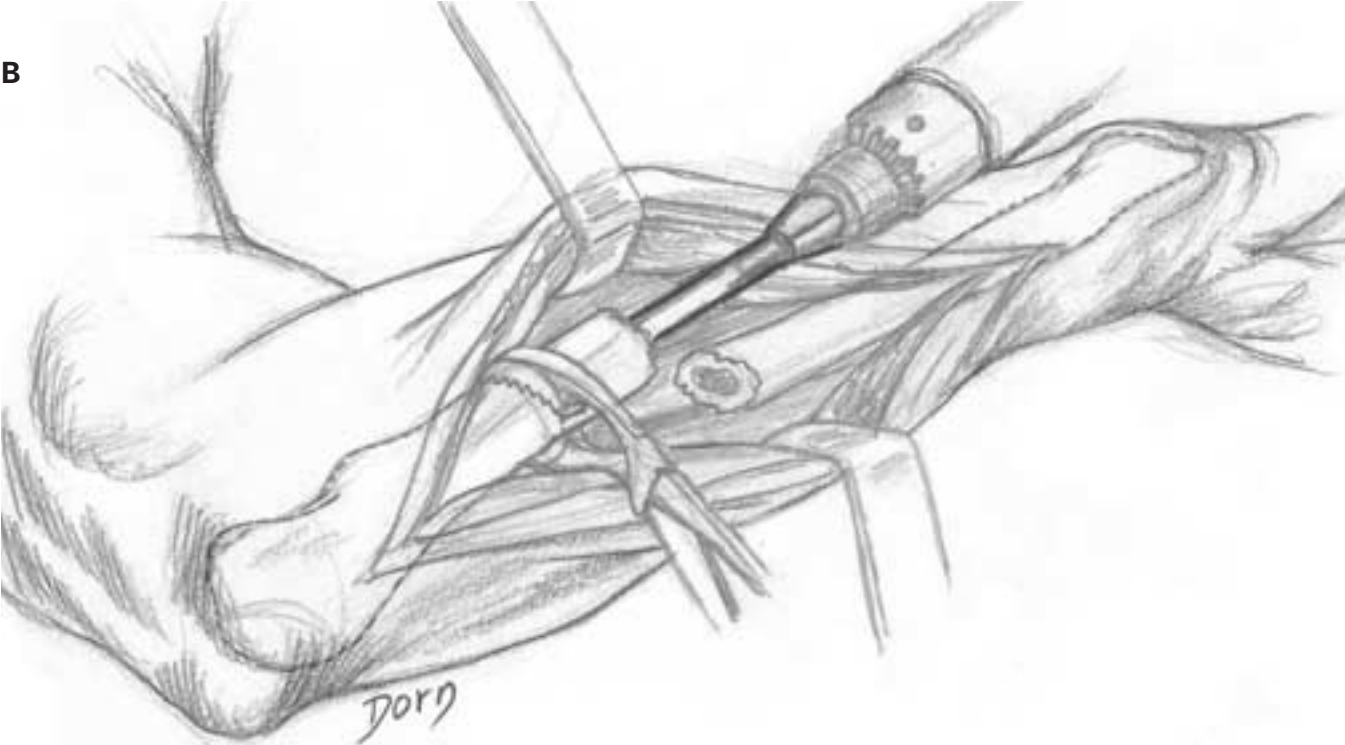
A Fracture of the radius treated by a plate.





# Upper limb surgery

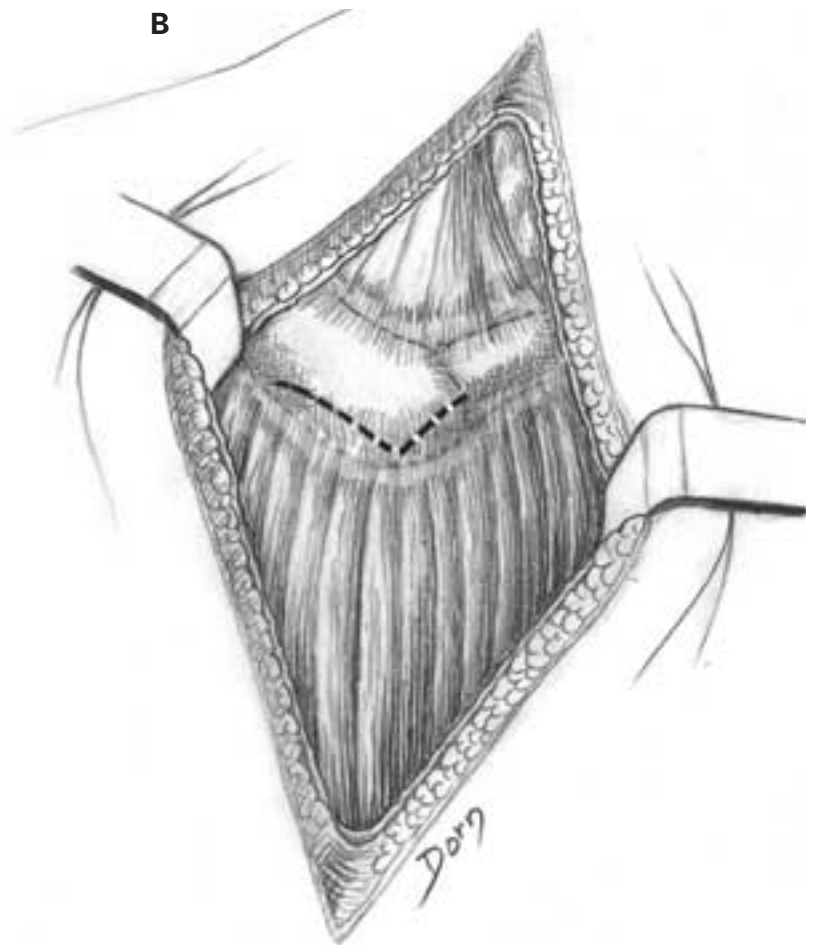
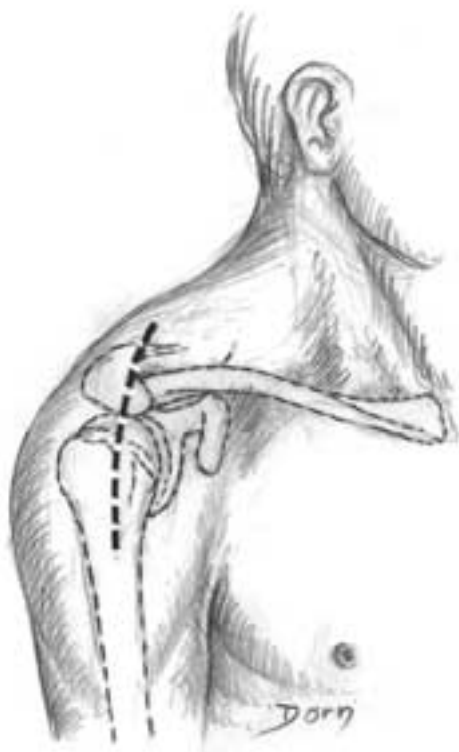
**B, C** The shaft of the ulna is reamed to put an intramedullar nail. The technique with exposure of the fracture site is obsolete.



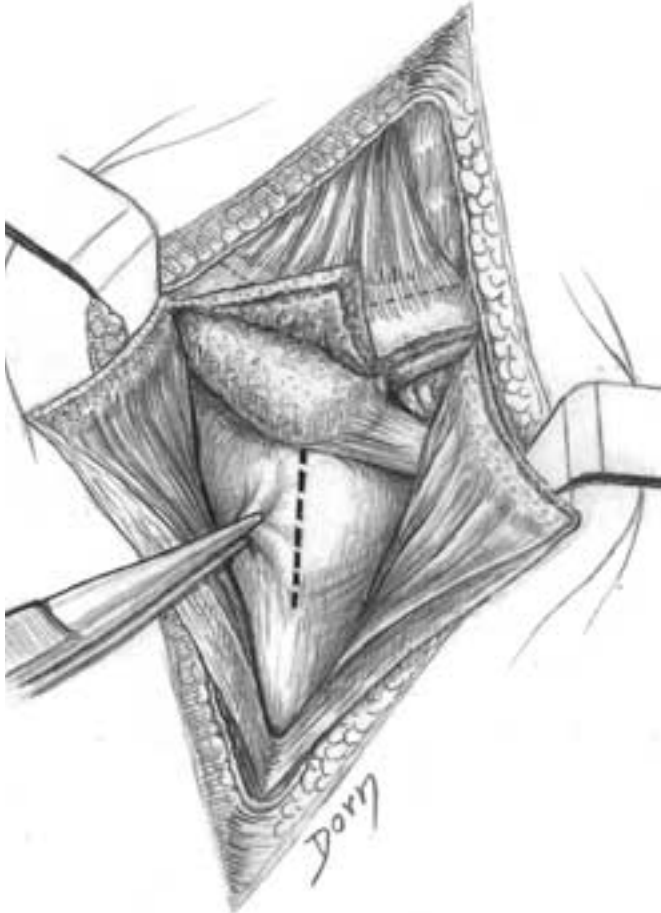
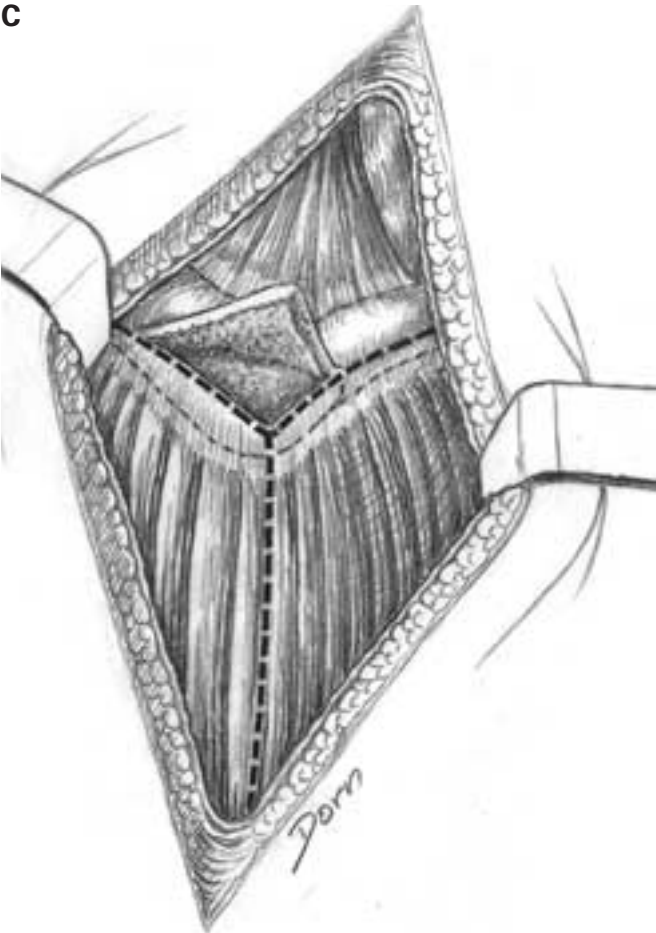
## Surgical exposure of the shoulder

Anterior approach to the subacromial space

**A** Skin incision according to the bony landmarks. **B, C** The deltoid origin is raised from the acromion and lateral clavicle.



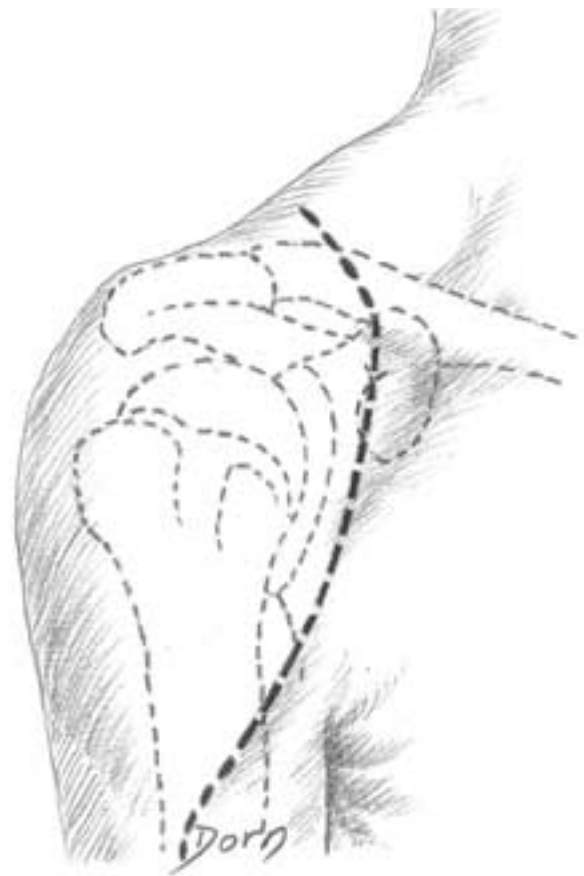
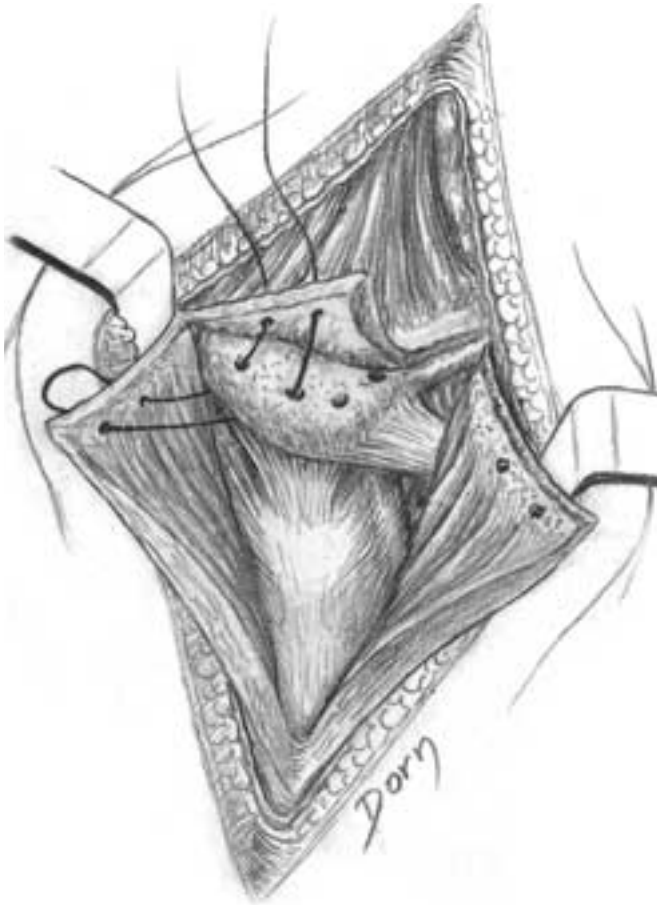
D Exposure and incision of the subdeltoid bursa.



E Musculoperiosteal flaps are reinserted by fixation to the bone.

Anterior approach to the glenohumeral joint

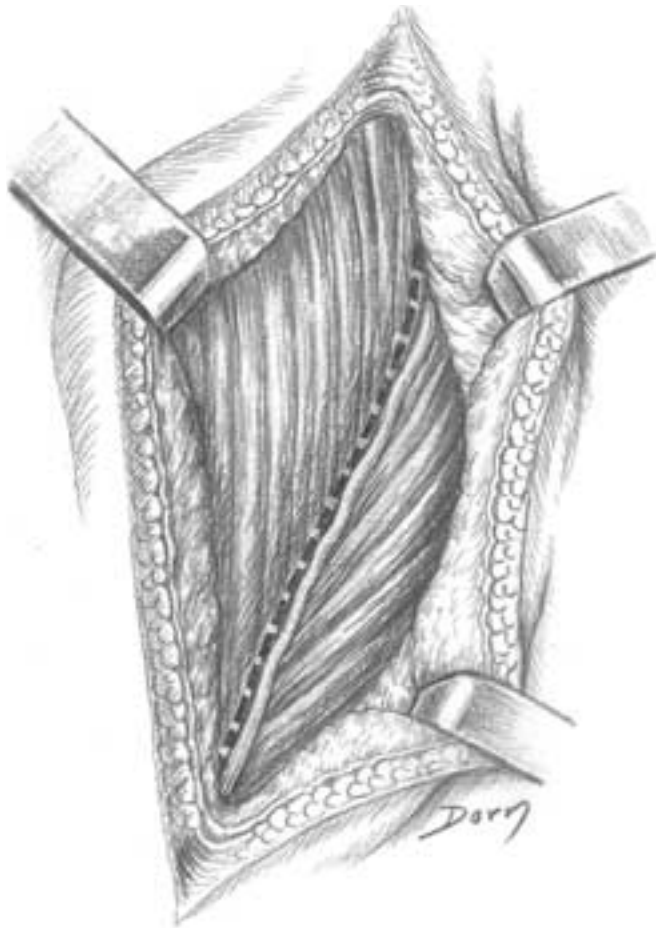
A Skin incision.



# Upper limb surgery

---

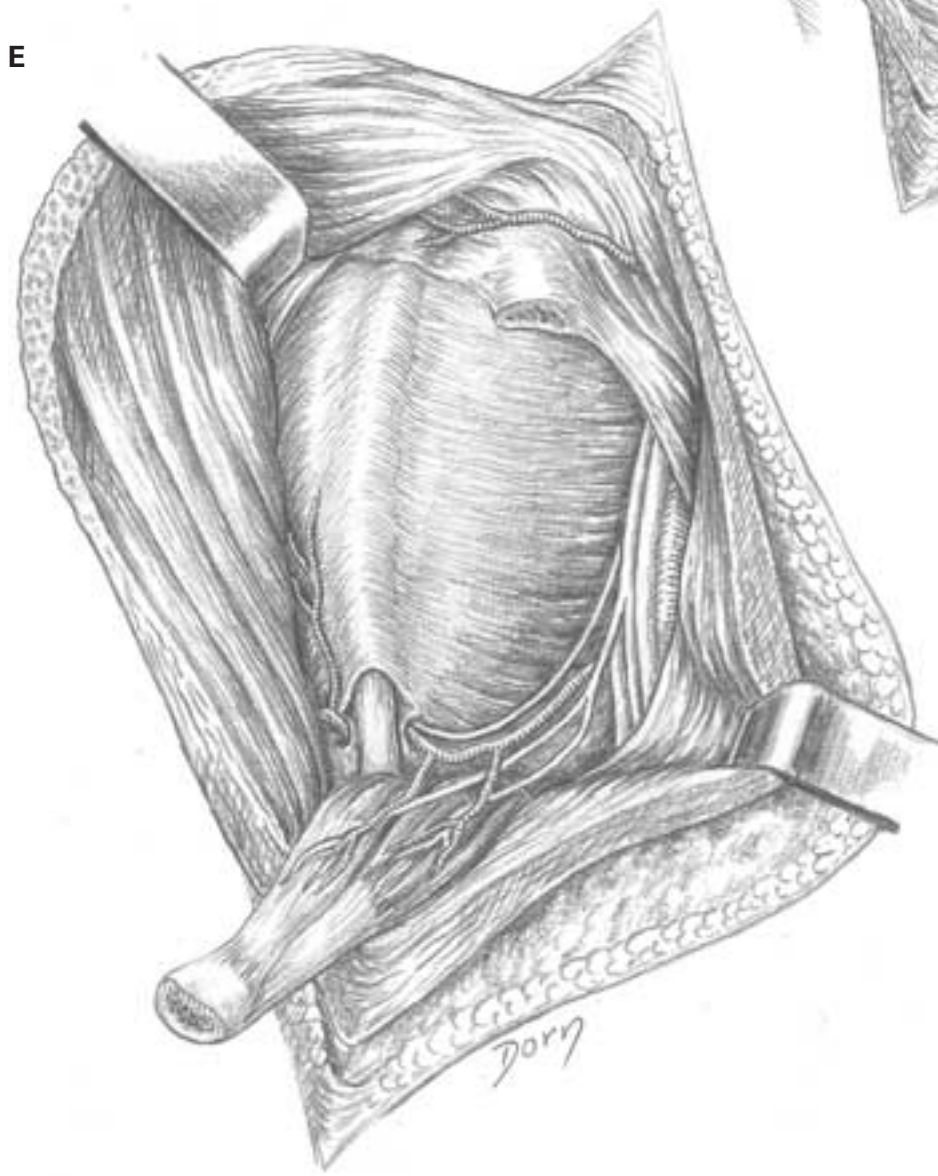
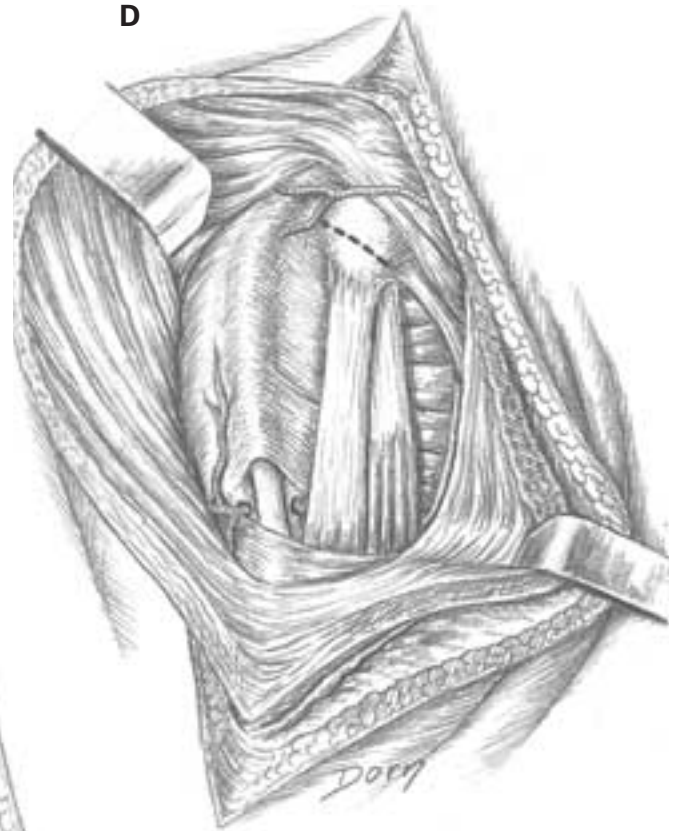**B** The deltopectoral groove is opened.



**C** Exposure of the coracobiceps by retracting the deltoid and the pectoralis major muscles.

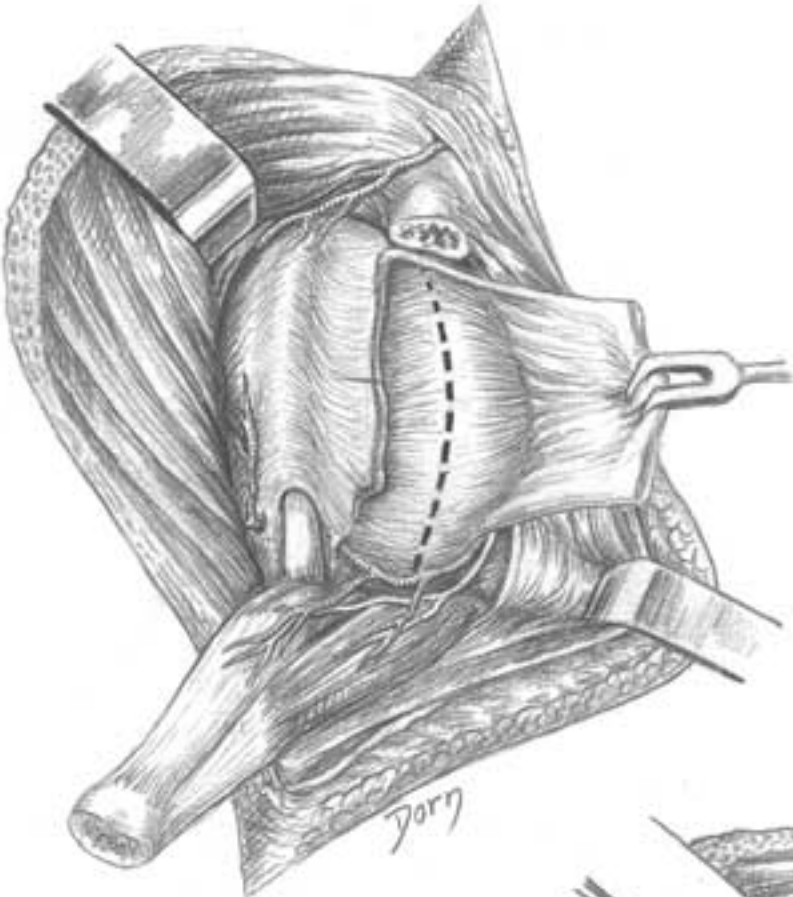


**D, E** The tip of the coracoid process is osteotomised. The coracobiceps is retracted, exposing the subscapularis muscle.

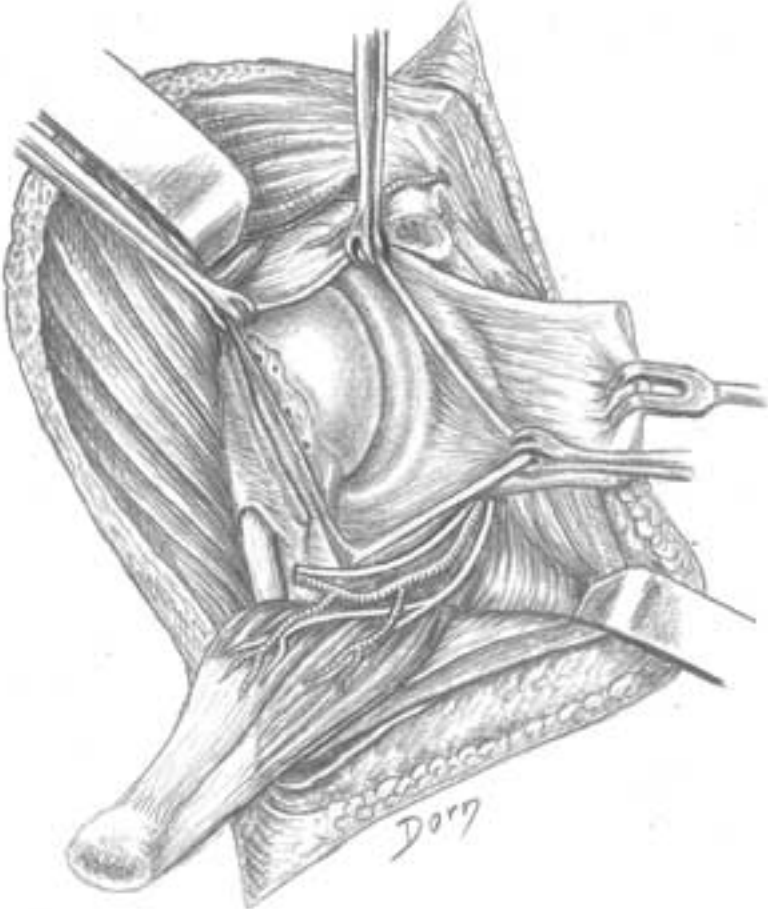


# Upper limb surgery

**F** The tendon of the subscapularis is severed and retracted. Exposure of the capsule.



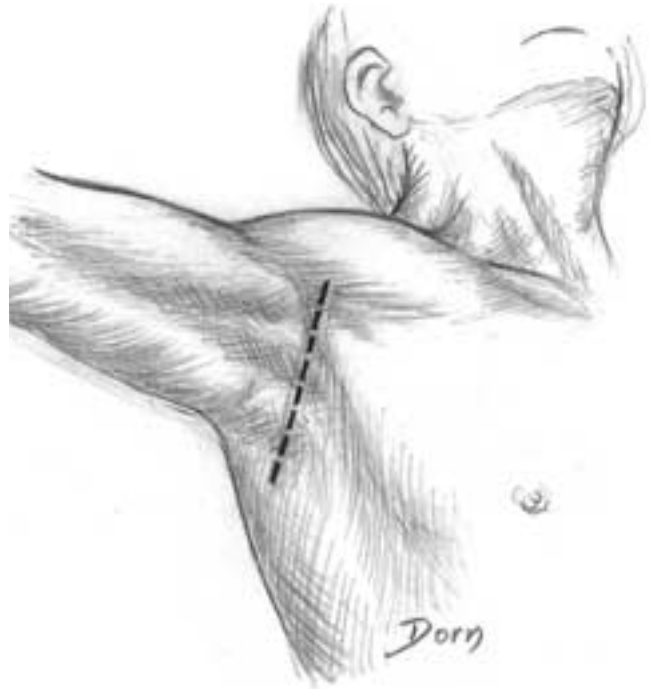**G** The capsule is opened.



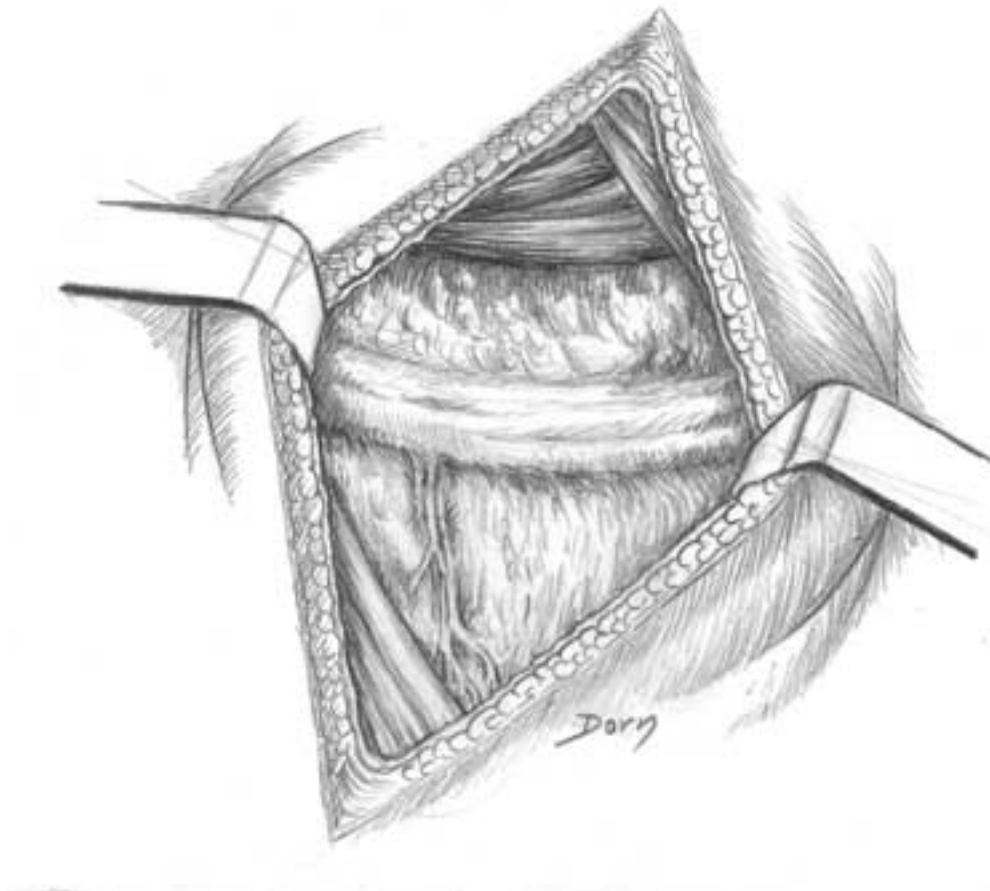
Axillary approach to the glenohumeral joint

Although rarely used because of the dissection of the neurovascular pedicles, this approach has the main advantage of a cosmetically acceptable scar.

**A** Skin incision.



**B** The neurovascular bundle is lying in the axillary fat.

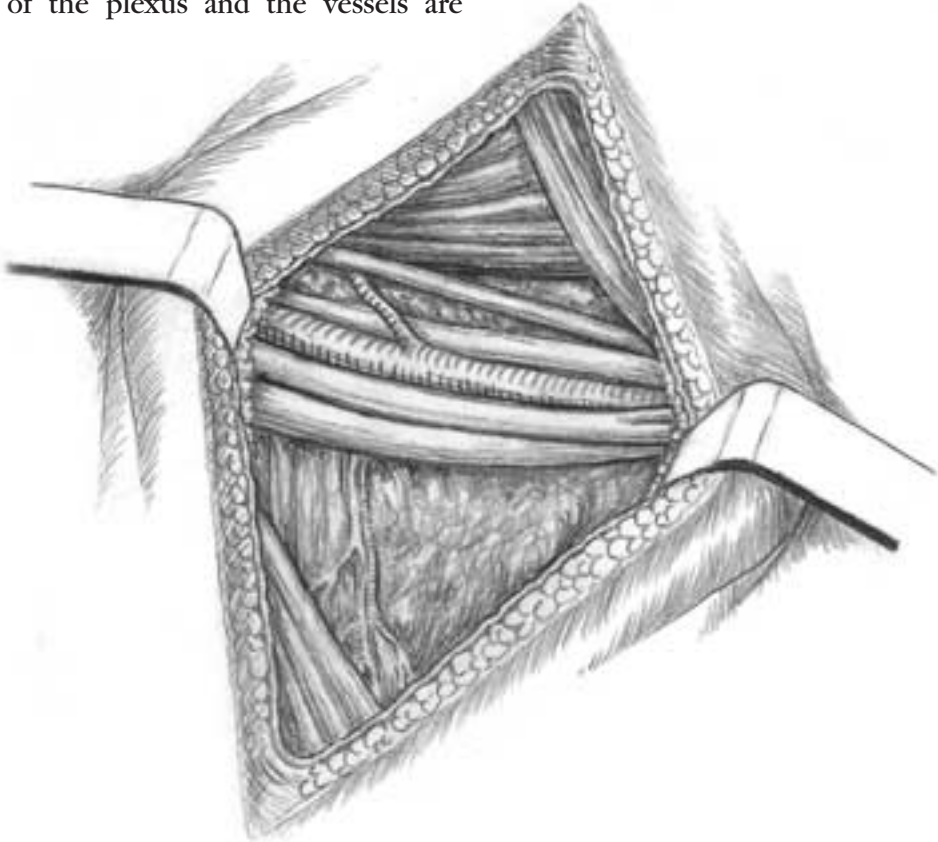




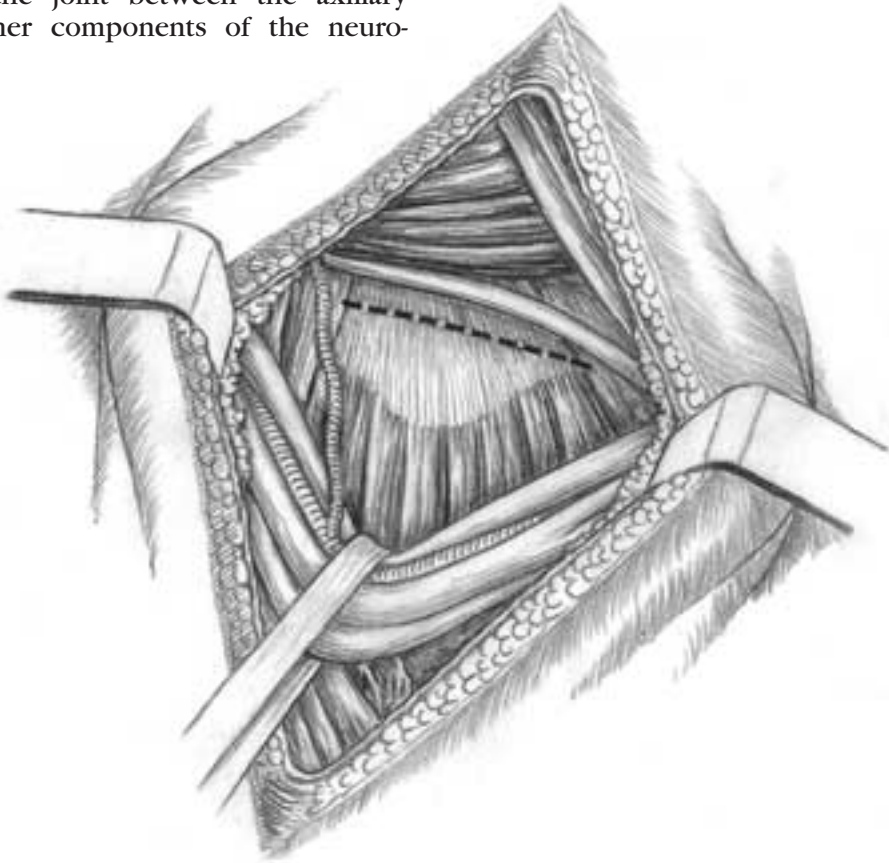
# Upper limb surgery

---

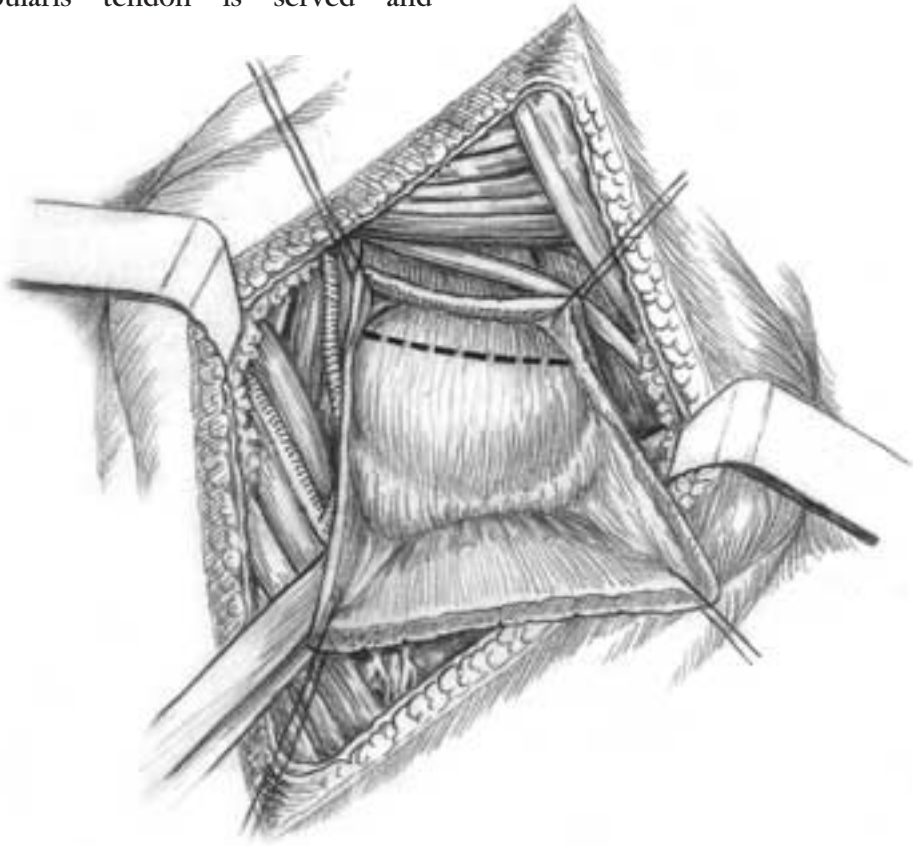
**C** The cords of the plexus and the vessels are visible.



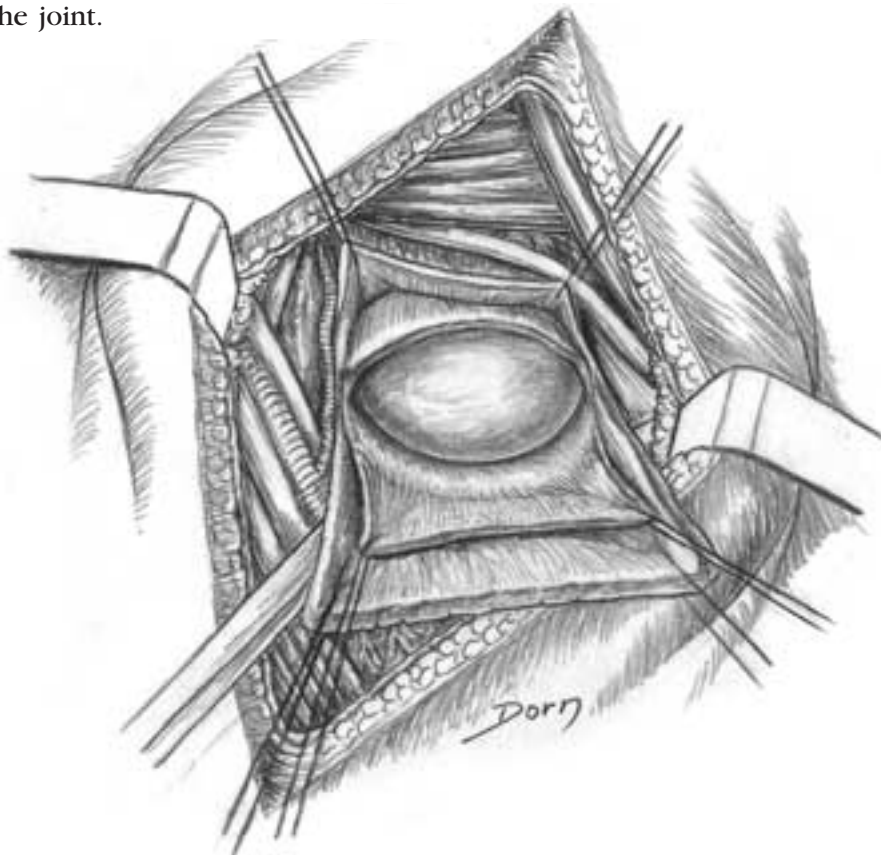
**D** Approach to the joint between the axillary nerve and the other components of the neurovascular bundle.



**E** The subscapularis tendon is served and retracted.



**F** Exposure of the joint.

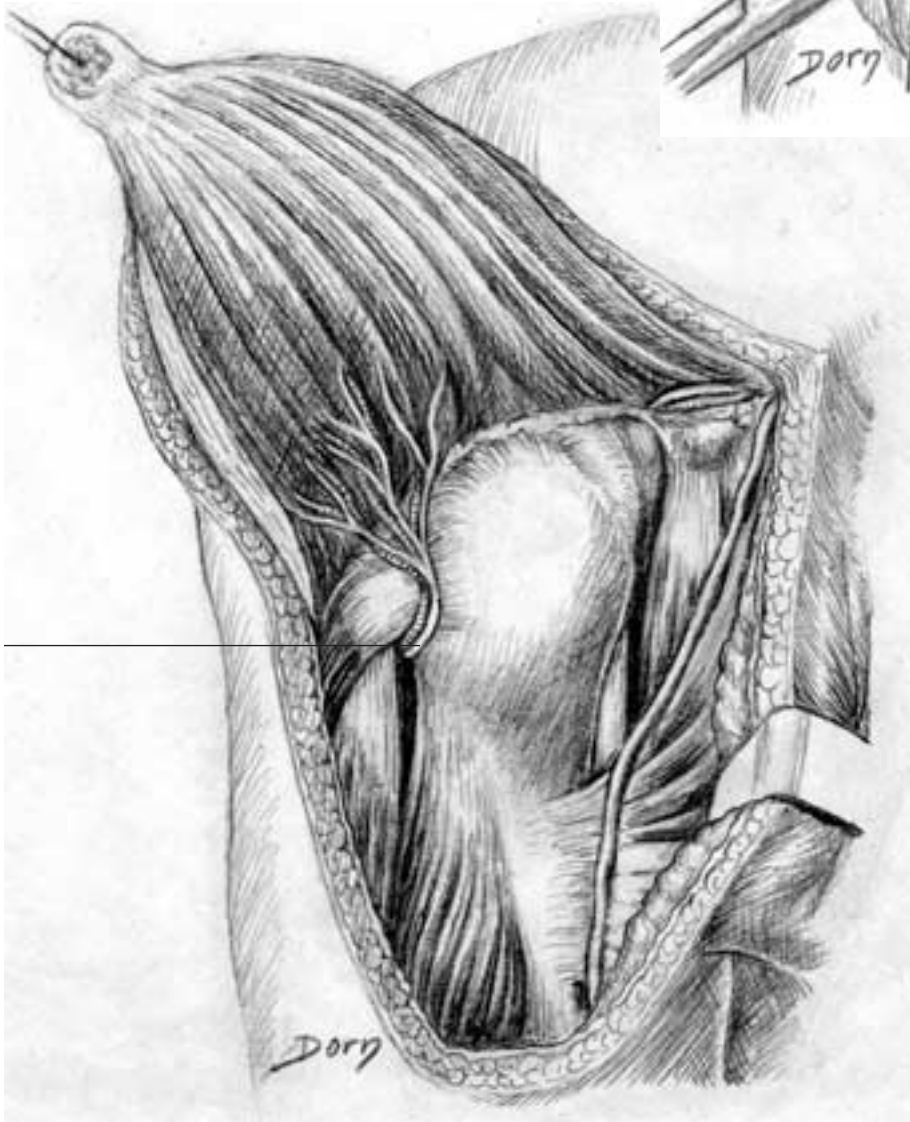
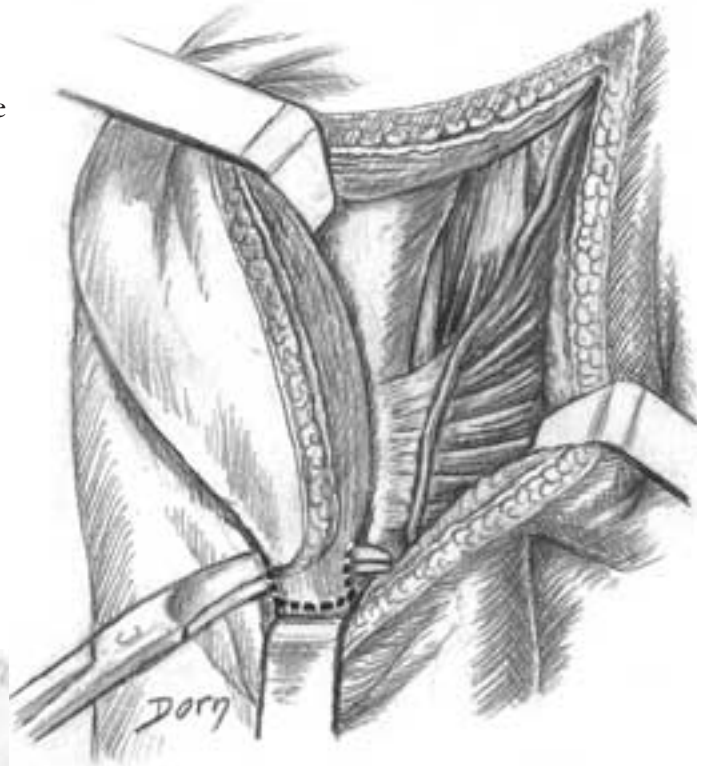


# Upper limb surgery

## Subdeltoid approach to the proximal metaphysis of the humerus

This approach is rarely used. Its indications are tumours and malunited fractures.

**A** The skin incision has a U shape.



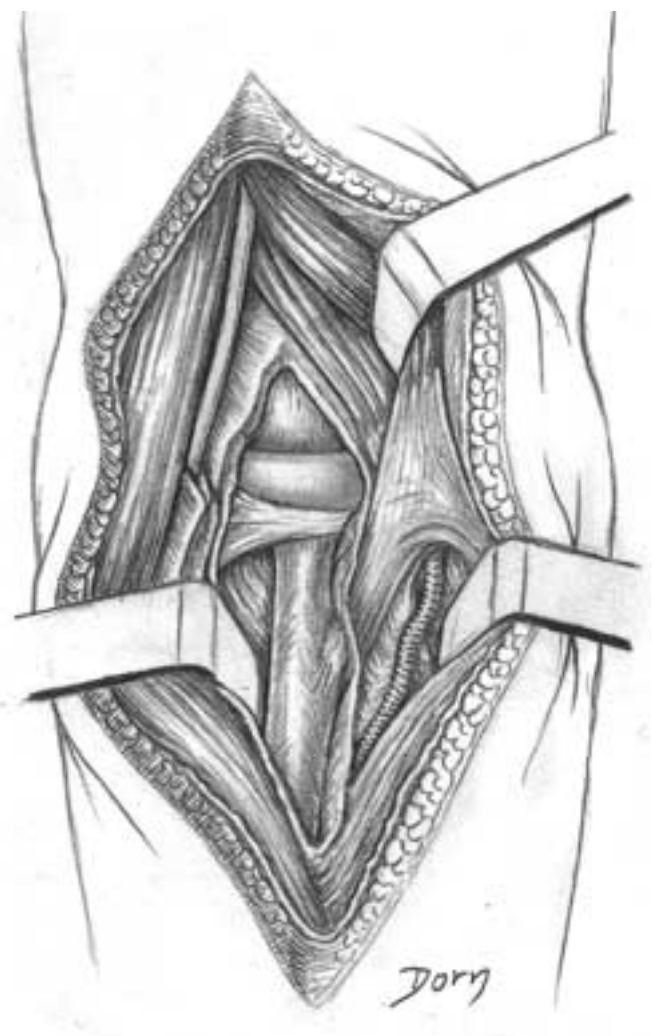
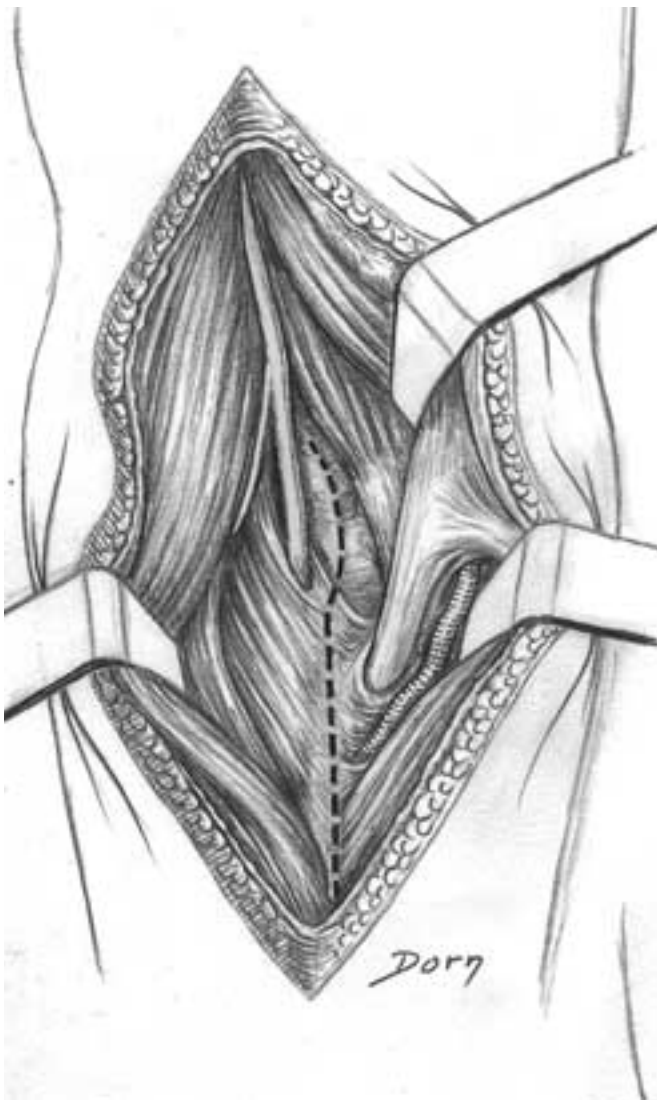**B** The distal insertion of the deltoid is released with a bone block. the skin flap and the deltoid are retracted *en bloc*.

1 axillary nerve

Anterior approach to the proximal third of the radius

**A** The approach is made with the forearm in supination. the brachioradialis muscle is retracted laterally exposing the two branches of the radial nerve and the supinator muscle. The biceps are retracted medially. The incision is made medially to the supinator and laterally to the biceps tendon.

**B** Exposure of the humeroradial joint and the proximal third of the radius.





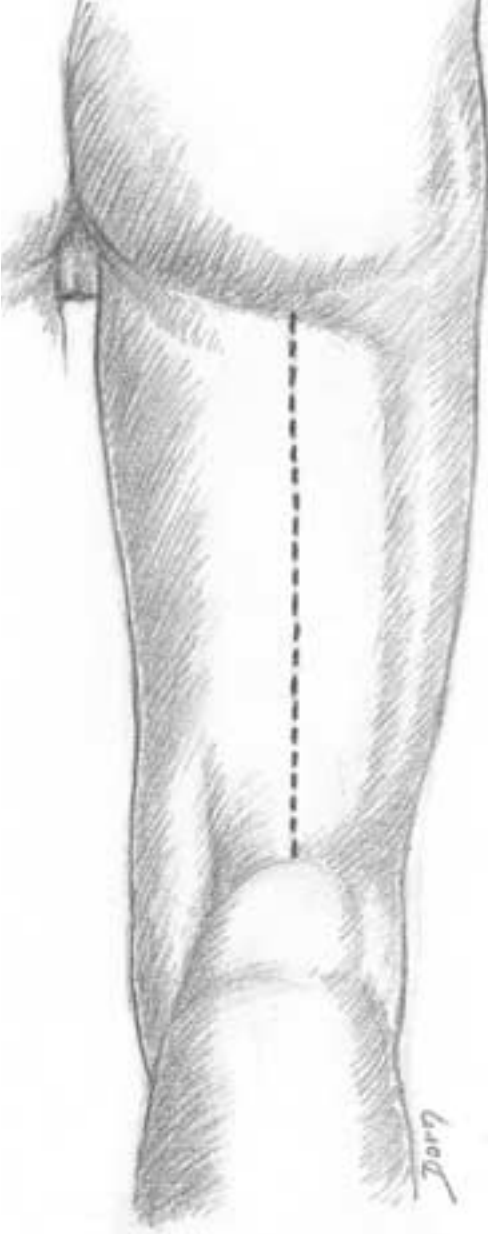
# Lower limb surgery

The lower extremity is traditionally an important part of orthopaedic surgery; however, it is also relevant to vascular surgeons. We will survey the following: anatomy, reconstructive surgery of the knee and some approaches to the hip and the foot.

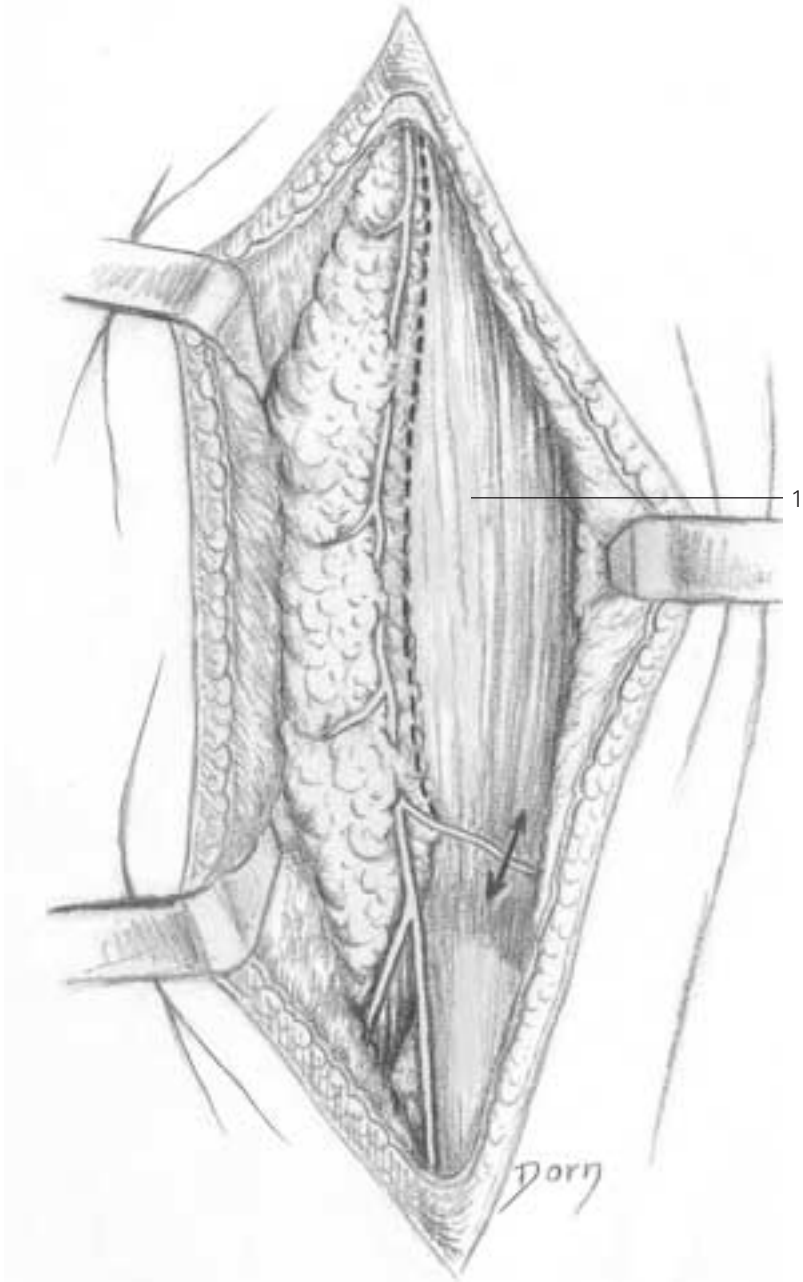
**Anatomy**

Anatomy of the posterior approach to the femoral shaft

**A** Skin incision.

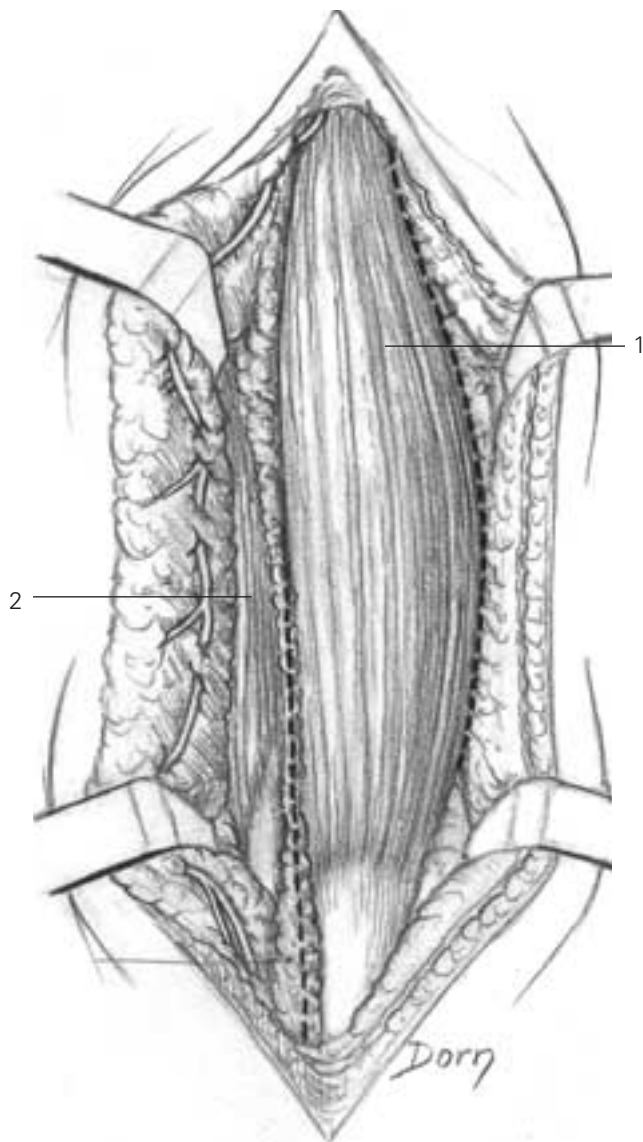


**B** Identification of the posterior femoral cutaneous nerve.



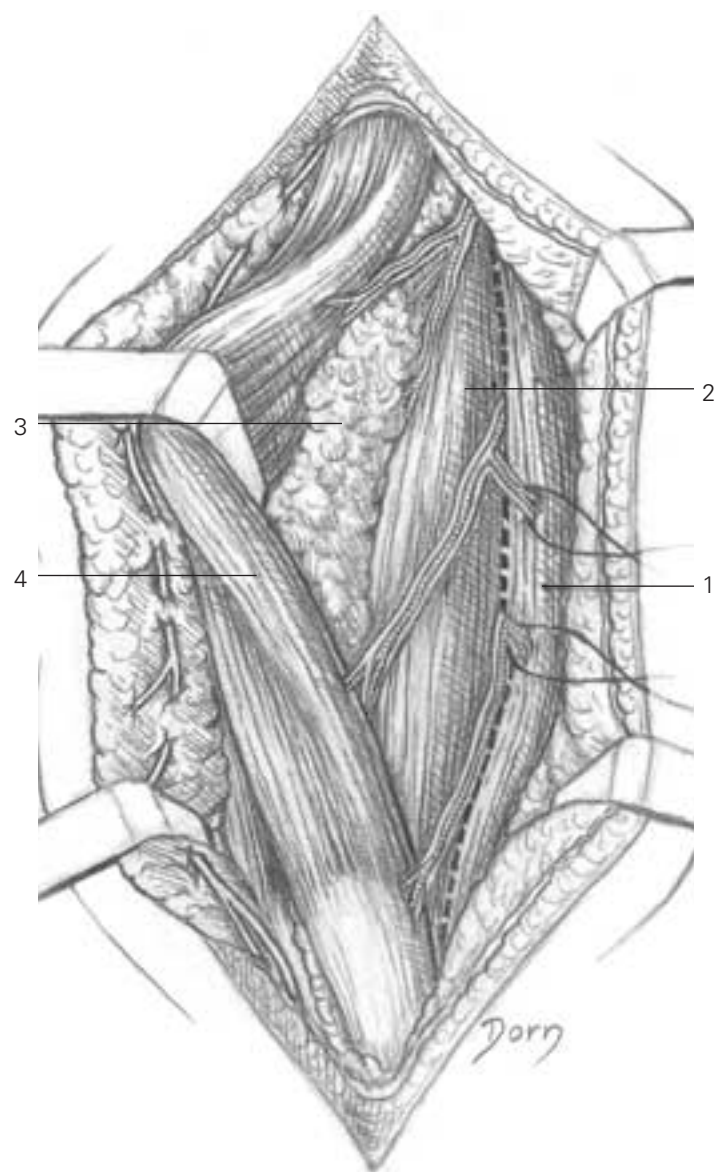
**B**  
1 biceps femoris

**C** Approach between biceps and vastus lateralis. The lower part of the biceps is released from the semitendinosus.



**C**  
1 biceps femoris  
2 semitendinosus

**D** The long head of biceps femoris is retracted medially; the plane between the short head and vastus lateralis is developed.

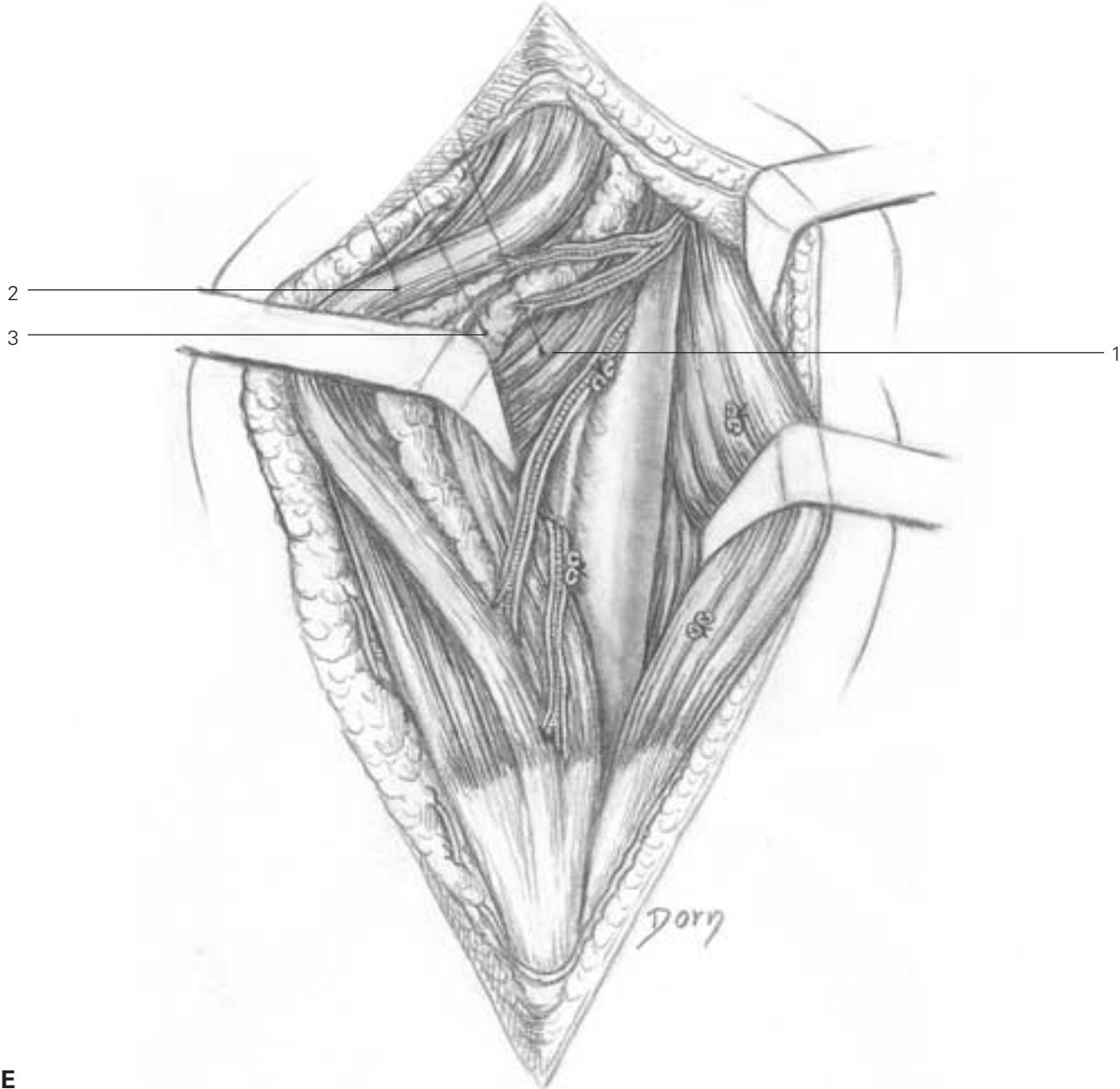


**D**  
1 vastus lateralis  
2 short head of biceps femoris  
3 fatty tissue containing sciatic nerve  
4 long head of biceps femoris



# Lower limb surgery

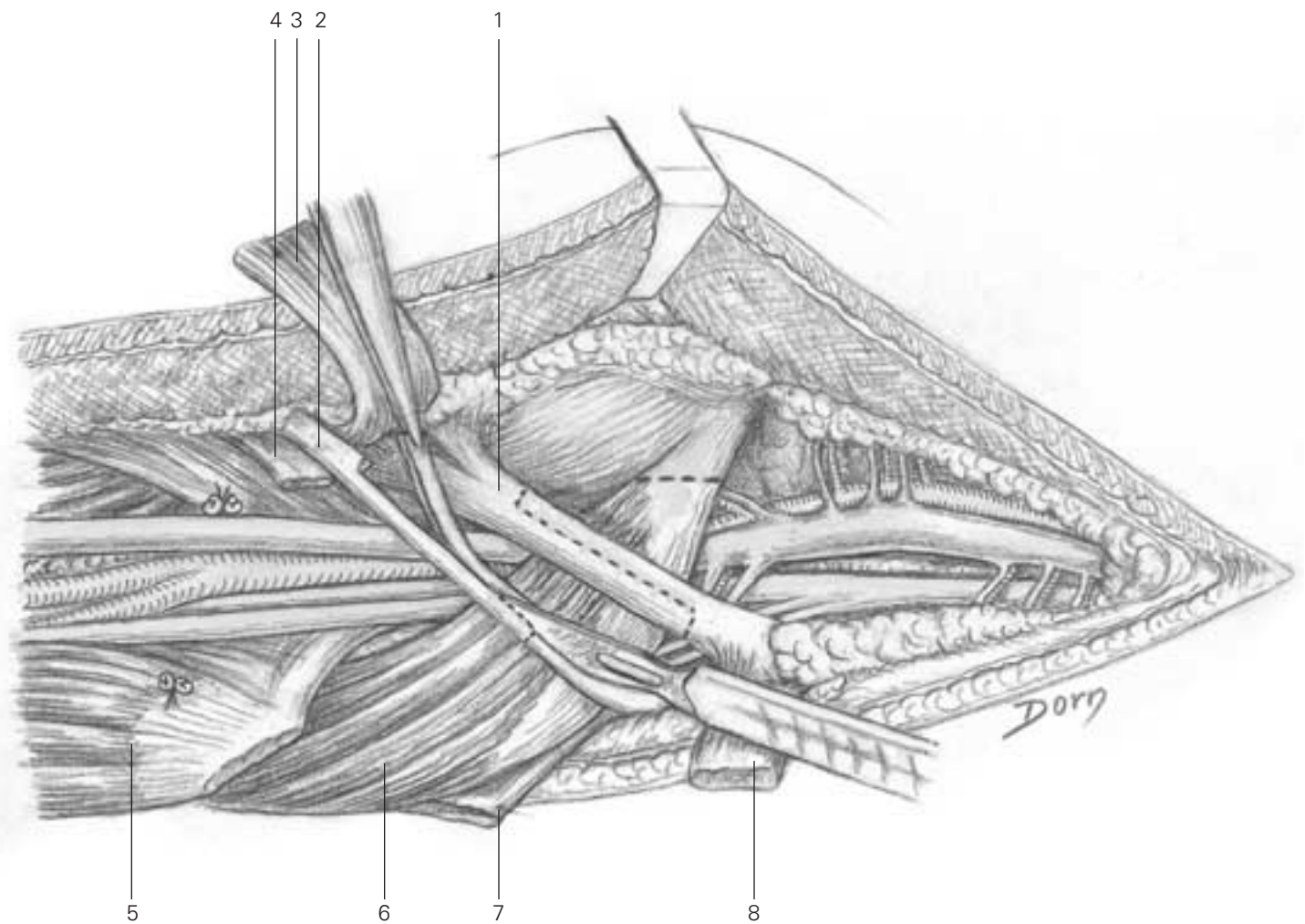
## E Exposure of the femoral shaft.



- E**
- 1 short head of biceps
  - 2 long head of biceps
  - 3 fatty tissue containing sciatic nerve

Extended medial approach to the popliteal vessels

**A** The soleus has been released from the tibia. The insertion of pes anserinus, semimembranosus and medial head of gastrocnemius are divided.

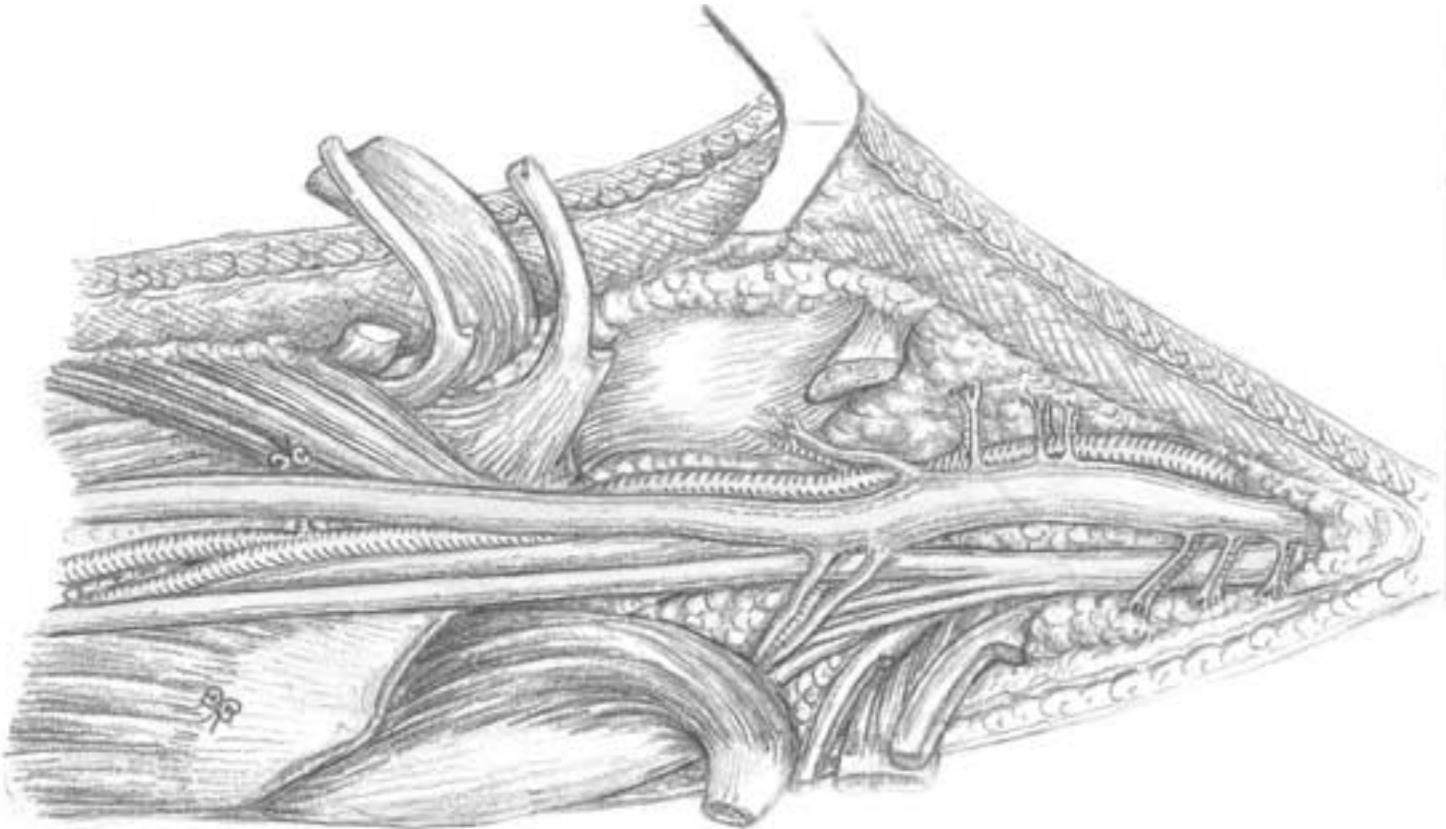


- A**
- 1 semimembranosus
  - 2 gracilis
  - 3 sartorius
  - 4 semitendinosus
  - 5 soleus
  - 6 gastrocnemius
  - 7 semitendinosus
  - 8 sartorius

# Lower limb surgery

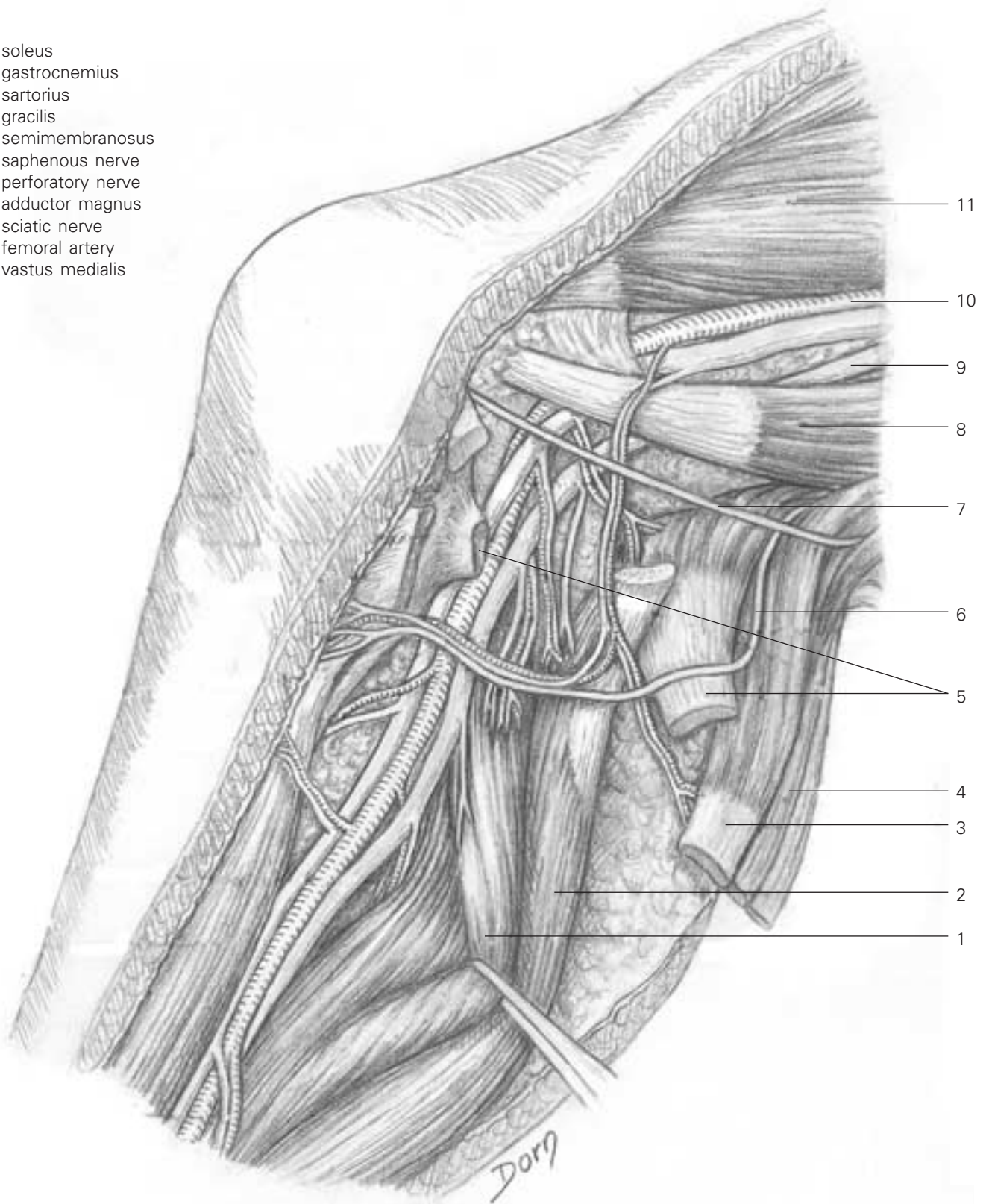
---

**B** Medial aspect of the popliteal neurovascular bundle.



**C** Extended anatomical view of the medial aspect of the knee with the vascular and nerve supply. Only muscle insertions or tendons have been divided.

- C**
- 1 soleus
  - 2 gastrocnemius
  - 3 sartorius
  - 4 gracilis
  - 5 semimembranosus
  - 6 saphenous nerve
  - 7 perforatory nerve
  - 8 adductor magnus
  - 9 sciatic nerve
  - 10 femoral artery
  - 11 vastus medialis

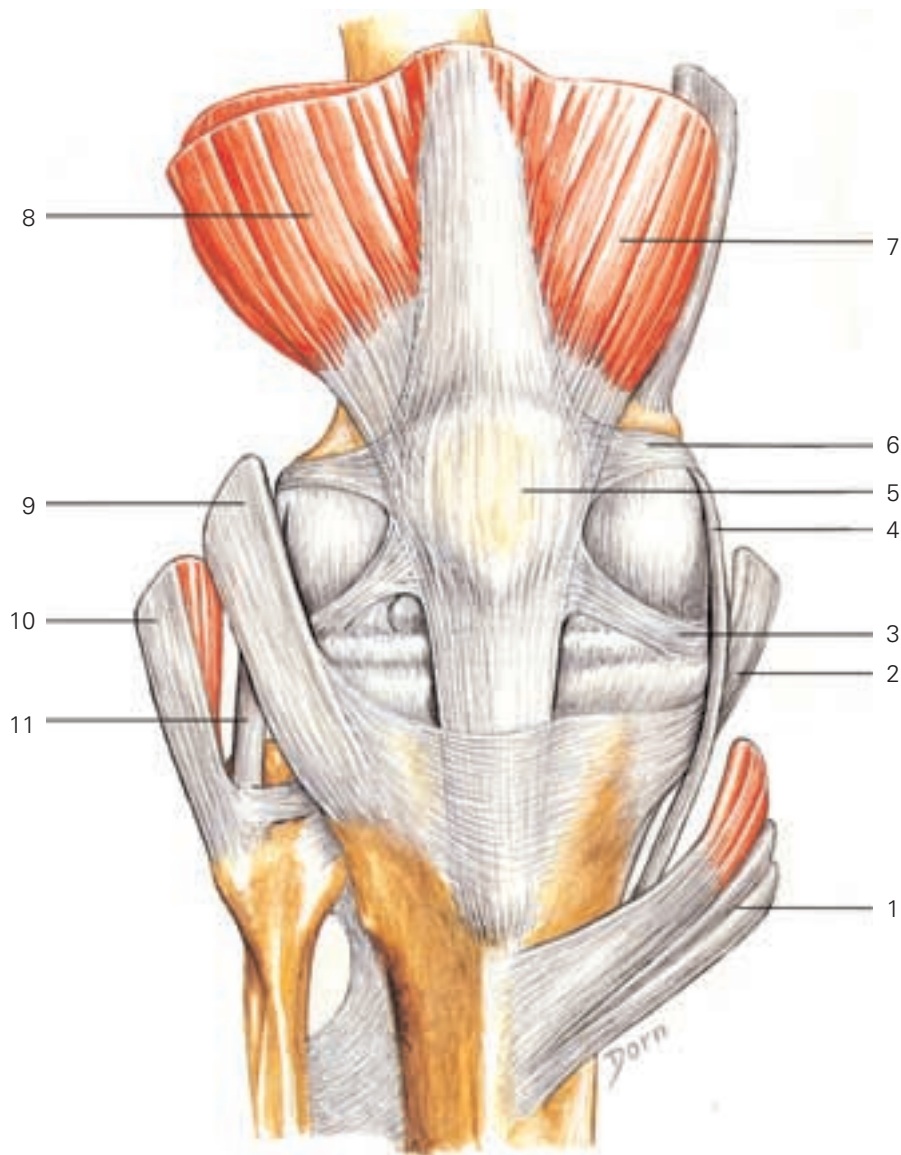


# Lower limb surgery

---

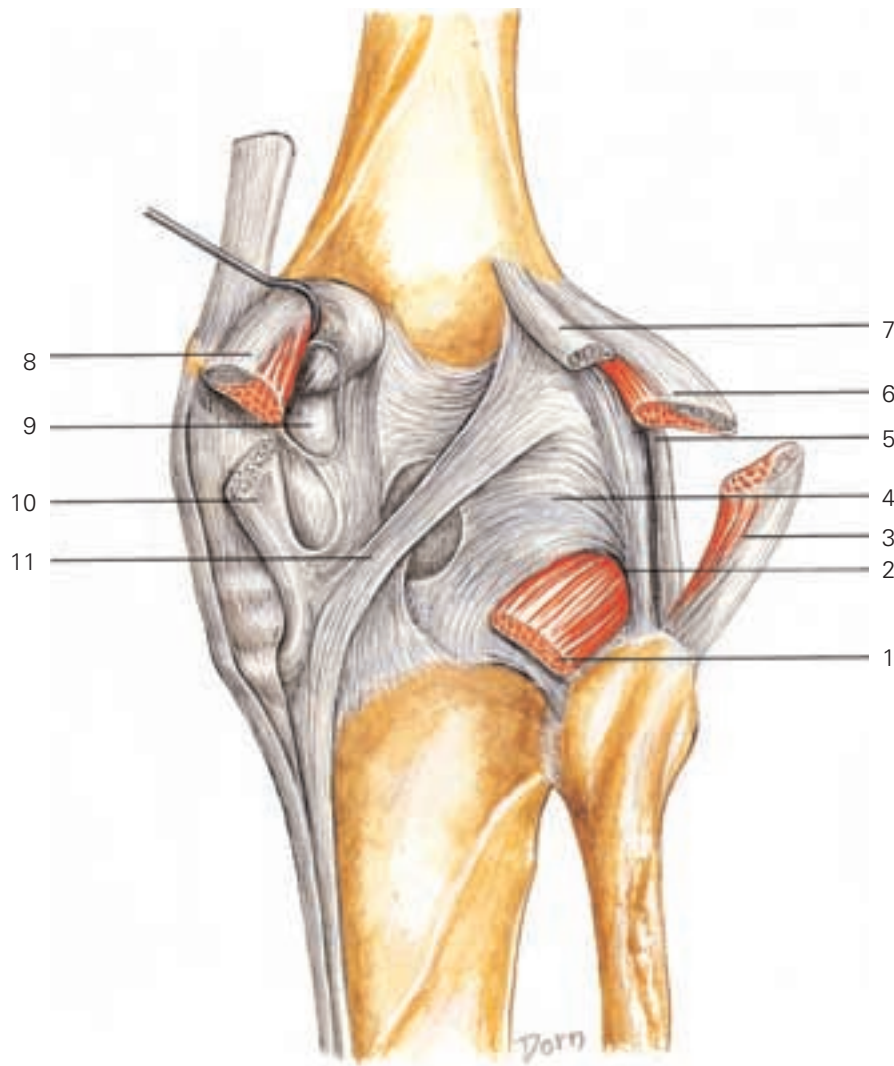
## Anatomy of the knee

### A Anterior view.



- 1 pes anserinus muscles
- 2 semimembranosus
- 3 patellomeniscal ligament
- 4 medial collateral ligament
- 5 patella
- 6 patellofemoral ligament
- 7 vastus medialis
- 8 vastus lateralis
- 9 iliotibial band
- 10 biceps femoris
- 11 lateral collateral ligament

**B** Posterior view.

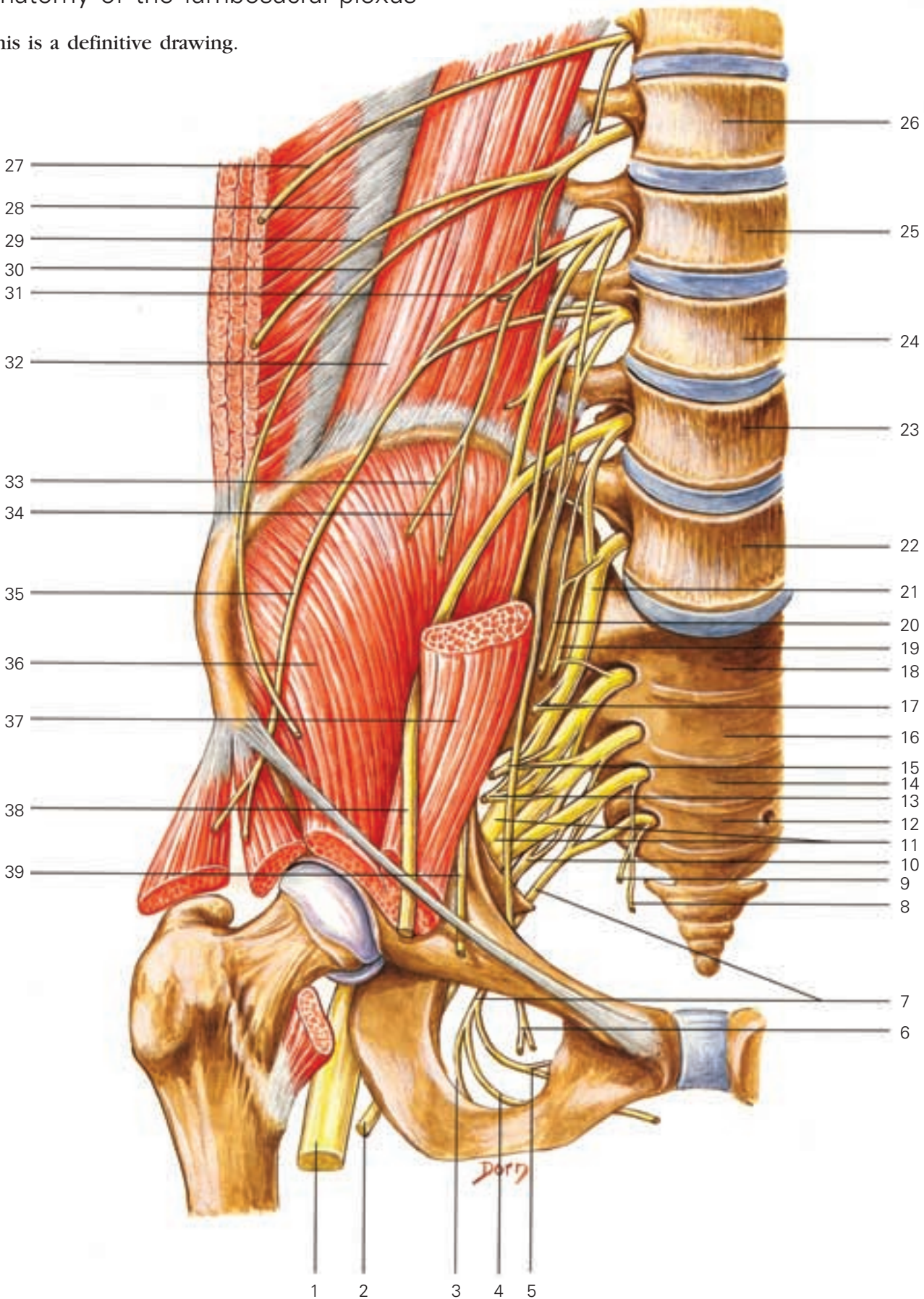


- 1 popliteus
- 2 popliteus hiatus
- 3 biceps femoris
- 4 arcuate ligament
- 5 lateral collateral ligament
- 6 lateral head of gastrocnemius
- 7 plantaris
- 8 medial head of gastrocnemius
- 9 bursa
- 10 semimembranosus
- 11 oblique ligament

# Lower limb surgery

## Anatomy of the lumbosacral plexus

This is a definitive drawing.



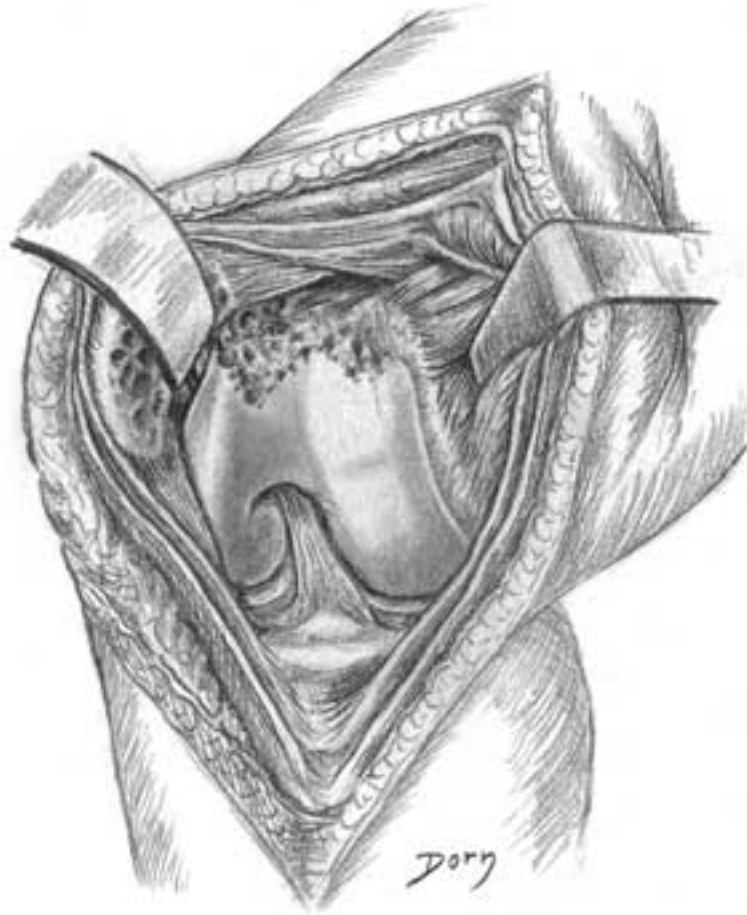
- 1 sciatic nerve
- 2 posterior cutaneous nerve of thigh
- 3 perineal nerve
- 4 dorsal nerve of penis/clitoris
- 5 inferior rectal nerve
- 6 obturator nerve
- 7 pudendal nerves (S2, 3, 4)
- 8 perineal branch of fourth sacral nerve
- 9 to levator ani and coccygeus (S3, 4)
- 10 posterior cutaneous nerve of thigh (S1, 2, 3)
- 11 sciatic nerve
- 12 S4
- 13 inferior gluteal nerve (L5, S1, 2)
- 14 S3
- 15 to piriformis (S1, 2)
- 16 S2
- 17 superior gluteal nerve (L4, 5, S1)
- 18 S1
- 19 to obturator internus and superior gemellus (L5, S1, 2)
- 20 to quadratus femoris and inferior gemellus (L5, S1, 2)
- 21 lumbosacral trunk
- 22 L5
- 23 L4
- 24 L3
- 25 L2
- 26 L1
- 27 subcostal nerve
- 28 transversus abdominis
- 29 iliohypogastric nerve (T12, L1)
- 30 ilioinguinal nerve (L1)
- 31 to psoas
- 32 quadratus lumborum
- 33 femoral branch of genitofemoral nerve
- 34 genital branch of genitofemoral nerve
- 35 lateral cutaneous nerve of thigh
- 36 iliacus
- 37 psoas
- 38 femoral nerve (L2, 3, 4)
- 39 accessory obturator nerve (L3, 4)



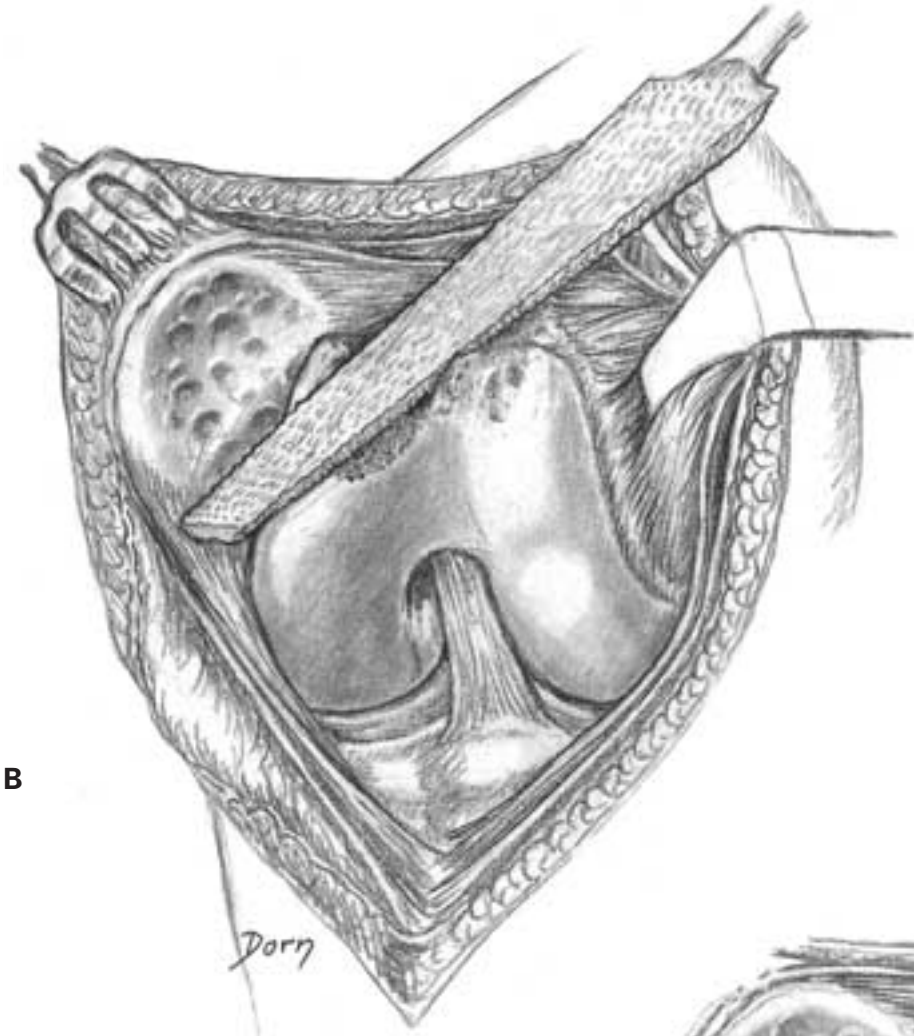
## **Surgery of the knee**

Prosthesis of the patella

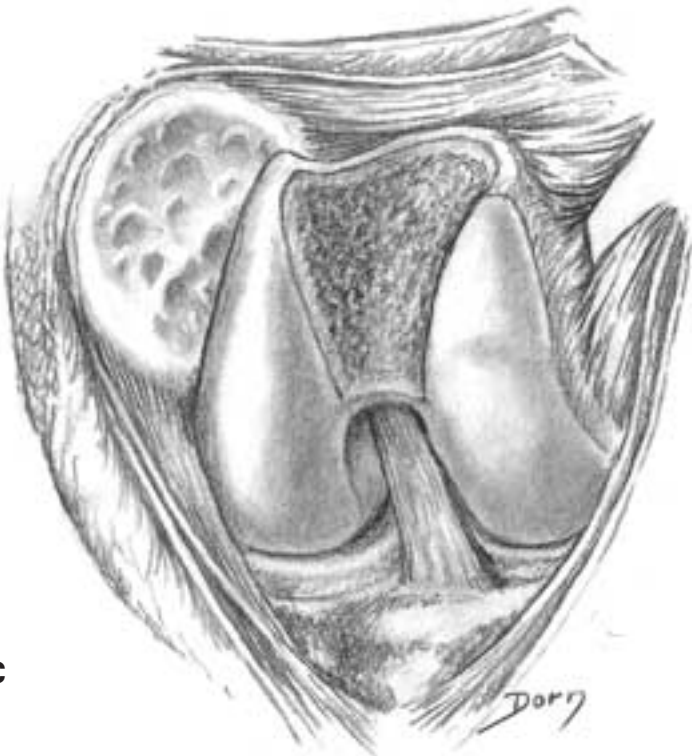
**A** Medial approach to the femoropatellar joint.



B-D Preparation of the trochlear implant.

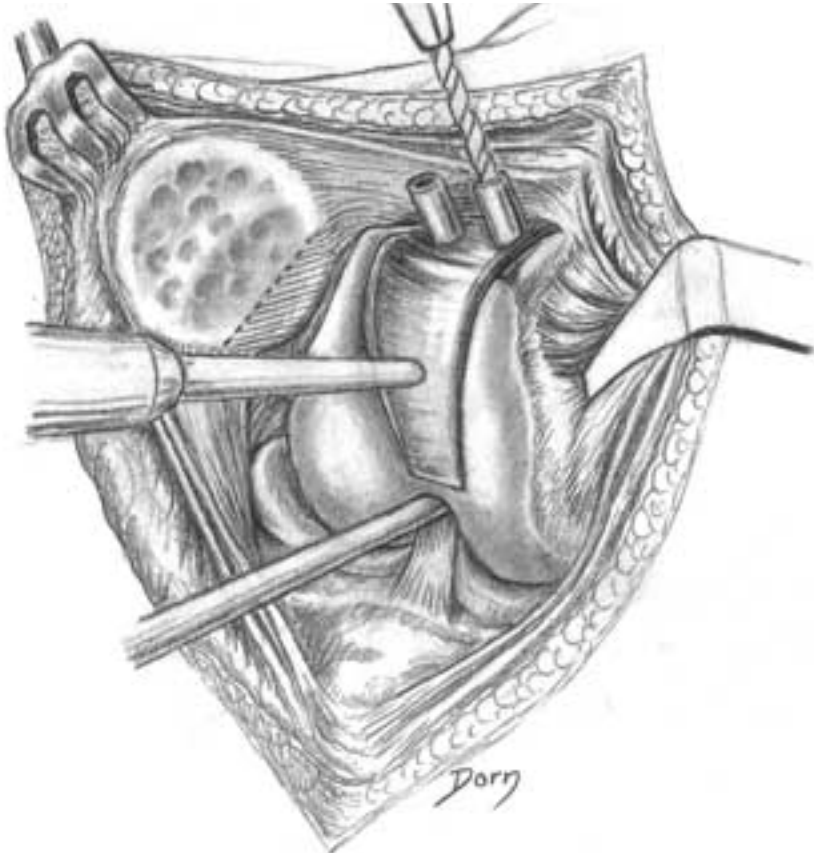


B



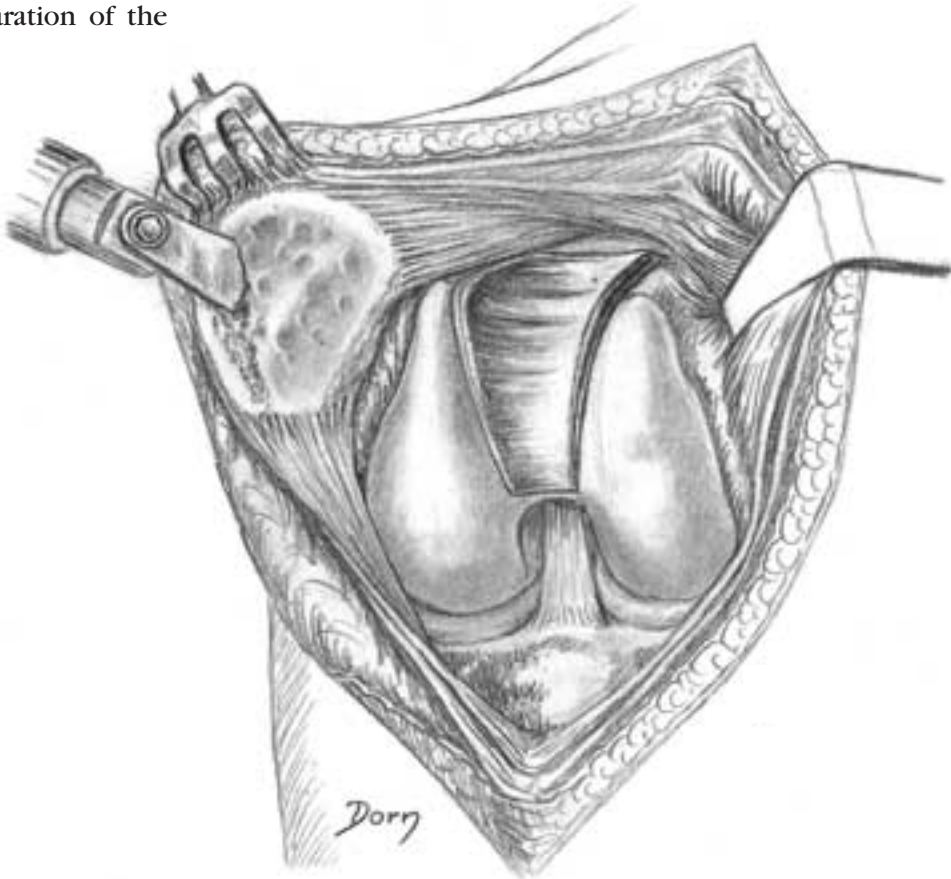
C

D

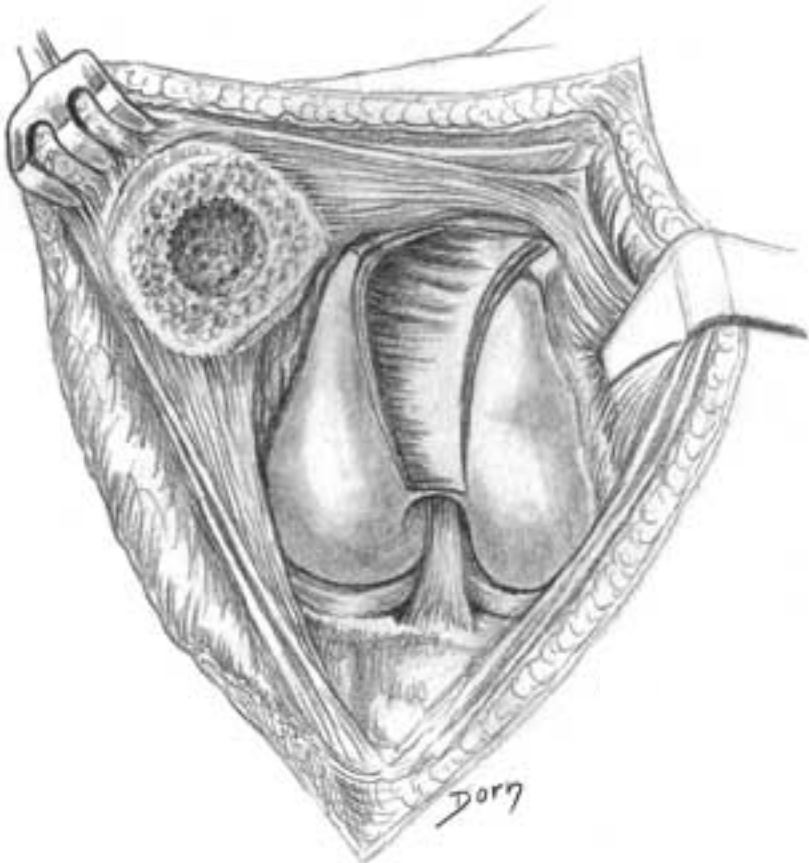


E, F Preparation of the patella.

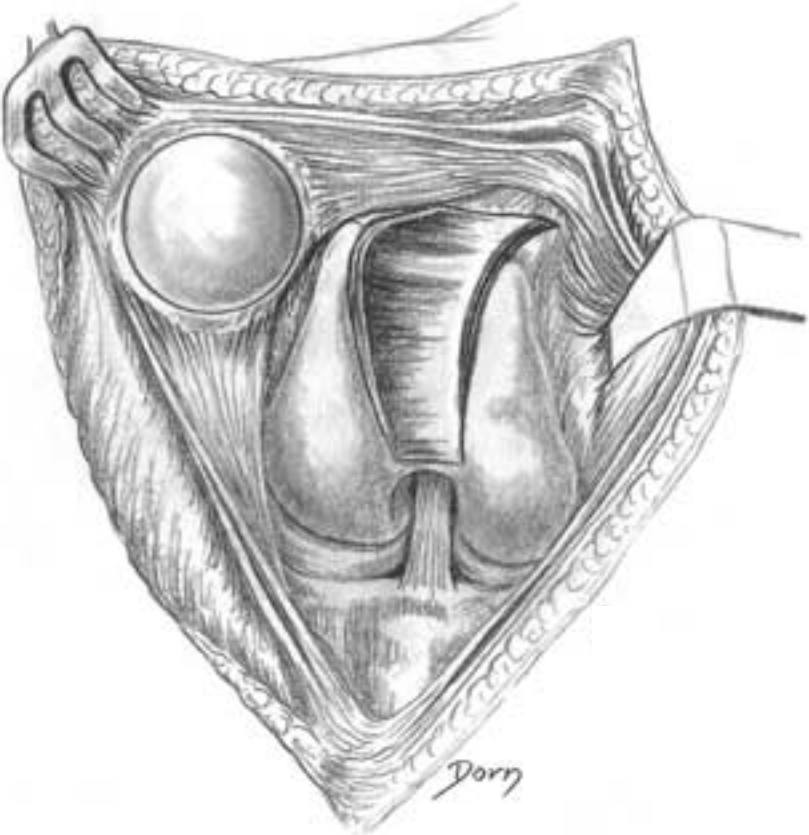
E



F



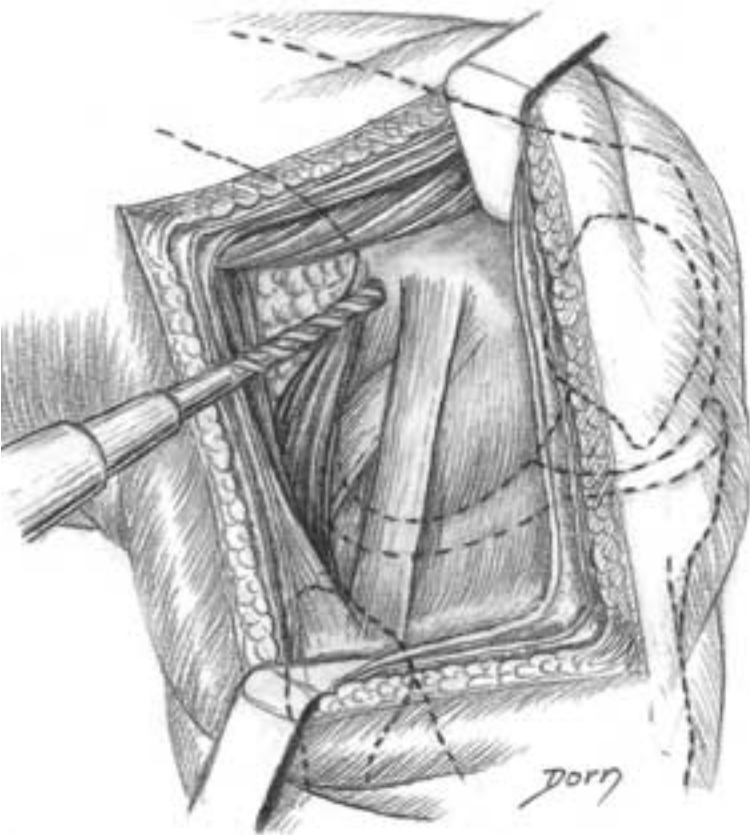
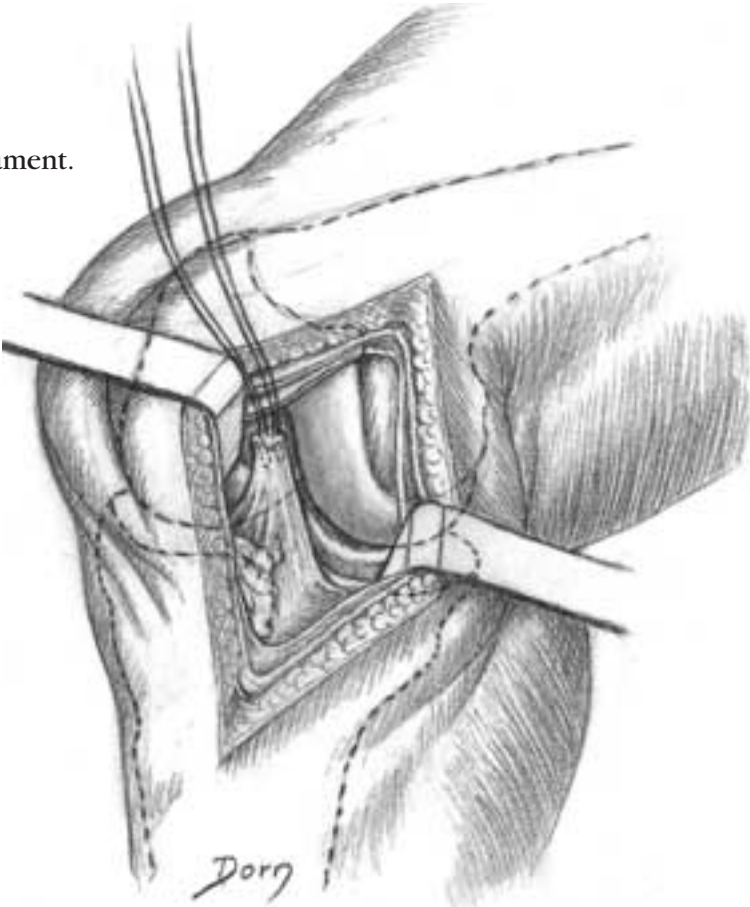
G The two components are in place.



# Lower limb surgery

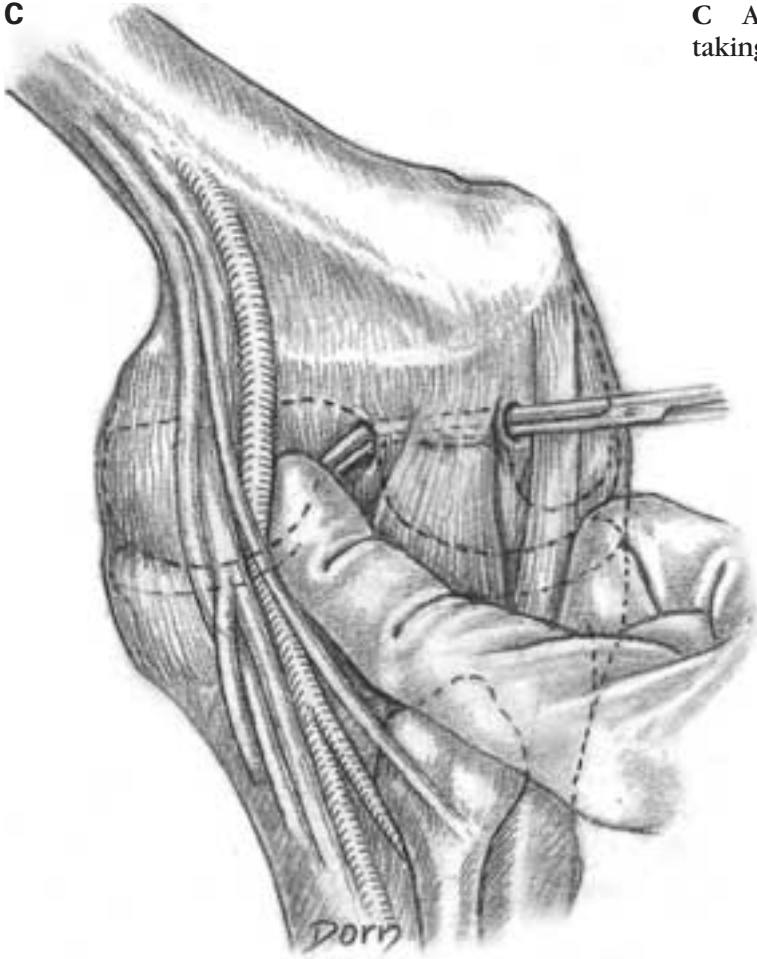
Repair of a rupture of the anterior cruciate ligament

**A** Anteromedial approach to retrieve the ligament.



**B** Posterolateral approach to perform a tunnel 'over the top' of the lateral condyle.

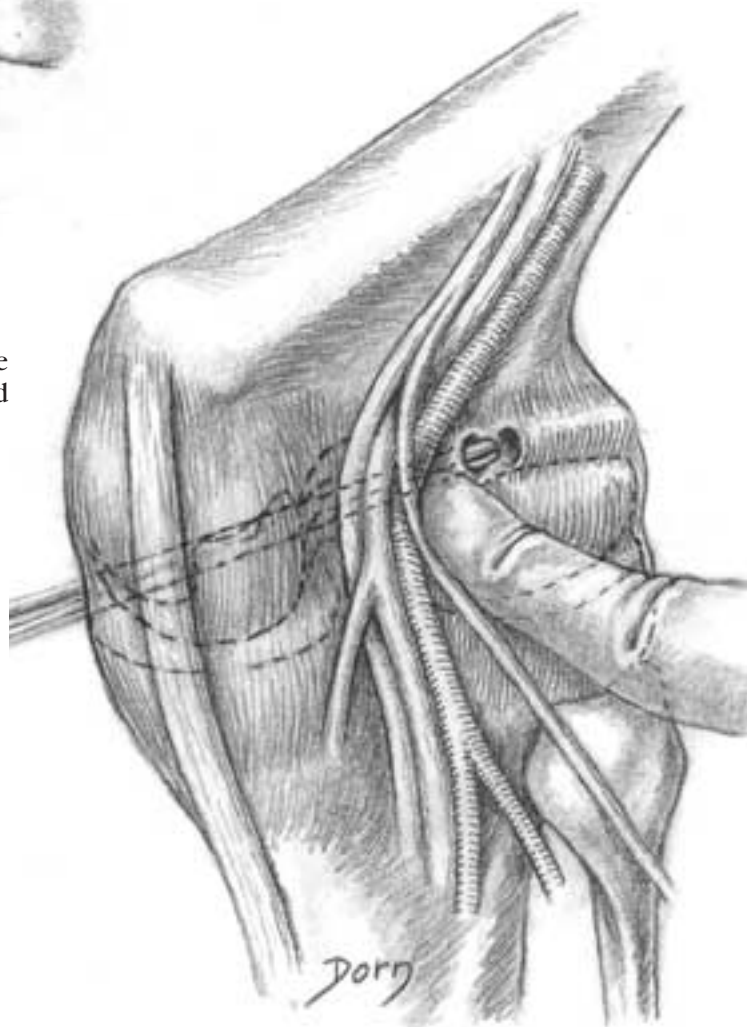
**C**



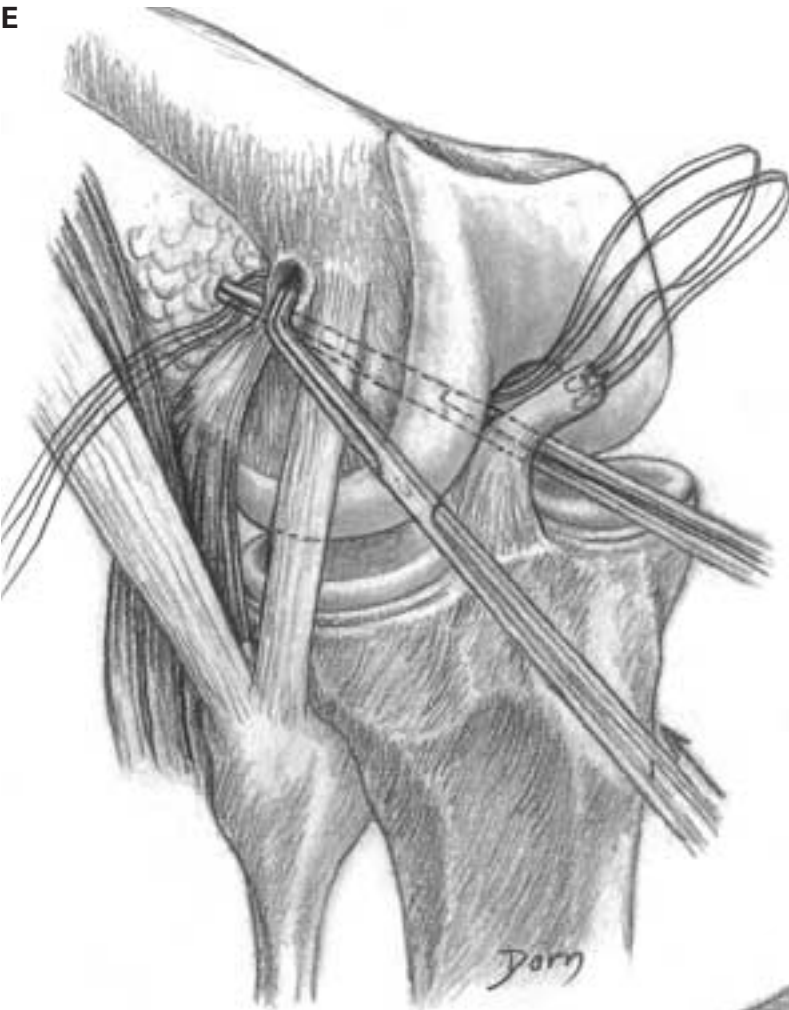
C A long forceps is passed through the tunnel, taking care of the vessels.

**D-G** The threads attached to the ligament are passed through posterior capsule and retrieved with the other forceps.

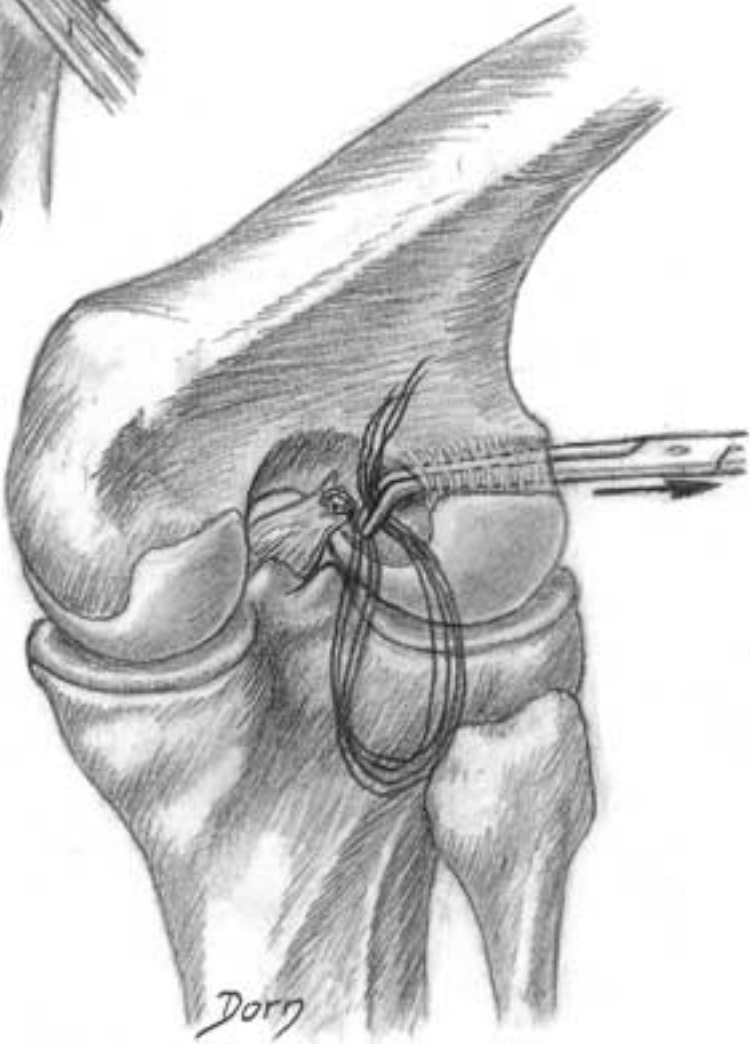
**D**



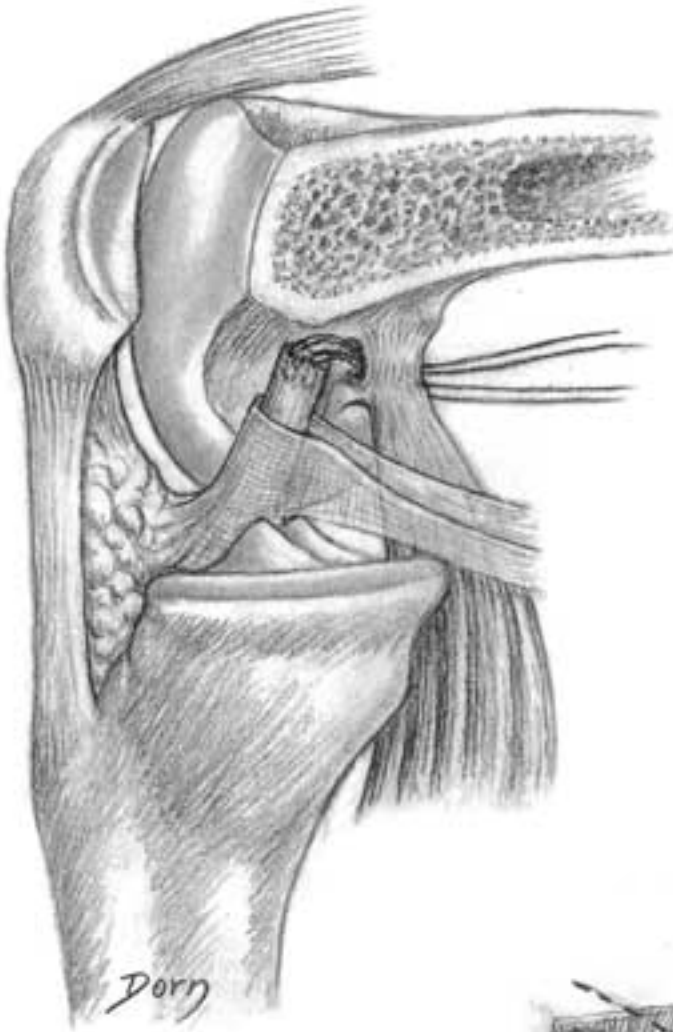E



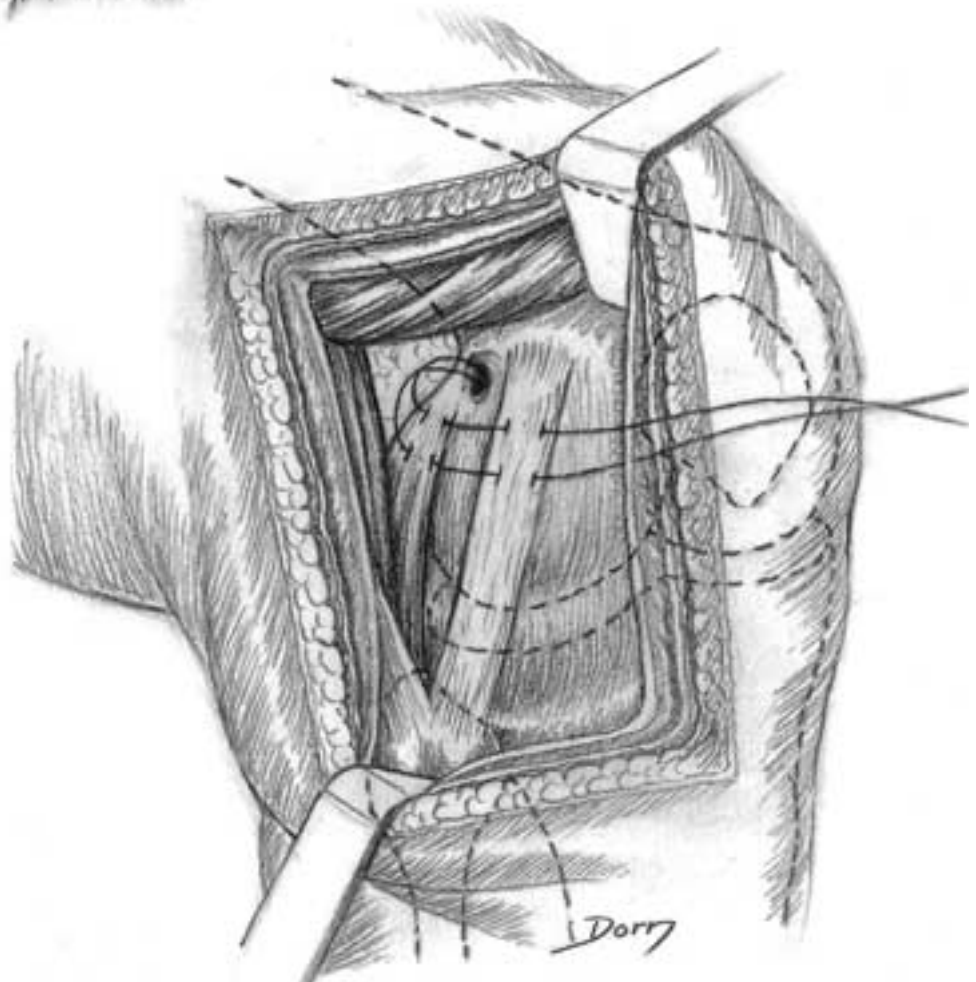
F



G



H The threads are passed through the tendon of the popliteal muscle and the lateral collateral ligament.

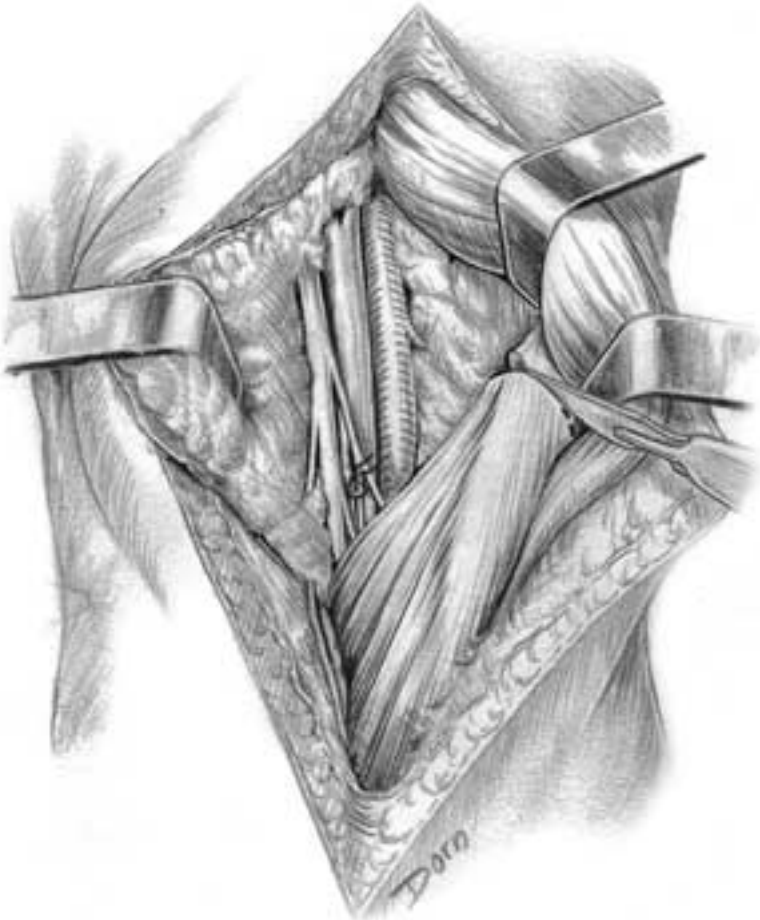
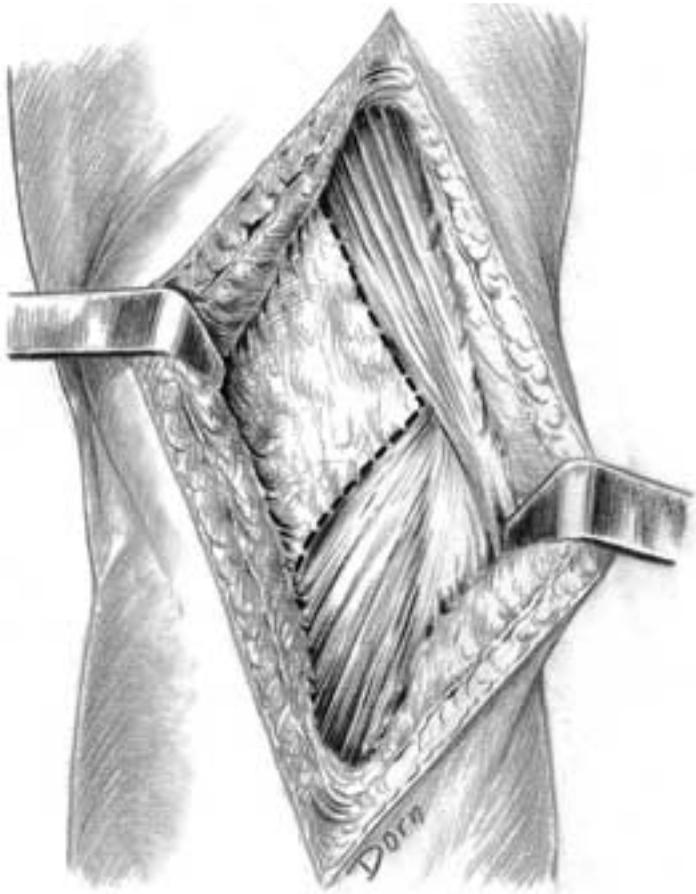




# Lower limb surgery

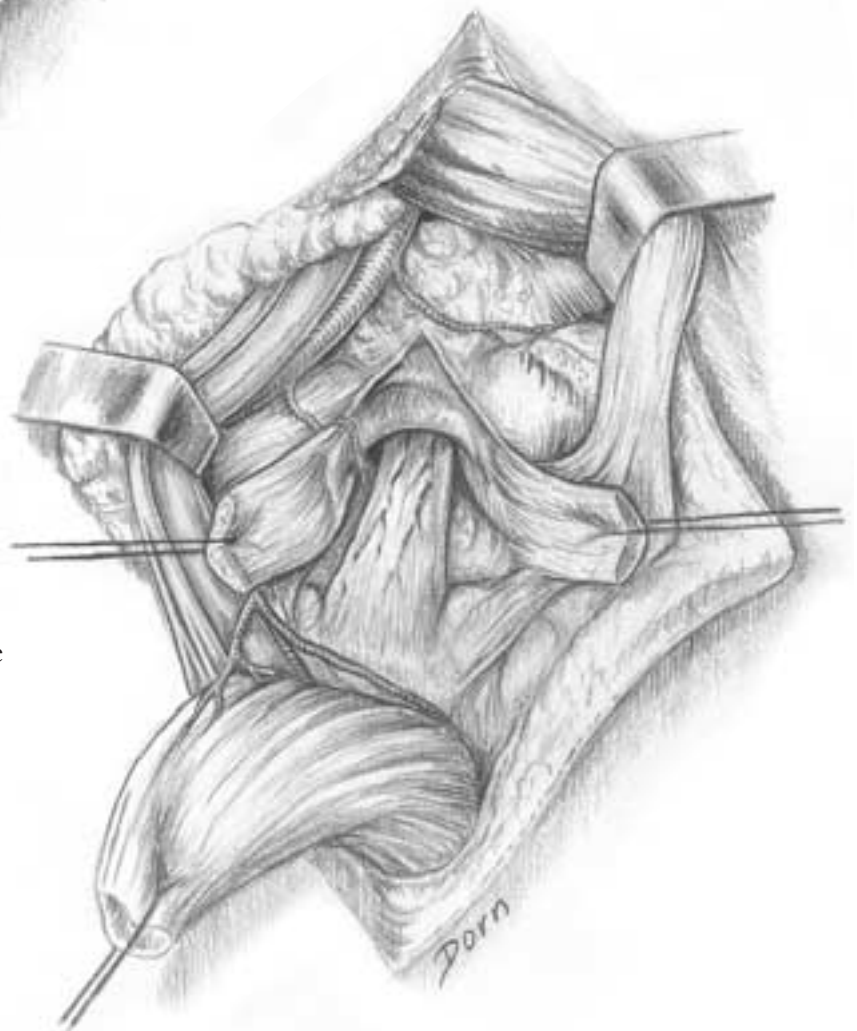
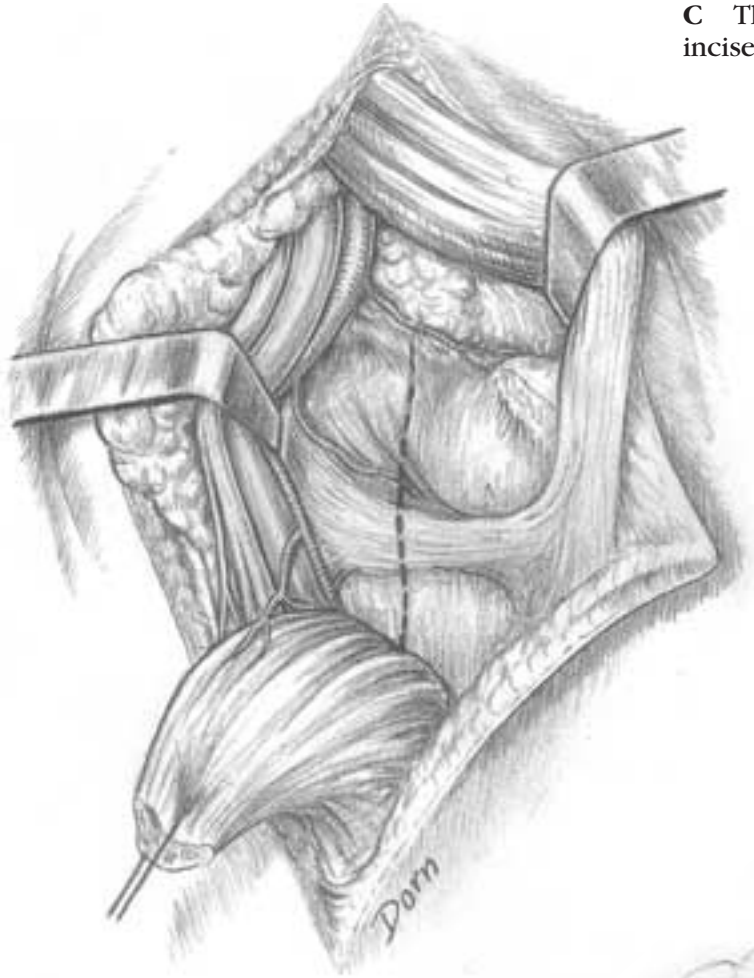Posterior approach to the posterior cruciate ligament (left limb)

**A** Popliteal fossa with the medial head of gastrocnemius.



**B** The tendon of the medial head is divided.

C The head is retracted laterally. The capsule is incised.

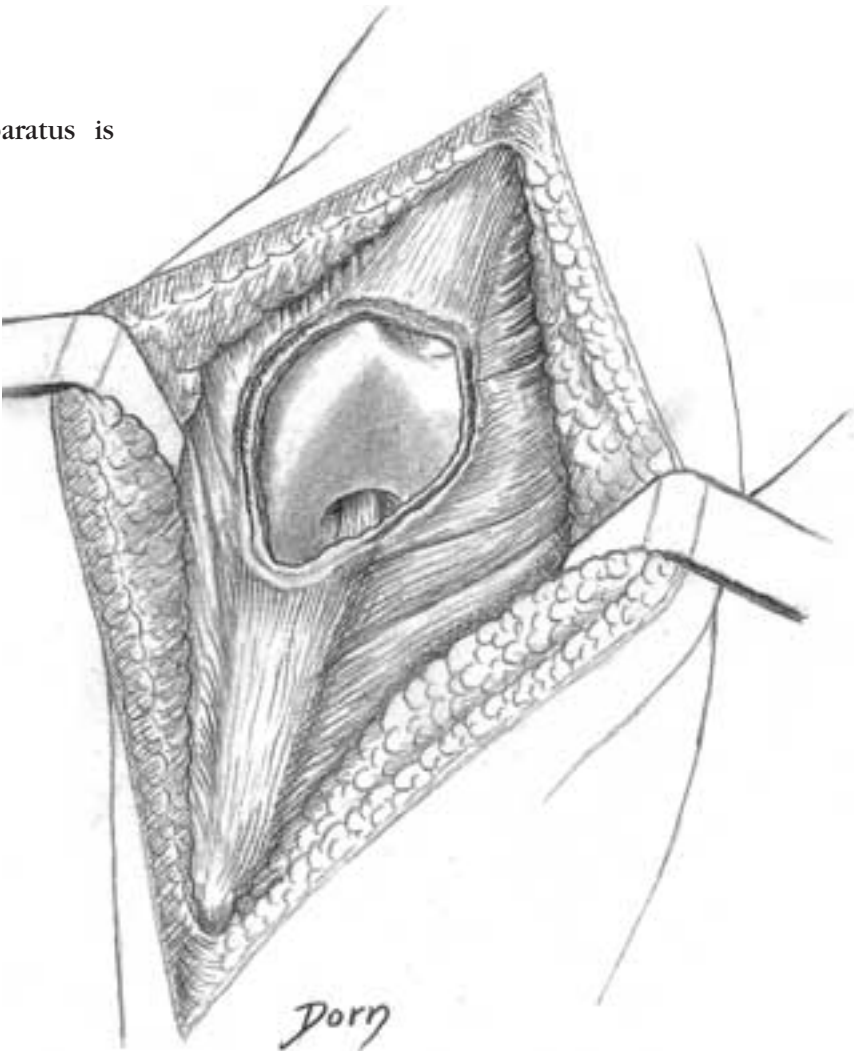
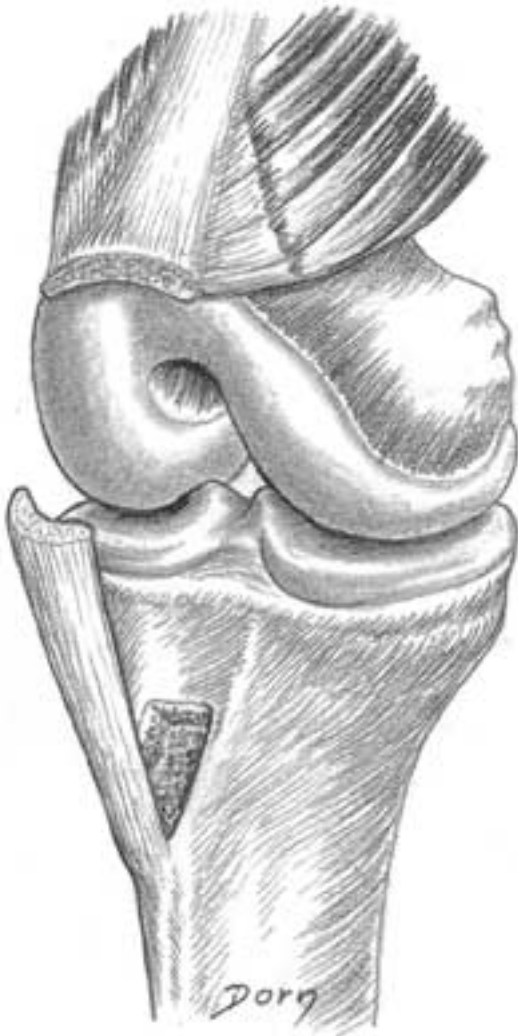

D Aspect of the posterior cruciate ligament.

# Lower limb surgery

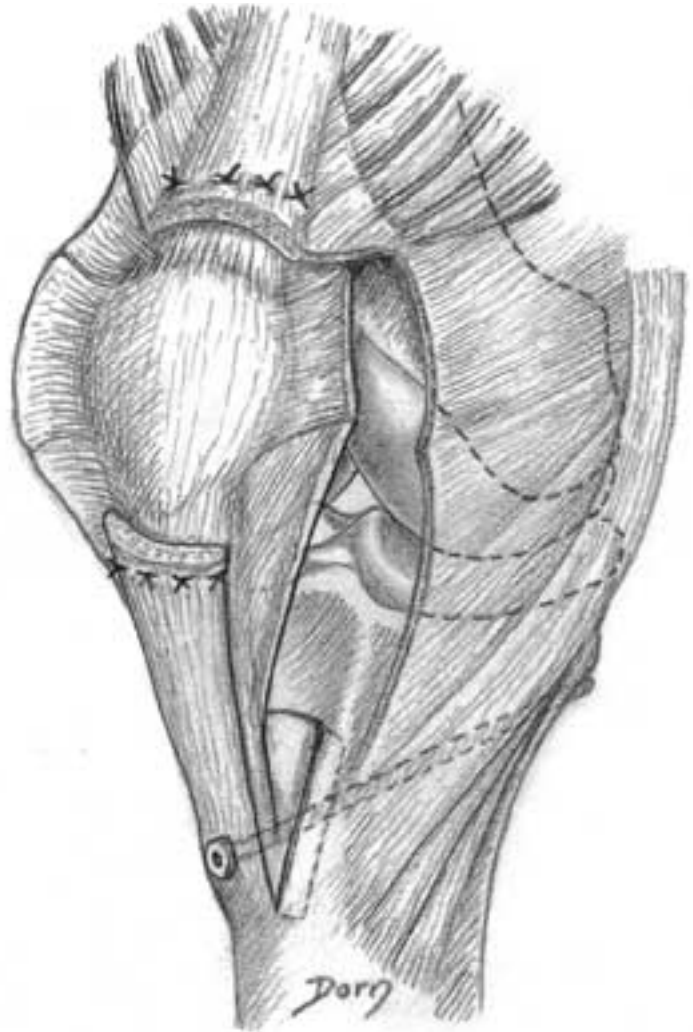
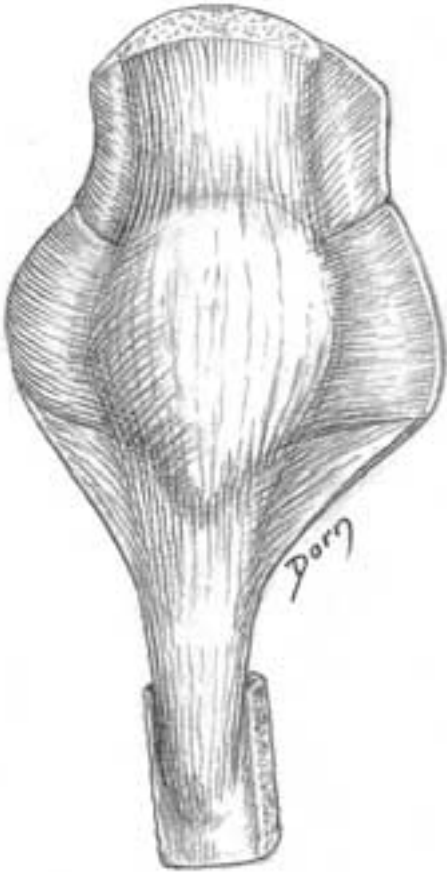
## Allograft of patella and patellar ligament

**A** The continuity of the extensor apparatus is interrupted.



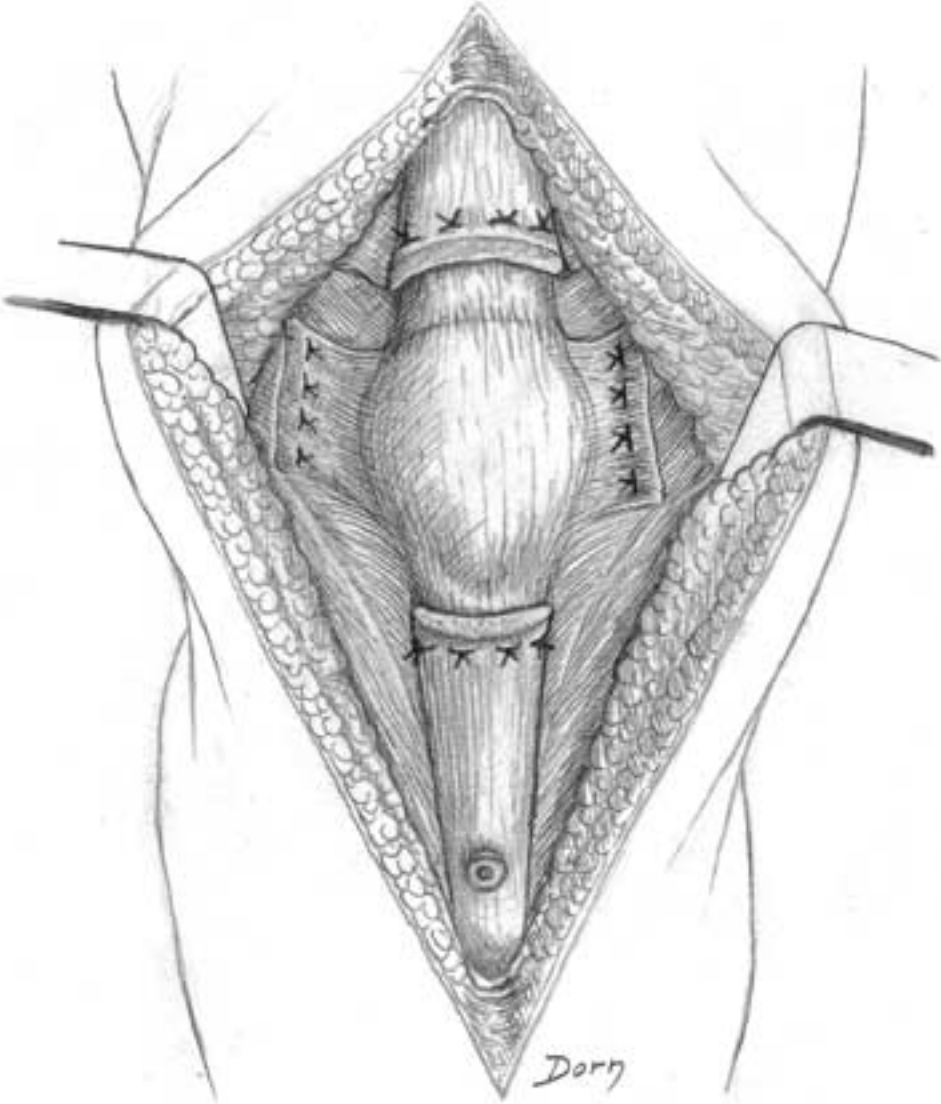
**B** Preparation of the recipient site.

**C** The allograft with a bone block and a short portion of rectus femoris tendon.    **D** Fixation and suture of the allograft.



# Lower limb surgery

E Final aspect with the sutures of the lateral patellar retinaculi.



## Exposures of the acetabulum

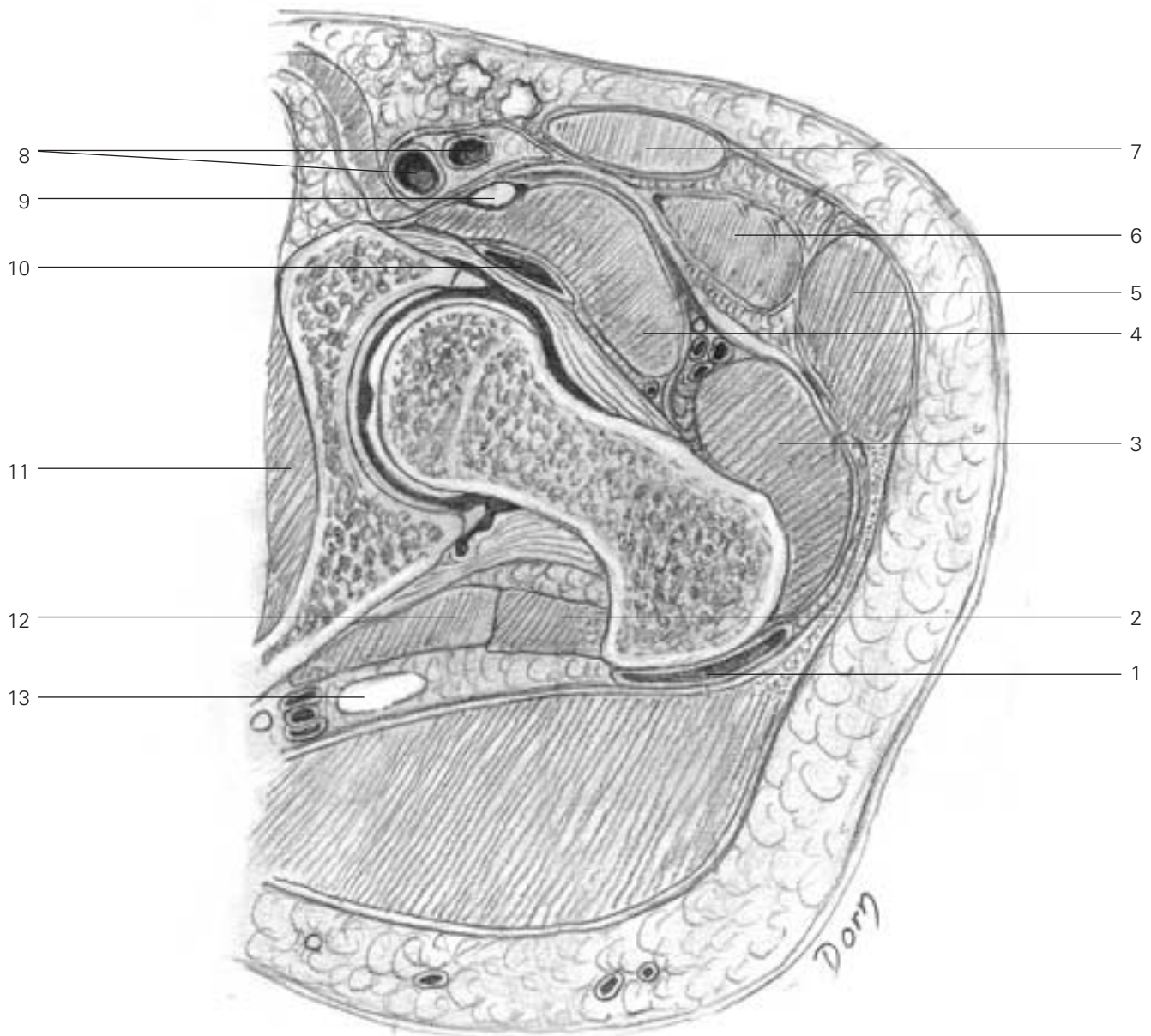
Surgery of the acetabulum is difficult given the depth of the joint and the extensive bone lesions.

Reconstructive surgery of the acetabulum was popularised by R. Judet and E. Letournel. The following series of drawings is among the most beautiful and precise artwork of Léon Dorn.

### Cross-section through the hip joint

Note the thick (and unknown) fascia lying at the deep aspect of the rectus femoris.

- 1 trochanteric bursa
- 2 obturator extremis
- 3 gluteus medius
- 4 ileopsoas
- 5 tensor fasciae latae
- 6 rectus femoris
- 7 sartorius
- 8 femoral vessels
- 9 femoral nerve
- 10 ilio psoas bursa
- 11 obturator internus
- 12 gemellus inferior
- 13 sciatic nerve



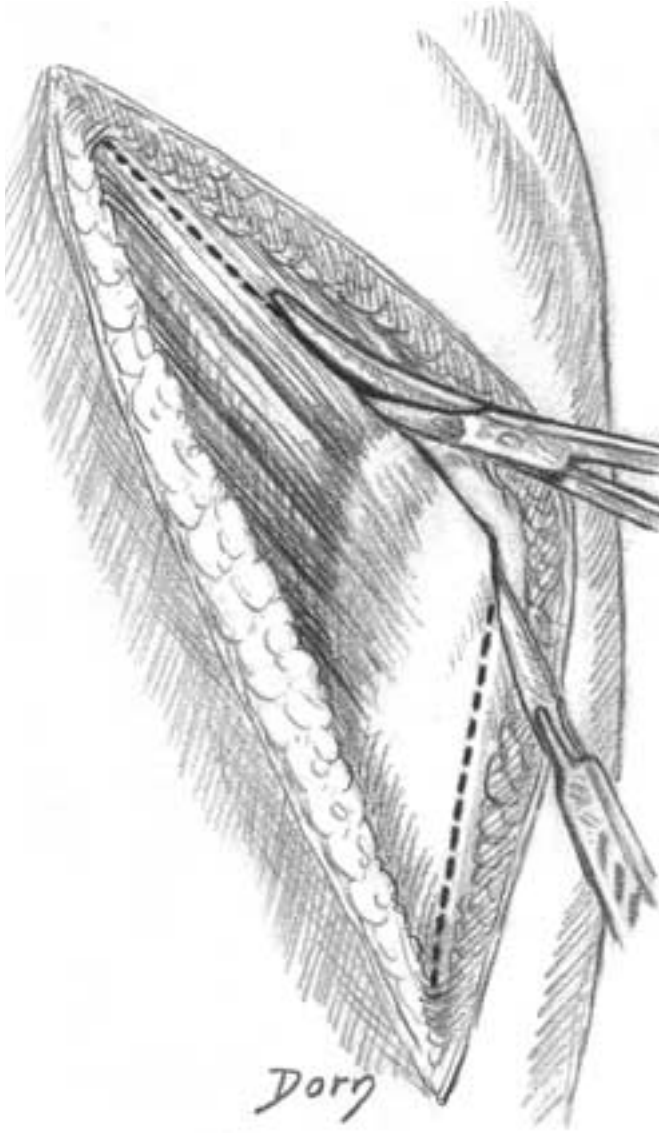
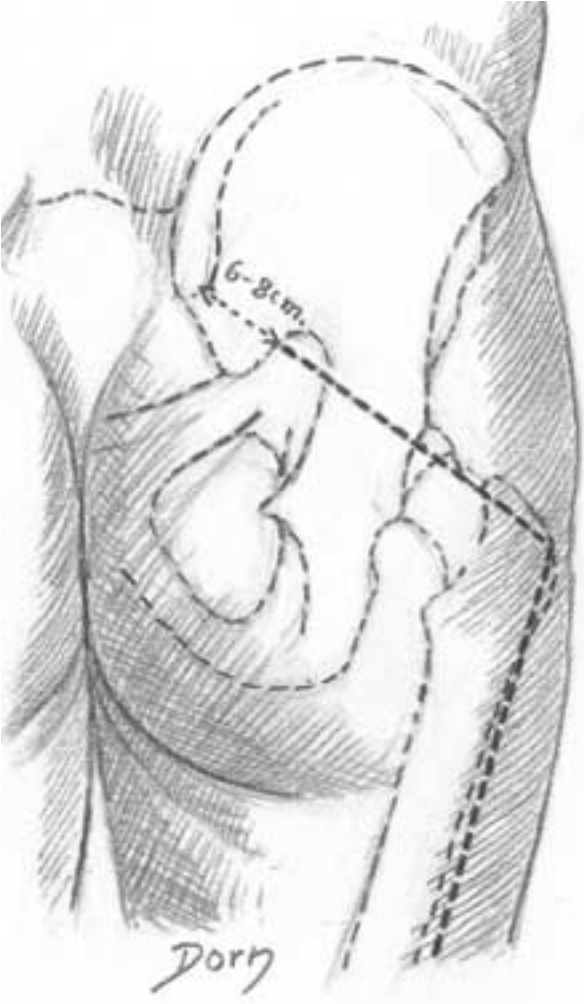
# Lower limb surgery

## Posterior approach to the acetabulum (Kocher–Langenbeck)

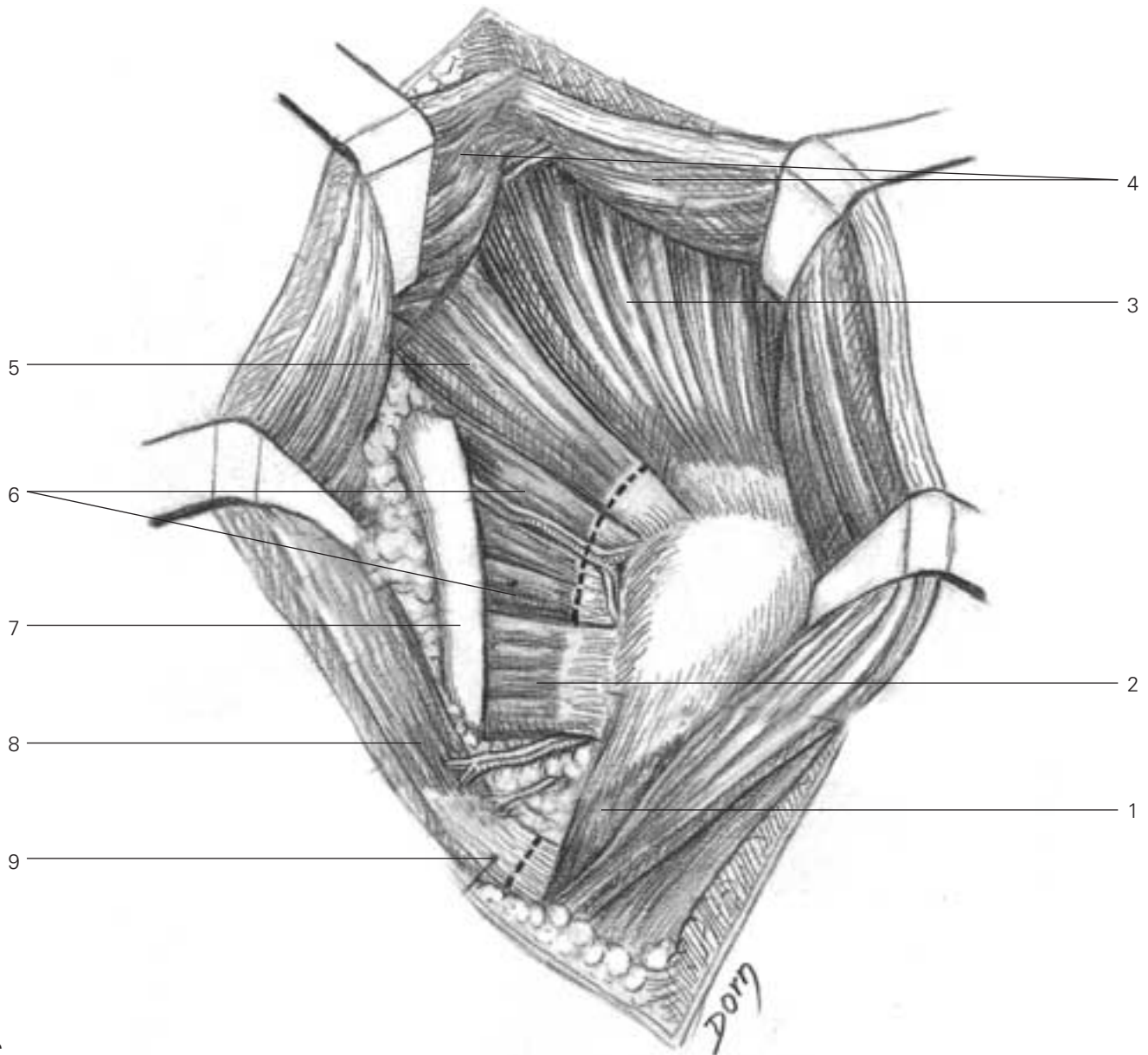
Its indication is the fracture of the posterior wall.

**A** Skin incision.

**B** Incision of the iliotibial tract and splitting of the fibres of the gluteus maximum muscle.



## C Exposure of the sciatic nerve and the external rotators of the hip.



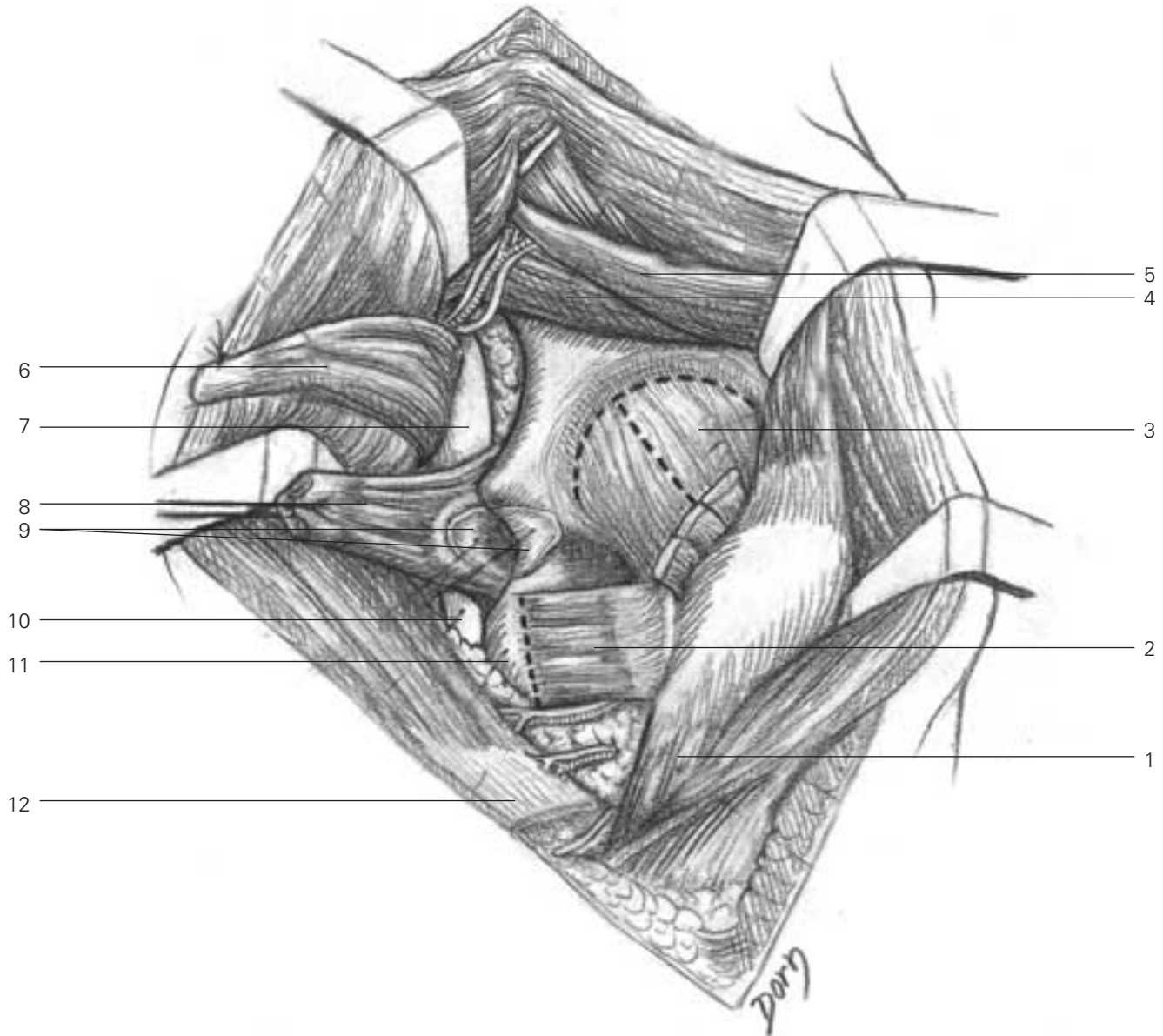
### C

- 1 vastus lateralis
- 2 quadratus femoris
- 3 gluteus medius
- 4 gluteus maximus, split
- 5 piriformis
- 6 obturator internus and gemelli
- 7 sciatic nerve
- 8 gluteus maximus
- 9 distal tendon of gluteus maximus (to be cut)



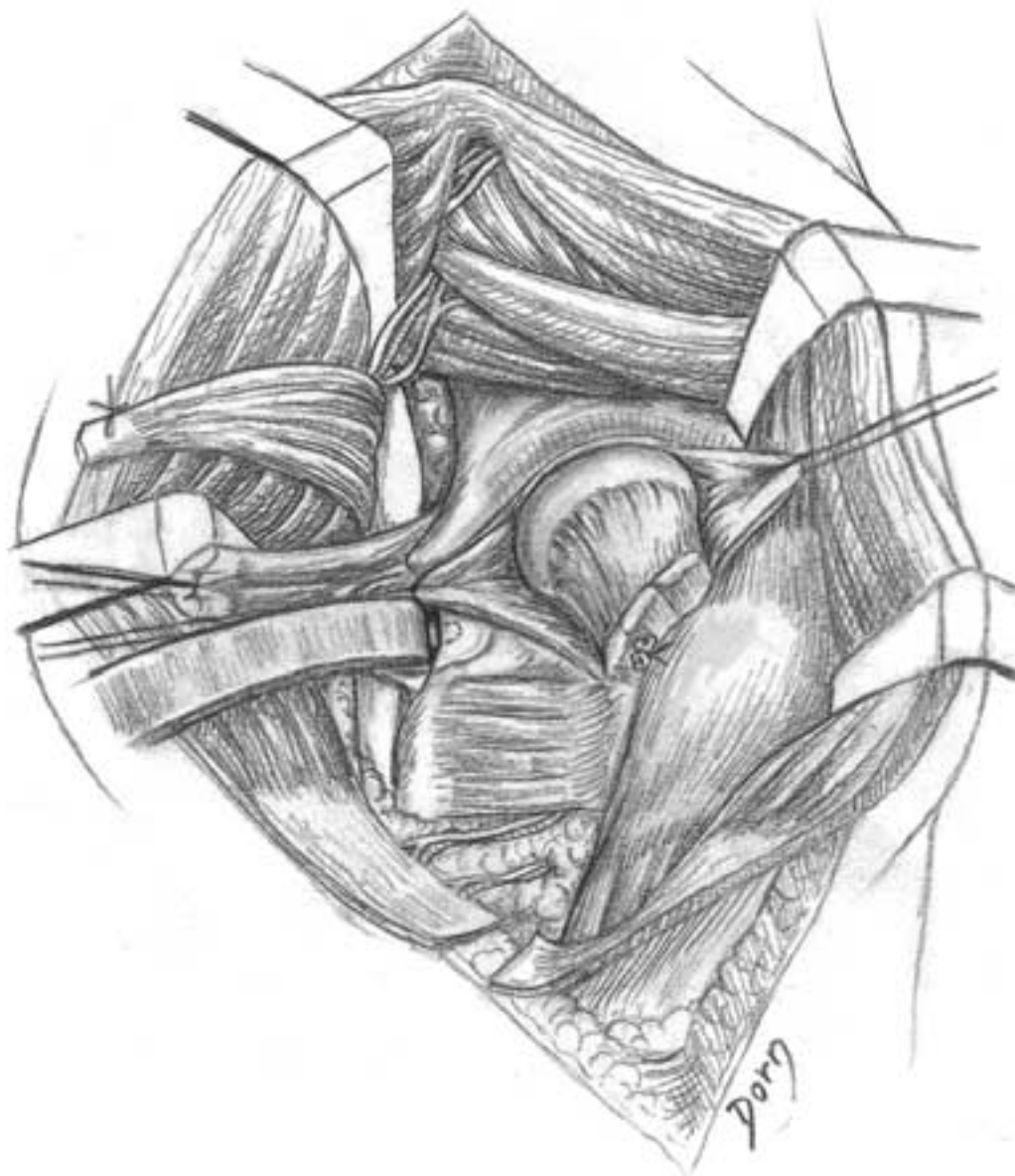
# Lower limb surgery

**D** The rotators are retracted, exposing the capsule; one of the key steps is to find the bursa between the ischium and the obturator internis and the gemelli.



- D**
- 1 vastus lateralis
  - 2 quadratus femoris
  - 3 capsule
  - 4 gluteus minimus
  - 5 gluteus medius
  - 6 piriformis
  - 7 sciatic nerve
  - 8 obturator internus and gemelli
  - 9 lesser sciatic notch and bursa
  - 10 sciatic nerve
  - 11 ischion
  - 12 distal tendon of gluteus maximus

**E** The capsule is incised. Note the retractor which has been placed into the plane of the bursa.



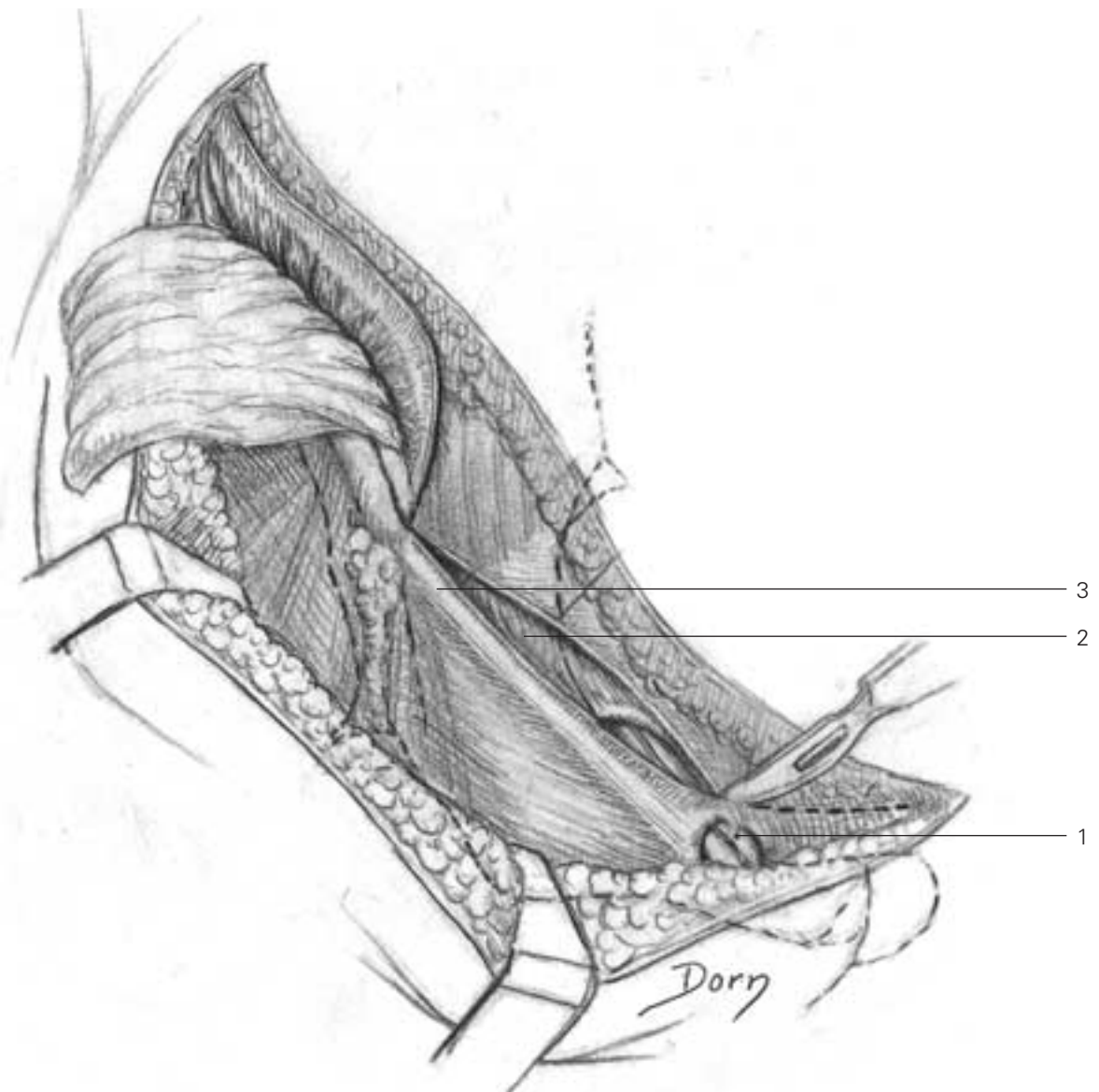
# Lower limb surgery

---

## Inguinal approach to the acetabulum

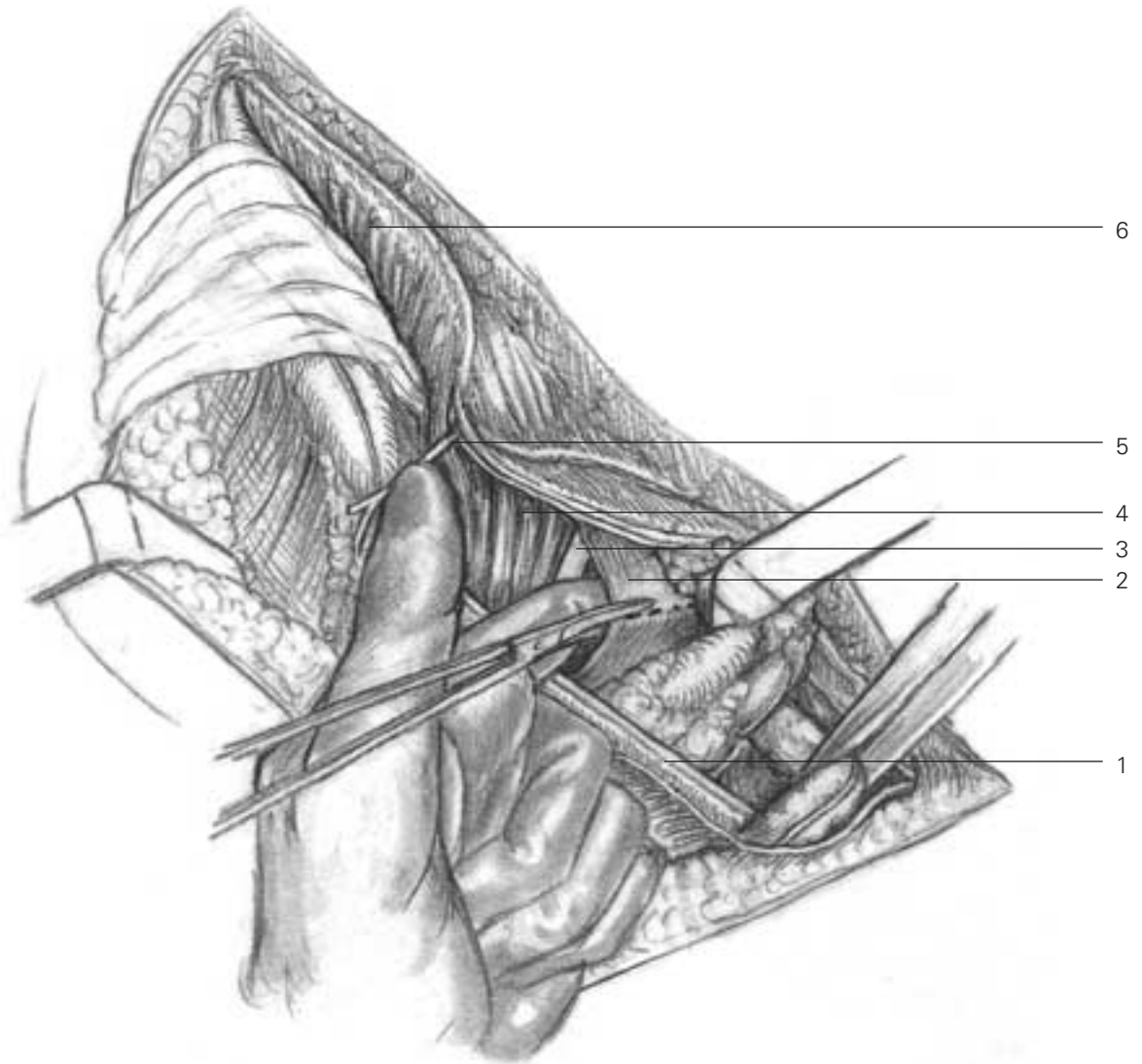
Its indications are the fracture of anterior wall or anterior column and some complex fractures involving both columns of the acetabulum.

**A** The fascia is incised in line with the skin incision.



- A**
- 1 spermatic cord
  - 2 internal oblique
  - 3 inguinal ligament

**B** The spermatic cord, the external iliac vessels, the femoral nerve, the psoas muscle and the lateral cutaneous nerve of the thigh have been isolated. The iliopsoas fascia is severed.

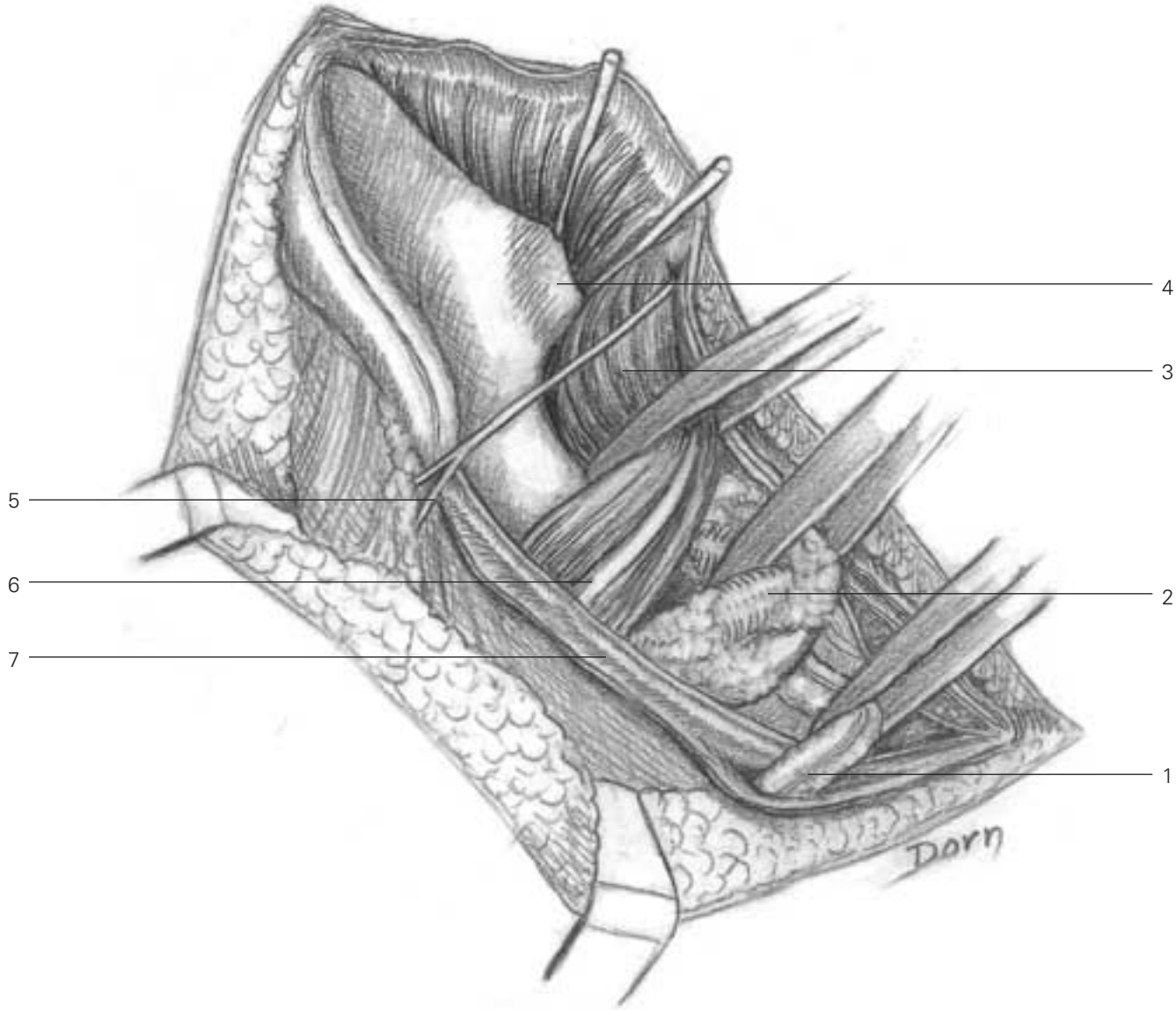


**B**

- 1 inguinal ligament
- 2 iliopsoas fascia
- 3 femoral nerve
- 4 iliopsoas
- 5 lateral cutaneous nerve of thigh
- 6 iliacus

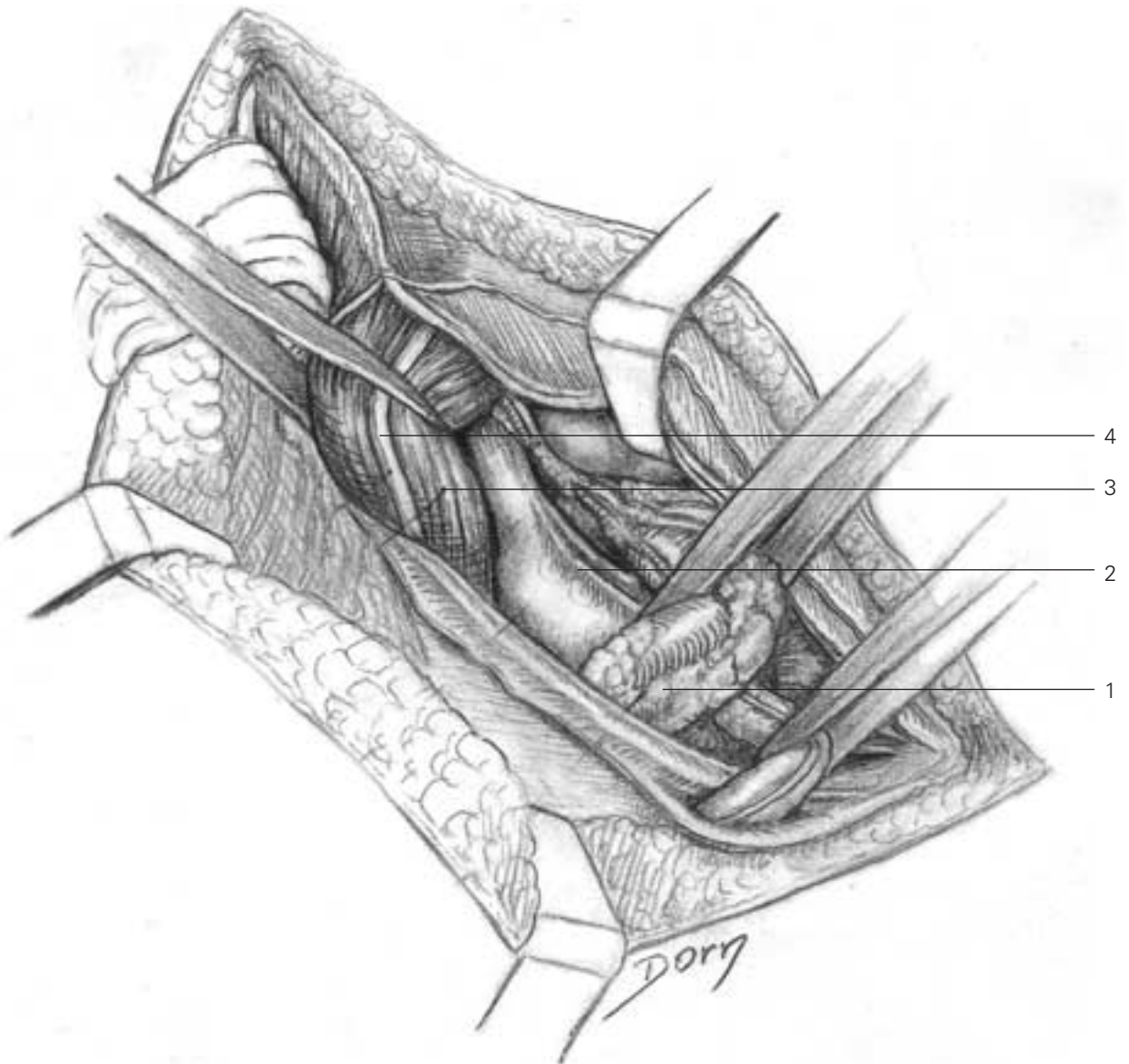
# Lower limb surgery

C All the structures are held and retracted by rubber slings. Medial retraction of the iliopsoas provides access to the iliac fossa.



- C**
- 1 spermatic cord
  - 2 external iliac vessels sheath
  - 3 ilio psoas
  - 4 sacroiliac joint
  - 5 lateral cutaneous nerve of the thigh
  - 6 femoral nerve
  - 7 inguinal ligament

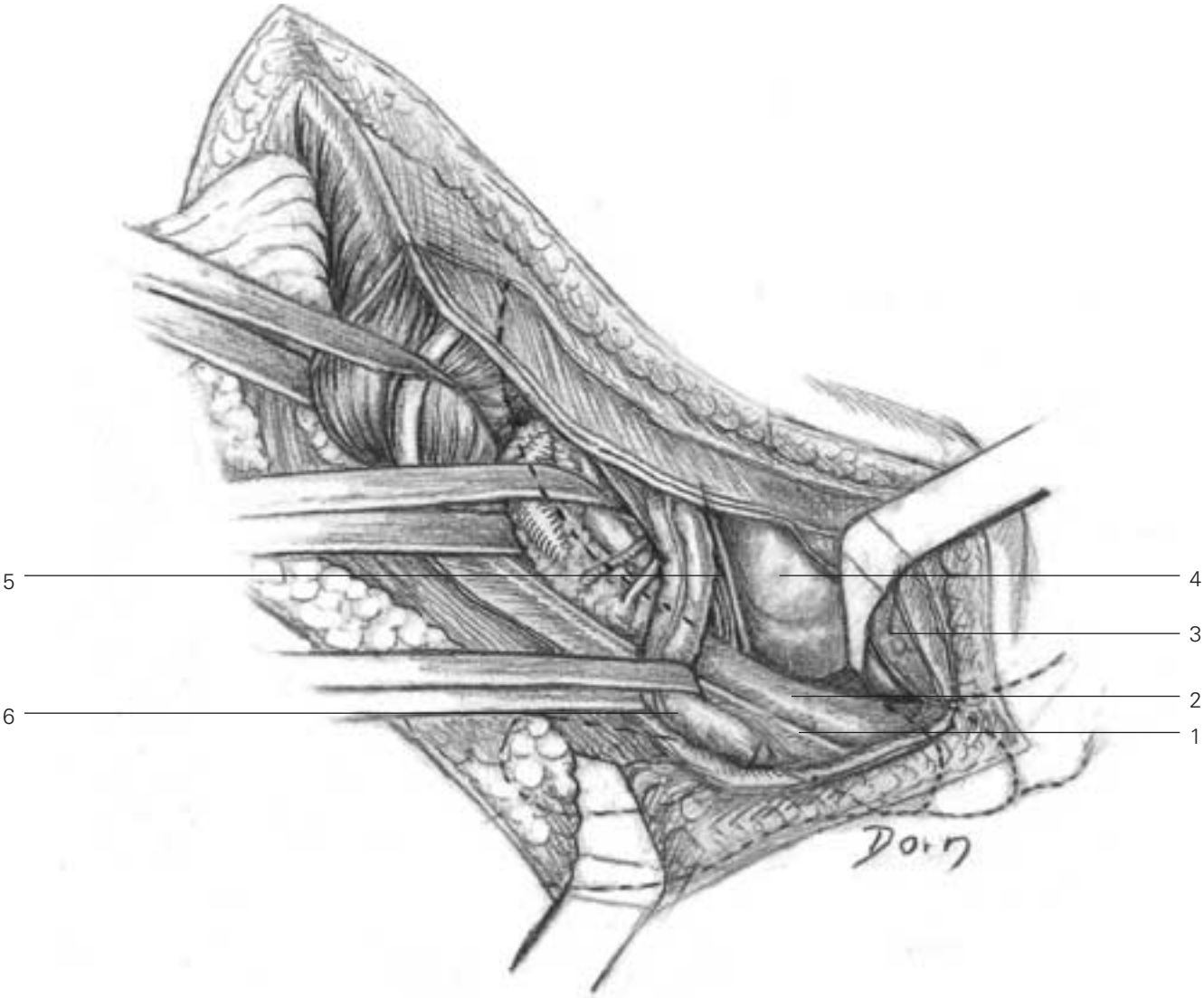
**D** Lateral retraction of the iliopsoas gives access to the pelvic brim.



- D**
- 1 external iliac vessels
  - 2 ilio pectineal eminence
  - 3 ilio psoas
  - 4 femoral nerve

# Lower limb surgery

**E** Lateral retraction of the vessels and spermatic cord gives access to the superior pubic ramus.

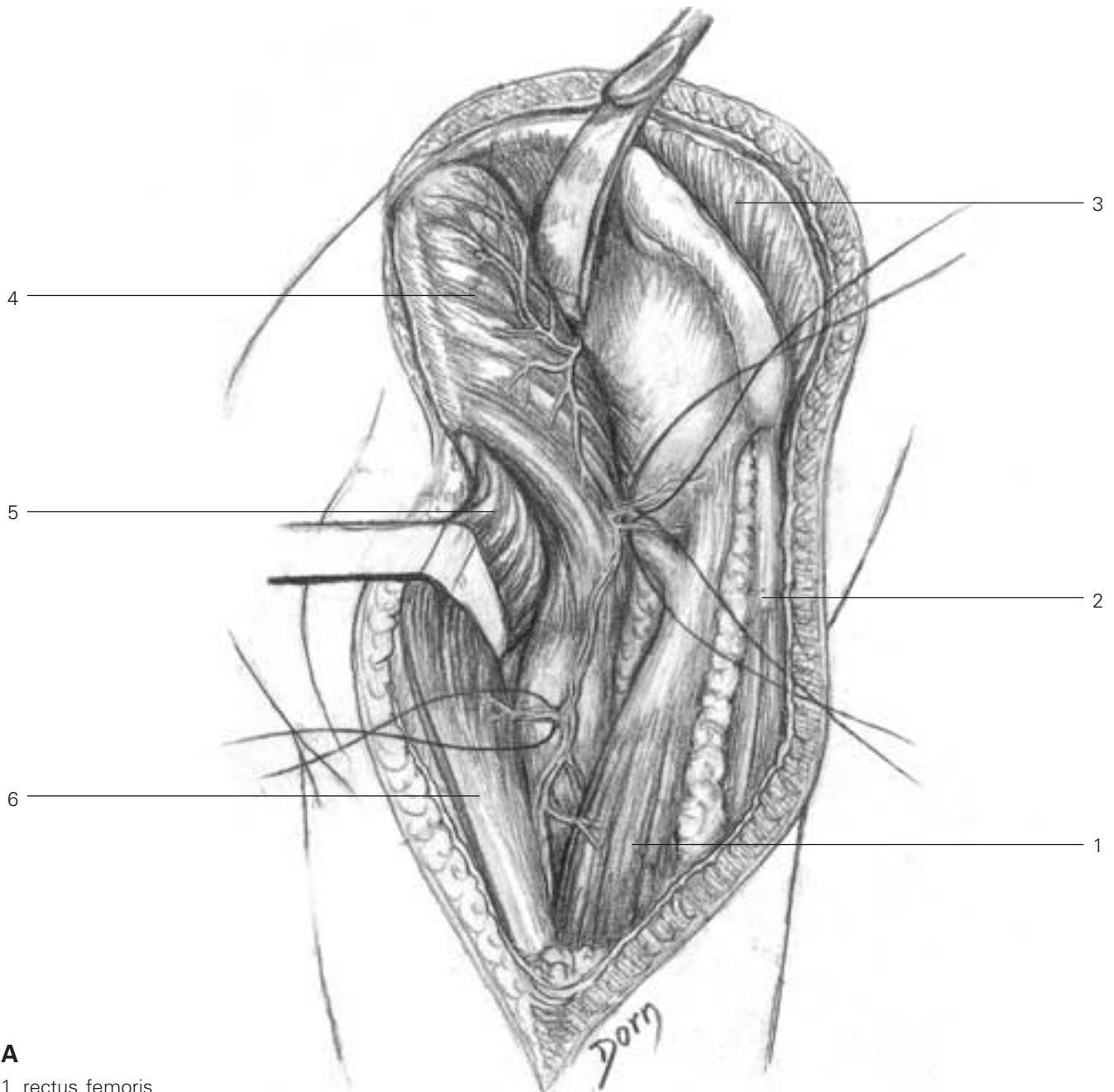


- E**
- 1 inguinal ligament
  - 2 superior pubic rami
  - 3 rectus abdominus
  - 4 urinary bladder
  - 5 neurovascular obturator bundle
  - 6 spermatic cord

## Extended iliofemoral approach to the acetabulum

This approach is also indicated in fractures of both columns.

**A** The gluteal muscles are reflected from the external iliac wing.



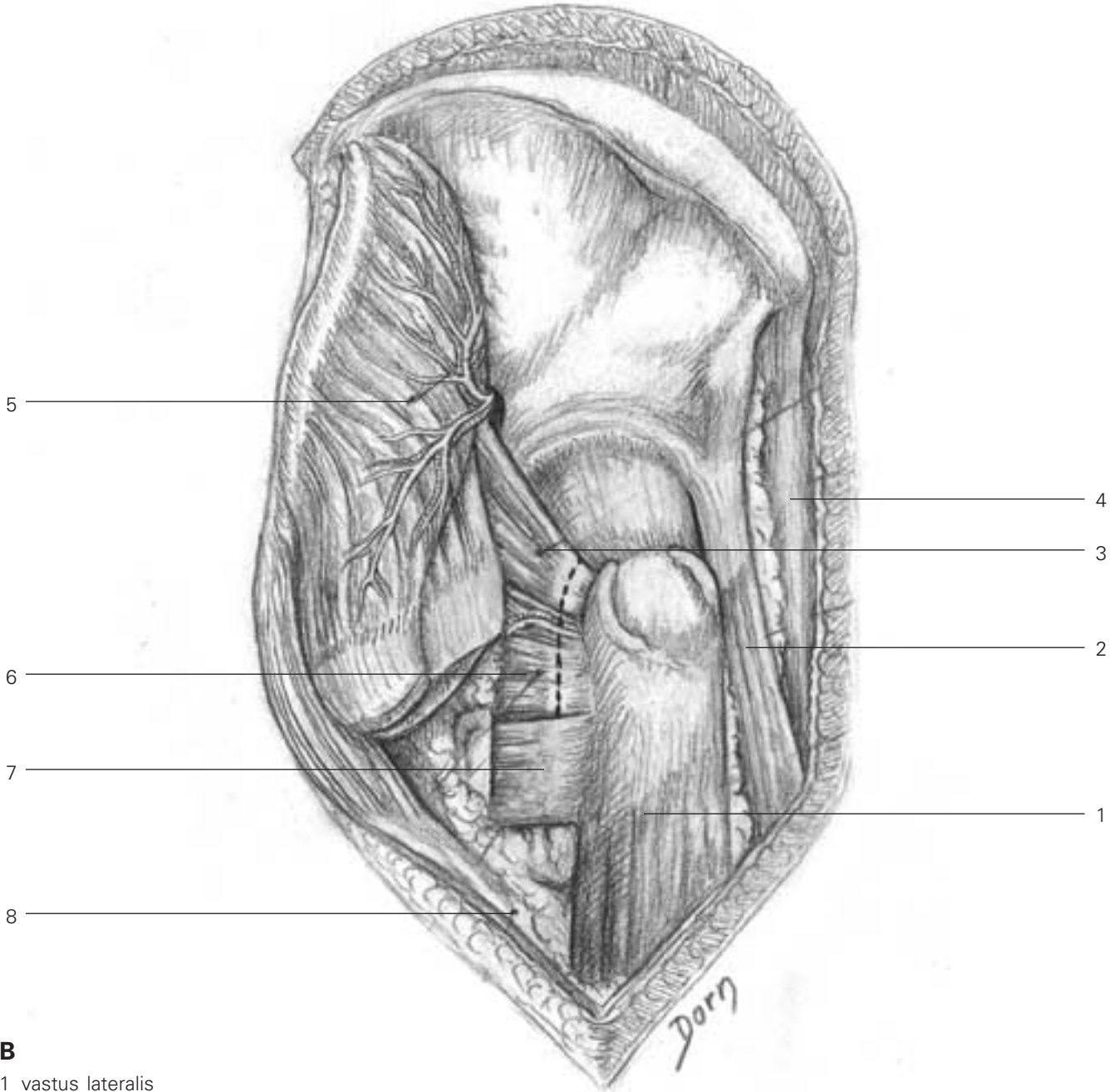
- A**
- 1 rectus femoris
  - 2 sartorius
  - 3 iliacus
  - 4 gluteus medius
  - 5 tensor fasciae latae
  - 6 fascia lata



# Lower limb surgery

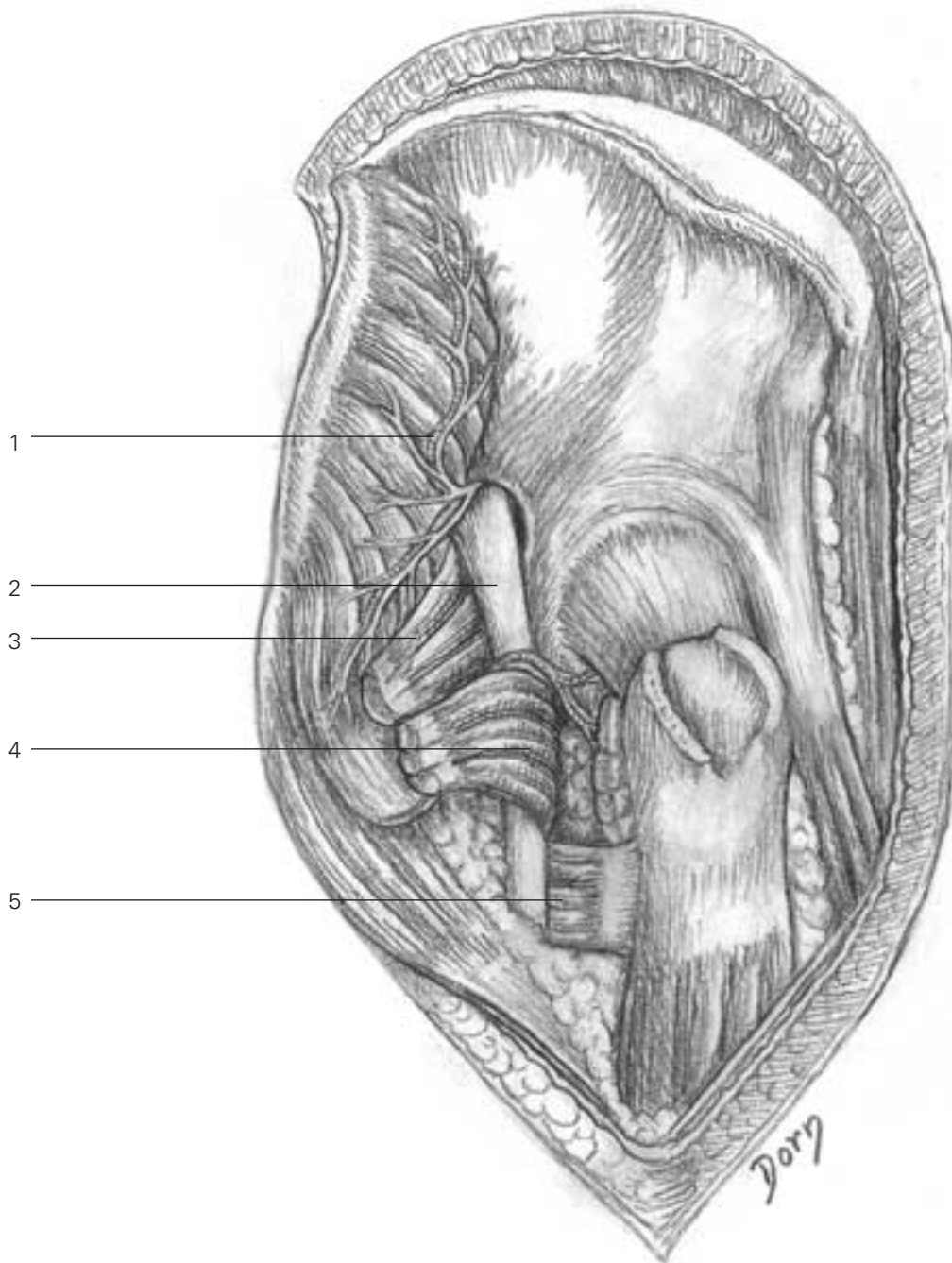
---

**B** The insertions of gluteus minimus and gluteus medius have been divided. The massive muscular flap comprising the gluteal muscles and tensor fascia latae is retracted posteriorly, exposing the short external rotators.



- B**
- 1 vastus lateralis
  - 2 rectus femoris
  - 3 piriformis
  - 4 sartorius
  - 5 gluteus medius
  - 6 pelvitrochanteric muscles
  - 7 quadratus femoris
  - 8 distal tendon of gluteus maximus

C The short rotators have been divided and retracted. Retraction of the piriformis exposes the sciatic nerve. The whole acetabulum is visible.

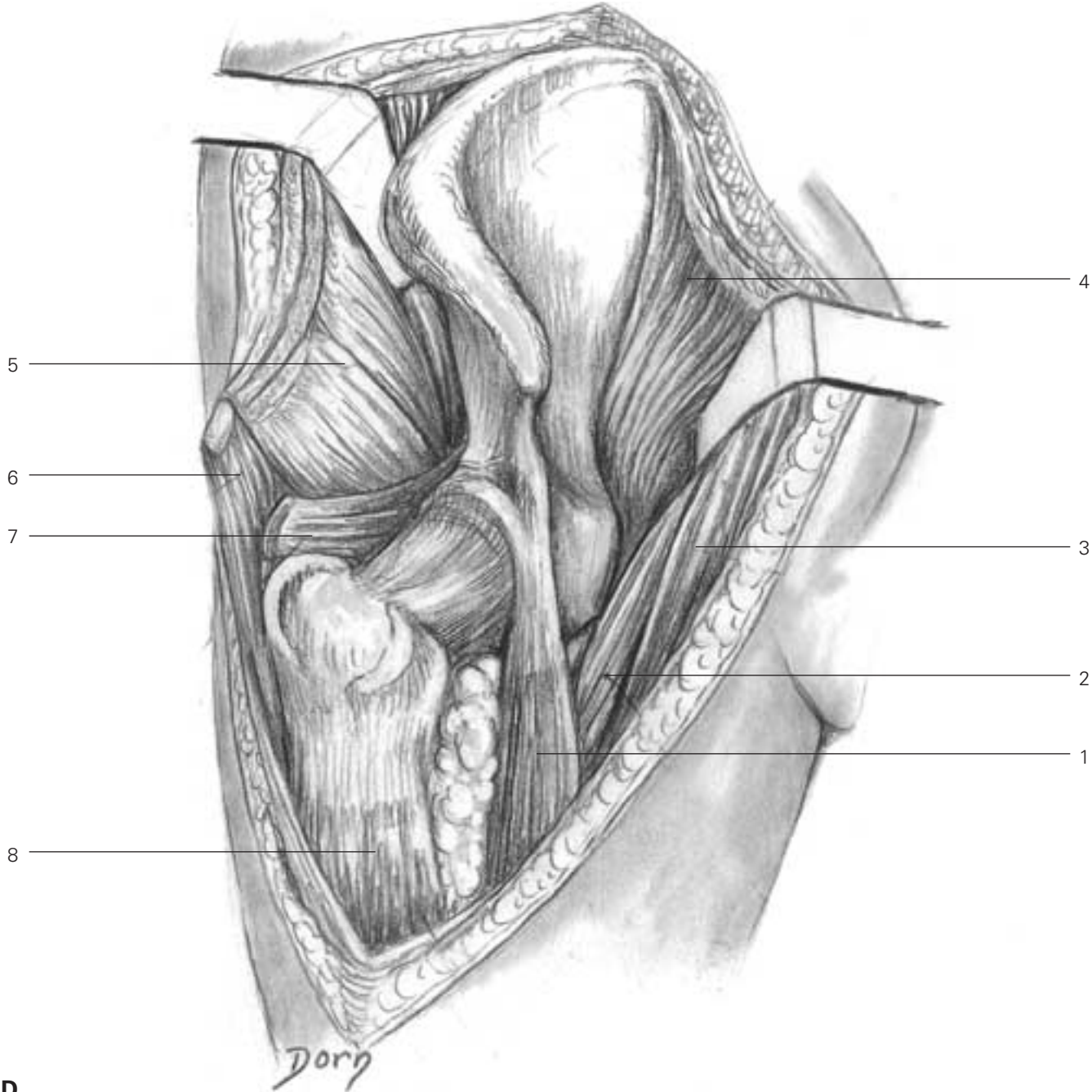


## C

- 1 superior gluteal pedicle and nerve
- 2 sciatic nerve
- 3 piriformis
- 4 obturator internus and the gemelli
- 5 quadratus femoris

# Lower limb surgery

**D** Elevation of the iliacus, sartorius and inguinal ligament gives access to the internal iliac fossa.

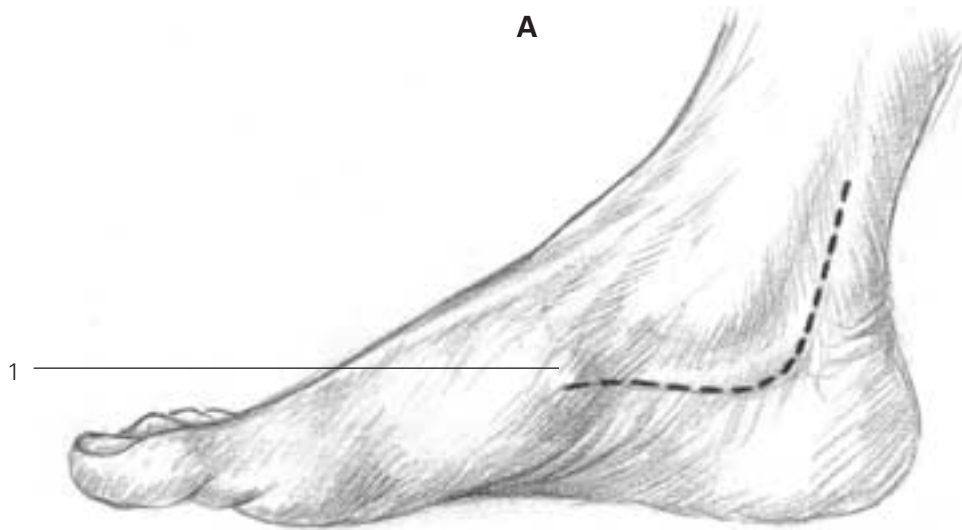


- D**
- 1 rectus femoris
  - 2 iliopsoas
  - 3 sartorius
  - 4 iliacus
  - 5 glutei
  - 6 tensor fasciae latae
  - 7 piriformis
  - 8 vastus lateralis

## Approaches to the foot and ankle

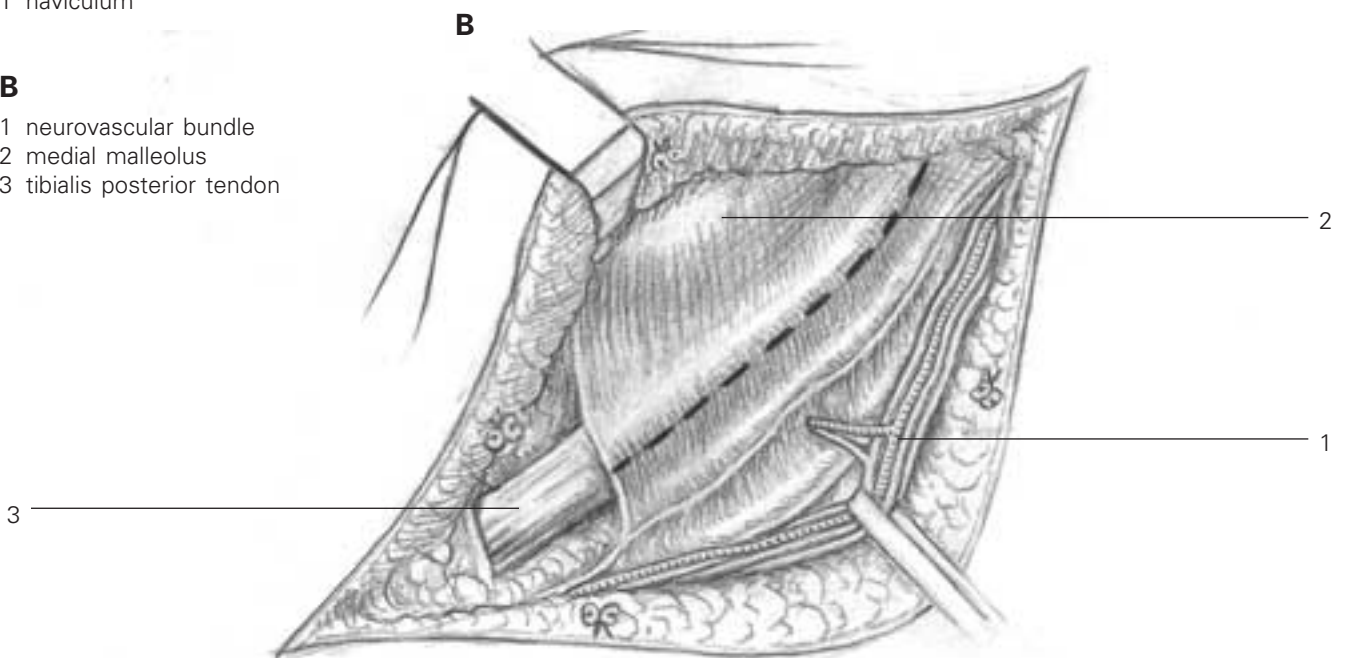
### Posteromedial approach to the ankle

**A, B** Skin incision. The flexor retinaculum is incised in line with the skin. The neurovascular bundle is identified.



**A**  
1 naviculum

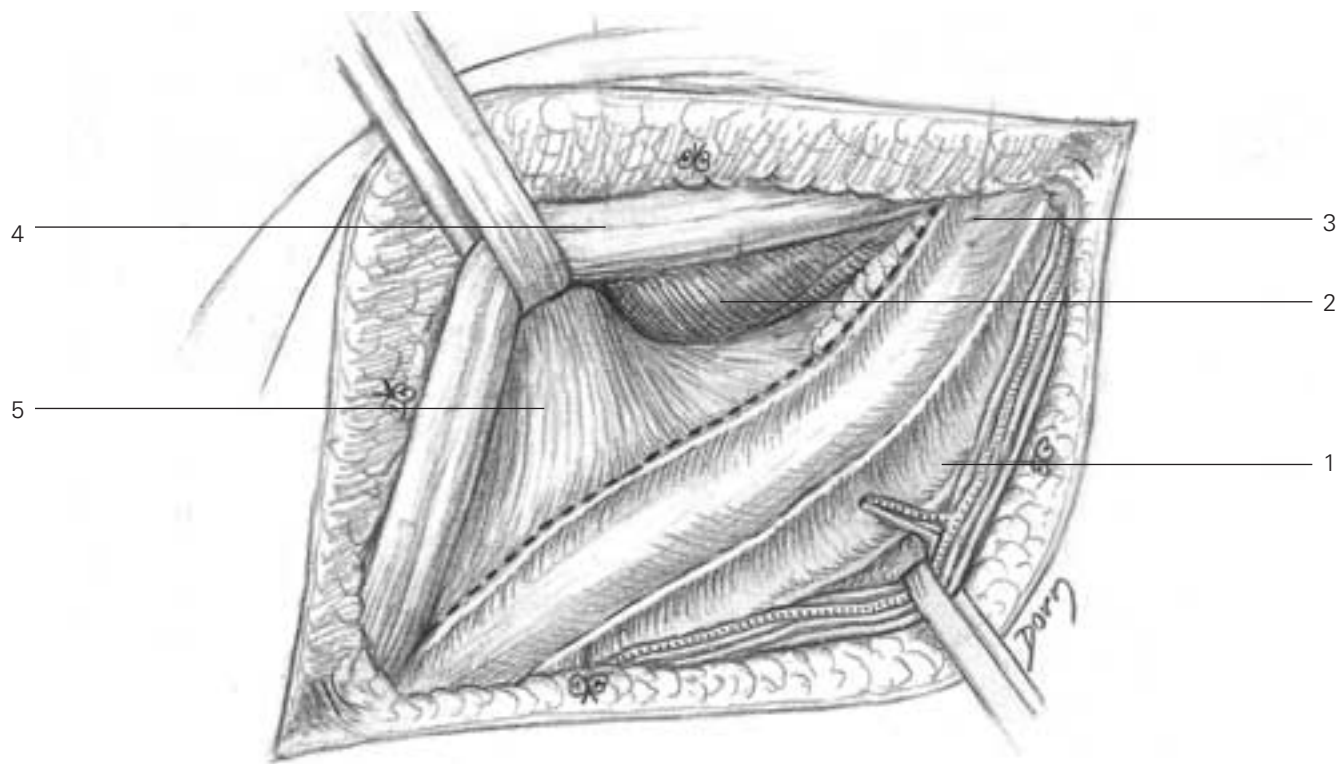
**B**  
1 neurovascular bundle  
2 medial malleolus  
3 tibialis posterior tendon



# Lower limb surgery

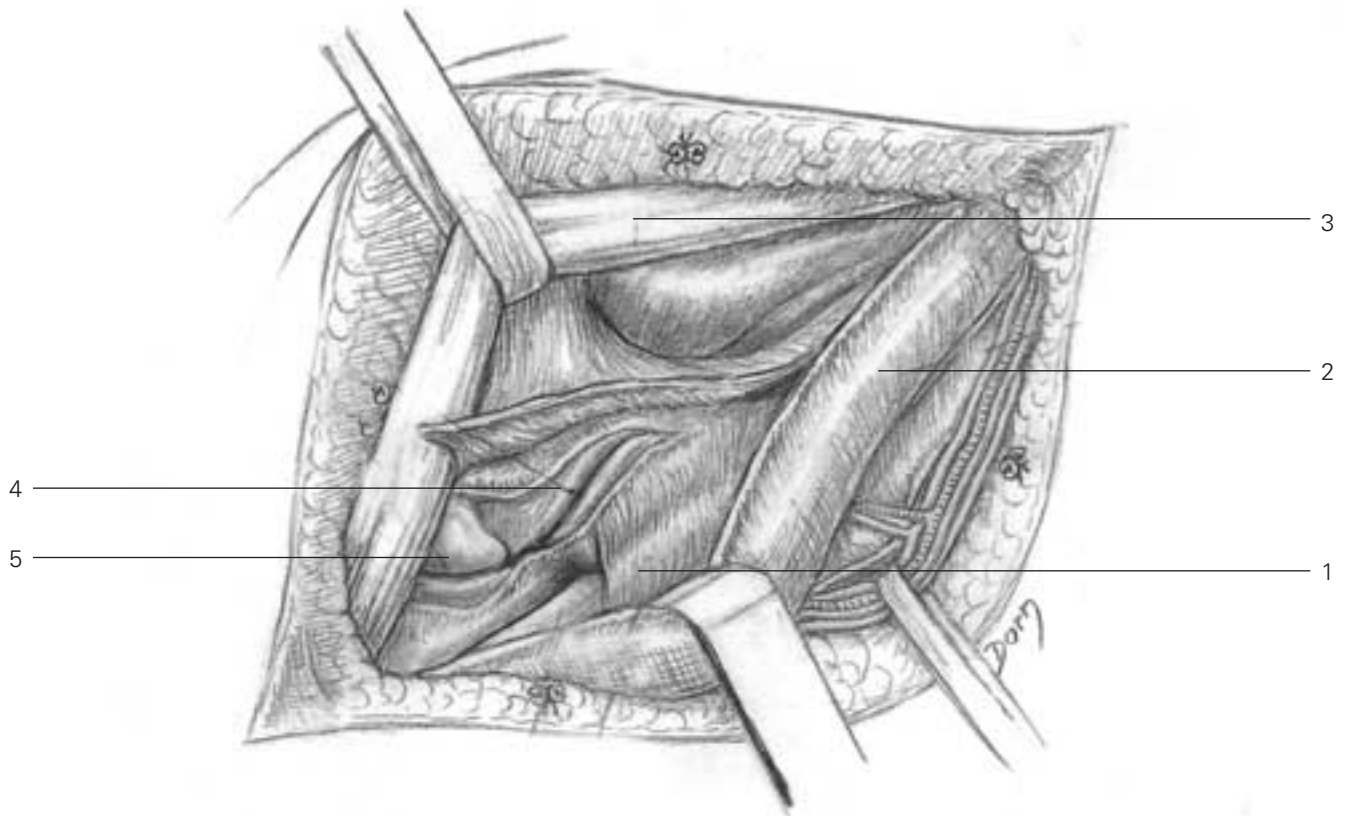
---

**C** The tendon of tibialis posterior is retracted anteriorly exposing the deltoid ligament.



- C**
- 1 neurovascular bundle sheath
  - 2 malleolus medialis
  - 3 tendon of flexor digitorum longus within its sheath
  - 4 tibialis posterior tendon
  - 5 deltoid ligament

**D** The capsule is incised, giving access to the subtalar joint and the posterior aspect of the ankle, chiefly if Achilles' tendon has been divided.



**D**

- 1 flexor hallucis longus
- 2 flexor digitorum longus retracted
- 3 tibialis posterior tendon
- 4 subtalar joint
- 5 head of talus

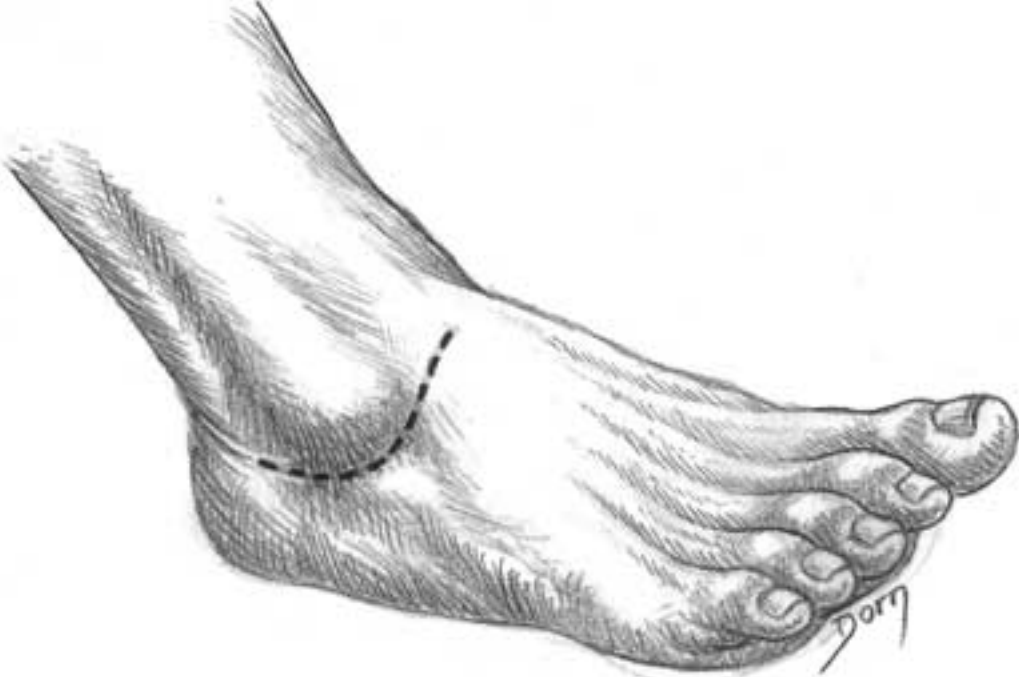# Lower limb surgery

## Lateral approach to the subtalar and midtarsal joint

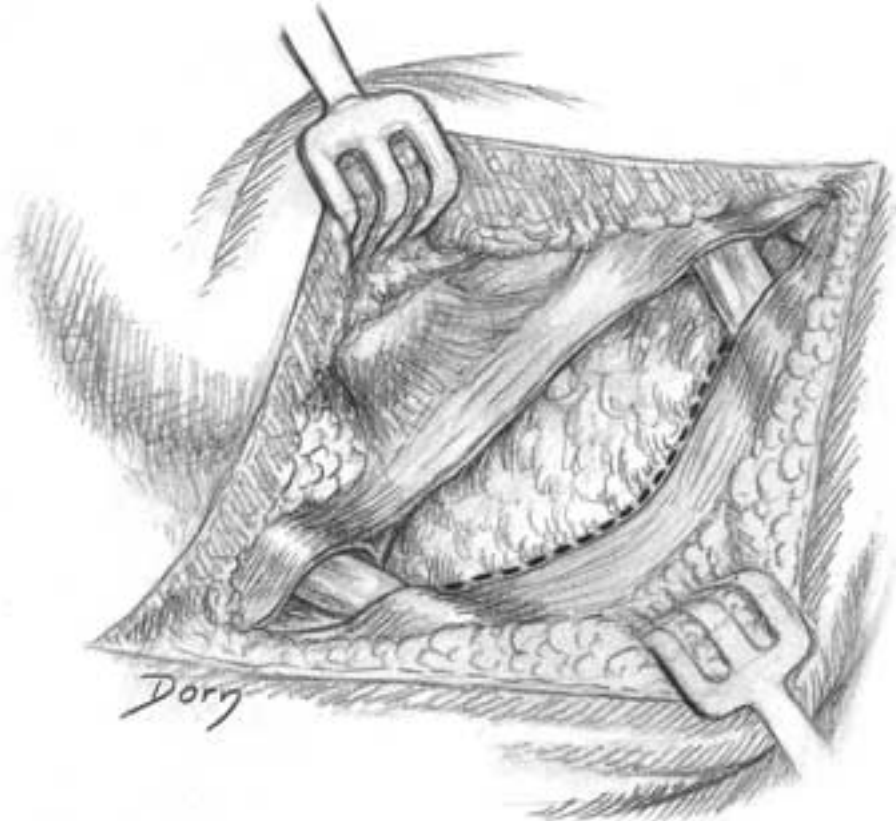
This exposure is used for fusion of the joints.

**A, B** Skin incision, exposing the inferior extensor retinaculum.

**A**



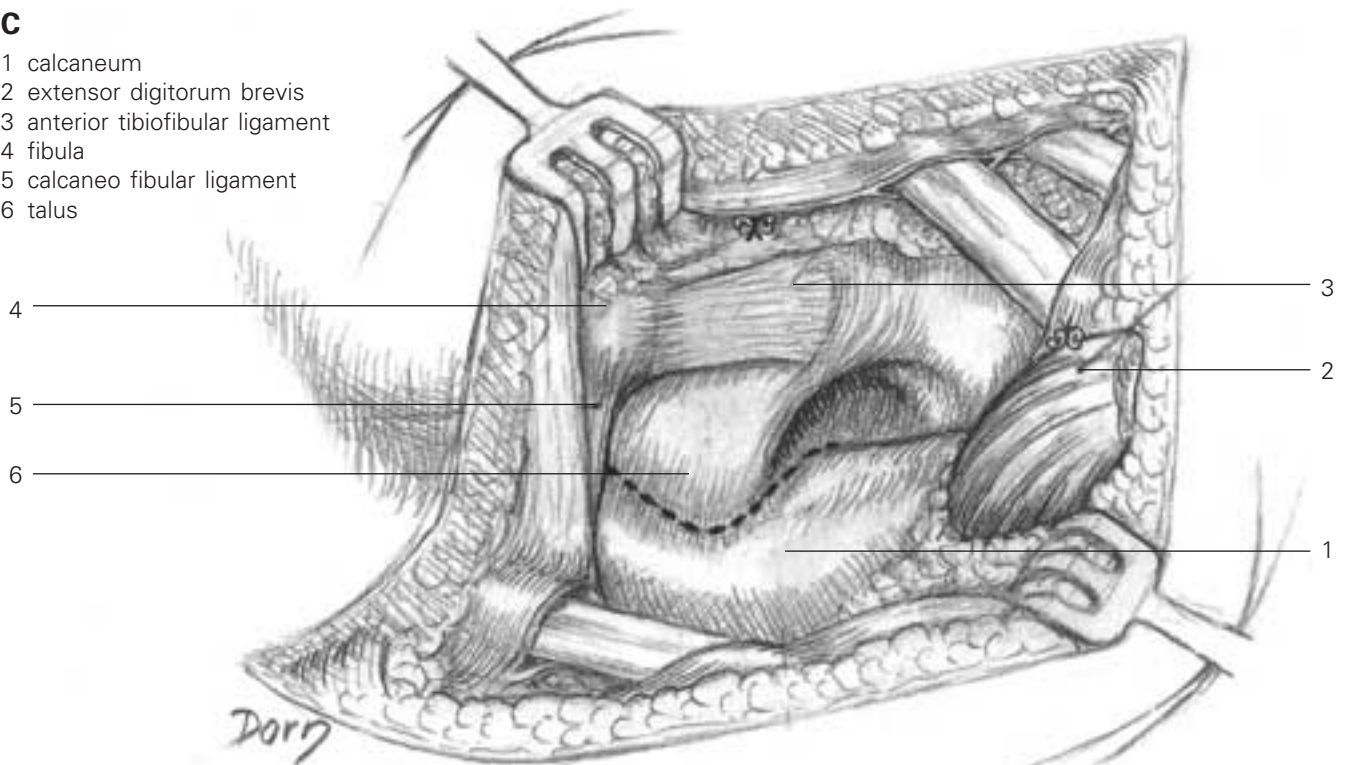
**B**



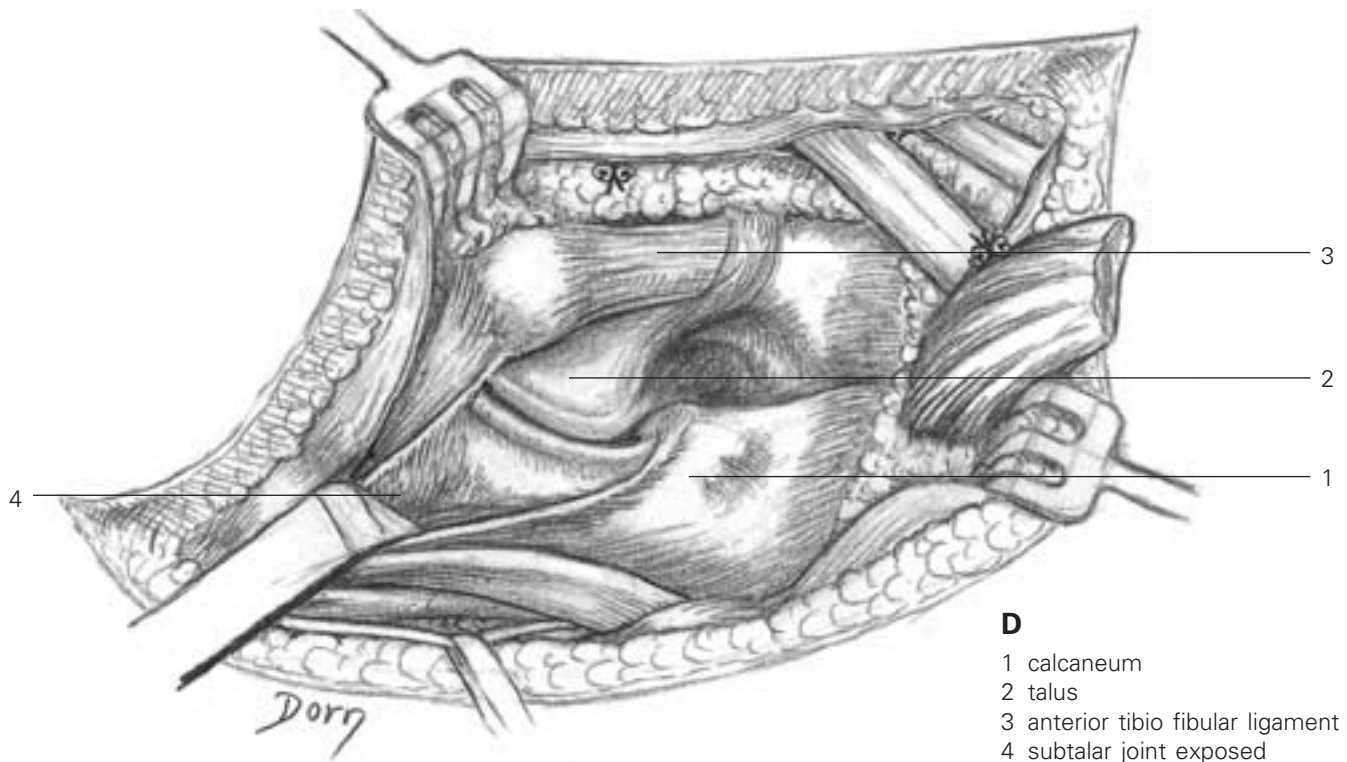
**C** The extensor digitorum brevis muscle is detached to expose the subtalar joint.

**C**

- 1 calcaneum
- 2 extensor digitorum brevis
- 3 anterior tibiofibular ligament
- 4 fibula
- 5 calcaneo fibular ligament
- 6 talus



**D** The subtalar joint and the talonavicular and calcaneocuboid joints are exposed.



**D**

- 1 calcaneum
- 2 talus
- 3 anterior tibio fibular ligament
- 4 subtalar joint exposed



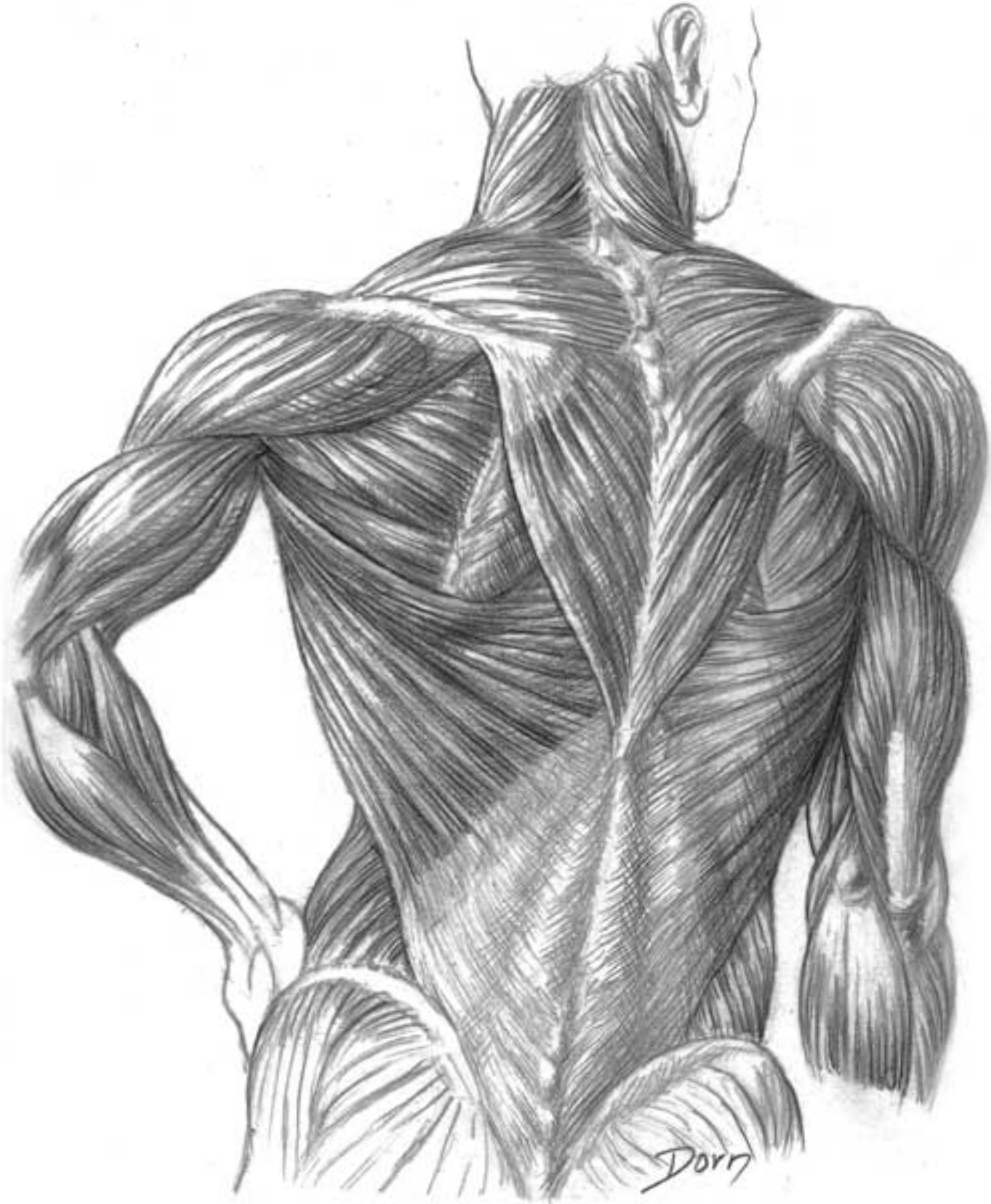


# Miscellaneous

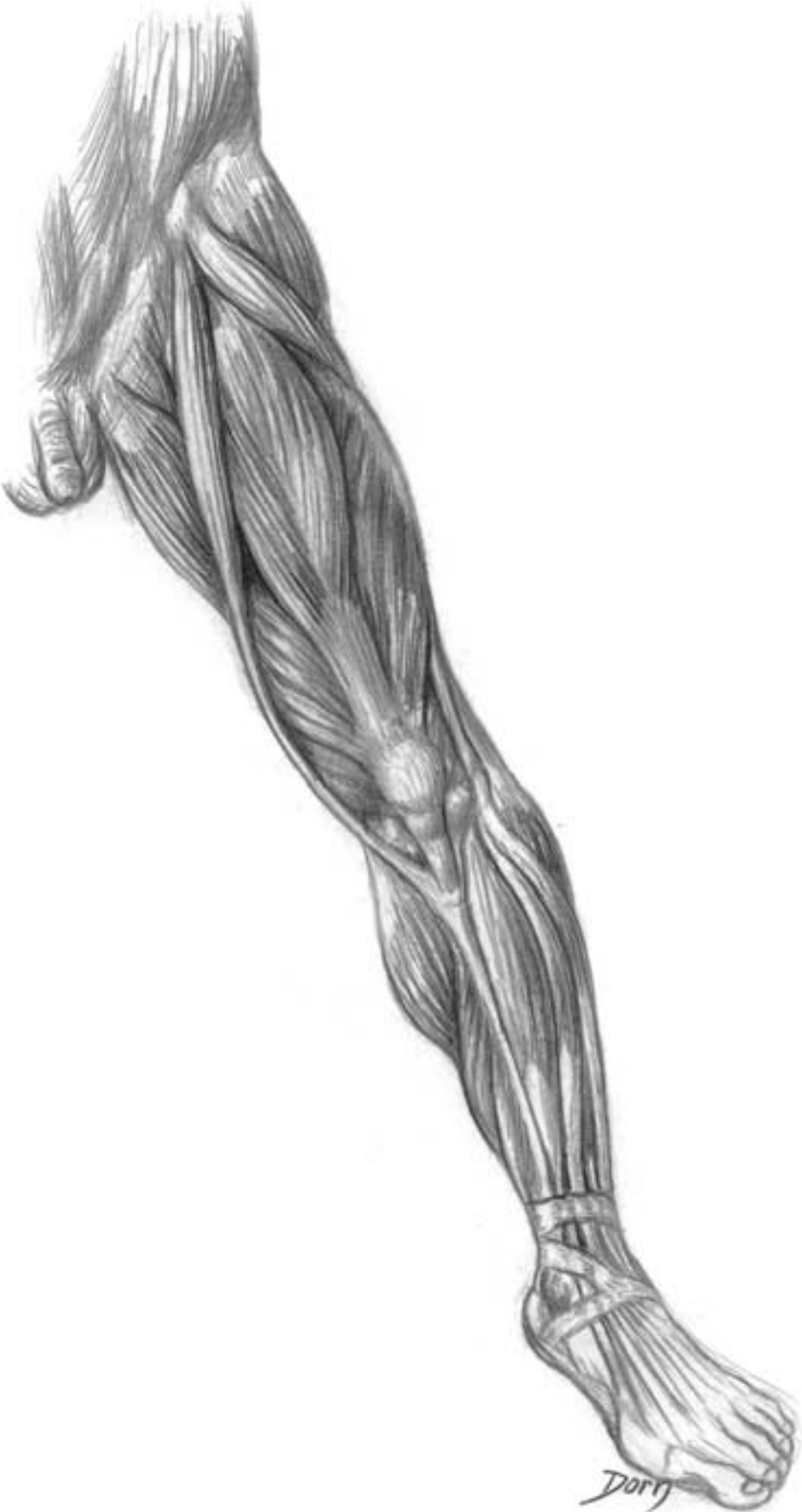## **Muscular studies**

The shape of the human body is very attractive for a medical illustrator.

Studies of the muscular relief were one of the main interests of the artists of the Renaissance. It can be said that one of the motivations for dissection during this period was to understand how the muscles contribute to the shape of the body. The following drawings of Léon Dorn, particularly the first one, recall the 'écorché of Vésale'. The difference is that Vésale's man seems to be very anxious while Dorn's has a relaxed (modern) attitude.





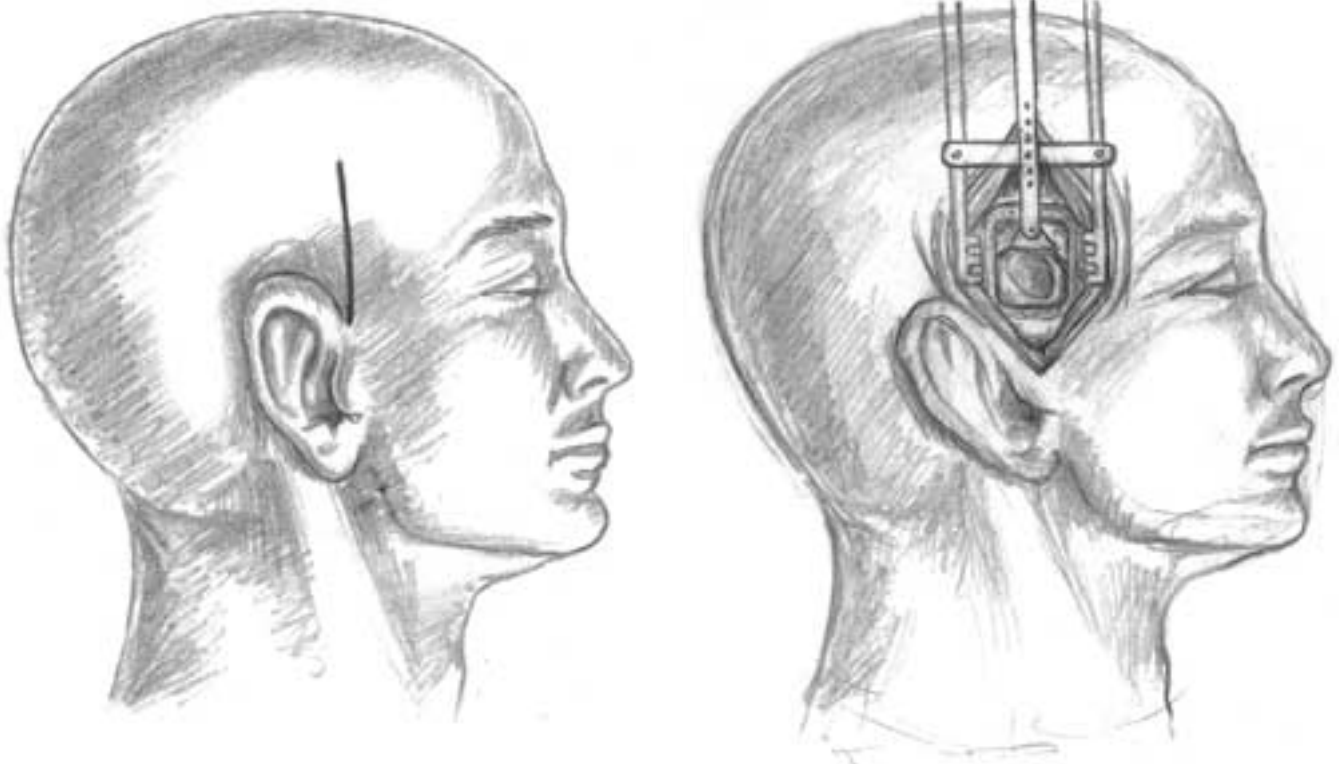


## Surgery of the ear

A series of drawings showing the boundary between neurosurgery and ear surgery

The first three drawings are devoted to the approach through the skull. The dura mater has been opened which allows exposure of the facial and other nerves.

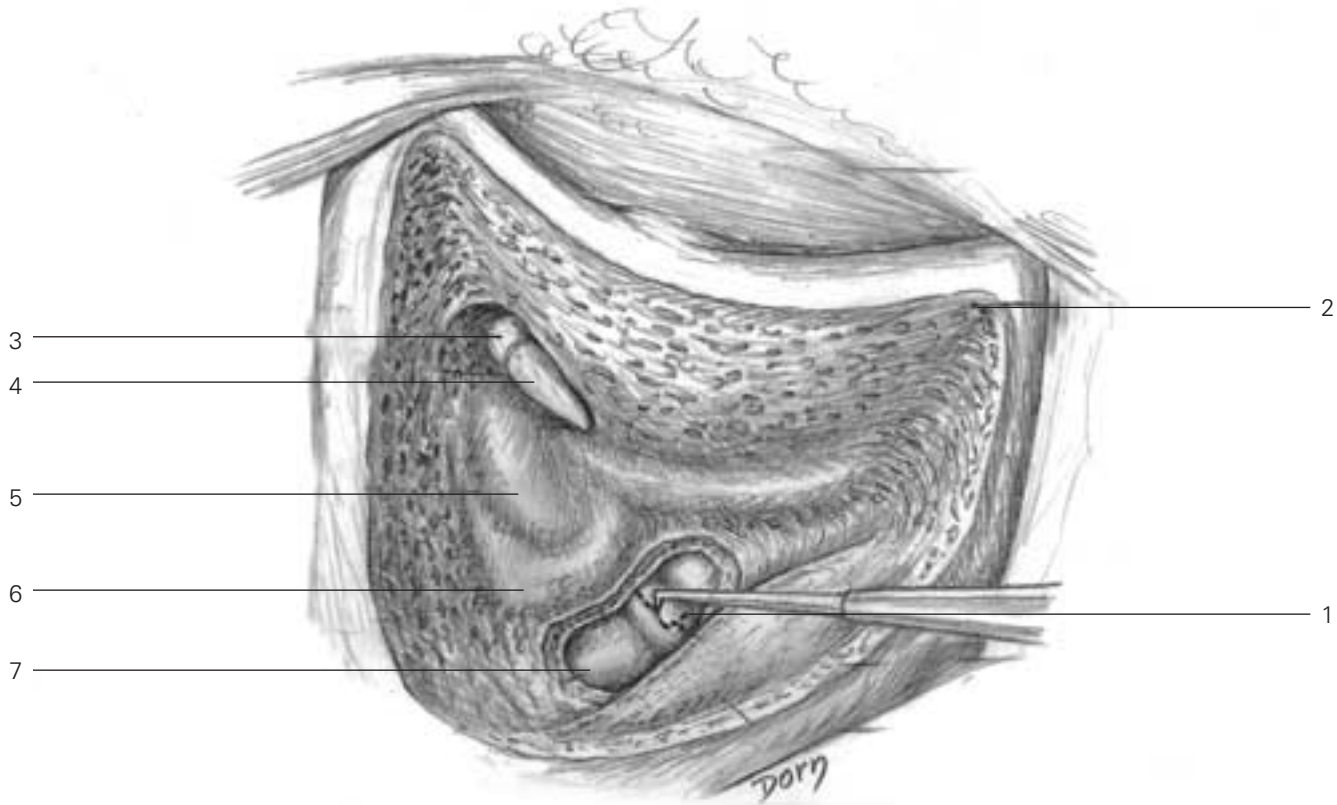
**A** Exposure of a tumour of the vestibular nerve by a retroauricular and transvestibular approach.



# Miscellaneous

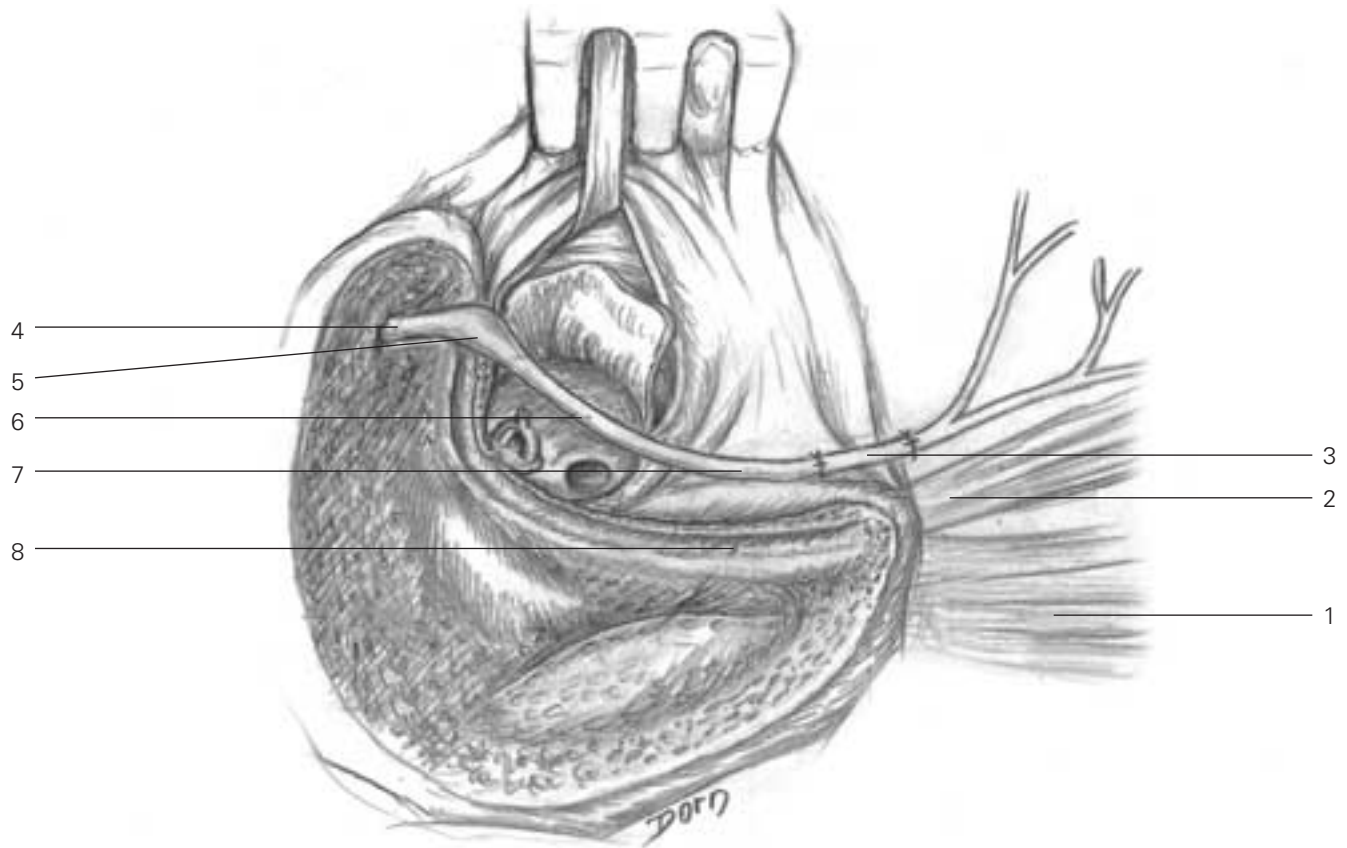
---

## **B** Opening of the endolymphatic sac in a case of Ménière's disease.



- B**
- 1 opening of the endolymphatic sac
  - 2 mastoid cortex
  - 3 malleus (head of malleus)
  - 4 incus (short process)
  - 5 lateral semicircular canal
  - 6 posterior semicircular canal
  - 7 stripped cerebellum dura mater

**C** Transmastoid approach to expose the second and third parts of the facial nerve, which is taken out of the Fallopian aqueduct.



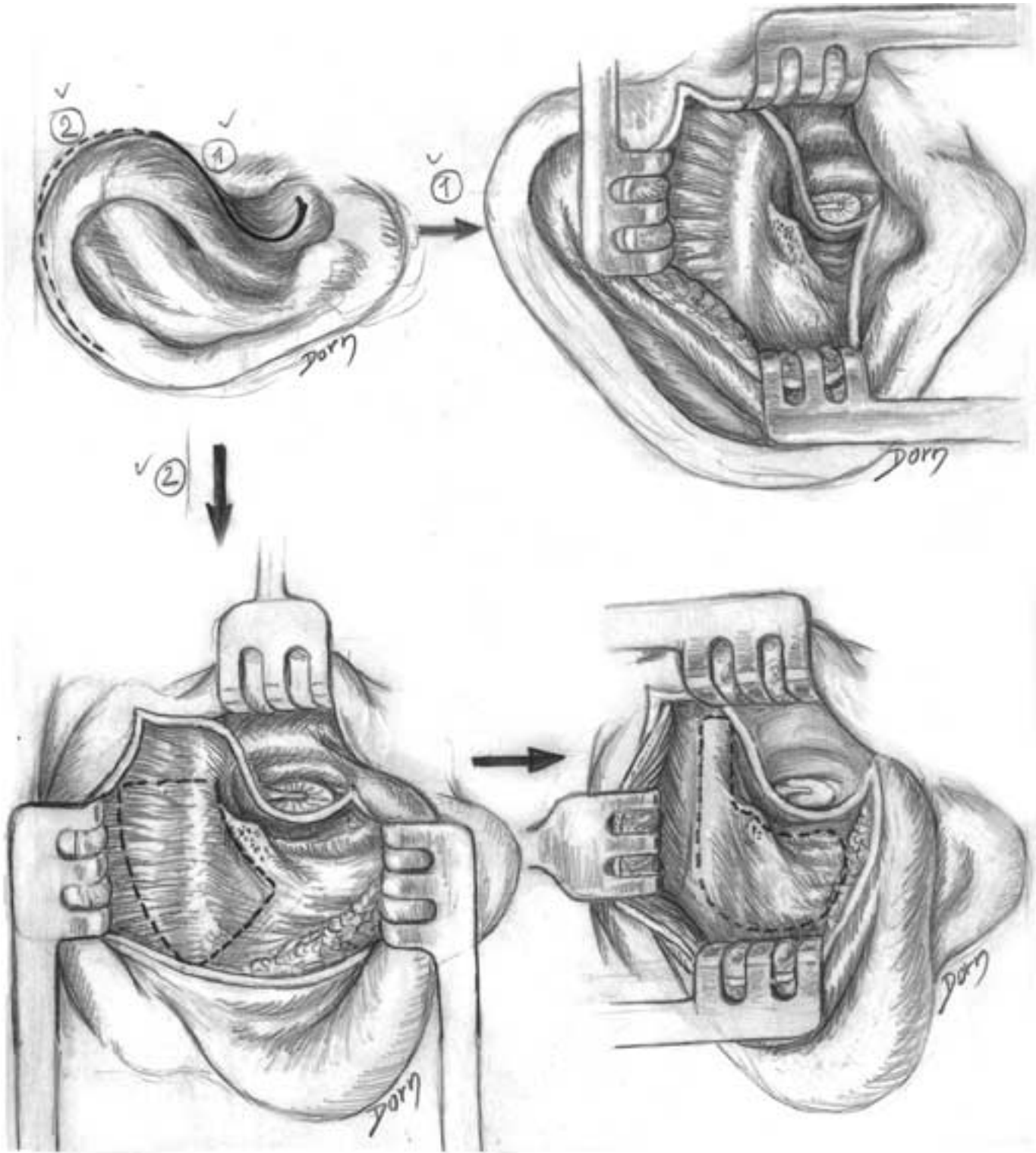
- C**
- 1 sternocleidomastoid muscle
  - 2 digastric muscle
  - 3 facial nerve grafting
  - 4 labyrinthine segment of the facial nerve
  - 5 geniculate ganglion of the facial nerve
  - 6 tympanic segment of the facial nerve
  - 7 mastoid segment of the facial nerve
  - 8 empty Fallopian aqueduct



# Miscellaneous

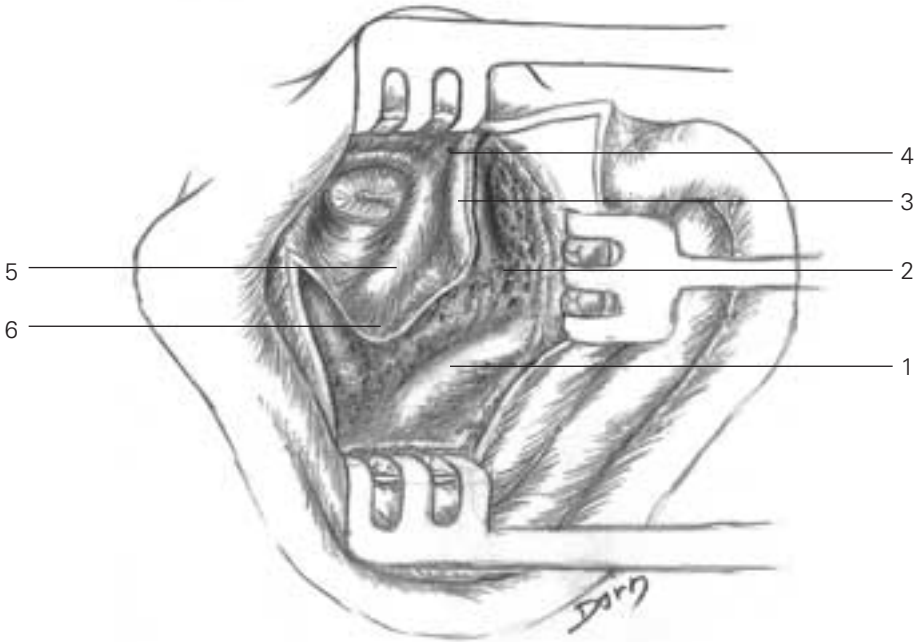
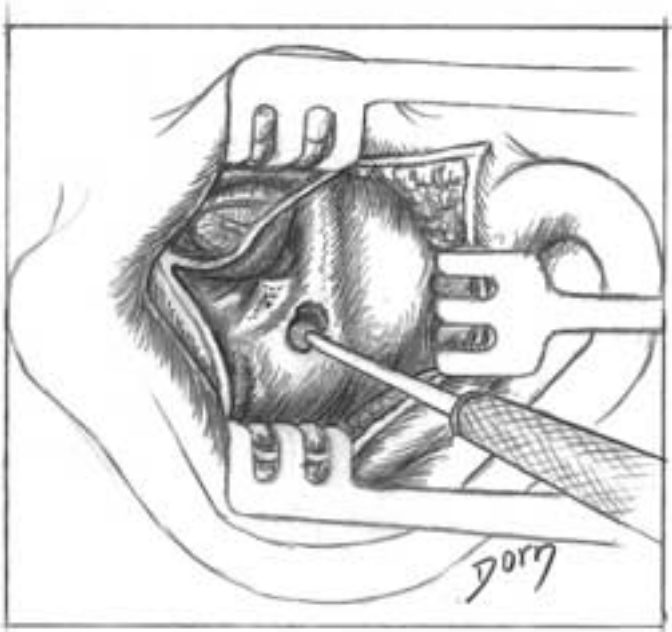
## Surgery of the middle ear

A The transmeatal and extended transmeatal approaches to the middle ear, which allows harvesting a temporal fascia graft.



**B** The Shambaugh approach allows grooving of the cavities of the middle ear.

- B**
- 1 relief of sigmoid sinus
  - 2 antium opened
  - 3 lateral semicircular canal
  - 4 anterior epitypanum
  - 5 facial nerve
  - 6 canal wall skin

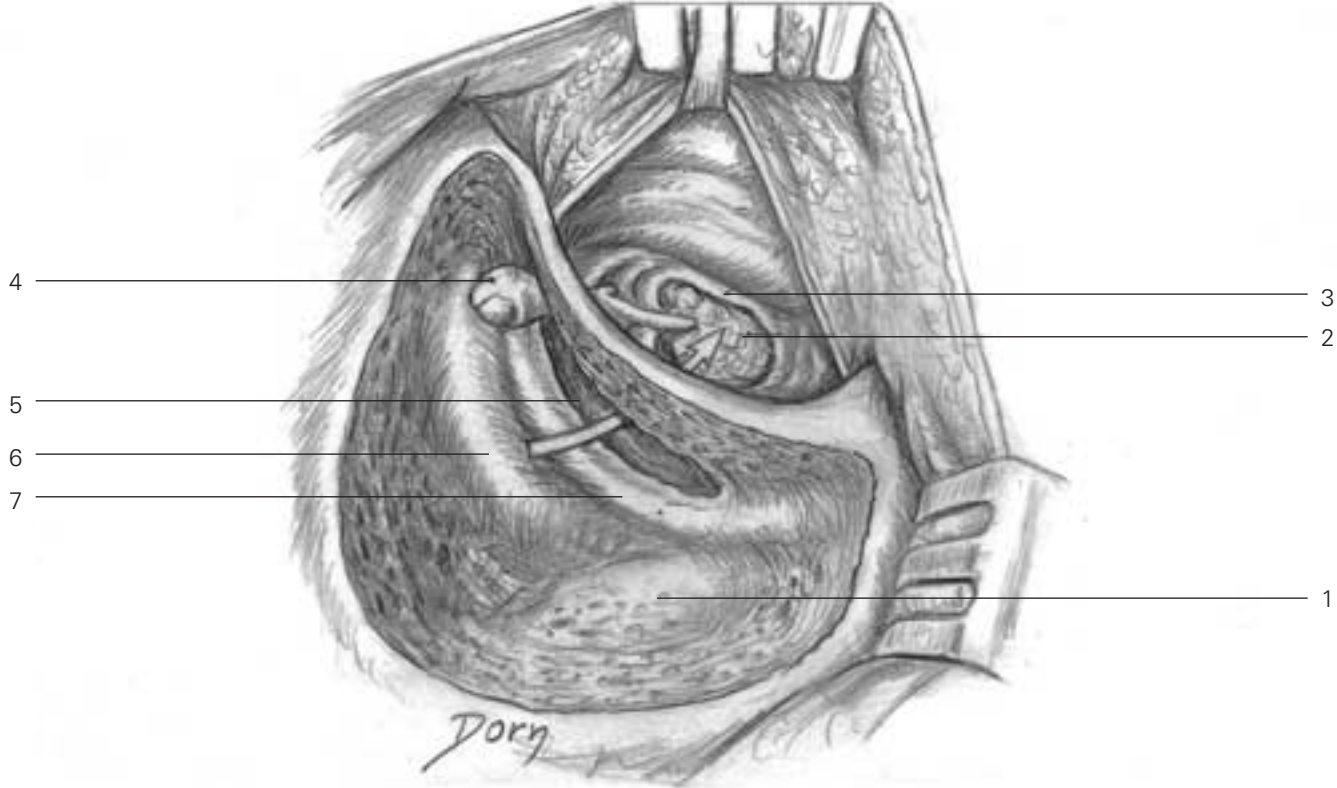


# Miscellaneous

---

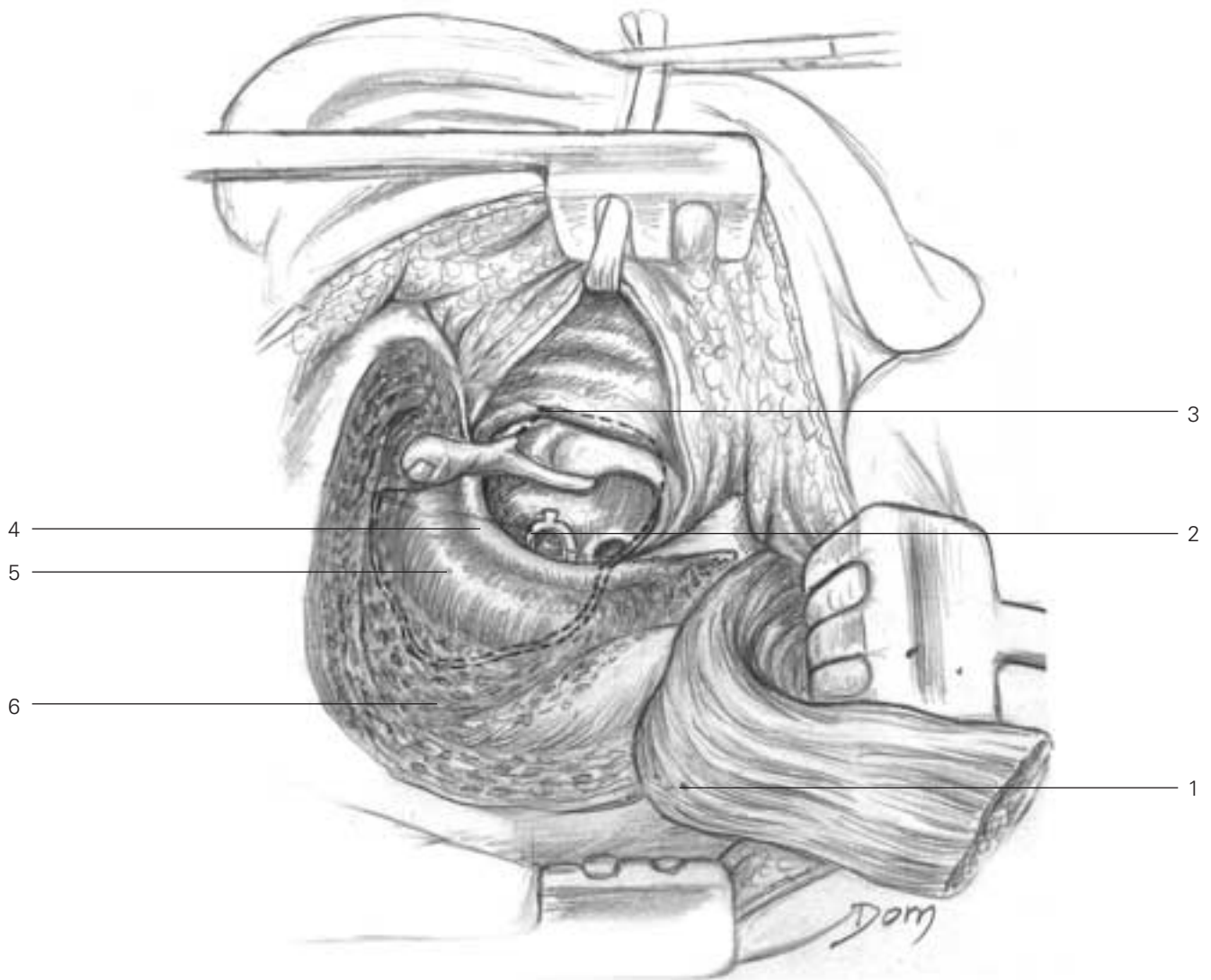
## Tympanic graft

### A Mastoidectomy (canal wall up procedure).



- A**
- 1 sigmoid sinus
  - 2 cholesteatoma
  - 3 perforated tympanic membrane
  - 4 head of the malleus
  - 5 posterior tympanectomy (facial recess opened)
  - 6 lateral semicircular canal
  - 7 facial nerve

**B** Exploration of the tympanic cavity, sparing the facial nerve. Mastoidectomy (canal wall down procedure) with tympanoplasty.

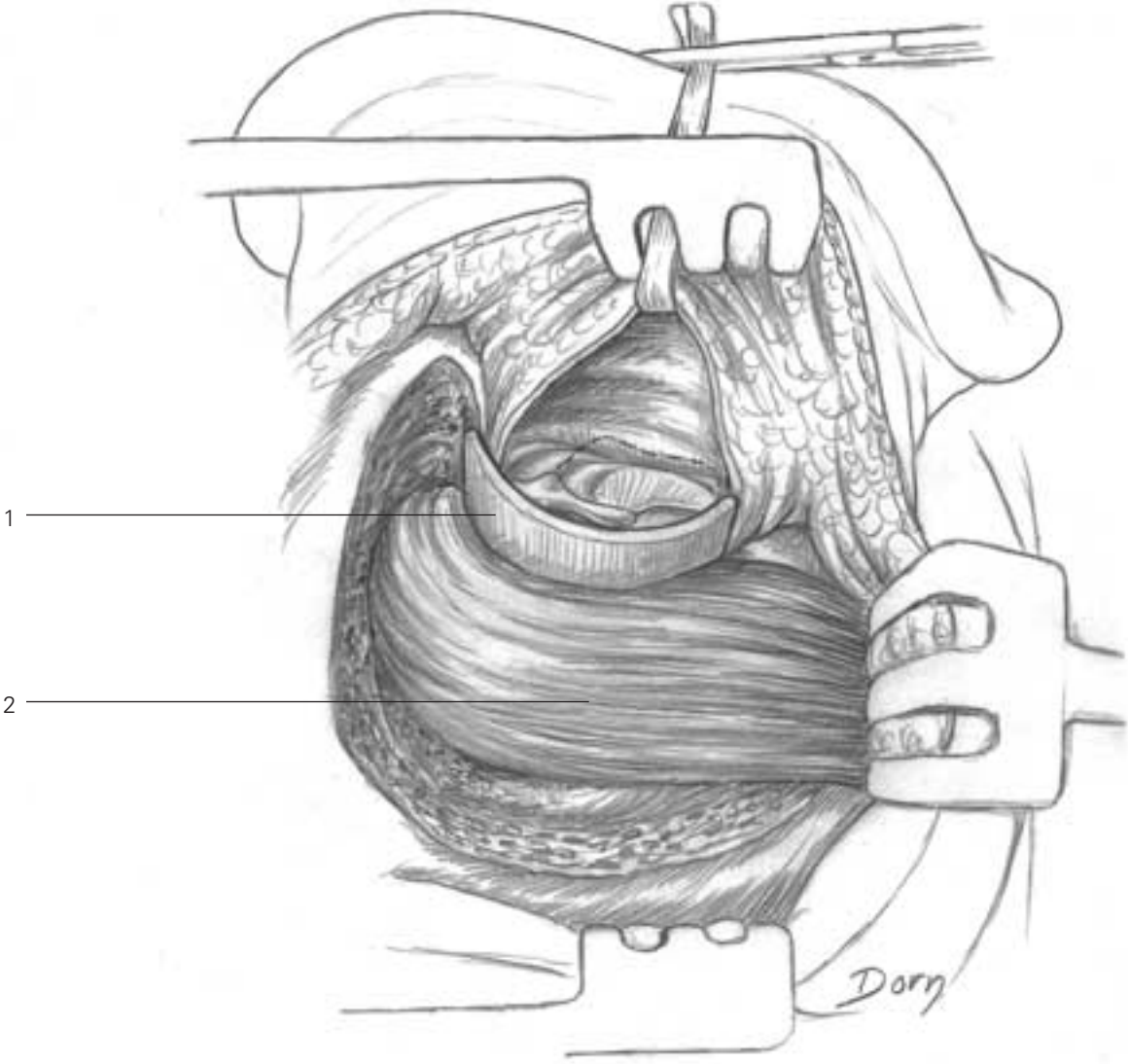


**A**

- 1 fibromuscular flap raised from the mastoidian and temporal muscles
- 2 stapes
- 3 temporal aponeurosis graft under the tympanic rests, on the facial nerve and the lateral semicircular canal
- 4 facial nerve
- 5 lateral semicircular canal
- 6 automastoidian cavity

# Miscellaneous

C A muscular flap from the temporal muscle fills up the mastoid cavity. Reconstruction of the auditory canal.



- C**
- 1 temporal aponeurosis graft prefigures the final outer ear canal
- 2 fascia temporalis graft and muscular flap of the temporalis muscle

## Paediatrics

Crying baby with a Pavlick's harness to prevent hip dislocation or instability

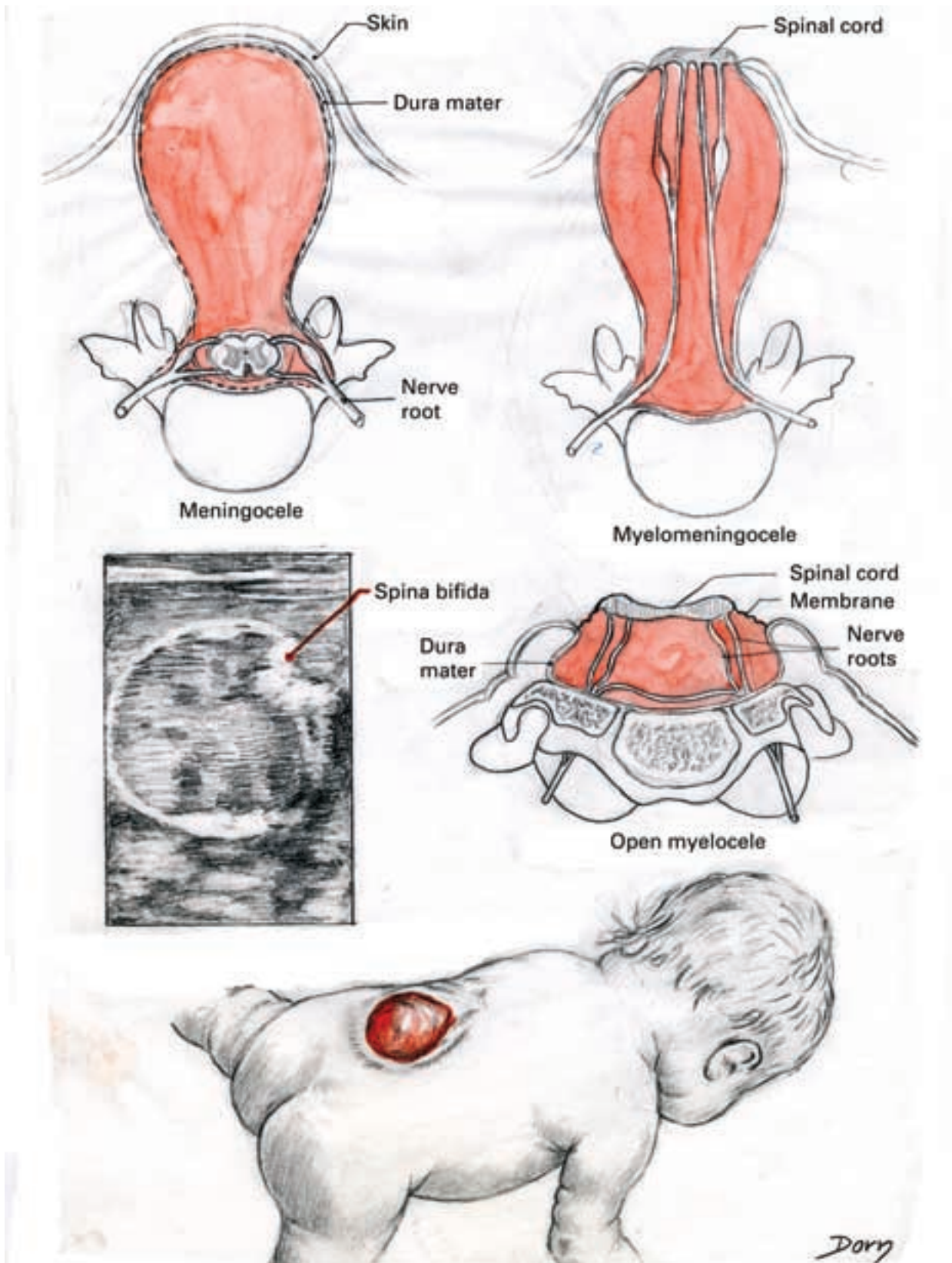


# Miscellaneous

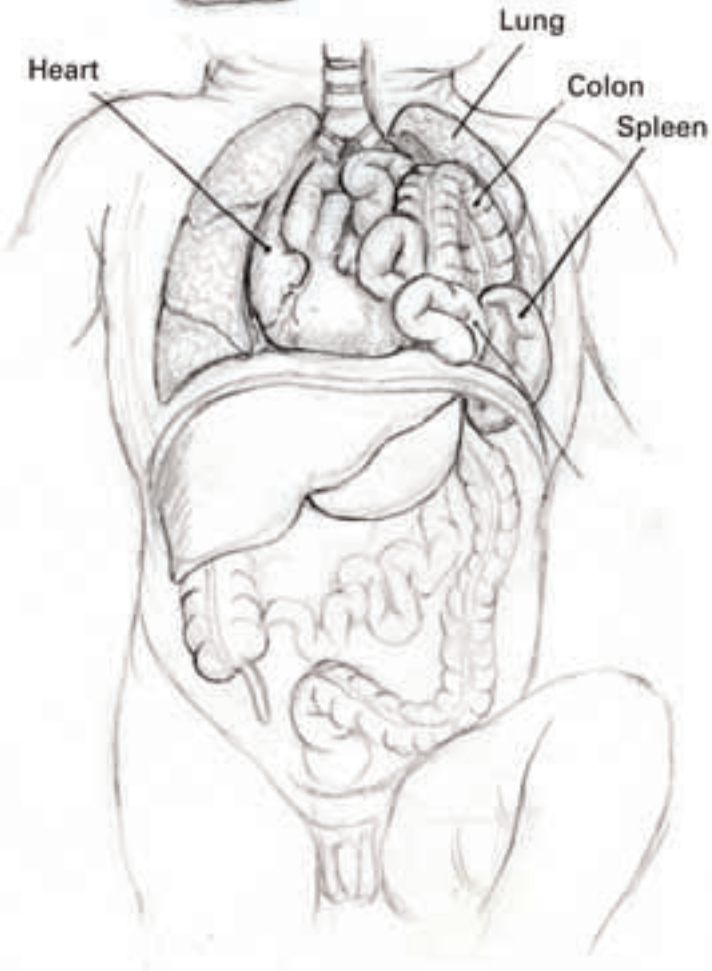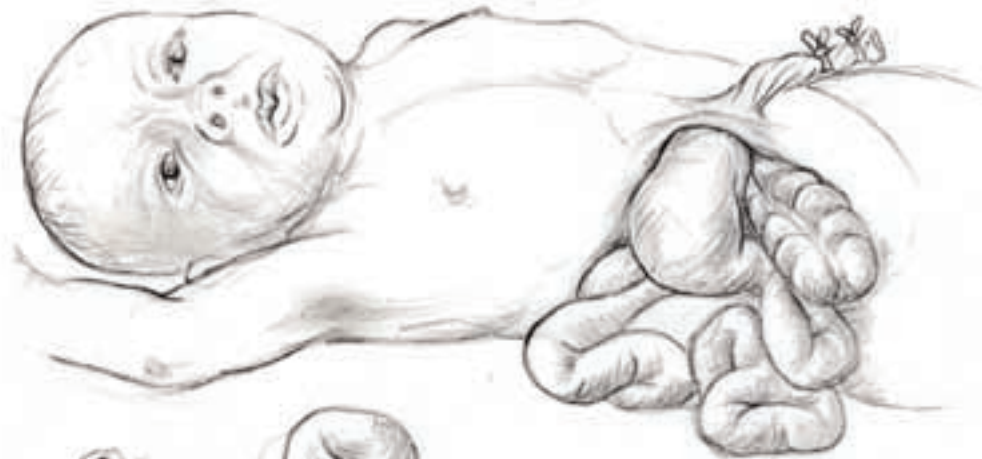## Congenital malformations

Each plate shows the relation of the clinical aspect with the anatomical lesions and the ultrasound imaging aspect

### A Myelomeningocele.



B Laparoschisis.



Diaphragmatic hernia

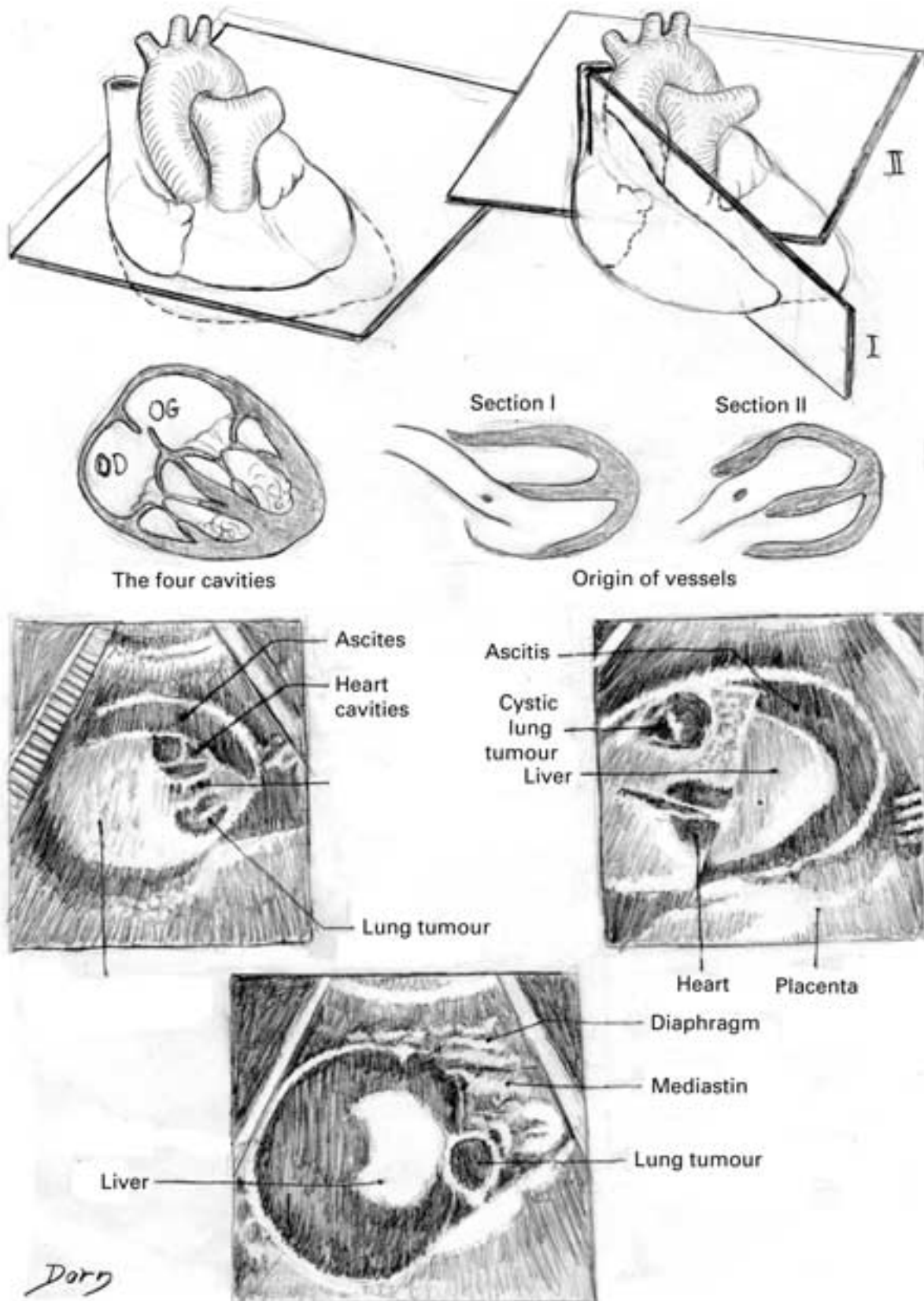


*Dorn*

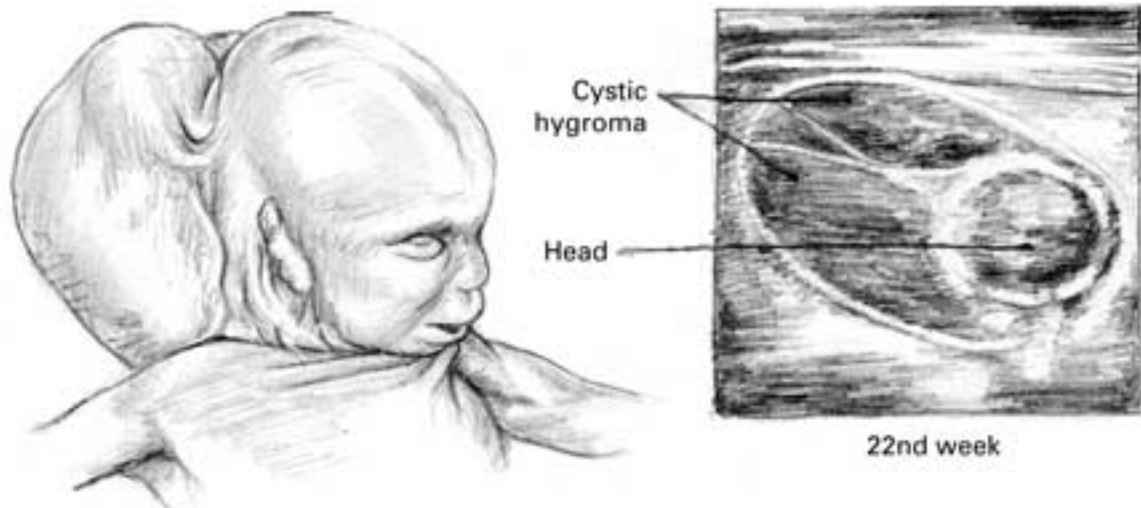


# Miscellaneous

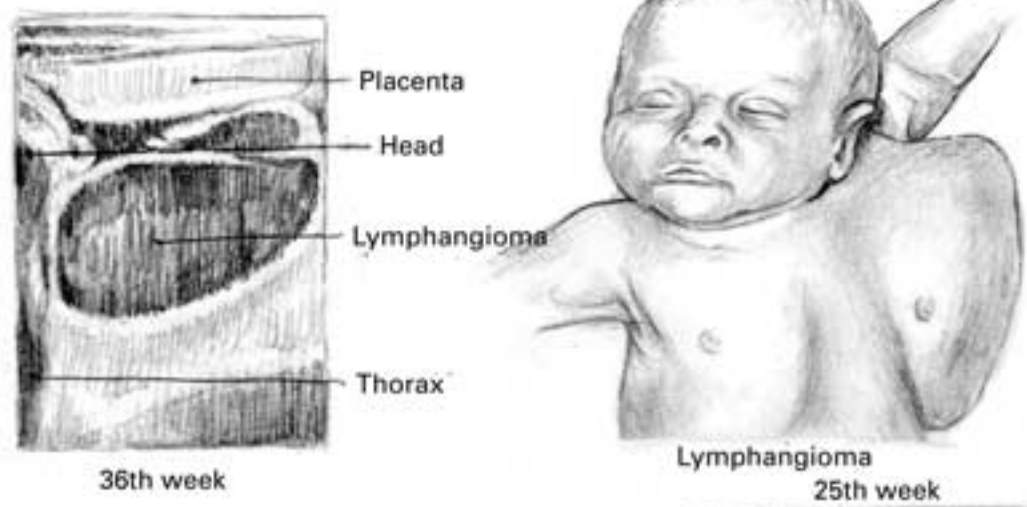
## C Cystic tumour of the lungs.



D Different varieties of tumours: cystic hygroma; lymphangioma; sacrococcygeal teratoma.

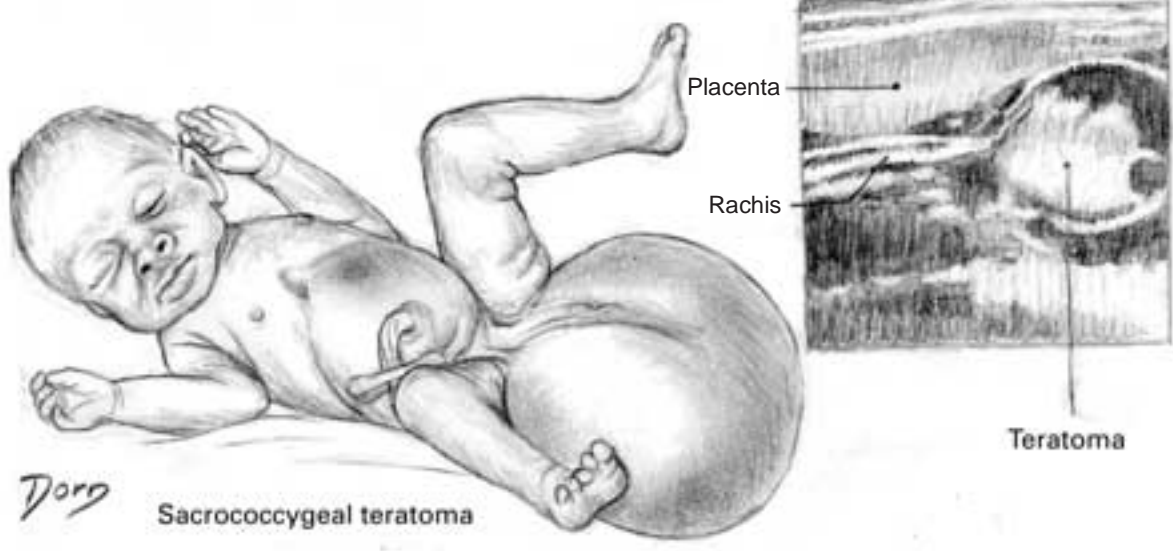


Cystic hygroma



Lymphangioma

25th week

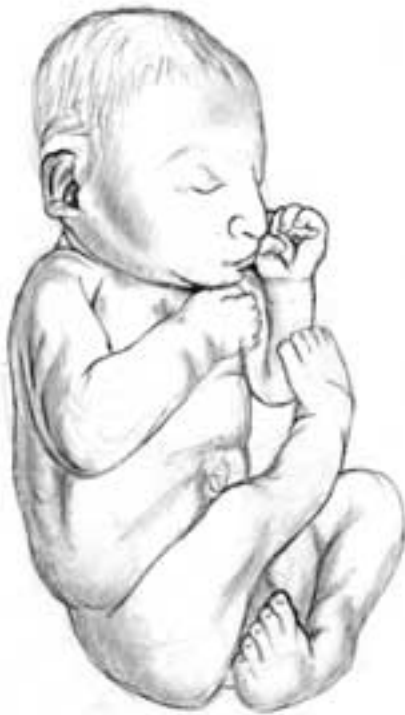

Sacrococcygeal teratoma

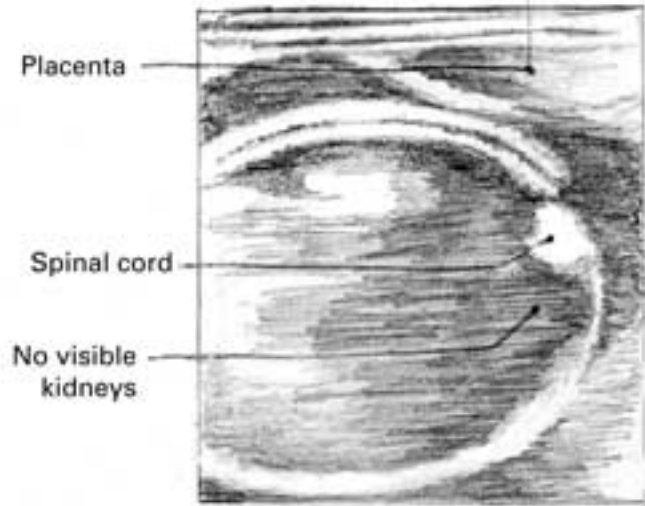
Teratoma

# Miscellaneous

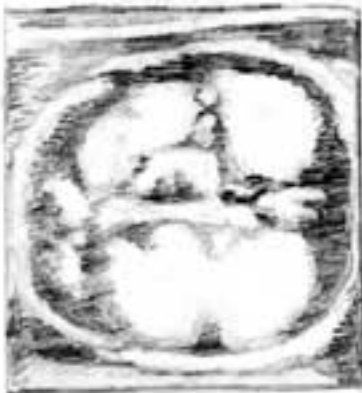E Anomalies of the urinary tract: agenesis of the kidneys; cystic tumour of the kidneys.



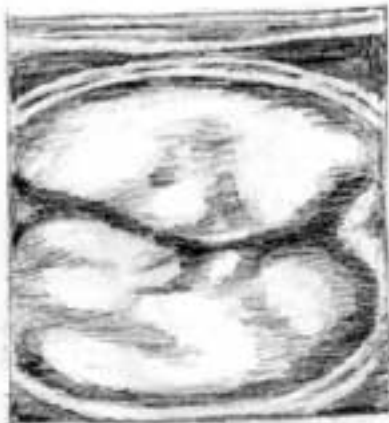Agenesis of the kidneys



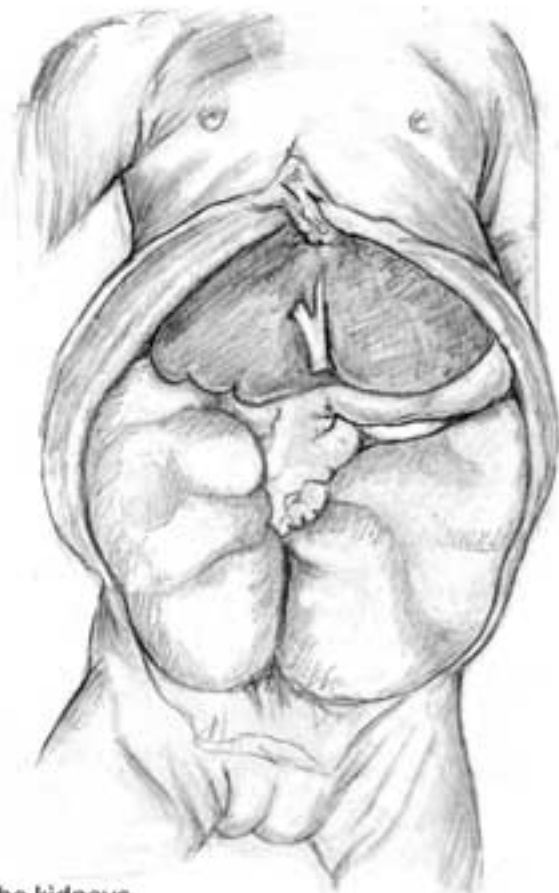Agenesis of the kidneys



32nd week



Increasing volume  
35th week



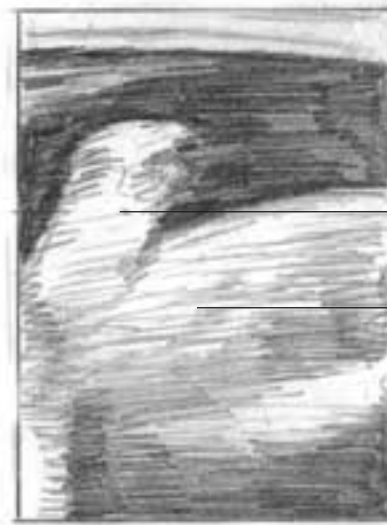Cystic tumour of the kidneys

*Dorn*

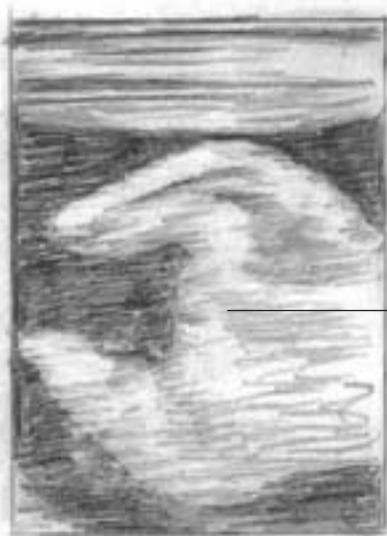F Achondrogenesis.



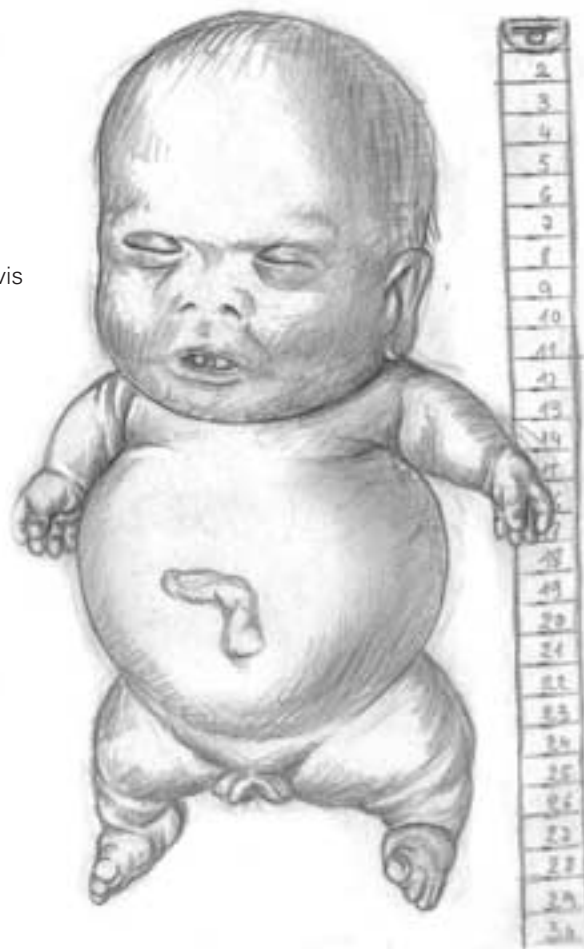35 weeks



35 weeks



35 weeks

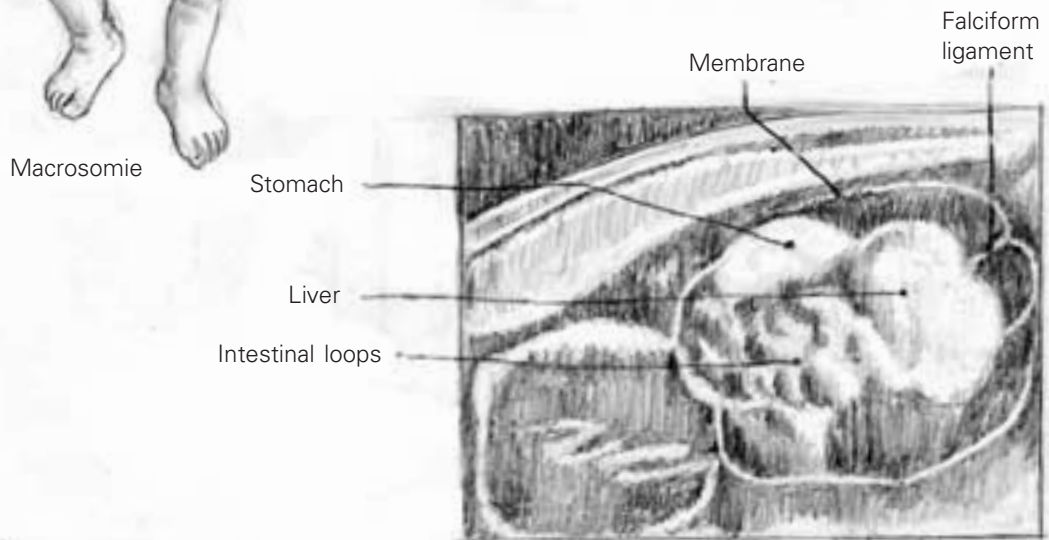
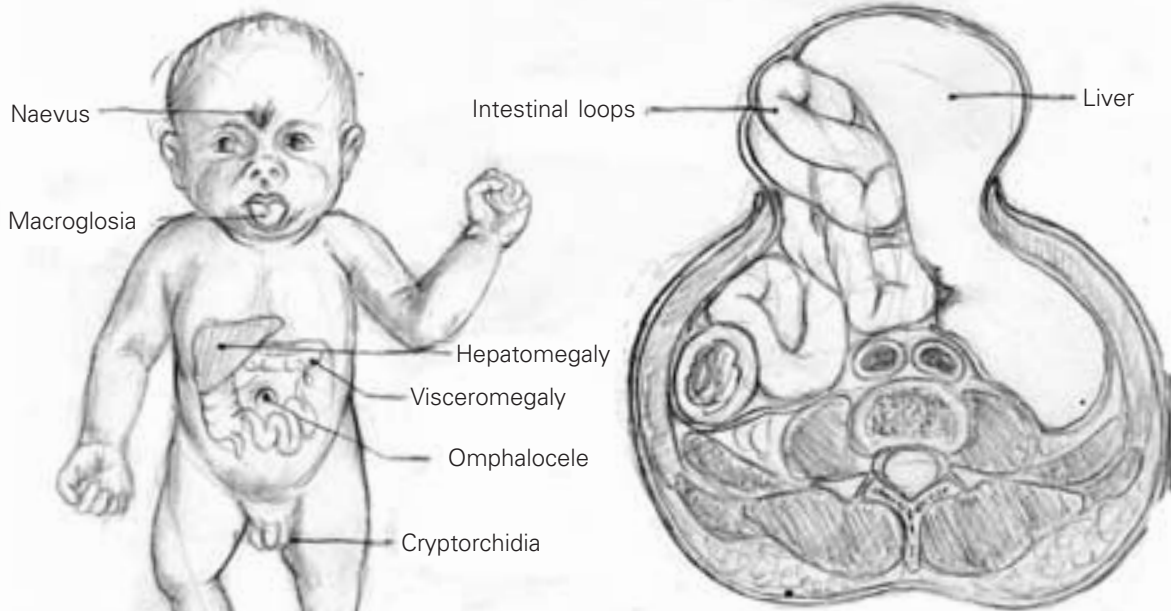
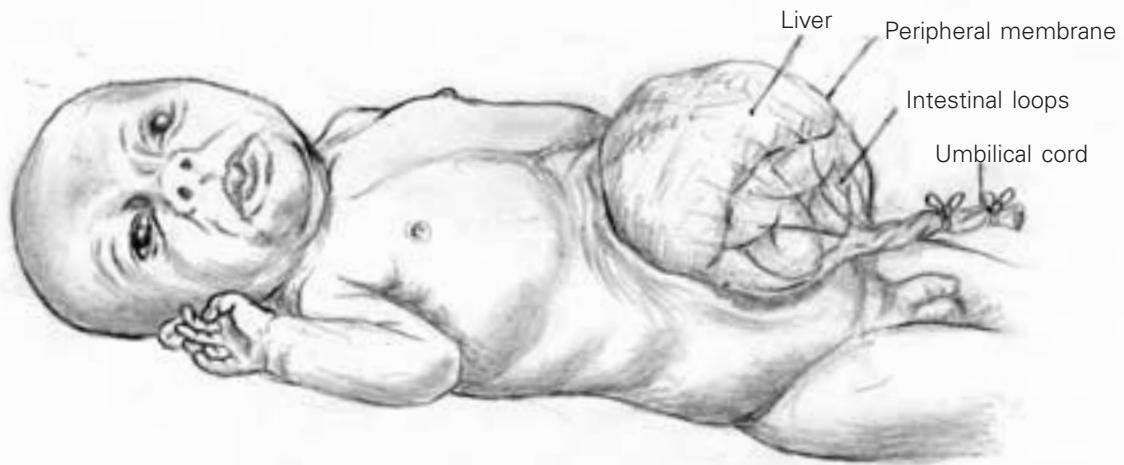


Achondrogenesis

*Dorn*

# Miscellaneous

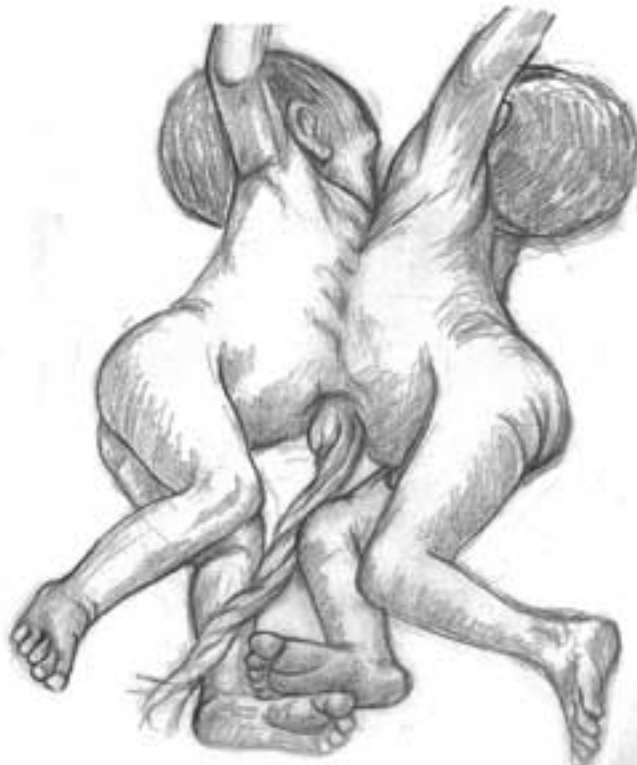## G Omphalocele.



Transverse section: omphalocele 37 weeks

*Dorn*

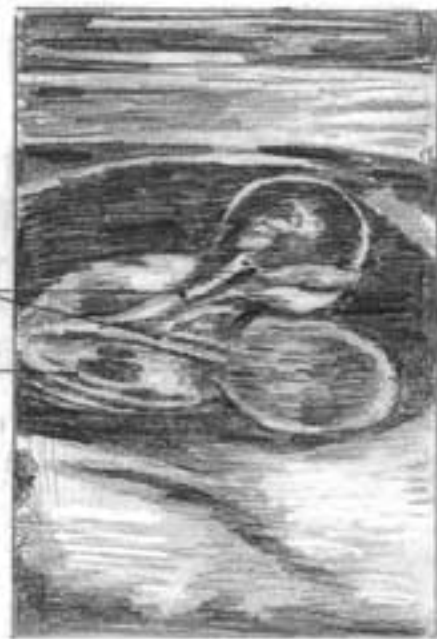**H** Monstrous anomalies.



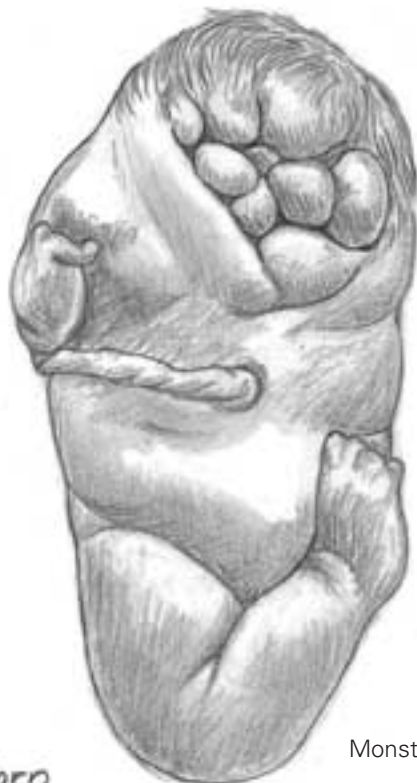Omphalothoracopage

two vertebral columns

one trunk



Two-headed foetus 14 weeks

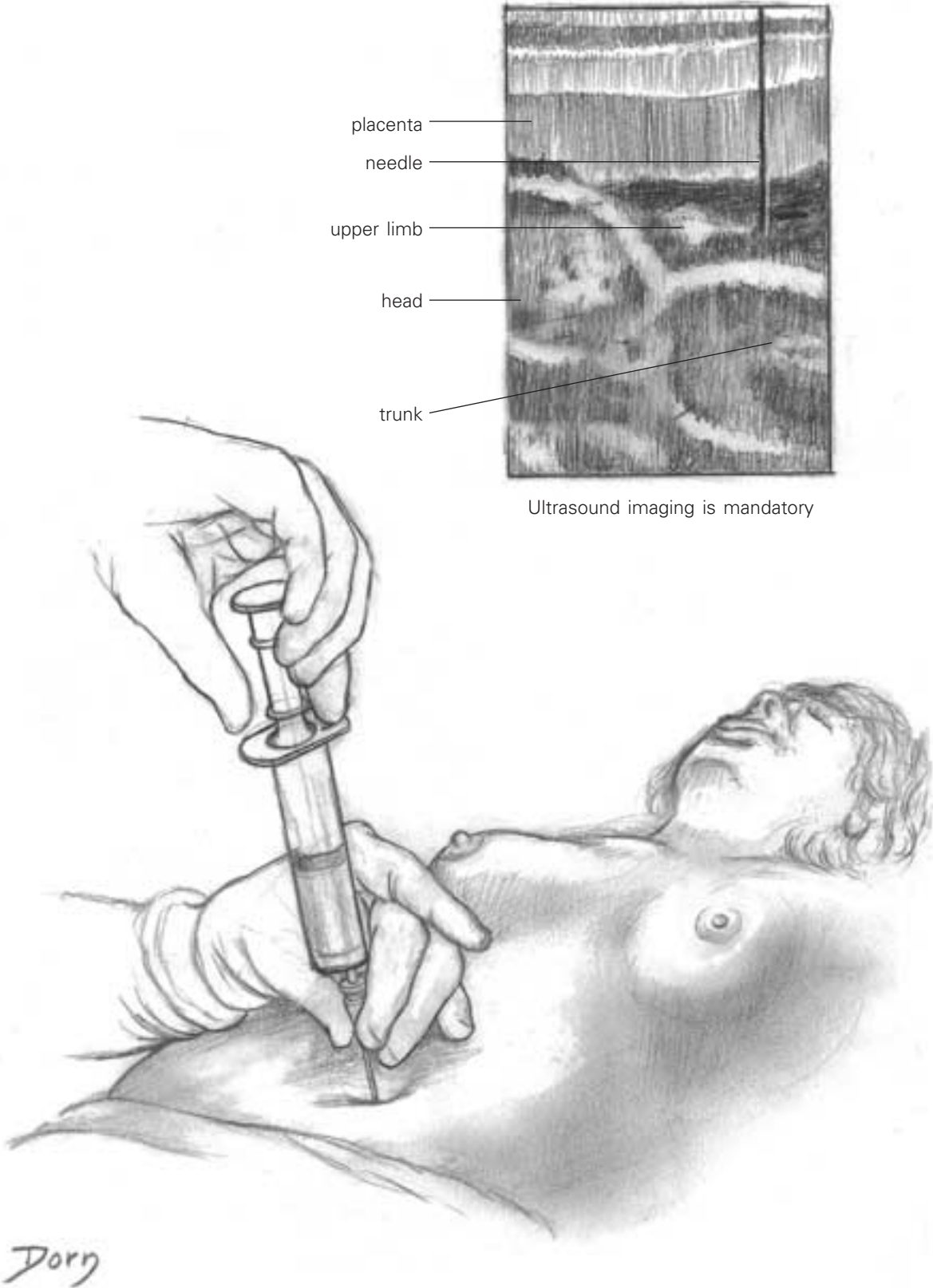


Monster

*Dorr*

# Miscellaneous

Detection of fetal anomalies.  
Amniocentesis under ultrasound  
imaging

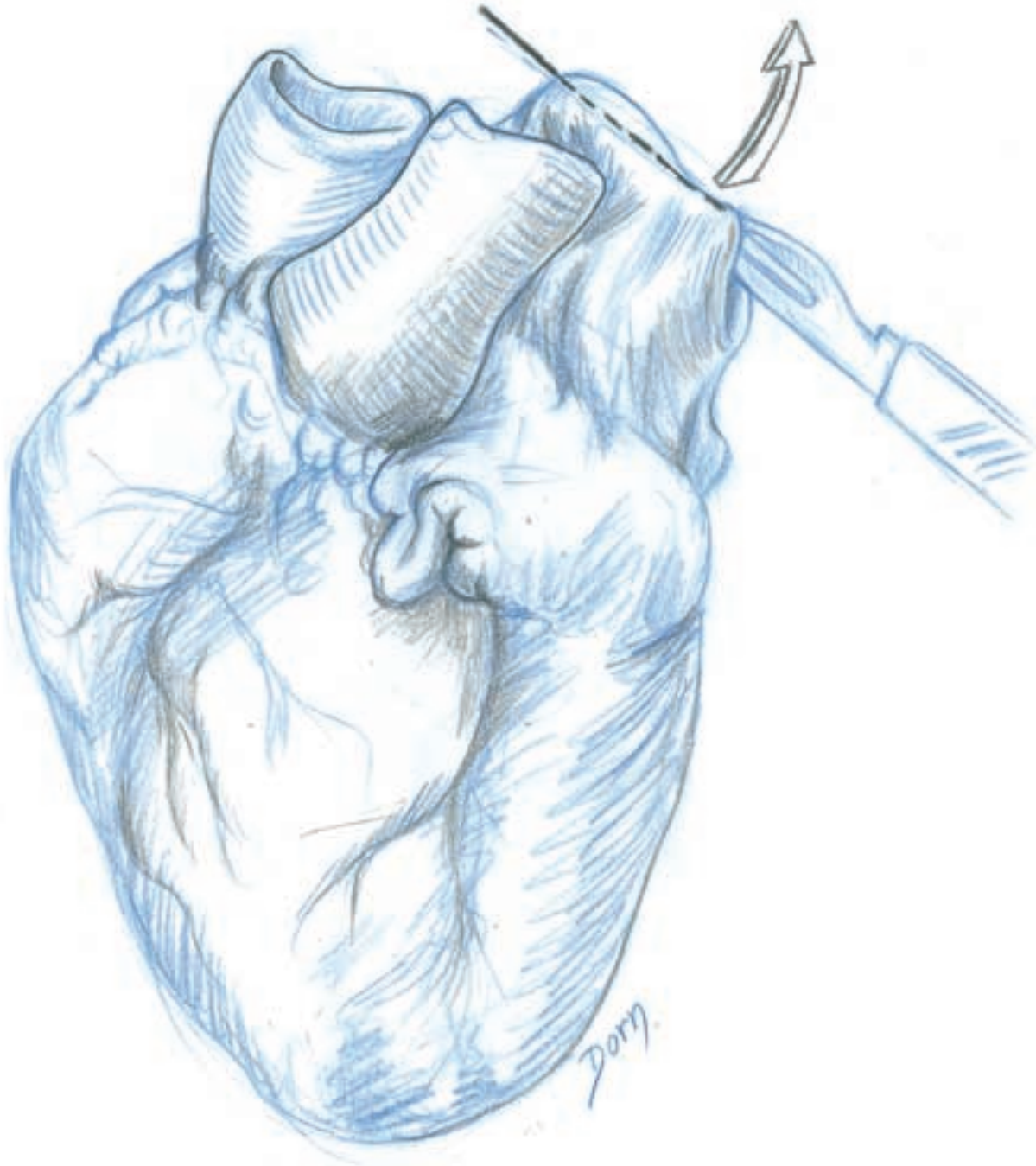


## Heart anatomy

Heart anatomy cannot be understood without exposing the cavities.

## Dissection of the left heart

A Section of the left auricle between the two pulmonary veins.

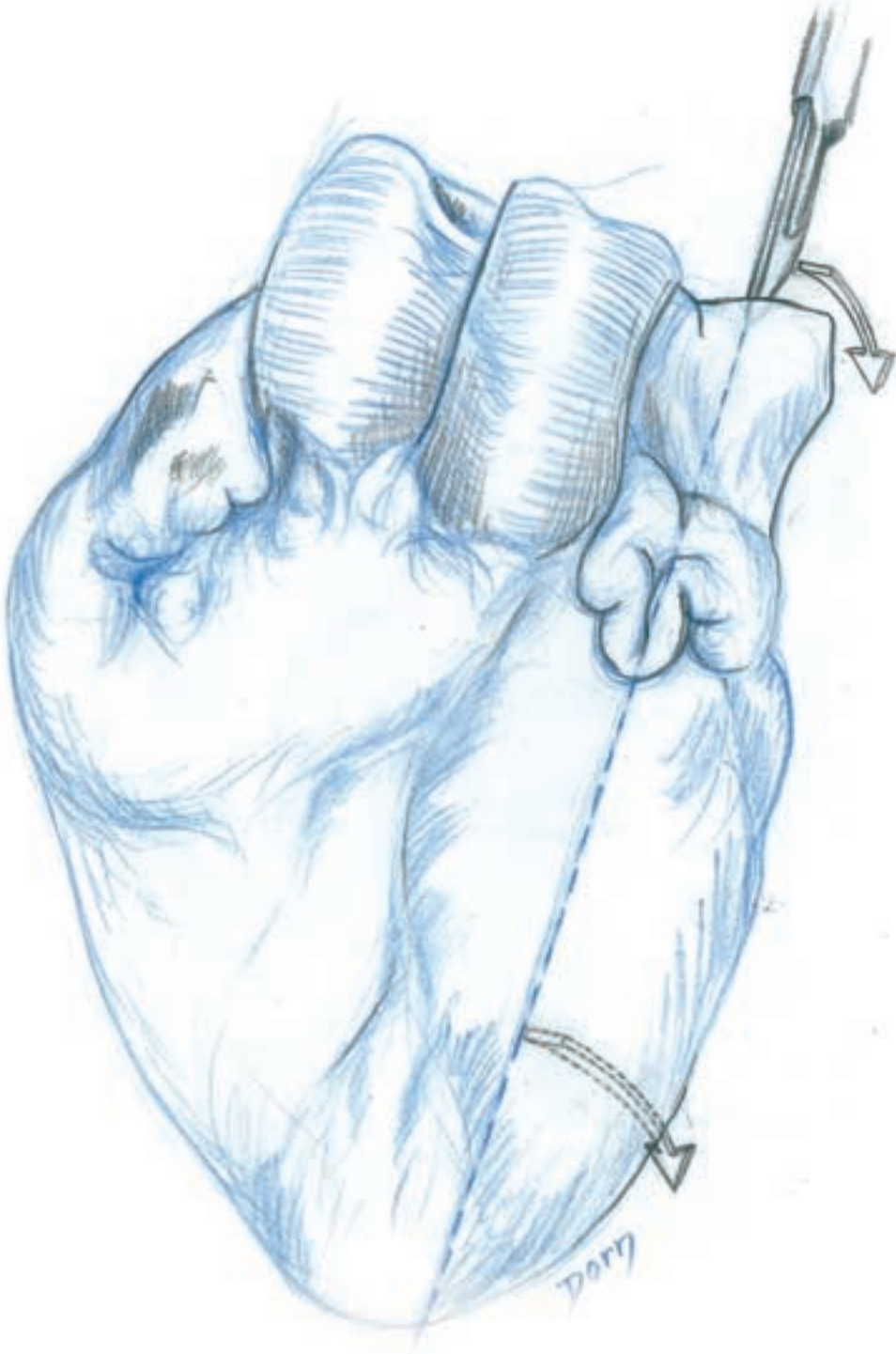




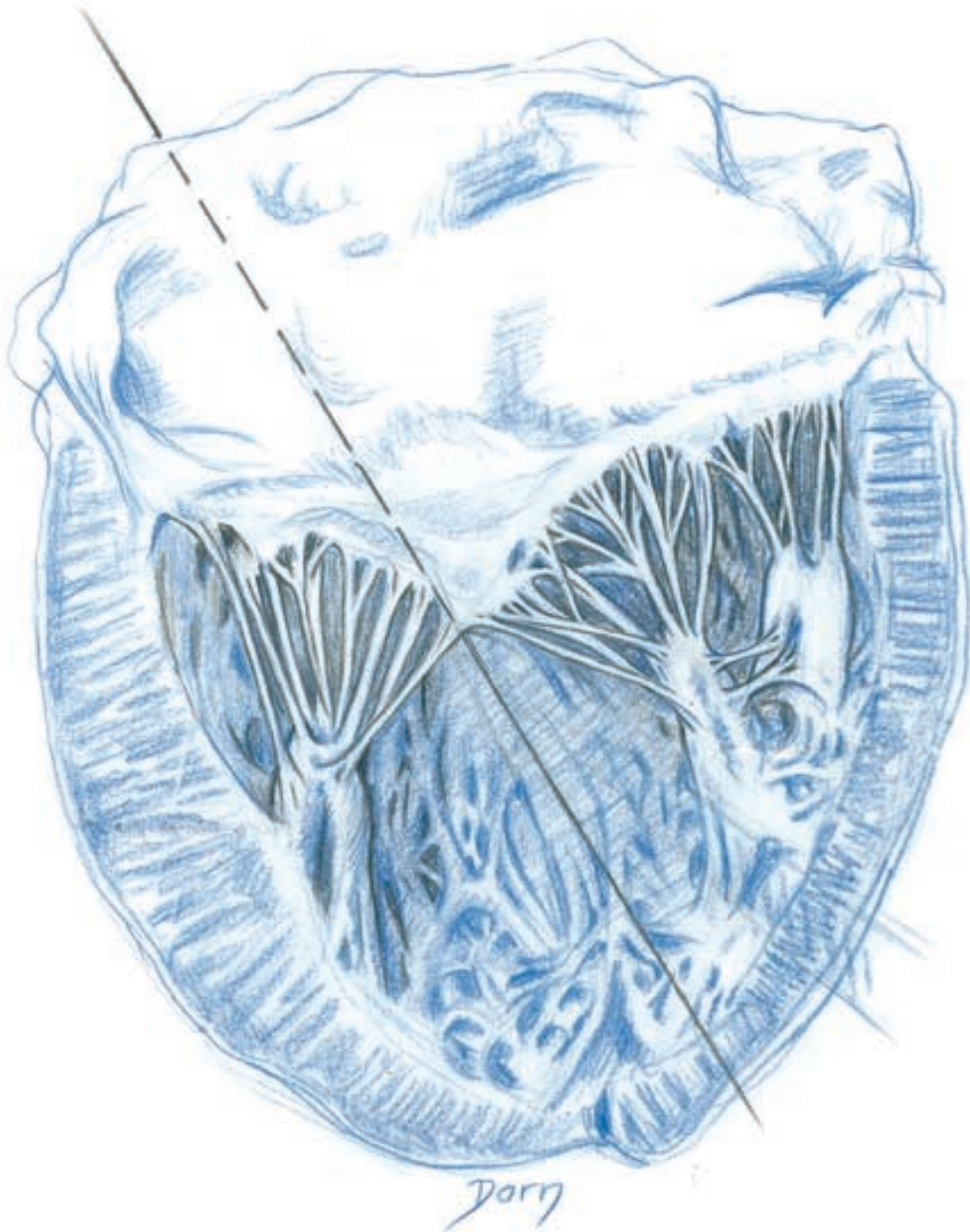
# Miscellaneous

---

**B** The knife is introduced in the left auricle.



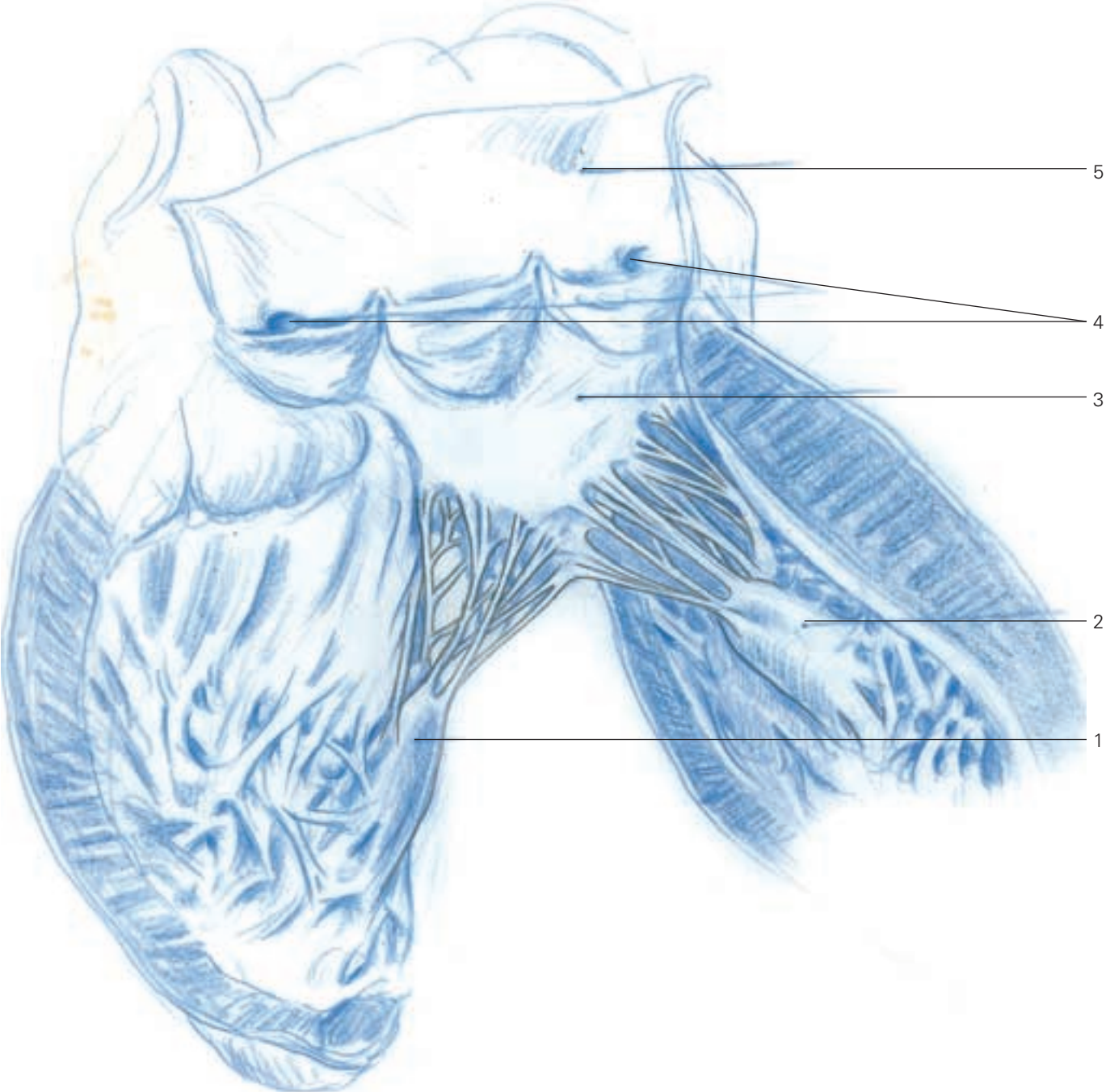
C Left ventricle. The mitral valve and the anterior and posterior papillary muscles are visible.



# Miscellaneous

---

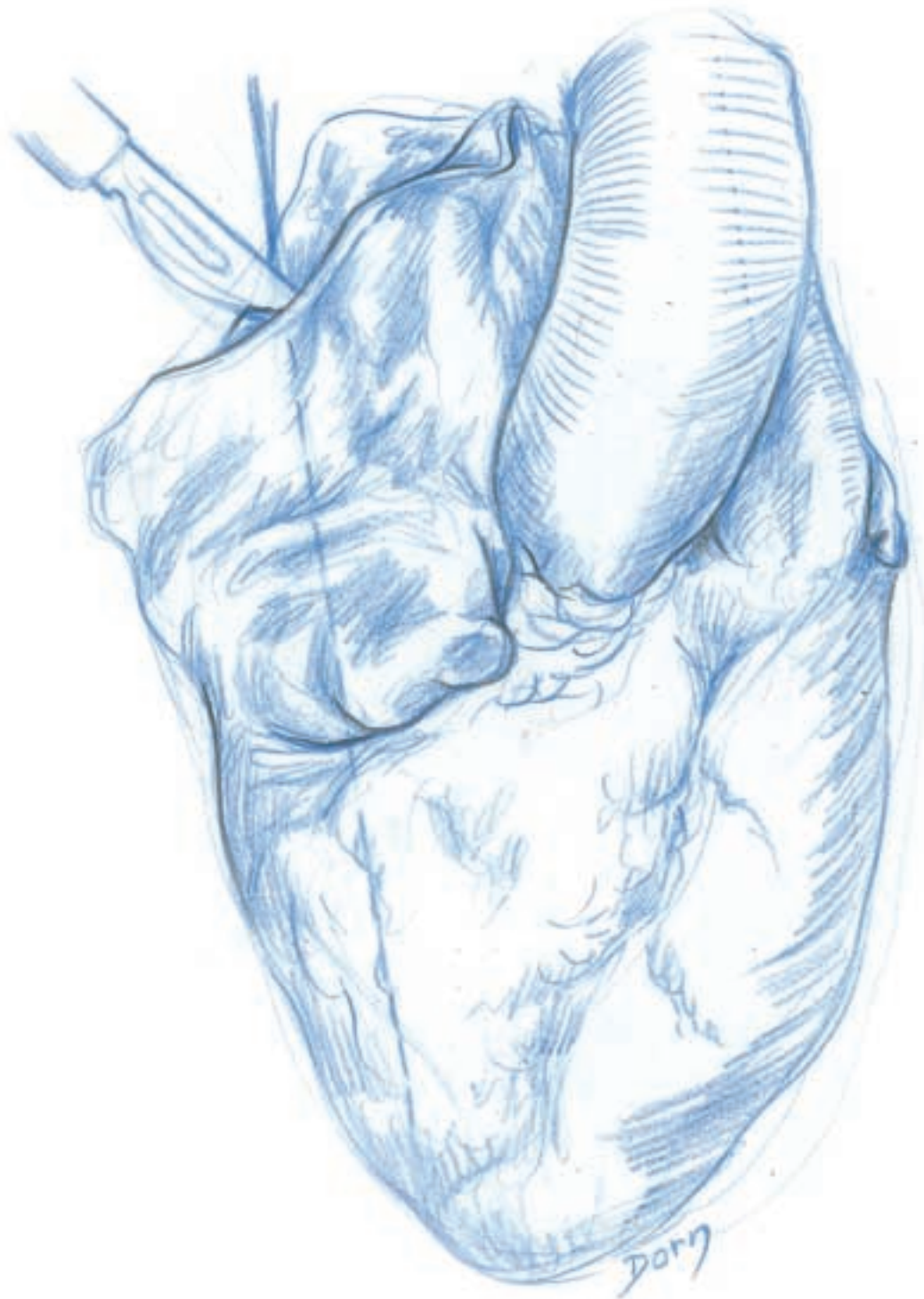
**D** The left ventricle is separated into two parts.



- D**
- 1 posterior papillary muscle
  - 2 anterior papillary muscle
  - 3 mitral valve
  - 4 opening of coronary arteries
  - 5 ascending aorta

## Dissection of the right heart

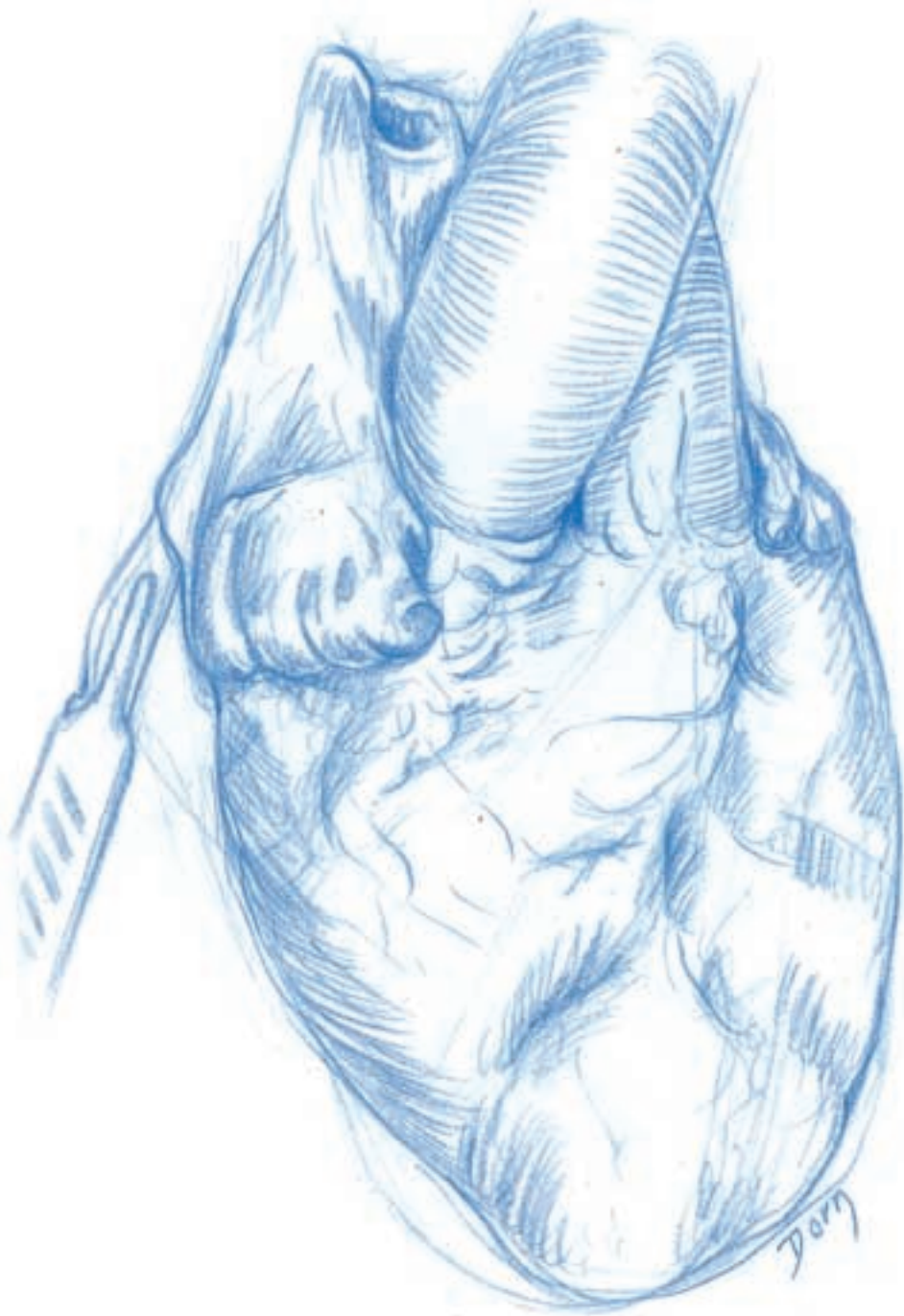
**A** Sectioning and opening of the right auricle between the two venae cavae.



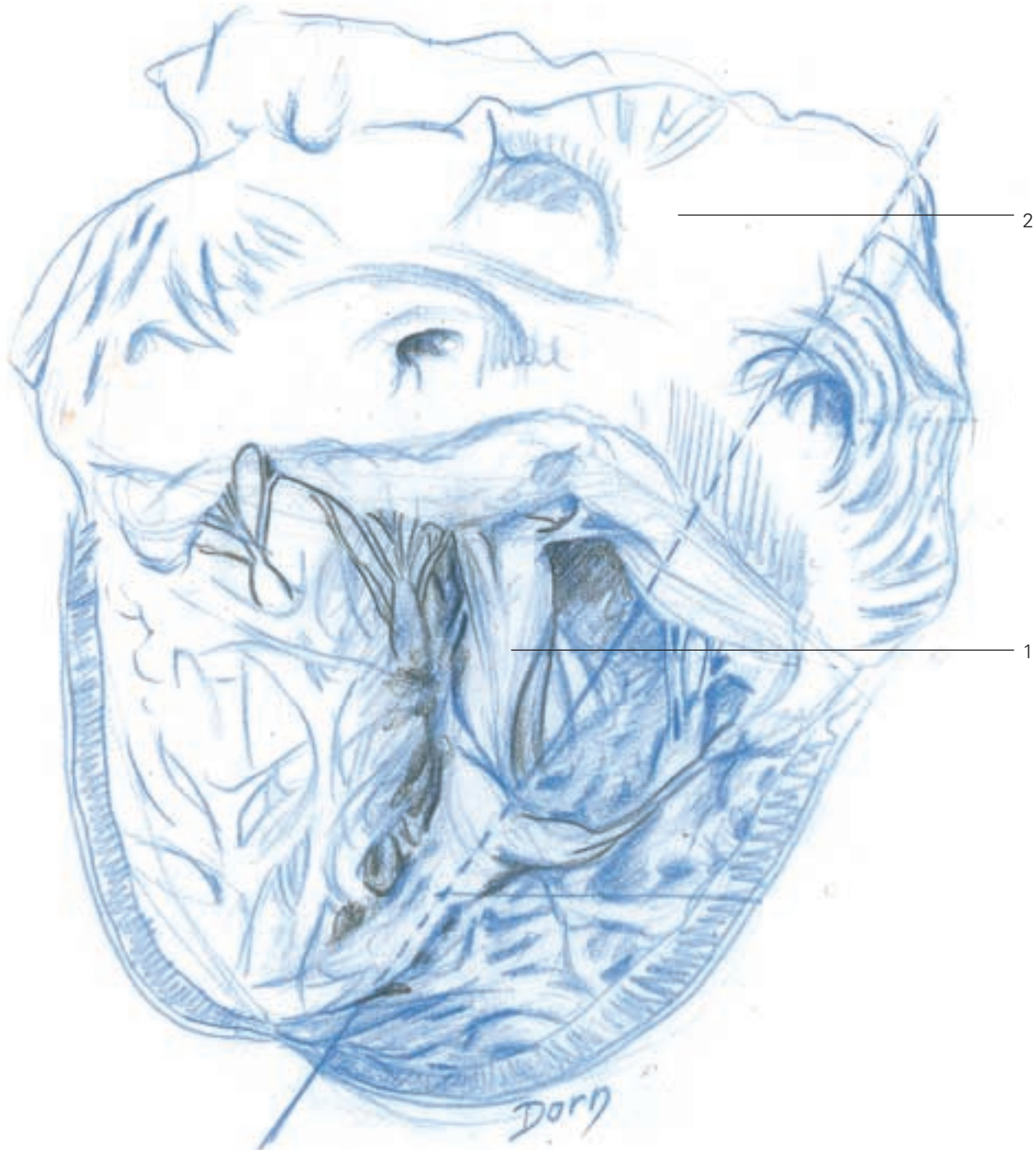
# Miscellaneous

---

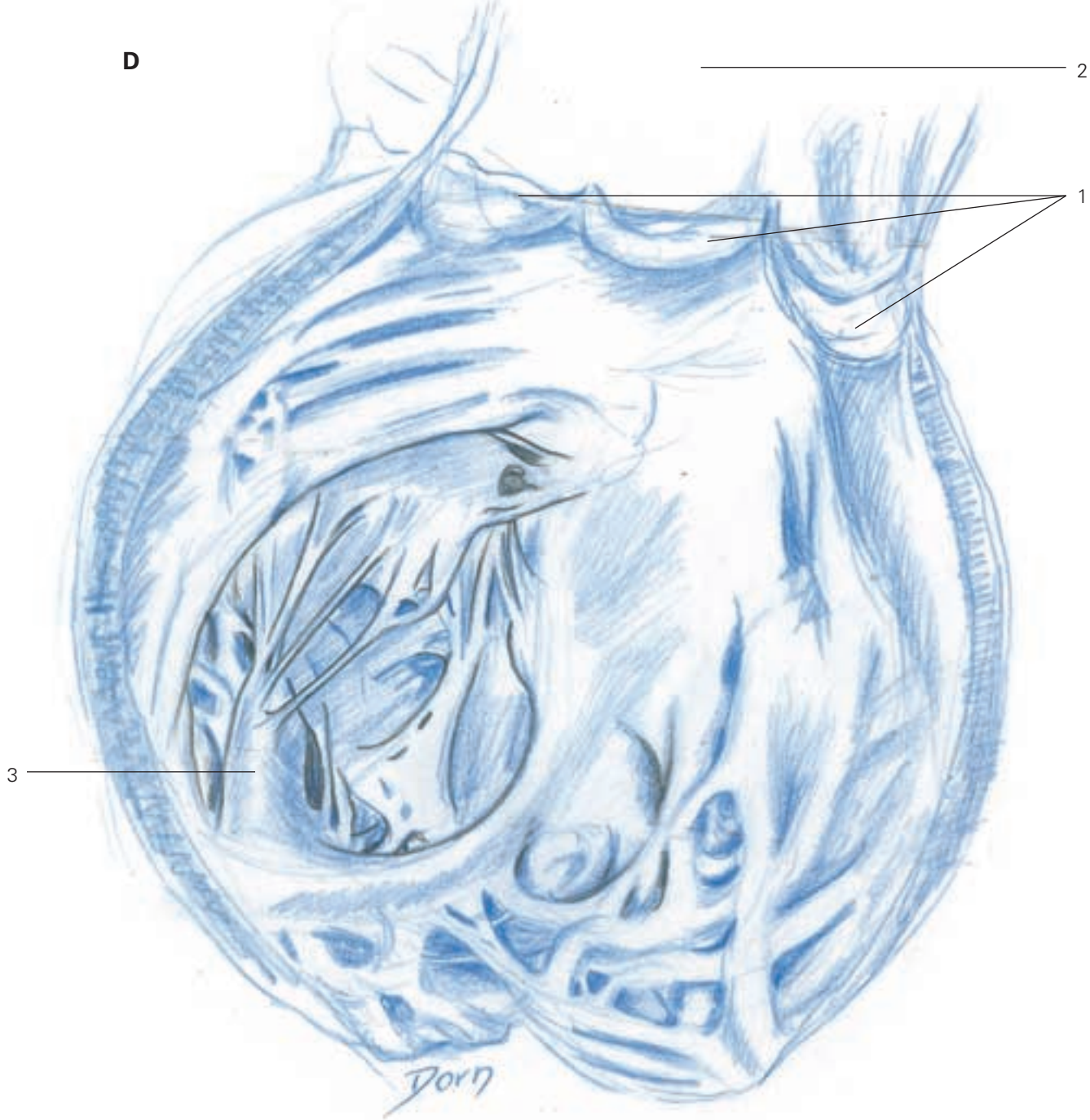
**B** The knife is introduced in the right auricle and the right ventricle is opened to the tip.



**C, D** The right ventricle is opened. The tricuspid valve and the papillary muscle are seen.



- 1 posterior papillary muscle
- 2 right atrium



**D**  
1 tricuspid valve  
2 right atrium  
3 posterior papillary muscle

# Index

---

- abdominal surgery 105-18
- abdominal wall 74
- acetabulum 189
  - cross-section through hip joint 177
  - exposures 177-90
  - extended iliofemoral approach 186
  - inguinal approach 182-6
    - posterior (Kocher-Langbeck) approach 178-81
- achondrogenesis 215
- acromion 141
- agenesis of kidneys 214
- Allen's test 24
- amniocentesis 218
- antiretrograde flow valves 107
- arm flap, lateral 2
- arteries
  - anterior interosseous 21
  - brachial 14
  - collateral 25
  - descending genicular 10
  - iliac
    - common 75
    - external 183
    - internal 75
  - interosseous
    - dorsal 39
    - posterior 18, 19
  - permeability (patency) test 24
  - peroneal
    - sural skin flap 9
    - vascularised fibula transfer 11, 12
  - radial
    - exposure of radial nerve at elbow 58
    - forearm radial flap 16, 17
    - ulnar 36, 37
- auditory canal reconstruction 208
- auricle
  - left 219-20
  - right 223-4
- back, muscle relief study of 198
- bladder
  - extrophy in young boy 81-5
    - bladder sutures 83
    - bone frame closure 84
    - muscular wall closure 85
    - skin flaps 81, 83
  - genital prolapse after hysterectomy 65
  - reconstruction 105, 106-9
    - antiretrograde flow valves 107
    - ileum isolation 106
    - ileum modification 107
    - ileum suture 106, 108
    - stabilisation 108
    - ureteric implantation 109
  - separation from vagina after genital prolapse 59-64
- blood supply *see* vascular supply
- bone
  - covering defects of 10
  - frame closure in bladder extrophy 84
  - transfer/transplantation
    - lumbar spondylolisthesis 124
    - patella allograft 175
    - scoliosis surgery 127
    - vascularised 10-13
- 'boutonnière' deformity 31-3
- brachial flap, lateral 14-15
- brachial plexus 49-53
  - anatomy 53
  - infraclavicular approach 51-2
  - supraclavicular approach 49-51
- bursae
  - in acetabulum 180, 181
  - subdeltoid 142
- calf, skin flap from 8
- canal wall down mastoidectomy 207
- canal wall up mastoidectomy 206
- cancellous bone
  - harvest/transplantation
    - lumbar spondylolisthesis 124
    - scoliosis surgery 127
- capsules
  - acetabulum 180, 181
  - ankle joint 193
  - glenohumeral joint 146
  - knee joint 173
  - trapeziometacarpal joint 28
  - vertebral 122
- carpal tunnel syndrome 36
- cervix, uterine 65
- clavicle
  - excision 137-8
  - exposure of brachial plexus 51
  - exposure of subacromial space 141
- cleidectomy 137-8
- clitoris plasty in feminisation 99, 101, 102
- compartments
  - of hand, Guyon's 36
  - of kidney in lithiasis 79
  - of leg 5
- congenital malformations 210-17
  - monstrous anomalies 217
  - of spine 210
  - tumours 212-14
- coracoid process 144
- corpora cavernosa
  - erectile function of penis, prosthesis for 90, 92, 94
  - feminisation 100, 102
  - hypospadias 87, 88
- corpora spongiosum 87, 88
- craniofacial surgery 10



- cul-de-sac of Douglas 64  
     elythrocele prevention 68  
     elythrocele treatment 70  
 cystic hygroma 213  
 cystic tumours  
     of kidneys 214  
     of lungs 212  
  
 defects, covering  
     of bone 10  
     of hand 17, 19  
     of heel 9  
     of knee 4  
     of lower limb 5  
 deltopectoral groove 143  
 diaphragmatic hernia 211  
 distal ulnar flap 2  
 Dorn, Léon vii, viii  
     evolution of style 139  
     on hands 23  
     his method ix  
         first stage sketch ix, x  
         second stage rough drawing ix, xi  
         third stage definitive drawing ix, xii  
 dorsal rachis 120-1  
 Douglas, cul-de-sac of 64  
     elythrocele prevention 68  
     elythrocele treatment 70  
 Dupuytren's disease 40-3  
     artery/nerve identification  
         at digitopalmar junction 42  
         in finger 41  
     radial side lesions 40  
     vertical septae, division of 43  
 dura mater 201  
  
 ear surgery 201-8  
     retroauricular/transvestibular  
         approach 201  
 écorché of Vésale 197  
 elythrocele  
     prevention 68  
     surgical treatment 70-2  
 endolymphatic sac 202  
 erectile function of penis, prosthesis  
     for 86, 90-6  
  
 Fallopian aqueduct 203  
 fasciocutaneous flaps 2  
 feminisation 97-104  
     clitoris plasty 99, 101, 102  
     final aspect 103  
     labia plasty 97, 103  
     vagina plasty 97  
  
 femur  
     distal metaphysis, flap from 10  
     posterior approach to shaft  
         154-6  
     recalcitrant non-union of 10  
 fetal abnormalities  
     detection 218  
     two-headed foetus 217  
 fibula transfer 11  
 finger, index, pollicisation of index  
     45-8  
     bone fixation/tendon suture 47  
     dissection of dorsal aspect 45  
     dissection of palmar structures  
         46  
     rotation 47  
 flaps  
     arm, lateral 2  
     brachial, lateral 14-15  
     from calf 8  
     distal ulnar 2  
     fasciocutaneous 2  
     feminisation 97, 99  
     free revascularised 2  
     hypospadias 89  
     interosseous, posterior 2, 18-19  
     island, pedicled 2, 10  
         distally based, with retrograde  
             blood flow 16  
     from lower limb 3-9  
     mucosal, in hypospadias 86  
         isolation 88  
         tubularisation 89  
     musculoperiosteal 143  
     neurocutaneous 8-9  
     osteoperiosteal 10  
     preputial 86  
     radial forearm 2  
     scapular 2  
     shoulder exposure 143  
     sural 8-9  
     sural skin 8-9  
     tree of, for upper limb 2  
     ulnar forearm 2  
     upper limb, tree of flaps for 2  
 forearm  
     interosseous nerve exposure  
         54-6  
     osteosynthesis of fracture 139-40  
     posterior interosseous flap  
         18-19  
     radial aspect anatomy 24  
     radial flap 16-17  
     radial flap pivot point 17  
     radial flaps 2  
     ulnar flaps 2  
  
 fractures  
     acetabulum  
         columns  
             anterior 182, 187  
             posterior 187  
     walls  
         anterior 182  
         posterior 178  
     forearm, osteosynthesis of  
         139-40  
     intra-articular, of hand 27  
     plate repair 139  
 free revascularised flaps 2  
  
 gastrectomy 110-14  
     jejunum, anastomoses with  
         112-14  
     oesogastrectomy 110-11  
 genital prolapse  
     after hysterectomy 65-9  
     lower approach 59-64  
 glans  
     erectile function of penis,  
         prosthesis for 90, 94  
     feminisation 102  
     hypospadias 89  
 Guyon's compartment 36  
 gynaecological surgery 59-72  
  
 hand  
     anatomy 24-6  
     covering defects of 17, 19  
     surgery 27-48  
 Harrington's rod 126, 128  
 heart anatomy 219-26  
     left heart 219-22  
     right heart 223-6  
 heel, covering defects of 9  
 hepatectomy, left 117  
     partial 118  
 hernia, diaphragmatic 211  
 humerus  
     lateral brachial flap 14, 15  
     shoulder implant stabilisation  
         136  
     subdeltoid approach to proximal  
         metaphysis 150  
 hygroma, cystic 213  
 hypogastric plexus, superior 129  
 hypospadias surgery 86-9  
     mucosal flap 86, 88, 89  
     skin flap 89  
 hysterectomy 66  
  
 ileum in bladder replacement 105,  
     106-7

- iliac crest 124  
 iliac fossa 184  
   internal 190  
 iliac wing, external 187  
 iliopsoas fascia 183  
 iliotibial tract 178  
 implantation  
   patella prosthesis 165-6  
   shoulder prosthesis 136  
   ureteric 109  
 interosseous flap, posterior 2,  
   18-19  
 intramedullar nail 140  
 ischium 180  
 island flaps, pedicled 2, 10  
   distally based, with retrograde  
   blood flow 16  
 jejunum 112-14  
 joints  
   acromioclavicular 138  
   ankle  
     neurovascular bundle 191  
     posteromedial approach to  
     191-3  
     posterior aspect 193  
   calcaneocuboid 195  
   DIP (distal interphalangeal) 31  
   distal radioulnar 44  
   elbow 57-8  
   femoropatellar 164-7  
   glenohumeral  
     anterior approach 143-6  
     capsule exposure/opening  
     146  
     muscle exposure 144-5  
     skin incision 143  
   axillary approach  
     joint exposure 149  
     neurovascular bundle 147-8  
     skin incision 147  
 hip  
   cross-section of 177  
   instability/dislocation 209  
 humeroradial, exposure of 151  
 knee  
   anatomy  
     anterior view 160-1  
     medial aspect 159  
   covering defect of 4  
   posterior approach 172  
   surgery 164-76  
     anteromedial approach 168  
     medial approach 164-7  
     posterolateral approach  
     168-71  
   midtarsal 194-5  
   PIP (proximal interphalangeal)  
     25  
     arthrolysis (limitation of  
     extension) 34-5  
     'boutonnière' deformity 31, 33  
   sternoclavicular  
     cleidectomy 138  
     dislocation 134-5  
     exposure 134  
   subtalar  
     exposure 195  
     lateral approach 194-5  
   talonavicular 195  
   trapeziometacarpal 28  
   wrist  
     distal radioulnar joint approach  
     44  
     posterior interosseous flap  
     pivot point 19  
     radial aspect anatomy 24  
 kidneys 73  
   agenesis 214  
   allotransplantation 74-8  
     skin incision 74  
     transplant presentation 76  
     vessel sutures 77, 78  
   cystic tumour 214  
   renal lithiasis  
     exposure 79-80  
     removal 80  
 Kocher-Langbeck (posterior)  
   approach 178-81  
 labia plasty in feminisation 97, 99,  
   103  
 laparoschisis 211  
 ligaments  
   coracoclavicular 138  
   costoclavicular  
     cleidectomy 138  
     repair/stabilisation 135  
   rupture 134  
 cruciate  
   anterior  
     anteromedial approach 168  
     posterolateral approach  
     168-71  
   posterior 172-3  
 deltoid 192  
 inguinal 190  
 ligamentum flavum 122  
 longitudinal, anterior 130  
 longitudinal, posterior 131  
 patellar, allograft of 174-6  
 radioulnar, posterior 44  
 ureterosacral  
   elythrocele treatment 72  
   genital prolapse  
     after hysterectomy 65, 67  
     lower approach 64  
 lithiasis, renal  
   exposure 79-80  
   removal 80  
 liver  
   hepatectomy, left 117  
     partial 118  
   lobes 106  
     distribution of cuts 115  
     distribution of vessels 115,  
     116  
   segmental resections 105  
   transplantation 105  
 lower limb  
   anatomy 154-63  
   covering defects of 5  
   flaps from 3-9  
   muscle relief study 200  
   surgery 153-93  
 lumbar disc hernia, anterior  
   approach to 129-31  
   disc excision 131  
   disc exposure 130  
 lumbar spondylolisthesis 122-5  
 lumbosacral plexus anatomy  
   162-3  
 lungs 121  
   cystic tumour 212  
 lymphangioma 213  
 macrosomia 216  
 macroglossia 216  
 mastoid canal 208  
 mastoidectomy  
   canal wall down procedure 207  
   canal wall up procedure 206  
 Ménière's disease 202  
 meningocele 210  
 mesentery in bladder replacement  
   106  
 metacarpals 28, 29  
 middle ear surgery  
   Shambaugh approach 205  
   transmeatal/extended transmeatal  
   approach 204  
 mitral valve 221  
 monstrous anomalies 217  
 mucosal flap in hypospadias 86  
   isolation 88  
   tubularisation 89

- muscles  
   biceps  
     approach to proximal third of radius 151  
     exposure of radial nerve at elbow 57  
     posterior approach to femoral shaft 155  
   biceps femoris 155  
   brachialis 57  
   brachioradialis  
     approach to proximal third of radius 151  
     exposure of radial nerve at elbow 57, 58  
   coracobiceps 144, 145  
   deltoid  
     glenohumeral joint approach to shoulder 144  
     subacromial space approach to shoulder 141  
     subdeltoid approach to proximal metaphysis of humerus 150  
   extensor carpi ulnaris 54  
   extensor digitorum brevis 195  
   extensor digitorum communis 54  
   extensor retinaculum, inferior 194  
   flexor hallucis longus 11  
   flexor retinaculum 191  
   gastrocnemius  
     approach to popliteal vessels 157  
     flap from lateral head 3-4  
     medial head 172, 173  
     soleus flap operation 5  
   gemelli 180  
   gluteal 187  
     gluteus maximus 178  
     gluteus medius 188  
     gluteus minimus 188  
   iliacus 190  
   iliopsoas 184, 185  
   ischiocavernosus 82  
   latissimus dorsi  
     flap vascular supply 2  
     transpleural approach to dorsal rachis 120  
   obturator internus 180  
   omohyoideus 49  
   papillary 221, 225  
   pectoralis major 144  
   pectoralis minor 51  
   pes anserinus 157  
   pisiformis 189  
   pronator quadratus  
     exposure 20  
     flap operation 20-1  
   pronator teres 57  
   psoas 183  
   relief studies 197-200  
   rotators of hip, external 179, 180, 188, 189  
   sartorius 190  
   scalenus anterior 49  
   semimembranosus 157  
   serratus anterior 2  
   soleus  
     approach to popliteal vessels 157  
     flap operation 5-7  
   subscapularis 146  
   supinator  
     approach to proximal third of radius 151  
     exposure of radial nerve at elbow 57  
     interosseous nerve exposure 55, 56  
   temporal 208  
   tensor fascia latae 188  
   of thenar eminence 28  
   tibialis posterior 11, 12  
   trapezium  
     removal 29  
     volar approach 27-30  
   vastus lateralis 155  
 musculoperiosteal flaps 143  
 myelomeningocele 210  
 nerves  
   axillary 148  
   cutaneous, lateral, of thigh 183  
   digital, common 46  
   facial  
     mastoidectomy 207  
     retroauricular/transvestibular approach 201  
     transmastoid approach 203  
   femoral 183  
   interosseous 54-6  
   of knee, medial aspect of 159  
   lumbosacral plexus anatomy 162-3  
   median 36-7  
   in penis, origins of 101  
   peripheral, surgery of 49-58  
   peroneal, common 4  
   posterior femoral cutaneous 154  
   radial  
     anterior 57-8  
     approach to proximal third of radius 151  
   exposure at elbow 57-8  
   posterior  
     exposure at elbow 57-8  
     interosseous nerve exposure 55  
   posterior interosseous flap 19  
   sciatic  
     extended iliofemoral approach to acetabulum 189  
     posterior (Kocher-Langbeck) approach to acetabulum 179  
   traumatic lesions 49  
   vestibular 201  
 neurocutaneous flaps 8-9  
 neurosurgery/ear surgery boundary 201  
 oesogastrectomy 110-11  
 oesophagus  
   excision in oesogastrectomy 110  
   stomach, anastomosis with 111  
   transpleural approach to dorsal rachis 121  
 omphalocele 216  
 omphalothoracopage 217  
 osteoperiosteal flap from femur 10  
 osteosynthesis of forearm fracture 139-40  
 paediatrics 209-17  
 patella 175  
   allograft of 174-6  
   prosthesis of 164-7  
     patellar preparation 166-7  
     trochlear implant 165-6  
   patellar retinaculi, lateral 175  
   Pavlick's harness 209  
 pedicles  
   adipofascial 8  
   neurovascular 101  
   vascular 1, 2  
 pelvic brim 185  
 penis  
   amputation for sexual ambiguity 97-104  
   corpora cavernosa  
     excision 102  
     release of 100  
   final aspect 103  
   neurovascular pedicles 101  
   release of penis 99  
   shortening 102  
   urogenital sinus incision 98

- bladder extrophy 82  
 curvature in hypospadias 87  
 nerves, origins of 101  
 prosthesis for erectile function 90-6  
 perineum  
   electrocele treatment 72  
   genital prolapse after hysterectomy 69  
 periosteum 11  
 peripheral nerve surgery 49-58  
 peritoneum  
   kidney allotransplantation 75  
   lumbar disc hernia treatment 129  
 plate repair of fracture 139  
 pleura 120  
 pollicisation of index finger 45-8  
   bone fixation/tendon suture 48  
   dissection of dorsal aspect 45  
   dissection of palmar structures 46  
   rotation 47  
 popliteal fossa 172  
 popliteal neurovascular bundle 158  
 popliteal vessels, extended medial approach to 157-9  
 preputial flap 86  
 prosthesis  
   for erectile function of penis  
     components 90  
     flaccid/erect state 91  
     placement 91, 96  
     surgical procedure 92-6  
   of patella 164-7  
   shoulder implant stabilisation 136  
 pubic ramus, superior 186  
  
 radial forearm flap 2  
 radius  
   anterior approach to proximal third 151  
   osteosynthesis of 139  
 reconstructive surgery 1-21  
   development of 1  
 rectum 70, 71  
 renal lithiasis  
   exposure 79-80  
   removal 80  
 renal pelvis 79, 80  
 retractile band 87  
 Retzius' space 91, 95  
 ribs 120  
  
 sacrococcygeal teratoma 213  
 scaphoid bone 39  
  
 scapular flaps 2  
 scoliosis surgery 126-8  
 scrotum 91, 95  
 sexual ambiguity  
   amputation of penis 97-104  
   diagrammatic representation 97  
 Shambaugh approach to middle ear 205  
 shoulder  
   bony landmarks 141  
   prosthetic implant stabilisation 136  
   surgical exposure 141-9  
     glenohumeral joint anterior approach 143-6  
     glenohumeral joint axillary approach 147-9  
     subacromial space anterior approach 141-3  
 skin flaps  
   from calf 8  
   in feminisation 97, 99  
   in hypospadias 89  
   sural 8-9  
 spermatic cord 183, 186  
 spina bifida 210  
 spinal cord 123  
 spinal surgery *see* vertebral column surgery  
 stomach  
   excision in oesogastrectomy 110, 112  
   oesophagus, anastomosis with 111  
 subacromial space, anterior approach to 141-3  
   musculoperiosteal flaps 143  
 subdeltoid bursa 142  
 sural skin flap 8-9  
  
 temporal aponeurosis graft 207, 208  
 temporal fascia graft 204, 208  
 tendons  
   Achilles'  
     posteromedial approach to ankle 193  
     soleus flap operation 6  
   biceps  
     approach to proximal third of radius 151  
     shoulder implant stabilisation 136  
   extensor 44  
   extensor digiti minimi 44  
   extensor, of hand  
     central band release/resection 32  
     central/lateral bands, suture of 33  
     lateral band release 31  
   flexor carpi radialis 29  
   flexor carpi ulnaris 38  
   flexor digitorum superficialis 26  
     blood supply 34, 35  
     transfer to thumb 38  
     vincula 34  
   flexor, of fingers 25  
   flexor profundus 26  
   to gastrocnemius medial head 172  
   lateral collateral 171  
   of popliteal muscle 171  
   semitendinosus 155  
   subscapularis 149  
   of tibialis posterior 192  
 teratoma, sacrococcygeal 213  
 thoracotomy 120-1  
 transplantation  
   bone  
     lumbar spondylolisthesis 124  
     patella allograft 175  
     scoliosis surgery 127  
     vascularised 10-13  
   kidneys 74-8  
     skin incision 74  
     transplant presentation 76  
     vessel sutures 77, 78  
   liver 105  
   patella/patellar ligament allograft 174-6  
   temporal fascia graft 204  
   tympanic graft 206-8  
 trapeziectomy 27, 29  
 tree of flaps for upper limb 2  
 tricuspid valve 225  
 Tubiana, Raoul 23, 40  
 tunnel syndromes 49  
   carpal 36  
 tympanic cavity exploration 207  
 tympanic graft 206-8  
 tympanoplasty 207  
  
 ulna, osteosynthesis of 140  
 ulnar forearm flap 2  
 ultrasound-guided amniocentesis 218  
 upper limb  
   flaps 2, 14-21  
   muscle relief study 199  
   nerve surgery 49  
   surgery 133-51  
     *see also* hand, surgery

# Index

---

- ureters
    - bladder replacement 109
    - genital prolapse after hysterectomy 65
    - renal lithiasis 79
    - sparing in elythrocele treatment 70
  - urethra
    - bladder extrophy 83
    - hypospadias 86, 87, 88
  - urethral canal reconstruction 86
  - urethral meatus, external 86, 88
  - urinary bladder *see* bladder
  - urinary tract anomalies, congenital 214
  - urogenital sinus 97, 98, 99
  - urological surgery 73-104
  - uterus 70, 71
    - cervix 65
  - vascularised fibula transfer 11
  - vascularised osteoperiosteal flap from femur 10
  - vagina
    - elythrocele treatment 70
  - genital prolapse after hysterectomy 67
  - plasty in feminisation 97
  - separation from bladder after genital prolapse 59-64
    - posterior aspect 63
  - valves, antiretrograde flow 107
  - vascular supply
    - flexor profundus 26
    - flexor tendons of fingers 25
    - knee, medial aspect of 159
    - liver lobes 115
    - upper limb flaps 2
  - vascularised bone transfers 10-13, 38
    - from distal metaphysis of femur 10
    - from metaphysis of second metacarpal 39
  - veins
    - anastomosis in kidney allotransplantation 77, 78
    - azygos 121
    - iliac, external 76, 183
    - iliac, internal 75
  - peroneal 11, 12
  - pulmonary 219
  - ulnar 37
- vena cavae 223
  - ventricle
    - left 221-2
    - right 225-6
  - vertebrae
    - fusion
      - lumbar spondylolisthesis 122, 124, 125
      - scoliosis surgery 127
    - resection
      - lumbar spondylolisthesis 122
      - scoliosis surgery 127
    - resection of posterior segment 123
    - sacral promontory exposure 129
  - vertebral bodies, distraction of 131
  - vertebral column surgery 119-31
  - vertebral disc hernia, anterior
    - approach to 129-31
    - disc excision 131
    - disc exposure 130

# An Atlas of Surgical Anatomy

*Alain C Masquelet, MD*

*Consultant Orthopaedic Surgeon, Hôpital Avicenne, Bobigny*

The author of a number of acclaimed and best-selling surgical atlases has here collaborated again with their distinguished award-winning artist to produce another invaluable resource to guide all surgeons, whether in training or in practice. Hand surgery and microsurgery form the core of the book, but all other parts of the body are also represented. The artwork is available to download from an integral CD-ROM, which will be a much-sought aid to embellish lectures and presentations. The accompanying text contains a commentary on points of surgical and clinical interest arising.

Alain C Masquelet's previous publications with Léon Dorn include *An Atlas of Surgical Exposures of the Upper Extremity* (1990), *An Atlas of Surgical Exposures of the Lower Extremity* (1993), *An Atlas of Flaps in Limb Reconstruction* (1995, winner of the Royal Society of Medicine Atlas award), *An Atlas of Surgical Techniques of the Hand and Wrist* (1999), *An Atlas of Surgical Exposures of the Upper and Lower Extremities* (2000), and *An Atlas of Flaps of the Musculoskeletal System* (2001); some of the preliminary drawings for these atlases are now published here, as well as some of the finished illustrations. Léon Dorn's preliminary artwork for a number of other landmark publications from his long career is also included.

## *Contents*

*Reconstructive surgery • Hand and peripheral nerve surgery • Gynaecological surgery • Urological surgery • Abdominal surgery • Surgery of the vertebral column • Upper limb surgery • Lower limb surgery • Miscellaneous*

*With 300 illustrations by Léon Dorn*



Taylor & Francis  
Taylor & Francis Group

[www.tandf.co.uk/medicine](http://www.tandf.co.uk/medicine)

ISBN 1-84184-405-5



9 781841 844053